

## Small bowel obstruction: a recurrence of melanoma during the second trimester of pregnancy

Lindsay Goad, BS, MD,<sup>1</sup> Yousef Zakharia, MD,<sup>2</sup> Heather Anaya, MS, DO<sup>3</sup>

**Keywords:** Metastatic melanoma, pregnancy, immunotherapy

### Abstract

*Background:* The incidence of melanoma is on the rise in the United States and is particularly prevalent among women of childbearing age. Obtaining a complete history and understanding the unpredictable behavior of melanoma is essential to make the diagnosis of recurrent disease during pregnancy.

*Case:* A 35-year-old G2P1 at 23 weeks and 1 days' gestation with a remote history of (treated) cutaneous melanoma underwent an exploratory laparotomy for small bowel obstruction. Pathology was consistent with recurrent metastatic melanoma.

*Conclusion:* Metastatic melanoma diagnosed during pregnancy is rare. There are no guidelines on how or when to proceed with treatment of metastatic disease or delivery of the fetus. Immunotherapy is changing the management of melanoma and is extending life expectancy. The significant survival benefits for mother with immunotherapy may outweigh the risks of preterm delivery for the baby.

<sup>1</sup>University of Iowa Carver College of Medicine, Iowa City, Iowa

<sup>2</sup>University of Iowa Hospitals and Clinics, Department of Internal Medicine, Iowa City, Iowa

<sup>3</sup>University of Iowa Hospitals and Clinics, Department of Obstetrics and Gynecology, Iowa City, Iowa

### Introduction

Melanoma is the most fatal form of skin cancer and is the sixth most common malignancy diagnosed in women.<sup>1</sup> The incidence has risen more than any other type of cancer in the last 50 years.<sup>2</sup> Melanoma is particularly prevalent among women of childbearing age and is a common malignancy diagnosed in pregnancy, accounting for 8% of all malignancies arising during gestation.<sup>3,4</sup> About one third of patients diagnosed with melanoma will have a recurrence later in life.<sup>5</sup> Although it is rare, recurrence can present many years later with metastatic disease, with a historical 5-year survival rate of less than 5%.<sup>2</sup>

There are few cases in the literature in which a patient presents with metastatic melanoma during pregnancy. The

Please cite this paper as: Goad L, Zakharia Y, Anaya A. Small bowel obstruction: a recurrence of melanoma during the second trimester of pregnancy. *Proc Obstet Gynecol.* 2017;7(3): Article 5 [ 7 p.]. Available from: <http://ir.uiowa.edu/pog/> Free full text article.

**Corresponding author:** Lindsay Goad, BS, MD, University of Iowa Carver College of Medicine, 375 Newton Road, Iowa City, IA 52242; Telephone: 847-414-8422 Email: [lindsay-goad@uiowa.edu](mailto:lindsay-goad@uiowa.edu); [lindsay.goad@gmail.com](mailto:lindsay.goad@gmail.com)

**Financial Disclosure:** The authors report no conflict of interest.

Copyright: © 2017 Goad et al. This is an open-access article distributed under the terms of the Creative Commons Attribution License, which permits unrestricted use, distribution, and reproduction in any medium, provided the original author and source are credited.

majority of cases are diagnosed as a clinically localized skin lesion; few cases present as advanced stage disease, therefore it is unlikely to be included on the list of differential diagnoses. This disease has serious consequences for both mother and fetus. We present a unique case of small bowel obstruction in the second trimester of pregnancy consistent with recurrent metastatic melanoma. Melanoma most commonly metastasizes to the lung, liver, bone and brain and is the most common malignancy to metastasize to the placenta and fetus, although this is exceptionally rare.<sup>1,5</sup> It can be diagnosed early in symptomatic presentation with the appropriate imaging, but can be overlooked. It is integral to patient care that a complete history is obtained and that clinicians understand the variable and unpredictable behavior of melanoma as it continues to become more prevalent.

### **Case**

In January 2016, a 35-year-old woman at 23 weeks and 1-day gestation presented to a local hospital with intractable nausea, vomiting, diffuse abdominal pain and a 10-lb weight loss since her first trimester. She reported having intermittent nausea, vomiting and abdominal cramping for the past two months and was hospitalized overnight early in the course for "gastritis." Symptoms were thought to be related to pregnancy and were treated accordingly. On presentation, she was afebrile but tachycardic. Her physical exam was significant for an acute abdomen with rebound tenderness and guarding. Abdominal x-ray was concerning for small bowel obstruction.

Chest x-ray revealed a left mid lung lesion measuring 4.0 x 3.8 cm. The patient's past medical history was significant for BRAF negative melanoma diagnosed in 2005 on the right shoulder at an outside hospital. Breslow depth and staging information was not available. She had a wide local excision and negative sentinel node biopsy that required no adjuvant therapy. She had been followed by dermatology biannually with the most recent skin exam in the spring of 2015 at which time she had a premalignant lesion excised from her right ankle.

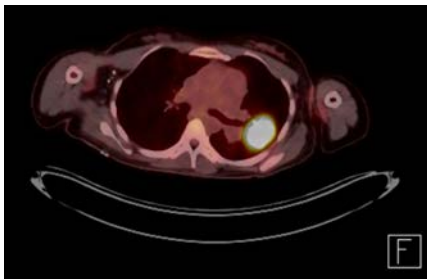
The patient was transferred to a local tertiary care center and underwent an exploratory laparotomy. Intraoperatively, a mass within the small bowel causing an intussusception was excised and the intussusception was reduced. No bowel resection was performed. Multiple liver nodules were seen and a superficial lesion was excised by wedge biopsy and many enlarged lymph nodes were excised from the mesentery. Pathology of the small bowel mass and liver lesion was consistent with BRAF negative metastatic melanoma. Lymph nodes were negative.

Following surgery, she presented to our department at 25 weeks and 2 days' gestation for a treatment plan. The neonatal intensive care unit was consulted to discuss preterm delivery and fetal viability. Due to the urgent need for treatment and the availability of new immunotherapy, the patient opted for preterm delivery in the 27th week of gestation. A full course of corticosteroids was given for lung maturity prior to delivery. Patient underwent an uncomplicated classical cesarean

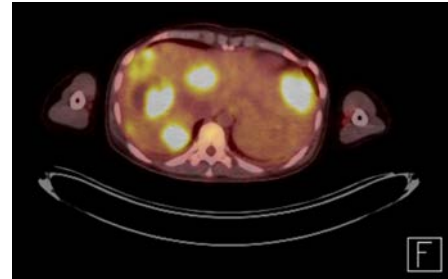
section due to breech presentation of a male fetus weighing 1223 grams at 27 weeks 4 days' gestation. Apgars were 7 and 8 at 1 minute and 5 minutes respectively and the neonate was transferred to the neonatal intensive care unit. Placenta evaluation by pathology was negative for melanoma metastasis. The baby did well and was discharged home from the neonatal intensive care unit on day of life 66 with a weight of 2860 grams.

A positron emission tomography-computed tomography (PET/CT) scan three days following delivery showed significant lesions in the liver, left lung and gastric outlet. Brain magnetic resonance imaging (MRI) was negative for brain metastasis.(Figure1, Figure 2)

#### **Pre-Immunotherapy PET/CT scans**



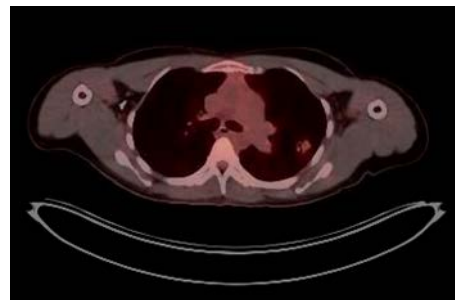
**Figure 1: Chest PET CT, notable for left lung lesion**



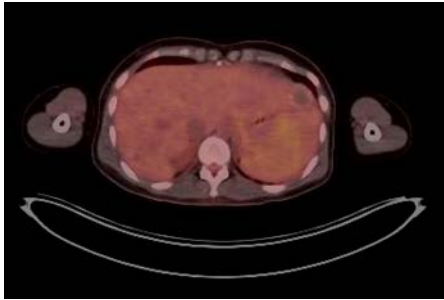
**Figure 2: Abdominal PET/CT, notable for several liver lesion**

The patient was started on an immunotherapy regimen of nivolumab (1mg/kg) and ipilimumab (3mg/kg) two weeks following delivery. She received combination therapy every three weeks followed by nivolumab alone every 2 weeks per the standard of care. A repeat PET/CT scan after four and eight cycles of treatment revealed partial response with smaller lesions and significantly less fludeoxyglucose (FDG) uptake; no new lesions were noted.

#### **Post 24 cycles of immunotherapy PET/CT scans**



**Figure 3: Chest PET/CT, notable for small lung lesion with minimal FDG uptake**



**Figure 4: Abdominal PET/CT, notable for several hyperdense hepatic lesions with no FDG uptake**

A repeat PET/CT scan after 24 cycles showed a stable, significantly improved from baseline, lung lesion with low-level FDG uptake and several hyperdense hepatic lesions with no FDG uptake, consistent with treated metastases.(Figure 3, Figure 4) She tolerated therapy well with minor gastrointestinal side effects.

### **Discussion**

Many studies have assessed whether pregnancy affects the prognosis and survival of women diagnosed with clinically localized melanoma during gestation. The consensus is that pregnancy does not adversely impact the prognosis or survival of women with localized cutaneous disease.<sup>6</sup> Due to the rarity of advanced stage disease on presentation, there are few cases in the literature in which a patient presents with metastatic melanoma during pregnancy. Therefore, there are no guidelines on how or when to proceed with treatment of the disease or delivery of the fetus. In the past, most women diagnosed with metastatic melanoma during pregnancy have either delivered at term and had poor outcomes with mortality within 12 months from

metastatic treatment refractory disease or opted for pregnancy termination.<sup>7</sup> There has been one previously published case report in which a woman was delivered prematurely at 28 weeks, received combination chemotherapy but died four months after delivery. Sadly, the baby died of septicemia at three months of age, a common complication of preterm delivery.<sup>8</sup> To our knowledge, this is the first case in the literature in which the survival benefits of immunotherapy outweighed the risks of preterm delivery at 27 weeks and resulted in positive outcomes for mother and baby.

It is common for pregnant women to present for care for fatigue, nausea, vomiting and abdominal pain during pregnancy and the differential diagnosis should be broad. It is imperative that a thorough history is completed, including past medical history of remote malignant disease as it can manifest many years later with detrimental effects to pregnant women and their fetus. Both patients and healthcare providers often do not recognize persistent symptoms as features of recurrence and the early presentation of a more serious diagnosis. The majority of melanoma recurrence occurs in the first three years (early recurrent); less than 7% of recurrences occur 10 or more years (late recurrent) after initial diagnosis.<sup>5,9</sup> Thus, presentation to care is delayed and the diagnosis is missed initially by clinicians.

The management for metastatic melanoma has changed dramatically over the past 5 years as new targeted immunotherapies have become available. The targeted BRAF inhibitors,

dabrafenib and vemurafenib, are now FDA approved. BRAF is a human proto-oncogene that makes the protein B-raf and is commonly seen in many different cancer types, including 50% of melanomas.<sup>10</sup> There is one published case report in which vemurafenib therapy was initiated during pregnancy for BRAF positive metastatic melanoma. While the fetus did well despite premature birth at 30 weeks, there was a poor maternal outcome with death about two months following delivery due to rapidly progressive metastatic disease.<sup>11</sup> Among the immunotherapy agents, ipilimumab (a cytotoxic T-lymphocyte-associated antigen 4 [CTLA-4] checkpoint inhibitor) was FDA approved in 2011 and was the first agent to demonstrate fairly good activity with an overall 3-year survival rate of 20% in patients with metastatic melanoma.<sup>12</sup> More promising results with less toxic adverse events are achieved with the newer generation PD-1 (programmed death 1) checkpoint inhibitors, nivolumab and pembrolizumab, both were approved for the treatment of metastatic melanoma by the FDA in 2014. These therapies have shown improved objective responses in 30% of patients while combination therapy with nivolumab and ipilimumab has resulted in significantly longer progression-free survival and objective response rates in 50 to 60% of patients with metastatic disease.<sup>13,14</sup> Although this new immunotherapy has not been studied in pregnancy, the positive survival outcomes, especially in BRAF negative disease, have proven the importance of treating metastatic melanoma aggressively and may be an indication for preterm delivery. The one-year national survival rate for an infant

delivered at 27 weeks is about 90%.<sup>15</sup>

## **Conclusions**

We hope this case emphasizes the significance of taking a complete history and serves to remind clinicians of the unpredictable behavior of recurrent melanoma as well as the importance of considering it when forming a differential diagnosis. Early diagnosis can change the clinical management of pregnancy and can save the life of the mother and fetus. Preterm delivery may be indicated in the future as new melanoma therapies have shown improved maternal survival outcomes in a previously dismal disease. It is imperative that care is referred to a tertiary center with the appropriate multidisciplinary team in a timely manner.

## **References**

1. Schwartz JL, Mozurkewich EL, Johnson TM. Current management of patients with melanoma who are pregnant, want to get pregnant, or do not want to get pregnant. *Cancer*. 2003 May 1;97(9):2130-3. <https://doi.org/10.1002/cncr.11342> PubMed PMID: 12712462.
2. Erdei E, Torres SM. A new understanding in the epidemiology of melanoma. *Expert Rev Anticancer Ther*. 2010 Nov;10(11):1811-23. <https://doi.org/10.1586/era.10.170> PubMed PMID: 21080806; PubMed Central PMCID: PMC3074354.



3. Wielowieyska-Szybińska DK, Spałkowska M, Wojas-Pelc A. Melanoma in pregnancy: a case report and review of the literature. *Postepy Dermatol Alergol.* 2015 Dec;32(6):483-7. <https://doi.org/10.5114/pdia.2014.44006> Epub 2015 Dec 11. PubMed PMID:26755917; PubMed Central PMCID: PMC4697016.
4. Jhaveri MB, Driscoll MS, Grant-Kels JM. Melanoma in pregnancy. *Clin Obstet Gynecol.* 2011 Dec;54(4):537-45. <https://doi.org/10.1097/GRF.0b013e318236e18b> PubMed PMID: 22031244.
5. Tas F. Metastatic behavior in melanoma: timing, pattern, survival, and influencing factors. *J Oncol.* 2012;2012:647684. <https://doi.org/10.1155/2012/647684> Epub 2012 Jun 27. PubMed PMID: 22792102; PubMed Central PMCID: PMC3391929.
6. Brady MS, Noce NS. Pregnancy is Not Detrimental to the Melanoma Patient with Clinically Localized Disease. *J Clin Aesthet Dermatol.* 2010 Mar;3(3):22-8. PubMed PMID: 20725540; PubMed Central PMCID: PMC2921744.
7. Beyeler M, Hafner J, Beinder E, Fauchère JC, Stoeckli SJ, Fehr M, Dummer R. Special considerations for stage IV melanoma during pregnancy. *Arch Dermatol.* 2005 Sep;141(9):1077-9. <https://doi.org/10.1001/archderm.141.9.1077> PubMed PMID: 16172302.
8. Mathew M, Sheik S, Rao K, Burney IA, Sawhney S, Al-Hamdani A. Metastatic Malignant Melanoma during Pregnancy: Case report and a Review of the literature. *Sultan Qaboos Univ Med J.* 2009 Apr;9(1):79-83. Epub 2009 Mar 16. PubMed PMID: 21509280; PubMed Central PMCID: PMC3074747.
9. Faries MB, Steen S, Ye X, Sim M, Morton DL. Late recurrence in melanoma: clinical implications of lost dormancy. *J Am Coll Surg.* 2013 Jul;217(1):27-34; discussion 34-6. <https://doi.org/10.1016/j.jamcollsurg.2013.03.007> Epub 2013 May 3. PubMed PMID: 23643694; PubMed Central PMCID: PMC3731060.
10. Ascierto PA, Kirkwood JM, Grob JJ, Simeone E, Grimaldi AM, Maio M, Palmieri G, Testori A, Marincola FM, Mozzillo N. The role of BRAF V600 mutation in melanoma. *J Transl Med.* 2012 Jul 9;10:85. <https://doi.org/10.1186/1479-5876-10-85> PubMed PMID: 22554099; PubMed Central PMCID: PMC3391993.
11. Maleka A, Enblad G, Sjörs G, Lindqvist A, Ullenhag GJ. Treatment of metastatic malignant melanoma with vemurafenib during pregnancy. *J Clin Oncol.* 2013 Apr 10;31(11):e192-3. <https://doi.org/10.1200/JCO.2012.45.2870> Epub 2013 Feb 11. PubMed PMID: 23401457.
12. Schadendorf D, Hodi FS, Robert C, Weber JS, Margolin K, Hamid O, Patt D, Chen TT, Berman DM, Wolchok JD. Pooled Analysis of Long-Term Survival Data From Phase II and Phase III Trials of Ipilimumab in Unresectable or Metastatic Melanoma. *J Clin Oncol.* 2015 Jun 10;33(17):1889-94. <https://doi.org/10.1200/JCO.2014.56.2736> Epub 2015 Feb 9. PubMed PMID: 25667295; PubMed Central PMCID: PMC5089162.

13. Robert C, Schachter J, Long GV, Arance A, Grob JJ, Mortier L, Daud A, Carlino MS, McNeil C, Lotem M, Larkin J, Lorigan P, Neyns B, Blank CU, Hamid O, Mateus C, Shapira-Frommer R, Kosh M, Zhou H, Ibrahim N, Ebbinghaus S, Ribas A; KEYNOTE-006 investigators. Pembrolizumab versus Ipilimumab in Advanced Melanoma. *N Engl J Med.* 2015 Jun 25;372(26):2521-32. <https://doi.org/10.1056/NEJMoa1503093> Epub 2015 Apr 19. PubMed PMID: 25891173.
14. Larkin J, Hodi FS, Wolchok JD. Combined Nivolumab and Ipilimumab or Monotherapy in Untreated Melanoma. *N Engl J Med.* 2015 Sep 24;373(13):1270-1. <https://doi.org/10.1056/NEJMc1509660> PubMed PMID: 26398076.
15. March of Dimes. What's the outlook for premature babies born before 28, 31, 33, or 36 weeks? babycenter. 04 Oct. 2015. [https://www.babycenter.com/0\\_whats-the-outlook-for-premature-babies-born-before-28-31-33\\_10300031.bc](https://www.babycenter.com/0_whats-the-outlook-for-premature-babies-born-before-28-31-33_10300031.bc)