



**University of Dundee**

**Patient and physician satisfaction in an observational study with methyl aminolevulinate daylight-photodynamic therapy in the treatment of multiple actinic keratoses of the face and scalp in 6 European countries**

Fargnoli, M. C.; Ibbotson, S. H.; Hunger, R. E.; Rostain, G.; Gaastra, M. T. W.; Eibenschutz, L.; Cantisani, C.; Venema, A. W.; Medina, S.; Kerrouche, N.; Pérez-Garcia, B.

*Published in:*

Journal of the European Academy of Dermatology and Venereology

*DOI:*

[10.1111/jdv.14691](https://doi.org/10.1111/jdv.14691)

*Publication date:*

2017

*Document Version*

Publisher's PDF, also known as Version of record

[Link to publication in Discovery Research Portal](#)

*Citation for published version (APA):*

Fargnoli, M. C., Ibbotson, S. H., Hunger, R. E., Rostain, G., Gaastra, M. T. W., Eibenschutz, L., ... Pérez-Garcia, B. (2017). Patient and physician satisfaction in an observational study with methyl aminolevulinate daylight-photodynamic therapy in the treatment of multiple actinic keratoses of the face and scalp in 6 European countries. *Journal of the European Academy of Dermatology and Venereology*, 32(5), 757-765. <https://doi.org/10.1111/jdv.14691>

**General rights**

Copyright and moral rights for the publications made accessible in Discovery Research Portal are retained by the authors and/or other copyright owners and it is a condition of accessing publications that users recognise and abide by the legal requirements associated with these rights.

- Users may download and print one copy of any publication from Discovery Research Portal for the purpose of private study or research.
- You may not further distribute the material or use it for any profit-making activity or commercial gain.
- You may freely distribute the URL identifying the publication in the public portal.

## ORIGINAL ARTICLE

# Patient and physician satisfaction in an observational study with methyl aminolevulinate daylight photodynamic therapy in the treatment of multiple actinic keratoses of the face and scalp in six European countries

M.C. Fargnoli,<sup>1,\*</sup> S.H. Ibbotson,<sup>2</sup> R.E. Hunger,<sup>3</sup> G. Rostain,<sup>4</sup> M.T.W. Gaastra,<sup>5</sup> L. Eibenschutz,<sup>6</sup> C. Cantisani,<sup>7</sup> A.W. Venema,<sup>8</sup> S. Medina,<sup>9</sup> N. Kerrouche,<sup>10</sup> B. Pérez-García<sup>11</sup>

<sup>1</sup>Department of Dermatology, University of L'Aquila, L'Aquila, Italy

<sup>2</sup>Photobiology Unit, Ninewells Hospital & Medical School, University of Dundee, Dundee, UK

<sup>3</sup>Department of Dermatology, Bern University Hospital, Inselspital, Bern, Switzerland

<sup>4</sup>Private Practice, Nice, France

<sup>5</sup>Centrum Oosterwal, Alkmaar, The Netherlands

<sup>6</sup>Dermato Oncology Unit, San Gallicano Dermatological Institute, Rome, Italy

<sup>7</sup>Department of Dermatology, Policlinico Umberto I, Sapienza University of Rome, Rome, Italy

<sup>8</sup>Europaweg, Assen, The Netherlands

<sup>9</sup>Dermatology Department, Príncipe de Asturias University Hospital, Madrid, Spain

<sup>10</sup>Galderma R&D, Sophia Antipolis, France

<sup>11</sup>Department of Dermatology, Ramón y Cajal University Hospital, Madrid, Spain

\*Correspondence: M.C. Fargnoli. E-mail: mariaconcetta.fargnoli@univaq.it

## Abstract

**Background** Guidelines recommend treating actinic keratoses (AKs) as they are recognized as precursors of invasive squamous cell carcinoma.

**Objective** The objective of this study was to collect real-world clinical data on the use of methyl aminolevulinate daylight photodynamic therapy (MAL DL-PDT) for the treatment of face and scalp AK in Europe.

**Methods** A prospective, multicenter, non-interventional study was conducted in six European countries in patients receiving a single treatment of MAL DL-PDT for face and/or scalp AK. Patient-reported outcomes were assessed by patient questionnaires at baseline and at 3 months after treatment, efficacy was assessed at 3 months using a 6-point global improvement scale, and adverse events (AE) were recorded at each visit.

**Results** Overall, 325 patients were enrolled from 52 investigational centres, 314 of whom attended the 3-month visit. Most patients had multiple lesions (58.4% had >10 lesions) with lesions mainly located on the scalp (60.0%) and/or forehead (54.2%). AKs were predominantly grade I (39.4%) or grade II (33.2%), and 10.5% of patients had grade III lesions. The proportions of patients and physicians that were overall satisfied to very satisfied with the MAL DL-PDT treatment were 80.4% and 90.3%, respectively. The vast majority of patients (90.0%) would consider using MAL DL-PDT again if needed. Physician-assessed efficacy at 3 months was at least much improved in 83.5% of patients, with 45.9% of patients requiring no retreatment. Related AEs were reported in 15% of patients.

**Conclusion** Use of MAL DL-PDT for multiple face and/or scalp AKs resulted in high levels of patient and physician satisfaction in clinical practice in Europe, reflecting the good efficacy and high tolerability of this convenient procedure.

Received: 18 August 2017; Accepted: 3 November 2017

## Conflicts of interest

All investigators or their institutions received financial support from Galderma R&D for conducting the study. MCF has acted as a paid consultant and lecturer for Galderma and has received research funding from Galderma. SI has received honoraria from Galderma and Spirit Healthcare. AWV has acted as a paid consultant for Galderma. NK is a full-time employee of Galderma R&D.

## Funding sources

The study was funded by Galderma R&D.

The copyright line for this article was changed on 27 July 2018 after original online publication.

## Introduction

Prevalence rates of actinic keratosis (AK) in Europe are increasing with the ageing population. A multicenter study across eight European countries confirmed the importance of chronic and high intermittent UV exposure, fair skin type and red or blonde hair as important risk factors for AK.<sup>1</sup>

Although not all AKs will progress to invasive squamous cell carcinoma (SCC) and some may regress, guidelines recommend treating AK as they are recognized as precursors of invasive SCC.<sup>2</sup>

Photodynamic therapy (PDT) is recommended as a first-line treatment for individual (lesion-directed therapy) or multiple and/or confluent AKs (field therapy) and has the potential to delay/reduce the development of new lesions.<sup>2-4</sup> Methyl aminolevulinate (MAL) cream with red light (conventional PDT; c-PDT) is indicated for the treatment of thin or non-hyperkeratotic and non-pigmented AKs on the face and scalp, superficial and/or nodular basal cell carcinoma and SCC *in situ* (Bowen's disease). More recently, MAL with daylight (MAL DL-PDT) has shown good efficacy and safety in the treatment of face and scalp, mild-to-moderate AK in multiple studies and has been approved in many countries for this indication.<sup>5,6</sup> In a randomized, controlled trial in Europe, MAL DL-PDT demonstrated similar efficacy, better tolerability with less pain and resulted in higher subject satisfaction compared to MAL c-PDT.<sup>6</sup> Furthermore, a structured expert consensus statement on AK recently rated MAL DL-PDT as the preferred option for patients with multiple AKs on both small and large fields due to its efficacy and tolerability profile.<sup>7</sup>

The objective of this study was to generate real-world data on patient and physician satisfaction, as well as efficacy and safety, of MAL DL-PDT in the treatment of face and scalp, mild-to-moderate AK in Europe.

## Methods

### Study design

A prospective, multicenter, non-interventional study was conducted in six European countries (Italy, Spain, France, the Netherlands, Switzerland and the United Kingdom) at a total of 52 sites. Eligible patients were aged 18 years or older and had been prescribed MAL DL-PDT as part of their routine medical care to treat mild-to-moderate AK on the face and/or scalp.

The study was conducted in accordance with the Declaration of Helsinki, the International Conference on Harmonization-Good Clinical Practice principles and in compliance with local regulatory requirements. The study was reviewed and approved by the appropriate Independent Ethics Committees, and written informed consent was obtained from all patients prior to study initiation. The study is registered at ClinicalTrials.gov identifier NCT02674048.

### Treatment

A single treatment of MAL DL-PDT was administered (Metvix<sup>®</sup>/Metvixia<sup>®</sup>, Galderma, Laboratories, Paris, France) according to the local Summary of Product Characteristics.

### Assessments

At baseline, the number and global severity of AK lesions were assessed by the physician and a follow-up visit for reassessment was proposed at 3 months. Efficacy was assessed using a 6-point global improvement scale from 1 (clear) to 6 (worse). Patient-reported outcomes were assessed by patient questionnaires at baseline and at 3 months. Each physician completed a questionnaire when all their study patients had completed the study. Post-treatment pain was assessed after treatment administration on a numerical rating scale (NRS) from 0 (no pain) to 10 (extreme pain). Incidence and severity of adverse events (AE) were recorded at each study visit.

### Statistical methods

All collected variables were descriptively summarized without replacement of any missing values (observed data only).

## Results

### Study population

Between April 2016 and August 2016, 325 patients were enrolled, including 69 from Italy, 57 from Spain, 56 from France, 55 from the Netherlands and 44 from each of Switzerland and the United Kingdom. Overall, 314 (96.6%) attended a follow-up visit 3 months after treatment.

Most patients were elderly (mean age 74.1 years) men (84.0%), and the majority had skin phototype II (68.0%) (Table 1). Among the patients who had received previous treatment for AK (88.9%), the mean duration of past AK treatments was 7.2 years and 36.0% and 14.5% of patients had previously received c-PDT and DL-PDT, respectively.

The majority of patients had multiple lesions (58.4% had >10 lesions) with most lesions located on the scalp (60.0%) and/or forehead (54.2%) (Table 1). Patients had lesions of predominantly grade I (39.4%), grade II (33.2%) or a mix of grade I and II (27.4%), and 10.5% of patients also had grade III AK (Table 1).

All physicians ( $N = 52$ ) were experienced dermatologists with a mean of 20.4 years (min-max 9–33) in clinical practice, and they treated 26 AK patients per week on average (min-max 30–100). The main reasons given by the physicians for choosing MAL DL-PDT were the high number and location of lesions over a large area to be treated, treatment tolerability and efficacy and patient adherence (see Table 2).

**Table 1** Baseline demographic and clinical characteristics of the study population

		Patients, n (%) N = 325
<b>Age (years)</b>	Mean $\pm$ SD	74.1 $\pm$ 9.0
	Min-max	41–95
<b>Gender</b>	Male	273 (84.0%)
<b>Skin phototype</b>	Type I	38 (11.7%)
	Type II	221 (68.0%)
	Type III	64 (19.7%)
	Type IV	2 (0.6%)
<b>Previous AK treatment received</b>	Yes	289 (88.9%)
	Cryotherapy	233 (80.6%)
	Conventional PDT	104 (36.0%)
	Fluorouracil	61 (21.1%)
	Diclofenac	56 (19.4%)
	Ingenol mebutate	49 (17.0%)
	Surgery	46 (15.9%)
	Daylight PDT	42 (14.5%)
	Imiquimod	37 (12.8%)
	Laser	10 (3.5%)
	Peelings	4 (1.4%)
Other	7 (2.4%)	
<b>Past medical history of AK treatments (years), N = 289</b>	Mean $\pm$ SD	7.2 $\pm$ 5.9
	Median (min-max)	5.0 (0–35)
<b>Number of lesions</b>	<5	29 (8.9%)
	5–10	106 (32.6%)
	11–20	108 (33.2%)
	>20	82 (25.2%)
<b>Location of lesions</b>	Scalp	195 (60.0%)
	Forehead	176 (54.2%)
	Cheek	103 (31.7%)
	Nose	84 (25.8%)
	Full face	54 (16.6%)
<b>Global severity of the lesions</b>	Majority of grade I	128 (39.4%)
	Majority of grade II	108 (33.2%)
	Well-balanced mix of grade I and II	89 (27.4%)
<b>Grade III lesions present</b>	Yes	34 (10.5%)

PDT, photodynamic therapy.

### MAL DL-PDT procedure

Before MAL application, the skin was prepared in most patients (86.8%) and curettage (71.3%) was the most frequently used method (Table 2). The entire field was prepared in around half the patients (54.3%) and the lesions only in around half (45.7%). The majority of patients applied sunscreen (83.1%), mostly before skin preparation (72.6%).

MAL was applied on the entire field for most patients (80.3%). After MAL application, patients went outside on

**Table 2** Daylight-activated methyl aminolevulinate treatment procedure

	Patients, n (%) N = 325
<b>Major consideration when choosing MAL DL-PDT treatment</b>	
Large area to treat	286 (88.0%)
High number of AK lesions	262 (80.6%)
Tolerability	260 (80.0%)
Location of lesions	244 (75.1%)
Efficacy	236 (72.6%)
Maintenance of AK clearance	185 (56.9%)
Patient adherence	172 (52.9%)
Cosmetic benefits	100 (30.8%)
Cost	26 (8.0%)
<b>Preparation of skin before MAL application</b>	282 (86.8%)
On entire field	153 (54.3%)
Lesions only	129 (45.7%)
<b>Method, N = 282</b>	
Curette	201 (71.3%)
Skin abrasive pad	51 (18.1%)
Keratolytic cream for a few days before	46 (16.3%)
Microdermabrasion	3 (1.1)
Other	6 (2.1%)
<b>Sunscreen applied</b>	270 (83.1%)
Before skin preparation and before MAL	196 (72.6%)
After skin preparation but before MAL	74 (27.4%)
<b>Location of MAL application</b>	
On entire field	261 (80.3%)
On lesions only	64 (19.7%)
<b>Time between MAL application and daylight exposure (min), N = 168</b>	
Mean $\pm$ SD	14.6 $\pm$ 11
Median (min-max)	10 (0–60)
<b>Time of daylight exposure (h), N = 168</b>	
Mean $\pm$ SD	2.0 $\pm$ 0.1
Median (min-max)	2.0 (1.5–3.0)
<b>Total time of MAL exposure (h), N = 168</b>	
Mean $\pm$ SD	2.4 $\pm$ 0.3
Median (min-max)	2.3 (2–4.5)
<b>Post-treatment care recommended</b>	
Sunscreen	320 (98.5%)
Moisturizer	296 (92.5%)
Cleanser	198 (61.9%)
	164 (51.3%)

MAL DL-PDT, Daylight-activated methyl aminolevulinate.

average 14.6 min later and stayed outside in the daylight for 2.0 h (Table 2).

Post-treatment care was recommended to the vast majority of patients (98.5%), especially sunscreen application (92.5%) (Table 2).

### Efficacy

In this patient population with multiple lesions, physician-assessed efficacy at 3 months was at least much improved in

83.5% of patients with 45.9% of patients requiring no retreatment at month 3. Of the patients (54.1%) requiring further treatment at 3 months for residual lesions, the preferred treatments were cryotherapy (55.3%) or MAL DL-PDT (21.2%).

**Patient and physician satisfaction**

At baseline after the MAL DL-PDT procedure, the vast majority of subjects (94.0%) indicated that the procedure was convenient to very convenient (Fig. 1).

At end of study, the proportion of patients and physicians overall satisfied to very satisfied with the MAL DL-PDT treatment was 80.4% and 90.3%, respectively. Most patients and physicians were satisfied or very satisfied with the effectiveness of the MAL DL-PDT treatment (78.9% and 82.6%, respectively) and with the cosmetic appearance of the treated skin (76.9% and 98.1%, respectively) (Fig. 2a).

The vast majority of patients (90.0%) and physicians (98.1%) would consider using MAL DL-PDT again (Fig. 2b).

**Safety**

After receiving the treatment, 66.2% of patients indicated they were not bothered at all by pain (Fig. 3) and the mean pain level was 1.4 (0–10 NRS scale).

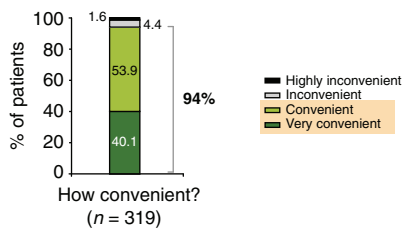
Related AEs were reported in 14.8% of patients, but most were mild in severity (10.8%).

The most commonly reported AEs were phototoxic AEs including skin irritation (4.6%), skin burning sensation (3.7%) and erythema (3.4%) (Table 3).

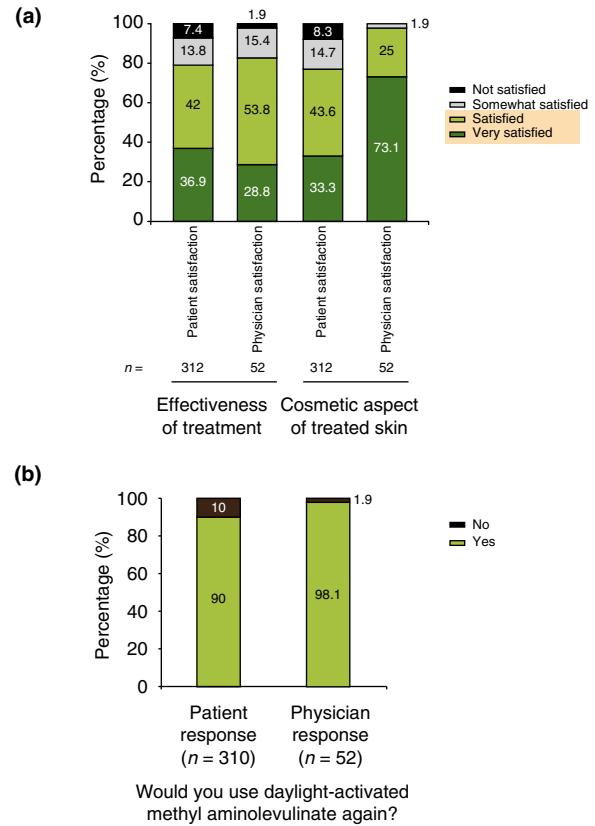
At the 3-month visit, 62.2% of patients indicated they were not bothered at all by side-effects (Fig. 3) and the mean duration of downtime due to skin reactions was 3.4 ± 7.1 days. The vast majority of physicians (86.5%) indicated they were very satisfied with the tolerability of MAL DL-PDT (Fig. 4).

**Discussion**

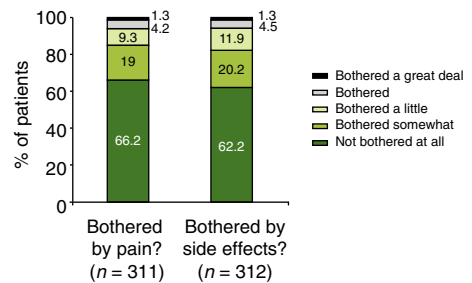
In this population of patients, most of whom were naïve to MAL DL-PDT (85.5%), high patient satisfaction (80.4% overall satisfied/very satisfied) was observed with this convenient (94.0% found it to be convenient/very convenient), almost painless



**Figure 1** Convenience of the daylight-activated methyl aminolevulinic acid treatment, as expressed by patients after treatment.



**Figure 2** According to patient and physician questionnaires at end of study (a) satisfaction with the treatment effectiveness and the cosmetic appearance of the treated skin and (b) proportion who would use daylight-activated methyl aminolevulinic acid again.

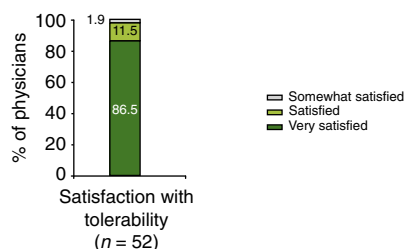


**Figure 3** Patients’ responses to the questions ‘How bothered by any pain?’ (questionnaire after treatment) and ‘How bothered by side-effects?’ (questionnaire at end of study).

procedure. Furthermore, despite the large number of lesions and large areas treated, 83.5% of patients were at least much improved at 3 months after a single treatment with MAL DL-PDT, which may also have contributed to the high patient

**Table 3** Overall related adverse events during the treatment visit and during the 3-month follow-up

	Events	Patients, n (%) N = 325
<b>Related adverse events</b>	66	48 (14.8%)
<b>Skin and subcutaneous tissue disorders</b>	66	48 (14.8%)
Skin irritation	15	15 (4.6%)
Skin burning sensation	12	12 (3.7%)
Erythema	11	11 (3.4%)
Scab	10	10 (3.1%)
Pruritus	9	9 (2.8%)
Pain of skin	4	4 (1.2%)
Skin exfoliation	4	4 (1.2%)
Dermatitis	1	1 (0.3%)

**Figure 4** Physician satisfaction with the tolerability of daylight-activated methyl aminolevulinic acid treatment.

satisfaction. The overall patient satisfaction was similar to the levels reported in a randomized controlled Phase III study conducted in Europe (96.2% satisfied to very satisfied).<sup>6</sup>

The main reasons for prescribing MAL DL-PDT in these patients were the large areas to be treated with many lesions, as well as its good tolerability and efficacy. As the surrounding area of sun-damaged skin (field cancerization) next to visible or palpable AK lesions may contain subclinical lesions and cellular changes, treatment of the entire field is important to treat both subclinical lesions and visible AKs.<sup>8,9</sup> In this study, MAL DL-PDT was applied to the entire field in 80.3% of patients. Of those patients (54.1%) requiring further treatment at 3 months for residual lesions, the main treatments considered were cryotherapy for residual individual lesions (55.3%) and around one-fifth of patients (21.2%) received further treatment with MAL DL-PDT.

Protocols for topical PDT conventionally recommend skin preparation to remove scales and crusts in order to enhance photosensitizing agent absorption and light penetration.<sup>2</sup> Skin preparation was performed over the entire field in half of the cases (54.3% of patients), with curettage of individual lesions (71.3%) much more commonly used than field skin preparations, such as skin abrasive pad or keratolytics (18.1% and

16.3%, respectively). More than one method could be used with, for example, curettage of individual lesions combined with a field skin preparation method.

Only 14.8% of patients had related AEs in this study, which is much lower than the 45.4% reported in the randomized controlled study conducted in Europe.<sup>6</sup> The results presented here for six European countries were part of a larger study, which also included 81 Australian patients. In the Australian study, almost half of the patients (48.1%) experienced related AEs, mainly mild erythema.<sup>10</sup> Phototoxic events are expected and appear to have been under-reported in this European observational study, possibly due to the fact that they were mild in severity and there was no visit at week 1. Indeed, mild phototoxic events are not necessarily considered as adverse events as photosensitivity from PDT is a desirable, intrinsic reaction due to the treated area being sensitized to light. By the 3-month visit, almost two-thirds (62%) of patients indicated they had not been bothered at all by side-effects and the average downtime of 3.4 days was considered acceptable.

Factors that may have contributed to the high patient and physician satisfaction with MAL DL-PDT include the convenient single treatment session (compared to several days for ingenol mebutate to weeks for imiquimod and 5-fluorouracil, even months with diclofenac plus hyaluronic acid gel).

A randomized, split-face, clinical trial on small areas of 25 cm<sup>2</sup> harbouring a similar number of AKs, comparing a single session of MAL DL-PDT with a 3-day treatment with ingenol mebutate, demonstrated similar efficacy for both treatments on face and scalp AKs.<sup>11</sup> However, MAL DL-PDT was associated with lower pain and inflammation scores, quicker wound healing, better cosmetic outcome and higher patient preference (77% preferred MAL DL-PDT vs. 33% for ingenol mebutate).<sup>11</sup> Similarly, in an intraindividual comparative analysis, MAL DL-PDT showed similar effectiveness with a superior tolerability profile in terms of local skin responses and pain compared to ingenol mebutate.<sup>12</sup> In an indirect comparison study in the treatment of mild-to-moderate AK, MAL DL-PDT was more than four times more effective than diclofenac plus hyaluronic acid gel at 12 weeks.<sup>13</sup>

Limitations of this study are the non-interventional nature and lack of a control group. However, this observational study on a large sample size of patients ( $n = 325$ ) and investigators ( $n = 52$ ) provided real-world evidence to support the results of a previous randomized controlled trial conducted in Europe.<sup>6</sup>

## Conclusions

Findings of this observational study in Europe are consistent with those from previous trials and demonstrate high levels of patient and physician satisfaction with MAL DL-PDT, reflecting the good efficacy and high tolerability of this convenient procedure in treating multiple mild-to-moderate AK of the face and/or the scalp.

## Acknowledgments

The authors thank all the other investigators who contributed to the study: JM Amici, P Beaulieu, H Garat, F Neuwirth, JL Riboulet, E Tisserand, G Toubel, P Young and P Zambelli from France; G Argenziano, S Calvieri, SR Mercuri, S Piaserico, M Puviani and M Venturini from Italy; A Avermaete, L Gonggryp, W Habets, A Langeveld, T Smits, M Tjioe and L van der Spek from the Netherlands; JL Artola Igarza, R Botella, J Dominguez, V Garcia Patos, J Hernández, R Ruíz Villaverde and A Segurado from Spain; O Gaide, A Härtel, L Imhof, P Itin, M Muhlstadt, S Nobbe and NS Tomi from Switzerland; U Brudnik, M Kaur, S Keohane, J Lear, C Morton, M Murison and C Perrett from the United Kingdom. Editorial and medical writing assistance was provided by Helen Simpson, PhD, of Galderma R&D.

## References

- Traianou A, Ulrich M, Apalla Z *et al.* EPIDERM Group. Risk factors for actinic keratosis in eight European centres: a case-control study. *Br J Dermatol* 2012; **167**(Suppl 2): 36–42.
- Morton C, Szeimies RM, Sidoroff A *et al.* European Dermatology Forum. European Dermatology Forum Guidelines on topical photodynamic therapy. *Eur J Dermatol* 2015; **25**: 296–311.
- Braathen LR, Szeimies RM, Basset-Seguín N *et al.* Guidelines on the use of photodynamic therapy for nonmelanoma skin cancer: an international consensus. *J Am Acad Dermatol* 2007; **56**: 125–143.
- Sidoroff A, Thaler P. Taking treatment decisions in non-melanoma skin cancer—the place for topical photodynamic therapy (PDT). *Photodiagnosis Photodyn Ther* 2010; **7**: 24–32.
- Rubel DM, Spelman L, Murrell DF *et al.* Daylight photodynamic therapy with methyl aminolevulinate cream as a convenient, similarly effective, nearly painless alternative to conventional photodynamic therapy in actinic keratosis treatment: a randomized controlled trial. *Br J Dermatol* 2014; **171**: 1164–1171.
- Lacour JP, Ulrich C, Gilaberte Y *et al.* Daylight photodynamic therapy with methyl aminolevulinate cream is effective and nearly painless in treating actinic keratoses: a randomised, investigator-blinded, controlled, phase III study throughout Europe. *J Eur Acad Dermatol Venereol* 2015; **29**: 2342–2348.
- Calzavara-Pinton P, Hædersdal M, Barber K *et al.* Structured expert consensus on actinic keratosis: treatment algorithm focusing on daylight PDT. *J Cutan Med Surg* 2017; **21**(1S): 3S–16S.
- Werner RN, Stockfleth E, Connolly SM *et al.* Evidence- and consensus-based (S3) guidelines for the treatment of actinic keratosis – International League of Dermatological Societies in cooperation with the European Dermatology Forum – short version. *J Eur Acad Dermatol Venereol* 2015; **29**: 2069–2079.
- Szeimies RM, Atanasov P, Bissonnette R. Use of lesion response rate in actinic keratosis trials. *Dermatol Ther (Heidelb)* 2016; **6**: 461–464.
- See JA, Gebauer K, Wu JK, Manoharan S, Kerrouche N, Sullivan J. High Patient Satisfaction with Daylight-Activated Methyl Aminolevulinate Cream in the Treatment of Multiple Actinic Keratoses: Results of an Observational Study in Australia. *Dermatol Ther* 2017; **7**: 525–533.
- Moggio E, Arisi M, Zane C, Calzavara-Pinton I, Calzavara-Pinton P. A randomized split-face clinical trial analyzing daylight photodynamic therapy with methyl aminolevulinate vs ingenol mebutate gel for the treatment of multiple actinic keratoses of the face and the scalp. *Photodiagnosis Photodyn Ther* 2016; **16**: 161–165.
- Genovese G, Fai D, Fai C, Mavilia L, Mercuri SR. Daylight methyl-aminolevulinate photodynamic therapy versus ingenol mebutate for the treatment of actinic keratoses: an intraindividual comparative analysis. *Dermatol Ther* 2016; **29**: 191–196.
- Calzavara-Pinton P, Zane C, Pacou M, Szeimies RM. Bucher's indirect comparison of daylight photodynamic therapy with methyl aminolevulinate cream versus diclofenac plus hyaluronic acid gel for the treatment of multiple actinic keratosis. *Eur J Dermatol* 2016; **26**: 487–492.