



THE AGA KHAN UNIVERSITY

eCommons@AKU

Department of Medicine

Department of Medicine

May 2014

Mechanical thrombectomy versus intrasinus thrombolysis for cerebral venous sinus thrombosis: a non-randomized comparison.

Fazeel M. Siddiqui

University of Texas Southwestern Medical Center; Dallas, TX, USA

Chirantan Banerje

Medical Center; Dallas, TX, USA.

Susanna M. Zuurbier

University of Texas Southwestern Medical Center; Dallas, TX, USA.

Qing Hao

University of California Los Angeles; Los Angeles, CA, USA.

Chul Ahn

*University of Texas Southwestern Medical Center; Dallas, TX, USA.**See next page for additional authors*Follow this and additional works at: http://ecommons.aku.edu/pakistan_fhs_mc_med_medPart of the [Integrative Medicine Commons](#), and the [Internal Medicine Commons](#)

Recommended Citation

Siddiqui, F. M., Banerje, C., Zuurbier, S. M., Hao, Q., Ahn, C., Prid, G. L., Wasay, M., . Majoie, C. B., Liebeskind, D., Johnson, J., Stam, J. (2014). Mechanical thrombectomy versus intrasinus thrombolysis for cerebral venous sinus thrombosis: a non-randomized comparison.. *Interventional neuroradiology : journal of peritherapeutic neuroradiology, surgical procedures and related neurosciences*, 20(3), 336-344.

Available at: http://ecommons.aku.edu/pakistan_fhs_mc_med_med/574

Authors

Fazeel M. Siddiqui; Chirantan Banerje; Susanna M. Zuurbier; Qing Hao; Chul Ahn; Glenn L. Prid; Mohammad Wasay; Charles B.L.M. . Majoie; David Liebeskind; ,Mark Johnson; and Jan Stam

Mechanical Thrombectomy versus Intrasinus Thrombolysis for Cerebral Venous Sinus Thrombosis: A Non-Randomized Comparison

FAZEEL M. SIDDIQUI¹, CHIRANTAN BANERJEE¹, SUSANNA M. ZUURBIER², QING HAO³, CHUL AHN¹, GLENN L. PRIDE¹, MUHAMMAD WASAY⁴, CHARLES B.L.M. MAJOIE², DAVID LIEBESKIND³, MARK JOHNSON¹, JAN STAM²

¹ University of Texas Southwestern Medical Center; Dallas, TX, USA

² Academic Medical Center, University of Amsterdam; Amsterdam, Netherlands,

³ University of California Los Angeles; Los Angeles, CA, USA

⁴ Aga Khan University; Karachi, Pakistan

Key words: thrombectomy, thrombolysis, stroke, cerebral venous thrombosis

Summary

Small retrospective studies have shown the benefit of endovascular treatment with intrasinus thrombolysis (IST) or mechanical thrombectomy (MT) with/without IST (MT+/-IST) in cases of multifocal cerebral venous thrombosis (CVT).

Our study compares the mortality, functional outcome and periprocedural complications among patients treated with MT +/- IST versus IST alone.

We reviewed clinical and angiographic findings of 63 patients with CVT who received endovascular treatment at three tertiary care centers. Primary outcome variables were discharge mortality and neurological dysfunction, and intermediate (three months) and long-term (>six months) morbidity. The modified Rankin scale (mRS) was used to assess morbidity. mRS ≤ 1 was considered a good recovery. Neurological dysfunction was rated as neuroscore: 0, normal; 1, mild (ambulatory, communicative); 2, moderate (non-ambulatory, communicative); and 3, severe (non-ambulatory, non-communicative/comatose).

In patients who received IST alone, presenting neurological deficits were comparatively minor ($p < 0.001$). When the two groups were adjusted for admission neuroscore, there was no statisti-

cal significance between discharge mortality [7(21%) versus 4(14%), $p = 0.228$], neurological dysfunction ($p = 0.442$), intermediate ($p = 0.336$) and long-term morbidity ($p = 0.988$). Patients who received MT +/- IST had a higher percentage of periprocedural complications without reaching statistical significance.

Compared to IST, MT was performed in severe cases with extensive sinus involvement. When adjusted for admission neurological dysfunction, both groups had similar mortality and discharge neurological dysfunction and similar intermediate and long-term morbidity.

Introduction

Cerebral venous thrombosis (CVT) is a rare type of stroke (0.5-1% of all strokes)¹. It can be a devastating disease with mortality ranging between 4.3 and 6.8% in assessment of two large databases^{2,3}. There has been a decline in mortality in recent years due to early recognition and treatment with anticoagulation³. There is modest evidence from three small randomized controlled clinical trials and multiple observational studies supporting a role for anticoagulation in the treatment of CVT regardless of the presence of intracerebral hemorrhage (ICH) before the initiation of treatment^{1,4}. De-

spite adequate anticoagulation, patients can still have a poor clinical outcome especially in cases with large and extensive, rapidly progressing or multifocal thrombosis^{1,4}. For such cases, endovascular delivery of fibrinolytic agents with or without mechanical disruption has been successfully used in multiple case reports and smaller case series^{1,5-8}. The theoretical advantages of this treatment include direct delivery of fibrinolytic agent into the clot minimizing systemic side-effects⁶.

AngioJet, a rheolytic thrombectomy system (MEDRAD, Inc, Warrendale, PA, USA) is the most commonly used device for mechanical thrombectomy (MT)^{6,9-22}, followed by the Penumbra thromboaspiration system (Penumbra, Inc, Alameda, CA, USA)²³⁻²⁷ and the MERCI

(Mechanical Embolus Removal in Cerebral Ischemia) clot retrieval device (Concentric Medical, Mountain View, CA, USA)²⁸. Mechanical methods result in more rapid recanalization and increase the surface of the thrombus exposed to thrombolytics⁶.

There is only one non-randomized comparison between anticoagulation versus IST and its findings suggested that local thrombolysis may be more effective than systemic heparin in selected cases²⁹. This study did not employ mechanical methods. A prospective series on 20 patients with severe CVT who mostly received MT with or without IST (MT +/- IST) showed higher mortality and post treatment ICH and advised caution in using endovascular methods⁶. We performed this study to compare the mor-

Table 1 Comparison of demographic and clinical characteristics of patients who received MT+/-IST versus IST alone.

Variables	Mechanical thrombectomy with/without continuous thrombolytic infusion (N=34)	Intrasinus thrombolysis (N=29)	P value
Age (Median, range)	35 (12-57)	32 (4-61)	0.978
Female (%)	26 (77)	20 (69)	0.576
Presenting symptoms			
– Headaches (%)	34 (100)	26 (90)	0.092
– Seizures (%)	17 (50)	10 (35)	0.307
– SE (%)	4 (11)	0 (0)	0.118
– FND (%)	28 (82)	18 (62)	0.091
– Encephalopathy/coma (%)	21 (62)	9 (31)	0.023*
Prothrombotic conditions (%)	15 (44)	17 (59)	0.315
Venous infarction (%)	25 (74)	13 (45)	0.038*
– Non-hemorrhagic (%)	8 (24)	4 (14)	0.358
– Hemorrhagic (%)	19 (56)	10 (35)	0.129
Reason for procedure			
– Extensive involvement of sinuses with altered mental status/coma (%)	25 (74)	10 (35)	
– Deterioration of symptoms despite being on anticoagulation (%)	24/33 (72)	6/10 (60)	
– Large space-occupying lesions, such as edema or (hemorrhagic) infarcts (%)	25 (74)	9 (31)	
– †Other/Unspecified (%)	4 (11)	14 (46)	
Admission neurological deficit			0.001*
– Normal (%)	0 (0)	5 (17)	
– Mild (%)	6 (17)	11 (38)	
– Moderate (%)	4 (12)	7 (24)	
– Severe (%)	24 (71)	6 (21)	
SD= Standard deviation; SE= Status epilepticus; FND= Focal neurological deficits			
* Statistically significant			
† All cases in the 'Other' category had persistent progressive headache or worsening papilloedema.			

tality and morbidity, angiographic recanalization and periprocedural complications between patients who received MT +/- IST versus IST alone.

Methods

We identified 63 patients with CVT who received endovascular treatment at three large tertiary care centers. (University of Texas Southwestern Medical Center, Dallas, Texas, USA, Academic Medical Center, University of Amsterdam, Netherlands and University of California, Los Angeles, California, USA). This study was approved by local institutional review boards for medical record chart review.

Patient selection

Academic Medical Center, University of Amsterdam, Netherlands: 27 patients, treated between 1999 and 2012 were identified from a prospective database (MT=24, IST alone=3). All patients had an assumed poor prognosis because of altered mental status or coma, straight sinus thrombosis, or large space-occupying lesions, such as edema or (hemorrhagic)

infarcts. Twenty patients have been previously described⁶.

University of Texas Medical Center, Dallas Texas, USA: 33 patients were identified retrospectively from hospital databases between 1995 and 2012 (MT=7, IST alone=26). Twenty-three cases were previously published^{24,29-31}. The decision to perform endovascular intervention was operator-dependent.

University of California, Los Angeles, California, USA: three patients were identified retrospectively from hospital databases from 1999 to 2012 (MT=3). Two cases were previously published²⁰. The decision to perform endovascular intervention was operator-dependent.

Diagnosis

The diagnosis of CVT was confirmed by MRI and MR venography, CT venography, or conventional angiography. The pretreatment CT or MRI scans were assessed for midline shift and lesion size, measured as the surface on the image with the largest diameter of the lesion on the last available scan before thrombolysis. Any cerebral lesion with CT or MRI signals compatible with blood was defined as hemorrhagic infarct.

Table 2 Description of mechanical thrombectomy devices and thrombolytic agents.

Variables	Mechanical thrombectomy with/without continuous thrombolytic infusion (n=34)	Intravenous thrombolysis (n=29)
Type of device		N/A
AngioJet	28	
Penumbra	3	
MERCII with Penumbra	1	
Balloon angioplasty	2	
Type of thrombolytics		
Urokinase	23	23
tPA	4	6
Tirofiban	2	0
None	7	N/A
Continuous thrombolysis	25	29
Urokinase	80,000-100000/h	80000-100000/h
tPA	1 mg/h	1 mg/h
Tirofiban	0.5 mcg/kg/h (In conjunction with tPA)	N/A
Duration of continuous thrombolysis	6-96 h	8-96h
N/A=Not applicable		

Endovascular methods: IST was performed by introducing a catheter via the internal jugular or femoral vein and advancing it into a frontal position in the superior sagittal sinus while the thrombus was dissolved with thrombolytic boluses [urokinase or tissue plasminogen activator (tPA)]. Other sinuses were approached if needed and boluses were given. In most cases, the catheter was left in situ, and thrombolytics were infused locally for variable periods of time depending upon the rate of recanalization. Sinus recanalization was examined by contrast injection through the thrombolysis catheter or by intra-arterial angiography. Recanalization was rated as no recanalization or technical failure, partial or incomplete recanalization (contrast visible but lumen too narrow) and complete or near complete recanalization. Heparin was continued during thrombolytic therapy. In patients who received MT, thrombosuction/thrombectomy was performed using AngioJet, Penumbra system or MERCI clot retrieval device.

Outcome variables: Primary outcome variables were discharge mortality and neurological dysfunction, and intermediate (three months) and long term (>six months) morbidity utilizing modified Rankin scores (mRS) [(0=complete recovery; 6=death)]. mRS \leq 1 was considered a good recovery. Neurological dysfunction was assessed on admission and discharge and was rated as neuroscore: 0, normal; 1, mild (ambulatory and communicative); 2, moderate (non-ambulatory but communicative); 3, severe (non-ambulatory and non-communicative/comatose). This scale was previously described by Wasay et al. in a similar population²⁹. The reason for using a non-standardized simple scale instead of a detailed disability scale is to minimize the variability in outcome assessment from chart review³⁰. Secondary outcome variables included periprocedural complications (defined as complications within a month of procedure), recanalization, delayed complications and recurrence rates. Recurrence was defined as clinical (new symptoms or recurrence

Table 3 Comparison of primary outcome variables between MT \pm IST versus IST alone.

Variables	Mechanical thrombectomy with/without continuous thrombolytic infusion (n=34)	Intravenous thrombolysis (n=29)	p1 (unadjusted)	p2 (adjusted)
Death (%)	7 (21%)	4 (14%)	0.526	0.248†
Discharge neurological deficit			0.002*	0.442‡
Normal (%)	6 (22%)	17 (68%)		
Mild (%)	13 (48%)	6 (24%)		
Moderate (%)	7 (26%)	2 (8%)		
Severe (%)	1 (4%)	0 (0%)		
mRS (3 months)			0.060	0.336‡
Lost to follow-up	2	8		
mRS \leq 1 (%)	17 (68%)	16 (94%)		
mRS>1 (%)	8 (32%)	1 (6%)		
mRS(>6 months)			0.378	0.988‡
Lost to follow-up	5	13		
mRS \leq 1 (%)	16 (73%)	11 (92%)		
mRS>1 (%)	6 (27%)	1 (8%)		

mRS=Modified Rankin score; Neuroscore-D=Discharge neuroscore
p1: *p-value represents Wilcoxon-rank sum test and rest of p-values are from Fisher's exact test
p2: p-values adjusting for neuroscore at admission
† p-value is from Cox regression adjusting for neuroscore at admission
‡ p-value is from logistic regression adjusting for neuroscore at admission

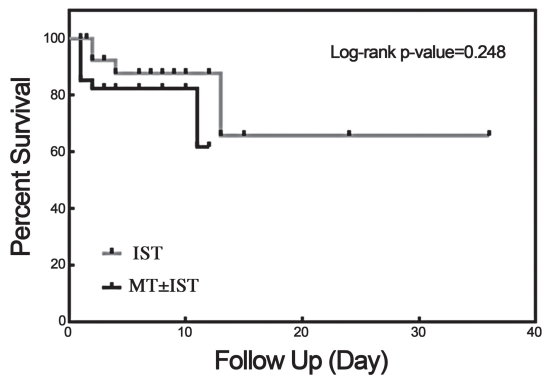


Figure 1 Kaplan Meyer curve depicting survival rates between MT±IST versus IST alone at discharge.

of previous symptoms) and neuroimaging (MRI/MRV) evidence of recurrent or more extensive CVT.

Statistical analysis

We used Fisher's exact test to compare the categorical variables and Wilcoxon rank sum test to compare continuous or ordinal variables between two groups of MT±IST and IST alone. Log-rank test was performed to determine if there was a significant difference in patient survival between the two groups. Cox regression analysis was used to investigate if time was significantly different between the two groups after controlling the effect of admission neuroscore. Logistic regression analysis was conducted to examine if there were significant differences in discharge neurological deficit, dichotomized mRS score (mRS≤1 vs. mRS>1) at three months and >six months between two groups after controlling the effect of admission neuroscore. Statistical analyses were two-tailed and considered significant if $p < 0.05$.

Results

Sixty-three patients underwent endovascular treatment for CVT. Thirty-four patients received MT +/- IST and 29 patient received IST alone. Table 1 provides a comparison of demographic and clinical characteristics between patients who received MT +/- IST versus IST alone. The most common presenting symptom was headache in both groups. Patients who received MT +/- IST had a higher percentage of seizures, focal neurological deficits, encephalopathy or coma. They also had significantly higher admission neuroscores. The reason for

an endovascular procedure was well-defined in patients who received MT +/- IST and included extensive involvement of the sinuses with altered mental status or coma, deterioration of symptoms despite being on anticoagulation, and large space-occupying lesions, such as edema or (hemorrhagic) infarcts. In patients who received IST only, reasons were less defined and operator-dependent (Table 1).

The term anticoagulation failure was loosely used for all patients that deteriorated clinically on an adequate dose of heparin or oral anticoagulants. The timing of anticoagulation prior to the procedure was variable and ranged from no anticoagulation to nine days. Exceptions were two patients who had a relapse of their symptoms after three months of adequate anticoagulation therapy and were considered candidates for endovascular intervention.

Five patients received heparin only for a few hours before endovascular intervention mainly during transfer from a peripheral facility to a tertiary care center. Eleven patients received heparin for the first time in the angiography suite. Twenty patients had no documentation of prior use of anticoagulation before the procedure.

Mechanical thrombectomy with/without intravenous thrombolysis

AngioJet was the most commonly used MT device (28 patients), followed by Penumbra and MERCI. Two patients received angioplasty only. Twenty-seven patients received IST during the procedures. Twenty-five patients received continuous thrombolytic infusion. Urokinase was the most commonly used thrombolytic agent followed by tPA. Duration of thrombolysis varied from six to 96 hours (Table 2).

Two patients received Tirofiban (Aggrastat, Mediceur Pharma) infusion in conjunction with tPA. Tirofiban is a glycoprotein IIb/IIIa inhibitor that has been anecdotally used in ischemic stroke mechanical interventions to maintain blood flow through channels opened by mechanical thrombectomy especially in the setting of hypercoagulable states^{30,32,33}.

Intrasinus thrombolysis: All patients in the thrombolysis group received continuous infusion for variable duration (8-96 h). The most commonly used thrombolytic agent was urokinase followed by tPA (Table 2).

Outcome: There was no statistically significant difference in adjusted discharge mortality between the two groups (7(21%) versus 4(14%), $p=0.248$) [Table 3, Figure 1]. The unadjusted discharge neuroscore was significantly higher in patients who received MT ($p=0.002$).

However, when adjusted for admission neuroscore using a logistic regression model, the difference was not significant ($p=0.442$).

There was no statistically significant difference in the adjusted intermediate and long-term morbidity between two groups (Table 3).

Periprocedural complications

There was a higher percentage of periprocedural complications in patients who received MT+/-IST (not significant, $P=0.299$) (Table 4). There were five new hemorrhagic infarctions and three enlargements of prior hemorrhages in the MT +/- IST group compared to four new hemorrhagic infarctions in the IST group. Complications secondary to direct catheter manipulations were more prevalent in the MT +/- IST group (Table 4).

Table 4 Comparison of secondary outcome variables between MT±IST versus IST alone.

Variables	Mechanical thrombectomy with/without continuous thrombolytic infusion N=34	Intrasinus thrombolysis N=29	
Hospital stay (median, range)	11 (1-53)	9 (2-30)	0.923
Peri-procedural complications (%)	14(41)	8(28)	0.299
Death	7	4	
New ICH	5	4	
Worsening of previous ICH	3	0	
Catheter-related complications	0	1	
Retroperitoneal hemorrhage	1	0	
Catheter tip fracture	1	0	
Perforation of sinus	1	0	
Groin hematoma	1	0	
Formation of bilateral inguinal aneurysm			
Recanalization rates	(n=33)	(n=10) [‡]	0.690
None*(%)	4(12)	0(0)	
Partial (%)	13(33)	5(50)	
Near to full Improvement [†] (%)	16(50)	5(50)	
Recurrence (%)	1(3)	3(10)	0.286

* One angioplasty and two AngioJet cases
[†] All Penumbra/MERCI cases
[‡] The 19 missing patients had either partial or complete recanalization but not well-documented

Recanalization rates: Recanalization rates were available in 33 MT +/- IST patients and ten IST alone patients. There was no significant difference between the two groups (Table 4).

Recurrence: The recurrence rate of CVT was 10% (n=3) in the IST alone group and 3% (n=1) in the MT +/- IST group (p=0.293). Three patients with recurrence presented within three months of discharge while one patient presented after two and a half years.

Delayed complications: Three patients in the MT +/- IST group developed pseudotumor cerebri with two of them requiring ventriculo-peritoneal shunts. All three had either partial or no recanalization after the procedure. In three patients from the IST alone group, IST was performed to treat pseudotumor cerebri but they continued to have persistent headaches and high intracranial pressure at long-term follow-up.

One patient developed seizures requiring medications. All four patients had adequate recanalization after the procedure.

Discussion

The first use of IST was reported by Scott et al. in 1988. They catheterized the sagittal sinus via a frontal burr hole and infused urokinase over an eight-hour period, followed by excellent recovery³⁴.

Dowd et al. reported the first case of using an MT device to treat CVT. They applied an AngioJet rheolytic system for thrombectomy followed by intrasinus infusion of urokinase for two days. Since then several case reports and series have been published on the successful use of either an MT device alone or in combination with direct intrasinus infusion of thrombolytic agents⁸.

According to the American Heart Association guidelines for diagnosis and management of CVT, the use of such procedures is recommended only if clinical deterioration occurs despite use of anticoagulation, or if the patient develops mass effect from a venous infarction or ICH that causes intracranial hypertension resistant to standard therapies¹. However, there is no proper definition or time limit for anticoagulation failure, as evident from the findings of our study. Hence, there is variability in the timing to intervene in patients who are already on therapeutic anticoagulation. In a recently published study, Mohammadian et al. defined

anticoagulation failure as clinical deterioration after at least four days of full anticoagulation with heparin (or 48 hours in patients with involvement of more than one sinus)⁷.

There is only one non-randomized comparison between heparin treatment and IST for the treatment of CVT. Its findings showed that IST may offer some benefit over heparin treatment although the study had several limitations³⁰. A clinical trial to compare endovascular treatment (all modalities) versus heparin has been set-up and is currently recruiting patients³⁵.

Our study offers a non-randomized comparison between MT +/- IST versus IST alone. The use of MT versus IST is institute and operator-dependent. In our study there was a significant difference in the choice of treatment between European and USA institutes. The cases received from the Academic Hospital of Amsterdam, Netherlands primarily used MT in most patients (24/27), whereas very few cases of attempted MT were found in the UTSW and UCLA institutional archives. Though theoretically, MT appears to be a better option than IST alone, clinical data are lacking to support this hypothesis. Soleu et al., in a small retrospective series of 31 patients who received all three treatment options (heparin versus IST versus MT), found MT to be more beneficial than IST with less hemorrhage risk.

They did not use IST in conjunction with MT³⁶. Proponents of both treatment modalities have published case series to advocate local thrombolysis or mechanical thrombectomy as safe first or second line treatment options for severe CVT^{7,10}. Many interventionalists fear that the procedure-related complications with MT devices may cause more harm than benefit to the patient. Older devices like AngioJet are bulky and stiff and had potential to cause sinus perforation. The large size of the AngioJet prevents it from accessing smaller sinuses minimizing its utility. This fear has been overcome in the recent years with the advent of newer techniques and devices such as Penumbra and MERCI.

Our study also indicates that in most institutes, MT is reserved mostly for complicated cases with severe neurological deficits. In milder cases IST is preferred.

Our study offers a modest comparison between two endovascular treatment groups in a diverse population. When adjusted for injury severity at admission, both groups had similar discharge, intermediate and long-term mortality.

ty and morbidity. Though periprocedural complications and recanalization rates were not significantly different between the two groups, direct catheter-related complications were more common in the MT group probably secondary to the more excessive manipulations required with thrombectomy or thromboaspiration.

Our study has several limitations. It is a retrospective study with non-randomized treatment groups. There is a hospital/operator preference for the treatment modality. The number of patients is relatively small, although larger than any previously published series on MT. We used a simplified scale to monitor outcome at discharge which is non-standardized. A large number of patients are lost to follow-up for long-term evaluations. There is variability of devices, thrombolytic agents, and the duration of continuous thrombolytic infusion.

References

- 1 Saposnik G, Barinagarrementeria F, Brown RD, Jr., et al. Diagnosis and management of cerebral venous thrombosis: a statement for healthcare professionals from the American Heart Association/American Stroke Association. *Stroke*. 2011; 42 (4): 1158-1192. doi: 10.1161/STR.0b013e31820a8364.
- 2 Ferro JM, Canhão P, Stam J, et al. Prognosis of cerebral vein and dural sinus thrombosis: results of the International Study on Cerebral Vein and Dural Sinus Thrombosis (ISCVT). *Stroke*. 2004; 35 (3): 664-670. doi: 10.1161/01.STR.0000117571.76197.26.
- 3 Borhani Haghighi A, Edgell RC, Cruz-Flores S, et al. Mortality of cerebral venous-sinus thrombosis in a large national sample. *Stroke*. 2012; 43 (1): 262-264. doi: 10.1161/STROKEAHA.111.635664.
- 4 Einhaupl KM, Villringer A, Meister W, et al. Heparin treatment in sinus venous thrombosis. *Lancet*. 1991; 338 (8767): 597-600. doi: 10.1016/0140-6736(91)90607-Q.
- 5 Canhão P, Falcao F, Ferro JM. Thrombolytics for cerebral sinus thrombosis: a systematic review. *Cerebrovasc Dis*. 2003; 15 (3): 159-166. doi: 10.1159/000068833.
- 6 Stam J, Majoie CB, van Delden OM, et al. Endovascular thrombectomy and thrombolysis for severe cerebral sinus thrombosis: a prospective study. *Stroke*. 2008; 39 (5): 1487-1490. doi: 10.1161/STROKEAHA.107.502658.
- 7 Mohammadian R, Sohrabi B, Mansourizadeh R, et al. Treatment of progressive cerebral sinuses thrombosis with local thrombolysis. *Interv Neuroradiol*. 2012; 18 (1): 89-96.
- 8 Rahman M, Velat GJ, Hoh BL, et al. Direct thrombolysis for cerebral venous sinus thrombosis. *Neurosurg focus*. 2009; 27 (5): E7. doi: 10.3171/2009.7.FOCUS09146.
- 9 Dowd CF, Malek AM, Phatouros CC, et al. Application of a rheolytic thrombectomy device in the treatment of dural sinus thrombosis: a new technique. *Am J Neuroradiol*. 1999; 20 (4): 568-570.
- 10 Dashti SR, Hu YC, Yao T, et al. Mechanical thrombectomy as first-line treatment for venous sinus thrombosis: technical considerations and preliminary results using the AngioJet device. *J Neurointerv Surg*. 2013; 5 (1): 49-53. doi: 10.1136/neurintsurg-2011-010112.
- 11 Shah CT, Rizqallah JJ, Oluwole O, et al. Delay in diagnosis of cerebral venous and sinus thrombosis: successful use of mechanical thrombectomy and thrombolysis. *Case Rep Med*. 2011: 815618. doi: 10.1155/2011/815618.
- 12 Summers SM. Transverse sinus thrombosis with hemorrhagic venous infarction treated with thrombectomy, endovascular tissue plasminogen activator, and systemic anticoagulation. *J Emerg Med*. 2011; 41 (4): e95-98.
- 13 Modi K, Misra V, Reddy P. Rheolytic thrombectomy for dural venous sinus thrombosis. *J Neuroimaging*. 2009; 19 (4): 366-369. doi: 10.1111/j.1552-6569.2008.00311.x.
- 14 Zhang A, Collinson RL, Hurst RW, et al. Rheolytic thrombectomy for cerebral sinus thrombosis. *Neurocrit Care*. 2008; 9 (1): 17-26. doi: 10.1007/s12028-008-9058-y.
- 15 Anand N, Chan C, Wang NE. Cerebral venous thrombosis: a case report. *J Emerg Med*. 2009; 36 (6): 132-137. doi: 10.1016/j.jemermed.2007.02.041.
- 16 Tsai FY, Kostanian V, Rivera M, et al. Cerebral venous congestion as indication for thrombolytic treatment. *Cardiovasc Intervent Radiol*. 2007; 30 (4): 675-687. doi: 10.1007/s00270-007-9046-1.
- 17 Kirsch J, Rasmussen PA, Masaryk TJ, et al. Adjunctive rheolytic thrombectomy for central venous sinus thrombosis: technical case report. *Neurosurgery*. 2007; 60(3): E577-578; discussion E578.
- 18 Agner C, Deshaies EM, Bernardini GL, et al. Coronary angiojet catheterization for the management of dural venous sinus thrombosis. Technical note. *J Neurosurg*. 2005; 103 (2): 368-71. doi: 10.3171/jns.2005.103.2.0368.
- 19 Curtin KR, Shaibani A, Resnick SA, et al. Rheolytic catheter thrombectomy, balloon angioplasty, and direct recombinant tissue plasminogen activator thrombolysis of dural sinus thrombosis with preexisting hemorrhagic infarctions. *Am J Neuroradiol*. 2004; 25 (10): 1807-1811.
- 20 Chow K, Gobin YP, Saver J, et al. Endovascular treatment of dural sinus thrombosis with rheolytic thrombectomy and intra-arterial thrombolysis. *Stroke*. 2000; 31 (6): 1420-1425. doi: 10.1161/01.STR.31.6.1420.

Conclusion

Our study compared two endovascular modalities for the treatment of severe CVT. Both treatment options have similar discharge, intermediate and long-term mortality and morbidity. However, device-related complications were more prevalent in the MT group. Based on our data, the decision to use endovascular options for the treatment of CVT is operator and institute-dependent. The term 'anticoagulation failure' is vague and causes unnecessary confusion in decision-making. There is a preference to use IST alone in milder cases of CVT and MT +/- IST in severe cases, probably caused by fear of complications with MT devices. Newer devices like Penumbra and MERCI have better safety profiles but data on their application for CVT is limited.

- 21 Novak Z, Coldwell DM, Brega KE. Selective infusion of urokinase and thrombectomy in the treatment of acute cerebral sinus thrombosis. *Am J Neuroradiol.* 2000; 21 (1): 143-145.
- 22 Opatowsky MJ, Morris PP, Regan JD, et al. Rapid thrombectomy of superior sagittal sinus and transverse sinus thrombosis with a rheolytic catheter device. *Am J Neuroradiol.* 1999; 20 (3): 414-417.
- 23 Choulakian A, Alexander MJ. Mechanical thrombectomy with the penumbra system for treatment of venous sinus thrombosis. *J Neurointerv Surg.* 2010; 2 (2): 153-156. doi: 10.1136/jnis.2009.001651.
- 24 Siddiqui FM, Pride GL, Lee JD. Use of the Penumbra system 054 plus low dose thrombolytic infusion for multifocal venous sinus thrombosis. A report of two cases. *Interv Neuroradiol.* 2012; 18 (3): 314-319.
- 25 Velat GJ, Skowlund CJ, Waters MF, et al. Direct thrombectomy using the Penumbra thromboaspiration catheter for the treatment of cerebral venous sinus thrombosis. *World neurosurg.* 2012; 77 (3-4): 591. e15-8.
- 26 Blackham KA. Extensive dural sinus thrombosis: successful recanalization with thrombolysis and a novel thrombectomy device. *J Neurosurg.* 2011; 114 (1): 133-135. doi: 10.3171/2010.2.JNS091186.
- 27 Kulcsár Z, Marosfoi M, Berentei Z, et al. Continuous thrombolysis and repeated thrombectomy with the Penumbra System in a child with hemorrhagic sinus thrombosis: technical note. *Acta Neurochir (Wien).* 2010; 152 (5): 911-916. doi: 10.1007/s00701-009-0570-4.
- 28 Newman CB, Pakbaz RS, Nguyen AD, et al. Endovascular treatment of extensive cerebral sinus thrombosis. *J Neurosurg.* 2009; 110 (3): 442-445. doi: 10.3171/2008.4.17491.
- 29 Wasay M, Bakshi R, Kojan S, et al. Nonrandomized comparison of local urokinase thrombolysis versus systemic heparin anticoagulation for superior sagittal sinus thrombosis. *Stroke.* 2001; 32 (10): 2310-2317. doi: 10.1161/hs1001.096192.
- 30 Rickert KL, Purdy PD, Welch BG. Mechanical and chemical thrombolysis of cerebral sinus thrombosis: evolution of a technique. *J Neurosurg.* 2011; 114 (1): 136-139. doi: 10.3171/2010.2.JNS09685.
- 31 Horowitz M, Purdy P, Unwin H, et al. Treatment of dural sinus thrombosis using selective catheterization and urokinase. *Ann Neurol.* 1995; 38 (1): 58-67. doi: 10.1002/ana.410380112.
- 32 Kwon JH, Shin SH, Weon YC, et al. Intra-arterial adjunct tirofiban after unsuccessful intra-arterial thrombolysis of acute ischemic stroke: preliminary experience in 16 patients. *Neuroradiology.* 2011; 53 (10): 779-785. doi: 10.1007/s00234-011-0939-y.
- 33 Mangiafico S, Cellerini M, Nencini P, et al. Intravenous glycoprotein IIb/IIIa inhibitor (tirofiban) followed by intra-arterial urokinase and mechanical thrombolysis in stroke. *Am J Neuroradiol.* 2005; 26 (10): 2595-2601.
- 34 Scott JA, Pascuzzi RM, Hall PV, et al. Treatment of dural sinus thrombosis with local urokinase infusion. Case report. *J Neurosurg.* 1988; 68 (2): 284-287. doi: 10.3171/jns.1988.68.2.0284.
- 35 Coutinho JM, Ferro JM, Zuurbier SM, et al. Thrombolysis or anticoagulation for cerebral venous thrombosis: rationale and design of the TO-ACT trial. *Int J Stroke.* 2013; 8 (2): 135-140. doi: 10.1111/j.1747-4949.2011.00753.x.
- 36 Soleau SW, Schmidt R, Stevens S, et al. Extensive experience with dural sinus thrombosis. *Neurosurgery.* 2003; 52 (3): 534-44; discussion 42-4. doi: 10.1227/01.NEU.0000047815.21786.C1.

Fazeel M. Siddiqui, MD
 5323 Harry Hines Blvd.
 Dallas, Texas 75390-8897
 Tel.: (214) 648-7811
 Fax: (214) 648-9311
 E-mail: fazeelmukhtar@gmail.com