



THE AGA KHAN UNIVERSITY

eCommons@AKU

Section of Neurosurgery

Department of Surgery

June 2017

Extent of resection and timing of surgery in adult low grade glioma

Farhan A. Mirza
Aga Khan University

Muhammad Shahzad Shamim
Aga Khan University Hospital, shahzad.shamim@aku.edu

Follow this and additional works at: http://ecommons.aku.edu/pakistan_fhs_mc_surg_neurosurg

 Part of the [Neurology Commons](#), and the [Surgery Commons](#)

Recommended Citation

Mirza, F., Muhammad Shahzad Shamim, . (2017). Extent of resection and timing of surgery in adult low grade glioma. *JPMA: Journal of the Pakistan Medical Association*, 67(6), 959-961.

Available at: http://ecommons.aku.edu/pakistan_fhs_mc_surg_neurosurg/58

Extent of resection and timing of surgery in adult low grade glioma

Farhan A. Mirza,¹ Muhammad Shahzad Shamim²

Abstract

Low grade glioma is a group of WHO grade II tumours including diffuse astrocytoma, oligodendroglioma, and oligoastrocytoma. Strong evidence exists in literature now to support early surgery and higher extent of safe resection in improving outcomes. In this review, we are highlighting some of the important studies done in the last few years specifically addressing timing of surgery and extent of resection.

Keywords: low grade glioma, extent of resection, early surgery, progression free survival, overall survival

Introduction

Low grade gliomas (LGG) are a group of slow growing WHO grade II tumours comprising of diffuse astrocytoma, oligodendroglioma and rarely oligoastrocytoma. These tumours ultimately undergo malignant transformation and turn into higher grade tumours with poor outcome. Gemistocytic astrocytoma, despite being a grade II entity, is not included in this group due to its unusual malignant behaviour. Low grade gliomas are infiltrative, often located in eloquent cortex, and are difficult to differentiate from normal brain tissue on gross examination, which leads to the inherent difficulty in incompletely resecting these lesions. Introduction and popularization of the use of IDH1 mutation status and 1p/19q co-deletion has allowed better understanding of the behaviour of these tumours and also for prediction of their malignant potential. Early surgery versus observation, and extent of safe resection are questions that have been investigated extensively for these tumours. A handful of studies in the last three decades have tried to address these questions for this subset of the glioma family. Operative adjuncts such as neuronavigation, awake craniotomy, intra-operative mapping, intra operative MRI (iMRI), functional MRI (fMRI), and fiber tractography are now playing an important role in achieving better

extent of resection with safety, even near eloquent cortex.

Review of Evidence

We queried the PubMed database with the phrases 'extent of resection in low grade glioma' and 'timing of surgery for low grade glioma'. Articles addressing these topics were reviewed.

Timing of Surgery

The incidence of low grade gliomas arose with the advent of computed tomography and improvement in imaging techniques. Historically, with lesions incidentally discovered on imaging that resembled low grade gliomas or even those presenting with new onset seizures, a 'wait and observe' approach was taken. In some instances stereotactic biopsy was performed to determine tissue diagnosis and then institute adjuvant therapy. This approach was fraught with issues as most of these tumours would progress and transform into higher grade malignant lesions, which is the natural history of these entities.

One of the first studies on this subject was a retrospective review in 1991 by Smith et al., on primary brain tumours presenting with epilepsy.¹ It had several limitations in its methodology and failed to show any meaningful difference in outcomes of early or late surgery. Similar conflicting results were seen in the study by van Weelen et al., in 1998.² Several studies in the subsequent years were performed to understand best treatment strategy for these low grade lesions, mainly addressing extent of resection. In 2012, the landmark Norwegian study by Jakola et al., comprehensively answered the question of upfront surgery vs. wait and watch approach. Their population based analysis took into account the practice of two hospitals: one favouring early biopsy and observe, whereas the other center favoured upfront resection in a homogenous patient population. Overall survival was significantly better with early surgical resection ($P=0.01$). Median survival was 5.9 years (95% CI, 4.5-7.3) with biopsy only while median survival was not reached in the group with early resection. Estimated 5-year survival was 60% (95% CI, 48%-72%) for biopsy and 74% for (95% CI, 64%-84%) early resection.³ Majority of the patients included were

¹Department of Neurosurgery, University of Kentucky, Lexington, KY, USA,

²Department of Surgery, Section of Neurosurgery, Aga Khan University Hospital, Karachi, Pakistan.

Correspondence: Muhammad Shahzad Shamim.

Email: shahzad.shamim@aku.edu

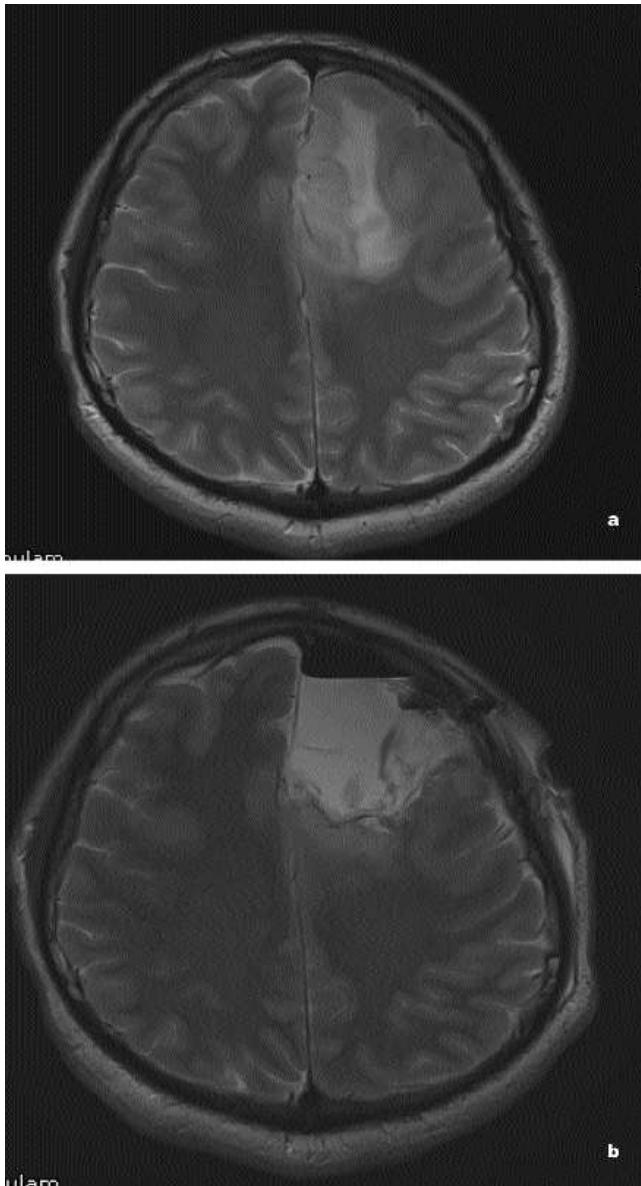


Figure: a) MRI T2WI of a left frontal low grade glioma. b) Post op MRI T2WI of same patient showing more than 90% resection after awake craniotomy.

found to have grade II astrocytoma. This was further studied in their post hoc analysis, revealing similar results with early surgery.

Extent of Resection

In 1993, Philippon et al., published a retrospective analysis of their experience and documented 80% 5 year survival with gross total resection (GTR) and 50% with subtotal resection (STR).⁴ Van Weelen et al., in 1998 published their volumetric results with 62% 5 year survival with >75% resection and 18% survival in <75% resection.² Smith et al in 2008 further elaborated on

correlation of volumetric extent of resection and noted 97% 5 year survival rate with 90-99% resection. They also correlated increased malignant progression free survival (MPFS) with greater EOR.⁵ In this large series, the authors also noted that large tumours on pre-operative scans, despite extent of resection, were associated with lower OS, PFS and MPFS. Similarly, McGirt et al., published their series the same year showing 95% 5 year survival with gross total resection (GTR), 80% 5 year survival with near total resection (NTR) and 70% survival with subtotal resection (STR), based on residual FLAIR abnormalities on post-operative T2 MRI. They documented increased malignant progression free survival (MPFS) with GTR.⁶

Concept of Supratotal Resection

The concept of cancer free margins is well established in solid organ surgery. In brain surgery, however, this can seldom be achieved given the eloquent nature of white matter tracts adjacent to the tumour even in presumably 'non-eloquent' regions of the brain. Employing the advantage of awake craniotomy with intra-operative cortical and subcortical mapping, Duffau and colleagues have very elegantly elaborated on the concept of supratotal resection, or negative margin neurosurgery in select patients.⁹ In their series from 2011, they performed supratotal resection in 15 patients with dominant left hemisphere non-eloquent region low grade glioma. Supratotal resection was performed, with 60% of the patients experience transient post-operative deficits with complete resolution. Compared to their comparable series of gross total resection, the supratotal resection group had lower rates of recurrence without malignant transformation. Despite the small numbers, this concept has had a profound implication on glioma surgery. Duffau and colleagues have since published extensively on this philosophy and their results with low grade gliomas surpass the results of any other center. Their work has also allowed us to better understand the behaviour of low grade gliomas and the cyto-architectural and functional changes in the brain associated with the progression of these lesions.

Conclusion

Overwhelming evidence suggests that upfront surgical resection instead of a wait and watch approach, and maximal safe resection not only changes the natural history of the disease but also improves overall survival as well as malignant progression free survival. Supratotal resection is a promising concept and has shown to

significantly improve outcomes. The heterogeneity of patient population, presenting symptoms, involvement of eloquent areas, and availability of local surgical resources to deal with these lesions in an effective fashion maybe limited in a developing or third world nation.

References

1. Smith DF, Hutton JL, Sandemann D, Foy PM, Shaw MD, Williams IR, et al. The prognosis of primary intracerebral tumours presenting with epilepsy: the outcome of medical and surgical management. *J Neurol Neurosurg Psychiatry*. 1991; 54: 915-20.
 2. vanVeelen ML, Avezaat CJ, Kros JM, van Putten W, Vecht C. Supratentorial low grade astrocytoma: prognostic factors, dedifferentiation, and the issue of early versus late surgery. *J Neurol Neurosurg Psychiatry*. 1998; 64: 581-7.
 3. Jakola AS, Myrmet KS, Kloster R, Torp SH, Lindal S, Unsgård G, et al. Comparison of a strategy favoring early surgical resection vs a strategy favoring watchful waiting in low-grade gliomas. *JAMA*. 2012; 308: 1881-8.
 4. Philippon JH, Clemenceau SH, Fauchon FH, Foncin JF. Supratentorial low-grade astrocytomas in adults. *Neurosurgery*. 1993; 32: 554-9.
 5. Smith JS, Chang EF, Lamborn KR, Chang SM, Prados MD, Cha S, et al. Role of extent of resection in the long-term outcome of low-grade hemispheric gliomas. *J Clin Oncol* 2008; 26: 1338-45.
 6. McGirt MJ, Chaichana KL, Attenello FJ, Weingart JD, Than K, Burger PC, et al. Extent of surgical resection is independently associated with survival in patients with hemispheric infiltrating low-grade gliomas. *Neurosurgery*. 2008; 63: 700-7; author reply 707-8.
 7. Johannesen TB, Langmark F, Lote K. Progress in long-term survival in adult patients with supratentorial low-grade gliomas: a population-based study of 993 patients in whom tumors were diagnosed between 1970 and 1993. *J Neurosurg* 2003; 99: 854-62.
 8. Hardesty DA, Sanai N. The value of glioma extent of resection in the modern neurosurgical era. *Front. Neur* 2012; 3: 140.
 9. Yordanova YN, Moritz-Gasser S, Duffau H. Awake surgery for WHO Grade II gliomas within "noneloquent" areas in the left dominant hemisphere: toward a "supratotal" resection. *Clinical article. J Neurosurg* 2011; 115: 232-9.
-