



THE AGA KHAN UNIVERSITY

eCommons@AKU

Section of Cardiothoracic Surgery

Department of Surgery

January 2007

Rare relapsed extrapulmonary hydatid disease

Saulat H. Fatimi

Aga Khan University, saulat.fatimi@aku.edu

MJ Schuurin

S. Sheikh

Follow this and additional works at: https://ecommons.aku.edu/pakistan_fhs_mc_surg_cardiothoracic

 Part of the [Cardiology Commons](#)

Recommended Citation

Fatimi, S., Schuurin, M., Sheikh, S. (2007). Rare relapsed extrapulmonary hydatid disease. *Journal of College of Physicians and Surgeons Pakistan*, 17(9), 570-571.

Available at: https://ecommons.aku.edu/pakistan_fhs_mc_surg_cardiothoracic/76

RARE RELAPSED EXTRAPULMONARY HYDATID DISEASE

Saulat H. Fatimi, Mark J. Schuurin^{*} and Sadaf Sheikh^{**}

ABSTRACT

Hydatid cysts are rarely seen at the extrapulmonary sites. We report relapsed hydatid cysts with abdominal origin in a 25 years old woman. Over 1000 Hydatid cysts were removed through right posterolateral thoracotomy without any complications. Only very few cases are reported in the literature.

KEY WORDS: *Hydatid cysts. Extrapulmonary. Surgery.*

INTRODUCTION

Hydatidosis still remains a major public health problem in endemic parts of the world, most notably the Mediterranean region, Australia, New Zealand, the Middle East and South America.¹ Hydatid cysts can theoretically involve any organ but an extrapulmonary location of hydatidosis in the thorax is very rare.² Surgery remains the primary treatment. Here, we report the surgical treatment and management by a right posterolateral thoracotomy.

CASE REPORT

A 25 years old female presented to the clinic with complaints of chest pain, cough and low grade fever. Abdominal pain had lasted for several years. Her history revealed previous four resections of hydatid cysts from abdomen in the past 15 years. Physical examination showed a patient with stable vital sign, the CT abdomen revealed widespread disease. Involved organs were the liver, spleen and pelvic structures. The CT thorax showed multiple cysts in the extrapleural cavities (Figure 1). Multiple hydatid cysts were diagnosed and the woman was admitted for surgical intervention.

A right posterolateral thoracotomy via the 5th intercostal space was performed in a left lateral decubitus position. Extrapleural hydatid cysts were found in the costophrenic angle posteriorly behind the diaphragm. Over 1000 cysts were taken out. (Figure 2) Hypertonic saline washout was performed. The lungs and pleura were normal. An extrapleural catheter was placed for pain control with Marcaine and the chest was closed in layers. The patient was kept on Albendazole for one year and discharged after 4 days postoperatively without any complications, and remained uneventful.

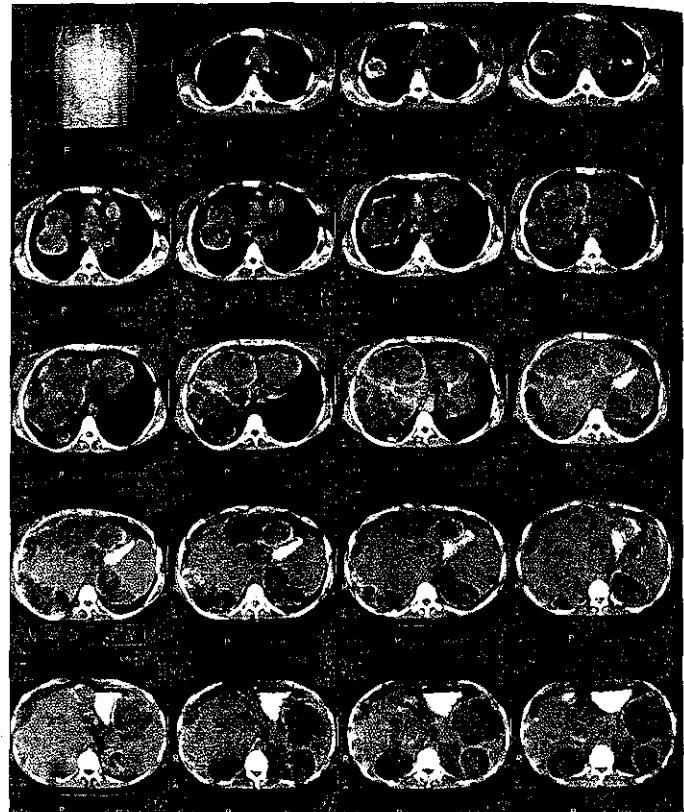


Figure 1: A 25-year-old woman presented with shortness of breath. CT scan showed widespread hydatid disease.



Figure 2: More than 1000 hydatid cysts were removed.

Department of Cardiothoracic Surgery, Aga Khan University, Karachi.
^{*}Academic Medical Centre, University of Amsterdam, The Netherland,
^{**}Monash University, Australia.

Correspondence: Dr. Sadaf Sheikh, DEPM, Monash University, 89 Commercial Road, Prahran, Melbourne-3004, Australia, Email: sheikh.sadaf@gmail.com

Received July 27, 2007; accepted July 20, 2007.

DISCUSSION

Hydatid cyst is a parasitic disease known from the time of Hippocrates, and it is still endemic in many places in the world. Liver and lung are the most common sites of the disease, but it can also be seen elsewhere in the body. Extrapulmonary location of the disease in the thorax is very rare and surgical removal is the best therapeutic option.¹

Thoracic hydatid disease located extrapulmonary is so rare that only a few cases have been reported in the literature. Buttenschoen *et al.*² in a study among 15,289 patients, reported an infection with hydatid disease other than abdominal or lung location in <0.2%.² Reported thoracic extrapulmonary locations include the chest wall, the mediastinum, the pericardium, the myocardium, thoracic fissures and cysts in the pleura. Fissure and pleural space are the most common sites among extrapulmonary cysts⁷ and most of them are attached to the visceral pleura by a thin pedicle. Ribs, sternum, or soft tissues of the chest wall are not a common location since overall bone involvement is only 0.9 - 2%.⁷

Generally, surgery remains the primary treatment of hydatid cysts. Morbidity is usually secondary to free rupture of the cyst (with or without anaphylaxis), infection of the cyst, or dysfunction of the involved organ.² Mortality is secondary to anaphylaxis, systemic complications of the cysts (sepsis, respiratory failure) or operative complications.²

Thoracotomy and removal of hydatid cysts as a treatment is only described in similar cases among small populations over long periods.³⁻⁵ It was reported among 22 patients over 14 years, showed no deaths and one case with postoperative empyema.³ Others reporting of 6 thoracotomies in 4 years showed no complications or recurrences during the follow-up period.⁴ Eleven cases with isolated primary mediastinal hydatid cyst have been reported by Eroglu *et al.*⁶ Total pericystectomy (n=7) and cystectomy plus local curettage (n=4) were performed and no complications and mortality were reported postoperatively. Extrapulmonary thoracic cysts has been associated with other locations as hepatic (n=7) and pleural (n=1) reported by Zidi *et al.*⁵ The patient described in our case had more than 1000 hydatid cysts in her body. Hydatid cysts grow slowly (1-30 mm in diameter yearly) and about 80% occur in one organ² which makes this case exceptional.

Complicated cysts are a result of rupture with leakage prior or damage due to surgery. To our knowledge, there is not any

valid literature about complicated cysts in extrapulmonary thoracic cysts. Complicated pulmonary hydatid cysts are in the literature associated with higher postoperative morbidity and mortality than uncomplicated cysts.⁷ In complicated pulmonary cases, infection and inflammation of the adjacent lung parenchyma may affect wound healing and lead to postoperative complications such as prolonged air leakage, empyema, and pneumonia. These complicated cysts result in supportive treatment and longer hospitalization rates. Safioleas *et al.*⁷ reported hospitalization trend in 42 patients with pulmonary hydatidosis with a 12-day median stay for uncomplicated cases versus a 21-day median stay for complicated cases.

In conclusion, hydatid cysts can be located in various tissues but an extrapulmonary thoracic location is extremely rare. After a reliable diagnosis with CT scan of the thorax and abdomen, surgery remains a safe curative treatment. Successful management through thoracotomy and removal of hydatid cysts will result without occurrence of complications. The literature has stressed that surgical intervention, before rupture of the cysts, is essential in order to minimize the development of morbidity and mortality.

REFERENCES

1. Kuzucu A, Soysal O, Ozgel M, Yologlu S. Complicated hydatid cyst of the lung: clinical and therapeutic issues. *Ann Thorac Surg* 2004; **77**:1200-4.
2. Buttenschoen K, Buttenschoen DC. Echinococcus granulosus infection: the challenge of surgical treatment. *Langenbecks Arch Surg* 2003; **388**: 218-30.
3. Oguzkaya F, Akcali Y, Kahraman C, Emirogullari N, Bilgin M, Sahin A. Unusually located hydatid cysts: intrathoracic but extrapulmonary. *Ann Thorac Surg* 1997; **64**: 334-7.
4. Zidane A, Arsalane A, Atoini F, Kabiri EH. Extra-pulmonary thoracic hydatid cysts. *Rev Pneumol Clin* 2006; **62**: 386-9.
5. Zidi A, Zannad-Hantous S, Mestiri I, Ghrairi H, Baccouche I, Djilani H, *et al.* Hydatid cyst of the mediastinum: 14 case reports. *J Radiol* 2006; **87**:1869-74.
6. Eroglu A, Kurkcuglu C, Karaoglanoglu N, Tekinbas C, Kaynar H, Onbas O. Primary hydatid cysts of the mediastinum. *Eur J Cardiothorac Surg* 2002; **22**:599-601.
7. Safioleas M, Misiakos EP, Dosios T, Manti C, Lambrou P, Skalkeas G. Surgical treatment for lung hydatid disease. *World J Surg* 1999; **23**: 1181-5.

