



THE AGA KHAN UNIVERSITY

eCommons@AKU

Section of Cardiothoracic Surgery

Department of Surgery

January 2012

How VATS has changed the management of spontaneous pneumothorax in the 21st century

Saulat H. Fatimi

Aga Khan University, sulat.fatimi@aku.edu

Hashim Muhammad Hanif

Aga Khan University

Sana Mansoor

Aga Khan University

Marium Muzaffar

Aga Khan University

Follow this and additional works at: http://ecommons.aku.edu/pakistan_fhs_mc_surg_cardiothoracic

 Part of the [Cardiology Commons](#)

Recommended Citation

Fatimi, S., Hanif, H., Mansoor, S., Muzaffar, M. (2012). How VATS has changed the management of spontaneous pneumothorax in the 21st century. *Journal of Pakistan Medical Association*, 62(10), 1041-1045.

Available at: http://ecommons.aku.edu/pakistan_fhs_mc_surg_cardiothoracic/67

How VATS has changed the Management of Spontaneous Pneumothorax in the 21st century

Saulat Hasnain Fatimi,¹ Hashim Muhammad Hanif,² Shahida Aziz,³ Sana Mansoor,⁴ Marium Muzaffar⁵
Department of Surgery, Division of Cardiothoracic Surgery,^{1,3} Medical College,^{2,4,5} Aga Khan University, Karachi, Pakistan.
Corresponding Author: Hashim Muhammad Hanif. Email: hashimhanif@gmail.com

Abstract

Objective: To determine the outcome of patients having undergone Video Assisted Thoracoscopic Surgery (VATS) for spontaneous pneumothorax in terms of hospital stay, complications and recurrence.

Methods: The retrospective study included the review of 39 cases who had presented with spontaneous pneumothorax at the Aga Khan University Hospital, Karachi, Pakistan, between January 2001 to November 2008 and had undergone video assisted thoracoscopic surgery (VATS).

Results: The duration of hospital stay (had a range of 3 to 9 days), and the length of chest tube in place (a range of 2 to 8 days), 2 (5.1%) patients developed recurrence after VATS while 3 (7.6%) patients developed bleeding post operatively requiring transfusion and 2 (5.1%) patients developed atelectasis requiring bronchoscopy.

Conclusion: Compared with figures for thoracotomy data from other studies, it was seen that the length of hospital stay and chest tube placement with VATS was less than that for thoracotomy, and the overall cost as well as post-operative pain was also low. The rate of recurrence was however comparable to that after thoracotomy.

Keywords: VATS; Spontaneous Pneumothorax. (JPMA 62: 1041; 2012)

Introduction

Pneumothorax is defined as the presence of air in the pleural space. It is classified as spontaneous (not caused by trauma or any obvious precipitating factor), traumatic (penetrating/blunt chest injury), or iatrogenic (due to transthoracic-needle aspiration, placement of a catheter in the subclavian, thoracentesis, pleural biopsy and barotrauma). Primary spontaneous pneumothorax (PSP) occurs in persons without clinically apparent lung disease; while secondary spontaneous pneumothorax (SSP) is a complication of preexisting lung disease.¹

Primary spontaneous pneumothorax has an estimated incidence of between 7.4 cases (age-adjusted incidence) and 18 cases per 100,000 population per year among males and between 1.2 cases (age-adjusted incidence) and 6 cases per 100,000 population per year among females.² It typically occurs in men between the ages of 10 and 30 years and rarely occurs in persons over the age of 40.³ Smoking cigarettes increases the risk of PSP in males by as much as a factor of 20.¹

Although patients with PSP have no apparent lung disease, majority (76-100%) of them have bullae formation found on VATS and thoracotomy.¹ PSP results in decreased vital capacity (VT) and increased alveolar-arterial oxygen gradient. Also, there is low ventilation-perfusion ratio and shunting, both of which result in hypoxia. However, as the underlying lung function is normal, hypercapnia does not develop. The onset is usually at rest with pleuritic chest pain and dyspnoea being, the most common complaint, but they usually get resolved in 24 hours. Findings on physical examination mostly include decreased movement of the chest wall, a hyper-resonant percussion note, diminished tactile fremitus, and decreased or absent breath sounds on the affected side. Chest X-Ray is the preferred method of diagnosis and the recurrence rate with PSP is around 30%.^{1,4}

SSP is, however, a more life threatening condition as it is often associated with chronic obstructive pulmonary diseases (COPD), Pneumocystis Jiroveci and pneumonia related to HIV infection. Incidence is approximately 6.3 cases per 100,000 population per year among males and 2 cases per 100,000 population per year among females with majority of the cases occurring later in life.² Clinical presentation includes severe dyspnoea, chest pain, hypoxia and hypotension, all of which do not resolve spontaneously. Physical findings however are minimal. Diagnosis is made on chest X-Ray and recurrence rates are similar to that of PSP (30%).

A number of surgical treatments are available for pneumothorax, the most widely used being insertion of a chest tube, pleurodesis, thoracoscopy through a single insertion port into the chest, video-assisted thoracoscopic surgery (VATS) and thoracotomy.

With the increasing advent of laparoscopic application in general surgery, VATS is also carving a niche for itself in thoracic surgery. Numerous studies have shown VATS to be associated with decreased perioperative pain and opiate requirement, better post-operative pulmonary function and decreased probable overall neutral cost impact which is found to be lower (22.7%) in comparison with traditional thoracotomy.^{5,6} Therefore the following study was designed as a retrospective case series with the objective of determining the outcome (in terms of hospital stay, complications, recurrences, and cost among other factors) of patients having undergone VATS for PSP and then comparing the results to the existing data available from previous international studies to validate the findings.

Patients and Methods

Retrospective analysis of charts of those patients who had under gone VATS for PSP between January 2001 and November 2008 at the Aga Khan University Hospital in Karachi was carried out. Data was collected during June/July 2010. Our sample size was 39. Based on convenience sampling, it included all the patients having undergone VATS for Spontaneous Pneumothorax during the specified period. SSP patients were excluded from the study. Data collected comprised of numerous variables including age, gender, mode of presentation, episodes of pneumothorax, operative procedure, pathological findings, postoperative complications, post-operative pain requirements, transfusion requirement, length of chest tube placement, hospital stay and the rate of recurrence. Results were calculated by taking out mean, median, frequency distribution and running a descriptive analysis of the data obtained.

Results

Of the total number of 39 patients in the study, 37 (94.9%) were males, and 2 (5.1%) were females. Indication for VATS was all patients with persistent air leak for more than 7 days or recurrence of pneumothorax after chest tube suction had been turned off or recurring pneumothorax. Patients with secondary causes of pneumothorax were not included. The age range was between 13-47 years (median age 21 years) (Figure-1). Smoking as risk factor was present in only 4 (10.3%) patients. Most common presenting complaint was pleuritic chest pain in 19 (48.7%) patients followed by chest pain and shortness of breath in 18 (46.1%). One (2.6%) female patient presented with complaints of monthly chest pain and one (2.6%) patient presented with fever which was later diagnosed as empyema secondary to pneumothorax. (Figure-2). The main diagnostic modality used in majority of patients was chest X-ray except in 8 (20.5%) patients where CT- Scan was done.

There were various indications for performing VATS in these patients. Out of the total who underwent VATS, 6

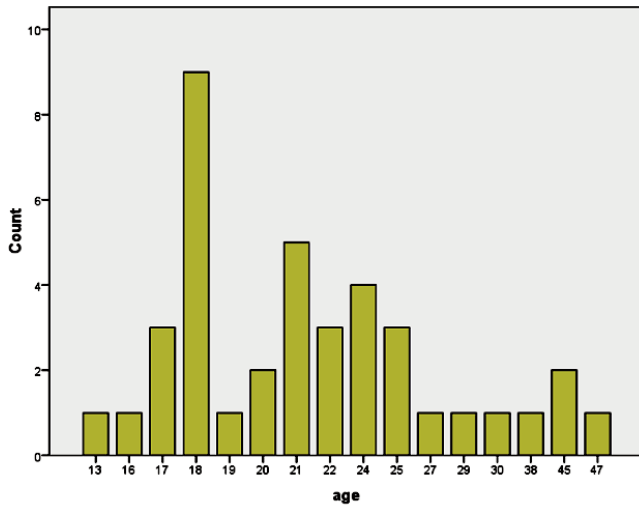


Figure-1: Age Demographics.

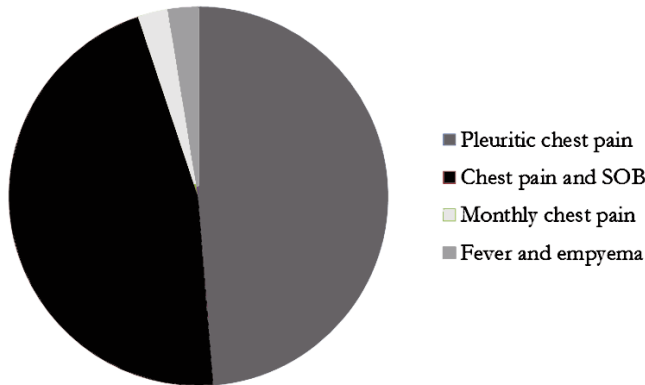


Figure-2: Presenting Complaints.

(15.4%) patients were after the first episode, because of persistent air leak, 28 (71.8%) patients were operated after second episode of spontaneous pneumothorax whereas 5 (12.8%) patients had to come to the hospital after a third episode of pneumothorax.

Among these patients, only 2 (5.1%) presented with bilateral pneumothorax, while 37 (94.9%) had unilateral pneumothorax. Out of the latter, the need for bilateral VATS was felt in 2 patients to assess the extensiveness of underlying pneumothorax and to rule out the high suspicion of bilateral disease process based on the severity of presenting complaints. Therefore VATS was done unilaterally in 35 (89.7%) patients and bilaterally in 4 (10.3%) after assessing the need for extensiveness of VATS required in each patient.

Operative procedures included VATS, clipping/stapling of bullae, apical pleurectomy and abrasive pleurodesis in 19 patients (48.7%), VATS, apical pleurectomy and abrasive pleurodesis in 18 (46.1%) patients and in 2

(5.2%), VATS was converted to open thoracotomy.

Pathological assessment of tissues revealed nonspecific findings in 30 (76.9%) patients, multiple bullae in 5 (12.8%), ruptured hydatid cyst in 2 (5.1%), histiocytosis X in 1 (2.6%) and catamenial pneumothorax in 1 (2.6%) patient.

The duration of hospital stay had a range of 3-9 days and length of chest tube in place had a range of 2-8 days. Recurrence of pneumothorax after VATS occurred in 2 (5.1%) patients. One was the patient with histiocytosis X, following one week after VATS and required chest tube insertion and talc pleurodesis. The other patient was a female with catamenial pneumothorax, who required thoracotomy and pleurectomy and treatment with Danazol for 1 year. Three (7.7%) patients developed bleeding postoperatively requiring transfusion. Two (5.1%) patients developed atelectasis requiring bronchoscopy. Of the total 32 (82.1%) patients did not have any complications post-operatively.

Discussion

Pneumothorax most commonly presents in the early age group that is amongst the teens and those in their early 20's.⁷ Incidence amongst male gender predominates such as in our study where 37 out of 39 patients were males. Patients have been known to most commonly present with pleuritic chest pain. The aim of the study was to assess the overall effectiveness of VATS and to weigh the pros and cons of using it as a primary means of treatment of pneumothorax where indicated. Although our study did not include the patients in whom thoracotomy was done, but the results were compared to the figures for patients undergoing both, either VATS or thoracotomy, from previous international studies. This therefore provided us with useful information for comparative analysis.

The two main therapeutic interventions for pneumothorax as discussed are thoracotomy and VATS. Thoracotomy is performed by a surgeon, and, rarely, by emergency physicians, to gain access to the thoracic organs, most commonly the heart, lungs, esophagus or thoracic aorta, or for access to the anterior spine for access to tumours in the spine. VATS on the other hand is based on the principle of laparoscopic surgeries, where a small camera and probes are inserted via much smaller incisions in the chest.

In our study, VATS as a primary treatment was successful in treating the majority of patients that is 37 out of a total of 39. It was accompanied by either clipping/stapling of bullae, apical pleurectomy or abrasive pleurodesis. There were only 2 cases where need for thoracotomy also arose.

A brief review of the existing data on the relevant subject provides us with a lot of positive results to compare the findings of our study. Christophe Doddoli et al.⁷ strongly suggested VATS to be a feasible, safe and efficacious

management option for recurrent primary spontaneous pneumothorax following thoracoscopic talc poudrage after 69% of the patients were successfully treated with this modality for recurrent pneumothorax

Sedrakyan et al. compared clinical outcomes of VATS and thoracotomy for three common procedures which were surgery for pneumothorax, minor resections, and lobectomy. The result of reviewing 12 trials with 670 randomised patients showed that VATS was associated with shorter length of stay (reduction ranged from 1.0 to 4.2 days) and less pain or use of pain medication than thoracotomy in the five out of seven trials in which the technique was used for pneumothorax or minor lung resection. VATS was also associated with substantially fewer recurrences than pleural drainage in two trials. However no significant advantage of VATS over thoracotomy was seen for lobectomies.⁸

Thoracotomy being a major surgical procedure and a more invasive one has various post-operative complications. Patients in surgical wards who have undergone thoracotomy are frequently seen with complications such as air leaks, infection, bleeding and respiratory failure. Postoperative pain is intense, generally requiring opioids, and does interfere with the recovery of respiratory function. This can even develop into chronic pain called thoracotomy pain syndrome. Thus one of the most important factor that goes in favour of VATS over thoracotomy is the reduced number of post-operative complications which are far less than that of thoracotomy.² Whereas patients being treated with thoracotomy needed special post-op pain management including intra thoracic nerve blocks, opiates and epidurals, such a need seldom arose following VATS, in which case the patients usually suffice with oral pain killers for a short duration. Thereby reducing the need and cost of pain relieving medications.

One of the greater benefits achieved with VATS is reduced inpatient duration. Patients following VATS become mobile sooner and are able to resume their everyday activity within a shorter period. Unlike those undergoing thoracotomy, where incision care and post-op pain management etc. require longer hospital stays, patients undergoing VATS can be very well managed on home care. In one study, hospital stays from operation until discharge were 11.5 days for open thoracotomy and 4.1 days for VATS ($p < 0.001$).⁹ Length of hospital stay as seen in ours and other studies ranged from 3 to 4 days which is again less than the hospital stay which is usual following thoracotomy.¹⁰ Furthermore it has also been noticed that length for which a chest tube is needed to be placed is shorter with VATS (average of 4 days as seen in our study), thus greatly reducing patient discomfort and hindrance in mobility.

This helps to cut down both financial and emotional burden on the patient. In a previous international study average management costs including hospitalization was

calculated at \$2,750.00 per patient for the group undergoing pleural drainage for primary pneumothorax compared with \$1,925.00 for the second group that underwent VATS.⁶

VATS also has application in treatment of PSP amongst paediatric population owing to its less postoperative complications and hospital stay. The results are particularly very good with Blebectomy plus pleurodesis (both mechanical and chemical).¹¹

A good indicator of the effectiveness with which a condition can be treated is the rate with which it can recur following the intervention in question.¹² One retrospective study compared the recurrence rates for conservative treatment, thoracotomy and VATS for spontaneous pneumothorax. The figures came out to be 56.4%, 3.0%, and 11.7%, respectively with no statistical difference between the open thoracotomy and VATS groups ($p = 0.15$).⁹

In our study the recurrence rate was 6% (2/37), which is almost comparable to the recurrence after thoracotomy. This itself speaks volumes about how both procedures can give equally good results with VATS having the edge in terms of being a less invasive modality.

As our understanding of science improves and technical advancements are made, it is but obvious that newer and more sophisticated methods of treatments are available. VATS is one such example. It promises to be a much safer, affordable and overall less invasive means of treating pneumothorax, which, itself being a life threatening condition was once believed to be only treatable by a major surgical procedure like thoracotomy alone. Despite having very good therapeutic results Thoracotomy carries with it various post-operative complications along with significant post-op pain and a considerably long recovery period in the hospital.

It can be argued that VATS requires specialised technical knowhow along with the knowledge of the basic underlying thoracic surgical techniques, but the benefits of it clearly outweigh the negatives. Not only PSP but minor resections and lobectomies can also be safely undertaken with VATS making it a multifunctional modality.¹³

It has also been proved that VATS in the treatment of primary spontaneous pneumothorax is emerging as a safe, less invasive treatment modality with overall good results that are comparable with more traditional surgical techniques.¹⁴

Conclusion

The study showed that the length of hospital stay, and period of chest tube placement in patients subjected to VATS was significantly less than patients undergoing thoracotomy.

References

1. Sahn SA, Heffner JE. Spontaneous pneumothorax. *N Eng J Med* 2000; 342: 868-74.

2. Melton LJ 3rd, Hepper NG, Offord KP. Incidence of spontaneous pneumothorax in Olmsted County, Minnesota: 1950 to 1974. *Am Rev Respir Dis* 1979; 120: 1379-82.
 3. Primrose WR. Spontaneous pneumothorax: a retrospective review of aetiology, pathogenesis and management. *Scott Med J* 1984; 29: 15-20.
 4. Schramel FM, Postmus PE, Vanderschueren RG. Current aspects of spontaneous pneumothorax. *Eur Respir J* 1997; 10: 1372-9.
 5. Qureshi R, Nugent A, Hayat J, Qureshi M, Norten R, et al., Should surgical pleurectomy for spontaneous pneumothorax be always thoracoscopic? *Interact Cardiovasc Thoracic Surg* 2008; 7: 569-72.
 6. Torresini G, Vaccarili M, Divisi D, Gisci R. Is video-assisted thoracic surgery justified at first spontaneous pneumothorax? *Eur J Cardio-thorac Surg* 2001; 20: 42-5.
 7. Gupta D, Hansell A, Nichols T, Duong T, Ayres JG, Strachan D. Epidemiology of pneumothorax in England. *Thorax* 2000; 55: 666-71.
 8. Sedrakyan A, Van der Meulen J, Lewsey J, Treasure T. Video assisted thoracic surgery for treatment of pneumothorax and lung resections: systematic review of randomised clinical trials. *BMJ* 2004; 329: 1008.
 9. Sawada S, Watanabe Y, Moriyama S. Video-assisted thoracoscopic surgery for primary spontaneous pneumothorax: evaluation of indications and long-term outcome compared with conservative treatment and open thoracotomy. *Chest* 2005; 127: 2226-30.
 10. Bense L, Wiman LG. Time relation between sale of cigarettes and the incidence of spontaneous pneumothorax. *Eur J Respir Dis* 1987; 71: 362-4.
 11. Bialas RC, Weiner TM, Phillips JD. Video-assisted thoracic surgery for primary spontaneous pneumothorax in children: is there an optimal technique? *J Pediatr Surg* 2008; 43: 2151-5.
 12. Doddoli C, Barlesi F, Fraticelli A, Thomas P, Astoul P, Guidicelli R, et al. Video-assisted thoracoscopic management of recurrent primary spontaneous pneumothorax after prior talc pleurodesis: a feasible, safe and efficient treatment option. *Eur J Cardio-thorac Surg* 2004; 26: 889-92.
 13. Sakurai, H., Videothoracoscopic surgical approach for spontaneous pneumothorax: review of the pertinent literature. *World J Emerg Surg* 2008; 3: 23.
 14. Henry M, Arnold T, Harvey J. BTS guidelines for the management of spontaneous pneumothorax. *Thorax* 2003; 58: ii52.
-