



THE AGA KHAN UNIVERSITY

eCommons@AKU

Section of Cardiothoracic Surgery

Department of Surgery

January 2016

Atresia of the descending aorta in a young woman requiring bypass graft

Ammarah Mashhood

Aga Khan University

Taimur Asif Ali

Aga Khan University

Saulat H. Fatimi

Aga Khan University, saulat.fatimi@aku.edu

Follow this and additional works at: http://ecommons.aku.edu/pakistan_fhs_mc_surg_cardiothoracic



Part of the [Surgery Commons](#)

Recommended Citation

Mashhood, A., Ali, T., Fatimi, S. (2016). Atresia of the descending aorta in a young woman requiring bypass graft. *Journal of College of Physicians and Surgeons Pakistan*, 26(11), S85-S86.

Available at: http://ecommons.aku.edu/pakistan_fhs_mc_surg_cardiothoracic/54

Atresia of the Descending Aorta in a Young Woman Requiring Bypass Graft

Ammarah Mashhood¹, Taimur Asif Ali² and Saulat Hasnain Fatimi²

ABSTRACT

Congenital aortic atresia is a malformation accounting for 4 - 6% of all congenital heart diseases in children. Left ventricular outflow obstruction due to atresia is common at the aortic valve but rarely has atresia been identified in the descending aorta. We report the case of a 25-year woman who was evaluated for headache and uncontrolled hypertension. CT scan chest showed a short atretic segment in the descending aorta at the isthmus, distal to the takeoff of the subclavian artery. She underwent surgery; a 22 mm Dacron graft was taken and jump graft was placed between the arch of the aorta and the descending aorta, using partial occlusion clamps. Patient tolerated the procedure well and was discharged on ACE Inhibitors and beta blockers, which were then weaned off over a period of one year. She remained stable and had no further complaints.

Key Words: Aorta. Aortic operation. Adult. Cardiopulmonary bypass. Echocardiography.

INTRODUCTION

Aortic atresia has a reported prevalence of 4.4 per 10,000 live births,¹ and is more common in males than females.² It is the most common congenital cause of left heart obstruction, accounting for 4 - 6% of all congenital heart defects.^{1,3}

Atresia is mostly congenital; but rarely, can be acquired due to severe atherosclerosis of the aorta, occurring most frequently in patients with severe hypercholesterolemia. Its prevalence sharply increases with age.⁴ Rheumatic fever can also lead to aortic atresia in very rare situations.⁵

The presentation of patients with aortic atresia is a wide spectrum ranging from being asymptomatic to having severe hemodynamic implications.

CASE REPORT

We present the case of a 25-year woman who was evaluated for headache and uncontrolled hypertension. The patient was noted to be hypertensive at various clinic visits. General physical examination revealed radiofemoral pressure difference of more than 60 mmHg, but the rest of the examination was unremarkable. Baseline investigations were all within normal limits. Echocardiography showed normal left ventricular (LV) function with left ventricular hypertrophy and flow, which

was suggestive of tight obstruction in the descending aorta. CT scan of the chest was done, which revealed a short atretic segment in the descending aorta at the level of the isthmus, distal to the take off of the subclavian artery (Figure 1).

The patient underwent surgery. The descending aorta and arch of the aorta were exposed via left posterolateral thoracotomy. The atretic segment of the aorta was identified. Intraoperatively, blood pressures were assessed by two arterial lines; one in right radial artery and the other in right femoral artery, which showed a significant difference of 40 mmHg across the atretic segment. A 22 mm Dacron graft was taken and jump graft was placed between the arch of the aorta and the descending aorta, using partial occlusion clamps (Figure 2).

Patient tolerated the procedure well. No significant pressure difference or radio-femoral delay was noted post-operatively. Postoperative course remained unremarkable.

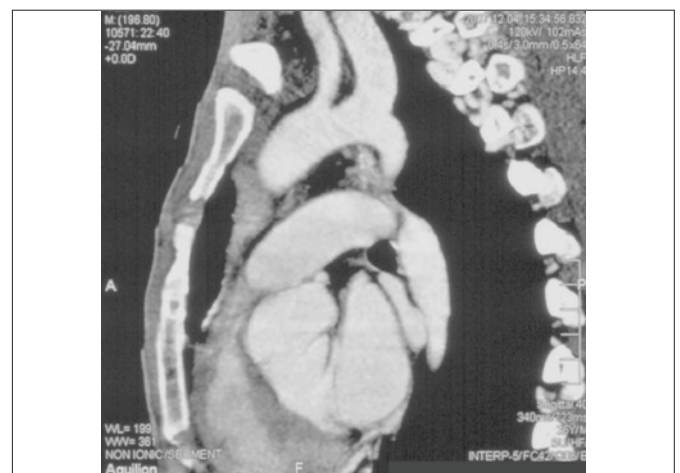

Figure 1: CT scan showing the atretic aortic isthmus.

¹ Medical College, The Aga Khan University, Karachi.

² Department of Surgery, Division of Cardiothoracic Surgery, The Aga Khan University Hospital, Karachi.

Correspondence: Dr. Ammarah Mashhood, Department of Cardiothoracic Surgery, The Aga Khan University Hospital, Stadium Road, P.O. Box 3500, Karachi.

E-mail: amashhood90@yahoo.com

Received: September 20, 2013; Accepted: March 04, 2016.

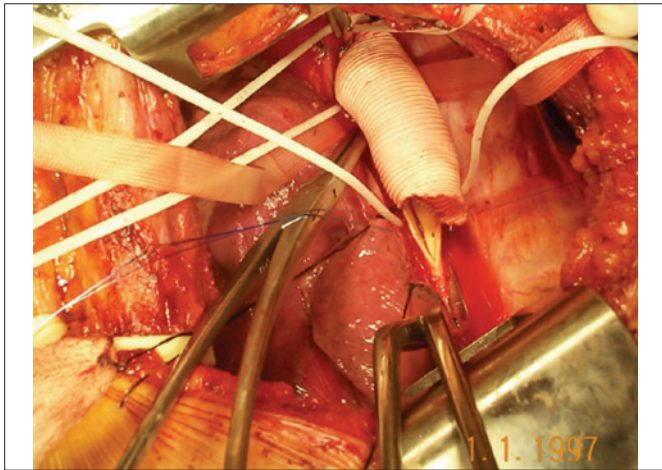


Figure 2: Dacron graft anastomosed proximal and distal to atretic segment as jump graft.

Patient was discharged on ACE Inhibitors and beta-blockers, which were weaned off over a period of one year with normalisation of blood pressures. A one-year follow-up echocardiogram showed normal LV function with almost complete regression of the LV hypertrophy.

DISCUSSION

Aortic atresia can occur either in isolation or with other complex cardiac anomalies such as patent ductus arteriosus, bicommissural pulmonic valve, and congenital mitral regurgitation. Left ventricular outflow obstruction due to atresia is most commonly present at the aortic valve; but rarely has atresia been identified in the descending aorta.

Children and adults with chronic severe aortic atresia maintain their left ventricular output by hypertrophy of the left ventricle.⁶ This may even sustain the large pressure gradient without compromising the cardiac output or resulting in left ventricular dilation or the development of any symptoms. Chronic obstruction, however, leads to left ventricular hypertrophy which at one hand, preserves ejection fraction; but simultaneously, leads to impaired coronary blood flow.

Many patients can be diagnosed before the onset of any symptom with an electrocardiogram, done on the basis of finding a systolic murmur on physical examination. There can be a long asymptomatic period; but as the disease progresses and the obstruction increases, symptoms like syncope, exertional dyspnea, and angina may be precipitated.⁷ There is a latent period during which the severity remains mild to moderate and the prognosis remains good. However, even with development of mild symptoms, survival rates decline.⁸

Reports have been published reporting cases of sudden death in a small time span following the onset of symptoms.⁹ Late findings may include heart failure, atrial fibrillation, pulmonary hypertension, and systemic venous hypertension.

Management varies depending upon the severity and presence of symptoms. Mild atresia in the absence of symptoms can be managed with endocarditis prophylaxis, patient education, and an echocardiogram follow-up. However, symptomatic patients require surgery. The past autopsy studies indicate that the mortality rate is 80% by age of 50, in patients in whom coarctation of aorta is not surgically repaired.¹⁰ The disease is rare, but the quality of life may be maintained if this pathology is taken care of adequately and surgery and management performed safely.

Aortic valve replacement is the most common surgery performed for aortic atresia. Due to an unusual location of the atresia in this case, a different approach was taken as a jump graft was used to bypass the atretic segment which was described earlier.

REFERENCES

1. Reller MD, Strickland MJ, Riehle-Colarusso T, Mahle WT, Correa A. Prevalence of congenital heart defects in metropolitan Atlanta, 1998-2005. *J Pediatr* 2008; **153**:807-13.
2. Kenny D, Hijazi ZM. Coarctation of the aorta: From fetal life to adulthood. *Cardiol J* 2011; **18**:487-95.
3. Hoffman JI, Kaplan S. The incidence of congenital heart disease. *J Am Coll Cardiol* 2002; **39**:1890.
4. lung B. Epidemiology of valvular heart diseases in the adult. *Rev Prat* 2009; **59**:173-7.
5. Essien IO, Onwubere BJ, Anisiuba BC, Ejim EC, Andy JJ, Ike SO. One year echocardiographic study of rheumatic heart disease at Enugu, Nigeria. *Niger Postgrad Med J* 2008; **15**: 175-8.
6. Rogers JH, Tamirisa P, Kovacs A, Weinheimer C, Courtois M, Blumer KJ, *et al.* RGS4 causes increased mortality and reduced cardiac hypertrophy in response to pressure overload. *J Clin Invest* 1999; **104**:567-76.
7. Carabello BA, Paulus WJ. Aortic stenosis. *Lancet* 2009; **373**: 956-66.
8. Ross J Jr., Braunwald E. Aortic stenosis. *Circulation* 1968; **38** (1 suppl):61-7.
9. Kelly TA, Rothbart RM, Cooper CM, Kaiser DL, Smucker ML, Gibson RS. Comparison of outcome of asymptomatic to symptomatic patients older than 20 years of age with valvular aortic stenosis. *Am J Cardiol* 1988; **61**:123-30.
10. Abbott ME. Statistical study and historical retrospect of 200 recorded cases, with autopsy, of stenosis or obliteration of the descending arch in subjects above the age of two years. *Am Heart J* 1928; 392-421, 574-618.

