



THE UNIVERSITY *of* EDINBURGH

Edinburgh Research Explorer

Endothelial Progenitor Cell Biology and Vascular Recovery Following Transradial Cardiac Catheterization

Citation for published version:

Mitchell, A, Fujisawa, T, Mills, NL, Brittan, M, Newby, DE & Cruden, NLM 2017, 'Endothelial Progenitor Cell Biology and Vascular Recovery Following Transradial Cardiac Catheterization' Journal of the American Heart Association, vol. 6, no. 11. DOI: 10.1161/JAHA.117.006610

Digital Object Identifier (DOI):

[10.1161/JAHA.117.006610](https://doi.org/10.1161/JAHA.117.006610)

Link:

[Link to publication record in Edinburgh Research Explorer](#)

Document Version:

Publisher's PDF, also known as Version of record

Published In:

Journal of the American Heart Association

Publisher Rights Statement:

This is an open access article under the terms of the Creative Commons AttributionNonCommercial License, which permits use, distribution and reproduction in any medium, provided the original work is properly cited and is not used for commercial purposes.

General rights

Copyright for the publications made accessible via the Edinburgh Research Explorer is retained by the author(s) and / or other copyright owners and it is a condition of accessing these publications that users recognise and abide by the legal requirements associated with these rights.

Take down policy

The University of Edinburgh has made every reasonable effort to ensure that Edinburgh Research Explorer content complies with UK legislation. If you believe that the public display of this file breaches copyright please contact openaccess@ed.ac.uk providing details, and we will remove access to the work immediately and investigate your claim.



Endothelial Progenitor Cell Biology and Vascular Recovery Following Transradial Cardiac Catheterization

Andrew Mitchell, MBChB, BSc;* Takeshi Fujisawa, PhD;* Nicholas L. Mills, MBChB, BSc, PhD; Mairi Brittan, BSc, PhD; David E. Newby, MBChB, MD, PhD; Nicholas L. M. Cruden, MBChB, BSc, PhD

Background—Transradial catheterization is associated with radial artery injury and vasomotor dysfunction and represents an accessible model of acute vascular injury in humans. We characterized vascular injury and functional recovery to understand the role of circulating endothelial progenitor cells in vascular repair.

Methods and Results—In 50 patients (aged 64 ± 10 years, 70% male) undergoing transradial cardiac catheterization, radial artery injury was assessed by optical coherence tomography and examination of explanted vascular sheaths. Flow- and nitrate-mediated dilatation of the radial artery was assessed in both arms at baseline, at 24 hours, and at 1, 4, and 12 weeks. Circulating endothelial progenitor cell populations were quantified using flow cytometry. Late endothelial outgrowth colonies were isolated and examined in vitro. Optical coherence tomography identified macroscopic injury in 12 of 50 patients (24%), but endothelial cells ($1.9 \pm 1.2 \times 10^4$ cells) were isolated from all arterial sheaths examined. Compared with the noncatheterized radial artery, flow-mediated vasodilatation was impaired in the catheterized artery at 24 hours ($9.9 \pm 4.6\%$ versus $4.1 \pm 3.1\%$, $P < 0.0001$) and recovered by 12 weeks ($8.1 \pm 4.9\%$ versus $10.1 \pm 4.9\%$, $P = 0.09$). Although the number of CD133⁺ cells increased 24 hours after catheterization ($P = 0.02$), the numbers of CD34⁺ cells and endothelial outgrowth colonies were unchanged. Migration of endothelial cells derived from endothelial outgrowth colonies correlated with arterial function before catheterization but was not related to recovery of function following injury.

Conclusions—Transradial cardiac catheterization causes endothelial denudation, vascular injury, and vasomotor dysfunction that recover over 12 weeks. Recovery of vascular function does not appear to be dependent on the mobilization or function of endothelial progenitor cells.

Clinical Trial Registration—URL: <https://www.clinicaltrials.gov>. Unique identifier: NCT02147119. (*J Am Heart Assoc.* 2017;6:e006610. DOI: 10.1161/JAHA.117.006610.)

Key Words: cardiac catheterization • endothelial cell • endothelial function • radial artery catheter • vascular imaging

Endothelial injury is central to the onset and progression of atherosclerosis and is ubiquitous following balloon inflation during percutaneous coronary intervention (PCI). The consequence of endothelial denudation and dysfunction is determined by the regenerative response mediated by the local vasculature and circulating cells. Efforts to study and modify this response have been hampered by the lack of an

accessible and well-characterized model of vascular injury in humans.

The radial artery has emerged as the access site of choice for cardiac catheterization,^{1,2} but there is a substantial incidence of subclinical radial artery injury,^{3,4} which is associated with vasomotor impairment.^{5–12} Although ethical considerations make it challenging to induce traumatic

From the BHF/University Centre for Cardiovascular Science (A.M., T.F., N.L.M., M.B., D.E.N., N.L.M.C.), and BHF Centre for Vascular Regeneration, Scottish Centre for Regenerative Medicine, (A.M., T.F., N.L.M., M.B., D.E.N., N.L.M.C.), University of Edinburgh, United Kingdom; Edinburgh Heart Centre, NHS Lothian, Edinburgh, United Kingdom (A.M., N.L.M., D.E.N., N.L.M.C.).

Accompanying Tables S1 through S3 are available at <http://jaha.ahajournals.org/content/6/11/e006610/DC1/embed/inline-supplementary-material-1.pdf>

*Dr Mitchell and Dr Fujisawa contributed equally to this work.

Correspondence to: Andrew Mitchell, MBChB, BSc, Centre for Cardiovascular Science, University of Edinburgh, Chancellor's Building, 49 Little France Drive, Edinburgh EH16 4SB, United Kingdom. E-mail: andrewjmitchell@doctors.org.uk

Received May 15, 2017; accepted July 28, 2017.

© 2017 The Authors. Published on behalf of the American Heart Association, Inc., by Wiley. This is an open access article under the terms of the Creative Commons Attribution-NonCommercial License, which permits use, distribution and reproduction in any medium, provided the original work is properly cited and is not used for commercial purposes.

Clinical Perspective

What Is New?

- Although radial artery injury is a well-recognized consequence of transradial cardiac catheterization, this study is the first to comprehensively and simultaneously describe structural injury, vasomotor function, and accompanying cellular profiles.
- The incidence of arterial injury detectable by intravascular imaging following transradial cardiac catheterization in this study using contemporary equipment is lower than described previously.
- Transradial cardiac catheterization causes reversible vasomotor dysfunction, the recovery of which is not influenced by peripheral blood endothelial progenitor cell concentrations or in vitro endothelial outgrowth cell function.

What Are the Clinical Implications?

- The superiority of the radial artery as the access route of choice for cardiac catheterization is emphasized by low incidence of arterial injury and the reversible nature of vasomotor dysfunction.
- The lack of association between traditionally defined endothelial progenitor cell concentrations and vascular recovery suggests that these populations may not play an important role in vascular repair.
- Given the feasibility of defining arterial injury and following arterial function noninvasively, the radial artery in the context of cardiac catheterization is a useful model to examine the processes influencing vascular repair and may be a useful tool in translational studies of potential therapies.

experimental arterial injury in human patients, transradial cardiac catheterization offers the opportunity to study this process in a controlled setting.

The cellular response to vascular injury is important in atherogenesis as well as in vascular remodeling following coronary intervention. Since the first description by Asahara et al in 1997,¹³ the role of circulating endothelial progenitor cells (EPCs), has been the focus of intense research. Associations have been observed between circulating EPC numbers, vascular function, and cardiovascular outcomes.¹⁴ However, controversy over the phenotypic definition of these cells and their specific role in vascular repair as well as their scarcity in the peripheral blood¹⁵ make their study and therapeutic manipulation challenging.

Late endothelial outgrowth cells (EOCs) are isolated from peripheral blood mononuclear cells expanded under angiogenic culture conditions.¹⁶ These cells have high proliferative activity, form a monolayer of cells resembling mature endothelium in culture, and form perfusing vessels

in vivo.^{16,17} As such, EOCs are widely considered to be the progeny of circulating EPCs.¹⁸ Assessment of EOC function and the mobilization of EPCs following controlled vascular injury may provide novel insights into their role in vascular repair and regeneration.

This study aimed to characterize the extent of acute vascular injury following transradial cardiac catheterization, the degree of functional impairment, the time course of recovery, and the contribution of circulating EPCs to the restoration of vascular function.

Methods

Participants

Fifty patients undergoing elective transradial cardiac catheterization for known or suspected coronary artery disease at the Royal Infirmary of Edinburgh, Scotland (UK) were recruited. Patients were excluded if they had a recent acute coronary syndrome or cardiac catheterization (<3 months) or had severe valvular heart disease, renal impairment (estimated glomerular filtration rate <30 mL/min per 1.73 m²), contrast allergy, pregnancy, or were unable to give informed consent. The study was approved by the local research ethics committee, and written informed consent was obtained from all patients.

Protocol

At the time of cardiac catheterization, structural injury to the radial artery was assessed by optical coherence tomography (OCT). Radial sheaths were also examined for endothelial cells in a subset of patients (n=10). Function of the radial artery was assessed using flow-mediated dilatation (FMD) and nitrate-mediated dilatation (NMD) at baseline, at 24 hours, and at 1, 4, and 12 weeks after angiography. In all patients, the contralateral (noncatheterized) radial artery was examined as an internal control. Venous blood was obtained to isolate and culture endothelial cells at baseline and at 24 hours following catheterization, as described below.

Cardiac Catheterization

Angiography was performed via the right radial artery in all cases. Briefly, following local anesthesia with 1% lidocaine, the radial artery was punctured using the Seldinger technique. An intravenous bolus of heparin (5000 U) was given, with additional heparin administered at the operator's discretion if follow-on coronary intervention was undertaken. Arterial sheaths were removed at the end of the procedure with hemostasis achieved by a compressive wrist band (TR band; Terumo).

Optical Coherence Tomography

OCT of the radial artery was performed at the beginning and end of the angiography procedure. Briefly, a 6-French arterial sheath (Check-Flo, 13 cm, uncoated; Cook Medical) was inserted a short distance (2 cm) into the vessel. A coronary guide wire (Balance Middleweight; Abbot Vascular) was then passed to the brachial artery under fluoroscopic guidance, over which an OCT catheter (Fastview; Terumo) was advanced with the position monitored using live intravascular imaging. Following 200 μ g of intraradial glyceryl trinitrate, contrast (75% solution Omnipaque; GE Healthcare) was injected into the radial sheath, and pullback of the 15 cm of artery proximal to sheath insertion was performed. The sheath was then inserted to its full length, and the invasive coronary angiogram was performed. At the end of the procedure, the sheath was withdrawn to its original insertion point (2 cm into the vessel) and the artery reimaged as described earlier.

Vessel dimensions were assessed at 1-cm intervals, with 3 consecutive frames analyzed at each location. Areas of the internal elastic lamina, external elastic lamina, and radial artery lumen were manually defined and then automatically calculated using proprietary software (Lunawave; Terumo). Mean intimal area was defined as average internal elastic lamina area minus average luminal area. Structural injury was assessed qualitatively on a frame-by-frame basis and classified as intimal tear (a visible flap contained within the intima) or medial dissection (extending into the media) when present on at least 3 consecutive frames.

FMD and NMD of the Radial Artery

FMD and NMD were assessed according to international guidelines.^{19,20} Briefly, the radial artery was imaged 5 cm proximal to the radial styloid with a 12- to 15-MHz linear-array ultrasound transducer (CX50; Phillips) held in place by a stereotactic clamp. A baseline recording was captured over 60 seconds. A suprasystolic cuff was then inflated to 220 mm Hg for 5 minutes immediately distal to the antecubital fossa. Following release of the cuff, the artery was imaged continuously for 5 minutes (FMD). After 15 minutes of rest, the artery was again imaged for 60 seconds. Participants then received 25 μ g of sublingual glyceryl trinitrate, and the radial artery was imaged for another 5 minutes (NMD). Assessments were carried out in a quiet, temperature-controlled (18–25°C) room at the same time of day to minimize biological variation. Blood pressure and heart rate were monitored during the resting period and after cuff release using an oscillometric sphygmomanometer placed on the contralateral arm. In previous studies, we demonstrated good reproducibility of these techniques with a mean bias

(between day repeatability for FMD) of -4.3% (95% confidence intervals of -18.3% to 9.7%).²¹

Image acquisition was ECG-gated with arterial diameter captured during end-diastole (*R*-wave triggered). The artery was initially identified using color-flow Doppler, which also allowed assessment of radial artery patency at all visits. The probe position that gave the largest arterial diameter and the clearest definition of the anterior vessel wall was chosen to minimize the potential to underestimate lumen diameter. The focus position of the probe was set to the anterior vessel wall, as this is the most challenging to resolve.¹⁹ Images were analyzed offline using proprietary software (Brachial Analyzer, Vascular Tools; Medical Imaging Applications). Baseline and peak diameters were measured in millimeters, with measurements averaged across 60 and 10 frames for baseline and peak values, respectively. FMD and NMD were expressed as percentage change in diameter from baseline.

Characterization of Arterial Sheath-Associated Cells

Arterial sheaths were examined for the presence of endothelial cells at the end of the procedure in a subset of patients ($n=10$). The lumen was flushed to remove blood, and the sheaths were placed in phosphate-buffered saline and centrifuged at 400 g for 8 minutes to recover adherent cells. Cells were incubated with a panel of monoclonal antibodies specific to the endothelial cell antigen CD31-PE (Phycoerythrin), platelets with CD42a-FITC (Flourescein isothiocyanate), and hematopoietic cells with CD45-APC (Allophycocyanin), and 40 000 events were acquired using a 4-laser flow cytometer (LSRFortessa; BD Biosciences).

Circulating EPCs

Venous blood (100 mL) was obtained from all patients immediately before and 24 hours after cardiac catheterization. Fresh blood was stained with panels of pre-conjugated anti-human monoclonal antibodies to quantify putative EPC populations: CD45-V450, CD34-APC/Cy7, KDR (Kinase domain receptor)-PE, and CD133-APC. CountBright beads (ThermoFisher Scientific) were used to quantify absolute cell numbers. Unstained samples were used as negative controls, and compensation was performed using commercially available beads. Samples were processed, and 80 000 events were acquired on lymphocyte gate using a 4-laser flow cytometer (LSRFortessa II; BD Biosciences).

Late-Outgrowth Endothelial Cells

EOCs were cultured as described by Ingram et al.¹⁶ Mononuclear cells were isolated from peripheral blood using gradient-

density centrifugation with Ficoll Paque PLUS (GE Healthcare). Next, 10 million mononuclear cells were suspended in endothelial growth medium (EGM II; Lonza) with 10% Hyclone fetal bovine serum (Lonza) and seeded onto type 1 rat's tail collagen-coated 6-well plates. Cells were incubated at 37°C, 5% CO₂, and 95% relative humidity. Medium was replenished twice per week. Late-outgrowth colonies were counted as they emerged, and cells were harvested using trypsin-EDTA for further analysis at 3 to 4 weeks.

The migratory potential and cell surface marker profile was compared at baseline and 24 hours after cardiac catheterization. Migratory potential was assessed using a standard "scratch" assay, as described previously.²² A scratch was made with a sterile pipette tip, and images were acquired at 0 and 16 hours (Zeiss Observer; Carl Zeiss). Images were analyzed using automated software (ImageJ; National Institutes of Health). Wound healing as a measure of the migratory potential of EOCs was expressed as a percentage of the scratch covered by 16 hours. EOC surface marker expression was assessed (passage 1–3) using preconjugated antibodies, as described.

Statistical Analyses

Results are expressed as mean±SD or median (interquartile range [IQR]), as appropriate. Comparisons between normally distributed variables were made using paired and unpaired *t* tests and ANOVA. For nonnormally distributed variables, populations were compared using Mann–Whitney and Wilcoxon matched pairs tests for paired and unpaired data, respectively. Kruskal–Wallis tests were used for comparisons between multiple groups with nonnormal distributions. Correlation was performed using Spearman or Pearson analyses, as appropriate. Analyses were performed using SPSS version 21.0 (IBM Corp). Statistical significance was taken to be a 2-sided *P*<0.05.

Results

Fifty patients (aged 64±10 years, 70% male) were enrolled, of whom 18 (36%) underwent follow-on PCI (Table 1). Forty-five patients completed the full protocol: 1 patient was excluded because of early repeated transradial cardiac catheterization, and 2 patients underwent early coronary artery bypass grafting. Two patients had persistent radial occlusion after the procedure that precluded further analyses of radial vasomotor function.

Radial Artery Injury

The radial artery was imaged by OCT over an average length of 132±12 mm. The radial artery diameter measured 3.2±0.4 mm with a cross-sectional area of 10.7±2.5 mm² and an intimal area of 0.6±0.2 mm². Macroscopic injury

Table 1. Characteristics of Study Population (n=50)

Clinical Characteristic	Mean±SD or n (%)
Age, y	64±10
Male	35 (70)
Hypertension	37 (74)
Diabetes mellitus	7 (14)
Current smoker	10 (20)
Hypercholesterolemia	28 (56)
Family history	38 (76)
Previous radial access	7 (14)
PCI	18 (36)
Total cholesterol, mg/dL	176±8.5
Creatinine, mg/dL	0.9±0.2
C-reactive protein, mg/L	3.7±4.4
Medications	
Aspirin	46 (92)
Clopidogrel	30 (60)
Beta-blocker	41 (82)
ACEI/ARB	18 (36)
Nitrate	10 (20)
Statin	48 (90)
Radial artery dimensions	
Baseline radial artery diameter (mm)	
Ultrasound	
Right (catheterized)	2.9±0.4
Left (noncatheterized)	2.9±0.5
OCT	
Right (catheterized)	3.0±0.4

ACEI indicates angiotensin-converting enzyme inhibitor; ARB, angiotensin receptor blocker; OCT, optical coherence tomography; PCI, percutaneous coronary intervention.

arising from transradial catheterization was observed in 12 of 50 patients (24%). Endothelial disruption limited to the intima was seen in 8 patients (16%), whereas significant dissection extending into the media was seen in 4 patients (8%; Figure 1). Macroscopic injury was observed in the distal vessel in 6 patients (50%), midvessel in 1 patient (8%), and in the proximal vessel in 5 patients (42%). Endothelial cells defined as CD31⁺, CD42a⁻, and CD45⁻ were isolated from all arterial sheaths (1.9±1.2×10⁴ cells per sheath) regardless of the presence or absence of macroscopic injury.

Flow- and Nitrate-Mediated Dilatation

Radial artery diameter at baseline was 2.9±0.4 mm and 2.9±0.5 mm in the catheterized and noncatheterized

arteries, respectively. Vasomotion in the catheterized arm both in response to glyceryl trinitrate and FMD was reduced (ANOVA, $P<0.05$) Bonferroni post hoc tests were used to compare catheterized and uncatheterized arteries at different time points. FMD was impaired in the catheterized radial artery at 24 hours ($4.1\pm 3.1\%$) compared with the non-catheterized artery ($9.9\pm 4.6\%$, $P<0.0001$). At 3 months, FMD was no longer significantly impaired in the catheterized radial artery compared with the noncatheterized radial artery ($8.1\pm 4.9\%$ versus $10.1\pm 4.9\%$, respectively; $P=0.09$; Figure 2). NMD in the catheterized radial artery at 24 hours was attenuated compared with the noncatheterized radial artery ($2.9\pm 4.7\%$ versus $8.8\pm 5.4\%$, respectively; $P<0.0001$). This impairment persisted at 1 week but was no longer present at 1 month ($6.6\pm 4.1\%$ versus $8.4\pm 3.4\%$ for catheterized versus noncatheterized radial arteries, respectively; $P=0.12$; Figure 2).

EPCs and Vascular Injury

Patients were classified as having acute vascular injury ($n=28$) if OCT imaging identified macroscopic injury of the radial artery ($n=12$) or if they underwent follow-on PCI ($n=18$) or both sustained radial injury and underwent PCI. Those in the no-injury group ($n=20$) had diagnostic angiography alone. There was no change in the number of CD34⁺ cells from baseline to 24 hours following cardiac catheterization regardless of whether the procedure induced vascular injury (median: 12.0 [IQR: 7.8–19.0] versus 15.0 [IQR: 12.4–32.3]

$\times 10^6$ cells/L; $P=0.08$) or not (median: 13.0 [IQR: 7.8–23.0] versus 16.0 [IQR: 11.1–21.0] $\times 10^6$ cells/L; $P=0.50$). There was an increase in CD133⁺ cells at 24 hours in those with evidence of vascular injury (median: 2.3 [IQR: 1.2–3.7] versus 2.8 [IQR: 2.3–6.1] $\times 10^6$ cells/L; $P=0.02$) but not in those without such evidence (median: 1.7 [IQR: 0.7–2.5] versus 2.6 [IQR: 1.4–4.9] $\times 10^6$ cells/L; $P=0.09$). There were no changes in CD34⁺KDR⁺ or CD34⁺133⁺KDR⁺ cells at 24 hours in either group (Figure 3). When patients were stratified by the extent or type of vascular injury, there were no differences in CD34⁺, CD133⁺ CD34⁺KDR⁺, or CD34⁺133⁺KDR⁺ cell concentrations between groups (cellular concentrations at baseline and 24 hours as well as change from baseline were compared across groups; see Tables S1 through S3).

Late EOCs

Isolated EOCs had a typical “cobblestone” monolayer morphology and consistently expressed CD31 and CD34 (Figure 4A). Compared with baseline, there was no difference in the number of EOC colonies isolated at 24 hours (median: 1.0 [IQR: 0.0–3.0] versus 0.5 [IQR: 0.0–2.0] colonies per patient; $P=0.06$). There was no difference in the migratory function of EOCs isolated at baseline and 24 hours ($50.0\pm 2.9\%$ versus $49.3\pm 2.9\%$ wound coverage; $P=0.82$; Figure 4B–4D). Compared with colonies isolated at baseline, there were no changes in EOC expression of CD34 ($69.7\pm 9.1\%$ versus $67.8\pm 9.9\%$, $P=0.80$), CD31 ($94.1\pm 2.8\%$ versus $98.3\pm 0.4\%$,

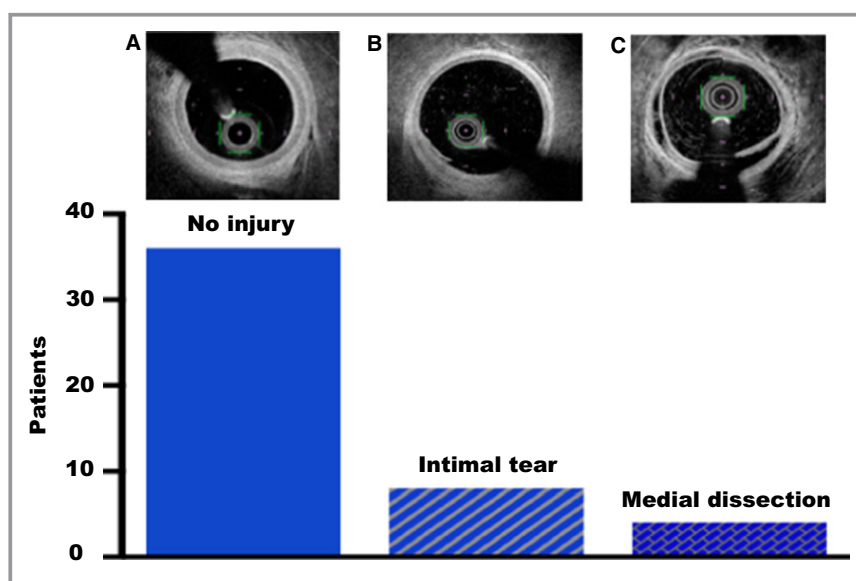


Figure 1. Radial artery injury following cardiac catheterization. Macroscopic injury was detectable on intravascular imaging in 12 of 50 patients (20%). Healthy uninjured artery at sheath withdrawal (A). Small intimal tear at the 7 o'clock position (B). Extensive circumferential dissection extending into the media (C).

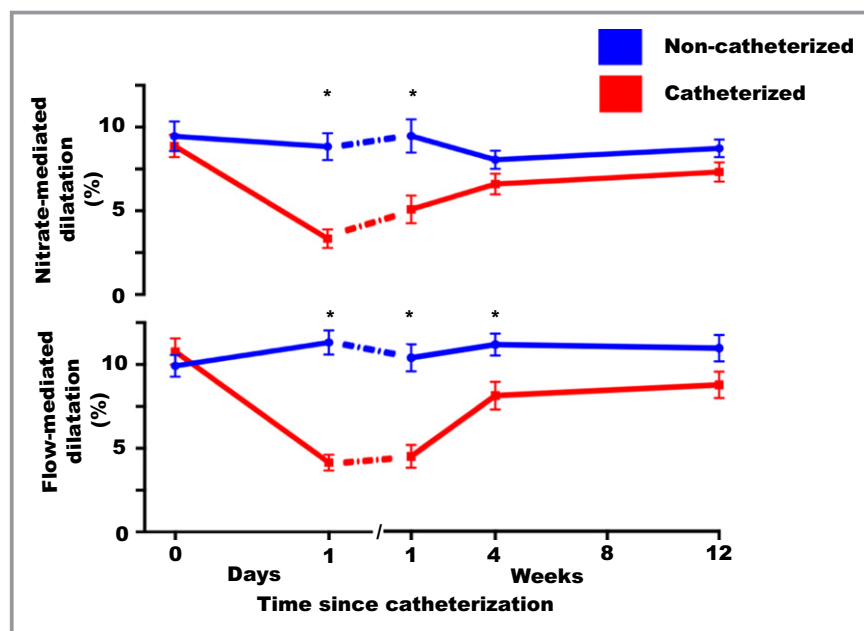


Figure 2. Changes in radial artery flow- and nitrate-mediated dilatation after catheterization. Flow-mediated dilatation in the catheterized radial artery was impaired at 24 h and at 1 and 4 wk compared with the noncatheterized radial artery but recovered by 3 months. Nitrate-mediated dilatation was impaired at 24 h and 1 wk, but by 4 wk, there was no longer a significant difference between catheterized and noncatheterized radial arteries. Red lines represent the catheterized right radial artery, and blue lines represent the noncatheterized left radial artery. Mean and 95% confidence intervals are displayed. Vasomotion in the catheterized arm both in response to glyceryl trinitrate and flow-mediated dilatation was reduced (ANOVA, $P<0.05$) Bonferroni post hoc tests were used to compare catheterized and uncatheterized arteries at different time points ($*P<0.05$ for catheterized vs noncatheterized comparison).

$P=0.61$), KDR ($61.0\pm 5.3\%$ versus $58.0\pm 8.0\%$, respectively; $P=0.85$) or CD146 ($95.4\pm 2.3\%$ versus $98.5\pm 0.5\%$, respectively; $P=0.42$) in those colonies isolated at 24 hours (Figure 4E). There was no difference in EOC phenotype between patients with and without vascular injury at any time point (data not shown).

Cellular Predictors of Baseline Arterial Function and Recovery

Baseline endothelial function (defined as FMD in the right radial artery) was negatively correlated with baseline CD34⁺ ($r=-0.4$, $P=0.004$) and CD133⁺ ($r=-0.33$, $P=0.02$) cell concentrations. Recovery of arterial function (defined as the recovery by 3 months of the deficit seen at 24 hours) was negatively correlated with baseline CD34⁺ concentration ($r=-0.33$, $P=0.04$; Table 2). Neither baseline arterial function nor recovery after injury correlated with the number of late EOC colonies isolated. There was a positive correlation between the migratory capacity of EOCs and baseline endothelial function ($r=0.47$, $P=0.03$) but not recovery following injury ($r=0.02$, $P=0.94$).

Discussion

This study is the first to examine the effect of vascular injury on EPCs in patients in whom the structural and functional consequences of arterial injury have been rigorously characterized. We demonstrated that vascular injury is common following transradial catheterization and is associated with endothelial-dependent and -independent vasomotor dysfunction that persists for 1 to 3 months, but circulating EPCs are not affected by the extent of injury, nor do they predict recovery of function.

Despite using high-resolution intravascular optical imaging, we demonstrated a low incidence of macroscopic radial artery injury. This is in contrast with previous intravascular imaging studies and likely reflects racial differences in radial artery diameter and the low incidence of repeated transradial catheterization (a predictor of vessel injury³) in our study. We observed that sheath insertion was universally associated with denudation of the local endothelial cell layer, in keeping with previous work (which has demonstrated endothelial disruption on resected radial artery specimens after catheterization)^{9,23} and explaining the functional impairment that we subsequently demonstrated. In addition to examining the

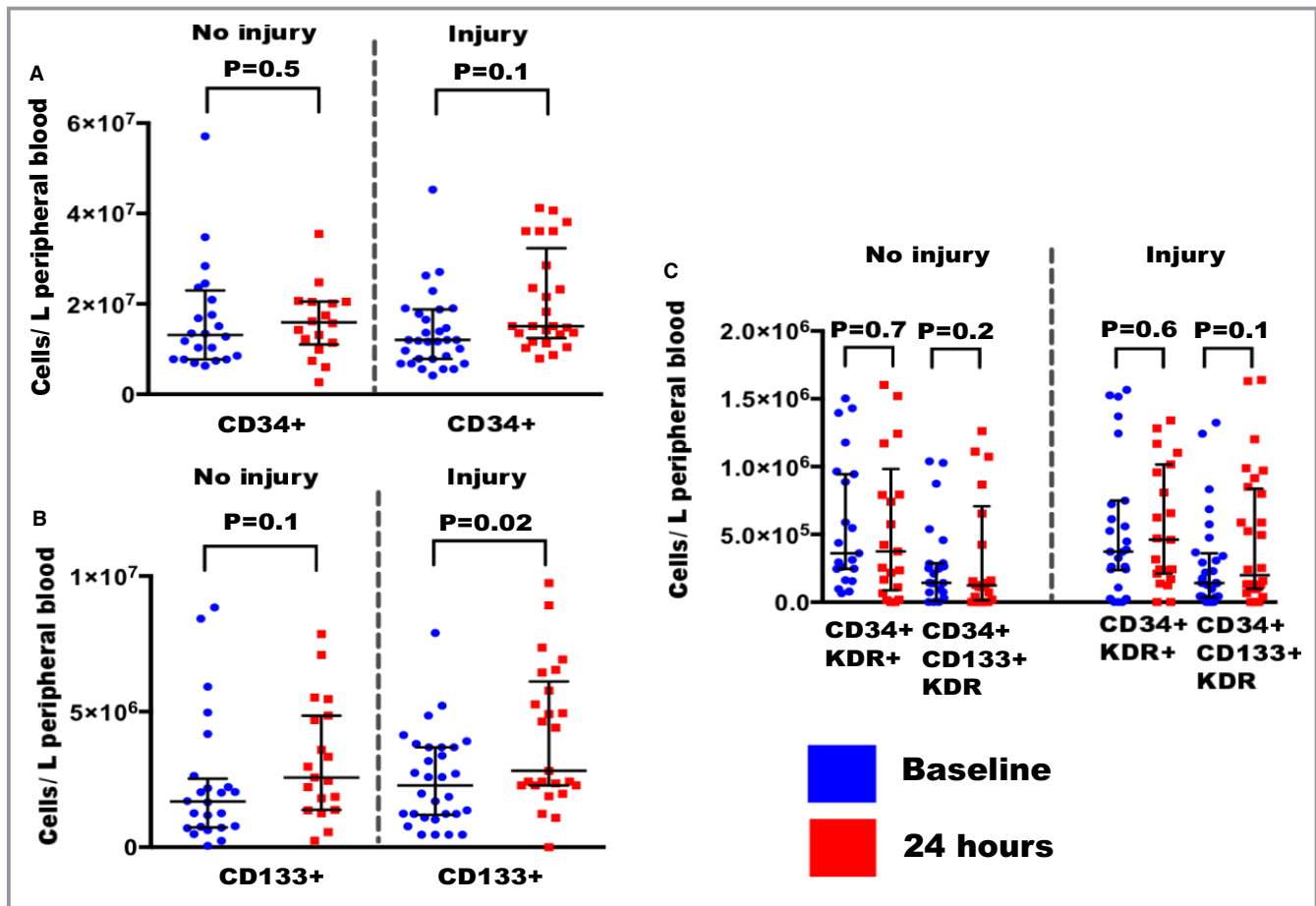


Figure 3. The effect of vascular injury on circulating progenitor cells. Patients were classified according to whether they sustained vascular injury. This was defined as having either macroscopic radial artery injury on optical coherence tomography (n=10), percutaneous coronary intervention (PCI; n=16), or both (n=2). Those in the no-injury group had cardiac catheterization alone with no radial artery injury or PCI (n=20). There was no significant change in peripheral blood CD34⁺ cells at 24 hours after angiography in either group (A). There was a modest increase in CD 133⁺ cells at 24 hours after angiography that was significant in those with evidence of vascular injury but not in those without (B). There was no significant increase in CD34⁺KDR⁺ or CD34⁺CD133⁺KDR⁺ cell concentration in either group (C). Values shown are median with interquartile range. The Wilcoxon matched pairs test was used for comparisons between baseline and 24 h.

number of EPCs in circulation before and after cardiac catheterization, we characterized their progeny late EOCs, demonstrating that there was no change in function as a consequence of vascular injury.

We observed impairment of vasomotor function at 24 hours that partially recovered over a period of several months. Endothelium-independent vasomotion recovered by 1 month, whereas endothelium-dependent vasomotion remained impaired at 3 months, albeit with a trend toward recovery. This disparity likely represents different processes in the media and intima with mild injury or transient dysfunction caused by local inflammation in the smooth muscle layer compared with extensive disruption of the endothelium. Our findings are consistent with previous work,^{5–12} although the time course of recovery varies, probably reflecting heterogeneity in study design and populations studied.

In our study, there was no significant change in the concentration of CD34⁺ cells or EPCs (defined as CD34⁺KDR⁺ or CD34⁺CD133⁺KDR⁺ cells) following transradial cardiac catheterization. We observed an increase in CD133⁺ cells at 24 hours in patients with evidence of vascular injury, although this did not correlate with the extent of injury. Although a subpopulation of CD34⁺ cells may exist, EPCs cannot be identified by expression of CD133 or CD34 expression alone, as these markers are expressed by numerous naïve, heterogeneous populations including hematopoietic cells.²⁴

Mobilization of CD34⁺ and CD133⁺ cells has been reported previously in response to large nonspecific inflammatory insults^{25–27} and myocardial infarction^{28,29} whereas cellular response to discrete vascular injury is less readily demonstrable.^{30,31} Acute mobilization of CD34⁺ populations has, however, been described after PCI, with higher concentrations predicting restenosis.^{28,32} Alongside the disappointing

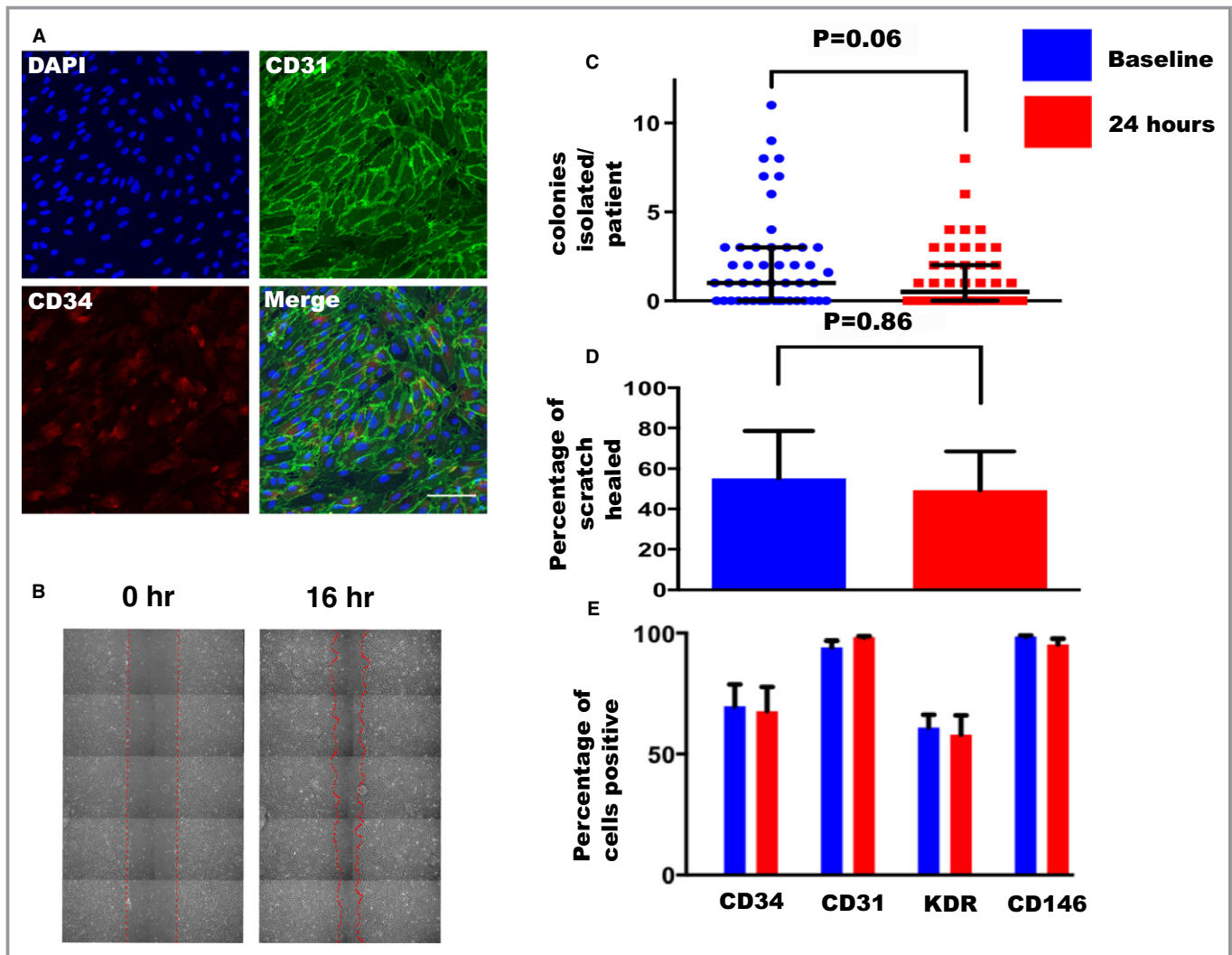


Figure 4. Late-outgrowth endothelial colony and wound healing analysis. Colonies of late-outgrowth endothelial cells were isolated and characterized. Immunofluorescence for DAPI (diamidino-2-phenylindole; nuclei [blue]), CD31 (fluorescein isothiocyanate; green), and CD34 (Alexa 568; red) was performed. Cells had a comparable phenotype to vascular endothelial cells with ubiquitous expression of CD31 and CD34. Scale bars = 100 μ m. A, Assessment of endothelial outgrowth cell migratory capacity was assessed using a “scratch” wound healing assay between 0 and 16 h (B). There was no significant difference in the number of endothelial outgrowth cell colonies isolated (C), their migratory potential (D), or cell-surface marker profile ($P>0.05$ for all comparisons) (E) between colonies isolated at baseline and 24 h after angiography.

experience of CD34⁺-capture stents,³³ this supports a nonspecific inflammatory role for these cells after injury.

Despite an increase in circulating CD133⁺ cells at 24 hours in those patients with vascular injury, we observed no difference in rates of EOC isolation, supportive of previous work suggesting that EOCs—the presumed progeny of circulating EPCs—cannot be isolated from the CD133⁺ fraction of peripheral blood.^{34,35}

Circulating concentrations of EPCs have been correlated with improved vascular function and decreased cardiovascular events.^{14,36,37} However, controversy surrounds the correct definition of a bona fide EPC, and the role of EPCs in vascular repair remains unclear. In our study, baseline CD133⁺ and CD34⁺ cell concentrations were inversely correlated with

endothelial function, and higher CD34⁺ concentrations predicted less complete recovery of endothelial function, again suggesting that these populations, when taken as a whole, are not important contributors to vascular repair.

We demonstrated a positive correlation between EOC migratory capacity and baseline endothelial function, although EOC migration did not predict recovery after injury. Consistent with previous work in uremia,³⁸ obesity,³⁹ and following in vitro exposure to oxidized low-density lipoprotein,⁴⁰ our finding of a positive correlation between EOC migration and baseline endothelial function suggests that characterization of EOC biology may provide information about vascular health at a cellular level that is complementary to information provided by those assessing blood flow and vascular physiology. Late EOCs

Table 2. Cellular Predictors of Baseline Endothelial Function and Recovery Following Injury

Correlate	R	P Value
Baseline arterial function		
CD34+	−0.40	0.004*
CD34+CD133+	−0.13	0.37
CD34+KDR+	−0.24	0.10
CD34+CD133+KDR+	−0.27	0.08
CD133+	−0.33	0.02*
CD34+CD45−	−0.17	0.23
Mean colony number	0.01	0.92
Wound healing	0.47	0.03*
Recovery of arterial function		
CD34+	−0.33	0.04*
CD34+CD133+	−0.29	0.06
CD34+KDR+	−0.08	0.60
CD34+CD133+KDR+	−0.02	0.90
CD133+	−0.19	0.20
CD34+CD45−	−0.02	0.49
Mean colony number	−0.14	0.38
Wound healing	0.02	0.94

Baseline arterial function and subsequently recovery of function following injury was correlated with various cellular populations as well as the function of isolated endothelial outgrowth cells. Cellular populations were expressed as absolute cell numbers per liter of peripheral blood, and wound healing was expressed as the percentage of a scratch healed by 16 hours. Baseline endothelial function was defined as left radial artery flow-mediated dilatation before angiography, and recovery of arterial function was defined as the percentage recovery by 3 months of the deficit observed at 24 hours in the catheterized artery.

are thought to play a central role in vascular regeneration^{16,17} and, in contrast to early outgrowth and CD34⁺ cells, are capable of incorporating into native vessels following transplantation in animal models of angiogenesis, increasing capillary density and reducing neointimal hyperplasia.^{41–43} Given these regenerative capabilities, it is perhaps not surprising that late EOC function in vitro correlates with radial artery vasomotor function. Further studies of late EOCs may provide insight into the cellular mechanisms that mediate vascular dysfunction.

Conclusion

The radial artery is an accessible model of vascular injury and repair in humans and offers opportunities to gain mechanistic insight into the pathophysiology of vascular disease and to examine the effects of novel therapies in translational research. Transradial cardiac catheterization causes reversible impairment of endothelium-dependent and -independent vasomotor function, but recovery does not appear to be mediated by circulating EPCs or outgrowth populations.

Sources of Funding

This research was supported by the British Heart Foundation (PG/13/32/30205, RM/13/2/30158, RE/13/3/30183), and Mills and Newby are supported by the Butler Senior Clinical Research Fellowship (FS/16/14/32023) and Chair Awards (CH/09/002) respectively. Newby is the recipient of a Wellcome Trust Senior Investigator Award (WT103782AIA). Cruden is supported by a National Health Service (NHS) Research Scotland (NRS) Fellowship from the Chief Scientist Office, Scotland. The Wellcome Trust Clinical Research Facility and Clinical Research Imaging Centre are supported by NRS through NHS Lothian.

Disclosures

None.

References

- Wagner JF, Rao SV. Radial artery occlusion after transradial approach to cardiac catheterization. *Curr Atheroscler Rep.* 2015;17:489.
- BCIS National Audit of Percutaneous Coronary Interventions. 2014. Available at: www.ucl.ac.uk. Accessed February 01, 2017.
- Di Vito L, Burzotta F, Trani C, Crea F. Radial artery complications occurring after transradial coronary procedures using long hydrophilic-coated introducer sheath: a frequency domain-optical coherence tomography study. *Int J Cardiovasc Imaging.* 2013;30:21–29.
- Yonetsu T, Kakuta T, Lee T, Takayama K, Kakita K, Iwamoto T, Kawaguchi N, Takahashi K, Yamamoto G, Iesaka Y, Fujiwara H, Isobe M. Assessment of acute injuries and chronic intimal thickening of the radial artery after transradial coronary intervention by optical coherence tomography. *European Heart J.* 2010;31:1608–1615.
- Madssen E, Haere P, Wiseth R. Radial artery diameter and vasodilatory properties after transradial coronary angiography. *Ann Thorac Surg.* 2006;82:1698–1702.
- Dawson EA, Rathore S, Cable NT, Wright DJ, Morris JL, Green DJ. Impact of catheter insertion using the radial approach on vasodilatation in humans. *Clin Sci (Lond).* 2010;118:633–640.
- Dawson EA, Rathore S, Cable NT, Wright DJ, Morris JL, Green DJ. Impact of introducer sheath coating on endothelial function in humans after transradial coronary procedures. *Circ Cardiovasc Interv.* 2010;3:148–156.
- Dawson EA, Alkarmi A, Thijssen DHJ, Rathore S, Marsman DE, Cable NT, Wright DJ, Green DJ. Low-flow mediated constriction is endothelium-dependent. *Circ Cardiovasc Interv.* 2012;5:713–719.
- Gaudino M, Leone A, Lupascu A, Toesca A, Mazza A, Ponziani FR, Fiore R, Tondi P, Massetti M. Morphological and functional consequences of transradial coronary angiography on the radial artery: implications for its use as a bypass conduit. *Eur J Cardiothorac Surg.* 2015; 48: 370–374.
- Okuyan H, Aqikgoz SK, Tacoy G, Kocaman SA, Abaci A. Effect of transradial coronary angiography procedure on vascular diameter and vasodilator functions in the access site. *Angiology.* 2012;64:515–521.
- Park KH, Park DW, Kim MK, Kim HS, Park WJ, Cho GY, Choi YJ. Effects of sheath injury and trimetazidine on endothelial dysfunction of radial artery after transradial catheterization. *J Interv Cardiol.* 2012;25:411–417.
- Burstein JM, Gidrewicz D, Hutchison SJ, Holmes K, Jolly S, Cantor WJ. Impact of radial artery cannulation for coronary angiography and angioplasty on radial artery function. *Am J Cardiol.* 2007;99:457–459.
- Asahara T, Murohara T, Sullivan A, Silver M, Isner J. Isolation of putative progenitor endothelial cells for angiogenesis. *Science.* 1997;275:964–966.
- Werner N, Kosiol S, Schiegl T, Ahlers P, Walenta K, Link A, Bohm M, Nickenig G. Circulating endothelial progenitor cells and cardiovascular outcomes. *N Engl J Med.* 2005;353:999–1007.
- Peichev M, Naiyer AJ, Pereira D, Zhu Z, Lane WJ, Williams M, Oz MC, Hicklin DJ, Witte L, Moore MA, Rafii S. Expression of VEGFR-2 and AC133 by circulating human CD34⁺ cells identifies a population of functional endothelial precursors. *Blood.* 2000;95:952–958.

16. Ingram DA, Meade V, Fenoglio A, Mortell K, Gilley D, Yoder MC. Identification of a novel hierarchy of endothelial progenitor cells using human peripheral and umbilical cord blood. *Blood*. 2004;104:2752–2760.
17. Yoder MC. Defining human endothelial progenitor cells. *J Thromb Haemost*. 2009;7:49–52.
18. Padfield GJ, Newby DE, Mills NL. Understanding the role of endothelial progenitor cells in percutaneous coronary intervention. *J Am Coll Cardiol*. 2010;55:1554–1565.
19. Corretti M, Anderson T, Benjamin E, Celermajer D, Charbonneau F, Vogel R. Guidelines for the ultrasound assessment of endothelial-dependent vasodilatation. *J Am Coll Cardiol*. 2001;20:1–9.
20. Thijssen DHJ, Black MA, Pyke KE, Padilla J, Atkinson G, Harris RA, Parker B, Widlansky ME, Tschakovsky ME, Green DJ. Assessment of flow-mediated dilation in humans: a methodological and physiological guideline. *Am J Physiol Heart Circ Physiol*. 2011;300:H2–H12.
21. Mitchell AJ, Mills NL, Newby DE, Cruden NL. Radial artery vasomotor function following transradial cardiac catheterization. *Open Heart*. 2016;3:e000443.
22. Brittan M, Hunter A, Boulberdaa M, Fujisawa T, Skinner EM, Shah AS, Baker AH, Mills NL. Impaired vascular function and repair in patients with coronary artery disease. *Eur J Prev Cardiol*. 2015;22:1557–1566.
23. Kamiya H, Ushijima T, Kanamori T, Ikeda C, Nakagaki C, Ueyama K, Watanabe G. Use of the radial artery graft after transradial catheterization: is it suitable as a bypass conduit? *Ann Thorac Surg*. 2003; 76:1505–1509.
24. Wognum A, Eaves A, Thomas T. Identification and isolation of hematopoietic stem cells. *Arch Med Res*. 2003;34:461–475.
25. Gill M, Dias S, Hattori K, Rivera ML, Hicklin D, Witte L, Girardi L, Yurt R, Himel H, Rafii S. Vascular trauma induces rapid but transient mobilization of VEGFR2⁺AC133⁺ Endothelial Precursor cells. *Circ Res*. 2001;88:167–174.
26. DeJarnett N, Yeager R, Conklin DJ, Lee J, O'Toole TE, McCracken J, Abplanalp W, Srivastava S, Riggs DW, Hamzeh I, Wagner S, Chugh A, DeFilippis A, Ciszewski T, Wyatt B, Becher C, Higdon D, Ramos KS, Tollerud DJ, Myers JA, Rai SN, Shah J, Zafar N, Krishnasamy SS, Prabhu SD, Bhatnagar A. Residential proximity to major roadways is associated with increased levels of AC133⁺ circulating angiogenic cells. *Atheroscler Thromb Vasc Biol*. 2015;35:2468–2477.
27. Padfield GJ, Tura O, Haeck MLA, Short A, Freyer E, Barclay GR, Newby DE, Mills NL. Circulating endothelial progenitor cells are not affected by acute systemic inflammation. *Am J Physiol Heart Circ Physiol*. 2010;298:H2054–H2061.
28. Schober A, Hoffmann R, Oprée N, Knarren S, Iofina E, Hutschenreuter G, Hanrath P, Weber C. Peripheral CD34⁺ cells and the risk of in-stent restenosis in patients with coronary heart disease. *Am J Cardiol*. 2005;96:1116–1122.
29. Padfield GJ, Tura-Ceide O, Freyer E, Barclay GR, Turner MR, Newby DE, Mills NL. Endothelial progenitor cells, atheroma burden and clinical outcome in patients with coronary artery disease. *Heart*. 2013;99:791–798.
30. Padfield GJ, Tura-Ceide O, Freyer E, Barclay GR, Turner MR, Newby DE, Mills NL. Percutaneous coronary intervention causes a rapid but transient mobilization of CD34⁺CD45⁺ cells. *Open Heart*. 2014;1:e000047.
31. Thomas HE, Avery PJ, Ahmed JM, Edwards R, Purcell I, Zaman AG, Arthur HM, Keavney BD. Local vessel injury following percutaneous coronary intervention does not promote early mobilization of endothelial progenitor cells in the absence of myocardial necrosis. *Heart*. 2008;95:555–558.
32. Inoue T, Sata M, Hikichi Y, Sohma R, Fukuda D, Uchida T, Shimizu M, Komoda H, Node K. Mobilization of CD34-positive bone marrow-derived cells after coronary stent implantation: impact on restenosis. *Circulation*. 2007;115:553–561.
33. Klomp M, Beijk MA, Varma C, Koolen JJ, Teiger E, Richardt G, Bea F, Van Geloven N, Verouden N, Chan YK, Woudstra P, Damman P, Tijssen JG, De Winter RJ. 1-year outcome of TRIAS HR (TRI-stent adjudication study-high risk of restenosis). *JACC Cardiovasc Interv*. 2011;4:896–904.
34. Timmermans F, Van Hauwermeiren F, De Smedt M, Raedt R, Plasschaert F, De Buyzere ML, Gillebert TC, Plum J, Vandekerckhove B. Endothelial outgrowth cells are not derived from CD133⁺ cells or CD45⁺ hematopoietic precursors. *Arterioscler Thromb Vasc Biol*. 2007;27:1572–1579.
35. Tura-Ceide O, Skinner EM, Barclay GR, Samuel K, Gallagher RCJ, Brittan M, Newby DE, Mills NL. Late outgrowth endothelial cells resemble mature endothelial cells and are not derived from bone marrow. *Stem Cells*. 2013;31:338–348.
36. Liao Y-F, Chen L-L, Zeng T-S, Li Y-M, Yu F, Hu L-J, Yue L. Number of circulating endothelial progenitor cells as a marker of vascular endothelial function for type 2 diabetes. *Vasc Med*. 2010;15:279–285.
37. Hill JM, Zalos G, Halcox J, Schenke WH, Waclawiw MA, Quyyumi AA, Finkel T. Circulating endothelial progenitor cells, vascular function, and cardiovascular risk. *N Engl J Med*. 2003;348:593–600.
38. Zhao J, Bolton EM, Randle L, Bradley JA, Lever AML. Functional characterization of late outgrowth endothelial progenitor cells in patients with end-stage renal failure. *Transpl Int*. 2014;27:437–451.
39. Richards WO, Prutzman RN, O'Hea MF, Audia JP, Alvarez DF. Bariatric surgery improves the circulating numbers and biological activity of late outgrowth endothelial progenitor cells. *Surg Obes-Relat Dis*. 2014; 10:906–913.
40. Lin FY, Tsao NW, Shih CM, Lin YW, Chen JW. The biphasic effects of oxidized-low density lipoprotein on the vasculogenic function of endothelial progenitor cells. *PLoS One*. 2015; 10:e0123971.
41. Barclay GR, Tura O, Samuel K, Hadoke PW, Mills NL, Newby DE, Turner ML. Systematic assessment in an animal model of the angiogenic potential of different human cell sources for therapeutic revascularization. *Stem Cell Res Ther*. 2012;3:23.
42. Minami Y, Nakajima T, Ikutomi M, Morita T, Komuro I, Sata M, Sahara M. Angiogenic potential of early and late outgrowth endothelial progenitor cells is dependent on the time of emergence. *Int J Cardiol*. 2015;186:305–314.
43. Schwarz TM, Leicht SF, Radic T, Rodriguez-Arabaolaza I, Hermann PC, Berger F, Saif J, Bocker SW, Ellwart JW, Alcher A, Heeschen C. Vascular incorporation of endothelial colony-forming cells is essential for functional recovery of murine ischemic tissue following cell therapy. *Arterioscler Thromb Vasc Biol*. 2012;32:13–21.

SUPPLEMENTAL MATERIAL

Table S1. Absolute cell numbers in peripheral blood at baseline prior to angiography. Cell numbers are expressed in numbers of cells per litre of peripheral blood. Krusal-Wallis tests were used to compare cell numbers between injury groups.

Population	No injury (n=20)	PCI only (n=15)	Radial injury (n=10)	Radial injury and PCI (n=3)	P
45+or-ve					
34+	13.1 (7.7-22.7)	12.8 (7.9-18.1)	11.8 (6.8-23.0)	6.8 (5.6-12.0)	0.69
133+	1.7 (0.7-2.6)	2.6 (1.1-3.6)	2.6 (1.4-3.8)	1.2 (0.5-3.7)	0.61
34+133+	1.1 (0.1-2.1)	1.3 (0.6-3)	1.6 (1.1-3.2)	1.2 (0.5-3.2)	0.97
34+KDR+	0.2 (0.2-0.9)	0.4 (0.2-0.9)	0.4 (0.2-1.3)	0.3 (0.0-0.5)	0.60
133+KDR+	0.1 (0.1-0.6)	0.2 (0.3-0.6)	0.2 (0.1-0.8)	0.0 (0.0-0.8)	0.39
34+133+KDR+	0.1 (0.1-0.3)	0.1 (0.2-0.3)	0.3 (0.0-0.6)	0.0 (0.0-0.04)	0.59
45-					
34+	0.4 (0.2-1.7)	0.6 (0.2-1.8)	0.5 (0.3-2.8)	0.6 (0.6-0.7)	0.31
133+	0.2 (0.0-0.4)	0.2 (0.1-0.6)	0.3 (0.1-1.5)	0.1 (0.0-2.3)	0.30
34+133+	0.1 (0.0-0.3)	0.1 (0.1-0.4)	0.1 (0.1-1.2)	0.1 (0.0-0.2)	0.40
34+KDR+	0.1 (0.0-0.1)	0.1 (0.0-0.2)	0.1 (0.0-0.2)	0.2 (0.0-0.2)	0.98
133+KDR+	0.0 (0.0-0.1)	0.0 (0.0-0.1)	0.0 (0.0-0.1)	0.0 (0.0-0.7)	0.51
34+133+KDR+	0.0 (0.0-0.1)	0.0 (0.0-0.1)	0.0 (0.0-0.1)	0.1 (0.0-0.2)	0.57
45+					
34+	13.7 (7.1-23.0)	12.6 (4.2-20.0)	11.1 (4.1-18.5)	6.5 (1.3-11.8)	0.29
133+	2.6 (1.3-6.5)	3.8 (1.8-5.3)	2.4 (1.4-5.6)	1.3 (0.5-2.4)	0.45
34+133+	1.2 (0.9-3.8)	1.9 (0.7-3.4)	1.3 (1.1-3.4)	1.1 (0.5-2.1)	0.75
34+KDR+	1.4 (0.6-2.9)	0.5 (0.3-1)	0.4 (0.2-0.9)	0.1 (0.1-0.4)	0.02
133+KDR+	0.3 (0.1-0.6)	0.4 (0.2-1.4)	0.6 (0.1-0.8)	0.1 (0.1-0.2)	0.39
34+133+KDR+	0.2 (0.1-0.6)	0.2 (0.2-0.4)	0.3 (0.1-0.6)	0.1 (0.1-0.2)	0.69

Table S2. Absolute cell numbers in peripheral blood at 24 hours post angiography. Cell numbers are expressed in numbers of cells per litre of peripheral blood. Krusal-Wallis tests were used to compare cell numbers between injury groups.

Population	No injury (n=20)	PCI only (n=15)	Radial injury (n=10)	Radial injury and PCI (n=3)	P
45+or-ve					
34+	16.6 (12.0 – 22.2)	15.1 (1.3 – 23.5)	13.2 (9.5 – 30.0)	15.1 (5.3 – 36)	0.71
133+	2.6 (1.4 – 4.9)	4.4 (2.0 – 6.5)	3.9 (2.0 – 7.8)	2.3 (1.0 – 2.4)	0.44
34+133+	1.6 (0.5 – 3.5)	2.0 (1.3 – 4.7)	2.0 (1.3 – 4.8)	2.0 (1.0 – 2.0)	0.36
34+KDR+	0.4 (0.1 – 1.1)	0.8 (0.2 – 1.2)	0.4 (0.2 – 1.3)	0.2 (0.0 – 0.2)	0.15
133+KDR+	0.2 (0.0 – 0.8)	0.6 (0.1 – 1.0)	0.4 (0.1 – 1.6)	0.1 (0.0 – 0.2)	0.49
34+133+KDR+	0.1 (0.0 – 0.6)	0.5 (0.1 – 0.9)	0.3 (0.1 – 1.0)	0.1 (0.0 – 0.1)	0.73
45-					
34+	0.5 (0.1 – 0.8)	0.4 (0.1 – 1.2)	0.3 (0.1 – 0.7)	0.3 (0.0 – 0.5)	0.72
133+	0.1 (0.0 – 0.3)	0.1 (0.0 – 0.3)	0.2 (0.1 – 0.9)	0.0 (0.0 – 0.1)	0.22
34+133+	0.1 (0.0 – 0.2)	0.1 (0.0 – 0.2)	0.1 (0.0 – 0.6)	0.0 (0.0 – 0.1)	0.16
34+KDR+	0.1 (0.0 – 0.1)	0.1 (0.0 – 0.1)	0.1 (0.0 – 0.2)	0.0 (0.0 – 0.0)	0.70
133+KDR+	0.0 (0.0 – 0.1)	0.0 (0.0 – 0.0)	0.0 (0.0 – 0.2)	0.0 (0.0 – 0.0)	0.43
34+133+KDR+	0.0 (0.0 – 0.0)	0.0 (0.0 – 0.0)	0.0 (0.0 – 0.1)	0.1 (0.0 – 0.1)	0.74
45+					
34+	15.3 (9.9 – 20.0)	15.7 (12.2 – 26.4)	11.1 (4.8 – 21.7)	14.8 (10.0– 36.0)	0.78
133+	2.7 (1.6 – 5.3)	4.3 (2.1 – 6.2)	2.5 (2.1 – 6.0)	2.6 (1.3 – 2.4)	0.28
34+133+	1.9 (0.8 – 3.3)	2.0 (1.2 – 4.6)	1.9 (1.2 – 3.8)	1.9 (1.9 – 4.1)	0.53
34+KDR+	0.9 (0.6 – 2.1)	0.8 (0.2 – 1.1)	0.3 (0.2 – 0.9)	0.2 (0.2 – 0.2)	0.04
133+KDR+	0.2 (0.1 – 0.8)	0.6 (0.1 – 1.0)	0.5 (0.1 – 1.5)	0.1 (0.1 – 0.2)	0.62
34+133+KDR+	0.1 (0.1 – 0.7)	0.5 (0.1 – 0.8)	0.5 (0.1 – 0.8)	0.1 (0.0 – 0.11)	0.65

Table S3. Absolute change in cell numbers in peripheral blood at from baseline to 24 hrs post-angiography. Cell numbers are expressed in numbers of cells per litre of peripheral blood. Krusal-Wallis tests were used to compare cell numbers between injury groups.

Population	No injury (n=20)	PCI only (n=15)	Radial injury (n=10)	Radial injury and PCI (n=3)	P
45+or-ve					
34+	+2.9 (-8.4 - 11.9)	+6.6 (-1.8 - 10.5)	+1.6 (-4.0 - 5.5)	+8.3 (7.2 - 24.1)	0.81
133+	+1.2 (-0.5 - 3.0)	+1.6 (-0.6 -3.8)	+1.3 (-0.5 - 8.0)	-1.1 (-1.4 - 1.2)	0.67
34+133+	+0.4 (-0.4 - 1.9)	+1.0 (-0.4 - 0.5)	+0.9 (-0.0 - 2.3)	-0.8 (-1.3 - 0.7)	0.28
34+KDR+	-0.1 (-0.2 - 0.4)	-0.0 (-0.4 - 0.5)	+0.2 (0.0 - 0.6)	-0.2 (-0.2 - 0.6)	0.63
133+KDR+	+0.1 (-0.1 - 0.4)	0.0 (-0.2 - 0.3)	+0.2 (0.0 - 0.4)	0.0 (0.0 - 0.5)	0.22
34+133+KDR+	+0.1 (-0.9 - 0.2)	+0.1 (-0.2 - 0.4)	+0.1 (-0.5 - 0.6)	+0.1 (0.1 - 0.9)	0.76
45-					
34+	+0.1 (0.2- 0.4)	-0.1 (-0.1 - 0.4)	-0.2 (-1.8 - -0.1)	-0.4 (-0.6 - -0.2)	0.29
133+	-0.1 (-0.1- 0.2)	-0.1 (-0.7 - -0.1)	0.0 (-0.1 - 0.2)	-0.1 (-2.3 - 0.2)	0.08
34+133+	0.0 (-0.2 - 0.1)	-0.1 (-0.4 - 0.0)	0.0 (-0.1 - 0.1)	-0.2 (-0.2 - 0.0)	0.31
34+KDR+	0.0 (-0.1 - 0.1)	-0.0 (-0.1 - 0.0)	0.0 (-0.1 - 0.1)	0.0 (-0.1- 0.1)	0.44
133+KDR+	0.0 (-0.0 - 0.0)	-0.0 (-0.1 - 0.0)	0.0 (0.0 - 0.1)	0.0 (-0.0 - 0.0)	0.12
34+133+KDR+	0.0 (-0.0 - 0.0)	-0.0 (-0.1 - 0.0)	0.0 (0.0 - 0.0)	0.0 (-0.0 - 0.0)	0.32
45+					
34+	+3.2 (-9.1 - 13.6)	+2.5 (-4.1 - 18.5)	+0.9 (-8.0 - 2.1)	-1.8 (-6.5 - 2.9)	0.74
133+	-0.2 (-1.9 - 0.9)	-0.4 (-1.0 - 0.6)	+0.1 (-0.9 - 0.9)	-0.1 (-0.5 - 1.0)	0.62
34+133+	+0.1 (-1.2 - 0.9)	+0.2 (-0.8 - 1.8)	+0.6 (-0.6 - 0.7)	+0.3 (-0.2 - 0.8)	0.39
34+KDR+	-0.4 (-0.7 - 0.2)	-0.0 (-0.3 - 0.5)	+0.0 (-0.2 - 0.3)	-0.1 (-0.2 - 0.1)	0.27
133+KDR+	0.0 (-0.2 - 0.1)	-0.2 (-0.4 - 0.1)	+0.1 (-0.0 - 0.5)	0.0 (0.0 - 0.1)	0.14
34+133+KDR+	0.0 (-0.2 - 0.1)	-0.5 (-0.6 - 0.3)	-0.1 (-0.1 - 0.2)	-0.1 (-0.1 - 0.1)	0.98



Endothelial Progenitor Cell Biology and Vascular Recovery Following Transradial Cardiac Catheterization

Andrew Mitchell, Takeshi Fujisawa, Nicholas L. Mills, Mairi Brittan, David E. Newby and Nicholas L. M. Cruden

J Am Heart Assoc. 2017;6:e006610; originally published October 28, 2017;

doi: 10.1161/JAHA.117.006610

The *Journal of the American Heart Association* is published by the American Heart Association, 7272 Greenville Avenue, Dallas, TX 75231
Online ISSN: 2047-9980

The online version of this article, along with updated information and services, is located on the World Wide Web at:

<http://jaha.ahajournals.org/content/6/11/e006610>