



THE UNIVERSITY *of* EDINBURGH

Edinburgh Research Explorer

Recovery from blindness following accidental quinine overdose

Citation for published version:

Hall, HN & Tatham, AJ 2017, 'Recovery from blindness following accidental quinine overdose' Practical neurology. DOI: 10.1136/practneurol-2017-001610

Digital Object Identifier (DOI):

[10.1136/practneurol-2017-001610](https://doi.org/10.1136/practneurol-2017-001610)

Link:

[Link to publication record in Edinburgh Research Explorer](#)

Document Version:

Publisher's PDF, also known as Version of record

Published In:

Practical neurology

Publisher Rights Statement:

This is an Open Access article distributed in accordance with the terms of the Creative Commons Attribution (CC BY 4.0) license, which permits others to distribute, remix, adapt and build upon this work, for commercial use, provided the original work is properly cited. See: <http://creativecommons.org/licenses/by/4.0/>

General rights

Copyright for the publications made accessible via the Edinburgh Research Explorer is retained by the author(s) and / or other copyright owners and it is a condition of accessing these publications that users recognise and abide by the legal requirements associated with these rights.

Take down policy

The University of Edinburgh has made every reasonable effort to ensure that Edinburgh Research Explorer content complies with UK legislation. If you believe that the public display of this file breaches copyright please contact openaccess@ed.ac.uk providing details, and we will remove access to the work immediately and investigate your claim.





Recovery from blindness following accidental quinine overdose

Hildegard Nikki Hall,^{1,2} Andrew J Tatham¹

¹Princess Alexandra Eye Pavilion, Edinburgh, UK
²MRC Human Genetics Unit, MRC Institute for Genetics and Molecular Medicine, University of Edinburgh, Edinburgh, UK

Correspondence to

Dr Hildegard Nikki Hall, Princess Alexandra Eye Pavilion, Chalmers Street, Edinburgh EH3 9HA, UK; nikki.hall@ed.ac.uk

Accepted 12 July 2017

CASE

A 46-year-old woman presented with sudden loss of vision in both eyes, apparent since waking. She also complained of partial hearing loss. The previous evening she had experienced difficulty sleeping due to (long-standing) restless legs and had self-medicated with quinine, taking an accidental overdose of 1.8 g.

On admission, she was alert but unable to perceive light in either eye, and had fixed, dilated pupils. Other than mild bilateral sensorineural hearing loss, the remainder of the neurological examination was normal. She was haemodynamically stable, but her ECG showed QT interval prolongation at 501 ms (normal 350–440); she therefore received intravenous sodium bicarbonate for suspected myocardial toxicity.

Ophthalmological review that day confirmed a visual acuity of no light perception and a bilateral afferent pupillary defect. Fundal examination suggested mild retinal oedema. Given the profound visual loss, we prescribed a 4-week course of oral nimodipine 60 mg 4-hourly, based on limited evidence from case series.¹

PROGRESS

Two days postoverdose, her vision started to return such that she could perceive light. Slit lamp fundus examination was normal at this point. Her sight gradually improved. By 1 month, visual acuity was 6/9 bilaterally, although subjectively her vision was akin to ‘being under water’. Colour vision was profoundly reduced: she could discern the Ishihara control plate only. Her pupils remained persistently dilated with sluggish direct reactions to light. Funduscopy now showed optic disc pallor and retinal vessel attenuation bilaterally (figure 1), with thinning of the nasal retinal nerve fibre layer on optical coherence tomography (figure 2). Visual fields were severely constricted (figure 3A) such that she remained functionally limited. Electrodiagnostic testing at 3 months was consistent with quinine overdose, with reduced electroretinogram amplitude and abnormal flicker response.

Over 6 months, her visual fields expanded significantly (figure 3B), reflecting partial recovery of retinal function following quinine toxicity.

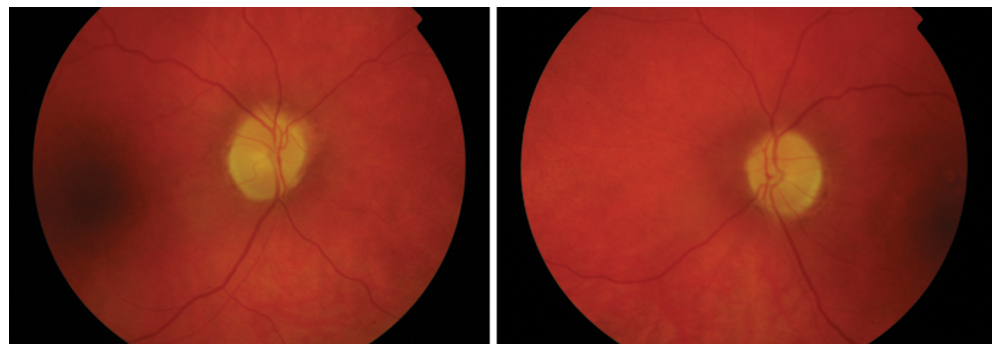


Figure 1 Fundus photographs showing pale discs and retinal vessel attenuation. The patient’s fundus appearance was unremarkable in the early stages; the changes seen here were seen from 1 month postoverdose and are secondary to the widespread quinine-induced retinal toxicity. These photographs were taken at 6 months, at which point there had been some recovery of the visual function but no further change to the fundoscopic appearance.



To cite: Hall HN, Tatham AJ. *Pract Neurol* 2017;**0**:1–3.

IMAGE OF THE MOMENT

DISCUSSION

Acute quinine toxicity produces a well-recognised constellation of clinical effects, known as cinchonism. This case demonstrated visual and hearing loss as well as signs of cardiac instability. In addition, cinchonism may comprise tinnitus, dizziness, headache, seizures and

vomiting. Quinine is believed to be directly toxic to the inner retina² and, while the natural history is of some recovery over days to weeks, residual visual field constriction is common and the vision may remain poor.

There is no high-quality evidence for any treatment for quinine-related blindness. However, due to the

RNFL Single Exam Report OU
SPECTRALIS® Tracking Laser Tomography



Diagnosis: ---

Comment: ---

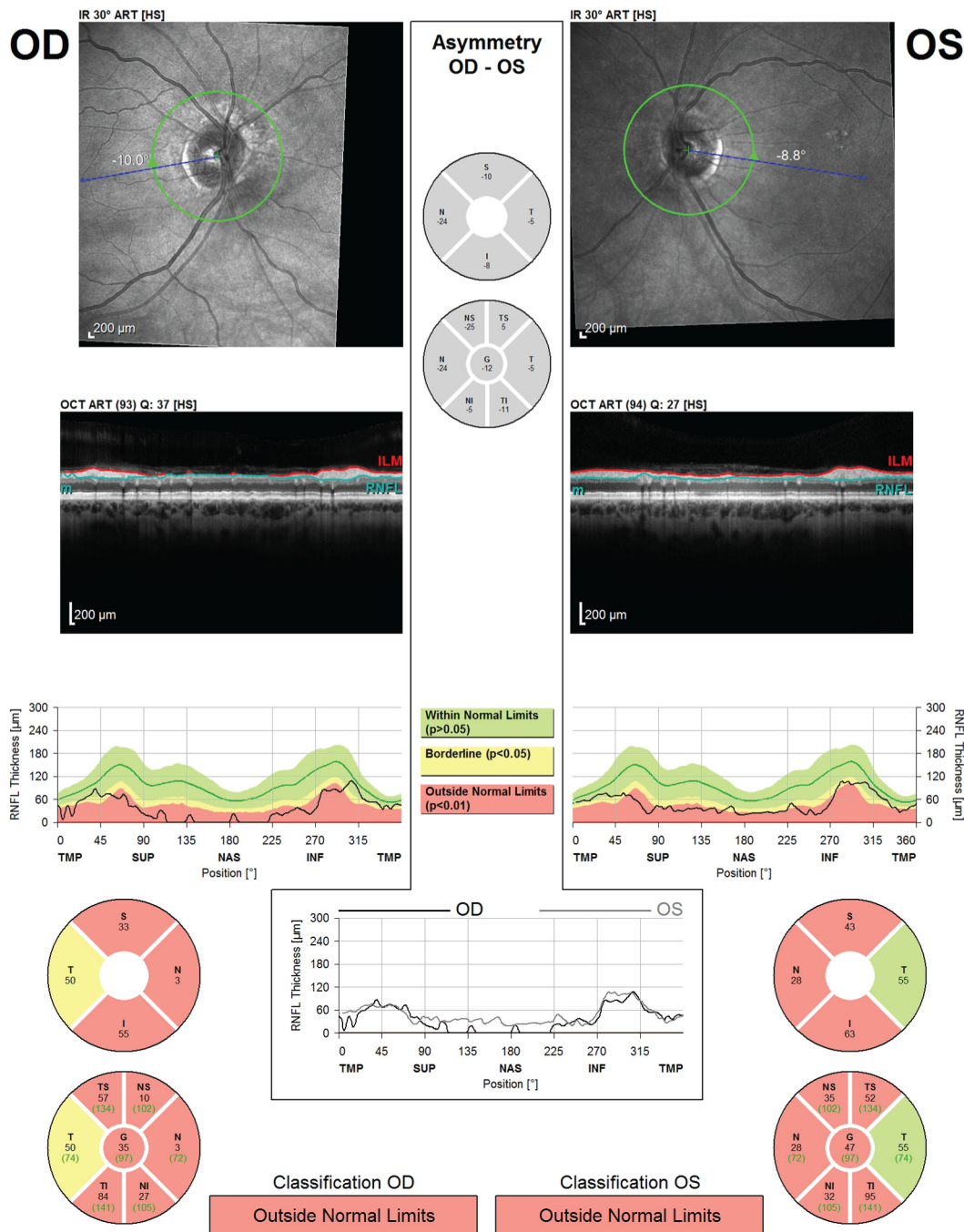


Figure 2 Optical coherence tomography showing thinning of the retinal nerve fibre layer (RNFL) 1 month postquinine overdose. OU, oculus uterque (both eyes); OD, oculus dexter (right eye); OS, oculus sinister (left eye).

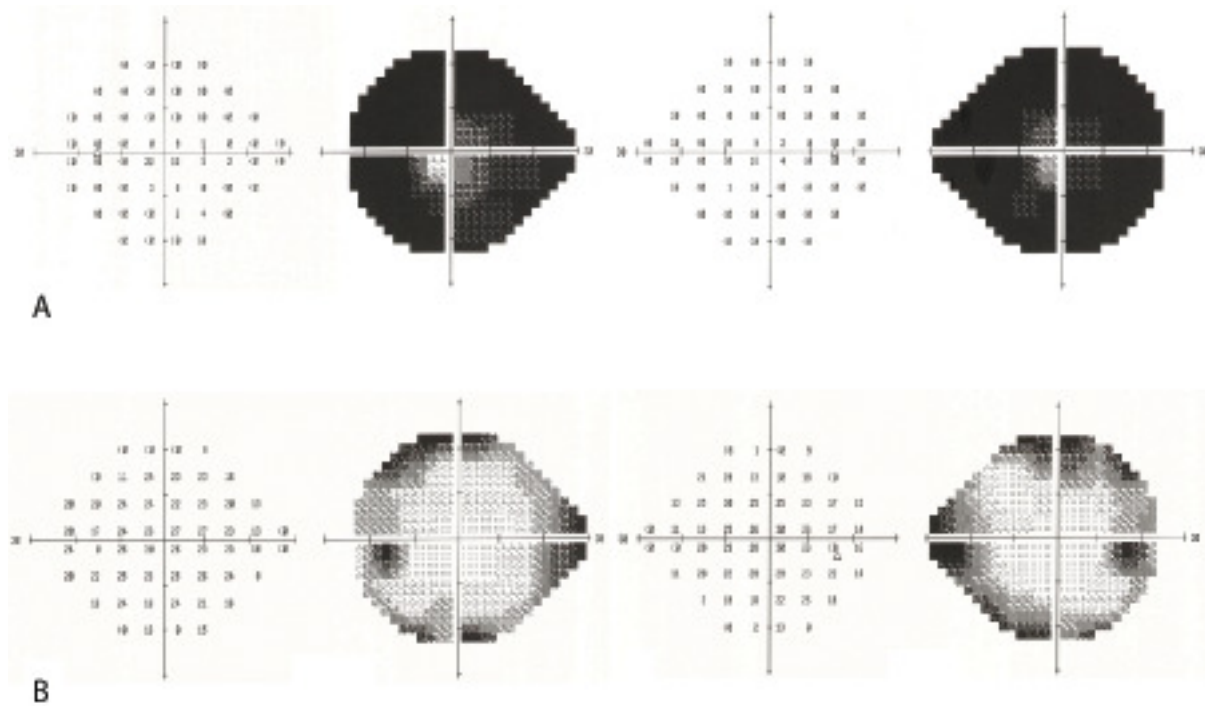


Figure 3 Humphrey perimetry (SITA-Standard 24-2): (A) 1 month postquinine overdose, showing marked constriction of the visual field; (B) 6 months postquinine overdose, showing clear improvement of the visual field defects.

arteriolar constriction seen in some, there have been several case reports of treatment to alleviate vasospasm with agents such as nimodipine.¹ While the retinal vasculature was unremarkable at initial assessment, we prescribed nimodipine based on the very poor level of vision and good safety profile of the medication.

Due to the narrow therapeutic range of quinine, visual effects can also rarely occur at normal doses. Furthermore, as quinine is a commonly prescribed medication, it is not always readily identified as the culprit. It should be suspected particularly in the presence of fixed, dilated pupils and other features of cinchonism.

Acknowledgements We thank the medical photography staff at the Princess Alexandra Eye Pavilion for their help.

Contributors HNH and AJT saw the patient and discussed the content of the manuscript, which was then drafted by HNH and edited by AJT.

Competing interests None declared.

Patient consent Obtained.

Provenance and peer review Not commissioned; externally peer reviewed. This paper was reviewed by Neil Anderson, Auckland, New Zealand.

Open Access This is an Open Access article distributed in accordance with the terms of the Creative Commons Attribution (CC BY 4.0) license, which permits others to distribute, remix, adapt and build upon this work, for commercial use, provided the original work is properly cited. See: <http://creativecommons.org/licenses/by/4.0/>

© Article author(s) (or their employer(s) unless otherwise stated in the text of the article) 2017. All rights reserved. No commercial use is permitted unless otherwise expressly granted.

REFERENCES

- 1 Barrett NA, Solano T. Quinine ocular toxicity: treatment of blindness using therapy for vasospasm. *Anaesth Intensive Care* 2002;30:234–5.
- 2 Christoforidis J, Ricketts R, Loizos T, *et al*. Optical coherence tomography findings of quinine poisoning. *Clin Ophthalmol* 2011;5:75–80.



Recovery from blindness following accidental quinine overdose

Hildegard Nikki Hall and Andrew J Tatham

Pract Neurol published online August 4, 2017

Updated information and services can be found at:

<http://pn.bmj.com/content/early/2017/08/04/practneurol-2017-001610>

These include:

References

This article cites 2 articles, 0 of which you can access for free at:

<http://pn.bmj.com/content/early/2017/08/04/practneurol-2017-001610#BIBL>

Open Access

This is an Open Access article distributed in accordance with the terms of the Creative Commons Attribution (CC BY 4.0) license, which permits others to distribute, remix, adapt and build upon this work, for commercial use, provided the original work is properly cited. See:

<http://creativecommons.org/licenses/by/4.0/>

Email alerting service

Receive free email alerts when new articles cite this article. Sign up in the box at the top right corner of the online article.

Topic Collections

Articles on similar topics can be found in the following collections

[Open access](#) (33)

Notes

To request permissions go to:

<http://group.bmj.com/group/rights-licensing/permissions>

To order reprints go to:

<http://journals.bmj.com/cgi/reprintform>

To subscribe to BMJ go to:

<http://group.bmj.com/subscribe/>