



THE UNIVERSITY *of* EDINBURGH

Edinburgh Research Explorer

Type I interferon causes thrombotic microangiopathy by a dose-dependent toxic effect on the microvasculature

Citation for published version:

Kavanagh, D, McGlasson, S, Jury, A, Williams, J, Scolding, N, Bellamy, C, Gunther, C, Ritchie, D, Gale, DP, Kanwar, YS, Challis, R, Buist, H, Overell, J, Weller, B, Flossmann, O, Blunden, M, Meyer, EP, Krucker, T, Evans, SJW, Campbell, IL, Jackson, AP, Chandran, S & Hunt, DPJ 2016, 'Type I interferon causes thrombotic microangiopathy by a dose-dependent toxic effect on the microvasculature' Blood. DOI: 10.1182/blood-2016-05-715987

Digital Object Identifier (DOI):

[10.1182/blood-2016-05-715987](https://doi.org/10.1182/blood-2016-05-715987)

Link:

[Link to publication record in Edinburgh Research Explorer](#)

Document Version:

Peer reviewed version

Published In:

Blood

Publisher Rights Statement:

This is the author's peer-reviewed manuscript as accepted for publication

General rights

Copyright for the publications made accessible via the Edinburgh Research Explorer is retained by the author(s) and / or other copyright owners and it is a condition of accessing these publications that users recognise and abide by the legal requirements associated with these rights.

Take down policy

The University of Edinburgh has made every reasonable effort to ensure that Edinburgh Research Explorer content complies with UK legislation. If you believe that the public display of this file breaches copyright please contact openaccess@ed.ac.uk providing details, and we will remove access to the work immediately and investigate your claim.



Type I interferon causes thrombotic microangiopathy by a dose-dependent toxic effect on the microvasculature

David Kavanagh¹, Sarah McGlasson², Alexa Jury², Jac Williams³, Neil Scolding⁴, Chris Bellamy⁵, Claudia Gunther⁶, Diane Ritchie³, Daniel P. Gale⁷, Yashpal S. Kanwar⁸, Rachel Challis¹, Holly Buist⁹, James Overell¹⁰, Belinda Weller³, Oliver Flossmann¹¹, Mark Blunden¹², Eric P. Meyer¹³, Thomas Krucker¹⁴, Stephen J. W. Evans¹⁵, Iain L. Campbell¹⁶, Andrew P. Jackson², Siddharthan Chandran³ and David P.J. Hunt^{2,3},

¹National Renal Complement Therapeutics Centre, Institute of Genetic Medicine, Newcastle University, UK

²MRC Institute of Genetics and Molecular Medicine, Edinburgh University, UK

³Centre for Clinical Brain Sciences, Edinburgh University UK,

⁴Institute of Clinical Neurosciences, University of Bristol, UK,

⁵Department of Renal Medicine, University of Edinburgh, UK,

⁶Department of Dermatology, University Hospital, Technical University Dresden, Germany,

⁷Centre for Nephrology, Royal Free Hospital, UCL, London, UK,

⁸Feinberg School of Medicine, Northwestern University, Chicago, USA

⁹Department of Cellular Pathology, Royal Victoria Hospital, Newcastle upon Tyne, UK.

¹⁰Institute of Neurological Sciences, Glasgow University, UK

¹¹Royal Berkshire Hospital, Reading, UK

¹²Barts and the London NHS Trust, London, UK,

¹³Institute of Molecular Life Sciences, University of Zurich, Switzerland,

¹⁴The Scripps Research Institute, La Jolla, California, USA,

¹⁵London School of Hygiene & Tropical Medicine, UK,

¹⁶School of Molecular Bioscience, University of Sydney, Australia

Address for correspondence: david.hunt@igmm.ed.ac.uk

Abstract

Many drugs have been reported to cause thrombotic microangiopathy (TMA), yet evidence supporting a direct association is often weak. In particular TMA has been reported in association with recombinant type I interferon therapies, with recent concern regarding the use of interferon in multiple sclerosis patients. However a causal association has yet to be demonstrated.

Here we adopt a combined clinical and experimental approach to provide evidence of a such an association between type I interferon and TMA. We show the clinical phenotype of cases referred to a national centre is uniformly consistent with a direct dose-dependent drug-induced TMA. We then show that dose-dependent microvascular disease is seen in a transgenic mouse model of interferon toxicity. This includes specific microvascular pathological changes seen in patient biopsies, and is dependent on transcriptional activation of the interferon response through the type I interferon receptor (IFNAR).

Together our clinical and experimental findings provide evidence of a causal link between type I interferon and thrombotic microangiopathy. As such, recombinant type I interferon therapies should be stopped at the earliest stage in patients who develop this complication, with implications for risk mitigation.

Key Points

- Type I interferon therapies can cause a dose-dependent thrombotic microangiopathy
- Recombinant type I interferon therapies should be stopped at the earliest opportunity in patients who develop thrombotic microangiopathy

Introduction

Thrombotic microangiopathy (TMA) syndromes are characterised by endothelial dysfunction, microangiopathic haemolytic anaemia and microvascular ischaemia, with diverse aetiologies which include drugs^{1,2}. Clinicians evaluating TMA patients must decide whether a particular drug is likely to have caused the disease. This difficult decision requires high quality evidence, and recent work has highlighted the difficulty of attributing a causal relationship¹. TMA is typically a rare but serious adverse event which can occur after many years of treatment. As such, an association is unlikely to be detected in randomised controlled trial data³. Therefore, for the large majority of drugs, causality with TMA is inferred from isolated case reports, without wider analyses of drug safety data or experimental evidence¹.

This problem is exemplified by recombinant type I interferon therapies. Recombinant interferon- α and interferon- β therapies act through the common type I interferon receptor IFNAR, and are widely used for the treatment of neoplastic, autoimmune and infectious diseases⁴. Case reports have linked TMA to both interferon- α and interferon- β therapies, the main subclasses of type I interferon^{5,6}. Particular concern has been recently raised regarding interferon- β use in multiple sclerosis patients, where fatal cases of TMA have been observed^{6,7}. However a causal role for interferon remains to be demonstrated, and alternative confounding aetiologies such as other drugs, complement mutations and *E.coli* exposure have been suggested^{6,8}.

Establishing causation in drug safety is a major challenge. Frameworks have been proposed to support evidence of a causal association between disease and environmental factors, the best known of which are the Bradford-Hill criteria^{9,10}. Such frameworks include a potential role for biological and experimental studies in establishing causation. As such the demonstration of causality in drug safety benefits from a multifaceted approach to the adverse drug event, encompassing analyses of individual cases, drug safety data and experimental evidence¹⁰. Critically, such analyses require accurate description of the adverse drug event of interest. This is particularly relevant to the study of TMA since this is a pathophysiologically heterogeneous syndrome, with at least nine primary TMA syndromes described². It is also important to establish whether an adverse event is caused by the drug's active ingredient or by other drug components^{11 12}. For example, renal failure caused by intravenous immunoglobulin therapy is associated with the high sucrose content of the drug, rather than the immunoglobulin itself, with important implications for understanding the adverse event and managing risk¹¹.

To address these questions we performed a detailed clinical analysis of type I interferon-associated TMA cases presenting to a national TMA centre to identify important features of the clinical phenotype of this complication. We provide experimental evidence which suggests that the interferon protein itself directly causes microvascular disease, using a transgenic model of type I interferon (interferon- α 1) toxicity. We subsequently consider the potential implications of these findings for the safety of patients receiving recombinant type I interferon therapies.

Methods

Patient evaluation and drug safety data

Patients with multiple sclerosis who developed thrombotic microangiopathy with interferon- β therapy were referred to the national TMA centre in Newcastle for further evaluation¹³. The study was approved by Newcastle and North Tyneside 1 Research Ethics Committee (MREC/1/3/83). Individual patient interferon dose was determined from patient records and adjusted for weight (mcg/kg). Dose-response was also further assessed through analysis of national spontaneous reporting data. Requests for safety data were submitted in the context of a registered patient safety audit (NHS Lothian DCNQIT417). Cases of interferon-associated thrombotic microangiopathy reported throughout the UK were identified through a request for spontaneous data submitted to the UK Medicines and Healthcare products Regulatory Authority (MHRA). All spontaneously reported cases of thrombotic microangiopathy associated with recombinant interferon- β from 1999 to January 2016 to the MHRA were identified, using search criteria “haemolytic uraemic syndrome”, “thrombotic thrombocytopenic purpura”, “thrombotic microangiopathy” and “malignant hypertension”. These cases represent all TMA cases spontaneously reported using the UK “Yellow Card” spontaneous reporting scheme as well as UK cases reported in the published literature.

Immunohistochemical analysis

Paraffin-embedded renal biopsies from patients with IFN- β -associated thrombotic microangiopathy were cut into 5 μ m sections, rehydrated and boiled in sodium citrate buffer (pH 6.0). Sections were stained with mouse-anti-MxA (kind gift, Otto Haller, University of Freiburg; 1:400) followed by staining with EnVision™ Gl2 System/AP Rabbit/Mouse (Dako) and counterstained with Mayer’s hematoxylin (Merck).

In vitro effects of type I interferon on endothelial cells

BEND.5 immortalised mouse brain endothelial cells were plated at 5×10^5 cells per well of a 6 well plate in 1 ml DMEM containing 10% FCS and incubated at 37°C with 5% CO₂. Recombinant mouse or human IFN- α or IFN- β (R+D Systems: Mouse interferon alpha A, 12100-1, mouse interferon beta 12400-1, human interferon beta 1a 11415-1, human interferon alpha 2 11105-1) was added to culture media at concentrations 0-10⁴U/mL and incubated for 24 hours. Total RNA was isolated from each well using QIAshredder and RNeasy (QIAGEN), according to the manufacturer’s instructions. Each biological replicate was assayed for expression of *Oas1A* and *Ifit1* and the housekeeping gene *Hprt* using Brilliant II SYBR master mix (Agilent technologies). Thermocycling and data acquisition were performed using ABI Prism 7900HT Real-time PCR system. A t-test was performed to compare relative gene expression at highest interferon dose to no interferon. (GraphPad Prism Version 6.0d). For human endothelial cells we accessed publically available microarray data from Interferome v 2.01¹⁴ for human endothelial cells (HUVECs) treated with interferon- α and interferon- β (recombinant protein from Schering-Plough at 1000 IU/ml)¹⁵. The fold-change for genes in interferon- α and interferon- β treated HUVECs were compared.

Analysis of microvasculature in a mouse model of type I interferon toxicity

The generation of transgenic mice (termed GFAP-IFN α 1) with astrocyte-targeted, brain-specific production of type I interferon has been described previously¹⁶. Animal experiments were approved by University of Sydney Animal Ethics Committee (protocol number 5374). All animal experimental procedures were carried out in compliance with local procedures and guidelines. The microvasculature of non-transgenic littermate wildtype mice (*WT*), transgenic mice with low levels of astrocyte-derived IFN- α 1 production (*IFN^{Low}*) and high levels of IFN- α 1 production (*IFN^{High}*) was

examined and quantified. Mice were perfused intracardially at 2-3 months of age, with ice-cold saline followed by 4% paraformaldehyde in PBS (n=8, each group). Brains were removed, postfixed overnight in the same fixative, dehydrated through graded alcohol solutions, and embedded in paraffin. For immunohistochemical detection of T cells and endothelial cells, sections were deparaffinized, rehydrated in graded alcohol, rinsed in phosphate-buffered saline (PBS), and blocked for 1 hour at room temperature in PBS containing 1% bovine serum albumin. The sections were then incubated overnight at 4°C with primary antibody diluted in blocking buffer (CD3, Abcam rabbit monoclonal ab16669 and CD31, Abcam rabbit polyclonal ab28364). The sections were then washed in PBS and incubated with anti-rabbit avidin-biotinylated horseradish peroxidase complex (ABC kit; Vector, Burlingame, CA) used according to the manufacturer's instructions. The total number of microvascular abnormalities was counted across three X20 magnification fields per anatomical region, with counting performed blind to mouse genotype. One-way ANOVA was performed across groups for each anatomical region (GraphPad Prism Version 6.0d). For rescue experiments *IFN^{High}* mice were crossed to *IFNAR^{-/-}* mice, which lack a functional type 1 interferon receptor¹⁷.

For RNA analysis, whole brain was removed and immediately snap-frozen in liquid nitrogen. Total RNA was extracted from the tissue samples using TriReagent (Sigma-Aldrich) performed according to the manufacturer's instructions. The RNA concentration of the samples was determined by UV spectroscopy at 260 nm. For all probe sets, a fragment of the *L32* gene was included and served as an internal loading control. The ribonuclease protection assays (RPAs) for interferon response genes were performed and analyzed as described previously^{18,19}, with autoradiographs quantified by densitometry using Image J software, n=3 each group.

Vascular casting of interferon transgenic mice

Vascular casting of *WT* (n=2) and *IFN^{High}* mice (n=6) was performed as previously described²⁰, in accordance with National Institutes of Health Guidelines for Care and Use of Laboratory Animals. Briefly, deeply anesthetized animals were perfused with artificial cerebrospinal fluid (ACSF) containing Heparin, followed by 4% paraformaldehyde in PBS, and an injection of the resin Mercor (Ladd Research, Williston, VT). After resin curing, soft tissue was subsequently macerated followed by decalcification with 5% formic acid. Casts were washed, then dried by lyophilization, mounted on stubs, and sputter-coated with gold for routine scanning electron microscopy.

Results

Interferon- β causes a direct drug-induced thrombotic microangiopathy

In view of the recent regulatory concerns regarding the potential association between type I interferon therapy and TMA in multiple sclerosis patients⁶, we first performed a detailed analysis of the clinical features of interferon- β associated thrombotic microangiopathy. The clinical phenotype of new and index⁶ cases of interferon- β associated TMA in multiple sclerosis patients was reviewed by the UK national thrombotic microangiopathy centre¹³ (n=8, Table 1, Figure 1). Microangiopathic haemolytic anaemia, renal failure and severe hypertension were universally seen and at least one other organ was affected, with prominent brain and cardiac involvement. (Figure 1A-D). No patient received any other drugs associated with TMA¹ and no other confounding TMA triggers or other autoimmune diseases were identified^{1,21,22,23}. Detailed genetic evaluation, including exome sequencing, did not identify mutations in any gene associated with thrombotic microangiopathy. The final diagnostic evaluation by the national centre was uniformly consistent with a chronic drug-induced thrombotic microangiopathy (Table 1, Supplementary Table 1)^{1,24,25}.

Drug-induced thrombotic microangiopathies can be caused by a direct toxic effect of the drug or via indirect immune-mediated mechanisms¹. Given that direct toxic reactions are typically dose-dependent²⁴, we next examined the relationship between TMA and interferon dose. Affected patients were all in the bottom weight quartile, adjusting for age and sex²⁶. This observation of low weight was replicated in an independent case series⁷. Therefore patients who developed TMA received a significantly higher weight-adjusted interferon dose than those who did not develop the complication (Figure 1E P<0.001 t-test). To confirm this dose-dependence we requested national spontaneous reporting data from the UK Medicines and Healthcare Products Regulatory Agency. This showed that all cases were associated with a dose of interferon- β in excess of 50mcg per week, with 92% of cases associated with the highest available dose (Figure 1F). Evidence of interferon bioactivity (Figure 1G-H) was detected in patient renal biopsies, and anti-interferon antibodies were not detected in any patient, consistent with a direct rather than immune-mediated effect of the drug. Taken together these results suggest that interferon- β causes a toxic drug-induced thrombotic microangiopathy in multiple sclerosis patients.

Thrombotic microangiopathy is observed with all type I interferon subtypes

We next asked whether TMA was observed with all subtypes of recombinant type I interferon therapies in clinical use. The type I interferon family of proteins consists of a family of 13 alpha subtypes and a single major beta subtype²⁷. These subtypes exhibit structural similarity and exert their biological activity via the common type I interferon receptor IFNAR (Figure 2A). Recombinant interferon- α therapies are used to treat a broad range of diseases such as CML, hepatitis C and melanoma. Systematic review of the literature shows that thrombotic microangiopathy has been reported as a complication of every subtype of recombinant type I interferon in clinical use; IFN α 2a, IFN α 2b, IFN β 1a and IFN β 1b (Figure 2B, Supplementary Figure 1).

We next compared the detailed clinical phenotype described here of interferon- β associated TMA with a comparably detailed analysis of a series of interferon- α associated TMA, analysed at a specialised centre⁵ (n=8 both groups). A similar clinical phenotype is observed in both case series (Supplementary Table 2). Specifically, interferon- α and interferon- β TMA were associated with long-term therapy at high-doses⁵. Both groups displayed severe hypertension, predominant involvement of the renal microvasculature, moderate thrombocytopenia and a poor renal outcome. All published cases are summarised in the supplementary tables 3 and 4 and confirm that this clinical picture is seen in

the majority of patients. Furthermore, the transcriptomic response of human endothelial cells to both human interferon- α and interferon- β are highly correlated (Figure 2C, $r=0.97$)¹⁵. Therefore thrombotic microangiopathy can occur with all subtypes of recombinant type I interferon therapies, and these subtypes exert an almost identical effect on endothelial cells.

Thrombotic microangiopathy is associated with “interferonopathic” disease

An activated type I interferon response can be induced by recombinant protein therapies, but can also occur spontaneously in patients in whom endogenous levels of type I interferon are pathologically elevated. These “interferonopathic” diseases include monogenic disorders of interferon dysregulation, as well as more common autoimmune diseases such as SLE^{28,29}. We reviewed pathological findings from patients with different diseases where transcriptomic evidence of an interferon signature has been reported, and identified an association with histopathological evidence of thrombotic microangiopathy, which is exceptionally rare as a spontaneous disease³⁰ (Supplementary Figure 1). Therefore thrombotic microangiopathy is observed in states of elevated endogenous and exogenous type I interferon in humans.

Type I interferon signalling is species specific, limiting interpretation of preclinical toxicity tests

Given this clinical evidence that TMA is a manifestation of interferon toxicity, we next sought to provide experimental evidence that the recombinant protein itself can cause the small vessel disease observed in the patients described here. To address whether interferon can directly cause microangiopathic disease in rodent models, we first evaluated available preclinical toxicity data used in the clinical development of both recombinant interferon - α and - β therapies^{31,32}. No reports of microvascular toxicity were recorded in extensive preclinical testing of human recombinant protein in rodents. However, type I interferon signalling is highly species specific, and human interferon - α and - β do not cause upregulation of interferon response genes in mouse endothelial cells (Figure 3A,B). Therefore, preclinical rodent toxicity models cannot be used to evaluate whether interferon causes endothelial toxicity^{31,32}.

Transgenic overexpression of type I interferon causes a spectrum of microangiopathic disease, including changes seen in patient biopsies

To overcome the problem of species disparity of interferon action, we utilised a species-matched transgenic mouse model to evaluate the effects of chronic type I interferon exposure on small blood vessels. In our model, type I interferon (IFN α 1) is transgenically produced in the brain at zero (*WT*), low (*IFN^{Low}*) or high (*IFN^{High}*) levels, leading to focal graded activation of the interferon response via IFNAR (Figure 4A)¹⁶. Quantitative histopathological analyses identified a dose-dependent spectrum of microvascular disease, including endothelial hypertrophy and intimal thickening, microaneurysms and perivascular inflammatory infiltrates (Fig. 4C-F, Figure 5, Figure 6). This microangiopathy was observed across anatomical regions and was dose-dependent (Figure 4G, Figure 6D $P<0.001$ one-way ANOVA).

The three-dimensional morphology of small blood vessels are difficult to assess using conventional histopathological techniques, therefore we performed scanning electron microscope analysis of microvascular casts. This confirmed widespread microvascular abnormalities in the brain, with prominent variations in microvascular calibre including luminal stenosis and occlusions, ectasia and microaneurysms (Fig. 5, Figure 6K-M). These abnormalities were not seen in *WT* mice. This dose-dependent type I interferon-associated microangiopathy included pathological

microvascular abnormalities seen in the biopsies of the patients described above, such as endothelial hyperplasia, luminal occlusion and microaneurysm formation (Figure 7A,B).

To confirm this microvascular pathology is caused by activation of the interferon response through the type I interferon receptor IFNAR, we crossed *IFN^{High}* mice with mice that were null for the type I interferon receptor¹⁷, generating *IFN^{High} x IFNAR1^{-/-}* mice. Both upregulation of interferon response genes (IRG) and microvascular disease were absent in *IFN^{High} x IFNAR1^{-/-}* mice, confirming a critical role of IFNAR in mediating disease (Figure 7C,D).

Taken together these data suggest that type I interferon therapies cause a dose-dependent thrombotic microangiopathy and the interferon protein itself can cause microangiopathic disease.

Discussion

To date, unambiguous evidence of a causal association between type I interferon therapies and thrombotic microangiopathy has been lacking. This lack of evidence, together with a limited understanding of the serious adverse event, has hampered risk mitigation measures for these drugs and makes the clinical decision as to whether to stop interferon treatment in patients with TMA difficult. Thrombotic microangiopathy is a particularly challenging adverse drug event to study since it is rare and may occur after prolonged exposure to the drug. As such, randomised clinical trials are not powered to identify a causal association^{3,33}. The detection of rare or delayed adverse events which occur outside trials typically relies on analysis of case reports and signal detection through spontaneous reporting data³. This approach is subject to bias and confounding and therefore even if an association is identified, a causal relationship cannot be inferred. A number of conceptual frameworks have been proposed when considering how to infer causality from observational clinical data^{10,34}. Some of these frameworks, such as the well-known Bradford-Hill criteria¹⁰, suggest that experimental evidence can provide an important role in establishing causation by demonstrating biological plausibility, and direct evidence of causation in model systems. Our analyses of clinical, drug safety and experimental data satisfy the Bradford-Hill criteria and therefore support a causal link between type I interferon therapy and thrombotic microangiopathy (Supplementary Table 5).

Careful definition of the adverse event of interest is central to the study of drug side-effects⁹. This is of particular relevance here since many cases of interferon-associated TMA have been reported using diverse terms including HUS⁷, TTP³⁵ or malignant hypertension^{35,36}, each implying a different pathophysiological process. It is therefore an important first step to define the clinical syndrome through a centre with expertise in the evaluation of this complex condition. Our analyses of cases suggest that interferon- β therapy is associated with a direct drug-induced thrombotic microangiopathy². Direct drug-induced TMAs, such as those induced by VEGF inhibitors, are characterised by a gradual onset, exposure to high drug dose and absence of immunogenicity^{1,2,24}. This phenotype is consistently reproduced in our cohort here. Three lines of evidence suggest that interferon- β associated TMA is associated with high dose therapy. Firstly, patients who developed the complication received nearly twice the weight-adjusted dose than patients who did not develop the complication. Secondly, our data shows that all cases of TMA spontaneously reported in the UK were associated with doses >50mcg/week. Thirdly, our experimental model recapitulates a striking dose-dependence of endothelial disease.

While our primary focus here has been to address recent ongoing concerns regarding recombinant interferon- β use in multiple sclerosis patients, our wider analyses suggest that thrombotic microangiopathy is associated with all subtypes of recombinant type I interferon in clinical use. Comparison of case series evaluated at centres with TMA expertise suggests that TMA with interferon- α and interferon- β therapy display a similar clinical phenotype. In particular, both are associated with prolonged exposure to high doses of interferon, with chronic changes observed on biopsy. This is characterised by panendothelial disease with prominent renal, cerebral and cardiac involvement which may evolve over months. Further review of the published literature suggests that this clinical phenotype is consistently observed in almost all reported IFN- β TMA cases and most IFN- α TMA cases. Some patients with IFN- α TMA can occasionally present with a broader phenotype more suggestive of TTP, in particular patients with underlying haematological malignancies⁵. Future deep phenotypic study of this adverse event across centres will be important to determine the spectrum and true incidence of this disease, as well as the influence of underlying morbidity on clinical presentation. We propose that the most appropriate working descriptive term for this complication is “type I interferon-associated thrombotic microangiopathy”.

We have tested the hypothesis that type I interferon itself can directly cause microvascular disease. This hypothesis cannot be evaluated in preclinical rodent models due to the species-specificity of type I interferon signalling. We have therefore studied two complementary “species-matched” states of elevated type I interferon in mice and humans. Firstly, our mouse model here provides experimental advantage over preclinical rodent models, through species-matching of interferon, and allows evaluation of the chronic effects of interferon exposure. Analysis of the microvasculature of this model demonstrates that type I interferon causes a spectrum of microangiopathy, with features that overlap with microvascular disease observed in the patients we describe. Secondly we show that TMA, which is exceptionally rare as a spontaneous disease³⁰, is consistently observed across a broad spectrum of human “interferonopathic” diseases. In these disease states, interferon levels are spontaneously elevated in the context of activated innate immunity²⁷. As such they might be considered by the Bradford-Hill criteria to represent an “analogous” system of human interferon toxicity. These diseases include rare genetic disorders of interferon dysregulation^{4,27,28}, as well as more common autoimmune disorders such as SLE³⁷. The precise subtypes of type I interferon which are elevated in these disease states are not yet fully described, but activation of the interferon response downstream of IFNAR is typically observed²⁸. Microangiopathy is a major cause of organ damage in these patients (Supplementary Figure 1)^{38,39}. For example, 25% of patients with SLE affecting the kidney have evidence of TMA on renal biopsy^{40,41} and microangiopathy is a dominant brain pathology in patients with SLE³¹. Therefore microangiopathic disease is consistently seen in mouse and human states of aberrantly elevated type I interferon. It is notable that in both patients and the mouse model we describe, microangiopathy is the dominant pathological feature, with microvascular thrombosis a less prominent feature. The lack of thrombosis on biopsy in many TMAs has resulted in a recent call for a change in nomenclature from TMA to microangiopathy with or without thrombosis to reflect this incongruity⁴².

These findings are relevant to clinicians who must decide whether to stop recombinant type I interferon therapy in patients who develop thrombotic microangiopathy. Our data suggests a causal association and therefore the drug should be stopped at the earliest opportunity given the serious ensuing morbidity. Furthermore our findings are of relevance to risk mitigation strategies since they raise the possibility of stratification and monitoring. In particular detailed retrospective analysis of clinical features and biopsies of cases suggests that type I interferon causes a chronic TMA, which evolves over weeks to months, with a detectable prodrome (supplementary table 6). At present, renal function monitoring and blood pressure monitoring is not mandated for patients receiving type I interferon therapies and none of the patients described here were actively monitored for this complication. Therefore, despite a potential window of opportunity for early recognition, all patients presented at a late stage to emergency or critical care facilities. This late presentation is characterised by fulminant disease and organ failure, sometimes with fatal consequences.

Additional blood pressure and renal function monitoring for TMA have subsequently been introduced across Scotland following concerns about the severity and incidence of this complication in multiple sclerosis patients, where an incidence of ~1:1000 patient-years has been observed in patients treated with high-dose interferon- β ⁶ (supplementary figure 2). This monitoring has led to prompt cessation of interferon- β in patients who have developed severe/accelerated hypertension associated with mild renal dysfunction. Since the implementation of targeted monitoring, no patients have developed fulminant organ failure due to interferon-associated TMA (supplementary Figure 2B). We suggest that further consideration should be given to risk mitigation measures for this serious adverse drug event.

In summary we have shown that type I interferon therapies cause a direct dose-dependent thrombotic microangiopathy and the interferon protein itself can directly damage small blood vessels. The chronic and dose-dependent nature of this complication identifies an opportunity to reduce risk to the large numbers of patients exposed to these drugs. These findings should facilitate and stimulate definitive and rigorous pharmacoepidemiological study of this serious adverse event, with an emphasis on quantification of risk and the potential for mitigation across the available type I interferon therapies. In the meantime, clinicians should be aware of this association when assessing patients and stop recombinant type I interferon therapies at the earliest stage in patients who develop TMA.

Author contributions

All authors contributed to the writing and editing of the manuscript. DH, BW, JO and SC registered and analysed audit with additional input from NS, DG and DK. DH and DK collated clinical data for patients. CB, CG, YK and HB performed histopathological analyses of human renal biopsy specimens. RC performed genetic analyses and exome sequencing. OF, MB, DK were responsible for clinical care and evaluation of inpatients. IC generated transgenic mice. AJu and DH analysed neuropathology of transgenic mice. IC, TK and EPM performed electron microscopic analysis of microvasculature of transgenic mice. JW analysed toxicity reports. SM performed in vitro endothelial cell culture experiments. DH, SC and SE performed pharmacoepidemiological analyses.

Potential Conflicts of Interests

DK and DH are supported by the Wellcome Trust.

IC, JW, CB, CG, OF, SE, EPM declare no conflicts of interest.

BW: Principal Investigator in clinical trials supported by Novartis, Sanofi-Aventis, Biogen Idec. Honoraria for advisory work from Merck, Biogen Idec, Novartis and Bayer. DK: Received honoraria for consultancy work from Alexion Pharmaceuticals. DG: Received honoraria for consultancy from Alexion, Novartis and Otsuka. TK is currently employed by Novartis (experimental work here performed prior to this). JO: Received honoraria for consultancy work and travel grants from Novartis, Teva UK Ltd, Biogen Idec and Merck. NS: Received honoraria and/or research and/or educational support from Merck Serono, Biogen Idec, Teva, GSK and Novartis. SC: Received honoraria for consultancy work from Merck Serono, Biogen Idec and Novartis. Research and/or educational support from Merck, Novartis and Biogen Idec.

Acknowledgements

DH and DK are supported by the Wellcome Trust (DH: WT101153MA) and the Academy of Medical Sciences. CG is supported by a grant from the Deutsche Forschungsgemeinschaft (KFO 249/GU1212/1-1 and GU1212/1-2). APJ is supported by the MRC. IC was supported by NHMRC project grant 512407 and NIH grant MH47680.

We are grateful to neurology consultants and nurses in all major Scottish multiple sclerosis centres and the MHRA for providing data as part of safety audit. We are grateful to Professor James Ironside for advice on neuropathology and Professor Tim Goodship and Dr Martin Reijns for discussions on the manuscript.

Figure 1. Interferon- β causes a direct drug-induced thrombotic microangiopathy in multiple sclerosis patients.

Recombinant interferon- β therapy causes a microangiopathy affecting multiple organs in multiple sclerosis (MS) patients: **(A,B)** MRI brain scan shows multiple small new lesions consistent with recent microvascular ischaemia, identified on diffusion-weighted sequences (white arrows). **(C)** Admission blood film showing fragmented red blood cells (black arrows). **(D)** Haematoxylin and Eosin stain of renal biopsy from patient shows pathological microvascular changes with endothelial swelling, luminal narrowing and trapped red blood cells (black arrow, scale bar = 25 μ m). **(E)** Patients who developed TMA, including patients from an independent cohort⁷, received a higher weight-adjusted dose than unaffected MS patients treated with the same interferon- β preparation, * $P < 0.001$ t-test **(F)** All UK reports of thrombotic microangiopathy associated with interferon- β are associated with IFN β 1a dose >50mcg/week and 92% associated with the highest available dose (n=15 reports) **(G,H)** Evidence of activation of interferon response in renal biopsy of affected patient (MxA immunohistochemistry, red, scale bar 10 μ m), with biopsy from patient with TMA not associated with interferon (G: genetic atypical HUS) for comparison.

Figure 2. Thrombotic microangiopathy is associated with all type I interferon subtypes in clinical use

(A) An overview of type I interferon signalling. Interferon- α and interferon- β act via the transmembrane type I interferon receptor IFNAR, leading to widespread upregulation of interferon response genes. (3D protein models rendered using PyMOL Molecular Graphics System, Version 1.8.2.2 Schrödinger, LLC with protein data obtained from the Protein Data Bank⁴³ www.rcsb.org) **(B)** Dendrogram of human recombinant interferon subtypes in clinical use. Recombinant type I interferon proteins associated with TMA highlighted in red (see supplementary figure 1 for full details). **(C)** Comparison of the transcriptomic response of human endothelial cells (HUVECs) to human interferon- α and interferon- β ¹⁴. The transcriptional response of human endothelial cells to both type I interferon subtypes is highly correlated ($r=0.97$, genes with fold-change >1 shown).

Figure 3. Type I interferon signaling is species specific, limiting interpretation of cross-species preclinical toxicity models Type I interferon proteins ($-\alpha$ and $-\beta$) act through a common receptor (IFNAR), leading to activation of downstream interferon response genes (IRGs). **(A)** Preclinical toxicity testing of human recombinant type I interferon utilises cross-species testing. Human recombinant type I interferon does not elicit a downstream interferon response in mouse endothelial cells, as measured by quantitative PCR for type I interferon response genes in bEnd.5 brain endothelial cell line. Despite extensive preclinical testing (355 mice tested with human interferon- α , 347 mice tested with human interferon- β), no reports of small vessel toxicity were observed in publically available preclinical tests for human recombinant type I interferon therapies tested in rodents^{31,32}. **(B)** In contrast, dose-dependent upregulation of interferon response genes is observed in mouse endothelial cells exposed to same-species recombinant type I interferon *in vitro* (data represent mean \pm SEM * = $P < 0.05$, t-test compared to no interferon, $n=3$ experiments, IFN- α shown).

Figure 4. Type I interferon causes a dose-dependent microangiopathy

(A) Overview of experimental design (see text), with structure of the fusion gene used to generate the GFAP-IFN- α transgenic mice. **(B)** Scanning electron micrograph of IFN^{high} vascular cast, coloured to show larger vessels (red) and microvasculature (box, yellow) **(C-E)** Haematoxylin and eosin sections of mice with maximal interferon overexpression show a spectrum of dose-dependent microangiopathic pathology, including endothelial hypertrophy and intimal thickening (C), microaneurysms (black arrows, D) and perivascular inflammatory cell infiltration and red blood cells within narrowed lumen (blue arrows, E). Scale bars = 20 μ m. **(F)** Scanning electron micrograph of small vessel cast showing variation in microvessel calibre (white arrows) **(G)** Microvascular pathology in interferon-overexpressing mice is dose-dependent, *WT*= wildtype, no transgenic overexpression, IFN^{low} = transgenic line with low interferon overexpression, IFN^{high} = transgenic line with high interferon overexpression (n=8 mice per group. Data represent mean \pm SEM one-way ANOVA $p < 0.001$).

Figure 5. Abnormal morphology of cerebral microvascular casts of *IFN^{High}* mice demonstrated by scanning electron microscopy (A,B,C) Scanning electron micrograph of cerebral microvascular casts of wildtype mice at low (x25), medium (x80) and high power (x300). **(D-F)** Abnormal microvascular morphology in *IFN^{High}* mice, with variations in microvessel calibre (red arrows), ectatic vessels and microaneurysms (blue arrows). Such microvascular abnormalities were observed in all *IFN^{High}* mice with highest levels of brain-restricted interferon- α 1 production (n=6) but not in wildtype mice.

Figure 6. Spectrum of microvascular abnormalities observed in a focal model of type I interferon toxicity.

A spectrum of microvascular disease is observed in mice with transgenic production type I interferon in the brain, across all anatomical regions. **(A-C)** Dose-dependent microvascular pathology in the hippocampus of transgenic mice with zero, low and high levels of interferon overexpression. (Haematoxylin/eosin, abnormal small blood vessel highlighted by black arrow) **(D)** Dose-dependent microvascular pathology was observed across all major brain regions *** $p < 0.01$ one-way ANOVA for each region $n=8$ each group. **(E-G)** Perivascular inflammatory cell infiltration: Haematoxylin/eosin (H+E), CD3 and CD31 immunohistochemistry shows small blood vessels with T-cell infiltration (CD3) and narrowing of lumen (CD31 endothelial marker). **(H)** Ectatic small vessel **(I)** Perivascular infiltration by T-cells (CD3, brown). **(J)** intravascular calcification (Scale bars E-G=20 μ m, H,I = 40 μ m). Scanning electron microscopy of microvascular cast shows **(K)** multiple small capillary microaneurysms **(L)** large microaneurysm and **(M)** ectatic microvessel

Figure 7. Specific pathological features of interferon-associated microangiopathy are seen in patient renal biopsy material and are mediated through the type I interferon receptor (A-B) Microvascular pathology identified in this model includes specific pathological abnormalities such as luminal narrowing (black arrows), endothelial hyperplasia (green arrows) and microaneurysm formation (blue arrows), which were seen in the biopsies of the patients described above. Scale bars = 20 μ m. **(C)** Upregulation of interferon response genes (*Isg15*, *Irf7*, *Cxcl10*) was observed in *IFN^{High}* transgenic mice and absent in mice which lack the type I interferon receptor (*IFN^{High} x IFNAR^{-/-}*). Total RNA was extracted from the brain of wildtype and transgenic mice and analyzed by ribonuclease protection assay and visualized by autoradiography (n=3 per group). **(D)** Rescue of microvascular pathology in *IFN^{High}* mice which lack the type I interferon receptor (*IFN^{High} x IFNAR^{-/-}*). Data represent mean +/-SEM *** P<0.001, t-test compared to *IFN^{High}* n=8 regions.

Clinical Feature		Number of cases n=8
Underlying disease	Relapsing remitting multiple sclerosis	All
Presenting features	Microangiopathic haemolytic anaemia	All
	Emergency/critical care admission	All
	Severe/malignant hypertension	All
	Renal Failure	All
	Additional organ involvement*	All
Specialist investigation	Reduced ADAMTS13 activity***	None
	aHUS mutations** <i>CFH, CFI, C3, CF, CD46, THBD</i>	None
	Immune reaction against IFN- β (neutralising antibody titre >20 NU/ml)***	None
Chronicity	Length of treatment > 5 years	All
	Thrombotic microangiopathy with chronic changes on renal biopsy**	All
Dose dependence	Treated with >50mcg/week	All
	Weight in bottom quartile	All
Final Diagnostic Evaluation	Direct drug-induced thrombotic microangiopathy	All

Table 1. Summary of clinical features of thrombotic microangiopathy associated with interferon- β referred to the national UK thrombotic microangiopathy centre. Summary of clinical features of new and index cases⁶ of interferon-associated thrombotic microangiopathy in multiple sclerosis patients referred to the national TMA centre in Newcastle. * neurological involvement 4/8 cases, cardiac involvement 6/8 cases **= data available for 7/8 cases. *** data available for 6/8 cases. Full clinical details of all cases are in Supplementary Table 1. Following diagnostic re-evaluation the clinical phenotype of the cases was uniformly consistent with a direct drug-induced thrombotic microangiopathy^{2,24}.

References

1. Al-Nouri ZL, Reese JA, Terrell DR, Vesely SK, George JN. Drug-induced thrombotic microangiopathy: a systematic review of published reports. *Blood*. Jan 22 2015;125(4):616-618.
2. George JN, Nester CM. Syndromes of thrombotic microangiopathy. *The New England journal of medicine*. Nov 6 2014;371(19):1847-1848.
3. Pirmohamed M, Breckenridge AM, Kitteringham NR, Park BK. Adverse drug reactions. *Bmj*. Apr 25 1998;316(7140):1295-1298.
4. McGlasson S, Jury A, Jackson A, Hunt D. Type I interferon dysregulation and neurological disease. *Nature reviews. Neurology*. Sep 2015;11(9):515-523.
5. Zuber J, Martinez F, Droz D, Oksenhendler E, Legendre C, Groupe D'etude Des Nephrologues Di-d-F. Alpha-interferon-associated thrombotic microangiopathy: a clinicopathologic study of 8 patients and review of the literature. *Medicine*. Jul 2002;81(4):321-331.
6. Hunt D, Kavanagh D, Drummond I, et al. Thrombotic microangiopathy associated with interferon beta. *The New England journal of medicine*. Mar 27 2014;370(13):1270-1271.
7. Laroche C, Grand'maison F, Bernier GP, Latour M, Cailhier JF, Prat A. Thrombotic thrombocytopenic purpura-hemolytic uremic syndrome in relapsing-remitting multiple sclerosis patients on high-dose interferon beta. *Multiple sclerosis*. Nov 2014;20(13):1783-1787.
8. Ben-Amor AF, Trochanov A, Fischer TZ. Cumulative Review of Thrombotic Microangiopathy, Thrombotic Thrombocytopenic Purpura, and Hemolytic Uremic Syndrome Reports with Subcutaneous Interferon beta-1a. *Advances in therapy*. May 2015;32(5):445-454.
9. Shakir SA, Layton D. Causal association in pharmacovigilance and pharmacoepidemiology: thoughts on the application of the Austin Bradford-Hill criteria. *Drug safety*. 2002;25(6):467-471.
10. Bradford-Hill A. The environment and disease: association or causation. *Proc R Soc Med*. 1965;58:295-300.
11. Orbach H, Tishler M, Shoenfeld Y. Intravenous immunoglobulin and the kidney--a two-edged sword. *Seminars in arthritis and rheumatism*. Dec 2004;34(3):593-601.
12. Casadevall N, Nataf J, Viron B, et al. Pure red-cell aplasia and antierythropoietin antibodies in patients treated with recombinant erythropoietin. *The New England journal of medicine*. Feb 14 2002;346(7):469-475.
13. Sheerin NS, Kavanagh D, Goodship TH, Johnson S. A national specialized service in England for atypical haemolytic uraemic syndrome-the first year's experience. *QJM : monthly journal of the Association of Physicians*. Jan 2016;109(1):27-33.
14. Rusinova IF, S.; Yu, S.; Hertzog, P.J.; INTERFEROME v2.0:an updated database of annotated interferon-regulated genes. *Nucleic Acids Research*. 2013;41:1040-1046.
15. Indraccolo SP, U.; Minuzzo, S.; Esposito, G.; Roni, V.; Mandruzzato, S.; Ferrari, N.; Albin, A.; Amadori, A. Identification of genes selectively regulated by IFNs in endothelial cells. *The Journal of Immunology*. 2007;178(2):1122-1135.
16. Akwa Y, Hassett DE, Eloranta ML, et al. Transgenic expression of IFN-alpha in the central nervous system of mice protects against lethal neurotropic viral infection but induces inflammation and neurodegeneration. *Journal of immunology*. Nov 1 1998;161(9):5016-5026.
17. Muller U, Steinhoff U, Reis LF, et al. Functional role of type I and type II interferons in antiviral defense. *Science*. Jun 24 1994;264(5167):1918-1921.
18. Campbell IL, Ertz M, Lim SL, et al. Trans-signaling is a dominant mechanism for the pathogenic actions of interleukin-6 in the brain. *The Journal of neuroscience : the official journal of the Society for Neuroscience*. Feb 12 2014;34(7):2503-2513.
19. Hofer MJ, Li W, Lim SL, Campbell IL. The type I interferon-alpha mediates a more severe neurological disease in the absence of the canonical signaling molecule interferon regulatory factor 9. *The Journal of neuroscience : the official journal of the Society for Neuroscience*. Jan 20 2010;30(3):1149-1157.
20. Meyer EP, Ulmann-Schuler A, Staufenbiel M, Krucker T. Altered morphology and 3D architecture of brain vasculature in a mouse model for Alzheimer's disease. *Proceedings of the National Academy of Sciences of the United States of America*. Mar 4 2008;105(9):3587-3592.
21. Caprioli J, Noris M, Brioschi S, et al. Genetics of HUS: the impact of MCP, CFH, and IF mutations on clinical presentation, response to treatment, and outcome. *Blood*. Aug 15 2006;108(4):1267-1279.
22. Cataland SR, Holers VM, Geyer S, Yang S, Wu HM. Biomarkers of terminal complement activation confirm the diagnosis of aHUS and differentiate aHUS from TTP. *Blood*. Jun 12 2014;123(24):3733-3738.
23. Schramm EC, Roumenina LT, Rybkina T, et al. Mapping interactions between complement C3 and regulators using mutations in atypical hemolytic uremic syndrome. *Blood*. Apr 9 2015;125(15):2359-2369.
24. Eremina V, Jefferson JA, Kowalewska J, et al. VEGF inhibition and renal thrombotic microangiopathy. *The New England journal of medicine*. Mar 13 2008;358(11):1129-1136.
25. Fang CJ, Fremeaux-Bacchi V, Liszewski MK, et al. Membrane cofactor protein mutations in atypical hemolytic uremic syndrome (aHUS), fatal Stx-HUS, C3 glomerulonephritis, and the HELLP syndrome. *Blood*. Jan 15 2008;111(2):624-632.
26. Anthropometric Reference Data for Children and Adults. National Health Statistics Reports. Number 10. October 22, 2008.

27. Crow YJ, Manel N. Aicardi-Goutieres syndrome and the type I interferonopathies. *Nature reviews Immunology*. Jul 2015;15(7):429-440.
28. Rice GI, Forte GM, Szykiewicz M, et al. Assessment of interferon-related biomarkers in Aicardi-Goutieres syndrome associated with mutations in TREX1, RNASEH2A, RNASEH2B, RNASEH2C, SAMHD1, and ADAR: a case-control study. *The Lancet Neurology*. Dec 2013;12(12):1159-1169.
29. Baechler EC, Batliwalla FM, Karypis G, et al. Interferon-inducible gene expression signature in peripheral blood cells of patients with severe lupus. *Proceedings of the National Academy of Sciences of the United States of America*. Mar 4 2003;100(5):2610-2615.
30. Miller DP, Kaye JA, Shea K, et al. Incidence of thrombotic thrombocytopenic purpura/hemolytic uremic syndrome. *Epidemiology*. Mar 2004;15(2):208-215.
31. *Toxicologist's review, BLA#99-1488, recombinant human interferon- α 2b.*
32. *Toxicologist's review, PLA#98-0261, recombinant human interferon- β 1a.*
33. Randomised double-blind placebo-controlled study of interferon beta-1a in relapsing/remitting multiple sclerosis. PRISMS (Prevention of Relapses and Disability by Interferon beta-1a Subcutaneously in Multiple Sclerosis) Study Group. *Lancet*. Nov 7 1998;352(9139):1498-1504.
34. Rothman KJ, Greenland S. Causation and causal inference in epidemiology. *American journal of public health*. 2005;95 Suppl 1:S144-150.
35. Vosoughi R, Marriott JJ. Thrombotic microangiopathy in Interferon Beta treated multiple sclerosis patients: Review of literature and report of two new cases. *Multiple sclerosis and related disorders*. May 2014;3(3):321-325.
36. Rubin S, Lacraz A, Galantine V, Gosse P. Malignant hypertension and interferon-beta: a case report. *Journal of human hypertension*. May 2014;28(5):340-341.
37. Bennett L, Palucka AK, Arce E, et al. Interferon and granulopoiesis signatures in systemic lupus erythematosus blood. *The Journal of experimental medicine*. Mar 17 2003;197(6):711-723.
38. Kolivras A, Aeby A, Crow YJ, Rice GI, Sass U, Andre J. Cutaneous histopathological findings of Aicardi-Goutieres syndrome, overlap with chilblain lupus. *Journal of cutaneous pathology*. Aug 2008;35(8):774-778.
39. Rasmussen M, Skullerud K, Bakke SJ, Lebon P, Jahnsen FL. Cerebral thrombotic microangiopathy and antiphospholipid antibodies in Aicardi-Goutieres syndrome--report of two sisters. *Neuropediatrics*. Feb 2005;36(1):40-44.
40. Song D, Wu LH, Wang FM, et al. The spectrum of renal thrombotic microangiopathy in lupus nephritis. *Arthritis research & therapy*. 2013;15(1):R12.
41. Scolding NJ, Joseph FG. The neuropathology and pathogenesis of systemic lupus erythematosus. *Neuropathology and applied neurobiology*. Jun 2002;28(3):173-189.
42. KDIGO Controversies Conference on Complement-Mediated Kidney Disease. Barcelona2015.
43. Berman HM, Westbrook J, Feng Z, et al. The Protein Data Bank. *Nucleic Acids Res*. Jan 1 2000;28(1):235-242.

Figure 1

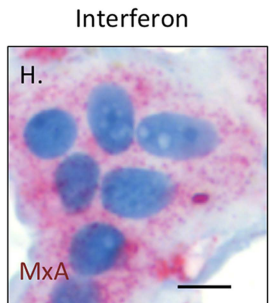
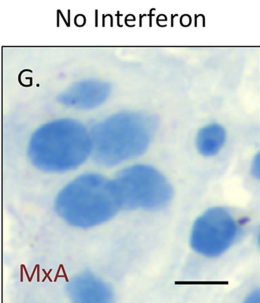
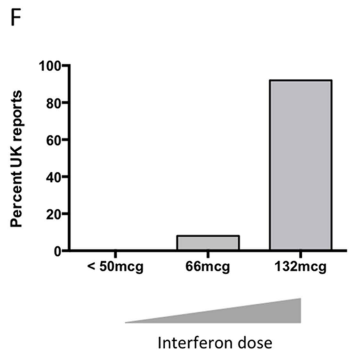
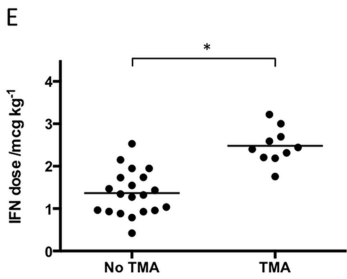
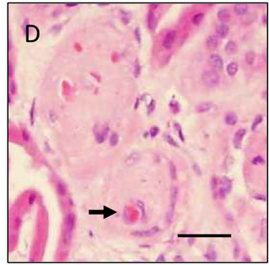
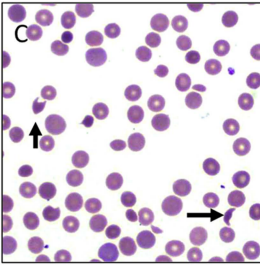
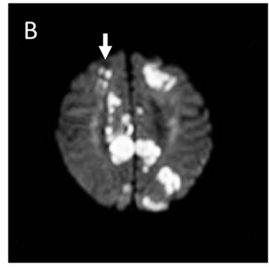
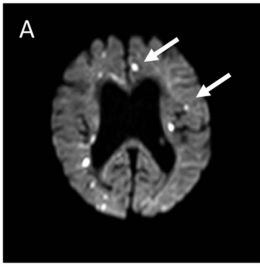


Figure 2

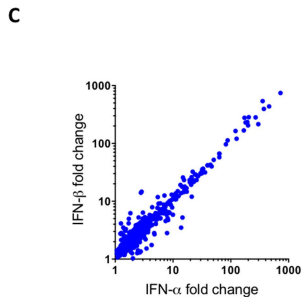
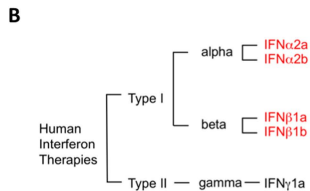
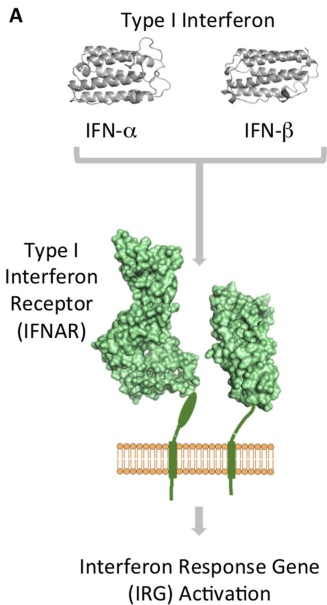


Figure 3

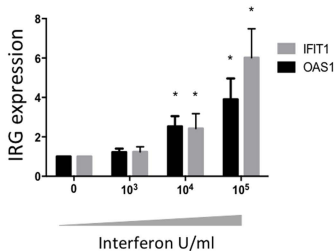
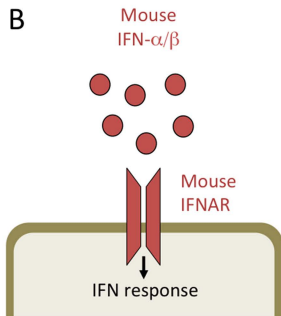
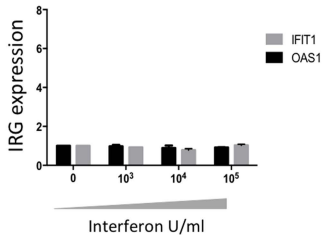
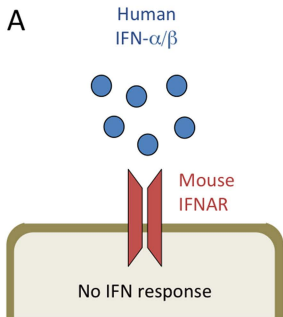


Figure 4

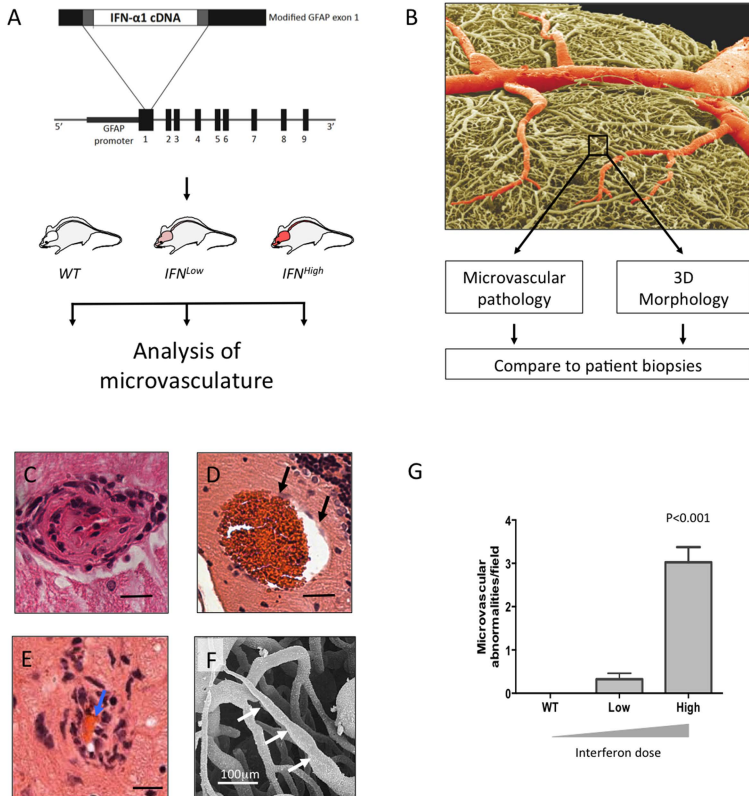

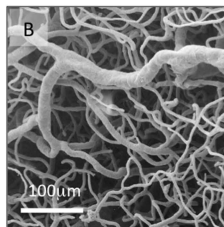


Figure 5


Wildtype



x25




x80

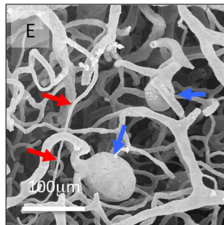


x300


Transgenic type I interferon production



x25



x80



x300

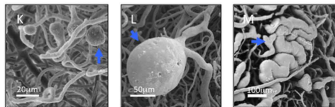
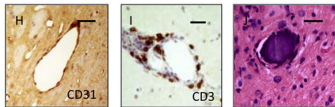
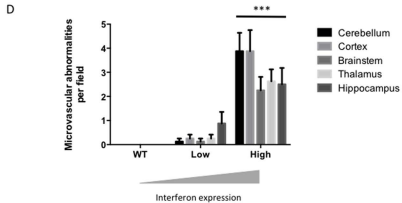
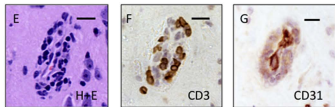
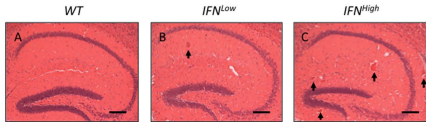
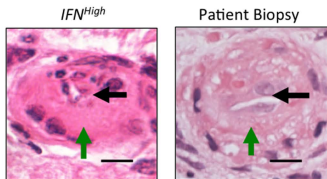
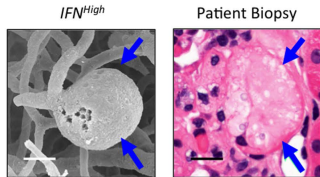


Figure 6

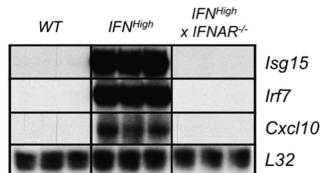
A ——— IFN-Microangiopathy ———



B ——— IFN-Microangiopathy ———



C



D

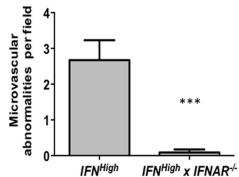


Figure 7