

Operative strategy for fistula-in-ano without division of the anal sphincter

AKY Fung, GV Card, NP Ross, SR Yule, EH Aly

NHS Grampian, UK

ABSTRACT

INTRODUCTION The treatment of perianal fistulas is diverse because no single technique is universally effective. Fistulotomy remains the most effective way of eradicating the pathology but it renders the patient at some risk of faecal incontinence, which many patients are reluctant to take. There are no data in the literature to indicate the healing rate of perianal fistulas when using an operative strategy that routinely avoids division of any part of the anal sphincter. The aim of this paper is to present the long-term results with an operative strategy that aims to avoid division of any part of the anal sphincter complex when treating all types of perianal fistulas, thereby minimising/eliminating the risk of postoperative incontinence.

METHODS We report 54 consecutive cases of anal fistula that presented electively and as an emergency. Patients with known or subsequently diagnosed inflammatory bowel disease or malignancy were excluded from the study.

RESULT Overall, 46 patients (37 male and 9 female) with a median age at presentation of 42 years (range: 19–73 years) were treated by lay-open of the subcutaneous tract of the perianal fistula and insertion of a loose seton for the part of the fistula tract related to the sphincter complex. The types of fistula treated were intersphincteric (89%), transsphincteric (4%) and high suprasphincteric (7%). The median length of time that the seton was left in place was 7 months (range: 1.5–24 months). The healing rate was 86% with a recurrence rate of 19% and a median follow-up duration of 42 months.

CONCLUSIONS Patients who are reluctant to take any risk of faecal incontinence could be treated using an operative strategy that routinely avoids division of any part of the anal sphincter complex as this has a recurrence rate that compares well with other treatment modalities.

KEYWORDS

Fistula-in-ano – Loose seton – Treatment

Accepted 10 February 2013

CORRESPONDENCE TO

Emad Aly, Consultant Colorectal Surgeon, Aberdeen Royal Infirmary, Foresterhill, Aberdeen AB25 2ZN, UK
T: +44 (0)7860 454 176; E: emad.aly@nhs.net

The management of perianal fistula continues to be challenging even though this condition has been well recognised for more than two and a half millennia. One of the earliest documented attempts at treatment of perianal fistulas was reported by Hippocrates in 400BC where he described fistulotomy using a cutting seton made of horse hair wrapped with lint threads.¹ More than 2,000 years later, the debate surrounding the various treatment options of perianal fistula is far from over and the optimal treatment method is yet to be found. The ideal treatment would result in complete healing of the fistula tract, a minimal recurrence rate and, most importantly, no compromise to the function of the anal sphincter.

The aetiology of fistula-in-ano includes Crohn's disease, tuberculosis and malignancy. However, the majority of perianal fistulas seen are related to sepsis in the anal glands situated in the intersphincteric space. Sir Alan Parks proposed this pathogenesis in his 'cryptoglandular hypothesis'.

Subsequently, Parks devised a classification system that categorised fistula-in-ano according to the relation of the primary fistula tract to the external anal sphincter. Fistulas could be intersphincteric, transsphincteric, suprasphincteric or extrasphincteric.² This classification is important to guide surgical management.

Fistula-in-ano can also be classified as simple and complex. Simple fistulas include those that involve the submucosa only with no anorectal muscle involvement while low intersphincteric and low transsphincteric fistulas include those where there is only one fistula tract from the perianal skin and rectal epithelium. In complex fistulas, there might be significant involvement of the anal sphincter muscle complex, they may contain multiple fistula tracts, or they may be associated with recurrent fistulas or inflammatory bowel disease.

Traditionally, treatment of a perianal fistula involves lay-open of the fistula tract by division of all or part of the

anal sphincter complex, depending on the exact anatomy of the fistula tract. While most surgeons were reluctant on division of the external anal sphincter, division of the internal sphincter was practised routinely during treatment of a perianal fistula until colorectal surgeons highlighted the risks associated with this practice; they reported 50–53% incidence of faecal incontinence after surgery for intersphincteric and transsphincteric fistulas.³ The incidence and severity of incontinence were not influenced by division of the external sphincter as 50% of patients with complete preservation of the external sphincter had some deficient sphincter function, which highlights the importance of the internal anal sphincter to attain faecal continence.

This study has emphasised the significance of the internal sphincter in faecal continence and also established the concept that the attempts to preserve the external anal sphincter while sacrificing the internal sphincter may be misguided. It is now well recognised that division of the internal sphincter is associated with an incidence of faecal incontinence of 20–40%.^{4,5} The risk of impairment of continence is particularly concerning in women with an anterior fistula and in the elderly.⁶

These observations led to the development of alternative treatment options. However, most of these choices are associated with either a high recurrence rate or risk of incontinence.

Understandably, many patients are reluctant to take the slightest risk of faecal incontinence, and they request during counselling and consent that no part of the sphincter complex should be divided during their surgery. There are no data in the literature to indicate the operative outcome of a strategy that routinely avoids division of any part of the anal sphincter complex to guide the surgeons when they consent this group of patients.

The aim of this study is to present the long-term outcome of our experience with an operative strategy that aims to achieve healing of perianal fistula without division of any part of the anal sphincter complex.

Methods

Retrospective review of a prospectively maintained database of all patients who presented with perianal fistulas under the care of the senior author (EHA) between 2005 and 2012. Patients presenting with elective, emergency, primary or recurrent fistulas were included but those with inflammatory bowel disease, anorectal malignancy, subcutaneous and submucosal fistulas were excluded.

All patients had examination under anaesthesia by or under the supervision of the senior author (EHA). Magnetic resonance imaging (MRI) of the pelvis was performed to delineate the fistula anatomy for selected patients only (those who had recurrent or complex fistulas). The primary outcome measures were fistula healing and recurrence rates. Secondary outcome was change in faecal incontinence at follow-up.

Operative strategy

An examination of the anorectal area and fistula was performed under general anaesthesia. The type of fistula was

determined during intraoperative assessment (Fig 1) and also whether the fistula tract involved the anal sphincter complex (high or low fistulas). The subcutaneous part of the fistula tract was laid open (Fig 2) to make the fistula tract as short as possible but at the same time without dividing of any part of the anal sphincter complex. Extralevator extension is usually blind sinus. Adequate drainage of the sinus was therefore ensured through the perineal wound by widening its opening with an artery forceps.

The remainder of the fistula tract related to the anal sphincter complex was treated with a loose seton (Fig 3). The procedure was completed without division of any part of the anal sphincter complex, whether internal or external sphincter muscles (Fig 4).

Postoperative care

All non-emergency patients were treated as a day case. The seton was left in situ following surgery, and the patient was discharged and reviewed as appropriate in the outpatient clinic at 6–12-week intervals as judged by the degree of resolution of the perianal sepsis and fistula discharge.

The seton was removed in the outpatient clinic once the perianal sepsis, induration and discharge had completely resolved. Patients were then reviewed at 3–6-month intervals to check for complete healing of the fistula. MRI was used selectively to assess healing of the fistula in patients who continued to have perianal discharge beyond three months following surgery (Fig 6). Patients were given direct access to outpatient clinic review if they had recurrence of their symptoms at a later date.

Results

Between 2005 and 2012, 54 consecutive patients were treated with a loose seton and subcutaneous tract lay-open for perianal fistulas. Of these 54 patients, 8 were excluded because of malignancy ($n=3$), Crohn's disease ($n=3$), ulcerative colitis ($n=1$) and a longstanding fistula related to previous haemorrhoid surgery ($n=1$) (Fig 5). Of the remaining 46 patients included in the study, 37 (80%) were men and 9 (20%) women. The median age at time of presentation with the fistula was 42 years (range: 19–73 years).

Mode of presentation

Seven of the forty-six patients (15%) had setons inserted at the time of acute presentation with abscess as there was an easily identifiable associated fistula tract on examination under anaesthesia. The remaining 39 patients (85%) had setons inserted electively after clinic referral. Of these, 15 (38%) were referred to clinic with perianal discharge and 24 (62%) were referred with recurrent perianal abscesses (Fig 5).

Previous incision and drainage or fistula surgery

Sixteen of the forty-six patients (35%) had undergone previous incision and drainage for a perianal abscess, and ten patients (22%) had undergone previous surgery for a perianal fistula (ie the current episode was a recurrence or they had had a lay-open in the past).

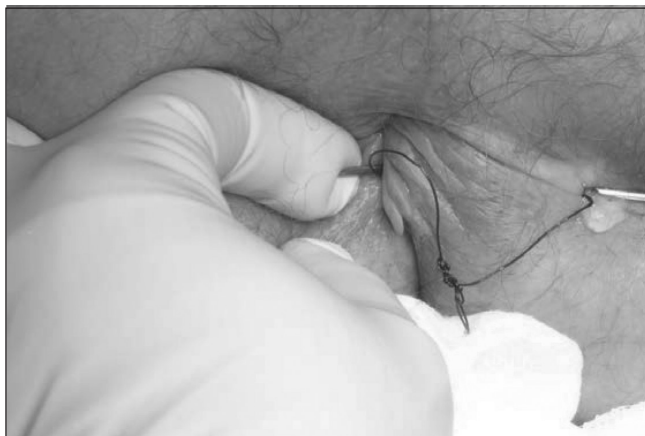

Figure 1 Residual perianal fistula following previous incision and drainage of perianal sepsis and insertion of draining seton

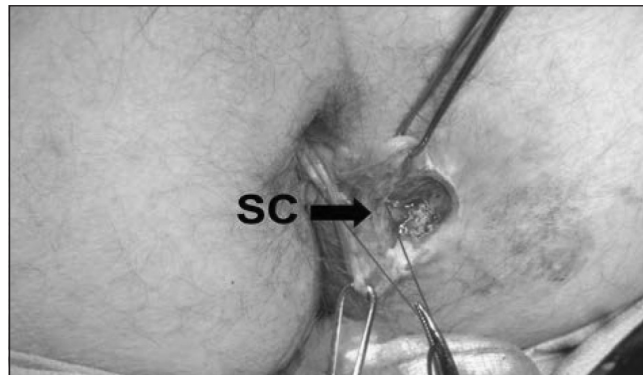


Figure 3 Sphincter complex (SC) is identified and preserved

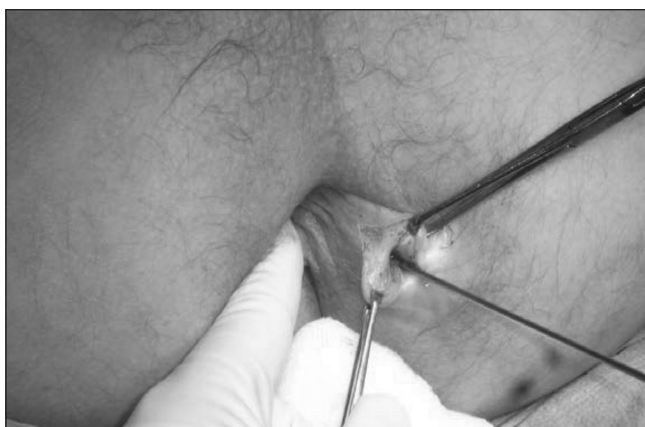

Figure 2 Lay-open of the subcutaneous part of the fistula tract

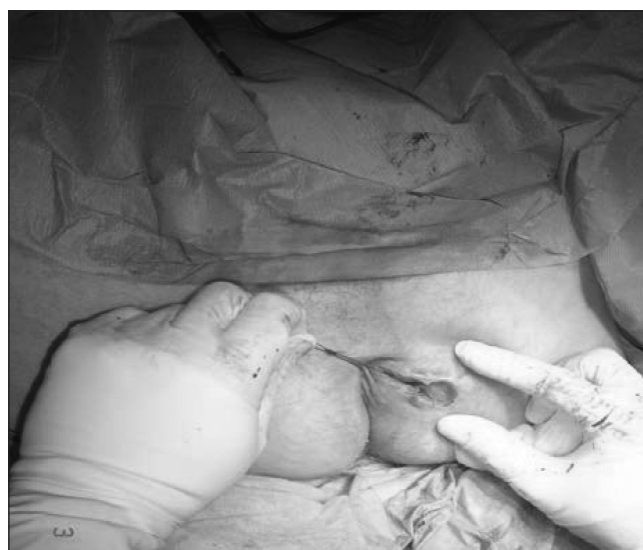

Figure 4 The fistula tract is made as short as possible and the sphincter related tract is drained by a loose seton.

Fistula anatomy

The types of fistula treated were intersphincteric (89%), transsphincteric (4%) and high suprasphincteric (7%). Seven patients (15%) had multiple external openings and were therefore treated with multiple setons.

Duration of treatment with loose seton

The median length of time that the seton was left in place was 7 months (range: 1.5–24 months) (*n*=42). At the time of writing, two patients were still under follow-up with their setons in place. One of these had opted to keep it in place as a long-term measure. Two further patients were lost to follow-up while their setons were still in place.

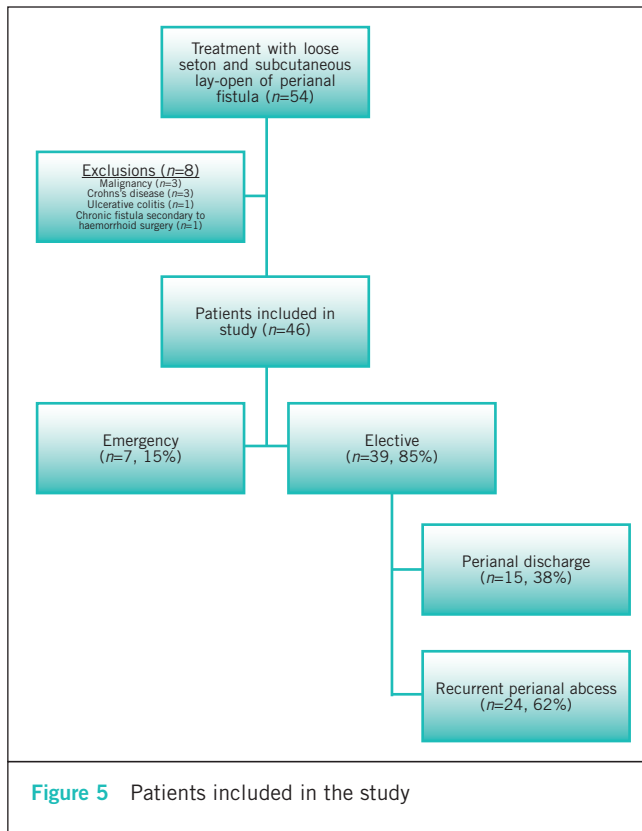
Healing rate

Thirty-six cases (86%) were deemed fully healed at the time of the first and subsequent follow-up appointment after removal of the seton (*n*=42). Two cases were lost to follow-up, and two cases still had their seton in situ at the time of writ-

ing. Of the six cases (14%) that were deemed not fully healed at the time of the first follow-up appointment after removal of the seton, two healed spontaneously while on the waiting list for repeat surgery and had no further recurrence, one required further incision and drainage of an abscess, one required another seton to be inserted, one opted for a Cook® (West Lafayette, IN, US) small intestinal submucosa (SIS) plug and one case did not attend follow-up appointments.

Follow-up period

The median duration of postoperative clinical follow-up (from time of seton insertion until discharge from clinic) was 14 months (range: 3–43 months). At the time of writing, 40 patients in the study group had been discharged from clinical follow-up with complete resolution of their fistulas following treatment with a seton and there had been no reported recurrence. Two patients in the study group



were lost to follow-up. Four patients remain under clinical follow-up.

For the purpose of ascertaining the recurrence rate within a certain timescale, the median period of study follow-up (from time of seton removal until last review of notes in April 2012) was 42 months (range: 7–80 months).

Recurrence rate

Of the 46 cases treated with a loose seton, 9 fistulas (19%) recurred within the median study follow-up period of 42 months (Table 1). Only 3 fistulas recurred within 12 months of seton removal. The median time to recurrence was 20 months (range: 5–34 months).

Of the nine cases that recurred, two had their seton inserted during an acute episode of perianal sepsis and seven were inserted electively following clinic referral. Four patients had received previous incision and drainage of an abscess, and three had previous treatment for fistulas. Eight patients had intersphincteric fistulas and one patient had a high suprasphincteric fistula. The median duration of treatment with a seton was seven months

Further interventions required for recurrent fistulas

Of the nine fistulas that recurred (Fig 6), two did not require any intervention and healed spontaneously while the patients were on the waiting list for further surgery. Four patients required further treatment with a seton. Two of the fistulas healed completely on this occasion, one seton remains in place for treatment and one remains in place at

the patient’s request as a long-term treatment option. One patient required lay-open of the submucous tract, which healed subsequently. One patient had insertion of a Cook® SIS plug with subsequent complete healing of the fistula. One patient re-presented with an abscess that required incision and drainage but no further treatment of the fistula was required.

Preoperative use of magnetic resonance imaging

Nine patients had MRI preoperatively to delineate fistula anatomy, and twelve patients had MRI postoperatively to assess treatment progress and to evaluate possible recurrence.

Discussion

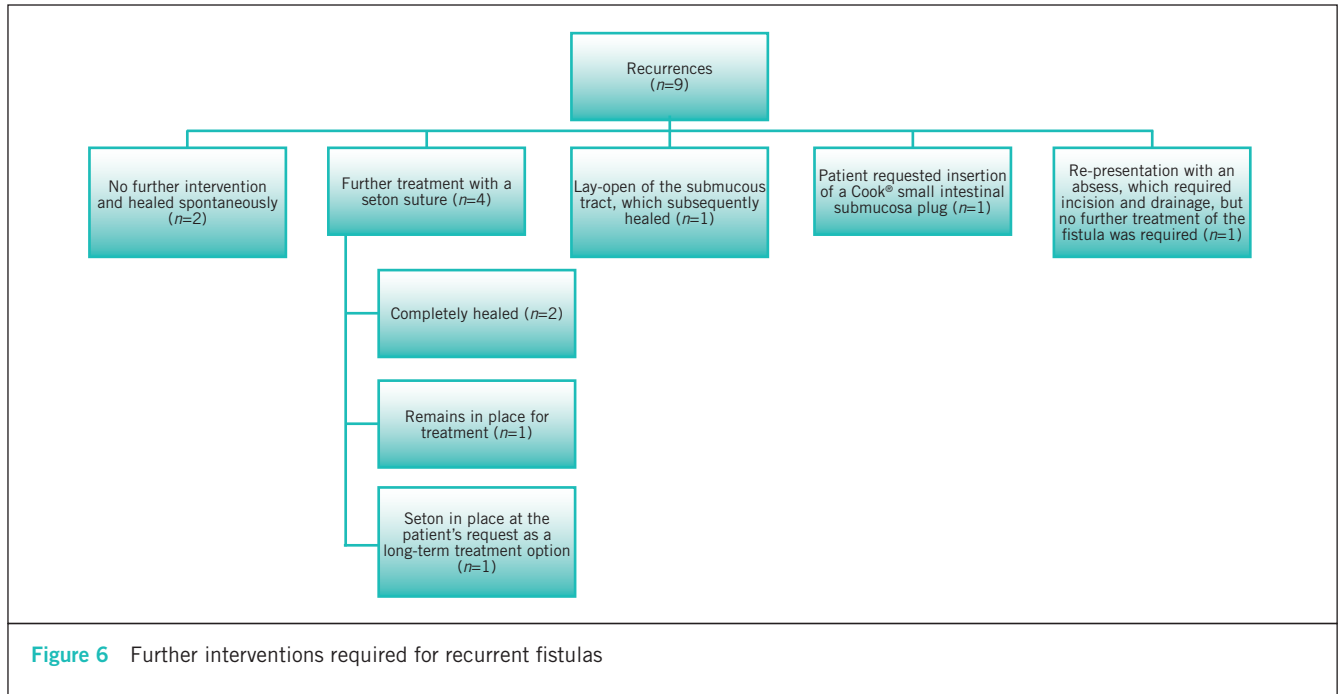
Non-specific perianal fistulas have an estimated incidence of 10 per 10,000 people per year,⁷ with an estimated 10–30% of all colorectal interventions performed to treat anal fistulas.⁸ It was felt previously that despite the increasing number of treatment options, neither frequency of relapse nor changes in postoperative continence have improved, regardless of the surgical technique used.⁹ Therefore, most of the newer treatment strategies (eg fistula plug, fibrin glue and ligation of the intersphincteric fistula tract with [BioLIFT] or without biological mesh insertion [LIFT]) consider preservation of anal continence as their prime focus.

This article presents the healing rate of an operative strategy that routinely avoids division of any of the parts of the anal sphincter complex that is often used in patients reluctant to take any risk of faecal incontinence with fistula surgery. Our results would help surgeons counselling this group of patients to give them an insight on the healing rate using such a strategy. Our proposed operative strategy focuses on two main principles: firstly, lay-open of the subcutaneous part of the fistula tract to make the fistula tract as short as possible and secondly, as a rule of thumb, no part of the anal sphincter complex is divided. Our results are compared with the recurrence and postoperative incontinence rates for the various treatment options in Table 2.

We appreciate that the use of long-term loose seton in the treatment of perianal fistula in itself is not a novel technique. However, we are adopting an innovative strategy by proposing its routine use as an initial measure in preference to lay-open of the fistula tract if it involves division of any part of the anal sphincter complex. This operative strategy aims to avoid the risk of faecal incontinence, whether immediate in the postoperative period or later as the patients get older.

In our series of 46 patients with perianal fistula who were treated by routine loose seton and lay-open of the subcutaneous tract, a fistula healing rate of 86% was demonstrated with a median follow-up period of 42 months. This healing rate compares favourably with the outcomes described in case series where other interventions were used (Table 2). We recorded a fistula recurrence rate of 19% in our case series. Additionally, no patients reported any change in continence at follow-up appointments.

This study challenges some of the longstanding beliefs in fistula treatment. Excision of the infected cryptoglandular



fistula, which is thought to be essential in most of the available treatment options, did not seem necessary as part of our treatment strategy. Furthermore, our healing rate defies the notion that closure of the internal fistula opening (as practised in advancement flap, fistula plug, fibrin glue and LIFT procedures) is crucial for perianal fistula healing.

Traditionally, the use of a loose seton only in the treatment of perianal fistula has been associated with very high failure rates.^{25,26} However, the use of loose seton in the context of our operative strategy seems to give promising results as the essential part of our technique is making the fistula tract as short as possible without sacrificing any anal sphincter muscles. This is potentially comparable with the recent interest in the LIFT procedure. Traditionally, simple closure of the internal opening of the perianal fistula has a high failure rate and is therefore rarely practised. Nevertheless, ligation of the internal fistula opening seems to be effective when applied in the context of LIFT. This success could be in part related to the fact that LIFT shortens the fistula tract connected to the internal opening.

We believe that making the fistula tract as short as possible is the key to accomplishing a successful outcome for treatment with a loose seton and this was achieved in our study by laying open the subcutaneous tract of the fistula but without sacrificing any of the anal sphincter muscles. It could be argued that in patients with a recurrent perianal fistula, combining shortening of the fistula tract with other treatment modalities (eg fistula plug) might increase the chances of complete fistula healing. We have started to employ this technique in patients with multiple recurrences but the total number of patients is too small to allow reporting the outcome of this operative strategy at this stage.

We believe strongly that modern strategies for perianal fistula surgery should always strive at complete preservation of the anal sphincter complex. Perianal fistula surgery in patients older than 45 years is known to be associated with a higher postoperative incontinence rate than for younger patients.²⁷ However, we suspect that the postoperative faecal incontinence reported in most studies is likely to be an underestimation of the true magnitude of the problem as there are no data in the literature to document faecal incontinence following anal fistula surgery in younger patients when they reach their seventh or eighth decade. It is well known that anal sphincter function deteriorates with age, especially in women, as it was noted that aging predominantly affects anal resting pressures while childbirth, particularly instrumental delivery, is detrimental to the structure and function of the external sphincter.²⁸ Previous surgery for a perianal fistula could potentially contribute further to this.²⁹

Consequently, we believe that division of the internal sphincter in fistula surgery should not be taken lightly as even though documented postoperative incontinence following lay-open of low intersphincteric fistulas is between 20%⁵ and 40%,⁴ these figures are related to incontinence in the early postoperative period because there are no data on the outcome when these patients are older.

There are several concepts to support the notion that the internal anal sphincter should be preserved in the interest of continence maintenance as its role in continence is rather complex because of anatomical, physiological and pharmacological factors, with some of these factors not being understood completely.³⁰ These concepts should be disseminated widely as perianal fistula surgery is currently performed across the world by surgeons with variable

Table 1 Clinical details of patients with recurrent fistulas after initial lay-open of subcutaneous tract and insertion of seton

Age at first presentation and sex	Referral	Duration of first loose seton	Duration until recurrence of fistula	Type of primary fistula	Previous fistula surgery	Preoperative MRI of pelvis
26 M	Clinic	7 mths	6 mths	Intersphincteric	No	Yes
35 M	Clinic	2.5 mths	34 mths	Intersphincteric	No	No
35 F	Clinic	10 mths	8 mths	Intersphincteric	Yes	Yes
41 M	Clinic	6 mths	21 mths	Intersphincteric	No	No
42 M	Acute	20 mths	14 mths	Intersphincteric	Yes	Yes
43 M	Clinic	4 mths	5 mths	High sphincteric	No	Yes
44 F	Clinic	14 mths	15 mths	Intersphincteric	Yes	Yes
45 M	Clinic	8 mths	20 mths	Intersphincteric	No	Yes
46 M	Acute	5 mths	20 mths	Intersphincteric	No	Yes

MRI = magnetic resonance imaging

interests and experience in coloproctology, and some of them might not be aware of or agree about the importance of the internal anal sphincter.

The long postoperative follow-up duration and the strict definition of recurrence used in this study are considered among its points of strength. Nevertheless, this study also had weaknesses. The patient cohort was small and the study was retrospective in methodology. A single experienced consultant colorectal surgeon managed these patients, and our results might not be easily reproducible without enough interest and experience in managing complex and recurrent perianal fistulas. Furthermore, in the absence of a control group, the study results were potentially subject to observer bias.

There was no change reported in incontinence after the operative procedure in our case series. This subjective assessment was performed at clinic review. A validated objective measurement of continence (such as the Cleveland Clinic Florida faecal incontinence score)⁵¹ was not undertaken. This scoring system may have detected more subtle changes in incontinence. A more precise method of assessing postoperative changes in the anal sphincter complex is to compare pre- and postprocedure anal manometry.⁵²

Despite these limitations, our results would be a useful guide for surgeons counselling patients who are keen to avoid division of any part of the anal sphincter complex during their fistula surgery.

Conclusions

Long-term follow-up of an operative strategy that routinely avoids division of any part of the anal sphincter complex has confirmed that it has a recurrence rate that compares well with other treatment modalities. These results would be useful information to provide to those patients who request during counselling and consent that no part of the sphincter complex should be divided during their surgery.

Acknowledgements

We would like to thank Mr ER MacDonald for his contribution in data collection during the early years of the study.

The material in this paper was presented as a poster at the annual meeting of the American Society of Colon and Rectal Surgeons held in Vancouver, Canada, May 2011.

References

1. On Fistulae. The Internet Classics Archive. <http://classics.mit.edu/Hippocrates/fistulae.mb.txt> (cited August 2013).
2. Parks AG, Gordon PH, Hardcastle JD. A classification of fistula-in-ano. *Br J Surg* 1976; **63**: 1–12.
3. Lunniss PJ, Kamm MA, Phillips RK. Factors affecting continence after surgery for anal fistula. *Br J Surg* 1994; **81**: 1,382–1,385.
4. Westertep M, Volkers NA, Poolman RW, van Tets WF. Anal fistulotomy between Skylla and Charybdis. *Colorectal Dis* 2003; **5**: 549–551.
5. Toyonaga T, Matsushima M, Kiri T *et al*. Factors affecting continence after fistulotomy for intersphincteric fistula-in-ano. *Int J Colorectal Dis* 2007; **22**: 1,071–1,075.
6. Marks CG, Ritchie JK, Lockhart-Mummery HE. Anal fistulas in Crohn's disease. *Br J Surg* 1981; **68**: 525–527.
7. Sainio P. Fistula-in-ano in a defined population. Incidence and epidemiological aspects. *Ann Chir Gynaecol* 1984; **73**: 219–224.
8. de la Portilla F, Rada R, Jiménez-Rodríguez R *et al*. Evaluation of a new synthetic plug in the treatment of anal fistulas: results of a pilot study. *Dis Colon Rectum* 2011; **54**: 1,419–1,422.
9. Garcia-Aguilar J, Belmonte C, Wong WD *et al*. Anal fistula surgery. Factors associated with recurrence and incontinence. *Dis Colon Rectum* 1996; **39**: 723–729.
10. Thomson JP, Ross AH. Can the external anal sphincter be preserved in the treatment of trans-sphincteric fistula-in-ano? *Int J Colorectal Dis* 1989; **4**: 247–250.
11. Parks AG, Stitz RW. The treatment of high fistula-in-ano. *Dis Colon Rectum* 1976; **19**: 487–499.
12. Goldberg SM, Garcia-Aguilar J. The Cutting Seton. In: Phillips RK, Lunniss PJ. *Anal Fistula: Surgical Evaluation and Management*. London: Chapman and Hall; 1996. pp95–102.
13. Christensen A, Nilas L, Christiansen J. Treatment of transsphincteric anal fistulas by the seton technique. *Dis Colon Rectum* 1986; **29**: 454–455.
14. Multicentric randomized controlled clinical trial of Kshaarasootra (Ayurvedic medicated thread) in the management of fistula-in-ano. *Ind J Med Res* 1991; **94**: 177–185.
15. Abbas MA, Lemus-Rangel R, Hamadani A. Long-term outcome of endorectal advancement flap for complex anorectal fistulae. *Am Surg* 2008; **74**: 921–924.

Table 2 Healing, recurrence and incontinence rates of perianal fistulas following different treatment options

Technique	Description of technique	Healing rate	Recurrence rate on follow-up	Incontinence rate
Seton (loose)	Preserve external anal sphincter integrity Part of staged fistulotomy	44% ¹⁰	20–80%	17% ¹¹
Seton (cutting/tight)	Gradual severance of anal sphincters, allowing for muscle fibrosis	100%	0%	62% ^{12,13}
Seton (chemical)	Alkalinity of chemical seton cuts through sphincter		4% ¹⁴	5% ¹⁴
Advancement flaps	Separation of fistula tract from bowel using advancement of full or partial- thickness flaps	83% ¹⁵	19% ¹⁶ –21% ¹⁷	40% ¹⁷
Fibrin glue	Glue used to occlude internal fistula tract Stimulation of fibroblast ingrowth to pro- mote healing	31–85% ¹⁸	–	0%
Anal fistula plug	Xenograft used to plug fistula tract	14–87% ¹⁹	–	0%
Ligation of intersphincteric fistula tract	Incision in intersphincteric groove to identify fistula tract Disconnection of fistula tract, followed by ligation	57% ²⁰ – 94% ²¹	17.7% ²² – 28% ²³	–
Ligation of the intersphincteric fistula tract with biological mesh insertion	Ligation of intersphincteric fistula tract with bioprosthetic mesh inserted in intersphincteric space	94% ²⁴	6% ²⁴	–
Lay-open of subcutaneous fistula tract and loose seton	As described in this article	86%	19%	0%

16. Ortiz H, Marzo M, de Miguel M *et al.* Length of follow-up after fistulotomy and fistulectomy associated with endorectal advancement flap repair for fistula in ano. *Br J Surg* 2008; **95**: 484–487.
17. van Koperen PJ, Wind J, Bemelman WA *et al.* Long-term functional outcome and risk factors for recurrence after surgical treatment for low and high perianal fistulas of cryptoglandular origin. *Dis Colon Rectum* 2008; **51**: 1,475–1,481.
18. Altomare DF, Greco VJ, Tricomi N *et al.* Seton or glue for trans-sphincteric anal fistulae: a prospective randomized crossover clinical trial. *Colorectal Dis* 2011; **13**: 82–86.
19. van Koperen PJ, Bemelman WA, Gerhards MF *et al.* The anal fistula plug treatment compared with the mucosal advancement flap for cryptoglandular high transsphincteric perianal fistula: a double-blinded multicenter randomized trial. *Dis Colon Rectum* 2011; **54**: 387–393.
20. Bleier JI, Moloo H, Goldberg SM. Ligation of the intersphincteric fistula tract: an effective new technique for complex fistulas. *Dis Colon Rectum* 2010; **53**: 43–46.
21. Rojanasakul A, Pattanaarun J, Sahakitrungruang C, Tantiphlachiva K. Total anal sphincter saving technique for fistula-in-ano; the ligation of intersphincteric fistula tract. *J Med Assoc Thai* 2007; **90**: 581–586.
22. Shanwani A, Nor AM, Amri N. Ligation of the intersphincteric fistula tract (LIFT): a sphincter-saving technique for fistula-in-ano. *Dis Colon Rectum* 2010; **53**: 39–42.
23. Ooi K, Skinner I, Croxford M *et al.* Managing fistula-in-ano with ligation of the intersphincteric fistula tract procedure: the Western Hospital experience. *Colorectal Dis* 2012; **14**: 599–603.
24. Ellis CN, Rostas JW, Greiner FG. Long-term outcomes with the use of bioprosthetic plugs for the management of complex anal fistulas. *Dis Colon Rectum* 2010; **53**: 798–802.
25. George Pinedo M, Gino Caselli M, Gonzalo Urrejola S *et al.* Modified loose-seton technique for the treatment of complex anal fistulas. *Colorectal Dis* 2010; **12**: e310–e313.
26. van Koperen PJ, Bemelman WA, Bossuyt PM *et al.* The anal fistula plug versus the mucosal advancement flap for the treatment of anorectal fistula (PLUG trial). *BMC Surg* 2008; **8**: 11.
27. Abbas MA, Jackson CH, Haigh PI. Predictors of outcome for anal fistula surgery. *Arch Surg* 2011; **146**: 1,011–1,016.
28. Boyle DJ, Knowles CH, Murphy J *et al.* The effects of age and childbirth on anal sphincter function and morphology in 999 symptomatic female patients with colorectal dysfunction. *Dis Colon Rectum* 2012; **55**: 286–293.
29. O'Connell PR. The effects of age and parity on anorectal function. *Dis Colon Rectum* 2012; **55**: 235–236.
30. Zbar AP, Khaikin M. Should we care about the internal anal sphincter? *Dis Colon Rectum* 2012; **55**: 105–108.
31. Jorge JM, Wexner SD. Etiology and management of fecal incontinence. *Dis Colon Rectum* 1993; **36**: 77–97.
32. Ommer A, Wenger FA, Rolfs T, Walz MK. Continence disorders after anal surgery – a relevant problem? *Int J Colorectal Dis* 2008; **23**: 1,023–1,031.