

PUBLISHED VERSION

Darren Foreman, Sophie A Plagakis

Splenunculi mimicking metastases in a patient with locally advanced prostate cancer

World Journal of Clinical Urology, 2016; 5(3):93

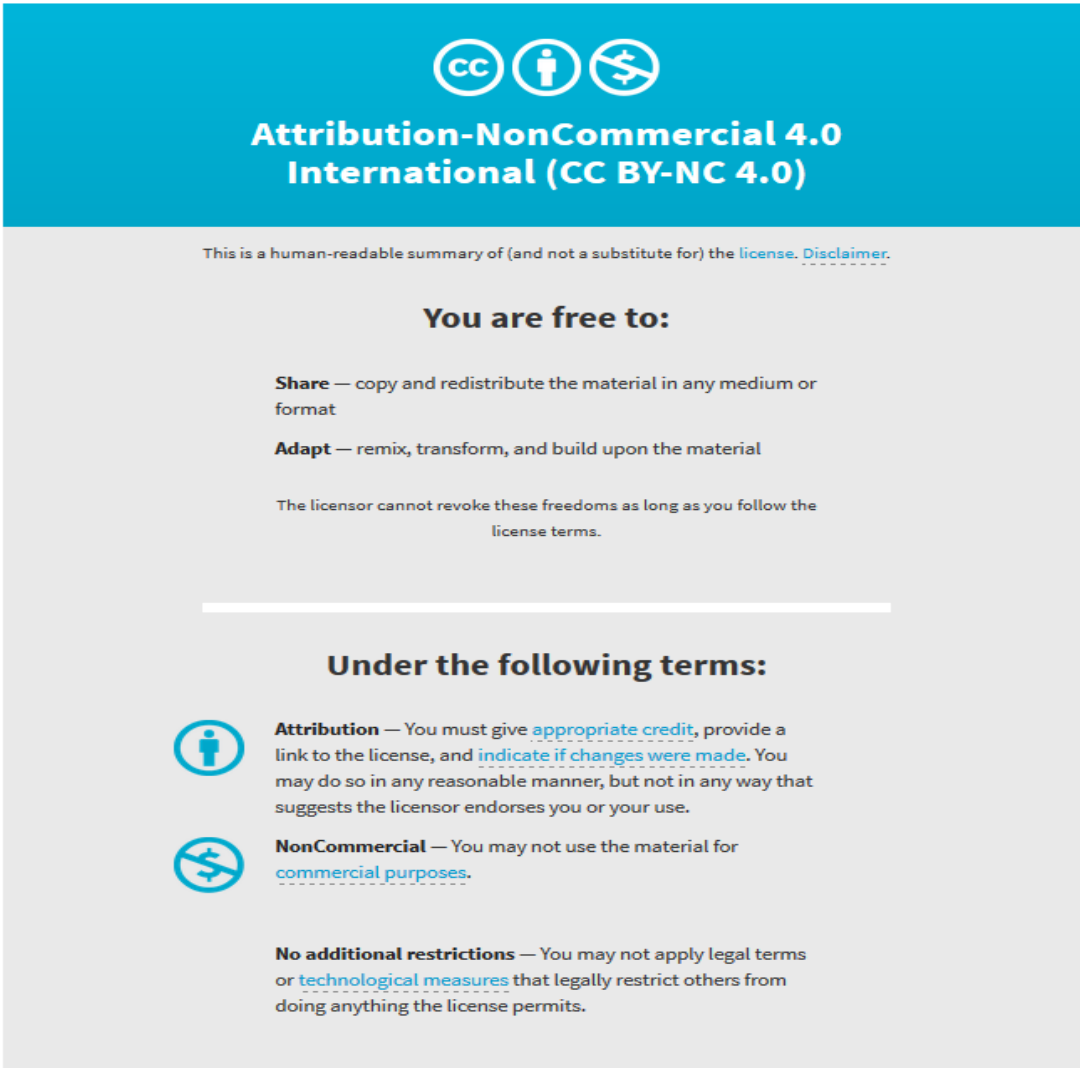
© The Author(s) 2016. Published by Baishideng Publishing Group Inc. All rights reserved. This article is an open-access article which was selected by an in-house editor and fully peer-reviewed by external reviewers. It is distributed in accordance with the Creative Commons Attribution Non Commercial (CC BY-NC 4.0) license, which permits others to distribute, remix, adapt, build upon this work non-commercially, and license their derivative works on different terms, provided the original work is properly cited and the use is non-commercial. See: <http://creativecommons.org/licenses/by-nc/4.0/>

Originally published at:

<http://doi.org/10.5410/wjcu.v5.i3.93>

PERMISSIONS

<http://creativecommons.org/licenses/by-nc/4.0/>



The image shows the Creative Commons Attribution-NonCommercial 4.0 International (CC BY-NC 4.0) license graphic. It features a blue header with the CC logo, a person icon, and a crossed-out dollar sign icon. Below the header, the text reads: "Attribution-NonCommercial 4.0 International (CC BY-NC 4.0)". A disclaimer states: "This is a human-readable summary of (and not a substitute for) the license. [Disclaimer.](#)". The main content is divided into two sections: "You are free to:" and "Under the following terms:". Under "You are free to:", it lists "Share" (copy and redistribute) and "Adapt" (remix, transform, and build upon). A note states: "The licensor cannot revoke these freedoms as long as you follow the license terms." Under "Under the following terms:", it lists "Attribution" (give appropriate credit, provide a link, and indicate if changes were made) and "NonCommercial" (do not use for commercial purposes). A final note states: "No additional restrictions" (do not apply legal terms or technological measures that restrict others).

This is a human-readable summary of (and not a substitute for) the [license](#). [Disclaimer.](#)

You are free to:

Share — copy and redistribute the material in any medium or format

Adapt — remix, transform, and build upon the material

The licensor cannot revoke these freedoms as long as you follow the license terms.

Under the following terms:

Attribution — You must give [appropriate credit](#), provide a link to the license, and [indicate if changes were made](#). You may do so in any reasonable manner, but not in any way that suggests the licensor endorses you or your use.

NonCommercial — You may not use the material for [commercial purposes](#).

No additional restrictions — You may not apply legal terms or [technological measures](#) that legally restrict others from doing anything the license permits.

27 June 2017

<http://hdl.handle.net/2440/106040>

Splenunculi mimicking metastases in a patient with locally advanced prostate cancer

Darren Foreman, Sophie A Plagakis

Darren Foreman, Department of Urology, Flinders Medical Centre, Flinders University, Adelaide, SA 5042, Australia

Darren Foreman, Discipline of Surgery, Adelaide University, Adelaide, SA 5000, Australia

Sophie A Plagakis, Department of Urology, Royal Adelaide Hospital, Adelaide, SA 5000, Australia

Author contributions: This manuscript was drafted by both Foreman D and Plagakis SA, with the final revisions being made by Plagakis SA.

Institutional review board statement: This case report was exempt from the Institutional Review Board standards at Flinders University.

Informed consent statement: The patient gave informed verbal consent for the use of his medical details in this publication.

Conflict-of-interest statement: There were no conflicts of interest in this study.

Open-Access: This article is an open-access article which was selected by an in-house editor and fully peer-reviewed by external reviewers. It is distributed in accordance with the Creative Commons Attribution Non Commercial (CC BY-NC 4.0) license, which permits others to distribute, remix, adapt, build upon this work non-commercially, and license their derivative works on different terms, provided the original work is properly cited and the use is non-commercial. See: <http://creativecommons.org/licenses/by-nc/4.0/>

Manuscript source: Invited manuscript

Correspondence to: Darren Foreman, Consultant Urologist, Department of Urology, Flinders Medical Centre, Flinders University, Flinders Drive, Bedford Park, Adelaide, SA 5042, Australia. dforeman@sturology.com.au
Telephone: +61-08-82045511
Fax: +61-08-82045450

Received: July 19, 2016
Peer-review started: July 21, 2016
First decision: September 5, 2016

Revised: September 21, 2016

Accepted: October 22, 2016

Article in press: October 24, 2016

Published online: November 24, 2016

Abstract

A 61-year-old man with locally advanced prostate cancer was found to have multiple solid intra-abdominal solid lesions during staging investigations. While some were in the pelvis, they were not located in the common landing sites for prostate cancer metastases, and his prostate specific antigen was not significantly elevated to suggest a high burden of metastatic disease. He reported a history of a blunt abdominal trauma due to a motor vehicle accident more than forty years ago which had been conservatively managed. His staging imaging revealed a lack of a discrete spleen in his left upper abdomen and this raised the suspicion that these solid lesions may represent ectopic splenic tissue. Imaging with nuclear medicine scintigraphy confirmed the lesions in his upper abdomen and pelvis to be splenunculi. He proceeded with a combination of androgen deprivation therapy and external beam radiotherapy for locally advanced, non-metastatic prostate cancer. Although it has been described in patients with low risk prostate cancer, this is the first case report of splenunculi mimicking metastases in a patient with locally advanced prostate cancer.

Key words: Prostate cancer; Splenosis; Metastasis; Locally advanced; Splenunculus

© **The Author(s) 2016.** Published by Baishideng Publishing Group Inc. All rights reserved.

Core tip: The appearance of ectopic splenic tissue in the abdomen and other body cavities can mimic that of solid tissue tumours and metastases. Splenosis may occur following blunt abdominal trauma during which a splenic

injury may or may not have been identified and is rarely symptomatic. Being aware of this unusual differential diagnosis may avoid anxiety for patients and allow early diagnosis. Nuclear medicine scintigraphy with Tc-99m is the imaging modality of choice to confirm splenunculi.

Foreman D, Plagakis SA. Splenunculi mimicking metastases in a patient with locally advanced prostate cancer. *World J Clin Urol* 2016; 5(3): 93-96 Available from: URL: <http://www.wjgnet.com/2219-2816/full/v5/i3/93.htm> DOI: <http://dx.doi.org/10.5410/wjcu.v5.i3.93>

INTRODUCTION

Spleno-sis is the autotransplantation of splenic tissue and formation of scattered tissue deposits secondary to abdominal trauma or splenectomy. It is a benign condition that is generally asymptomatic with a reported incidence of up to 67% of people who have sustained an abdominal injury^[1,2]. Due to increasing rates of abdominal imaging, these cases are now seen more often and the unexpected findings have been mistaken for metastatic disease and hepatoma, as reported in the literature.

CASE REPORT

We present a case of a 61-year-old man with newly diagnosed locally advanced, high risk prostate cancer, with multiple intra-abdominal masses initially mistaken for metastatic disease. This patient was referred to a Urologist with a prostate specific antigen (PSA) of 6.6 ng/mL. He had no significant medical or family history, apart from being involved in a motor vehicle accident at 18 years of age. The accident involved side impact, and he spent three days in hospital for observation but did not undergo surgery. There was no imaging available from that previous admission.

Digital rectal examination found a generally firm and suspicious feeling prostate gland, and trans-rectal ultrasound (TRUS) showed no hypoechoic lesions. TRUS guided prostate biopsy was performed and revealed a large volume of Gleason 4 + 3 = 7 disease occupying 80%-90% of all cores. The specimen from the right base showed extra-prostatic extension of disease, confirming pathological staging as T3.

Staging investigations included a computed tomography (CT) scan of the abdomen and pelvis, whole body bone scan (WBBS) and magnetic resonance imaging (MRI) of the pelvis. WBBS did not reveal any bony abnormalities or metastases. CT showed a 2.4 cm lesion between the liver and right kidney and a 3.4 cm lesion between the bladder and rectum, just superior to the seminal vesicles (Figure 1). The lesions were solid and enhanced with intravenous contrast. There was no discrete spleen in the left upper quadrant, however multiple small lesions lay in this region measuring up to 2 cm in diameter each (Figure 2). There was no pelvic or para-aortic lymphadenopathy

present. MRI demonstrated disease within the prostate and no gross extraprostatic extension was present. The MRI clearly displayed the pelvic lesion superior to the seminal vesicles, which was not attached to surrounding structures.

Due to suspicion of ectopic splenic tissue, a heat-damaged radioisotope-labelled red cell scan (99mTc) was performed. All of the lesions seen on CT demonstrated intense tracer uptake and confirmed the presence of multiple intra-abdominal splenunculi (Figure 3), and excluded abdominal metastatic disease.

Following discussion of treatment options for locally advanced, high risk, non metastatic prostate, the patient elected to undergo external beam radiotherapy in combination with 24 mo of androgen deprivation therapy (ADT).

A PSA rise occurred 21 mo after ADT finished, and the patient required intermittent ADT since then. It has been 8 years since diagnosis and the patient is currently off ADT with no metastatic disease on cross sectional imaging and has a PSA of 0.8 ng/mL.

DISCUSSION

Spleno-sis is believed to result from the spillage of cells from the splenic pulp during surgical manipulation or following splenic injury. It is reported to develop over an average of 10 years following the insult, and is more common following trauma than iatrogenic causes^[3].

The cells can implant in any other location and take their blood supply from surrounding structures; spleno-sis has been reported as intrathoracic where there is a concomitant diaphragmatic injury or intra-hepatic following an emergency splenectomy for trauma^[4,5]. The pathogenesis is generally accepted to be mechanical implantation of cells, however there are case reports of intracranial splenic deposits from purported haematological spread^[6].

Whilst it is assumed to be functional splenic tissue, spleno-sis usually does not have the histological appearance of normal spleen, nor does it form a hilum or a mature capsule. Patients are rarely symptomatic and the condition is most often discovered incidentally on abdominal imaging.

This is distinct from an accessory spleen which is congenital and arises from the left side of the dorsal mesogastrium. These deposits are usually found in the region of the gastrosplenic ligament or splenopancreatic ligaments, commonly solitary, and if multiple hardly ever exceed six. They are histologically and functionally normal splenic tissue and usually have their own blood supply derived from the splenic artery. They are also usually asymptomatic, but there have been reports of torted accessory spleens and migratory deposits on long vascular pedicles.

The most useful imaging modality by far for investigation of spleno-sis is nuclear medicine scintigraphy. This can be performed using the agents Technetium-99 sulphur colloid, Technetium-99 heat-damaged erythrocytes

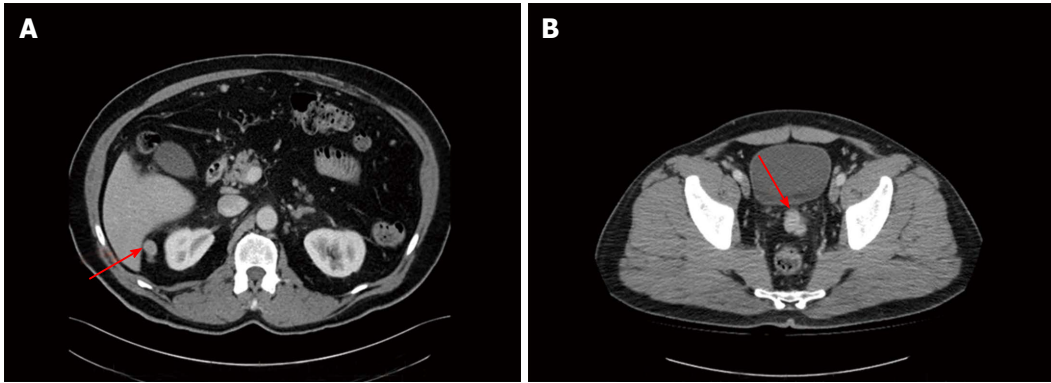


Figure 1 Axial computed tomography image of the abdomen. A: Red arrow pointing to soft tissue mass in between liver and right kidney; B: Red arrow pointing to soft tissue mass between bladder and rectum.

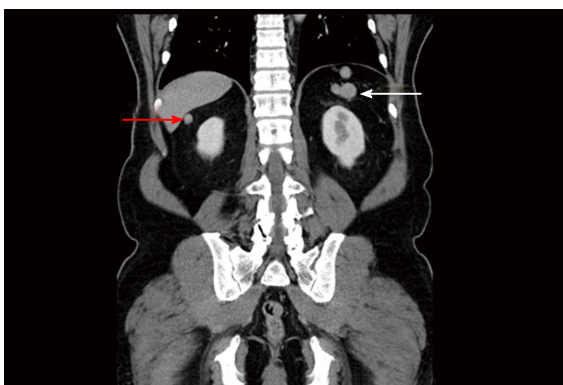


Figure 2 Coronal computed tomography image of the pelvis. White arrow pointing to nodular soft tissue mass in left upper quadrant, where discrete spleen was not visualised; red arrow pointing to soft tissue mass beneath liver.

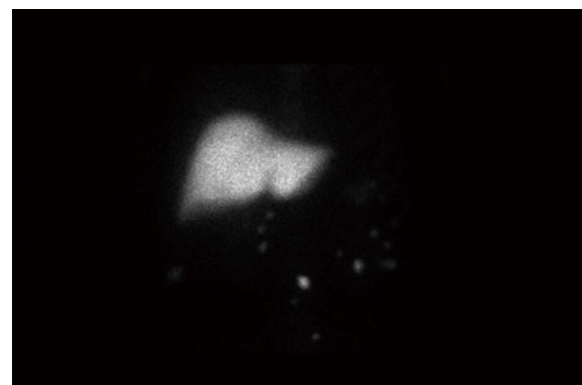


Figure 3 Nuclear scintigraphy image of this patient demonstrating uptake in the ectopic tissue seen in the pelvis and beneath the liver on the computed tomography images, confirming they are ectopic splenic tissue. Liver shows normal tracer uptake.

or Indium-111 labelled platelets. These agents are widely distributed in the reticuloendothelial system including the liver, bone marrow and spleen. Tc-99m and In-111 labelled platelets are the most sensitive and specific agents for the detection of ectopic splenic tissue^[7,8]. If nuclear scintigraphy is not available or conclusive, the option of percutaneous biopsy of the masses can be pursued but this is often challenging given the varying size and location of the masses.

Multiple published case reports describe the initial misdiagnosis of splenosis as solid tumours, metastases or recurrences for breast, renal, colorectal and hepatocellular cancers, to name a few^[9-12].

Prostate cancer has been reported once in the literature in this context, in a patient with low grade disease that should not have undergone further imaging according to staging guidelines^[13]. This is the first report of splenosis in a patient with high risk prostate cancer.

The presence of splenosis following blunt abdominal trauma is under-recognised and, due to its indolent clinical nature, is usually discovered incidentally years later when it is mistaken for malignant disease. This is the first case report of it appearing in the context of high risk, locally advanced prostate cancer. A heat labelled red cell scan is a sensitive and definitive imaging modality for diagnosis. Early consideration of splenosis and diagnostic

confirmation is essential to ensuring appropriate care is instituted in each clinical scenario.

COMMENTS

Case characteristics

Soft tissue masses in the context of newly diagnosed prostate cancer.

Clinical diagnosis

Splenunculi.

Differential diagnosis

Metastatic prostate cancer.

Laboratory diagnosis

Routine bloods only, no biopsy was required.

Imaging diagnosis

Technetium-99 scan confirmed splenunculi.

Pathological diagnosis

Ectopic splenic tissue.

Related reports

Multiple other case reports have indicated this differential diagnosis in the staging of many other cancers, but not locally advanced prostate cancer.

Term explanation

Splenuosis is the condition related to ectopic splenic tissue formed as a result of trauma. Accessory spleen is a congenital condition.

Experiences and lessons

One must consider the differential of ectopic splenic tissue in a patient post abdominal trauma, with no discernible spleen, if their soft tissue masses are out of keeping with their expected cancer staging. Technetium-99 scans are the most accurate for assessment of splenic tissue.

Peer-review

This is the first case report of splenunculi mimicking metastases in a patient with locally advanced prostate cancer presented by Foreman D and Plagakis SA. Overall, the case report is quite interesting, well organized and written according to the journal's style. The language is satisfactory and the figures quite interesting.

REFERENCES

- 1 **De Vuysere S**, Van Steenberg W, Aerts R, Van Hauwaert H, Van Beckevoort D, Van Hoe L. Intrahepatic splenosis: imaging features. *Abdom Imaging* 2000; **25**: 187-189 [PMID: 10675464 DOI: 10.1007/s002619910042]
- 2 Case records of the Massachusetts General Hospital. Weekly clinicopathological exercises. Case 29-1995. A 65-year-old man with mediastinal Hodgkin's disease and a pelvic mass. *N Engl J Med* 1995; **333**: 784-791 [PMID: 7643887 DOI: 10.1056/NEJM199509213331208]
- 3 **Fleming CR**, Dickson ER, Harrison EG. Splenosis: autotransplantation of splenic tissue. *Am J Med* 1976; **61**: 414-419 [PMID: 961705 DOI: 10.1016/0002-9343(76)90380-6]
- 4 **Normand JP**, Rioux M, Dumont M, Bouchard G, Letourneau L. Thoracic splenosis after blunt trauma: frequency and imaging findings. *AJR Am J Roentgenol* 1993; **161**: 739-741 [PMID: 8372748 DOI: 10.2214/ajr.161.4.8372748]
- 5 **Abu Hilal M**, Harb A, Zeidan B, Steadman B, Primrose JN, Pearce NW. Hepatic splenosis mimicking HCC in a patient with hepatitis C liver cirrhosis and mildly raised alpha fetoprotein; the important role of explorative laparoscopy. *World J Surg Oncol* 2009; **7**: 1 [PMID: 19123935 DOI: 10.1186/1477-7819-7-1]
- 6 **Rickert CH**, Maasjosthusmann U, Probst-Cousin S, August C, Gullotta F. A unique case of cerebral spleen. *Am J Surg Pathol* 1998; **22**: 894-896 [PMID: 9669351 DOI: 10.1097/00000478-199807000-00011]
- 7 **Tsitouridis I**, Michaelides M, Sotiriadis C, Arvaniti M. CT and MRI of intraperitoneal splenosis. *Diagn Interv Radiol* 2010; **16**: 145-149 [PMID: 19838993 DOI: 10.4261/1305-3825.DIR.1855-08.1]
- 8 **Dokal IS**, Deenmamode M, Lewis SM. Detection and functional assessment of accessory splenic tissue (splenunculi) with radiolabelled heat damaged autologous erythrocytes. *Clin Lab Haematol* 1990; **12**: 387-393 [PMID: 2081379 DOI: 10.1111/j.1365-2257.1990.tb00350.x]
- 9 **Froehner M**, Leike S, Manseck A, Haase M, Wirth MP. Splenunculus mimicking late local recurrence of renal cell carcinoma. *Scand J Urol Nephrol* 1998; **32**: 418-419 [PMID: 9925009 DOI: 10.1080/003655998750015232]
- 10 **Basu S**, Ray AK, Banerjee S. Splenunculus masquerading as colonic malignancy. *Int Surg* 2003; **88**: 181-183 [PMID: 14717521]
- 11 **Foroudi F**, Ahern V, Peduto A. Splenosis mimicking metastases from breast carcinoma. *Clin Oncol (R Coll Radiol)* 1999; **11**: 190-192 [PMID: 10465475 DOI: 10.1053/clon.1999.9040]
- 12 **Liu Y**, Ji B, Wang G, Wang Y. Abdominal multiple splenosis mimicking liver and colon tumors: a case report and review of the literature. *Int J Med Sci* 2012; **9**: 174-177 [PMID: 22359484 DOI: 10.7150/ijms.3983]
- 13 **Li H**, Snow-Lisy D, Klein EA. Hepatic splenosis diagnosed after inappropriate metastatic evaluation in patient with low-risk prostate cancer. *Urology* 2012; **79**: e73-e74 [PMID: 22119260 DOI: 10.1016/j.urology.2011.09.041]

P- Reviewer: Gofrit ON, Goluboff ET, Koukourakis GV

S- Editor: Ji FF **L- Editor:** A **E- Editor:** Li D





Published by **Baishideng Publishing Group Inc**

8226 Regency Drive, Pleasanton, CA 94588, USA

Telephone: +1-925-223-8242

Fax: +1-925-223-8243

E-mail: bpgoffice@wjgnet.com

Help Desk: <http://www.wjgnet.com/esps/helpdesk.aspx>

<http://www.wjgnet.com>

