



Title	Therapeutic strategies for etiologies in the oral and maxillofacial regions
Author(s)	Tei, Kanchu; Ohiro, Yoichi; Matsusita, Kazuhiro; Matsuzawa, Yusuke; Satoh, Kazuyo; Yamada, Tamaki
Citation	北海道歯学雑誌, 38(Special issue), 151-156
Issue Date	2017-09
Doc URL	<a href="http://hdl.handle.net/2115/67355">http://hdl.handle.net/2115/67355</a>
Type	article
File Information	22_Kanchu Tei.pdf



[Instructions for use](#)

# Therapeutic strategies for etiologies in the oral and maxillofacial regions

Kanchu Tei, Yoichi Ohiro, Kazuhiro Matsusita, Yusuke Matsuzawa, Kazuyo Satoh  
and Tamaki Yamada

Oral and Maxillofacial Surgery, Department of Oral Pathobiological Science, Faculty of Dental Medicine and Graduate school of Dental Medicine, Hokkaido University

**ABSTRACT** : In this paper we describe our strategies for treatment of oral cancer, jaw deformity, and odontogenic tumors. Details of the strategy for cleft palate is introduced in a separate report, by Professor Mikoya. Newly applied strategies for patients with post-surgical swallowing dysfunction and dentoalveolar surgery are also introduced. Oral cancer, jaw deformity, cleft, and odontogenic tumors are the main etiologies in the oral and maxillofacial region.

Early stages of oral cancer (StageI and StageII) are mainly treated with surgery or radiotherapy alone, and the 5-year survival rate is 80 to 90%. With advanced oral cancer (StageIII and StageIV) a combination of chemotherapy and radiotherapy with or without surgery is the norm, but the 5-year survival rate is below 50% overall. Therefore, there is a need for an effective combination of therapies for advanced oral squamous cell carcinomas.

The treatment goal for jaw deformities is to achieve a functional and desirable occlusion. To achieve desirable occlusion, treatment by the team approach is introduced, it includes oral and maxillofacial surgeons, orthodontists, and prosthodontists. A unique method, termed the "Dredging Method" is used in the treatment strategies of odontogenic tumors. The method was introduced to remove all of the tumor and restore the form and function of the jaw through bone generation. The Dredging Method involves four steps: Deflation, Enucleation, Dredging, and Follow up.

Tooth autotransplantation in our department stands out in comparison with other facilities in the field of dentoalveolar surgery. The annual number of cases exceeds 150, and up to December of 2015 the total number of cases reached 1,100. The 5-year survival rate for cases with transplanted third molars to the molar region is 86%. Post-surgical swallowing dysfunction is strongly dependent on the extent of the surgery and type of reconstruction. Here, post-surgical swallowing dysfunction can be accurately predicted prior to the surgery, and to develop plans for individual rehabilitation programs to overcome post-surgical swallowing dysfunction is crucial.

**Key Words** : oral cancer, jaw deformity, odontogenic tumors, post-surgical swallowing dysfunction, dentoalveolar surgery

## 1. Oral Cancer

To improve clinical outcomes for cancer patients is the highest priority. The following will provide a brief summary of how this is managed at our hospital with our protocols for locally advanced oral cancer patients. Recently noted characteristics of oral cancer are also discussed.

The main point of multidisciplinary treatment of oral cancers is the constant annual focus. Hokkaido University

Hospital is approved and registered as a "Regional Cancer Hospital" by the government of Japan. This designation is approved under the second Basic Plan to promote Cancer Control Programs of the Ministry of Health, Labour and Welfare. One of the missions of our hospital is to provide the best professional care to cancer patients.

Based on this Program, the optimal treatment plan for each patient must be discussed in a cancer board established for specific organs. Oral surgeons, otorhinolaryngologists, radiotherapists, medical

---

### Address of Correspondence

Kanchu Tei, DDS, PhD.

Oral and Maxillofacial Surgery, Department of Oral Pathobiological Science, Faculty of Dental Medicine and Graduate school of Dental Medicine, Hokkaido University, Kita 13, Nishi 7, Kita-ku, Sapporo, 06-8586, Japan

TEL/FAX : +81-11-706-4283 ; E-mail : teik@den.hokudai.ac.jp

oncologists, and qualified nurses are required to be members of the cancer board for head and neck cancers. In order to provide a high quality cancer care, the oral cancer team of our department is composed of oral surgeons certified as General Clinical Oncologists by the Japanese Board of Cancer Therapy. Generally, the treatment plan for a patient is discussed and decided by following the NCCN guidelines.

For locally advanced resectable oral cancer patients, however, we conduct a regimen of concurrent chemoradiotherapy before the planned surgery. This protocol was developed in our department more than ten years ago. Patients with oral squamous cell carcinomas diagnosed as stage III and IV are administered weekly docetaxel and daily cisplatin intravenously simultaneous with radiotherapy. This protocol significantly improved clinical outcomes of locally advanced oral cancer patients. Adverse events which have developed under this regimen are mucositis and myelosuppression, but all of these events have been controlled and eliminated in a matter weeks, having allowed all affected patients to undergo the planned surgery. Last year (2016), our department participated in a domestic multicenter retrospective study, and presented data at the Congress of the Japanese Society for the Oral and Maxillofacial Surgeons. In that presentation, the data from 430 oral cancer patients, almost all at Stage III and IV showed a 71.3% in overall survival rate and better than 80% locoregional control.

The better outcomes for oral cancer patients are also achieved by the reconstruction with vascularized free flaps to close off the resected defect. In past years, local pedicle flaps, such as the DP- or PMMC-flaps were used for primary closure. The application of vascularized free flaps have extended the limitations of resection by its extensive application. In our department, anastomosis is performed by plastic surgeons with favorable results. Before the operation, oral and plastic surgeons discuss details of the operation plan which considers the patient condition and the precise volume of the defect in the jaw and soft tissue after resection. The main topic of this discussion is focused on the loss of function by resection and restoration of function after reconstruction. This is a very important procedure to create unity of purpose and avoid confusion during the operation.

Japan is world-leading in the rapidity of aging of society. Recently, elderly cancer patients, above eighty or ninety years of age, are increasing in number, nationwide (Fig. 1).

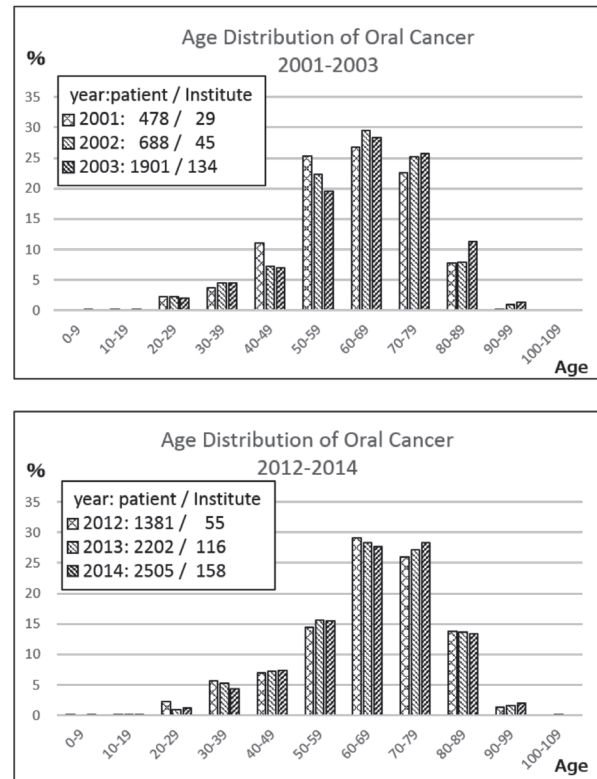


Fig. 1 Changes in age distribution of oral cancer patients in Japan

The peak of morbidity of oral cancer patients in Japan has shifted from the 50's to the 60's in recent years. Data is adapted from the Japan Society for Head and Neck Cancer, Report of the Head and Neck Cancer Registry of Japan, 2016. Age distribution of Oral Cancer patients X2

Data from the Japan Society for Head and Neck Cancer show that the peak of morbidity of oral cancer was the ages of 50s to 70s 15 years ago, and recent data shows that the peak has shifted to the 60s and 70s. We must be aware of the slight increase in the number of patients in their 80s. The clinical issues of older patients is the decreased operability due to lower Performance Status or dementia related disorders. Especially in advanced cases where the patient is able to tolerate radical surgery, it is difficult for patient and family to accept post-operative oral dysfunction. Early cancer discovery does not give rise to severe dysfunction even with patients undergoing surgery. Unfortunately most Japanese show low interest in oral hygiene, and many patients only visit dental clinics or hospitals when they have difficulties with advanced cancer. This is also the case for the younger generations however. Both a change in health awareness of all nations and early detection of oral cancer by dentists are important elements to be able to decrease advanced cancer incidence and to improve clinical outcomes.

## 2. Jaw deformity

At the early period of orthognathic surgery in Hokkaido University, the profile approach aiming to make aesthetic improvements was generally performed in Europe. Orthodontic treatment was only secondarily taken into consideration, if necessary and following the surgery. No braces were attached to the teeth during surgery, it was an era when the facial profile attracted much more interest than occlusion. The concept of preoperative orthodontic treatment was hardly considered. However, functional improvement was not necessarily accomplished by the aesthetic improvement alone and, importantly, the level of aesthetic satisfaction was different for different individuals. It is not governed by objective rules and standards. We were of the opinion that facial structure was originally created for functionality and functional improvement would certainly bring about aesthetic improvements which would be unique to an individual. Then, over time we have created our own team to achieve a desirable and functional approach. Different from conventional team or cooperative approaches, focusing on only orthognathic surgery governed by oral surgeons and orthodontists as practiced at other institutes, prosthodontists were recruited for the cooperative work we aimed to accomplish in accordance with the well-known proverb by Pichler "Keine Kieferprothese, ohne Kieferchirurgie". To reproduce the dynamics of unique jaw movements *ex vivo*, face-bow transfer has been carried out and a semi-adjustable articulator has been introduced in every case since the first surgery case treated here. This was in addition to the introduction of preoperative orthodontic treatment. The use of this procedure increased the accuracy of reproducibility remarkably and has been closely related to post-operative stability stability. The approach has been validated using postoperative cephalometrics determined sequentially for years after the surgery.

We have long considered what stability consists in and how stability should be achieved, and a range of approaches have been introduced without sacrificing even a single tooth. The concept of occlusion has become elaborated and finally defined as Desirable Occlusion (DO), comprised of the following three conditions ; 1) Maximum intercuspal position to be the centric occlusal position ; 2) Lateral guidance to be achieved at the lateral teeth ; and 3) Anterior guidance to be achieved at the anterior teeth.

These are very simple rules but have a very significant meaning. Every treatment should be carried out to achieve the establishment of functional occlusion based on these three conditions. The precise treatment plan should be developed from very detailed discussion and from the start of the planning, the treatment goals should be shared by all staff concerned.

In the surgical intervention, and for a number of reasons, formerly the targeted jaw was mainly the mandible and an acceptable, favorable treatment could not be carried out on the most severe cases. At present however, double jaw surgery in even combination with multiple segmentation of the maxilla is commonly and conventionally performed. The more complicated the surgery is, the more important the contribution of the prosthodontists become. An accurate evaluation of the expected post-operative occlusion and final goals in conjunction with measurements of the movement of the segments, confirming whether all is within the appropriate range, enables a reliable establishment of a functional occlusion which satisfies the original DO of the patient. With the progress of the team approach, surgical accuracy and post-operative stability have been steadily improving. Even in these circumstances, we do not adopt surgical intervention if teeth can be moved and a desirable occlusion can be obtained by ordinary orthodontic treatment alone. We strongly believe that surgical intervention should be applied only when modalities other than surgery are entirely unable to control the unfavorable conditions.

At present, the number of surgery cases is about 30 a year but it reached just under 100 some years ago. The numbers are actually decreasing recently, but we are entirely comfortable with accumulating credit for successful results rather than increasing the number of cases of surgery.

Patients who have a single and bi-maxillary jaw procedure can expect an average duration of operation of about 2-3 hours and 6-8 hours, respectively, and one week of hospitalization irrespective of the osteotomy modalities. The length of hospitalization has shortened year by year and immediate restoration functioning has been also achieved. This is mainly due to the care and attention shown in the planning and the lowered risk brought about by the surgery with the team approach.

### 3. Odontogenic tumors

Odontogenic tumors (OTs) are growths originating in epithelial and/or ectomesenchymal elements of the tooth-forming apparatus. The World health organization (WHO) published the first edition of the “Histological Typing of Odontogenic Tumors” in 1971, and the second edition in 1992. The latter was widely cited as it reported a large series or isolated cases of OTs. However, due to the diversity of OTs, there is still much controversy concerning the classification, terminology, and diagnosis of these lesions. In 2005, the third edition of the WHO histological type assignment of OTs was published with definitions of some pathological entities changed. The fourth edition was published in 2017. Odontogenic cysts which were eliminated from the third edition were re-included in the fourth edition as well as other unique related conditions of the jaws were added. The most controversial decision in the 2017 classification was to move keratocystic odontogenic tumors back into the cyst category as odontogenic keratocysts (OKC). Despite the 2017 classification, we should keep in mind that ameloblastomas and OKC which are most common among OTs, show a higher infiltrative potential, rate of recurrence, and prevalence compared to other odontogenic neoplasms.

Either of conservative or aggressive surgery is selected in the treatment, considering the clinical background and pathological characteristics of the tumors. In the case of large lesions, surgeons will often select aggressive surgery, marginal or segmental resection of the mandible or maxilla. Cases with jaw resection, including the condyle and/or wide anterior region are associated with a wide range of complications: loss of jaw bone support, deformity, dysfunction, and psychological distress even after reconstruction. The morphological changes of the oral cavity are directly related to the oral function including all of mastication, swallowing, speech, and facial esthetics. To avoid these disadvantages, a less traumatic and conservative approach can be useful in some cases of OTs. Various conservative treatments include simple enucleation with or without curettage, or marsupialization have been developed. Overall oral surgeons must be able to make the choice of the most suitable treatment from among the various treatments giving proper consideration to the age of the patient, location, nature, and extent of the diseased parts.

In our department, we have employed a unique

method, termed the “Dredging Method” since 1973. This method aims to remove all of the tumor and restore the form and function of the jaw through bone generation. The Dredging Method involves four steps : Deflation, Enucleation, Dredging, and Follow up. Deflation is the first step where a portion of the overlying bone and the cystic wall are removed. It is important to release the intracystic pressure and create a single undivided bony cavity. Enucleation is the second step, here the whole of the cystic wall is removed together with the surrounding bone tissue. Dredging is the third step, and here the scar tissue covering the bone surface and the surrounding bone tissue is removed. This step is performed repeatedly to accelerate new bone formation and to remove all of tumor cell remnants in the dredged out scar tissue, repeated at intervals of two to three months. After these steps including the deflation, enucleation, and dredging are satisfactorily completed, the bony cavity is kept open for about three months until the open wound is closed. It is crucial to preserve the periosteum in these three steps to allow the periosteum to restore the bone form. If the periosteum has been damaged, the tumor will spread over the periosteum and recur at the surroundings of the site. If this happens it is difficult to remove all of the newly developing tumor cells.

Ameloblastomas and OKC are known to occur most commonly at the site of the lower molars. The teeth involved in Ameloblastomas or OKC are almost always extracted because recurrence commonly occurs around the teeth. Recently, utilizing a “modified-Dredging Method”, we aim to preserve both the jawbone and the teeth involved in Ameloblastomas and OKC.

### 4. Dentoalveolar surgery

Dentoalveolar surgery was originally used originated in pre-prosthetic surgery, and has developed from there. It is a field of surgery that makes it possible to improve the oral functions such as mastication, speech, and swallowing. A number of surgical techniques were performed to use improved prostheses in Europe and America from the 1970s, and later, the development and use of dental implants greatly changed current dentistry. Dentoalveolar surgery was also greatly changed by the introduction of dental implants. The number of cases and variations in dentoalveolar surgery related to implants have increased in our hospital during these recent ten years. The surgical operation with the largest increase is

bone augmentation for dental implants. The developed bone harvesting procedures and implant fixation methods have enabled accurate predictions of bone augmentation and improved the results of the surgery. Previously the grafted bone was harvested from the ilium only, while now it is harvested from almost all parts of the jaw bone. We have performed a clinical study of the use of autogenous demineralized dentin as a transplant material in the past several years where we have adopted bone grafts such as veneer graft, onlay graft, saddle graft and sinus lift in addition to distraction osteogenesis.

In addition, dentoalveolar surgery is not only used in the treatment of hard tissue, it is also used in the treatment of soft tissue around dental implants, one example of this is vestibuloplasty using palatal mucosal grafts.

Further, our department stands out among other facilities in the field of tooth autotransplantation. The annual number of cases treated is above 150, and the total number of cases reached 1,100 as of Dec. 2016. The 5 year survival rate in the case of transplanted third molars to the molar region is 86% which shows the high standards achieved here. Dentoalveolar surgery has accomplished rapid progress in these latest 10 years in our department, but this field is becoming increasingly important and will expand in the dentistry of the future.

## 5. Post-operative Swallowing dysfunction in patients with Oral Cancer

We have conducted videofluoroscopic evaluations of 100 patients with dysphagia annually (Fig.2). About 80 to 90 % of these have been oral cancer patients.

Postsurgical oromandibular defects have been restored using microvascular free flaps with high rates of success. Nevertheless, the impairment of postsurgical functions, including articulation, mastication, and swallowing has remained an issue for such patients. Our strategy for post-operative swallowing dysfunction in patients with oral cancer can briefly be described as follows.

We perform pre-operative counseling 1-2 weeks before the surgery and inform the patients of the details of the likely functional outcome of the surgery. And we also instruct the patients in pre-operative exercises such as the "Cough Out Exercise" and "Supraglottic Swallowing" at this time. The "Cough Out Exercise" involves coughing forcefully to maintain the airway free of secretions. "Supraglottic Swallowing" is designed to close the airway

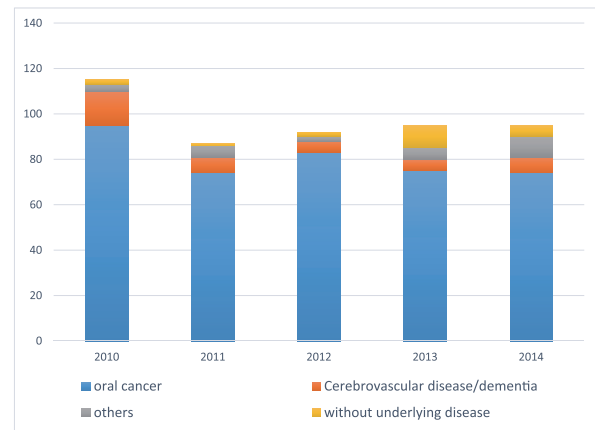


Fig. 2 Number of patients undergoing the VF exam by year at department of oral and Maxillofacial Surgery and Oral medicine, Hokkaido University Hospital.

About 80 to 90 % of these have been oral cancer patients.

at the level of the true vocal folds before and during swallowing. We ask that these exercises be resumed immediately after the surgery and continued during the whole period of the treatment.

Pre-operative videofluoroscopic evaluation is useful to know details of the basic swallowing function of the patient and allows the patient to understand the mechanism of post-operative swallowing dysfunctions by viewing the images. A videoendoscopic evaluation is also useful as it can provide a superior view of the pharyngeal anatomy, including the relationship between the epiglottis, airway entrance, valleculae, aryepiglottic folds, and piriform sinus. Endoscopy does not visualize the oral stage of swallowing, or the moment when the pharyngeal swallow trigger causes the pharynx to close around the endoscopic tube, blocking the image during the swallowing. An advantage of this evaluation is that it does not give rise to radiation exposure.

After the surgery, the post-operative swallowing function of the patients is assessed in several ways including a videofluoroscopic evaluation which allows the patient to initiate the rehabilitation to improve the oropharyngeal function soonest possible. Before the surgical procedures some issues have to be resolved, an early removal of the tracheal tube promotes early initiation of post-operative exercises of the swallowing dysfunction. Stretching exercises of the neck, shoulder and upper extremity dysfunction after neck dissections are also helpful to improve the swallowing function.

Exercises and practice to deal with post-operative swallowing dysfunction may be roughly divided into two approaches, indirect and direct therapy. Indirect

therapy involves exercise programs or swallowing of saliva but here no food or liquid is given. The “Cough Out Exercise” and “Supraglottic Swallowing” detailed above are also part of the indirect therapy. Indirect therapy techniques to improve the oropharyngeal function include “Lip Closure”, “Movement of Cheek and Tongue”, “Oral Sensory Awareness”, “Crycopharyngeal Opening”, and “Swallowing maneuvers” such as “Supraglottic swallowing” and the “Mendelsohn Maneuver”.

Posture techniques as compensatory treatment procedures such as “Chin Down” and “Head Rotation to the Damaged Side” are usually introduced in advance of direct therapy. These procedures are to control the flow of food and eliminate patient symptoms such as in aspiration, but they do not necessarily change the physiology of the patient swallowing function. With the “Chin Down” posture, the tongue base and epiglottis are pushed closer to the posterior pharyngeal wall and the airway entrance is narrowed. In the “Head Rotation to the Damaged Side” the change in posture twists the pharynx and closes the damaged side of the pharynx so that food flows down the unaffected side, this posture is used when there is unilateral pharyngeal wall impairment or unilateral vocal fold weakness.

Before the time of discharge from the hospital, nutritional counseling by a dietician is essential. Unfortunately some oral cancer patients are unable to ingest food orally after the surgery despite the

rehabilitation. Then, it becomes necessary to select other types of feeding such as gastrostoma.

After the discharge, we monitor the body weight and food consistency of actual eaten food closely at the out-patient department. Also, periodic evaluations of swallowing using videofluoroscopic examinations are recommended.

## References

- 1) Japan Society for Head and Neck Cancer, Report of Head and Neck Cancer Registry of Japan, 2016.
- 2) Inoue N, Nishikata S, Kobayashi I, Murakami Y, Hirano M, Kawamura M. Orthognathic surgery of dentofacial deformities by team approach procedure. *Hokkaido J. Dent. Sci* 9 : 32-51, 1988. (in Japanese)
- 3) Clinical study on the third molar autotransplantation to molar region, Yuna Abe, Yusuke Matsuzawa and Kanchu Tei, *Hokkaido J. Dent. Sc.*, 36 : 98-109, 2015
- 4) Tei K, Sakakibara N, Yamazaki Y, Ohiro Y, Ono M, Totsuka Y, : Does swallowing function recover in the long term in patients with surgically treated tonguecarcinomas? *J Oral Maxillofac Surg* 70(11) : 2680-2386, 2012
- 5) Tei K, Maekawa K, Kitada H, Ohiro Y, Yamazaki Y, Totsuka Y. : Reocvery from postsurgical swallowing dysfunction in patients with oral cancer. *J Oral Maxillofac Surg* 65(6) :1077-1083, 2007