



Title	Development of a technical aid for occlusal adjustment during dental treatment under general anesthesia
Author(s)	Kobayashi, Kunihiko; Okada, Kazutaka; Ozaki, Kimiya; Yamazaki, Yutaka; Notani, Kenji; Inoue, Nobuo
Citation	北海道歯学雑誌, 38(Special issue), 144-150
Issue Date	2017-09
Doc URL	http://hdl.handle.net/2115/67354
Type	article
File Information	21_Kunihiko Kobayashi.pdf



[Instructions for use](#)

Development of a technical aid for occlusal adjustment during dental treatment under general anesthesia

Kunihiko Kobayashi, Kazutaka Okada, Kimiya Ozaki, Yutaka Yamazaki, Kenji Notani
and Nobuo Inoue

Gerodontology, Department of Oral Health Science, Faculty of Dental Medicine and Graduate School of Dental Medicine, Hokkaido University

ABSTRACT :

Background General anesthesia can increase the volume of the tongue. A large tongue between the upper and lower teeth may be a serious obstacle, especially for tapping during occlusal adjustments in prosthetic treatment. We developed a tongue retractor to eliminate interference by the tongue. This study assesses the effect of the tongue retractor on occlusal adjustment time and describes two patients in which the tongue retractor was used.

Methods The study involved five patients and two dentists. Measurements were performed during occlusal adjustment of the molars. The time from when the dentist took hold of the articulating paper to the first tap was compared in situations with and without the tongue retractor.

Results The mean occlusal adjustment time was significantly shorter ($p < 0.05$) than without the tongue retractor for both dentist A and B in all patients.

Conclusion Use of the tongue retractor considerably shortened occlusal adjustment times under general anesthesia.

Clinical reports We have been using the tongue retractor in clinical practice for 7 years. Two individual patients are described. One was a 34-year-old woman with cerebral palsy who underwent full mouth reconstruction, consisting of prosthetic appliances (full cast crown and resin facing crown) for 26 teeth. The second was a 29-year-old man with Down's syndrome who underwent adjustment of mandibular position by prosthetic treatment of molars.

Key Words : tongue retractor, occlusal adjustment, general anesthesia, technical aid

Introduction

Dental treatment under general anesthesia is performed on patients unable to undergo dental treatment while awake, including disabled persons¹⁾, patients with abnormal gag reflexes²⁾, and patients with dental phobias. General anesthesia frequently increases the volume of the tongue in the oral cavity³⁾. An enlarged tongue is a serious obstacle during prosthetic treatment, especially during occlusal adjustments. The enlarged tongue frequently enters between the upper and lower teeth at the time of biting, thereby interfering with tapping (Fig. 1). In the absence

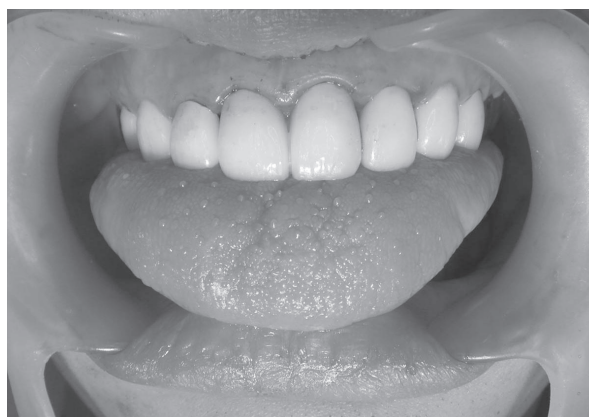

Fig. 1 The enlarged tongue of patient 1 under general anesthesia entered between the upper and lower teeth.

Address of Correspondence

Kunihiko Kobayashi, DDS, PhD.

Gerodontology, Department of Oral Health Science, Faculty of Dental Medicine and Graduate School of Dental Medicine, Hokkaido University, Kita 13, Nishi 7, Kita-ku, Sapporo, 060-8586, Japan

TEL : +81-11-706-4583 ; FAX : +81-11-706-4582 ; E-mail : kobayasi@den.hokudai.ac.jp

of a restraining device for the tongue, the dentist must use any instrument available to push the tongue away from its position between the upper and lower teeth prior to occlusal adjustment. However, even if the upper and lower teeth can contact each other, it may be difficult to accurately insert articulating paper into the gap between the upper and lower teeth. Even when using precisely made crown prostheses, repeat occlusal adjustments are required to achieve a final accuracy of about $0\text{-}30\ \mu\text{m}^4$. Interference by the tongue must be eliminated during each attempt at adjustment attempt, resulting in stress on the dentist. Moreover, this may reduce the accuracy of occlusal adjustments, prolonging time under anesthesia.

Occlusal adjustments are difficult to perform in many patients, including disabled persons, while they are awake. Therefore, they must undergo dental treatment under general anesthesia. General anesthesia relaxes the muscles, enabling the lower jaw to be guided to a centric relation and to obtain an appropriate centric occlusion. Occlusion is very important for conservation of the stomatognathic

system and for improving masticatory function.

To date, no device that eliminates interference by the tongue during occlusal adjustment under general anesthesia has been described. We therefore developed a device for use as a tongue retractor⁵, and have been using it in clinical practice (Fig. 2, 3).

This report, describes the effect of the tongue retractor on occlusal adjustment⁶, including a full description in two patients who underwent occlusal adjustment using the tongue retractor.

Part. 1 : Development of a technical aid for occlusal adjustment

Design of the tongue retractor.

Impressions were taken of the upper and lower jaws and working models constructed. The tongue was placed in the space between the palate and the floor of the oral cavity. The working model was filled with pressure-welded paraffin wax to the desired thickness

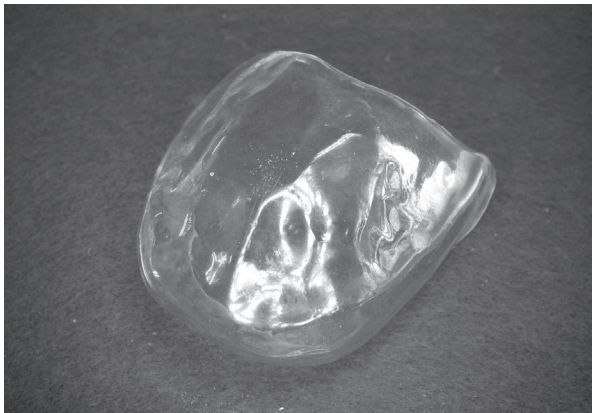


Fig. 2 A tongue retractor

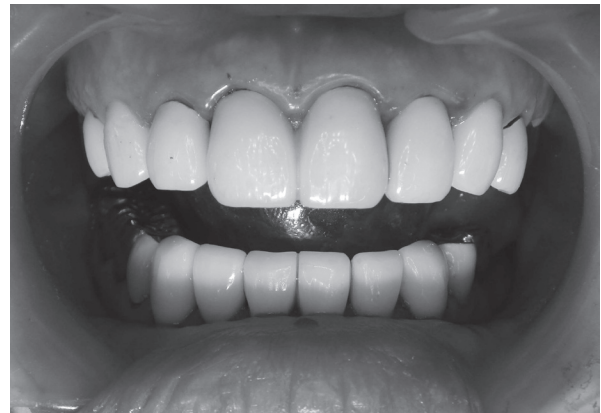

Fig. 3 The insertion of the tongue retractor. The enlarged tongue was eliminated between the upper and lower teeth.

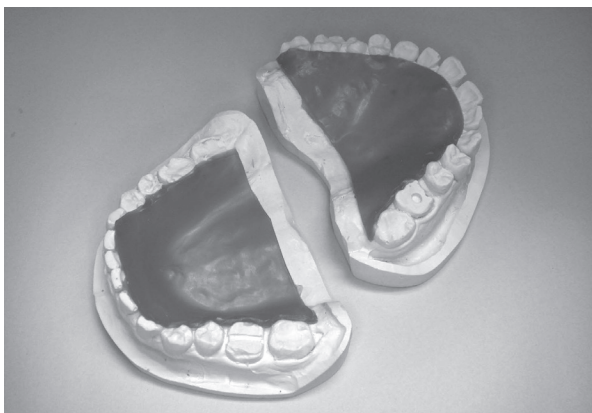


Fig. 4 Working models of the teeth with pressure-welded paraffin wax.

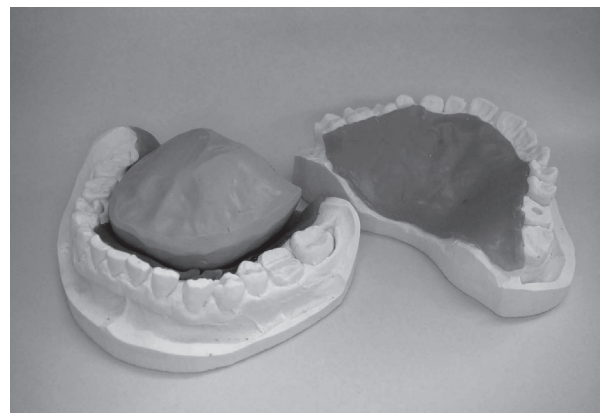

Fig. 5 A virtual tongue made of silicone impression material.

of the tongue retractor (Fig. 4). The space encompassed by the wax was filled with silicone putty to yield a virtual tongue (Fig. 5). The virtual tongue was covered with a 1.5 mm thick thermoplastic cover (Erkodur, Erkodent, Pfalzgrafenweiler, Germany) using a vacuum thermoforming unit (Erkoform, Erkodent) (Fig. 2). The thermoplastic cover was subsequently adjusted to eliminate the tongue in the oral cavity (Fig. 3).

Effects of the tongue retractor

The study involved five patients undergoing prosthetic treatment under general anesthesia (Table 1). Two dentists were involved; dentists A and B had 10 years and 3 years, respectively, of experience performing dental treatment under general anesthesia and 30 years and 10 years, respectively, of experience performing dental treatments.

Table 1 Patients in the study

Patient	Sex	Age	Reason for the general anesthesia
1	female	32	Autism
2	male	29	Mental retardation
3	male	38	Mental retardation
4	male	38	Dental phobia
5	female	21	Dental phobia

Patients were placed under general anesthesia, and measurements made during the occlusal adjustment of molars. The time from when the dentist took hold of the articulating paper to the first tap was compared in situations with and without the tongue retractor. The measurements were performed five times each for the 5 patients by the two dentists.

We adopted the mean of the 5 measurements and conducted statistical analysis using the paired-T test.

The study protocol was approved by the Hokkaido University Hospital Clinical Trials Committee (No. 010-0302)

Result

The results are shown in Table 2. The time used with the tongue retractor was significantly shorter than that without for both dentist A and B in each patient ($p < 0.05$). There was no statistically significant difference between the dentists in each case with or without the tongue retractor.

Table 2 Results of the study. The time used with the tongue retractor was significantly shorter than that without for both dentists in each patient ($p < 0.05$). There was no statistically significant difference between the dentists in each case with or without the tongue retractor.

Patient	Dentist A		Dentist B	
	Tongue retractor			
	Used	Not used	Used	Not used
1	1.71 ± 0.40	14.15 ± 7.05	1.50 ± 0.67	14.63 ± 3.16
2	1.33 ± 0.17	11.90 ± 1.45	1.12 ± 0.16	23.15 ± 6.52
3	1.29 ± 0.23	20.05 ± 2.39	1.81 ± 0.28	36.60 ± 11.3
4	1.62 ± 0.33	9.60 ± 0.43	1.45 ± 0.42	11.13 ± 1.05
5	1.38 ± 0.23	12.26 ± 0.49	1.89 ± 0.41	12.61 ± 1.99

(Seconds ± SD)

Discussion

Effect of tongue retractor

For both dentists, mean occlusal adjustment time was significantly shorter with than without the tongue retractor in each patient. Comparing the with and without measurements for each subject, the difference in their means ranged from 8.0 s (patient 4) to 18.8 s (patient 3) for dentist A and from 9.7 s (patient 4) to 34.8 s (patient 3) for dentist B.

Because occlusal adjustments are often repeated, the tongue retractor can considerably shorten total treatment time. These differences are especially important in the prosthodontic treatment of multiple teeth or in full mouth occlusal adjustments, although they likely do not have a great effect on the treatment of a few teeth.

Differences due to length of clinical experience of dentists

There were no differences between the two dentists under both situations; *i.e.*, when using and not using the tongue retractor. All measurements using the tongue retractor varied between 1 and 2 seconds, suggesting that the time required was not based on length of clinical experience and that qualified persons would perform occlusal adjustments similarly. However, times taken by the two dentists in the absence of the tongue retractor differed by >10 seconds in two patients (Patients 2 and 3). Further, the minimum was 9.6 seconds and maximum 36.6 seconds, very large differences existed in the measured values. Studies in larger numbers of patients undergoing treatment by a larger number of dentists are necessary to determine the effects of clinical experience on occlusal adjustment times.

Individual differences among patients

Although occlusal adjustments may be performed rapidly in some patients without using the tongue retractor, those patients were not included in this study. However, this study showed that the ease of excluding the tongue results in large inter-individual differences among patients.

Accuracy of occlusal adjustment

The accuracy of occlusal adjustment was not determined due to ethical considerations. However, the difficulty of the operation and the mental stress imposed on dentists in the absence of a tongue retractor would likely influence the accuracy of occlusal adjustments.

Articulating paper

The study also did not investigate whether the articulating paper reached the lingual cusp. However, the procedure required to insert the articulating paper to reach the lingual cusp is simple and straightforward when the tongue retractor is used. In the absence of the tongue retractor, however, it is more difficult to fully insert the articulating paper to the lingual cusp, although tapping can still be performed.

Conclusion.

This study found that use of the tongue retractor was effective in considerably shortening occlusal adjustment times under general anesthesia. These times were not affected by factors associated with the patient or dentist.

Part. 2 : Clinical reports

Two patients are described in detail.

Patient 1

The first patient was a 31-year-old woman, with cerebral palsy, mental retardation, limb movement disorder and visual disability. Although nursed by her family, but her oral care was insufficient. She was unable to undergo dental treatment while awake. Therefore, dental X-rays were taken and treatment begun under general anesthesia. Dental XP photographs were observed (Fig. 6). It was impossible to preserve two molars of her right lower jaw; moreover, all her other teeth had dental caries, and 15 teeth required root canal treatment. Occlusal support of molars on both sides was minimal, although movement of her temporomandibular joint was normal. Root canal treatments of her existing

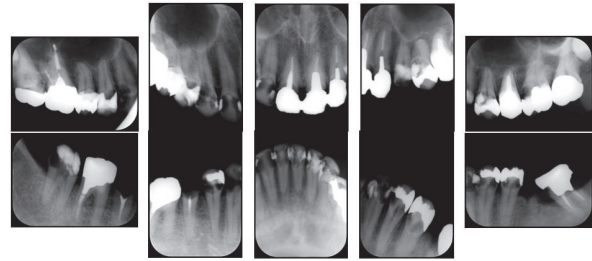


Fig. 6 Dental X-ray photographs of the patient 1 at first general anesthesia, showing dental caries in most teeth.

teeth were performed under general anesthesia. After root canal filling, abutment construction was performed using a composite resin with prefabricated stainless steel posts, followed by provisional restoration (Fig. 7), with all procedures performed using the tongue retractor. She underwent nine dental treatments under general anesthesia in a year. Provisional crowns were placed on all teeth during the sixth treatment. We observed her progress for one month and asked her mother about her meal habits, including time taken and quantity eaten. Her mother confirmed that she had no problems with occlusion and jaw movement. We therefore decided insert a final prosthesis in this mandibular position (Fig. 8). Prosthetic appliances (full cast crown and resin facing crown) for 26 teeth were inserted during a single treatment session under general anesthesia using the tongue retractor (Fig. 9).

Full mouth reconstruction requires multiple treatment sessions. Occlusal adjustment during full mouth reconstruction is very difficult to perform while awake. Under general anesthesia, however, the masticatory muscles are relaxed and the patient is non-resistant, allowing the jaw to be manipulated more easily than while awake. We elected to insert prostheses during

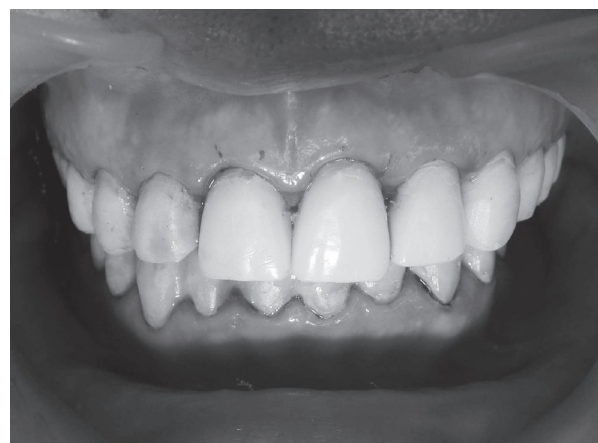

Fig. 7 Insertion of the provisional restorations.

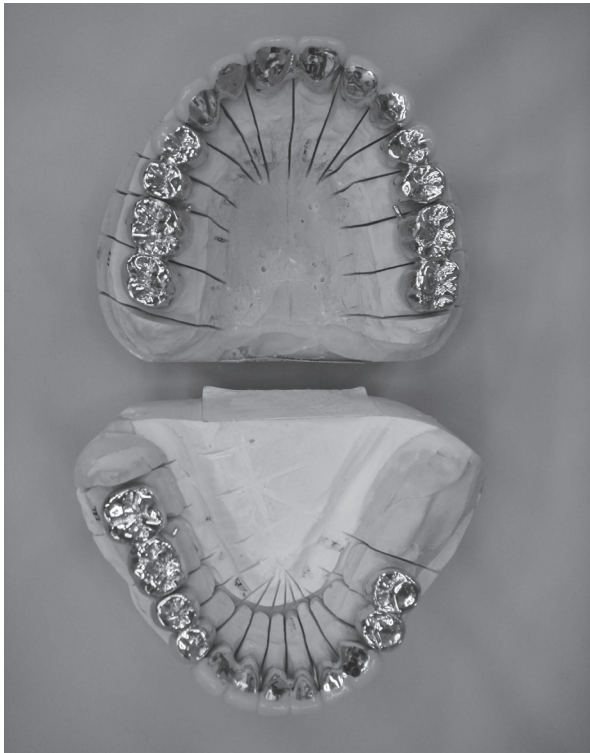


Fig. 8 The prostheses (14 full cast crowns and 12 resin facing crowns)

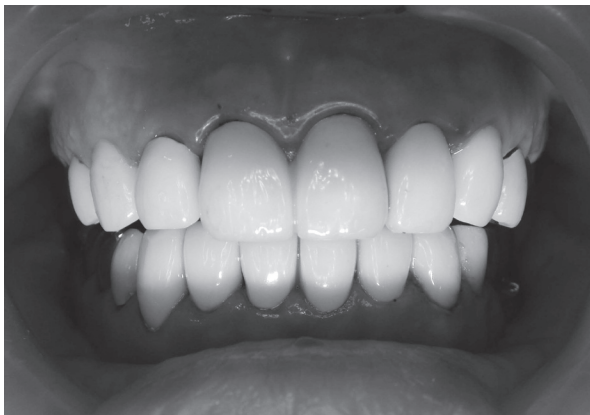

Fig. 9 Setting of 26 teeth prostheses during a single treatment under general anesthesia using the tongue retractor

a single treatment session because of the simplicity of bilateral jaw manipulation and because we could use the tongue retractor to simplify occlusal adjustment for centric positioning. In addition, the patient had severe apical lesions, with some possibly requiring extraction. We therefore completed root canal treatment and used temporary restorations. Furthermore, multiple treatments for inserting prostheses increased the number of treatment sessions and extended the treatment period. Finally, two specialists in the Japan prosthodontic society guided the lower jaw to the same centric position. This

treatment could not have been performed without the tongue retractor. Regular follow up has shown that this patient continues to do well.

Patient 2

The second patient was a 29-year-old man with Down's syndrome, mental retardation and difficulty communicating. The patient required treatment of a fixed partial denture in his upper right molars (Fig. 10). He underwent general dental treatment while awake, but could not bite according to instructions. He could not bite or undergo occlusal adjustment while awake, indicating that these procedures should be performed under general anesthesia, whereas other treatments could be performed while awake. After root canal treatment and abutment construction while awake, his occlusion was examined using the tongue retractor under general anesthesia. We found that the habitual intercuspal position had shifted to the right, by about 1.5 mm from the centric position, during bilateral manipulation (Fig. 11, 12). There was mutual contact in the position but no disorder in the movement of his left and right temporomandibular

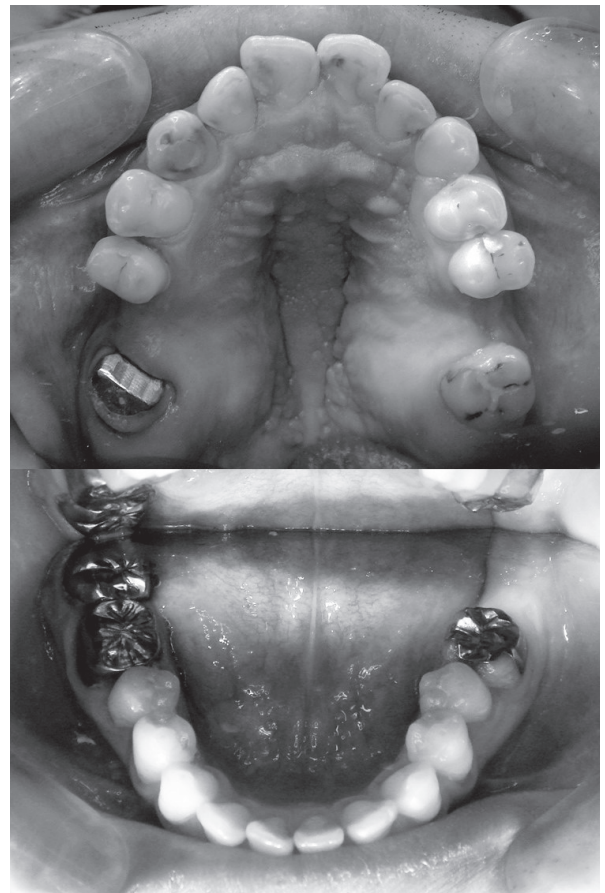

Fig. 10 The upper and lower dental arch of the patient 2.

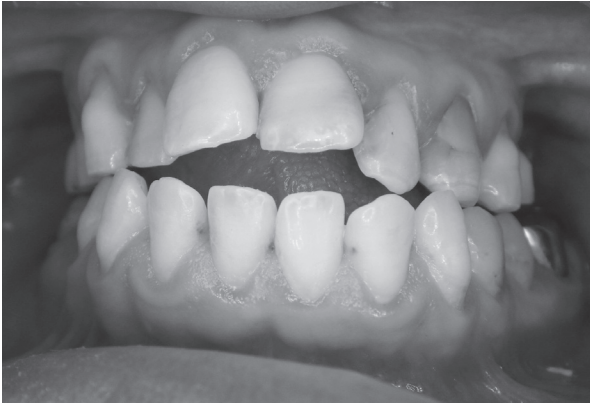

Fig. 11 Habitual occlusal position.

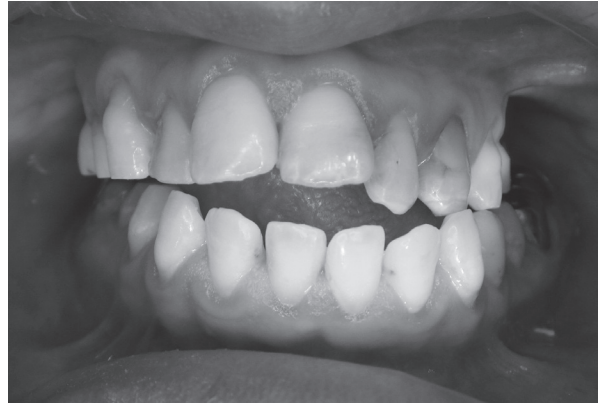

Fig. 12 Centric relation guided by bilateral manipulation.

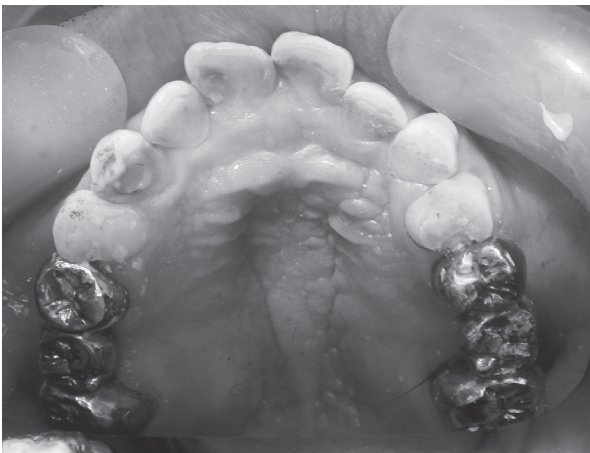


Fig. 13 Results after prosthetic treatment, both his right and left upper molars were treated by the bridges.




Fig. 14 Tracing table of a simplified gothic arch tracer, showing almost no dispersion.

joints. An open bite was present between his upper and lower anterior teeth. Therefore, we elected to treat both his right and left molars, and corrected the mandibular position under general anesthesia (Fig. 13). Again, two specialists in the Japan prosthodontic society guided the lower jaw to the same centric position.

The dispersion of tapping points was verified under general anesthesia using a simplified gothic arch tracer and the tongue retractor. Two dentists, with 12 and 5 years of experience, respectively, in dental treatment under general anesthesia and 32 and 12 years of experience, respectively, in dental treatment, tapped five times each. The tracing tables showed almost no dispersion (Fig. 14). The reproducibility of mandibular position is being further investigated.

Mastication ability before and after treatment was evaluated by examining the types of foods⁷⁾ that could be eaten by this patient. A questionnaire submitted by his mother showed that his score increased from 61.6 before

treatment to 91.9 after treatment. His mother reported that he ate more foods and that his mealtimes were shorter.

As this patient could not bite according to instructions, he could not receive sufficient dental treatment while awake. Although the dentists performing this procedure had experience performing dental treatment under general anesthesia, mandibular guidance may not have gone well, and mandibular position may have shifted. The tongue of this patient became enlarged, obstructing occlusal adjustment. However, use of the tongue retractor allowed us to easily guide the mandible and perform occlusal adjustment without being affected by the large tongue.

Many disabled persons cannot undergo dental treatment while awake and cannot respond when asked about occlusion. Thus, occlusion of these patients is often inadequate. As shown by this patient, appropriate occlusion may enhance patient quality of dietary life.

Application to other fields

The tongue retractor can also be used on surgery of brain tumors. Surgery performed while applying electrical stimulation to the brain and while confirming innervations can cause the jaws to suddenly close and to bite the tongue. Multiple repetitions of this procedure can greatly damage the tongue. Although large amounts of gauze were packed into the oral cavity to reduce damage to the tongue, this gauze had little effect. A tongue retractor to fix to the dentition of the lower jaw was therefore constructed (Fig. 15). To date, it has been used in three patients. The device did not become dislodged from the oral cavity during the operation, there was no damage to the tongue, and good results were obtained.

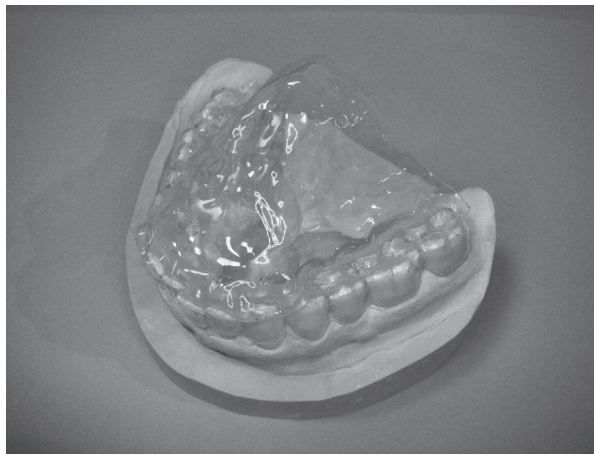


Fig. 15 The tongue retractor for neurosurgery. The retractor is fixed to the dentition of the lower jaw.

Conclusion

The tongue retractor makes occlusal adjustment easy for persons who can undergo dental treatment only under general anesthesia. This tongue retractor may be applicable not only for dental procedures but for medical procedures.

Acknowledgements

The authors received no financial supports and declare they have no potential conflicts of interests with respect to authorship and/or publication of this article. Special thanks to the patients who cooperated in this study and the staff of the Clinic of Dental Anesthesia of Hokkaido University Hospital.

References

- 1) Ogasawara T, Ohtsuki M, Ohtsuki Y, Takai T, Hosaka K : Medical accident in dental treatment of patients with disability. *J. Jpn. Soc. Disability Oral Health* 22 : 168-177, 2001.
- 2) Saita N, Fukuda K, Koukita Y, Ichinohe T, Yamashita S : Relationship between gagging severity and its management in dentistry. *J Oral Rehabil.* 40 : 106-111, 2013.
- 3) Tan WK, Liu EH, Thean HP : A clinical report about an unusual occurrence of post-anesthetic tongue swelling. *J Prosthodont* 10 : 105-107, 2001.
- 4) Ishibashi K, Kawazoe T, Kawawa T, Hukushima S, Yatani H : *Crown and Bridge Prosthodontics.* 227-230, Ishiyaku, Tokyo, 2006.
- 5) Kobayashi K, Inoue N : Invention of the tongue retractor for occlusal adjustment under general anesthesia. *J. Jpn. Soc. Disability Oral Health* 32 : 73-75, 2011.
- 6) Kobayashi K, Okada K, Inoue N : Tongue retractor developed for occlusal adjustment under general anesthesia. *J Disabil Oral Health* 15 : 18-22, 2014.
- 7) Koshino H, Hirai T, Toyoshita Y, Yokoyama Y, Tanaka M, Iwasaki K, Hosoi T : Development of new food intake questionnaire method for evaluating the ability of mastication in complete denture wearers. *Prosthodont Res Pract* 7 : 12-18, 2008.