



Title	Lip incompetence and myofunctional therapy
Author(s)	Iida, Junichiro; Kaneko, Tomoo; Nakanishi (Ohtsuka), Mai; Yoshizawa, Saori; Yamamoto, Takaaki; Sato, Yoshiaki
Citation	北海道歯学雑誌, 38(Special issue), 130-135
Issue Date	2017-09
Doc URL	http://hdl.handle.net/2115/67351
Type	article
File Information	18_Junichiro Iida.pdf



[Instructions for use](#)

Lip incompetence and myofunctional therapy

Junichiro Iida¹⁾, Tomoo Kaneko²⁾, Mai (Ohtsuka) Nakanishi³⁾, Saori Yoshizawa³⁾,
Takaaki Yamamoto³⁾ and Yoshiaki Sato¹⁾

¹⁾ Orthodontics, Department of Oral Functional Science, Division of Dental Medicine, Faculty of Dental Medicine and Graduate School of Dental Medicine, Hokkaido University, ²⁾ Department of Stomatognathic Function, Center for Advanced Oral Medicine, Hokkaido University Hospital, ³⁾ Department of Orthodontics, Division of Oral Rehabilitation, Hokkaido University Hospital

ABSTRACT : Lip incompetence, which is a state in which the upper and lower lips are constantly apart, is thought to induce mouth breathing that may result in the development of gingivitis and periodontal disease. In the orthodontic field, lip incompetence has major problems for diagnosis, when determining the treatment goal and at the time of retention. We have been performing studies on lip incompetence and have obtained the following results : (1) it is possible to predict to some extent the state of lip closure during sleep by examination only in an awake state, (2) anterior teeth are positioned forward in individuals with lip incompetence, and (3) a training method called Button Pull is effective as a myofunctional therapy for improving lip incompetence, but there remains a need to clarify the background.

Key Words : lip incompetence, myofunctional therapy, button pull, orbicularis oris muscle, orthodontics

Introduction

In people with lip incompetence, which is a state in which the upper and lower lips are apart at rest and mouth breathing always occurs, the inside of the mouth easily becomes dry, a condition that might lead to the development of periodontal disease as well as gingivitis (Fig 1). In orthodontics, lip incompetence is thought to be related to malocclusion and failure of retention to stabilize the position of teeth after orthodontic treatment.

In orthodontic treatment, craniofacial morphology is examined by cephalometric analysis and the goal of

treatment is to have the teeth in harmony with the maxillofacial form. Orthodontic treatment is performed to achieve normal occlusion. However, when performing orthodontic treatment, consideration must be given to lifetime maintenance of the corrected position of teeth or achieved normal occlusion. Retainers are generally used to maintain the corrected position of teeth or corrected occlusion, but it is very rare for a retainer to be used for life.

Since teeth are constantly exposed to forces generated by the muscles and soft tissues around the oral cavity such as the lips, cheeks and tongue, the position of teeth can be gradually changed by these forces. Consideration of the forces generated by soft tissues around the oral cavity is important for achieving a good outcome of orthodontic treatment.

The results of studies on lip incompetence and treatments for lip incompetence are presented in this paper.

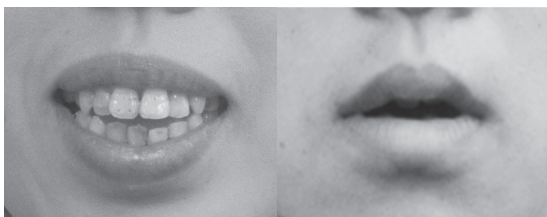

Fig. 1 Lip incompetent situation

Address of Correspondence

Junichiro Iida, DDS, PhD.

Orthodontics, Department of Oral Functional Science, Division of Dental Medicine, Faculty of Dental Medicine and Graduate School of Dental Medicine, Hokkaido University, Kita 13, Nishi 7, Kita-ku, Sapporo, 060-8586, Japan

TEL : +81-11-706-4285 ; FAX : +81-11-706-4285 ; E-mail : iidaj@den.hokudai.ac.jp

1. Magnitude of force for tooth movement

Focusing on the labio-lingual position of the front teeth, it can be considered that the front teeth are located so as to maintain a balance between the force from the labial side applied by the lips and the force from the lingual side applied to the teeth by the tongue. It is thought that a stable condition of the position of teeth and an appropriate width and shape of the dental arch are achieved by the balance of forces from the lingual side and the labial/buccal side at rest or during activities such as talking and swallowing. Alternatively, it can be considered that the position of teeth in the dental arch is determined by the eruption of teeth into the gaps between the tongue and the lip/cheek. Such a way of thinking has long been advocated as equilibrium theory by Brodie¹⁾ and Moyers *et al*²⁾.

We sometimes experience patients with a tongue protruding habit at rest or when talking or swallowing. One way to correct this habit in orthodontic treatment is to attach a tongue guard to the lingual side so that the tongue cannot come into contact with the front teeth. If this method is effective, the front teeth will move to the lingual side within a few months (Fig 2). A possible explanation of this phenomenon is that the balance of forces from the lingual side and the labial side greatly changes due to attachment of the tongue guard and the front teeth move to the lingual side due to the force of the lip from the labial side.

Many studies have been carried out on the strength of force applied to the teeth by soft tissue such as the

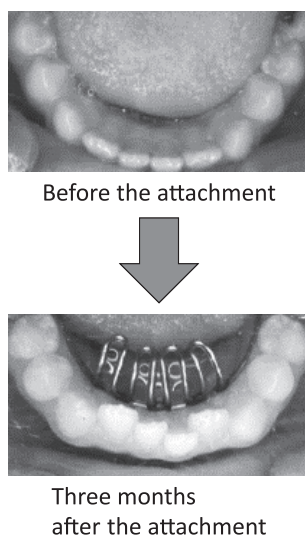


Fig. 2 The movement of lower anterior teeth to lingual side at three months after the attachment of tongue guard

lip or tongue that determines the position of teeth. Dr. Kato reported that the force is 5 gf / cm² or less at rest, 10 to 20 gf / cm² when swallowing and 5 to 14 gf / cm² when talking³⁾. The strengths of forces in other reports are almost the same^{4, 5)}. An *in vivo* study on the effect of compression of microvessels showed that weak continuous pressure stimulation that does not occlude microvessels effectively induces bone resorption⁶⁾ (Fig 3). Those results suggest that the strength of force applied by the lip, tongue or cheek to teeth is weak and that the position of teeth can be changed by even a weak force.

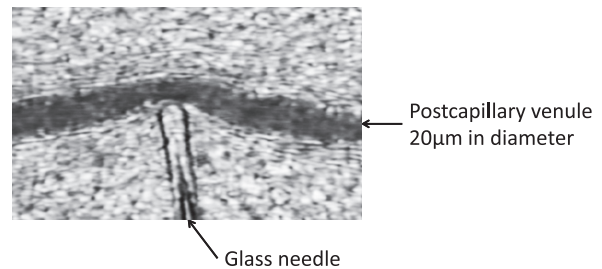


Fig. 3 In vivo study observing the change of blood stream during the deformation of a microvessel

In orthodontic treatment, when the front teeth of the upper and lower jaw are greatly retracted to improve lip protrusion, the position of the front teeth will gradually return to the original protruded position if the force from the lip and tongue to the front teeth is the same as that before the treatment.

Thus, at the stage of diagnosis prior to the start of orthodontic treatment, if the goal of treatment is not set with consideration of the environment of the force applied to teeth by the lip, tongue and cheek, the position of the teeth will return to the original position after treatment. Thus, when determining the goal of orthodontic treatment, it is very important to consider the condition of soft tissue around the oral cavity for both patients with and those without lip incompetence.

2. Relationship between lip competence and position of anterior teeth

We have been conducting research on lip incompetence with the assumption that lip incompetence affects the stable position of front teeth. Although lip incompetence can be judged to some extent by observation in a clinical examination, it is necessary to determine how long the lips are closed during the course of one day including sleeping time, which accounts for about one-third of the

day. A sleep study in an examination room is needed to confirm the presence or absence of lip closure during sleep, but it is difficult to conduct such a study as a general clinical examination for all patients. To solve this problem, Handa⁷, Kaneko, and others have been trying to establish a method for estimating the all-day state of lip closure including that during sleep by inspecting the state of lip closure only in an awake state, and they have studied the association between lip closure state in an awake state and that during sleep.

Those investigators developed a device together with Yamamoto to record the closed state of the mouth, and they used it to determine the state of lip closure during sleep and when awake in 25 subjects with normal occlusion. A sleep state was confirmed by using polysomnography, and the state of lip closure was monitored in each of the subjects for 2 hours during sleep. The state of lip closure was also monitored for 15 minutes in an awake relaxed condition in which each subject closed their eyes and listened to soothing music. As another condition in an awake state, each subject was instructed to perform simple calculations for 15 minutes and the state of lip closure was also monitored in that condition. It was found that the subjects who had their lips close almost all of the time under both of the conditions in an awake state had an almost completely closed lip state during sleep, whereas the subjects who had their lips apart almost all of the time in both of the conditions in an awake state had lip incompetence during sleep⁸.

Based on the results of that research, Endo^{9, 10}, Sato and others examined the relationship between a lip closed state and the labio-lingual position of front teeth in 19 subjects with normal occlusion. The 19 subjects included eight subjects whose lips were open for almost all of the day including sleeping time (lip-incompetent group) and 11 subjects who were considered to have their lips closed for almost all of the day (lip-competent group). The skeletal and dental morphology of each of the subjects was analyzed using lateral cephalograms. It was found that the front teeth of the upper and lower jaws were positioned significantly more forward in the lip-incompetent group than in the lip-competent group (Fig 4). These results indicate that, even though occlusion was normal, the labio-lingual position of anterior teeth was different in subjects with lip incompetence and those with lip competence. In other words, it was revealed that anterior teeth were located on the labial side with

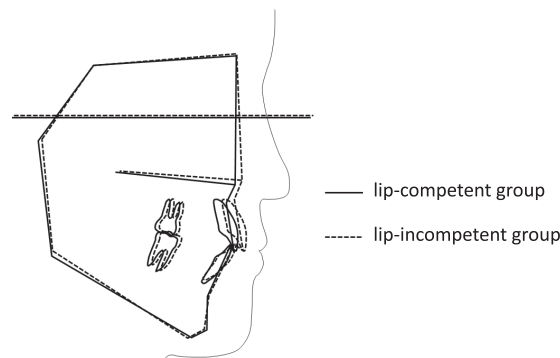


Fig. 4 Superimposition of averaged profilograms of lip-competent and lip-incompetent groups in the subjects with normal occlusion (modified from Endo, *Orthodontic Waves* 2009)

stable positioning in subjects in the lip-incompetent group even though they had normal occlusion. These results imply that as a goal of orthodontic treatment for patients with lip incompetence, anterior teeth should be positioned more anteriorly than those in patients with lip competence in order to achieve stability.

Thus, when determining the labio-lingual position of anterior teeth as the goal of orthodontic treatment, the state of lip closure must be taken into consideration.

3. Training to improve lip incompetence

Next, we examined whether it is possible to improve the state of lip incompetence.

Attempts have been made to improve lip incompetence by using myofunctional therapy. One of the representative exercises of myofunctional therapy is "Button Pull", which is advocated by Zickefoose¹¹. It is an exercise to train the orbicularis oris muscle by inserting a large button into the oral vestibule and pulling it with a string or hanging a weight on the string (Fig 5). Although this exercise has been introduced in some textbooks, details of the training conditions and the effectiveness of the exercise have not been elucidated. Ohya^{12, 13} examined the appropriate conditions of this lip training method by measuring oxygen saturation (oxygenated hemoglobin and deoxygenated hemoglobin levels) in the orbicularis oris muscle and determined effective training conditions as aerobic exercise and hypoxic exercise. The effective conditions were found to be loading 50% of the maximum force for 5 seconds and resting for 5 seconds with 20 repetitions as aerobic exercise and loading 80% of the maximum force for 5 seconds and resting for 5 seconds with 5 repetitions as hypoxic exercise (Fig 6).

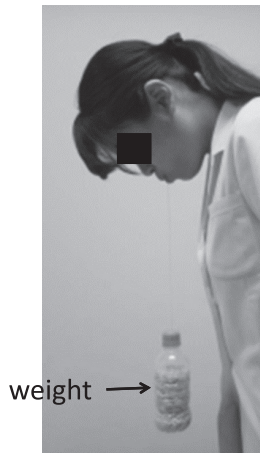


Fig. 5 Exercise method of “Button Pull” hanging a weight on the string

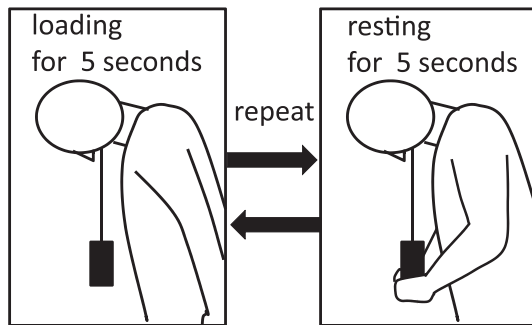


Fig. 6 Hypoxic and aerobic exercise

aerobic exercise: loading 50% of the maximum force for 5 seconds and resting for 5 seconds with 20 repetitions. hypoxic exercise: loading 80% of the maximum force for 5 seconds and resting for 5 seconds with 5 repetitions

It was also shown that training under the condition of aerobic exercise for 4 weeks resulted in a significant increase in endurance of the orbicularis oris muscle and that training for 4 weeks under the condition of hypoxic exercise increased both maximum muscular strength and muscular endurance (Otsuka, Yoshizawa *et al.*^{14, 15}).

Next, Otsuka and Yoshizawa *et al.*^{14, 15} investigated whether lip incompetence can be improved by aerobic and hypoxic exercise training of the orbicularis oris muscle and which exercise is more effective. They recruited 38 subjects with lip incompetence. Eighteen of the subjects performed training of the orbicularis oris muscle by aerobic exercise for 4 weeks, and the other 20 subjects performed training of the orbicularis oris muscle by hypoxic exercise for 4 weeks. The state of lip closure was monitored in two conditions (at rest and during a task requiring concentration) in an awake state. It was found that subjects who had lip incompetence for most of the day achieved an approximately 90% lip-competent

state by either training method. Otsuka and Yoshizawa *et al.*^{14, 15} also found that the acquired lip-competent state was maintained for 2 months after the termination of training (Fig 7). Thus, it was clarified that both aerobic exercise and hypoxic exercise for 4 weeks can improve a lip-incompetent state to a lip-competent state.

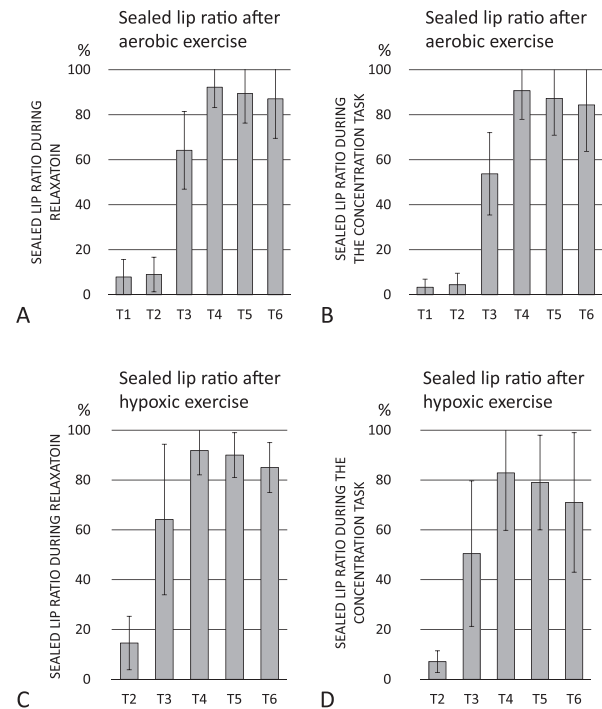


Fig. 7 Sealed lip ratio after aerobic and hypoxic exercise

Both of aerobic and hypoxic exercise for 4 weeks improves lip-incompetent state to a lip-competent state and it maintained for 2 months.

A : sealed lip ratio during relaxation after aerobic exercise, B : sealed lip ratio during the concentration task after aerobic exercise (modified from Ohtsuka¹⁴, Orthodontic Waves 2015), C : sealed lip ratio during relaxation after hypoxic exercise, D : sealed lip ratio during the concentration task after hypoxic exercise (modified from Yoshizawa¹⁵), T1 : four weeks before the start of the exercise, T2 : at the start of the exercise, T3 : two weeks after the start of the exercise, T4 : four weeks after the start of the exercise (at the termination of the exercise), T5 : four weeks after the termination of the exercise, T6 : eight weeks after the termination of the exercise,

4. Background of the improvement in lip incompetence

Yoshizawa then focused on muscle activity of the orbicularis oris muscle and examined the muscle activity at the time of lip closure using electromyography of the orbicularis oris muscle. In the lip-competent group, the electromyogram of the orbicularis oris muscle did not show much activity of the muscle during lip closure,

indicating that the orbicularis oris muscle was not activated and that the lip closed state was naturally maintained. On the other hand, strong muscle activity was recorded at the time of lip closure in the lip-incompetent group, indicating that the orbicularis oris muscle needed to be strongly activated in order to close the lips.

Yoshizawa therefore conducted training by hypoxic exercise using the Button Pull method for 4 weeks in a group of subjects with lip incompetence, and she investigated muscle activity of the orbicularis oris muscle in the lip closed state achieved as a result of the training. It was found that lip closure could be performed without large activity of the orbicularis oris muscle, as was observed in the lip-competent group, for up to 8 weeks after the end of training¹⁶⁾ (Fig 8).

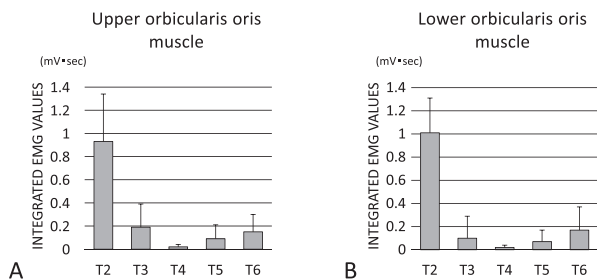


Fig. 8 Integrated EMG values before and after the hypoxic exercise of orbicularis oris muscle in the lip closed state
A :Upper orbicularis oris muscle, B : Lower orbicularis oris muscle

T2 : at the start of the exercise, T3 : two weeks after the start of the exercise, T4 : four weeks after the start of the exercise (at the termination of the exercise), T5 : four weeks after the termination of the exercise, T6 : eight weeks after the termination of the exercise, modified from Yoshizawa¹⁶⁾

This result is surprising because it suggests that factors other than reinforced strength or reinforced endurance of the orbicularis oris muscle may have created an environment in which the lips can achieve naturally closed state without orbicularis oris muscle activity.

There are two possibilities for the creation of an environment in which lip closure can be performed without activity of the orbicularis oris muscle. One possibility is that the muscular activity around the oral cavity other than the orbicularis oris muscles acts comprehensively to create an environment in which a lip closed state can be achieved without activity of the orbicularis muscle. The other possibility is that the brain functions to recognize what is desirable to maintain a

closed state of the lips without activity of the orbicularis oris muscle

Further investigation of these possibilities is needed.

Conclusion

Lip incompetence not only induces mouth breathing that may cause gingivitis and periodontal disease but also some problems from an orthodontic point of view. It became clear that the front teeth are positioned forward with stability in individuals with lip incompetence. If the anterior teeth are greatly retracted by orthodontic treatment while a lip-incompetent state is maintained, there is the possibility that the position of the front teeth will gradually return to the labial side after the orthodontic treatment. For such patients, it was found that a training method called Button Pull is effective as myofunctional therapy for improving lip incompetence, but there remains a need to clarify the background.

Acknowledgment

We thank Kaori Handa, Waka Ooya, Satimary Endo Leonardo for their active important contribution to this research.

References

- 1) Brodie, A.G. : Consideration of musculature in diagnosis, Treatment and retention. *Am. J. Orthodont*, 38 : 823-835, 1952.
- 2) Moyers, R.E. : *Handbook of Orthodontics*, Yearbook, Medical Publishers Inc., Chicago, 1958.
- 3) Kato Y, : Intraoral Pressure Measurement with Telemetry System. *J Stomatol Soc Jpn* 54/1 : 175-189, 1987.
- 4) Winders R V. : Recent findings in myometricresearch. *Angle Ortho.* 44 : 38-43, 1962.
- 5) Gould MSE and Picton DCA : A study of pressures exerted by the lips and cheeks on the teeth of subjects with Angle's Class II division 1, Class II division 2 and Class III malocclusion compared with normal occlusion. *Arch oral Biol* 13 : 527-541, 1968.
- 6) Iida J, Warita H, Nakagawa N, Soma K : White blood cell movement changes in post-capillary venule during intermittent or continuous compressions. *Davidovitch Z and Norton LA Ed. Biological Mechanisms of Tooth Movement and*

- Craniofacial Adaptation, 189-194, Harvard Society for the Advancement of Orthodontics., Boston Massachusetts, 1996.
- 7) Handa K, Sato Y, Kaneko T, Yamamoto T, Iida J : A new method to evaluate lip sealing and its clinical application Part 1 Development of a new device for determining continuous sealing of lips. *Hokkaido J Dental Sci.* 26/2 : 146-152, 2005.
 - 8) Handa K, Sato Y, Kaneko T, Yamamoto T, Iida J : A new method to evaluate lip sealing and its clinical application Part 2 Lip sealing during the daytime and sleep. *Hokkaido J Dental Sci.* 26/2 : 153-163, 2005.
 - 9) Endo L S, Sato Y, Handa K, Kaneko T, Yamamoto T, Iida J : Relationship between lip sealing ability and dentofacial morphology. *Hokkaido J Dental Sci.* 29/2 : 139-147, 2008.
 - 10) Endo L S, Sato Y, Kaneko T, Yamamoto T, Handa K, Iida J : Differences in dento-facial morphology in lip competence and lip incompetence. *Orthodontic Waves.* 68/1 : 12-19, 2009.
 - 11) Zickefoose WE : *Techniques of Oral Myofunctional Therapy.* O.M.T. Materials 1989.
 - 12) Ooya W, Kaneko T, Handa K, Iida J : Orbicularis oris muscle training - Oxygenation in the orbicularis oris muscle using near-infrared spectroscopy -. *Hokkaido J Dental Sci.* 29/2 : 129-138, 2008.
 - 13) Ooya W, Kaneko T, Handa K, Iida J : Training methods effectively in the strength and endurance of the orbicularis oris muscle. *J Jpn Soc Stomatognath Funct* 15 : 131-138, 2009.
 - 14) Ohtsuka M, Kaneko T, Iida J : Effectiveness of training methods to improve orbicularis oris muscle endurance in patients with incompetent lips. *Orthodontic Waves,* 74/4 : 99-104, 2015.
 - 15) Yoshizawa S, Ohtsuka M, Kaneko T, Iida J : Study of training for improving lip incompetence. *Orthodontic Waves* 75/3, 47-53, 2016.
 - 16) Yoshizawa S : Effectiveness of hypoxic lip training for improving lip incompetence. Doctoral Thesis submitted to the Graduate School of Dental Medicine Hokkaido University, 2016.