



Title	Root canal treatment of traumatized permanent teeth with external root resorption
Author(s)	Yawaka, Yasutaka; Toyota, Yuki; Hisada, Akina; Maeda, Ayako; Inoue, Shohei; Yoshihara, Toshihiro
Citation	北海道歯学雑誌, 38(Special issue), 122-129
Issue Date	2017-09
Doc URL	http://hdl.handle.net/2115/67350
Type	article
File Information	17_Yasutaka Yawaka.pdf



[Instructions for use](#)

Root canal treatment of traumatized permanent teeth with external root resorption

Yasutaka Yawaka, Yuki Toyota, Akina Hisada, Ayako Maeda, Shohei Inoue
and Toshihiro Yoshihara

Dentistry for Children and disabled Persons, Department of Oral Functional Science, Faculty of Dental Medicine,
Hokkaido University

ABSTRACT : External root resorption is an important challenge in the preservation of traumatized teeth. External root resorption is observed in cases of replanted teeth from dental trauma. Root canal dressing containing calcium hydroxide ($\text{Ca}(\text{OH})_2$) is one recommended clinical approach for external root resorption treatment. However, complete control of external resorption may not be possible due to certain factors, such as the smear layer, which is formed by reaming and filing during root canal treatments. The smear layer plugs dentinal tubules and inhibits the effects of $\text{Ca}(\text{OH})_2$ as a root canal dressing material. Our study showed that root canal irrigation with ethylenediaminetetraacetic acid (EDTA) and sodium hypochlorite (NaOCl) with an ultrasonic device is the most effective method to remove the smear layer. Additionally, we observed an alkaline environment at the outer root surface due to ion diffusion from $\text{Ca}(\text{OH})_2$ following this treatment. As a result, the combined use of EDTA and NaOCl with an ultrasonic device for root canal irrigation led to good control of external root resorption.

Key Words : dental trauma, replanted tooth, external root resorption, calcium hydroxide, smear layer

Introduction

Dental trauma is an accident, not a disorder. Therefore, rapid and suitable treatments for traumatized teeth produce good convalescence of the teeth. For tooth avulsions, treatment consists of replanting teeth. However, in many cases, replanted teeth showed external root resorption after replantation (Fig. 1)^{1,2)}. External root resorption with dental trauma affects preservation of the traumatized tooth. Root canal treatments are necessary for replanted teeth to control root canal conditions and stop external root resorption³⁾. However, it is difficult to control/stop external root resorption adequately.

This review describes control/cessation of external root resorption as shown by our studies with an emphasis on root irrigation, the smear layer, and calcium hydroxide.

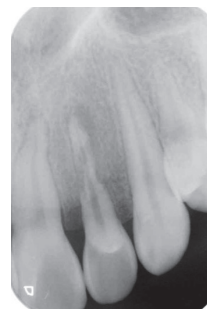

Fig. 1 External root resorption

A representative X-ray photograph of an upper left lateral incisor shows external root resorption caused by dental trauma.

Root resorption

Odontoclasts play a leading role in root resorption^{1, 4-6)}. Odontoclasts adhere to the root surface with a clear zone of attachment, and a small area is created between the

Address of Correspondence

Yasutaka Yawaka, DDS, PhD.

Dentistry for Children and disabled Persons, Department of Oral Functional Science, Faculty of Dental Medicine,
Hokkaido University, Kita 13, Nishi 7, Kita-ku, Sapporo, 060-8586, Japan

TEL : +81-11-706-4292 ; E-mail : yawaka@den.hokudai.ac.jp

odontoclast and root surface. Odontoclasts also secrete acid and enzyme. The acid decalcifies mineral and enzyme dissolves organic substances such as collagen fiber, leading to root surface resorption.

Two kinds of root resorption are observed in traumatized teeth : inflammatory resorption and replacement resorption⁶⁾. Advanced inflammatory resorption particularly affects preservation of traumatized tooth. However, control/cessation of root resorption is very difficult in clinical cases. Dentists should try to stop the resorption as quickly as possible.

Calcium hydroxide (Ca(OH)₂)

Calcium hydroxide (Ca(OH)₂) is commonly used in root canal filling of primary teeth. Ca(OH)₂ is an alkali with sterilization effects^{7, 8)}. Moreover, Ca(OH)₂ inactivates lipopolysaccharide⁹⁾. Therefore, dentists use root canal dressings containing Ca(OH)₂ in root canal treatments. In the clinical setting, inflammation around the root is reduced by root canal treatments. The use of Ca(OH)₂ in root canal dressings changes the root canal environment to alkaline by ion diffusion via dentinal tubules from the root canal to outer root surface. Ion diffusion from Ca(OH)₂ neutralizes acid secreted from odontoclasts and inhibits root decalcification^{3, 10-12)}. While this method is good for clinical treatment, it is not reliable.

Smear layer

It was reported that a smear layer develops on the root canal wall and in dentinal tubules after instrumentation such as reaming and filing in root canal treatment¹³⁻¹⁶⁾(Fig. 2). The smear layer on root canals comprises dentin and necrotic and viable tissue, including remnants of odontoblastic processes, pulp tissue, and microorganisms¹⁷⁾. The smear layer penetrates dentinal tubules¹⁸⁾ and reduces root dentin permeability¹⁹⁾. Therefore, studies have focused on techniques to remove the smear layer, including root canal irrigation of permanent teeth. The combined use of ethylenediaminetetraacetic acid (EDTA) and sodium hypochlorite (NaOCl) as chemical substances was very effective for removal of the smear layer. In particular, EDTA decalcified minerals in the smear layer, and NaOCl dissolved organic substances²⁰⁾. Moreover, ultrasonic irrigation was more effective than conventional needle irrigation^{21, 22)}.

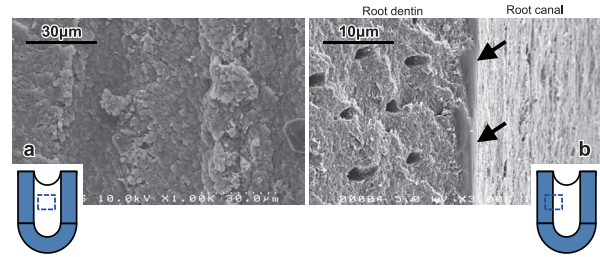


Fig. 2 Representative SEM photographs of the smear layer on root canal wall after root preparation
 a : The surface of the root canal wall was covered with a smear layer.
 b : A smear layer (arrows) of 1-2 µm thickness was observed on the root canal surface.

Study in our department

The detailed effects of root canal irrigation with EDTA and NaOCl are unclear. Our department has focused on developing a suitable root canal irrigation method²³⁾, which we describe in detail below. This study was approved by the Research Ethics Committee of Hokkaido University Graduate School of Dental Medicine (Number 2012-1).

Materials and methods

1) Specimens

Fifty-five human permanent teeth with a single root and single root canal were used in this study. The crowns were cut off all teeth.

2) Percentage of opened dentinal tubules

a) Root canal irrigation

The root canals of 28 permanent teeth were enlarged by a #80 K-file (ISO). Permanent teeth were divided into 4 groups according to root canal irrigation method used with 7 teeth in each group (Table 1). Ultrasonic irrigation was performed using an endodontic tip (ST49-0.8 tip, Osada, Tokyo, Japan ; #30 U-file, Mokuda Dental, Hyogo, Japan) attached to an ultrasonic device (ENAC OE-W10, Osada) (Fig. 3).

Table 1 Methods of root canal irrigation

group	method	time
G1	10%NaOCl, 31%H ₂ O ₂ (alternate use with syringes)	45s
G2	10%NaOCl + ultrasonic device	45s (15s x3)
G3	14%EDTA + ultrasonic device	45s (15s x3)
G4	14%EDTA + ultrasonic device / 10%NaOCl + ultrasonic device	45s (15s x3) / 45s (15s x3)

*ultrasonic device : ENAC OE-W10 (Osada, Tokyo, Japan) with an endodontic tip (ST19A + #30 U-file) at power 1




Fig. 3 Ultrasonic device and endodontic tip

a : The ultrasonic device (ENAC OE-W10 ; Osada)

b : An endodontic tip (ST49-0.8 tip, Osada ; #30 U-file, Mokuda Dental)

b) Observation of root canal walls

Teeth were divided into two sections cut parallel to the tooth axis and fixed in glutaraldehyde in 0.1 M sodium cacodylate buffer (pH 7.4) for 24 h. The specimens were then dehydrated in a graded series of ethanol, dried in a critical-point dryer, and ion sputter coated. The irrigated root canal walls of specimens were observed by scanning electron microscopy (SEM ; HITACHI S-4000, HITACHI, Tokyo, Japan), at an accelerated voltage of 10 kV. SEM photographs were taken at 10 sites in the middle region and four sites in the apical region per tooth. These sites were randomly selected so that each site was not repeated. The middle and apical regions of the canals were scanned to evaluate the amount of smear layer. The percentage of opened dentinal tubules (POD) at the middle and apical regions of canals was calculated by using a SEM photograph taken at $1,500\times$ magnification. Each photograph measured $120\text{ mm} \times 150\text{ mm}$. POD was defined as follows :

$$\text{POD (\%)} = \left[\frac{\text{area of root canal dentin with opened dentinal tubules in an SEM photograph (cm}^2\text{)}}{12 \times 15 (\text{cm}^2)} \right] \times 100.$$

c) Statistical analysis

Differences in POD between groups were statistically analyzed using one-way factorial analysis of variance followed by the posthoc Dunn-Bonferroni test. Statistical

analyses were conducted using SPSS software (IBM, Tokyo, Japan) and p values < 0.01 were considered statistically significant.

3) Ion diffusion at the outer root surface (alkaline environment)

The root canals of 30 permanent teeth were enlarged by a #30 K-file (ISO). Teeth were divided into 3 groups according to root canal dressing material used with 10 teeth in each group. Five root canals of 10 teeth were irrigated by the G1 method in each group, while the other five root canals were irrigated by the G4 method. The root canals were then dressed using three $\text{Ca}(\text{OH})_2$ -based pastes : Calcipex[®] II (Nippon Shika Yakuhin, Tokyo, Japan), Calvital[®] (Neo Dental Chemical Products, Tokyo, Japan), and Vitapex[®] (Neo Dental Chemical Products) (Fig. 4). Calcipex[®] II and Calvital[®] are hydrophilic materials, while Vitapex[®] is a hydrophobic material. The root canal orifice and apical foramen of teeth were blocked by quick self-curing resin (Unifast II, GC, Tokyo, Japan). Then, external root resorption was simulated by creating two resorptive defects on the outer root surface by a round bar. The teeth were embedded in agar culture medium with 1% phenolphthalein, a colorless indicator that becomes pink in alkaline regions (pH > 8.5) (Fig. 5).

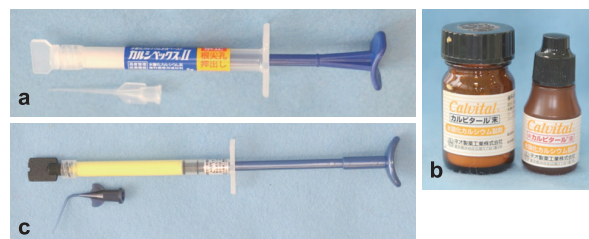


Fig. 4 $\text{Ca}(\text{OH})_2$ -based pastes

a : Calcipex[®] II (Nippon Shika Yakuhin)

b : Calvital[®] (Neo Dental Chemical Products)

c : Vitapex[®] (Neo Dental Chemical Products)



Fig. 5 Embedding of a tooth in agar medium

The color change of the culture medium, indicating ion diffusion from resorptive defects, was observed for 4 weeks. The rate of color change (ion diffusion) was then calculated.

Results

1) Observation of root canal wall

a) Middle region of root canals

In the G1 group, the smear layer was not removed and dentinal tubules were not clear due to the remaining smear layer. In the G2 group, a moderate smear layer was present and dentinal tubules were clear, but few were opened. In the G3 group, the smear layer was removed and many dentinal tubules were opened, but there was some debris on the root canal wall. In the G4 group, the smear layer was removed and many dentinal tubules were clearly opened (Fig. 6).

POD for the G4 group was significantly higher than that of G1, G2, and G3 groups ($p < 0.01$). Additionally, POD for the G3 group was significantly higher than that of G1 and G2 groups ($p < 0.01$). There was no significant difference in POD between G1 and G2 groups (Fig. 7).

b) Apical region of root canals

In the G1 group, the smear layer was not removed and dentinal tubules were not clear due to the remaining smear layer. In the G2 group, a considerable smear layer was present and dentinal tubules were clear, but

few were opened. In the G3 group, the smear layer was removed and many dentinal tubules were opened, but there was some debris on the root canal wall. In the G4 group, the smear layer was removed and many dentinal tubules were clearly opened (Fig. 8).

POD for G3 and G4 groups was significantly higher

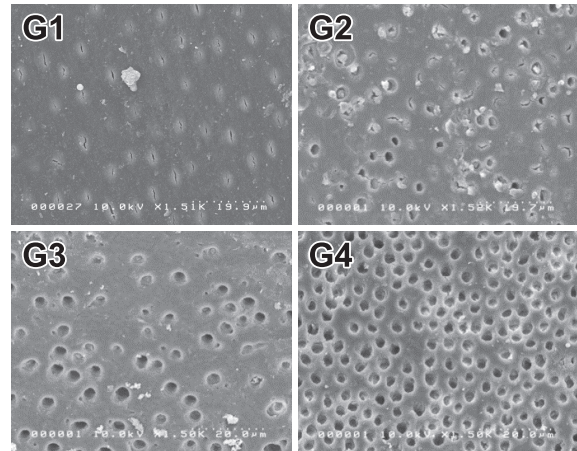
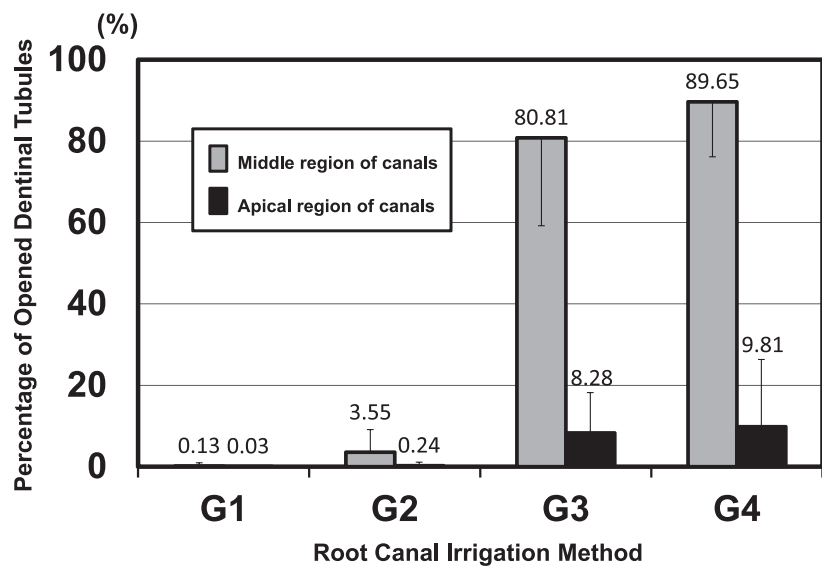


Fig. 6 Representative SEM photographs of the middle region of permanent root canal walls after root irrigation

The effectiveness of smear layer removal by four irrigation methods (G1-G4) was evaluated.

- G1 (NaOCl, H₂O₂ : alternate use with syringes) : Dentinal tubules were not clear due to the remaining smear layer.
- G2 (NaOCl + ultrasonic device) : Dentinal tubules were clear, but few were opened.
- G3 (EDTA + ultrasonic device) : Many dentinal tubules were opened.
- G4 (EDTA + ultrasonic device / NaOCl + ultrasonic device) : Most dentinal tubules were opened.



* $p < 0.01$ Middle region : G3 vs G1, G2 Apical region : G3 vs G1, G2
 G4 vs G1, G2, G3 G4 vs G1, G2

Fig. 7 Percentage of opened dentinal tubules

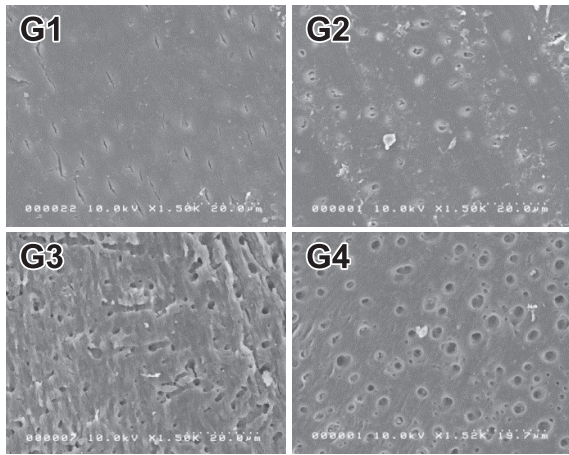


Fig. 8 Representative SEM photographs of the apical region of permanent root canal walls after root irrigation. The effectiveness of smear layer removal by four irrigation methods (G1–G4) was evaluated.

G1 (NaOCl, H₂O₂ : alternate use with syringes) : Dentinal tubules were not clear due to the remaining smear layer.

G2 (NaOCl + ultrasonic device) : Dentinal tubules were clear, but few were opened.

G3 (EDTA + ultrasonic device) : Many dentinal tubules were opened.

G4 (EDTA + ultrasonic device / NaOCl + ultrasonic device) : Most dentinal tubules were opened.

than that of G1 and G2 groups ($p < 0.01$). There was no significant difference in POD between G3 and G4 groups or between G1 and G2 groups (Fig. 7).

2) Ion diffusion of outer root surface

Ion diffusion (alkaline environment) from the root canal to the outer surface cavity was observed by a color change in culture medium due to the reaction of phenolphthalein. G1 specimens hardly showed a medium color change (data not shown). However, color change was observed in Calcipex[®] II and Calvital[®] treated G4 specimens with considerable frequency (Fig. 9a).

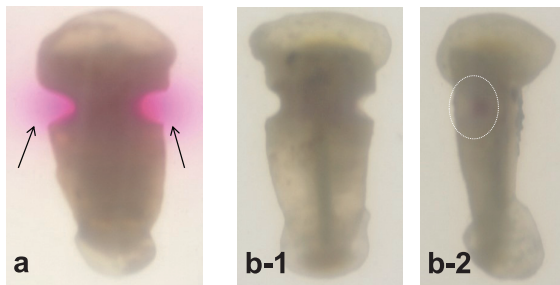


Fig. 9 Color change of agar medium (G4)

a : A clear color change (arrows) was observed with Calcipex[®] II.

b-1 : In Vitapex[®], a color change was observed on the defect surface only (oval). b-2 is a 90° rotation of b-1.

In Vitapex[®] treated G4 specimens, color change was observed on the resorptive defect surface only (Fig. 9b).

Root canal irrigation by G4 showed a high ion diffusion rate. However, Vitapex[®] treated G4 specimens showed color change on the defect surface only. Accordingly, the rate of diffusion of Vitapex[®] treated G4 specimens was “0” (Fig. 10).

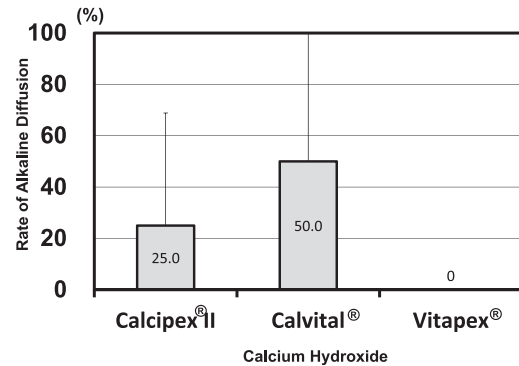


Fig. 10 Rate of ion diffusion

Root canal irrigation in the G4 group showed a high ion diffusion rate. However, Vitapex[®] treated G4 specimens exhibited a color change on the defect surface only. Accordingly, the rate of diffusion was “0”.

Effects of root canal irrigation with an ultrasonic device

The use of EDTA with an ultrasonic device or the combined use of EDTA and NaOCl with an ultrasonic device was effective in removing the smear layer on permanent teeth. This finding suggested that root canal irrigation with an ultrasonic device strongly removed the smear layer on root canal walls, leading to ion diffusion (alkaline environment) from Ca(OH)₂. These results are in agreement with those of previous studies^{18, 20, 22, 24}.

Hydrophilic/hydrophobic materials for root canal dressings

Ion diffusion of Calcipex[®] II and Calvital[®] treated specimens differed from that of Vitapex[®] treated specimens. We speculated this result was due to the chemical behavior of materials (hydrophilic vs. hydrophobic).

Root canal dressing materials composed of Ca(OH)₂ are divided into two main groups : hydrophilic materials such as Calcipex[®] II and Calvital[®] and hydrophobic materials such as Vitapex[®]. The results showed that ion diffusion when using Calcipex[®] II and Calvital[®] was more

widespread and rapid than that of hydrophilic materials occurred more widely and rapidly than that Vitapex®. However, ion diffusion of Calcipex®II and Calvital® did not persist. For Vitapex®, ion diffusion was observed to the outer root surface and continued for a long time. Therefore, when selecting root canal dressing material, the location and progression of external root resorption should be carefully considered.

Clinical approach

In our clinic, traumatized permanent teeth with external root resorption are treated with root canal treatments using a rubber dam.

Here, we describe the treatment of a case of replanted permanent teeth with external root resorption (case report is described in Fig. 11). Root canal irrigation was performed using 14% EDTA (Morphine® for dental liquid, Showa Yakuhin Kako, Tokyo, Japan) with an ultrasonic device for three cycles of 15 s (total time : 45 s), and then the root canal was dried by cotton points. Next, 10% NaOCl (Neo Cleaner, Neo Dental Chemical Products, Tokyo, Japan) was applied with an ultrasonic

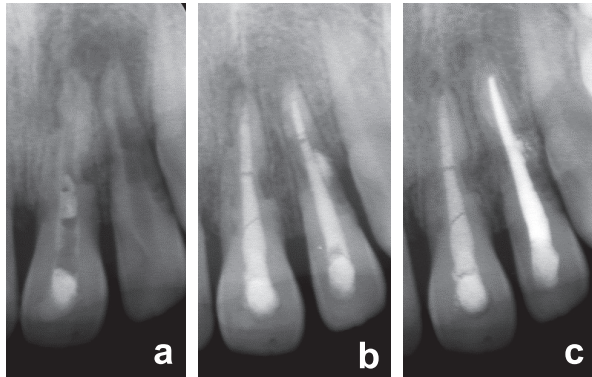


Fig. 11 Treatment of traumatized teeth with external root resorption

X-ray photographs of a case of replantation. A 12-year-old boy fell and his upper left central and lateral incisors avulsed. The teeth were replanted by a general practitioner. Since the replanted teeth showed severe external root resorption at 2 months after replantation, the patient visited our clinic. Severe external root resorption was observed at the initial visit (a). Root canal treatment with Ca(OH)_2 was initiated to control root canal conditions and stop external root resorption. Root canal irrigation with EDTA and NaOCl with an ultrasonic device was performed. After 2 months, external root resorption was stopped mostly by root canal treatments with Ca(OH)_2 -based paste, such as Calcipex®II (b). After 1 year, the periodontal ligament space became normal (c). The root canal dressing used for the upper left central incisor was Calcipex®II, and the root canal dressing used for the lateral incisor was Vitapex®.

device for three cycles of 15 s (total time : 45 s), and then the root canal was dried by cotton points. Ultrasonic irrigation was performed using an endodontic tip (ST49-0.8 tip, Osada ; #30 U-file, Mokuda Dental) attached to an ultrasonic device (ENAC OE-5, Osada).

Root canal dressing using hydrophilic materials such as Calcipex®II was applied during treatment at the initial visit. Widespread and rapid ion diffusion was effective to stop root resorption by neutralizing the resorbed surface. After external root resorption was stopped, hydrophobic materials such as Vitapex® were used before root canal filling (Fig. 11).

A periodic examination was performed every 3 months. The condition of the traumatized tooth was evaluated by inspection, palpation, percussion test, and X-ray photographic examination. After external root resorption was stopped and the continuity of the periodontal ligament space recovered, root canal filling material was changed from Ca(OH)_2 to gutta percha with a sealer.

Root canal irrigation in primary teeth

Most studies examining the effectiveness of root canal irrigation for smear layer removal focused on permanent teeth¹⁷⁻²⁶. Few studies using primary teeth have been reported. Therefore, we sought to determine how root canal irrigation affects smear layer removal in primary teeth.

In our study using primary teeth, conventional needle irrigation with NaOCl could not remove the smear layer effectively. However, ultrasonic irrigation with NaOCl could remove the smear layer. Ultrasonic irrigation with EDTA removed the smear layer more effectively than that with NaOCl, however, erosive effects such as enlargement of the orifices of dentinal tubules were observed on root canal wall dentin (Fig. 12)²⁷.

There are more organic substances and water in the dentin of primary teeth, resulting in a low degree of hardness²⁸. Furthermore, the density of dentinal tubules in primary teeth is greater than that of permanent teeth²⁹. Because of these structural differences, the dentin of primary teeth is more reactive to chemical substances³⁰. Conversely, erosion weakens root dentin^{31, 32}. Therefore, caution is needed when using EDTA in primary teeth. Our study suggested that root canal irrigation with NaOCl using an ultrasonic device is effective for smear layer removal in primary teeth.




Fig. 12 Representative SEM photographs of the middle region of primary root canal walls after root irrigation. The effectiveness of smear layer removal by three irrigation methods (G1, G2, G4) was evaluated.

G1 (NaOCl, H₂O₂ : alternate use with syringes) : Dentinal tubules were not clear due to the remaining smear layer.

G2 (NaOCl + ultrasonic device) : Many dentinal tubules were clear and opened.

G4 (EDTA + ultrasonic device / NaOCl + ultrasonic device) : Most dentinal tubules were opened. However, erosive effects such as enlargement of the orifices of dentinal tubules were observed.

Conclusion

It is difficult to definitively control/stop external root resorption. However, a key factor is the alkaline environment produced by Ca(OH)₂. Root irrigation with EDTA and NaOCl with an ultrasonic device is effective for smear layer removal, and ion diffusion from Ca(OH)₂ occurs from the root canal to outer root surface. Ion diffusion neutralizes acid that is secreted by odontoclasts²⁾ and effectively stops root resorption.

However, root canal treatments of replanted tooth should be completed before addressing external root resorption. Therefore, after replantation of avulsed teeth, dentists should carefully examine the condition of replanted teeth at periodic checkups.

In conclusion, it is more important to prevent root resorption than to stop root resorption.

References

- 1) Andreasen FM, Andreasen JO : 9. Luxation injuries. edited by Andreasen JO, Andreasen FM, Textbook and color atlas of traumatic injuries to the teeth. 3rd edi. 315-382, Munksgaard, Copenhagen, 1993.
- 2) Cvek M : 14. Endodontic management of traumatized teeth. edited by Andreasen JO, Andreasen FM, Textbook and color atlas of traumatic injuries to the teeth. 3rd edi. 517-585, Munksgaard, Copenhagen, 1993.
- 3) American Association of Endodontists Recommended Guidelines : Treatment of the avulsed permanent tooth. Dent Clin North Am 39 : 221-225, 1995.
- 4) Ten Cate AR : 12 Shedding of deciduous teeth. edited by Bhaskar SN, Orban's Oral histology and embryology. 9th edi. 386-403, CV Mosby, St. Louis-Tronto-London, 1980.
- 5) Cawson RA, Binnie WH, Eveson JW : Resorption of teeth, Color atlas of oral disease, clinical and pathologic correlations. 2nd edi. 3.11-3.12, Wolfe, St. Louis, 1994.
- 6) Andreasen JO, Andreasen FM : 10. Avulsions. edited by Andreasen JO, Andreasen FM, Textbook and color atlas of traumatic injuries to the teeth. 3rd edi. 383-425, Munksgaard, Copenhagen, 1993.
- 7) Hugo WB : Inhibition and destruction of the microbial cell. 277, Academic Press, London, 1971.
- 8) Wadachi R, Araki K, Suda H : Effect of calcium hydroxide on the dissolution of soft tissue on the root canal wall. J Endod 24 : 326-330, 1998.
- 9) Safavi KE, Nichols FC : Effects of calcium hydroxide on bacterial lipopolysaccharide. J Endod 19 : 76-78, 1993.
- 10) Tronstad L, Andreasen JO, Hasselgren G, Kristerso L, Riis I : pH changes in dental tissues after root canal filling with calcium hydroxide. J Endod 7 : 17-21, 1981.
- 11) Lengheden A, Blomlöf L, Lindskog S : Effect of delayed calcium hydroxide treatment on periodontal healing in contaminated replanted teeth. Scand J Dent Res 99 : 147-153, 1991
- 12) Fuss Z, Tsesis I, Lin S : Root resorption-diagnosis, classification and treatment choices based on stimulation factors. Dent Traumatol 19 : 175-182, 2003.
- 13) McComb D, Smith DC : A preliminary scanning electron microscopic study of root canals after

- endodontic procedures. *J Endod* 1 : 238-242, 1975.
- 14) Mader CL, Baumgartner JC, Peters DD : Scanning electron microscopic investigation of the smeared layer on root canal walls. *J Endod* 10 : 477-483, 1984.
 - 15) Fogel HM, Pashley DH : Dentin permeability : Effects of endodontic procedures on root slabs. *J Endod* 16 : 442-445, 1990.
 - 16) Sen BH, Wesselink PR, Turukun M : The smear layer : a phenomenon in root canal therapy. *Int Endod J* 28 : 141-148, 1995.
 - 17) Hata G, Hayami S, Weine FS, Toda T : Effectiveness of oxidative potential water as a root canal irrigant. *Int Endod J* 34 : 308-317, 2001.
 - 18) Kumar P, Prasad N, Darawade A, Bhagat SK, Vanamala N, Darawade P : The effect of four commonly used root canal irrigants on the removal of smear layer : an in-vitro scanning electron microscope study. *J Int Oral Health* 7(9) : 88-93, 2015.
 - 19) Torabinejad M, Handysides R, Khademi AA, Bakland LK : Clinical implications of the smear layer in endodontics: a review. *Oral Surg Oral Med Oral Pathol Oral Radiol Endod* 94 : 658-666, 2002.
 - 20) Yamada RS, Armas A, Goldman M, Lin PS : A scanning electron microscopic comparison of high volume final flush with several irrigating solutions : Part 3. *J Endod* 9 : 137-142, 1983.
 - 21) Rome WJ, Doran JE, Walker 3rd WA : The effectiveness of Gly-Oxide and sodium hypochlorite in preventing smear layer formation. *J Endod* 11 : 281-288, 1985.
 - 22) Lui JN, Kuah HG, Chen NN : Effect of EDTA with and without surfactants or ultrasonics on removal of smear layer. *J Endod* 33 : 472-475, 2007.
 - 23) Yawaka Y : The endodontic study for the control of resorption on outer root surface with dental trauma. *Int J Paed Dent* 23 (Suppl.) : 146, 2013.
 - 24) Clegg MS, Vertucci FJ, Walker C, Belanger M, Britto LR : The effect of exposure to irrigant solutions on apical dentin biofilms in vitro. *J Endod* 32 : 434-436, 2006.
 - 25) Garberoglio R, Becce C : Smear layer removal by root canal irrigants. *Oral Surg Oral Med Oral Pathol* 78 : 359-367, 1994.
 - 26) Khedmat S, Shokouhinejad N : Comparison of the efficacy of three chelating agents in smear layer removal. *J Endod* 34 : 599-602, 2008.
 - 27) Toyota Y, Yoshihara T, Hisada A, Yawaka Y : Removal of smear layer by various root canal irrigations in primary teeth. *Ped Dent J* 27 : 8-13, 2017.
 - 28) William TB : Dentin collagen : chemical structure and role in mineralization. edited by Linde A, Dentin and dentinogenesis, vol II. 37-54, CRC Pres Inc, Boca Raton, 1984.
 - 29) Sumikawa DA, Marshall GW, Gee I, Marshall SJ : Microstructure of primary tooth dentin. *Pediatr Dent* 21 : 439-444, 1999.
 - 30) Nör JE, Feigal RJ, Dennison JB, Edwards CA : dentin bonding : SEM comparison of the resin-dentin interface in primary and permanent teeth. *J Dent Res* 75 : 1396-1403, 1996.
 - 31) Calt S, Serper A : time-dependent effects of EDTA on dentin structures. *J Endod* 28 : 17-19, 2002.
 - 32) Dadresanfar B, Khalilak Z, Delvarani A, Mehrvarzfar P, Vatanpour M, Pourassadollah M : Effect of ultrasonication with EDTA or MTAD on smear layer, debris and erosion scores. *J Oral Sci* 53 : 31-36, 2011.