



Title	Application of poly CDME (PCDME) gel to the palatal plate
Author(s)	Kaneko, Tomoo; Mikoya, Tadashi
Citation	北海道歯学雑誌, 38(Special issue), 136-139
Issue Date	2017-09
Doc URL	http://hdl.handle.net/2115/67352
Type	article
File Information	19_Tomoo Kaneko.pdf



[Instructions for use](#)

Application of poly CDME (PCDME) gel to the palatal plate

Tomoo Kaneko and Tadashi Mikoya

Department of Stomatognathic Function, Center for Advanced Oral Medicine, Hokkaido University Hospital

ABSTRACT : In some patients with cleft lip and palate, the palatal cleft is wide and three-dimensionally deformed at birth. This can result in difficulty in sucking, which subsequently causes poor weight and development. The resin-based palatal plate for patients is maintained in position with retentive components such as a ball clasp and Adams clasp. In this study, we report on our experience conducting research and developing a palatal plate that consists of PCDME [Poly-N-(carboxymethyl)-N,N-dimethyl-2-(methacryloyloxy) ethanaminium] gel adhered to a polycarbonate frame. The gel is viscous and adheres to the mucosa, thereby maintaining the plate. Moreover, there are no retentive components, such as clasps for attachment and detachment ; therefore, it can be worn with a comfortable fitting, *i.e.*, tight and with sufficient pressure. If this device is put to practical use, the burden on patients with cleft palate could be reduced considerably.

Key Words : palatal plate, PCDME gel, cleft lip and palate, speech therapy, adhesiveness

Introduction

In patients with cleft lip and palate, the palatal cleft is wide and three-dimensionally deformed at birth. This results in difficulty in sucking, which subsequently causes poor weight and development. By attaching a Hotz plate to the maxilla immediately after birth, the entry of the tongue and the nipple into the cleft is prevented. This promotes natural growth, enabling the maxillary arch to attain its normal morphology, and ameliorates the difficulty in sucking (Figs. 1, 2). Attaching a Hotz plate and adjusting the maxillary morphology to serve

as the foundation of the upper lip and nose can lead to better results of cheiloplasty, which is generally performed at 3 to 5 months of age. In palatoplasty, the initial operative treatment limited to closure of the soft palate is performed at the age of approximately 1½ years, with the intention of minimizing surgical invasiveness and jaw development disorder. A two-stage method is adopted for the cleft of the hard palate, which is closed at approximately 6 to 7 years of age, in addition to performing alveolar bone graft. The site of communication between the nasal and oral cavities in the hard palate is closed from the palatal floor to prevent

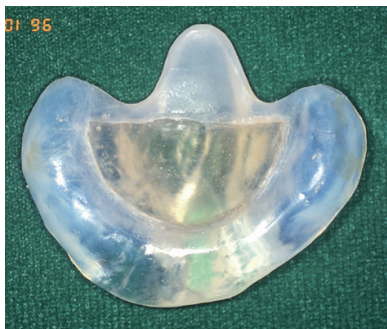

Fig. 1 Hotz plate

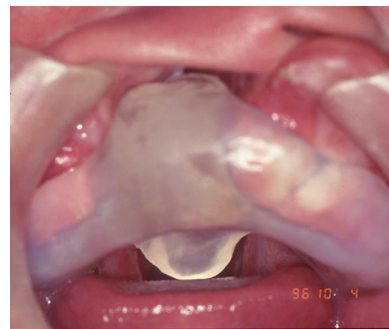

Fig. 2 Hotz plate attached

Address of Correspondence

Tomoo Kaneko, DDS, PhD.

Department of Stomatognathic Function, Center for Advanced Oral Medicine, Hokkaido University Hospital, Kita 14, Nishi 5, Kita-ku, Sapporo, 060-8648, Japan

TEL : +81-11-706-4287 ; FAX : +81-11-706-4287 ; E-mail : tmkaneko@den.hokudai.ac.jp

exhalational nasal discharge and to prevent hindrance in language development¹⁻⁴⁾.

The resin-based palatal plate is maintained in position with retentive components such as ball clasp and Adams clasp. However, clasping of the palatal plate may cause gingivitis and hinder the lateral growth of the teeth. Therefore, here, we report our experience conducting research and developing a palatal plate that does not use clasps in collaboration with the Laboratory of Soft & Wet Matter, Faculty of Advanced Life Science, Hokkaido University Graduate School.

1. Palatoplasty

The pushback method has been conventionally used for one-stage operative treatment; however, as this method leaves a large scar on the entire palate (*i.e.*, it is a highly invasive surgical procedure), it has the disadvantage of hindering future maxillary growth.

In two-stage operative treatment, an initial surgery is performed to close the posterior half of the palate (soft palate). A surgery to close the anterior half (hard palate) is subsequently performed at the age of 5 years or later. By minimizing the invasiveness of the surgery, smooth maxillary growth can be expected even after the initial surgery, and developmental disorders of the midface (maxilla and nose) can be minimized. However, as there is a possibility of air leakage from the anterior part of the

palate, which still communicates with the nose, precise management is necessary after the initial surgery so as to prevent problems in speaking; therefore, a palatal plate is attached at this time.

Periodic postoperative follow-up is performed by a speech-language-hearing therapist, to assess the verbal development while wearing the palatal plate. The soft palate gradually moves from approximately three months postoperatively, enabling the actions of blowing and sucking to be incorporated into play in daily life (*e.g.*, blowing into a straw, blowing a harmonica). Moreover, rehabilitative training of the muscular movement of the soft palate necessary to master correct pronunciation (articulation) is performed.

The palatal plate is a device similar to a denture and blocks the nasal leakage of air from the anterior portion of the palate to prevent mispronunciation.(Figs. 3, 4)

2. Overview of the palatal plate in the present study

We obtained an impression of the maxillary dentition model with an alginate-based impression material and made a silicone dentition model using a silicone-based impression material (Memosil 2 ; Heraeus Kulzer Japan Co., Ltd.). (Fig 5)

Using a 1-mm polycarbonate plate (Impreleon ; Rocky Mountain Morita Corporation) for the maxillary dentition model, a frame was prepared with Biostar (Rocky

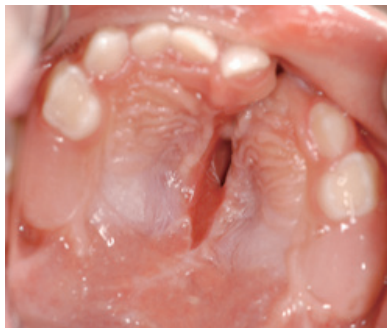

Fig. 3 After palatoplasty

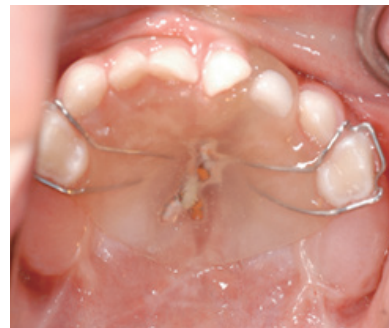

Fig. 4 Palatal plate attached



Fig. 5 Silicone dentition model




Fig. 6 Polycarbonate frame

Mountain Morita Corporation). (Fig. 6)

The method of preparing PCDME gel is as follows : an aqueous solution of CDME (monomer) and crosslinking agent was allowed to flow into a silicone dentition model (Memosil 2 ; Heraeus Kulzer Japan Co., Ltd.). This was overlaid with an initiator-coated polycarbonate frame (Imprelon; Rocky Mountain Morita Corporation) and irradiated with ultraviolet light (365 nm) for 8 hours in an argon atmosphere for polymerization. After polymerization, the polycarbonate frame to which the gel was adhered was removed from the silicone dentition model and washed with pure water (Fig. 7).

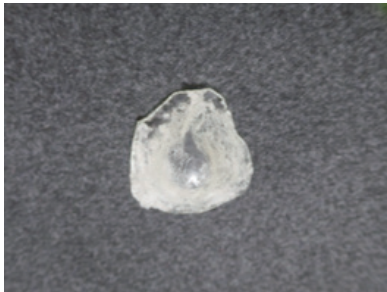


Fig. 7 PCDME gel palatal plate

This palatal plate consists of PCDME [Poly-N-(carboxymethyl)-N,N-dimethyl-2-(methacryloyloxy) ethanaminium] gel adhered to a polycarbonate frame (Fig. 8). The gel is viscous and adheres to the mucosa, thereby maintaining the plate.

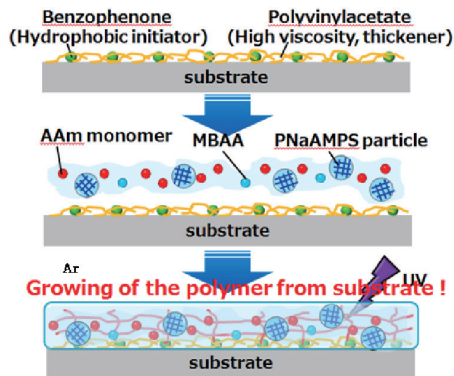


Fig. 8 PCDME [Poly-N-(carboxymethyl)-N,N-dimethyl-2-(methacryloyloxy) ethanaminium]

3. Method to manufacture PCDME gel

To prepare the polymerization initiator solution, polyvinyl acetate and benzophenone were dissolved in acetone. The solution ratio is polyvinyl acetate (2g), benzophenone (0.3g), acetone (100g). To prepare the monomer solution, N-dimethyl-2- (methacryloyloxy)

ethanaminium, inner salt (monomer ; CDME), and crosslinking agent were dissolved in pure water. The solution ratio was 1 mol/L CDME concentration, 1 mol% crosslinking agent concentration relative to CDME. It was irradiated with ultraviolet light (wavelength 365nm) for 8 hours in an argon atmosphere and polymerized. After polymerization, it was washed with pure water.

4. Adhesiveness of the gel

The gel swells when it contains moisture, and the adhesiveness changes with the degree of moisture. Therefore, the PCDME gel set to 1-mm thickness on completion of polymerization. After washing with pure water, the expanded gel was dried in a room and the moisture content of the entire sample was measured. The results are shown in Table 1. The thickness, weight, and adhesiveness of the gel at that time were also observed and the viscosity was assessed (Table 2). Thus, viscosity was obtained from the PCDME gel in specific wet state.

Table. 1 The adhesiveness changes with the degree of moisture

Gel thickness (mm)	Moisture content (%)
1.56	89.26
0.39	78.21

Table. 2 The thickness, weight, and adhesiveness of the gel at that time were also observed and the viscosity was assessed.

Drying and hardening time (hours)	Thickness (mm)	Weight (g)	Adhesiveness
0	1.12	6.21	Absent
2	0.93	5.4	Absent
3	0.83	5.01	Absent
4.5	0.77	4.56	Present
23.5	0.34	4.58	Present

5. Future outlook

The PCDME gel used in the present study appears to be influenced by the moisture in the oral cavity as it has the properties of absorbing moisture, swelling, and changing the degree of adhesion depending on the degree of wetness. By attaching the polycarbonate frame inside the oral cavity and attaching the PCDME gel to the mucosal side, it was possible to reduce the influence of the moisture in the oral cavity and perform adjustments, so that moderate wetness and adhesion to the mucosa could be obtained in the present study. In addition, thinning the PCDME gel may reduce the expansion rate. While applying the palatal plate, the moisture content

at which the adhesiveness is maximized is adjusted, the wet state changes by wearing, and the moisture content rises ; it appears to have regenerated by drying in the air. In addition, it appears that this PCDME gel possesses sufficient adhesion to the polycarbonate frame and does not detach from it. Moreover, the durability of the device can be maintained by the frame.

Since the PCDME gel palatal plate is maintained by its adhesiveness, it can be used from the time of tooth eruption and applied to the Hotz plate. Expansion of the maxillary teeth, which promotes further growth of the maxilla, can also be performed by utilizing the expanding property of the gel. Moreover, there are no retentive components such as clasps for attachment and detachment ; therefore, it can be worn with a tight feeling or feeling of pressure. Attachment and detachment of the plate can be performed by legal guardian, without causing any damage to the oral cavity.

Conclusion

PCDME gels applied to this palatal plate must be approved under the Pharmaceutical Affairs Act. However, if this device is put to practical use, the burden on patients with cleft palate would be reduced considerably. In addition, speech therapy by a speech-language-hearing therapist would also contribute greatly to the rehabilitation. This material can be applied to the mucosal surface of the floor such as the denture and may be an innovation in the field of dentistry.

Acknowledgments

We are indebted to Associate Professor Takayuki Kurokawa and Yukiko Hane of the Laboratory of Soft & Wet Matter, Faculty of Advanced Life Science, Hokkaido University Graduate School for preparation of the PCDME gel and cooperation in the present study.

References

- 1) Mikoya T, Matsuzawa Y, Sogabe I, Ito Y, Yamamoto E, Sibukawa T, Kaneko T, Mikami A, Imai S, Donen M, Murakami Y, Watanabe M, Nakamura E, Inoue N, Totsuka Y : Clinico-statistical Study of Cleft Lip and/or Plate Patients in the Past 16 years at the Center for Advanced Oral Medicine, Hokkaido University Hospital. *J. Jpn. Cleft Palate Assoc.* 36 :166-173, 2011.
- 2) Mikoya T, Inoue N, Matsuzawa Y, Totsuka Y, Kajii TS, Hirokawa T. : Monocortical mandibular bone grafting for reconstruction of alveolar cleft. *Cleft Palate Craniofac J.* 47 : 454-468, 2010.
- 3) Sogabe I, Mikoya T, Sibukawa T, Imai S, Ishikawa A, Matsuzawa Y, Ito Y, Matsuoka M, I, Yamamoto E, Kaneko T, Michida T, Tei K : Speech Outcome in Patients with Cleft Lip and Palate Following Two-stage Palatoplasty -At the Age of 4 and 5 Years-. *J. Jpn. Cleft Palate Assoc.* 39 : 7-16, 2014.
- 4) Mikoya T, Shibukawa T, Susami T, Sato Y, Tengan T, Katashima H, Aoyama A, Matsuzawa Y, Ito Y, Funayama E : Dental Arch Relationship Outcomes in One- and Two-Stage Palatoplasty for Japanese Patients with Complete Unilateral Cleft Lip and Palate. *The Cleft Palate-Craniofacial Journal* 52 : 277-286, 2015.