



Title	Treatment of infected root canals with 4-META/MMA-TBB resin
Author(s)	Sugaya, Tsutomu; Tanaka, Saori; Miyaji, Hirofumi; Shimoji, Shinji; Kudo, Megumi; Takefu, Hiroe; Washizu, Taro
Citation	北海道歯学雑誌, 38(Special issue), 111-121
Issue Date	2017-09
Doc URL	http://hdl.handle.net/2115/67349
Type	article
File Information	16_Tsutomu Sugaya.pdf



[Instructions for use](#)

Treatment of infected root canals with 4-META/MMA-TBB resin

Tsutomu Sugaya¹⁾, Saori Tanaka²⁾, Hirofumi Miyaji¹⁾, Shinji Shimoji¹⁾, Megumi Kudo¹⁾,
Hiroe Takefu¹⁾ and Taro Washizu¹⁾

¹⁾ Periodontology and Endodontology, Department of Oral Health Science, Faculty of Dental Medicine and Graduate School of Dental Medicine, Hokkaido University, ²⁾ Center for Dental Clinics, Division of General Dentistry, Hokkaido University Hospital

ABSTRACT : This review paper describes the various applications of 4-methacryloxyethyl trimellitate anhydride/methyl methacrylate-tri-n-butyl borane (4-META/MMA-TBB) and reviews research studies on the treatment of infected root canals using 4-META/MMA-TBB resin. 4-META/MMA-TBB resin exhibits good biocompatibility, polymerisation, and adhesiveness to dentine. As a result, it has improved the previously low success rates of root-end sealing, root canal filling, and perforation sealing in difficult cases. Root-end sealing of resected surfaces using 4-META/MMA-TBB during apicoectomy and intentional replantation prevents leakage from root canal and root resorption. 4-META/MMA-TBB can offer sealing for root canals with opened root apex in which pressure could not be applied during root canal filling. In this paper we will discuss clinical cases related to the application of this resin and the benefits of 4-META/MMA-TBB resin.

Key Words : 4-META/MMA-TBB resin, infected root canal, sealing, biocompatibility

Introduction

4-META/MMA-TBB resin (Super-Bond, Sun Medical, Shiga, Japan) can achieve a high rate of polymerization even when moisture is present because it uses tri-n-butyl borane (TBB) as its polymerization initiator^{1, 2)}. It exhibits excellent biocompatibility even when it polymerizes on tissues³⁻¹¹⁾. As it offers both biocompatibility and adhesiveness to dentin, it is now possible to manage cases that had previously been considered difficult to treat. This material has increased previously low success rates of root-end sealing, perforation sealing, and root canal filling in difficult cases.

Root-end sealing

1. The advantages of root-end sealing

Apicoectomy and intentional replantation require retrograde filling of the root canal, but when surgery has to be performed with the infected root canal because

preoperative root canal therapy is not performed for reasons such as a post and/or crown that cannot be removed, excellent sealing ability is required to prevent leakage from the root canal and accessory canals. The microleakage is not completely inhibited in vitro with amalgam, zinc oxide eugenol cement, glass ionomer cement or mineral trioxide aggregate (MTA)¹²⁻²²⁾. Furthermore, when the root canal has not been cleaned, bacteria can enter the dentinal tubules²³⁾ and, if the resected surface is exposed to the infected dentinal tubules, this can lead to inflammation of the surrounding tissue and inflammatory resorption of the root²⁴⁾. Root-end sealing, whereby adhesive resin is applied to the entire resected surface, can solve all of these problems (Fig. 1).

Applying a bonding agent to a resected root end has been shown to reduce microleakage²⁵⁻²⁷⁾. Resin is known to be sensitive to moisture during application, and this could potentially lead to poor clinical results²⁸⁾. Thus, Super-Bond might be suitable for retrograde root sealing following apicoectomy or intentional replantation.

Address of Correspondence

Tsutomu Sugaya, DDS, PhD.

Periodontology and Endodontology, Department of Oral Health Science, Faculty of Dental Medicine and Graduate School of Dental Medicine, Hokkaido University, Kita 13 Nishi 7 Kita-ku, Sapporo, Hokkaido 060-8586, Japan

TEL : +81-11-706-4266 ; E-mail : sugaya@den.hokudai.ac.jp

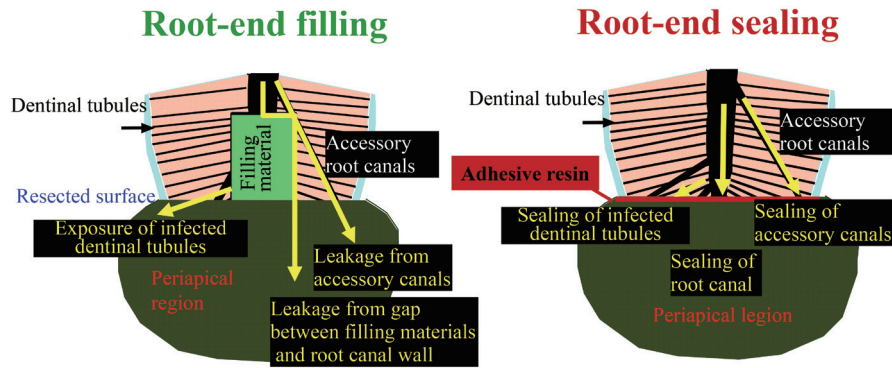


Fig. 1 Root-end filling and root-end sealing.

2. Coronal sealing ability

In a previous study, crowns and root-ends of extracted teeth were removed. In some roots, the root canal was prepared and retrograde cavity preparation was performed before filling with Spherical-D (Shofu, Kyoto, Japan) or Super-EBA (Harry Bosworth Co., Skokie, IL, USA) while in other roots, root-end sealing was performed with Super-Bond. Methylene blue was then poured into the root canals and leakage volume from the root apices was measured over 50 weeks. The control group consisted of root apices that were not sealed²⁹.

In the control group, all the methylene blue had quickly leaked out from the root apex. A large amount of dye also leaked from root apices where amalgam had been used. Although the leakage for Super-EBA was small, all specimens did exhibit leakage after 32 weeks. No root apices sealed with Super-Bond exhibited any leakage at 50 weeks (Fig. 2).

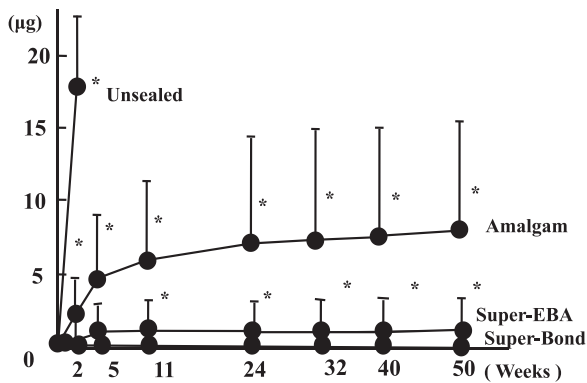


Fig. 2 Integrated amount of dye leakage from root apex
* : significant difference compared with Super-Bond p<0.05

3. Healing after intentional replantation

In a beagle dog study, tooth crowns were removed, the root canals were prepared, and bacterial infection was induced within the root canals³⁰. Eight weeks later,

radiographs were used to confirm periapical lesions and intentional replantation was performed. The root-ends of the extracted teeth were resected. Retrograde cavities 3-mm deep were prepared and filled with amalgam or Super-EBA cement or root-end sealing was performed with Super-Bond before replantation. In the control group, root-ends were resected and the apex was not sealed. Root canals were not cleaned or filled in any of the groups.

Four and eight weeks postoperatively, undecalcified specimens were prepared and bone defect and root resorption were assessed. After eight weeks, bone was formed close to Super-Bond and bone defect area was

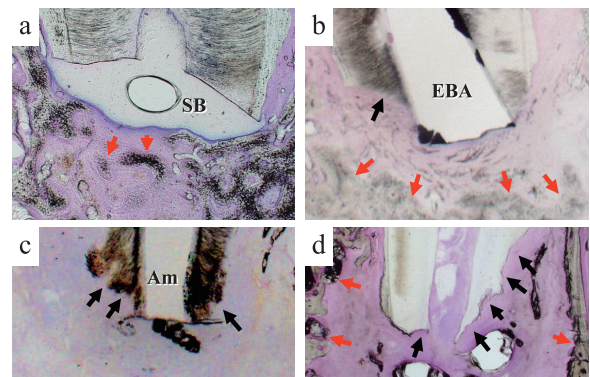


Fig. 3 Healing after intentional replantation (8 weeks later)
a : Super-Bond, b : Super-EBA, c : Amalgam, d : Control.

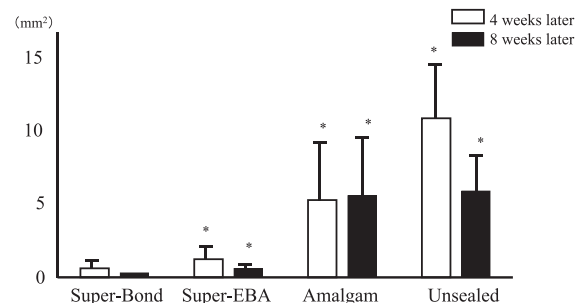


Fig. 4 Bone defect area after intentional replantation
* : Significant difference comparison with Super-Bond p< 0.05

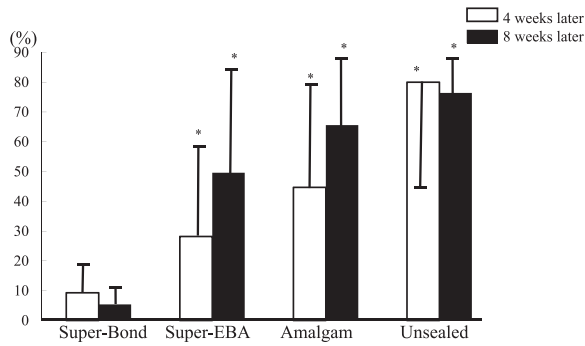


Fig. 5 Root resorption rates after intentional replantation
* : Significant difference comparison with Super-Bond $p < 0.05$

reduced with Super-EBA (Fig. 3), but root resorption was exacerbated in the other three groups. The bone defect area (Fig. 4) and root resorption area (Fig. 5) were smaller in the Super-Bond group than the other three groups at both four and eight weeks.

4. Healing after apicoectomy

Beagle tooth crowns were removed, root canals were prepared, and bacterial infection was induced within root canals. Eight weeks later, radiographs were used to confirm whether lesions had formed in the root apex regions and apicoectomy was performed^{31,32}. Tooth root-end exposed in the bone defect was resected and root-end sealing with Super-Bond was performed on some specimens, while retrograde filling with Super-EBA or

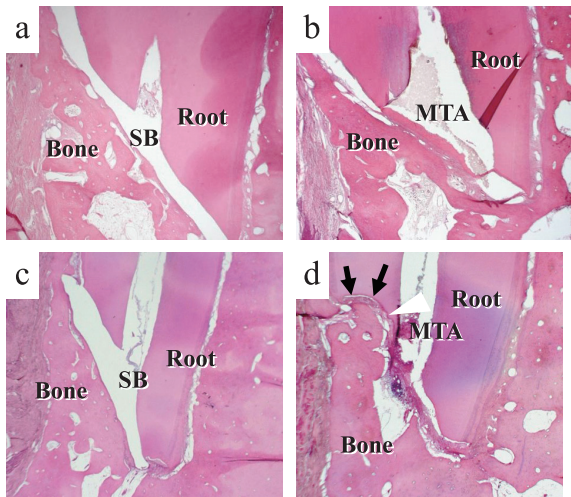


Fig. 6 Healing after apicoectomy

- a : Super-Bond (12 weeks later)
 - b : ProRoot MTA (12 weeks later)
 - c : Super-Bond (48 weeks later)
 - d : ProRoot MTA (48 weeks later), root resorption can be observed (arrows)
- Super-Bond and MTA were dissolved during specimen preparation.

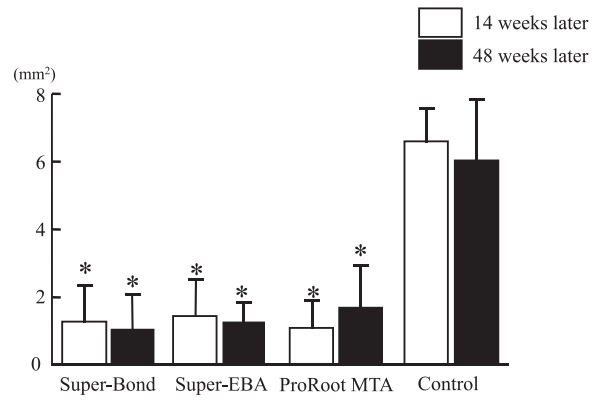


Fig. 7 Bone defect area after apicoectomy

Bone defect area was significantly smaller in the three non-control groups compared with control group.

* : Significant difference comparison with control $p < 0.05$

ProRoot MTA (Dentsply Tulsa Dental, Johnson City, TN, USA) was performed on other specimens. Control group specimens had root apex resection with no root apex sealing. The root canal was not cleaned in all specimens. After 12 and 48 weeks, decalcified specimens were prepared and histopathologically assessed.

After 12 weeks (Fig. 6), bone defect areas were reduced in both the Super-Bond, Super-EBA and MTA groups, with significant differences noted compared with the control group. However, no significant differences were noted between the three non-control groups (Fig. 7). The state of the bone defect areas remained unchanged after 48 weeks, although some root resorption was noted.

Root resorption is known to occur after replantation, but it can also occur over the long-term after apicoectomy if the root canal is infected. Therefore, we considered that root-end sealing, which covers the entire resected surface, appeared to be the most reliable method.

5. Influence of blood contamination

1) Inhibition of adhesion

Fresh, human, whole blood was applied to bovine dentin surface before being treated for five seconds with Green Activator (Sun Medical, Shiga, Japan) or after treatment with Green Activator. Air blowing, rinsing or repeated tooth surface treatment were then performed, after which Super-Bond was applied^{33, 34}. Adhesive surface before applying Super-Bond and interface between dentin and Super-Bond were observed with a scanning electron microscope (SEM) and microtensile bond strength (μ TBS) measurement and dye penetration test were performed.

Results indicated that when the pre-treated tooth surface was contaminated with blood, conventional tooth

surface treatment resulted in good adhesion. However, when blood contaminates the surface after tooth surface treatment, fibrin could not be removed with air blowing or rinsing alone, creating a gap with the adhesive interface. Retreatment of contaminated surface with Green Activator led to good adhesion (Fig. 8). By rinsing after blood contamination following tooth surface treatment, μ TBS was significantly decreased compared with the control group ($p < 0.05$). Retreatment of contaminated surface led to μ TBS that did not differ significantly from the control group ($p > 0.05$). The results of dye penetration test indicated that length of dye penetration in the rinsing after blood contamination following tooth surface treatment was significantly more than control, but that of retreatment of the contaminated surface was not significantly different from the control (Fig. 9).

The results of this experiment indicated that when performing root-end sealing, it is important to properly perform hemostasis.

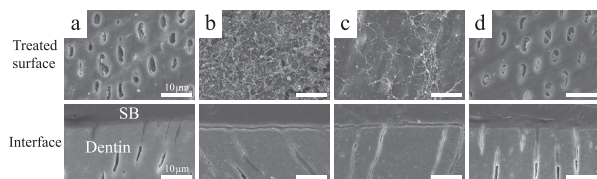


Fig. 8 Treated surfaces and interfaces between dentin and Super-Bond after blood contamination and retreatment of contaminated surface

a : Contamination, surface treatment and rinsing, b : Surface treatment, contamination and air blowing, c : Surface treatment, contamination and rinsing, d : Surface treatment, contamination and retreatment.

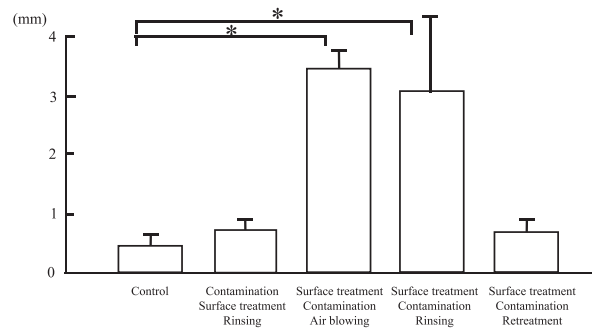


Fig. 9 Dye penetration length after blood contamination and surface treatment

* : Significant difference $p < 0.05$

2) Influence of blood contamination time after application of Super-Bond on sealing ability

Human extracted teeth and root-end were resected, after which retrograde cavities were prepared. They

were either filled with Super-EBA or performed root-end sealing with Super-Bond. Super-EBA group specimens were immersed in human whole blood 5 minutes after filling, while Super-Bond group specimens were immersed two seconds, five seconds, 10 seconds and five minutes after application³⁵.

The results of dye penetration testing indicated that there was only a slight amount of dye penetration caused by immersion in blood two seconds and five minutes after application of Super-Bond to the resected surface, with no significant difference. At each of the immersion times, length of dye penetration was significantly less than in the Super-EBA group (Fig. 10). It appeared that the fact that rapidly polymerizing Super-Bond at the dentin surface, thus achieving adhesion, ensured that dye did not penetrate the interface between dentin and resin even when specimens were immersed in blood for a short time.

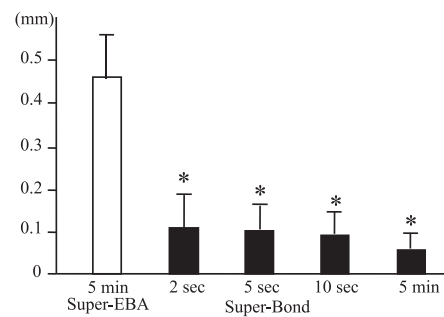


Fig. 10 Blood contamination time after application of Super-Bond and length of dye penetration

* : Significant difference compared with Super EBA $p < 0.05$

3) Blood contamination and biocompatibility

In order to clarify whether covering Super-Bond in blood during polymerization would inhibit polymerization and reduce biocompatibility, Super-Bond with three different polymerization environments was transplanted onto rat dorsal connective tissue and histopathologically evaluated³⁶. The Super-Bond polymerization environments were as follows. (1) A Super-Bond mixture paste was applied to connective tissue and the skin flap was sutured five seconds later so that polymerization occurred while covered in blood. (2) Super-Bond that had undergone polymerization while exposed to air for 10 minutes was transplanted. (3) Super-Bond of (2) was transplanted after polishing.

Results found that Super-Bond surfaces left to undergo polymerization while exposed to air exhibited inflammatory cell infiltration of mainly lymphocytes, while hardly any inflammation occurred when polymerization occurred in the specimens that underwent polymerization

while covered in blood or the specimens with polished surfaces (Fig. 11). This may have been because Super-Bond exhibits higher surface polymerization rates when not exposed to air and the blood acted as an air barrier, and/or because metal ions in the blood such as Fe²⁺ increased the polymerization rate^{2, 37}. While the exact reason remains unknown, it appears that hemostasis until polymerization of Super-Bond is complete actually decreases biocompatibility.

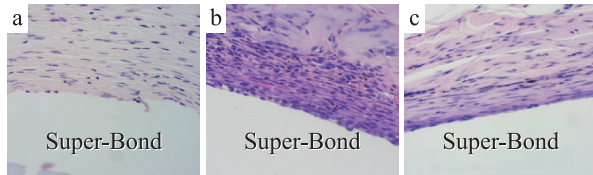


Fig. 11 Super-Bond polymerization environments and tissue reactions (1 week later)

a : Covered with blood 5 s. later, b : Polymerization while exposed to air for 10 m., c : Polishing after cure Super-Bond was dissolved while specimen preparation.

6. Case of intentional replantation

A 60-year-old female exhibited a large periapical lesion in the right mandibular first premolar. As no improvement was seen with root canal therapy, intentional replantation was performed. For intentional replantation, the root-end was resected and root-end sealing was performed with Super-Bond (Clear type). The periapical lesion disappeared and 6 years later no root resorption was apparent (Fig. 12).

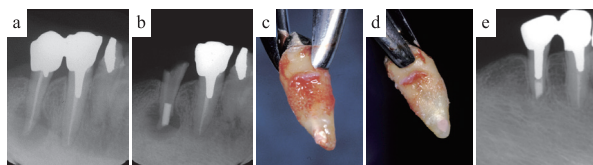


Fig. 12 A case in which intentional replantation was performed with root-end sealing using Super-Bond

a : Initial examination, b : After root canal filling, c : Tooth extraction, d : Root-end sealing, e : 6 years later

7. Apicoectomy case

A 37-year-old male had a fistula in maxillary left canine and first premolar and the radiograph exhibited a periapical lesion (Fig. 13). Resection of the root-end revealed contamination between the root canal and gutta-percha point. However, root-end sealing with Super-Bond was performed without cleaning the root canal and the flap was sutured. Eleven years later, neither root resorption nor periapical lesion was observed.

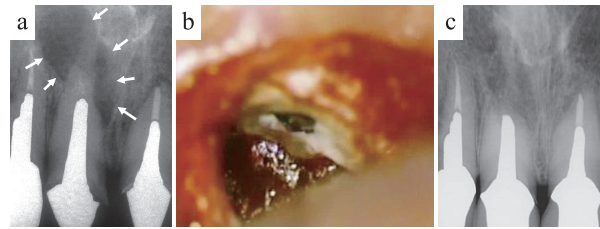


Fig. 13 A case in which apicoectomy was performed with root-end sealing using Super-Bond

a : Initial examination, b : After apicoectomy, c : 11 years later

8. Clinical outcomes

Table 1 shows the prognoses of cases that underwent apicoectomy or intentional replantation with root-end sealing. Apicoectomy failed in five of the 35 cases for which root canal preparation could not be performed preoperatively, while it did not fail in any of the cases that had undergone root canal preparation³⁸. All cases that underwent replantation also underwent root canal preparation preoperatively, but replantation failed in two cases. Although it has been reported that performing apicoectomy without preoperative root canal enlargement leads to a poor clinical outcome, root-end sealing with Super-Bond achieved relatively good outcomes and there was no statistically significant difference between cases in which root canal preparation was or was not performed preoperatively.

Root-end sealing can be performed even in cases with long posts exposed through the resected surface, which can be considered as an additional indication for apicoectomy.

Table 1. Clinical outcomes after root-end sealing with Super-Bond

	Preoperative root canal preparation	Complete healing	Incomplete healing	Failures
Apicoectomy	No : 35 (teeth)	22	8	5
	Yes : 10 (teeth)	8	2	0
Replantation	Yes : 25 (teeth)	18	6	2

Root perforation sealing

1. Tissue reaction when Super-Bond is used for adhesion of artificial perforations

Pulp chamber floors of cat molars were artificially perforated with a 1/2 round bur. Some roots were sealed with Super-Bond after applying activated liquid to the perforated sites while other roots were sealed with Super-Bond without applying the activated liquid. Four

weeks later, the two groups were histopathologically compared. Results indicated strong inflammation mainly in lymphocytes and some root absorption with odontoclasts (arrows) in the cases in which activated liquid was applied to the perforated site (Fig. 14a)³⁹. Super-Bond formed a hybrid layer with the periodontal ligament and a small number of giant cells (arrows) appeared directly under the hybrid layer and no infiltration of inflammatory cells such as lymphocytes was apparent in the cases in which activated liquid was not applied (Fig. 14b). Inflammatory cell infiltration area was significantly smaller in the perforation sealed without applying activated liquid than those sealed after activated liquid was applied and non-sealed perforations (Fig. 15).

Activated liquid application enhances wettability of the resin, but it may cause inflammation. As sufficient sealing can be achieved without applying it, it is recommended that sealing be performed without applying activated liquid to the perforated site.

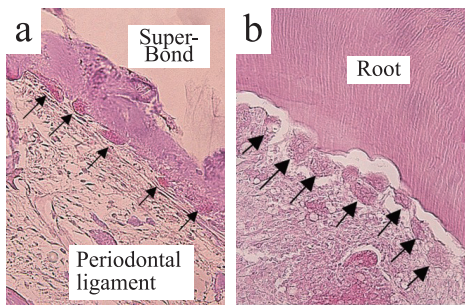


Fig. 14 Perforated site of pulp chamber floor sealed with Super-Bond

Source : Reproduced from reference 39 with permission from The Japanese Society of Conservative Dentistry.

a : Sealing without applying activated liquid.
 b : Sealing after applying activated liquid.
 Super-Bond was dissolved during specimen preparation.

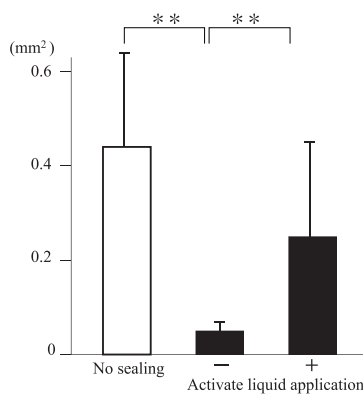


Fig. 15 Inflammatory cell infiltration in activated liquid application

** : significant difference $p < 0.01$

2. Pulp chamber floor perforation sealed with Super-Bond

A 28-year-old female presented with swelling of the buccal gingiva of the mandibular right first molar. A perforation was noted in the furcation and after removing infected dentin around the perforated site under microscope, calcium hydroxide was applied. The furcation perforation was sealed once inflammation had subsided. Four years later, the bone defect had almost completely disappeared (Fig. 16).

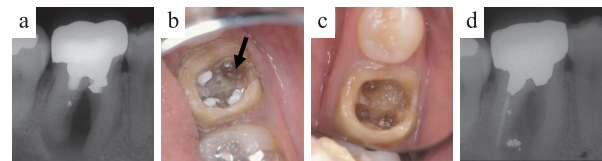


Fig. 16 A case of perforation sealing with Super-Bond in pulp chamber floor

a : Initial examination.
 b : At the time of the crown removal, when removing the amalgam that had filled the perforated site, drainage was observed (an arrow).
 c : Sealing with Super-Bond (Clear type).
 d : Four years later.

3. Clinical outcomes of perforation sealing with Super-Bond in pulp chamber floor

A perforation was observed in the mandibular molar bifurcation. Sealing was performed with Super-Bond and clinical outcomes were investigated six months to three years postoperatively. Of the 16 teeth examined in this study, nine teeth exhibited preoperative symptoms such as redness, swelling, drainage, fistula and percussion pain. Only one tooth exhibited these symptoms postoperatively. Bone defects were observed preoperatively in six teeth, but it had disappeared postoperatively in two teeth, had been reduced in three teeth, and not been reduced in one tooth (Table 2)⁴⁰.

In the one case in which the perforated site communicated with the periodontal pocket preoperatively, no improvement in symptoms or bone defect was exhibited postoperatively, while the other 15 cases followed a favorable postoperative course.

Table 2. Clinical outcomes of perforation sealing with Super-Bond in pulp chamber floor of mandibular molar

	Symptoms	Bone defect
Pre-treatment	9/16	6/16
Post-treatment	1/16	4/16
		(reduced : 3, no change : 1)

4. Tissue reaction with combined use of the internal matrix technique

Hemostasis can normally be performed as required if inflammation is not present. However, hemostatics filling the perforated site completely control bleeding. This prevents blood contamination of the adhered dentin surface and breaking of the resin applied to the perforated site by hemorrhagic pressure before the resin hardens. Therefore, it makes reliable sealing possible even for patients that have been administered anticoagulant drugs.

However, if hemostatics inhibit polymerization of the resin, inflammation may be induced after absorption of hemostatics. Therefore, we used cellulosic hemostatics (SURGICEL, Johnson & Johnson, Tokyo, Japan) and collagen hemostatics (TERUPLUG, Terumo, Tokyo, Japan) and implanted them to connective tissue either dry or soaked with blood after applying a mixture paste of Super-Bond to them⁴¹⁾. After two and six weeks, we examined the specimens histopathologically. Results indicated less inflammation with TERUPLUG than SURGICEL. Furthermore, inflammation around the Super-Bond area after the hemostatics had been resorbed was less apparent when hemostatics had been soaked in blood than when dry hemostatics were used (Fig. 17). This suggested that it is better to use TERUPLUG rather than SURGICEL and that Super-Bond should be applied after soaking them in blood.

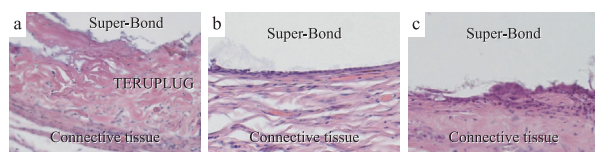


Fig. 17 Tissue reaction after applying Super-Bond to hemostatic material

a : Blood-soaked TERUPLUG (2 weeks later)

b : Blood-soaked TERUPLUG (6 weeks later)

c : Dry TERUPLUG (6 weeks later)

SuperBond was dissolved during specimen preparation.

5. Sealing a root canal perforation using the internal matrix technique with TERUPLUG

A 43-year-old female exhibited a fistula at her right maxillary first premolar and radiograph indicated bone resorption in the mesial mid-region of root. As the apex of the post was perforated, infected dentin was removed around the perforated site, the perforated site was filled with TERUPLUG and sealed while bonding the post with Super-Bond (Radiopaque type). The bone defect almost

completely disappeared and good healing was achieved (Fig. 18).

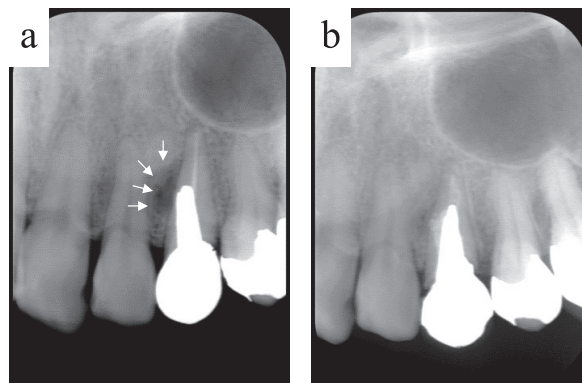


Fig. 18 Sealing a perforation using the internal matrix technique with TERUPLUG

a : Initial examination, b : 2 months later.

6. The advantages of Super-Bond as a root perforation sealing material

If non-adherent materials such as mineral trioxide aggregate (MTA) are used to seal root perforations^{42, 43)}, cavity preparation must be performed for filling. As the dentin often thins around the perforation site, cavity preparation can enlarge the perforation, thereby exacerbating the problem. Therefore, Super-Bond could be said to have a wider range of applicability, as it does not require a cavity to be used. Furthermore, because it can be used as a post adherent cement and root canal filling material, it can be used on the root apex side or near the root canal orifice and does not impair the subsequent prosthetic treatment.

Root canal filling

1. Sealing ability in root canal with open apices

Root canal therapy has been reported as leading to poor outcomes in teeth in which the apical foramen has opened widely. This is because it is difficult to shape root canals that can withstand the pressure applied during root canal filling. Super-Bond sealer (Sun Medical, Shiga, Japan) does not require any pressure to be applied as it seals with adhesion. Therefore, we enlarged the apex into elliptical shapes with a major axis of #130 and minor axis of #80, performed root canal filling with three different methods, and compared sealing⁴⁴⁾.

The following three methods of root canal filling were used. (1) The lateral condensation method using CANALS-N (Syowa Yakuin Kako, Tokyo) and gutta-

percha point, (2) the vertical condensation method using Obtura II (Obtura Spartan, Algonquin, IL, USA), and (3) the single point method with Super-Bond sealer. After root canal filling, dye penetration test was conducted and the distance of dye penetration from the apex to inside the root canal was measured. Results indicated significantly greater sealing with the single point method using Super-Bond sealer (Fig. 19).

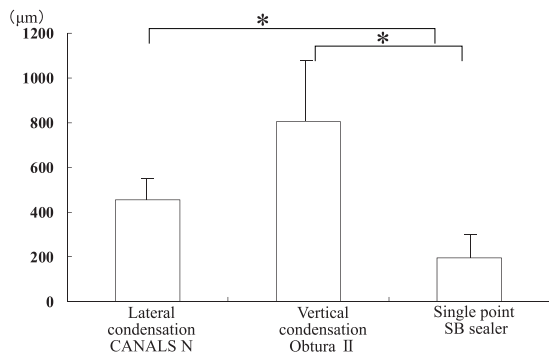


Fig. 19 Root canal filling methods and dye penetration lengths.

* : Significant difference $p < 0.05$

2. Sealing with Super-Bond only

With the single point method, flat or C-shaped root canals can cause the sealer thicken in certain sites and gaps can appear between the root canal wall due to contraction during polymerization. Therefore, we performed root canal filling with Super-Bond only, without using the gutta-percha point, and investigated whether sufficient sealing could be achieved. Root canals were enlarged to #140 up to the root apex and the following three methods were used to conduct root canal filling. (1) Filling of Super-Bond sealer with a syringe, (2) filling of Super-Bond Bulk-mix Radiopaque with a syringe, and (3) directly filling RealSeal SE sealer (SybronEndo Corporation, Orange, CA, USA) with a mixing tip. After dye penetration from the apex, tooth roots were cut into 0.5 mm horizontal slices, dye penetration rates were measured, and SEM observation was conducted⁴⁵⁾.

Results revealed hardly any dye penetration with Super-Bond sealer and Super-Bond Bulk-mix Radiopaque indicated significantly greater sealing than that achieved with RealSeal SE (Fig. 20). SEM showed that resin remained on the root canal wall (Fig. 21). With RealSeal SE, contraction gaps had formed between the root canal wall. These different results appeared to be greatly influenced by the fact that polymerization of Super-Bond progresses from the root canal wall. Thus, it could offer

strong sealing not only for root canals with opened apex but also for flat or C-shaped root canals. Furthermore, bondable root canal sealing with Super-Bond may promote creating monoblocks within the root canal^{46, 47)}.

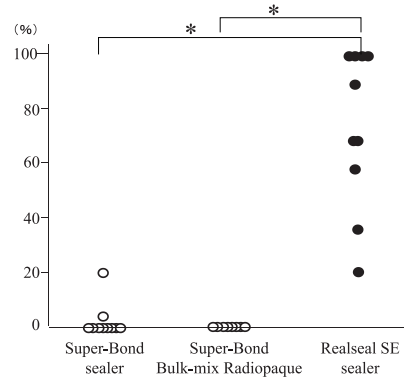


Fig. 20 Dye penetration rates after sealing with resin only
* : Significant difference $p < 0.05$

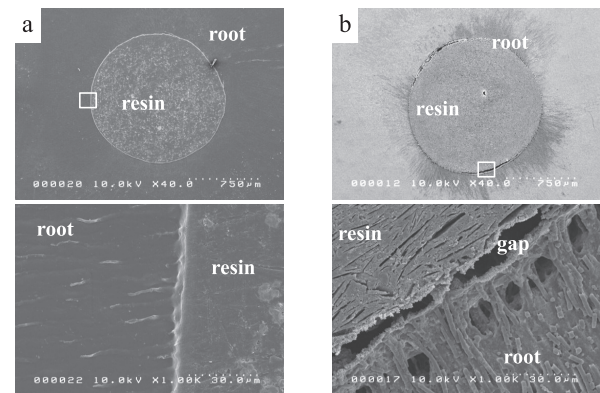


Fig. 21 SEM photographs after sealing with resin only

a : Super-Bond sealer, b : RealSeal SE sealer

3. A tooth with opened root apex filled with Super-Bond

A 38-year-old female presented with a fistula (Fig. 22a, arrows) in the apical region of mandibular right first molar and the radiograph revealed bone resorption. As she had previously undergone apicoectomy, the root length had been halved. An ultrasonic file was used to enlarge the root canal under microscope and single point method was conducted using Super-Bond sealer (Fig. 22b). Six months after root filling, bone resorption in the apical region had disappeared and the patient is recovering favorably (Fig. 22c, d).

4. Sealing a C-shaped root canal with Super-Bond

A 50-year-old male presented with bone resorption in the apical region of the mandibular left second molar.

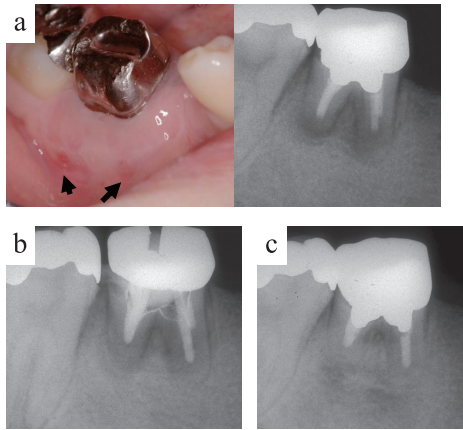


Fig. 22 A case of root canal sealing with Super-Bond sealer after unsuccessful apicoectomy
a : Initial examination, b : after sealing, c : 6 months after sealing

Removal of his crown revealed a C-shaped root canal. The root canal was enlarged with an ultrasonic file under a microscope and the root canal was sealed with Super-Bond Bulk-mix Radiopaque via a syringe without using the gutta-percha point. The periapical bone resorption disappeared and the patient is following a favorable course (Fig. 23). As Super-Bond has high fluidity and application of pressure is not necessary, it appears to be particularly effective in root canals shaped such as in this case.

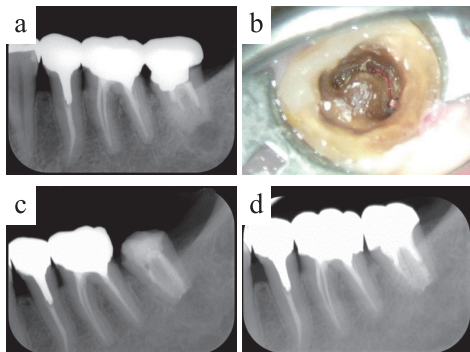


Fig. 23 A case of root canal sealing of a C-shaped root canal with Super-Bond Bulk-mix Radiopaque
a : Initial examination, b : During root canal preparation, c : After sealing, d : 2 years later

5. Resistance to vertical root fracture

Root canal filling with adhesive resin sealer is more likely to increase resistance of vertical root fracture. Therefore, we compared the vertical fracture resistance of the root canal filled teeth with resin-based-sealer in combination with resin point or gutta-percha point⁴⁸⁾. Extracted bovine root canals were prepared to size #140. After preparation, root canals were filled with following ;

① group R : Single resin point and 4-META / MMA-TBB resin-based-sealer, ② group G : Single gutta-pacha point and 4-META / MMA-TBB resin-based-sealer, ③ group C : No filling. The resin points are consisted of 4-META / MMA-TBB resin and the same shape as #140 point. Tensile strength test in the bucco-lingual direction was performed.

As the results, an average of tensile strengths in the group R was significantly higher than those of group C and group G. And there was no significant difference between group C and Group G (Fig. 24). Therefore, it is suggested that root canal filling with resin-based-sealer and resin points was effective for the resistance of vertical root fracture.

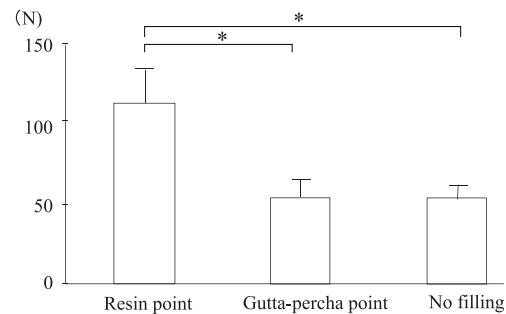


Fig. 24 Tensile strength after root canal filling with 4-META / MMA-TBB resin-based-sealer

* : Significant difference $p < 0.05$

Conclusion

The conclusions derived from this paper which reviewed research studies on treatment of infected root canals and vertically fractured roots using 4-META/MMA-TBB resin are as follows :

1. When the root canal has not been cleaned, root-end sealing of resected surface using Super-Bond during apicoectomy and intentional replantation could prevent leakage from root canal and root resorption, and bone defects disappeared resulting in good clinical outcomes.
2. Super-Bond could offer strong sealing for root canals in which pressure could not be applied during filling: root canal perforation, opened apex and C-shaped root canals.

Acknowledgements

The authors thank all the research co-workers, for their helpful discussions and suggestions regarding the preparation of this review paper.

References

- 1) Okamoto Y, Takahata K, Saeki K : Studies on the behavior of partially oxidized tributylborane as a radical initiator for methyl methacrylate (MMA) polymerization. *Chem Lett* 12 : 1247-1248, 1998.
- 2) Taira Y, Imai Y : Review of methyl methacrylate (MMA)/tributylborane (TBB)-initiated resin adhesive to dentin. *Dent Mater J* 33 : 291-304, 2014.
- 3) Noguchi H, Sugaya T, Kato H : Treatment of vertically fractured root by cohesion Part 2. Histological evaluation on cohesion with adhesin cement. *Jpn J Conserv Dent* 40 : 1453-1460, 1997.
- 4) Hosoya Y, Ichinose N, Inoue T, Fukumoto S, Goto G : Histo-pathological changes in dental pulp capped with 4-META/MMA-TBB resin. Report 1. *Jpn J Ped dent* 35 : 401-409, 1997.
- 5) Maniglia AJ, Nakabayashi N, Paparella MM, Werning JW : A new adhesive bonding material for the cementation of implantable devices in otologic surgery. *Am J Otol* 18 : 322-327, 1997.
- 6) Nakamura M, Inoue T, Shimono M : Immunohistochemical study of dental pulp applied with 4-META/MMA-TBB adhesive resin after pulpotomy. *J Biomed Mater Res* 51 : 241-248, 2000.
- 7) Inoue T, Miyakoshi S, Shimono M : The in vitro and in vivo influence of 4-META/MMA-TBB resin components on dental pulp tissues. *Adv Dent Res* 15 : 101-104, 2001.
- 8) Yoshimine Y, Ono M, Akamine A : In vitro comparison of the biocompatibility of mineral trioxide aggregate, 4-META/MMA-TBB resin, and intermediate restorative material as root-end-filling materials. *J Endod* 33 : 1066-1069, 2007.
- 9) Nakatsuka M, Kawamura N, Sugaya T, Kawanami M : Long-term stability of adhesion between 4-META/MMA-TBB resin and bone. *J Jpn Soc Dent Mater Dev* 27 : 455-465, 2008.
- 10) Morishita T, Sugaya T, Nakatsuka M, Sunosaki M, Kawanami M : Connective tissue reaction and bone-cement contact after implantation of PMMA resin cements. *J Oral Tissue Engin* 10 : 1-12, 2012.
- 11) Inoue T, Shimono M : Influences of 4-META/MMA-TBB resin on pulp tissue. *Adhes Dent* 32 : 36-62, 2014.
- 12) Vertucci FJ, Beatty RG : Apical leakage associated with retrofilling techniques : a dye study. *J Endod* 12 : 331-336, 1986.
- 13) Smee G, Bolanos OR, Morse DR, Furst ML, Yesilsoy C : A comparative leakage study of P-30 resin bonded ceramic, tefron, amalgam, and IRM as retrofilling seals. *J Endod* 13 : 117-121, 1987.
- 14) McDonald NJ, Dumsha TC : A comparative retrofill leakage study utilizing a dentin bonding material. *J Endod* 13 : 224-227, 1987.
- 15) Thirawat J, Edmunds DH : The sealing ability of materials used as retrograde root filling in endodontic surgery. *Int Endod J* 22 : 295-298, 1989.
- 16) Bohsali K, Pertot WJ, Hosseini B, Camps J : Sealing ability of super EBA and Dyract as root-end fillings ; a study in vitro. *Int Endod J* 31 : 338-342, 1998.
- 17) Wu M-K, Kontakiotis EG, Wesselink PR : Long-term seal provided by some root-end filling materials. *J Endod* 24 : 557-560, 1998.
- 18) Aqrabawi J : Sealing ability of amalgam, super EBA cement, and MTA when used as retrograde filling materials. *Br Dent J* 188 : 266-268, 2000.
- 19) Torabinejad M, Watson TF, Pitt Ford TR : Sealing ability of a mineral trioxide aggregate when used as a root end filling material. *J Endod* 19 : 591-595, 1993.
- 20) Torabinejad M, Rastegar AF, Kettering JD, Pitt Ford TR : Bacterial leakage of mineral trioxide aggregate as a root-end filling material. *J Endod* 21 : 109-112, 1995.
- 21) Fischer EJ, Arens DE, Miller CH : Bacterial leakage of mineral trioxide aggregate as compared with zinc-free amalgam, intermediate restorative material, and Super-EBA as a root-end filling material. *J Endod* 24 : 176-179, 1998.
- 22) Maltezos C, Glickman GN, Ezzo P, He J : Comparison of the sealing of Resilon, Pro Root MTA, and Super-EBA as root-end filling materials : A bacterial leakage study. *J Endod* 32 : 324-327, 2006.
- 23) Kouchi Y, Ninomiya J, Yasuda H, Fukui K, Moriyama T, Okamoto H : Location of *Streptococcus mutans* in the dentinal tubules of open infected root canals. *J Dent Res* 59 : 2038-2046, 1980.
- 24) Andreasen JO : Relationship between surface and inflammatory resorption and changes in the pulp after replantation of permanent incisors in monkeys. *J Endod* 7 : 294-301, 1981.
- 25) Rud J, Munksgaard EC, Andreasen JO, Rud V, Asmussen E : Retrograde root filling with composite and a dentin-bonding agent. 1. *Endod Dent Traumatol* 7 : 118-125, 1991.
- 26) Vignaroli PA, Anderson RW, Pashley DH :

- Longitudinal evaluation of the microleakage of dentin bonding agents used to seal resected root apices. *J Endod* 21 : 509-512, 1995.
- 27) Murray MJ, Loushine RJ, Weller RN, Kimbrough WF, Pashley DH : Use of self-etching adhesives to seal resected apices. *J Endod* 30 : 538-540, 2004.
 - 28) Keh E, Hayakawa I, Takahashi H, Watanabe A, Iwasaki Y, Akiyoshi K, Nakabayashi N : Improving a self-curing dental resin by eliminating oxygen, hydroquinone and water from its curing process. *Dent Mater J* 21 : 373-382, 2002.
 - 29) Tanaka Y, Sugaya T, Kawanami M : Long-term durability of root-end sealing with 4-META/MMA-TBB resin. *Dent Mater J* 23 : 453-456, 2004.
 - 30) Hasegawa Y, Sugaya T, Kawanami M : Effectiveness or root-end sealing using 4-META/MMA-TBB resin on healing of apical periodontitis. *Jpn J Conserv Dent* 47 : 622-632, 2004.
 - 31) Ohtani K, Sugaya T, Kawanami M : Long-term healing of experimental apical periodontitis after apicoectomy using different sealing methods on resected root end. *Jpn J Conserv Dent* 51 : 648-658, 2008.
 - 32) Ohtani K, Sugaya T, Miyaji H, Tomita M, Hasegawa Y, Motoki Y, Takanawa Y, Tanaka S, Kawanami M : Healing of experimental apical periodontitis after apicoectomy using different sealing methods on resected root end. *Dent Mater J* 30 : 485-492, 2011.
 - 33) Takefu H, Shimoji S, Sugaya T, Kawanami M : Influence of blood contamination before or after surface treatment on adhesion of 4-META/MMA-TBB resin to root dentin. *Dent Mater J* 31 : 131-138, 2012.
 - 34) Takefu H, Shimoji S, Sugaya T, Tanaka T, Kawanami M : Influence of duration of blood contamination on adhesion of 4-META/MMA-TBB resin to root dentin. *Jpn J Conserv Dent* 56 : 407-414, 2013.
 - 35) Sugaya T, Kato H : Fundamental studies of periodontal destruction after vertical root fracture and treatment. *Clin Res Dent* 1 : 1-10, 2004.
 - 36) Kawamura N, Sugaya T, Miyaji H, Kawanami M : Influence of curing condition on tissue reaction to the 4-META/MMA-TBB resin. *Jpn J Conserv Dent* 46 : 853-859, 2003.
 - 37) Kiyomura M, Abe Y, Nakabayashi N : Effect of pretreatment on the bond strength to dentin -The composition and period. *Jpn J Conserv Dent* 28 : 277-284, 1985.
 - 38) Sugaya T, Noguchi H, Hasegawa , Tanaka Y, Kawanami M : Clinical evaluation of 4-META/MMA-TBB resin as a root-end sealant following apicoectomy. *Jpn J Conserv Dent* 45 : 62-67, 2002.
 - 39) Yamamoto T, Sugaya T, Kato H : Histopathological evaluation of periodontal healing after treatment of furcation perforations with 4-META/MMA-TBB resin. *Jpn J Conserv Dent* 43 : 1239-1248, 2000.
 - 40) Yamamoto T, Sugaya T, Kato H : Clinical evaluation of furcation perforation treatment with 4-META/MMA-TBB resin. *Jpn J Conserv Dent* 47 : 543-548, 2004.
 - 41) Takanawa Y, Kawamura N, Sugaya T, Kawanami M : Tissue reaction of 4-META/MMA-TBB resin used together with hemostasis compound. *Hokkaido J Dent Sci* 31 : 35-43, 2010.
 - 42) Sluyk SR, Moon PC, Hartwell GR : Evaluation of setting properties and retention characteristics of mineral trioxide aggregate when used as a furcation perforation repair material. *J Endod* 24 : 768-771, 1998.
 - 43) Schwartz RS, Mauger M, Clement DJ, Walker WA : Mineral trioxide aggregate : a new material for endodontics. *J Am Dent Assoc* 130 : 967-975, 1999.
 - 44) Mikami D, Sugaya T, Kawamura N, Kawanami M : Influence of difference of root canal filling methods on apical sealing in apical foramen widening. *Hokkaido J Dent Sci* 32 : 124-134, 2012.
 - 45) Honma K, Sugaya T, Kawanami M : Sealing ability of root canal fillings using SuperBond sealer after chemical enlargement. *Hokkaido J Dent Sci* 33 : 72-81, 2013.
 - 46) Tay FR, Pashley DH : Monoblocks in root canals : a hypothetical or a tangible goal. *J Endod* 33 : 391-398, 2007.
 - 47) Kim YK, Grandini S, Ames JM, Gu L, Kim SK, Pashley DH, Gutmann JL, Tay FR : Critical Review on Methacrylate Resin-based Root Canal Sealers. *J Endod* 36 : 383-399, 2010.
 - 48) Wasizu T, Sugaya T : Resistance to vertical root fracture by root canal filling using 4-META/MMA-TBB resin sealer and resin point. *Adhes Dent* 34 : 9-15, 2016.