

Dieulafoy's Lesion: The Role of Endoscopic Ultrasonography as a Roadmap

Rita Barosa^a Sara Pires^b Pedro Pinto-Marques^a José António Pereira^c
Tiago Bilhim^c

^aDepartment of Gastroenterology, Hospital Garcia de Orta, Almada, ^bGastroenterology Department, Hospital do Espírito Santo, Évora, and ^cRadiology Department, Hospital de São José, Centro Hospitalar de Lisboa Central, Lisbon, Portugal

Keywords

Gastrointestinal endoscopy · Endosonography · Gastrointestinal hemorrhage · Vascular malformations

Lesão de Dieulafoy: Papel do Mapeamento por Ecoendoscopia

Palavras Chave

Endoscopia gastrointestinal · Endossonografia · Hemorragia gastrointestinal · Malformações vasculares

A 28-year-old man without any remarkable past medical history presented with hematemesis and hemodynamic instability. There was no significant past medical history. He denied any medication intake, namely non-steroidal anti-inflammatory drugs, alcohol abuse, or smoking habits. Upper gastrointestinal endoscopy (UGE) revealed fresh blood and a giant clot covering the gastric

body and fundus. Repeated UGE showed no mucosal defect. Radial endoscopic ultrasound (EUS) was performed, indicating a submucosal vessel arising in the greater curvature of the proximal gastric body which identified a Dieulafoy's lesion as the possible source of bleeding. Considering clinical stability, EUS-guided therapy with linear scope was planned for the next morning when the scope was available, but rebleeding occurred. UGE was performed with a therapeutic scope, as the site of bleeding was already identified and active bleeding was expected. Thus, the advantages of a dual channel scope, which is more easily maneuvered, would outweigh the advantages of using the echoendoscope, which has the main benefit when the Dieulafoy's lesion cannot be identified on UGE because it is no longer bleeding. UGE revealed an adherent clot in the suspected Dieulafoy's lesion location previously described on EUS. After the first clip deployment, massive bleeding occurred. Hemostasis was achieved after adrenalin and polidocanol injection and clipping. EUS was performed to confirm vessel obliteration but still identified a large caliber (2.5 mm) feeding vessel arising

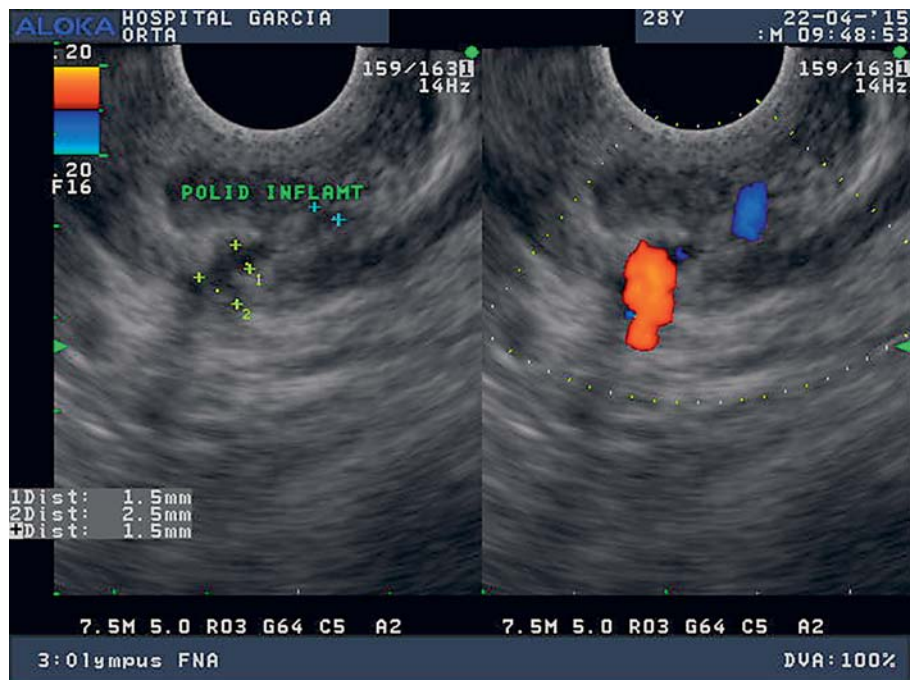


Fig. 1. Large caliber (2.5 mm) feeding vessel arising from the splenic artery penetrating the gastric muscularis propria.

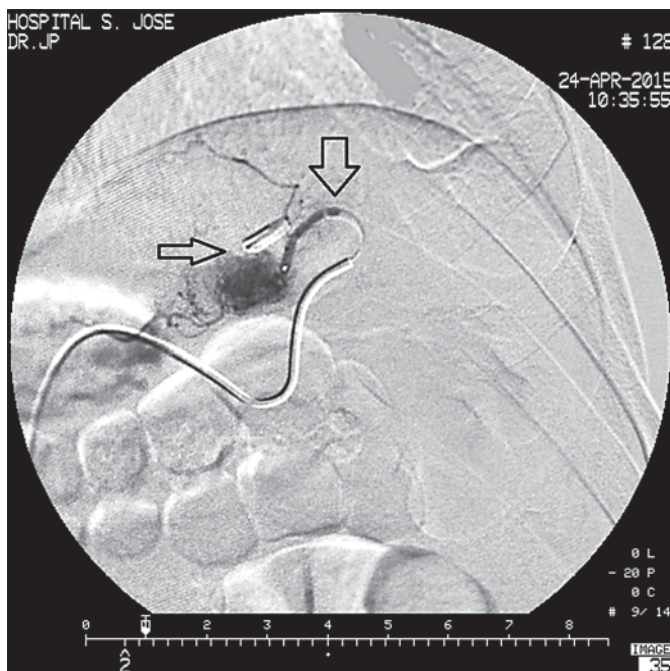


Fig. 2. Selective splenic artery angiogram revealing a short gastric artery ectasia and hypervascularization (large arrow) ending in the previously endoscopically placed clips (small arrow).

from the splenic artery penetrating the gastric muscularis propria (Fig. 1). Selective splenic artery angiogram as determined by EUS was performed, revealing a short gastric artery ectasia and hypervascularization (Fig. 2, large arrow) ending in the previously endoscopically placed clips (Fig. 2, small arrow). Superselective transcatheter arterial embolization (TAE) was performed, and the patient presented no further episodes of gastrointestinal bleeding at the 1-year follow-up.

Dieulafoy's lesion is a relatively rare cause of upper gastrointestinal bleeding which may be difficult to detect on endoscopy in the case of nonactive bleeding [1]. EUS may be used to identify a nonactively bleeding Dieulafoy's lesion, to perform EUS-guided therapy, and to monitor therapy effectiveness [1, 2]. In fact, it is our practice to perform EUS after inconclusive UGE in a severe upper gastrointestinal bleeding setting, clinically suggestive of Dieulafoy's lesion origin, and we also systematically perform EUS after endoscopic therapy to confirm effective vessel obliteration [3]. When refractory to endoscopic treatment, surgery and TAE should be considered [1]. Marking the lesion with a metallic clip has accurately guided the endovascular intervention in cases of nonactive bleeding ulcer and may be equally useful in the treatment of Dieulafoy's lesions [4]. With this case, we emphasize the role of EUS as a roadmap for other interventions, such as selective TAE.

Statement of Ethics

This study did not require informed consent or review/approval by the appropriate ethics committee.

Disclosure Statement

The authors have no conflicts of interest to declare.

References

- 1 Nojkov B, Cappell MS: Gastrointestinal bleeding from Dieulafoy's lesion: clinical presentation, endoscopic findings, and endoscopic therapy. *World J Gastrointest Endosc* 2015;7:295–307.
- 2 Law R, Fujii-Lau L, Wong Kee Song LM, Gostout CJ, Kamath PS, Abu Dayyeh BK, et al: Efficacy of endoscopic ultrasound-guided hemostatic interventions for resistant nonvariceal bleeding. *Clin Gastroenterol Hepatol* 2015;13:808–812.
- 3 Pinto-Marques P, Gíria J, Brito M, Camacho R, Loureiro R: Unusual cause for upper GI bleeding: a splenic artery aneurysm mimicking a Dieulafoy lesion. Role for systematic EUS assessment? *Gastrointest Endosc* 2010;71:845–846.
- 4 Eriksson LG, Sundbom M, Gustavsson S, Nyman R: Endoscopic marking with a metallic clip facilitates transcatheter arterial embolization in upper peptic ulcer bleeding. *J Vasc Interv Radiol* 2006;17:959–964.