

University of Massachusetts Medical School
eScholarship@UMMS

Open Access Articles

Open Access Publications by UMMS Authors

2016-11-11

Examination of Huntington's disease with atypical clinical features in a Bangladeshi family tree

Md Mahfuz Al-Mamun
Institute for Developing Science & Health Initiatives

Et al.

Let us know how access to this document benefits you.

Follow this and additional works at: <https://escholarship.umassmed.edu/oapubs>

 Part of the [Nervous System Diseases Commons](#)

Repository Citation

Al-Mamun MM, Sarker SK, Qadri SK, Shirin T, Mohammad QD, LaRocque R, Karlsson EK, Saha N, Asaduzzaman M, Qadri F, Mannoor MK. (2016). Examination of Huntington's disease with atypical clinical features in a Bangladeshi family tree. Open Access Articles. <https://doi.org/10.1002/ccr3.743>. Retrieved from <https://escholarship.umassmed.edu/oapubs/2993>

Creative Commons License



This work is licensed under a [Creative Commons Attribution-NonCommercial-No Derivative Works 4.0 License](#). This material is brought to you by eScholarship@UMMS. It has been accepted for inclusion in Open Access Articles by an authorized administrator of eScholarship@UMMS. For more information, please contact Lisa.Palmer@umassmed.edu.

CASE REPORT

Examination of Huntington's disease with atypical clinical features in a Bangladeshi family tree

Md Mahfuz Al-Mamun^{1,†}, Suprovath Kumar Sarker^{1,†}, Syeda Kashfi Qadri², Tahmina Shirin³, Quazi Deen Mohammad⁴, Regina LaRocque⁵, Elinor K. Karlsson⁶, Narayan Saha⁷, Muhammad Asaduzzaman⁸, Firdausi Qadri^{1,8} & Md Kaiissar Mannoor¹

¹Institute for Developing Science & Health Initiatives (IDESHI), Dhaka, Bangladesh

²KK Women's and Children's Hospital, Singapore city, Singapore

³Department of Virology, Institute of Epidemiology, Disease Control and Research, Dhaka, Bangladesh

⁴Department of Neurology, National Institute of Neurosciences & Hospital, Dhaka, Bangladesh

⁵Division of Infectious Diseases, Department of Medicine, Massachusetts General Hospital, Boston, Massachusetts, USA

⁶Broad Institute, University of Massachusetts Medical School, Cambridge, Massachusetts, USA

⁷Pediatric Neurology, National Institute of Neurosciences & Hospital, Dhaka, Bangladesh

⁸Centre for Vaccine Sciences, International Centre for Diarrheal Disease Research, Dhaka, Bangladesh

Correspondence

Md Kaiissar Mannoor, Institute for Developing Science & Health Initiatives (IDESHI), Mohakhali, Dhaka-1212, Bangladesh. Tel: +8801797440713; Fax: +88029889190; E-mail: kaiissar@ideshi.org

Funding Information

Institute for Developing Science and Health Initiatives.

Received: 24 March 2016; Revised: 4 October 2016; Accepted: 9 October 2016

Clinical Case Reports 2016; **4**(12): 1191–1194

doi: 10.1002/ccr3.743

†Equal contribution.

Key Clinical Message

Atypical manifestation of Huntington's disease (HD) could inform ongoing research into HD genetic modifiers not present in the primarily European populations studied to date. This work demonstrates that expanding HD genetic testing into under-resourced healthcare settings can benefit both local communities and ongoing research into HD etiology and new therapies.

Keywords

Atypical clinical features, Bangladeshi family tree, CAG repeat, Huntington's disease, mutation

Prior to enrollment, written informed consent was obtained from all study participants. The study was approved by the Ethical Review Committee (ERC) of Bangladesh Medical Research Council (BMRC).

Here, we describe an extended family in northern Bangladesh with eight members affected with Huntington's disease (HD) exhibiting atypical clinical features. All eight have the CAG repeat expansion in exon 1 of HTT gene and do not carry mutations associated with other HD-like disorders, Wilson's disease, or other neurodegenerative diseases. The affected family, in northern Bangladesh, has eight living members with Huntington's disease (HD), all with atypical clinical features. The disorder appeared almost 130 years ago in one of the two siblings. All affected individuals are progeny of the affected sibling,

and no progeny of the healthy sibling are affected. No consanguineous marriages are reported for the study participants. The age of onset decreased from 65 to 20 years over five generations, and this information is consistent with Huntington's disease. Clinical information was obtained for all eight patients. All of the patients (100%) exhibited mild jerky movement of fingers and slow movement of eyes as the first detectable clinical symptoms. Four of the patients (50%) exhibited moderate-to-severe chorea, whereas the remaining four cases (50%) did not exhibit any choreatic movement disorder except mild jerky movement of fingers and slow movement of eyes. All eight patients (100%) seemed normal in terms of cognitive function because there was no significant dementia as manifested by mini-mental state examination. In

addition, none of the patients did show any psychiatric disturbances. Although three cases (37.5%) showed characteristic features of anxiety, there was no tendency of committing suicide. It is mentionable here that one patient had severe chorea characterized by balanced trouble, clumsiness, tremor, significant weight loss, fidgeting, facial grimaces, increased appetite, less control over handwriting, rigidity, speech difficulties, grunting and abnormal speech patterns, inability to control speed and force of movement, general weakness, and impairment of superficial sensation. However, the clinical symptoms, as manifested by brain imaging and mini-mental state examination, were not fully consistent with typical Huntington's disease (HD) or any other choreatic movement-associated neurodegenerative diseases including HD-like disorders or Wilson's disease. Analysis of blood parameters like total bilirubin, ALT (alanine aminotransferase), and ceruloplasmin as well as Kayser–Fleischer (K-F) ring test did not show any abnormal results (data not shown), excluding the possibility Wilson's disease. MRI examination of the patient's brain did not reveal pathology typical of Huntington's disease (Fig. 1) [1, 2]. Putamen and Caudate are the primary sites to be affected for the structural changes in Huntington's disease. No changes were evident in the caudate nucleus and striatum regions like putamen and globus pallidus, although mild cerebellar atrophy was observed (Fig. 1).

Because of the atypical clinical symptoms, genetic testing using DNA specimens was used to diagnose the disorder. We first used PCR-based method to check the length of the HTT allele [3]. All four unaffected subjects tested had typical HD allele length of 80–85 bp, while all

affected individuals were heterozygous, with one normal HD allele and one expanded allele (Fig. 2A). We used Sanger DNA sequencing to show that the normal allele had 20 CAG repeats, within the previously reported range of 6–35 [4, 5]. The expanded allele had either 53 CAG repeats (seven patients) or 70 CAG repeats (one patient), confirming the diagnosis of Huntington's disease (Fig. 2A and B) [6–9]. The patient with the longer CAG repeat was just 20 years of age and thus was diagnosed as juvenile HD [10–12]. We found no mutations in three genes (PRNP, JPH3, and TBP) associated with HD-like diseases HDL 1, HDL 2, and HDL 4, respectively (data not shown). Major clinical characteristic of typical Huntington's disease (HD) is manifested by progressive dementia. However, HD chorea without dementia [13–15] and absence of observable atrophy of either cortex or basal ganglia [16] have been reported. Although CAG repeat length can be correlated with some of the phenotypic variability like age of onset and disease severity [17, 18, 19], other genetic modifiers like loci 4p16 (LOD 1.93), 6p21–23 (LOD 2.29), and 6q24–26 (LOD 2.28) may influence the expression of HD [20].

This extended family pedigree from northern Bangladesh exhibited an atypical, undiagnosed neurodegenerative disease. Using genetic sequencing, we diagnosed Huntington's disease. Although there are no HD-specific treatments available yet, the affected people can now receive symptoms-specific intervention to reduce the severity of the disease. In addition, genetic counseling can now help members of this family make informed reproductive decisions. This is the first study on diagnosis of a neurodegenerative disease using a sequencing-based

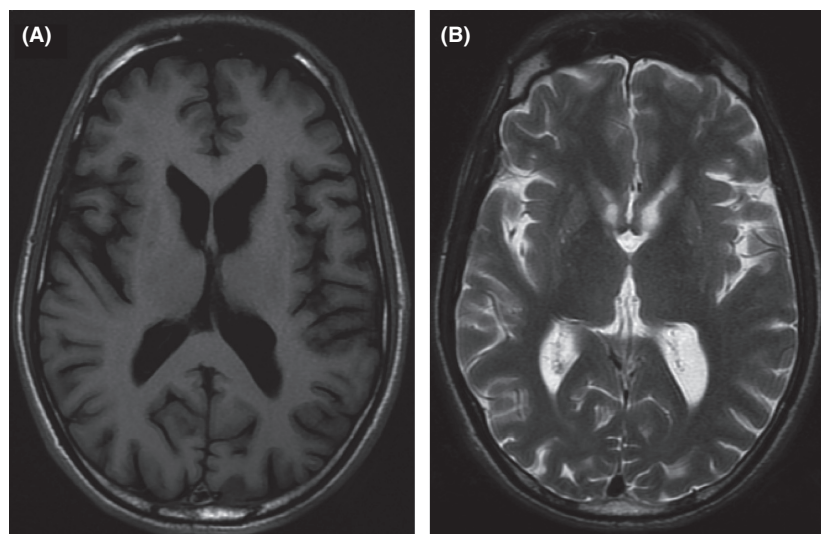


Figure 1. A representative brain MRI examination of patient with severe choreatic movement disorder. Bioimages of brain were obtained using the 1.5 T MRI systems (GE Healthcare, UK), with transverse T1- and T2-weighted scans at the level of basal ganglia. (A) indicates T1-weighted scan, whereas (B) indicates T2-weighted scan.

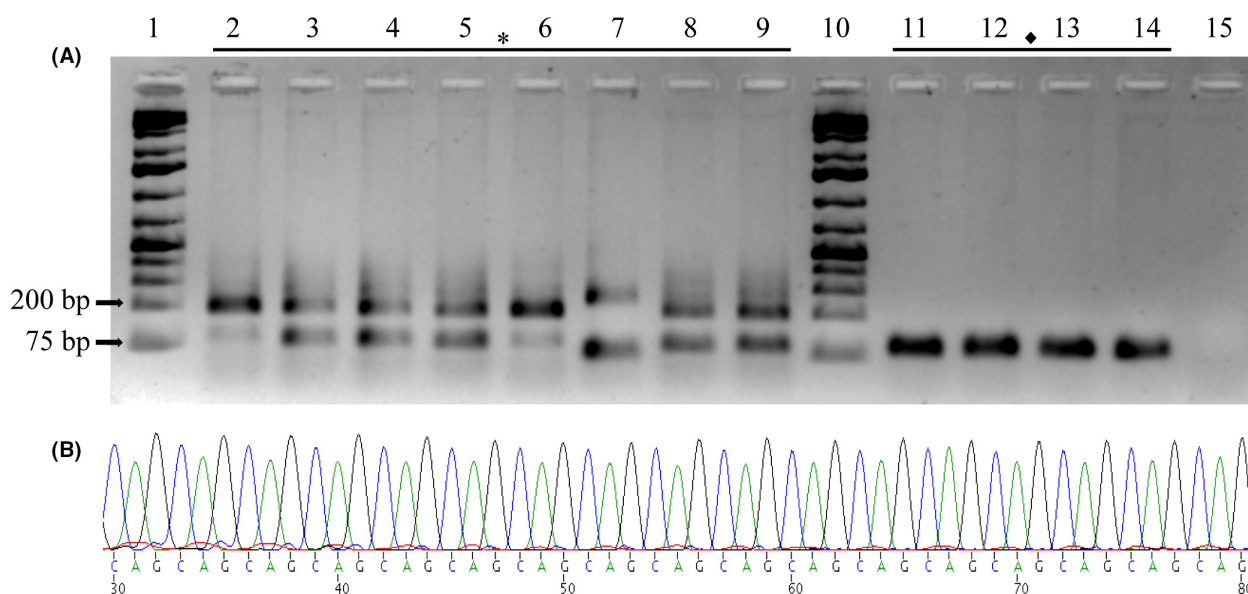


Figure 2. DNA-based analysis of patients' specimens. (A) Agarose gel (2.0%) electrophoresis of human HTT gene polymerase chain reaction products of eight different patients and four healthy controls. Following electrophoresis, the PCR-amplified products were stained with GelRed™ (Biotium Inc., Hayward, CA, USA) and photographed under UV light. Lanes 1 and 10 denote 1 kb+ Ladder (Thermo Fisher Scientific (Fermentas)); *(lanes 2–9) indicates affected individuals, ♦(lanes 11–14) indicates unaffected individuals, and lane 15 denotes template of negative control. (B) A representative partial sequencing chromatogram for a HD-suspected patient. Gel-extracted PCR product was used for Sanger DNA sequencing.

approach in Bangladesh, paving the way for expansion of facilities for diagnosis of other genetic disorders. Furthermore, the atypical manifestation of HD in this Bangladeshi family could inform ongoing research into HD genetic modifiers not present in the primarily European populations studied to date. This work demonstrates that expanding HD genetic testing into under-resourced healthcare settings can benefit both local communities and ongoing research into HD disease etiology and new therapies.

Acknowledgments

Brain MRI was analyzed by Professor Quazi Deen Mohammad. This work was supported by Institute for Developing Science and Health Initiatives.

Conflict of Interest

All authors declare no conflicts of interest to report this manuscript.

Authorship

Sequencing of purified PCR products was carried out by Dr. Regina LaRocque. Data compilation and initial manuscript writing were carried out by Md Mahfuz Al-Mamun. MKM and EKK edited the manuscript. MMM and SKS

together performed laboratory experiments and assembled the figures, while KM helped in troubleshooting. MMM and SKS contributed equally in terms of performing laboratory experiments and other works. SKQ, TS, MA, NS, and FQ contributed to design the experiments and upgrade the manuscript. KDM helped MRI image interpretation.

References

1. Jernigan, T. L., D. P. Salmon, N. Butters, and J. R. Hesselink. 1991. Cerebral structure on MRI, Part II: specific changes in Alzheimer's and Huntington's diseases. *Biol. Psychiatry* 29:68–81.
2. Negi, R. S., K. L. Manchanda, and S. Sanga. 2014. Imaging of Huntington's disease. *Med. J. Armed Forces India* 70:386.
3. Craufurd, D., R. MacLeod, M. Frontali, O. Quarrell, E. K. Bijlsma, M. Davis, et al. 2015. Diagnostic genetic testing for Huntington's disease. *Pract. Neurol.* 15:80–84.
4. Gonzalez-Alegre, P., and A. K. Affi. 2006. Clinical characteristics of childhood-onset (juvenile) Huntington disease: report of 12 patients and review of the literature. *J. Child Neurol.* 21:223–229.
5. Nance, M. A., and R. H. Myers. 2001. Juvenile onset Huntington's disease—clinical and research perspectives. *Ment. Retard. Dev. Disabil. Res. Rev.* 7:153–157.
6. Barron, L. H., J. P. Warner, M. Porteous, S. Holloway, S. Simpson, R. Davidson, et al. 1993. A study of the

- Huntington's disease associated trinucleotide repeat in the Scottish population. *J. Med. Genet.* 30:1003–1007.
7. MacDonald, M. E., C. M. Ambrose, M. P. Duyao, R. H. Myers, C. Lin, L. Srinidhi, et al. 1993. A novel gene containing a trinucleotide repeat that is expanded and unstable on Huntington's disease chromosomes. *Cell* 72:971–983.
 8. Novelletto, A., F. Persichetti, G. Sabbadin, P. Mandich, E. Bellone, F. Ajmar, et al. 1994. Analysis of the trinucleotide repeat expansion in Italian families affected with Huntington disease. *Hum. Mol. Genet.* 3:93–98.
 9. Zühike, C., O. Rless, K. Schröder, I. Sledlaczck, J. T. Epplen, W. Engel, et al. 1993. Expansion of the (CAG) n repeat causing Huntington's disease in 352 patients of German origin. *Hum. Mol. Genet.* 2:1467–1469.
 10. Quarrell, O. W., H. M. Brewer, and F. Squitieri. 2009. *Juvenile huntington's disease: and other Trinucleotide repeat disorders.* Oxford University Press, New York.
 11. Rubinsztein, D. C., J. Leggo, R. Coles, E. Almqvist, V. Biancalana, J. J. Cassiman, et al. 1996. Phenotypic characterization of individuals with 30–40 CAG repeats in the Huntington disease (HD) gene reveals HD cases with 36 repeats and apparently normal elderly individuals with 36–39 repeats. *Am. J. Hum. Genet.* 59:16.
 12. Wheeler, V. C., F. Persichetti, S. M. McNeil, J. S. Mysore, S. S. Mysore, M. E. MacDonald, et al., and US–Venezuela Collaborative Research Group. 2007. Factors associated with HD CAG repeat instability in Huntington disease. *J. Med. Genet.* 44:695–701.
 13. Schady, W., and R. J. Meara. 1988. Hereditary progressive chorea without dementia. *J. Neurol. Neurosurg. Psychiatry* 51:295–297.
 14. Behan, P. O., and I. Bone. 1977. Hereditary chorea without dementia. *J. Neurol. Neurosurg. Psychiatry* 40:687.
 15. Britton, J. W., R. J. Uitti, J. E. Ahlskog, R. G. Robinson, B. Kremer, and M. R. Hayden. 1995. Hereditary late-onset chorea without significant dementia genetic evidence for substantial phenotypic variation in Huntington's disease. *Neurology* 45:443–447.
 16. Quarrell, O. W., and P. S. Harper. 1986. Huntington's chorea without dementia. *Br. J. Psychiatry* 148:612–613.
 17. Andrew, S. E., Y. P. Goldberg, B. Kremer, H. Telenius, J. Theilmann, S. Adam, et al. 1993. The relationship between trinucleotide (CAG) repeat length. *Nat. Genet.* 4:398–403.
 18. Snell, R. G., J. C. MacMillan, J. P. Cheadle, I. Fenton, L. P. Lazarou, P. Davies, et al. 1993. Relationship between trinucleotide repeat expansion and phenotypic variation in Huntington's disease. *Nat. Genet.* 4:393–397.
 19. Duyao, M., C. Ambrose, R. Myers, A. Novelletto, F. Persichetti, M. Frontali, et al. 1993. Trinucleotide repeat length instability and age of onset in Huntington's disease. *Nat. Genet.* 4:387–392.
 20. Li, J. L., M. R. Hayden, E. W. Almqvist, R. R. Brinkman, A. Durr, C. Dodé, et al. 2003. A genome scan for modifiers of age at onset in Huntington disease: the HD MAPS study. *Am. J. Hum. Genet.* 73:682–687.