

11-3-2017

Post-Pericardiotomy Syndrome Disguised as Fever of Unknown Origin

Ida Micaily, MD

Abington Jefferson Health, ida.micaily@jefferson.edu

Bilal Lashari, MD

Abington Jefferson Health, bilal.lashari@jefferson.edu

Aditya Munshi, MD

Abington Jefferson Health, aditya.munshi@jefferson.edu

Zulfiqar Arif, MD

Abington Jefferson Health, zulfiqar.arif@jefferson.edu

Let us know how access to this document benefits you

Follow this and additional works at: <https://jdc.jefferson.edu/internalfp> Part of the [Medicine and Health Sciences Commons](#)

Recommended Citation

Micaily, MD, Ida; Lashari, MD, Bilal; Munshi, MD, Aditya; and Arif, MD, Zulfiqar, "Post-Pericardiotomy Syndrome Disguised as Fever of Unknown Origin" (2017). *Division of Internal Medicine Faculty Papers & Presentations*. Paper 18.<https://jdc.jefferson.edu/internalfp/18>

INTRODUCTION

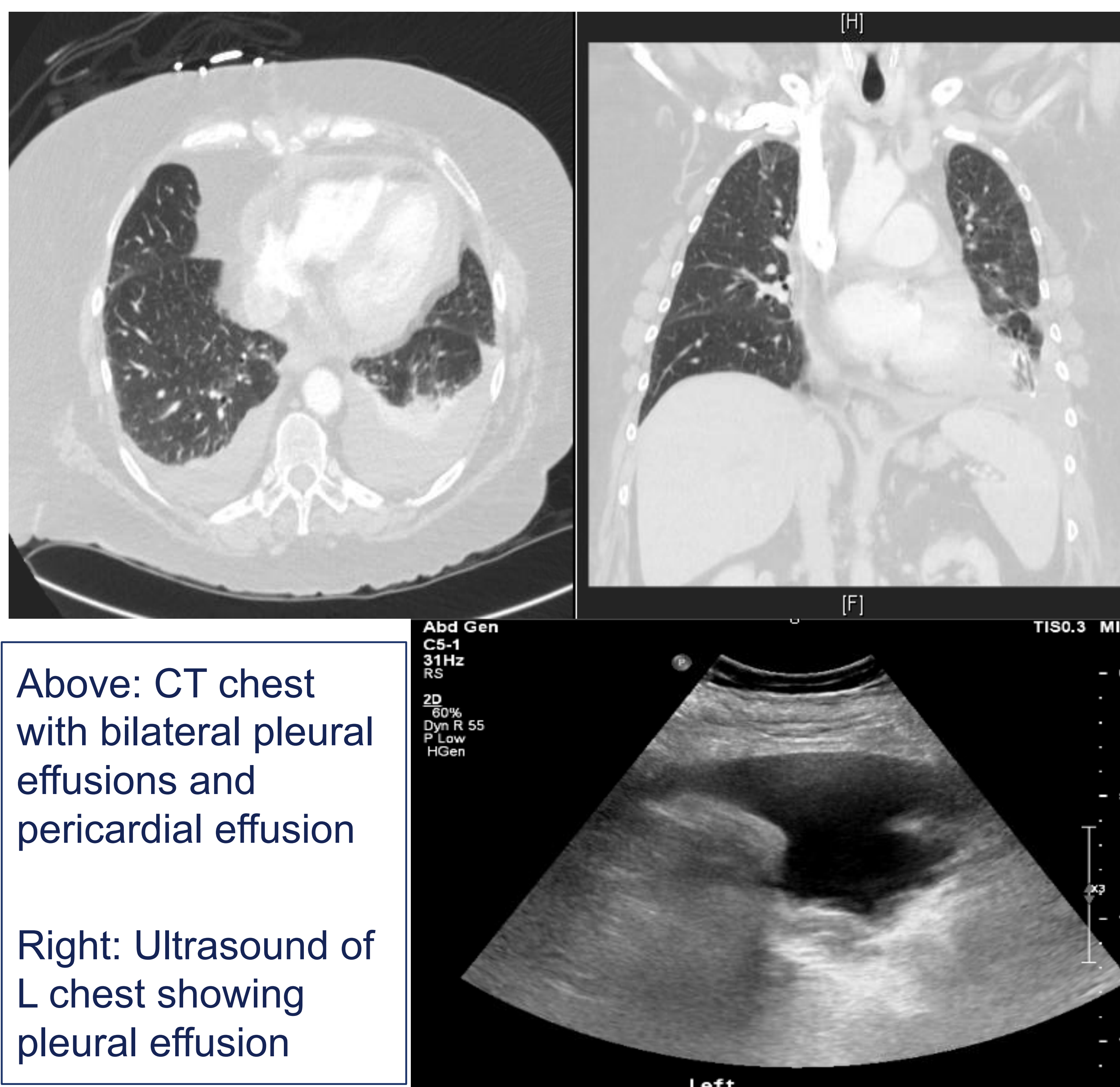
- ❑ Post -Pericardiotomy syndrome (PPS) is a clinical diagnosis characterized by fever, pericardial or pleural effusions, and a pericardial friction rub occurring over several days after cardiac surgery.
- ❑ The infrequency of PPS can cause delay in recognition and management, thus leading to significant morbidity.
- ❑ We present a case of fever of unknown origin, pericardial and pleural effusion secondary to post-pericardiotomy syndrome 10 days after an Aortic Valve Replacement (AVR)

CASE DESCRIPTION

- ❑ **Chief complaint:** A 62 year-old Caucasian female presented 10 days after AVR with fever, weakness, night sweats, chills, and altered mentation.
- ❑ **Examination:** Mildly lethargic. Tachycardic with I/IV systolic ejection murmur, no elevation of JVD. Coarse breath sounds, decreased at lung bases bilaterally. Mild lower extremity edema to ankle.
- ❑ **Electrocardiogram:** Normal sinus rhythm. Nonspecific ST-T wave changes.
- ❑ **Laboratory data:** CBC showed leukocytosis without bandemia. CMP, troponin, CK, and cardiac BNP were all within normal limits. Blood, urine and sputum cultures were all negative for growth.

CASE DESCRIPTION CONTINUED...

- ❑ **Chest X-ray:** Left pleural effusion, left lower lobe opacity with cardiomegaly.
- ❑ **Transesophageal echocardiogram:** Small pericardial effusion, small left sided pleural effusion, bioprosthetic valve without vegetation.
- ❑ **Chest CT (below) :** Confirmed small pericardial effusion. Small bilateral pleural effusions with consolidation.
- ❑ **Thoracentesis:** Mild exudative fluid collection. Negative cultures.



CASE DESCRIPTION CONTINUED...

- ❑ **Treatment:** The patient was treated with empiric antibiotics for a presumed pneumonia after AVR. However, the patient remained febrile with worsening dyspnea and tenderness to palpation of the chest wall throughout the hospital course. After her course of antibiotics were completed, the patient was started on a trial of NSAIDs, to which her fever and leukocytosis responded immediately.

DISCUSSION

- ❑ PPS is thought to occur secondary to mesothelial pericardial injury, release of cardiac antigens and subsequent immune response.
- ❑ PPS has been known for decades and can occur from 3 to 30% of cardiac surgery patients.
- ❑ This case showed the value of clinical diagnosis in a fever of unknown source.
- ❑ In the setting of a recent cardiac procedure, PPS should be considered as a potential cause of fever in the extended post-operative period.

REFERENCES

- 1) Imazio, M: Diagnosis and Management of the Postpericardiotomy Syndrome. Clinical Pulmonary Medicine, 21 (5): 220-24, Sept 2014
- 2) Imazio M, Hoit BD: Post-cardiac injury syndromes. An emerging cause of pericardial diseases. Int J Cardiol, 168 (2): 648-52, Sept 2013