



11-2017

Allergic contact dermatitis to 2-octyl cyanoacrylate after surgical repair: Humidity as a potential factor

Avi Bitterman

Sidney Kimmel Medical College; Jersey Shore University Medical Center

Karanjit Sandhu

Einstein Medical Center

[Let us know how access to this document benefits you](#)

Follow this and additional works at: https://jdc.jefferson.edu/student_papers

 Part of the [Dermatology Commons](#), and the [Surgery Commons](#)

Recommended Citation

Bitterman, Avi and Sandhu, Karanjit, "Allergic contact dermatitis to 2-octyl cyanoacrylate after surgical repair: Humidity as a potential factor" (2017). *Student Papers*. Paper 9.

https://jdc.jefferson.edu/student_papers/9

This Article is brought to you for free and open access by the Jefferson Digital Commons. The Jefferson Digital Commons is a service of Thomas Jefferson University's [Center for Teaching and Learning \(CTL\)](#). The Commons is a showcase for Jefferson books and journals, peer-reviewed scholarly publications, unique historical collections from the University archives, and teaching tools. The Jefferson Digital Commons allows researchers and interested readers anywhere in the world to learn about and keep up to date with Jefferson scholarship. This article has been accepted for inclusion in Student Papers by an authorized administrator of the Jefferson Digital Commons. For more information, please contact: JeffersonDigitalCommons@jefferson.edu.



Allergic contact dermatitis to 2-octyl cyanoacrylate after surgical repair: Humidity as a potential factor

Avi Bitterman, MD,^{a,b} and Karanjit Sandhu, MD^c
Neptune, New Jersey and Philadelphia, Pennsylvania

Key words: allergy; contact dermatitis; Dermabond; dermatitis; sensitization; surgical glue.

Allergic contact dermatitis to 2-octyl cyanoacrylate (Dermabond; Ethicon, Somerville, NJ) after surgical repair is an extremely rare condition with few reported cases. In recent years, contact dermatitis to Dermabond has been reported with increasing frequency.^{1,2} Cyanoacrylates are the most commonly used surgical adhesives and rely on their rapid polymerization to prevent sensitization from antigen presenting cells (APCs), because APCs are only capable of monomeric recognition of cyanoacrylates. It is thought that arid climates may contribute to increased sensitization of cyanoacrylates because water drives the polymerization reaction, decreasing the number of monomers capable of recognition by APCs. With less water present in the air to drive the polymerization forward, it is thought that monomers will persist longer, providing APCs more time to become sensitized.^{3,4} Indeed, most cases of allergic contact dermatitis to Dermabond published in the literature are from arid environments, such as a case from Las Vegas, Nevada and 4 cases from San Antonio, Texas.^{4,5} These observations should in theory extend to home heaters and air conditioners. We present a case of allergic contact dermatitis to 2-octyl cyanoacrylate after the use of a home heater shortly after application.

CASE REPORT

A 44-year-old woman with end stage renal disease presented with a pruritic papulovesicular eruption around her arteriovenous fistula incision site that was placed on the patient's right forearm

2 weeks earlier (Fig 1). The surgery was uncomplicated and was closed with Dermabond. The patient denied any application of topical antibiotics, emollients, or creams postsurgery. Over a period of 5 days of inpatient hospitalization (to rule out infectious etiology), a workup of the lesion involving a Gram stain, Tzanck smear, wound culture, herpes culture, and blood cultures were all negative. The papulovesicular eruption worsened during this period, demonstrating an increase in size of the individual vesicles and causing increased pruritus to the patient (Fig 2). Upon follow-up 3 days later, the vesicular eruption showed no improvement and residual surgical glue was found at the incision site. The surgical glue was carefully removed from the incision folds and the site was redressed using the same brand of gauze (Curity 4×4; Covidien, Dublin, Ireland) as the previous dressing. The patient's rash quickly resolved over the next week. The patient underwent extensive patch testing, including a glue series containing various cyanoacrylate compounds, in addition to 2-octyl cyanoacrylate (which is not usually included in most glue series) as well as iodopovidone (as iodopovidone was used in the initial surgical preparation). The patch test revealed a 2+ reaction to 2-octyl cyanoacrylate and a negative reaction to all other cyanoacrylates and iodopovidone, confirming the diagnosis of the surgical glue allergy specific to Dermabond. It was also discovered that after the closure of the surgical wound with surgical glue, the patient had been using a home heater.

From Sidney Kimmel Medical College,^a Philadelphia; Jersey Shore University Medical Center,^b Neptune; and Einstein Medical Center,^c Philadelphia.

Funding sources: None.

Conflicts of interest: None declared.

Correspondence to: Avi Bitterman, MD, Sidney Kimmel Medical College, 217-Stevenplace, Woodmere, NY 11598. E-mail: Avi.Bitterman@jefferson.edu.

JAAD Case Reports 2017;3:480-1.
2352-5126

© 2017 by the American Academy of Dermatology, Inc. Published by Elsevier, Inc. This is an open access article under the CC BY-NC-ND license (<http://creativecommons.org/licenses/by-nc-nd/4.0/>).

<http://dx.doi.org/10.1016/j.jidcr.2017.07.006>

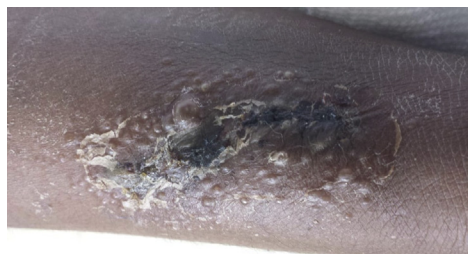


Fig 1. Initial presentation of the vesicular rash localized to the arteriovenous fistula incision.

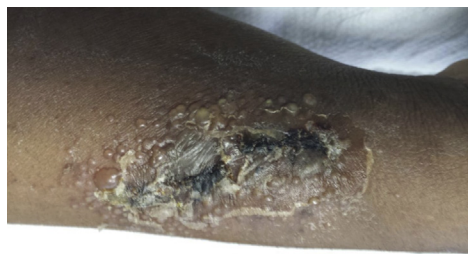


Fig 2. Progression of the vesicular rash localized to the site of arteriovenous fistula incision.

DISCUSSION

The reason for the rarity of allergic contact dermatitis to surgical glue is because surgical glue is inherently designed to protect itself from sensitization through its polymerization. The nucleophile that drives the polymerization is water (Fig 3), and arid environments effectively deprive the reaction of its principle nucleophile—slowing the polymerization process. This allows more time for APCs to recognize monomeric components of the polymer, resulting in sensitizing the patient to both the monomer and the polymer. The findings in this case report strengthen this theory of sensitization of surgical glue.

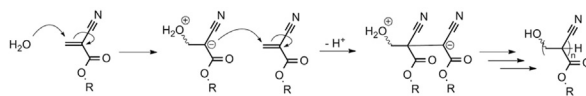


Fig 3. Mechanism of cyanoacrylate polymerization, showing water as the principle nucleophile driving the reaction.

It may be apt for the clinician to advise patients to avoid excessively dry environmental situations after surgical procedures closed with surgical glue to avoid being sensitized, especially during the same day in which the surgical glue is applied. The findings of this study also show that an allergy to one form of surgical glue does not necessarily mean that cross reactivity will occur with other cyanoacrylate-based glues. Should patients require future use of a surgical glue, it would be apt to use a different surgical glue, such as n-butyl cyanoacrylate after patch testing has ruled out cross reactions. Finally, as mentioned in another case report,¹ the findings reaffirm the need for glue series patch tests to include 2-octyl cyanoacrylate to aid these patients in accurate diagnoses.

REFERENCES

1. Davis MD, Stuart MJ. Severe allergic contact dermatitis to Dermabond Prineo, a topical skin adhesive of 2-octyl cyanoacrylate increasingly used in surgeries to close wounds. *Dermatitis*. 2016;27:75-76.
2. Lefevre S, Valois A, Truchetet F. Allergic contact dermatitis caused by Dermabond((R)). *Contact Derm*. 2016;75:240-241.
3. Leggat PA, Kedjarune U, Smith DR. Toxicity of cyanoacrylate adhesives and their occupational impacts for dental staff. *Ind Health*. 2004;42:207-211.
4. Hivnor CM, Hudkins ML. Allergic contact dermatitis after postsurgical repair with 2-octylcyanoacrylate. *Arch Dermatol*. 2008;144:814-815.
5. Bowen C, Bidinger J, Hivnor C, et al. Allergic contact dermatitis to 2-octyl cyanoacrylate. *Cutis*. 2014;94:183-186.