



6-27-2017

Disseminated *Nocardia cyriacigeorgia* causing pancreatitis in a haploidentical stem cell transplant recipient.

Jason Chen, MD

Department of Medical Oncology, Sidney Kimmel Medical College of Thomas Jefferson University, jason.chen@jefferson.edu

Jonathan Pan, MD

Department of Medical Oncology, Sidney Kimmel Medical College of Thomas Jefferson University, jonathan.pan@jefferson.edu

Joanne Filicko-O'Hara

Department of Medical Oncology, Sidney Kimmel Medical College of Thomas Jefferson University, Joanne.Filicko-O'Hara@jefferson.edu

Margaret Kasner

Department of Medical Oncology, Sidney Kimmel Medical College of Thomas Jefferson University, Margaret.Kasner@jefferson.edu


Phyllis Flomenberg

*Division of Infectious Diseases, Department of Medicine, Sidney Kimmel Medical College of Thomas Jefferson University, Phyllis.Flomenberg@jefferson.edu*Follow this and additional works at: <https://jdc.jefferson.edu/medfp> Part of the [Other Medical Specialties Commons](#)

Recommended Citation

Chen, MD, Jason; Pan, MD, Jonathan; Filicko-O'Hara, Joanne; Kasner, Margaret; and Flomenberg, Phyllis, "Disseminated *Nocardia cyriacigeorgia* causing pancreatitis in a haploidentical stem cell transplant recipient." (2017). *Department of Medicine Faculty Papers*. Paper 210.
<https://jdc.jefferson.edu/medfp/210>

This Article is brought to you for free and open access by the Jefferson Digital Commons. The Jefferson Digital Commons is a service of Thomas Jefferson University's [Center for Teaching and Learning \(CTL\)](#). The Commons is a showcase for Jefferson books and journals, peer-reviewed scholarly publications, unique historical collections from the University archives, and teaching tools. The Jefferson Digital Commons allows researchers and interested readers anywhere in the world to learn about and keep up to date with Jefferson scholarship. This article has been accepted for inclusion in Department of Medicine Faculty Papers by an authorized administrator of the Jefferson Digital Commons. For more information, please contact: JeffersonDigitalCommons@jefferson.edu.



Case report

Disseminated *Nocardia cyriacigeorgia* causing pancreatitis in a haploidentical stem cell transplant recipient



Jason Chen^a, Jonathan Pan^a, Joanne Filicko-O'Hara^b, Margaret Kasner^b, Phyllis Flomenberg^{c,*}

^a Department of Medical Oncology, Sidney Kimmel Medical College of Thomas Jefferson University, 834 Chestnut St., Suite 320, Philadelphia, PA 19107, United States

^b Department of Medical Oncology, Sidney Kimmel Medical College of Thomas Jefferson University, 925 Chestnut St., Suite 420A, Philadelphia, PA 19107, United States

^c Division of Infectious Diseases, Department of Medicine, Sidney Kimmel Medical College of Thomas Jefferson University, 1015 Chestnut St., Suite 1020, Philadelphia, PA 19107, United States

ARTICLE INFO

Keywords:

Nocardia cyriacigeorgia
Disseminated nocardiosis
Acute pancreatitis
Graft-versus-host disease
Stem cell transplant
Immunosuppression

ABSTRACT

We report the first published case of acute pancreatitis secondary to disseminated nocardiosis in a hematopoietic stem cell transplant (HSCT) recipient on chronic immunosuppression for graft-versus-host disease (GVHD). Nocardiosis in the HSCT population is relatively rare, and has not yet been described in haploidentical HSCT recipients. Our patient is a 28-year-old male with a history of haploidentical HSCT and GVHD of the skin and lung who was admitted to the hospital with acute pancreatitis. The workup for the etiology of his pancreatitis was initially unrevealing. He subsequently developed worsening sepsis and respiratory failure despite broad spectrum antimicrobials. After multiple bronchoscopies and pancreatic fluid sampling, he was found to have disseminated nocardiosis with *Nocardia cyriacigeorgia*.

Introduction

Nocardia spp. is an aerobic gram-positive filamentous branching bacterium that is an uncommon cause of opportunistic infections in patients receiving hematopoietic stem cell transplantation (HSCT). While the incidence of nocardiosis in the allogeneic HSCT population is unclear, it is estimated around 0.3 to 1.7% according to two studies in the 1990s [1,2]. Risk factors for infection include immunosuppression for chronic GVHD and use of inhaled pentamidine for pneumocystis prophylaxis [3].

Nocardia can be found throughout the environment, including in water and soil. Due to its ability to aerosolize, it commonly causes a primary pulmonary infection, with a majority of patients presenting with fever, cough, and pleuritic chest pain [4]. However, *Nocardia* can disseminate to other organs, particularly the skin and central nervous system. Nocardial infection of the pancreas has been reported in an immunocompetent patient who had a resection and radiotherapy for bladder cancer [5]. We report the first published case of acute pancreatitis secondary to disseminated nocardiosis in a HSCT recipient on chronic immunosuppression for GVHD.

Patient presentation

The patient is a 28-year-old male who was diagnosed with acute myelogenous leukemia after presenting with fevers and chills. He underwent induction chemotherapy on clinical trial with cytarabine, idarubicin and sirolimus, and subsequent consolidation therapy with high-dose cytarabine. After achieving complete remission, he underwent a haploidentical HSCT from his mother. His conditioning regimen consisted of high-dose total body irradiation and cyclophosphamide. His transplant course was complicated by neutropenic fevers without positive cultures and skin GVHD. He was discharged on tacrolimus, mycophenolate mofetil and high-dose prednisone. His prophylactic antimicrobials included penicillin VK, valacyclovir, voriconazole and inhaled pentamidine every four weeks, due to a sulfonamide allergy. His post-transplant course was unfortunately complicated by staphylococcal bacteremia and pneumonia, influenza and respiratory syncytial viral infections and pseudomonas sinusitis requiring debridement. In addition to skin GVHD, he also developed pulmonary GVHD confirmed by video assisted thoracic surgery (VATS) biopsy 10 months after his HSCT. The biopsy was negative for aerobic, anaerobic, fungal and acid-fast bacilli (AFB) cultures.

The patient then presented in October, two years after his transplant, with fevers and abdominal pain. At that point, he was on

* Corresponding author.

E-mail addresses: Jason.Chen@jefferson.edu (J. Chen), Jonathan.Pan@jefferson.edu (J. Pan), Joanne.Filicko@jefferson.edu (J. Filicko-O'Hara), Margaret.Kasner@jefferson.edu (M. Kasner), Phyllis.Flomenberg@jefferson.edu (P. Flomenberg).

<http://dx.doi.org/10.1016/j.idcr.2017.05.005>

Received 30 January 2017; Received in revised form 9 May 2017; Accepted 9 May 2017

2214-2509/ © 2017 The Authors. Published by Elsevier Ltd. This is an open access article under the CC BY-NC-ND license (<http://creativecommons.org/licenses/by-nc-nd/4.0/>).

dexamethasone 6 mg daily and ruxolitinib 5 mg twice daily for his pulmonary GVHD, and inhaled budesonide and montelukast for his chronic sinusitis. He had been previously on high-dose prednisone and sirolimus, with multiple failed attempts at weaning. He was also on prophylactic posaconazole, valacyclovir, atovaquone and azithromycin. His listed allergies at time of admission were: amoxicillin causing rash, vancomycin causing acute kidney injury, sulfonamide drugs causing rash, and voriconazole causing transaminitis. He was diagnosed with acute pancreatitis with an elevated lipase of 1204 units/l (normal range 13–60 units/l), though CT scan of the abdomen did not show any peripancreatic inflammation.

Workup of the etiology of the pancreatitis was unrevealing. While steroids are a known cause of pancreatitis, the patient had been on both high dose prednisone and dexamethasone in the past without GI complications. The patient denied alcohol use and abdominal ultrasound was negative for cholelithiasis. He had normal triglyceride and calcium levels, negative CMV titers, galactomannan, viral hepatitis serologies, Epstein-Barr virus and adenovirus titers. Stool studies were also negative for infectious diarrheal pathogens. His initial CT scan of the chest to evaluate his fevers showed multiple pulmonary nodules, which were attributed to progression of chronic GVHD (Fig. 1: CT chest on hospital day 4, showing multiple pulmonary nodules and tree-in-bud opacities). He also had a CT of the abdomen that showed a nebulous, hypoattenuating 1 cm lesion in the pancreatic body (Fig. 2: CT abdomen on hospital day 4, with vague 1 cm lesion in pancreatic body).

Due to persistent fevers, he was started on linezolid and meropenem in addition to his prophylactic antimicrobials. Shortly after, he underwent bronchoscopy on hospital day 5, which showed grossly normal airways. Cultures for bacteria, fungus and AFB were initially negative. Bronchoalveolar lavage analysis showed predominantly macrophages, without signs of malignancy, viral or fungal infection. Despite resolution of his abdominal pain and fevers, he had progressive respiratory failure requiring intubation and presumed septic shock of unknown origin.

On hospital day 12, he underwent a second bronchoscopy with both lavage and transbronchial biopsies. His cultures were initially negative although the transbronchial biopsy pathology demonstrated focal interstitial and organizing pneumonia. His antibiotics were broadened by adding amikacin and voriconazole. He was continued on high dose steroids for refractory shock and chronic GVHD and initially showed clinical improvement. His first bronchoscopy cultures showed *Mycobacterium avium* complex (MAC). However, given that no

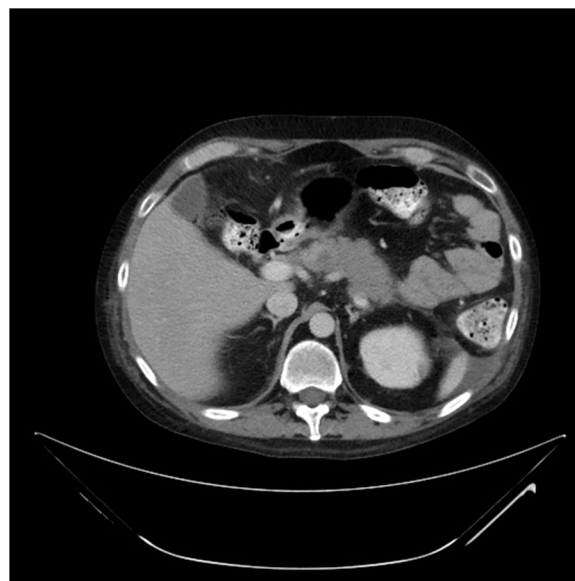


Fig. 2. CT abdomen on hospital day 4, with vague 1 cm lesion in pancreatic body.

subsequent cultures were positive and he clinically improved, this was thought to be due to colonization.

On hospital day 20, he developed another episode of acute abdominal pain. Repeat CT of the abdomen showed a new pancreatic tail fluid collection measuring 6 cm x 4.5 cm x 4.1 cm (Fig. 3: CT abdomen on hospital day 20, showing worsening pancreatic collection). Repeat CT of the chest to evaluate his persistent respiratory failure showed progressively worsening pulmonary nodules with a miliary appearance.

The gastroenterology team evaluated the patient and thought his abdominal CT scan was consistent with a simple pancreatic pseudocyst related to his earlier pancreatitis. His lipase level was normal during this episode and his symptoms resolved without intervention. After being weaned off antibiotics and steroids, he developed recurrent abdominal pain with severe guarding concerning for an acute abdomen. On hospital day 25, a CT angiography of the abdomen was performed. It did not show any mesenteric vascular occlusion but noted that the pancreatic fluid collection had become multi-lobed and enlarged in size, measuring 13.8 cm x 7.2 cm x 6.8 cm. In addition, there was a new intraperitoneal loculated collection near the liver (Fig. 4: CT

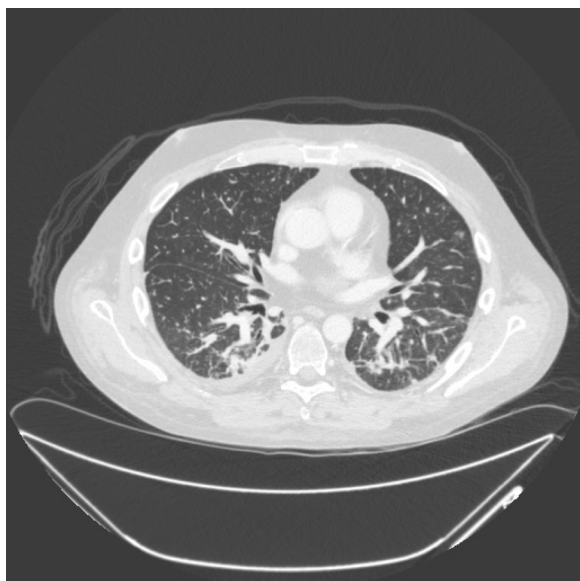

Fig. 1. CT chest on hospital day 4, showing multiple pulmonary nodules and tree-in-bud opacities.

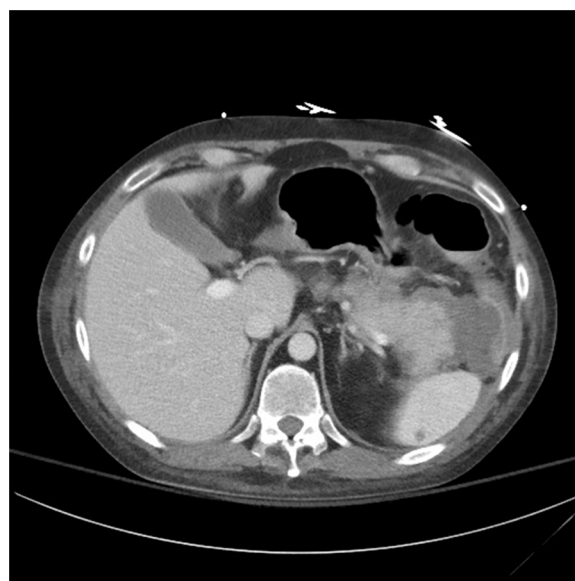

Fig. 3. CT abdomen on hospital day 20, showing worsening pancreatic collection.

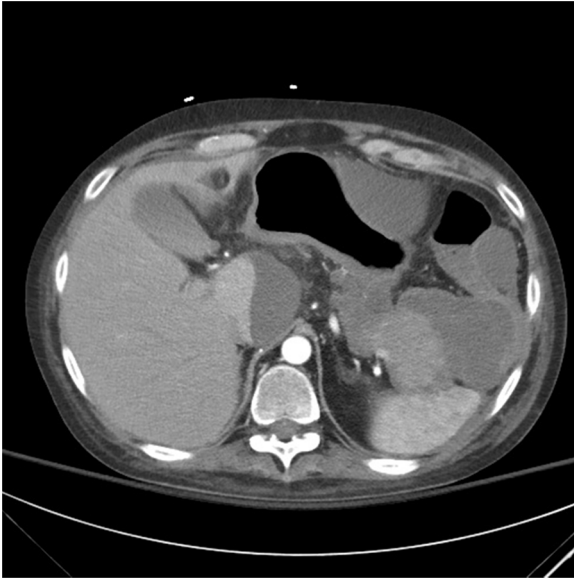


Fig. 4. CT abdomen on hospital day 25, showing worsening pancreatic collection and new caudate lobe collection.

abdomen on hospital day 25, showing worsening pancreatic collection and new caudate lobe collection).

On hospital day 29, he underwent emergent percutaneous catheter drainage of the pancreatic fluid collection. Seven days later, pancreatic fluid cultures grew branching acid-fast Gram-positive bacilli concerning for *Nocardia*. Concurrently, his prior bronchoscopy culture from hospital day 12 grew out the same pathogen. Given the propensity for nocardiosis to affect the CNS, the patient had MRI scans of the brain and complete spine, which showed multiple microabscesses affecting the brain and cervicothoracic spine (Fig. 5: MRI brain on hospital day 36, with punctate enhancing lesions and one notable ring-enhancing lesion (T1 post contrast). The organism was eventually identified as *Nocardia cyriacigeorgia*, with the following susceptibilities: sensitive to trimethoprim-sulfamethoxazole (TMP-SMX), linezolid, amikacin, ceftriaxone, doxycycline, minocycline and tobramycin; intermediate to imipenem; resistant to ciprofloxacin, moxifloxacin, amoxicillin-clavulanate and clarithromycin. The patient was initially started on imipenem (which was narrowed to high-dose ceftriaxone after susceptibilities became available), amikacin and TMP-SMX after

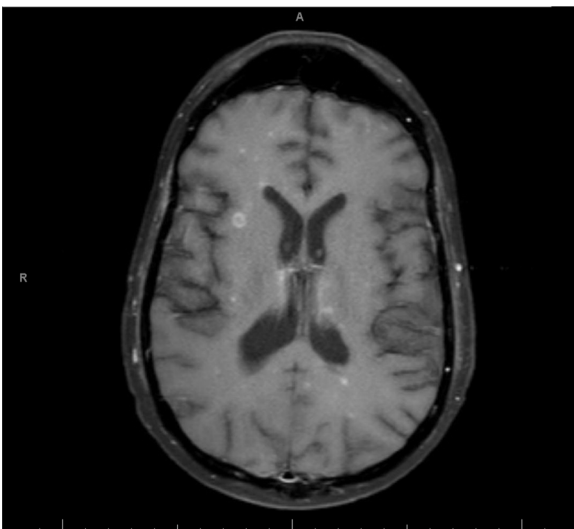


Fig. 5. MRI brain on hospital day 36, with punctate enhancing lesions and one notable ring-enhancing lesion (T1 post contrast).

desensitization due to his sulfonamide allergy.

Discussion

Acute pancreatitis is a common medical diagnosis with several etiologies, though the role of infectious agents is less well understood. Most common infectious etiologies of pancreatitis are viruses, including herpesviruses, viral hepatitis, enteroviruses and HIV, as well as parasite infections such as ascariasis. While the incidence of various infectious causes has not been determined, a 1996 case review showed that a minority of cases reported were bacterial in origin, and out of those, few had positive pancreatic tissue or fluid cultures [6].

This is a rare case of disseminated nocardiosis presenting as acute pancreatitis. Our patient presented with pancreatitis 2 years post HSCT in the setting of chronic immunosuppressive treatment for GVHD. His initial work up did not identify a cause of acute pancreatitis. Unfortunately, it was only after a prolonged hospital stay with multiple imaging and invasive studies that a definitive cause was elucidated. He was initially treated empirically with linezolid and meropenem for fevers and worsening lung infiltrates. Following a negative bronchoscopy, he received increased immunosuppression for a presumed flare of pulmonary GVHD. He then developed recurrent abdominal pain and a new pancreatic fluid collection; aspirate of this fluid identified *Nocardia* on culture. Later, the second bronchoscopy turned positive for *Nocardia*, confirming a lung source of infection. Thus, his clinical picture was complicated by ongoing high-intensity immunosuppression, difficulty interpreting his abnormal chest CT findings in the setting of pulmonary GVHD, and intermittent treatment with broad spectrum antibiotics active against *Nocardia*, which likely reduced the yield from the bronchial aspirate cultures.

Management of disseminated nocardiosis can be difficult because of the variation of antibiotic susceptibilities among different strains and populations, as well as delay in accurate pathogen identification and susceptibilities. Additionally, patients on TMP-SMX prophylaxis are still susceptible to *Nocardia* infection. A 2007 case-control study involving solid organ transplant recipients showed that 69% of affected patients were on TMP-SMX prophylaxis three times weekly prior to infection [8]. Standard therapy for nocardiosis depends on the degree of involvement. Treatment for isolated cutaneous lesions can consist of single-agent TMP-SMX, with alternative therapy based on sensitivities. Treatment of severe infection consists of intravenous TMP-SMX or imipenem, combined with amikacin. However, with evidence of CNS involvement, all three antibiotics are preferred. Of note, our patient had an allergy to TMP-SMX. Because of the long history of effective treatment with TMP-SMX and excellent widespread tissue penetration, in patients with sulfonamide allergy, desensitization therapy is recommended while susceptibilities are pending. In a recent study of 132 cancer patients with nocardiosis in Texas, isolates remained highly susceptible to TMP-SMX [9]. Interestingly, this patient's *Nocardia cyriacigeorgia* isolate susceptibility pattern correlates with the isolates from the above mentioned study, with almost all isolates resistant to fluoroquinolones and clarithromycin. However, the Centers for Disease Control reported increasing resistance of *Nocardia* isolates to sulfonamide antibiotics between 1995 and 2004, with 61% of isolates resistant to SMX and 42% resistant to TMP-SMX [10]. This highlights the high degree of variability in antibiotic susceptibility depending on geographic location.

The adequate duration of therapy depends on the severity of illness. Overall, there is a paucity of clinical trial data and recommendations are based mostly on expert opinion. Most advocate for initial intravenous therapy for six weeks, with transition to oral therapy for a total of at least three months of treatment [11]. However, with patients requiring prolonged immunosuppression on treatment for viral co-infection or with graft failure, disease management may require longer courses of therapy. One retrospective study of 27 HSCT patients with nocardiosis from 1969 to 1995 demonstrated survival rates of 66% at

one year with a majority of patients receiving a sulfonamide-containing regimen [1].

In summary, this is a unique case of disseminated nocardiosis presenting as acute pancreatitis in an immunocompromised patient. Only through extensive work up including invasive procedures to obtain sampling of peripancreatic and bronchial fluid was the organism isolated. The patient was aggressively treated with a multidrug regimen for severe disseminated disease until culture sensitivities were determined, with initial clinical improvement. However, he suddenly decompensated approximately 1 month after initiation of nocardial antimicrobial therapy, was placed on comfort measures, and expired shortly afterwards. Autopsy revealed widespread distribution of microabscesses in the kidneys, liver, lungs, spleen, heart (myocardium and endocardium), mesentery and thyroid.

Funding sources

This research did not receive any specific grant from funding agencies in the public, commercial, or not-for-profit sectors.

Consent

As part of participation on an investigational trial, the patient

consented to publications of any transplant-related outcomes.

References

- [1] van Burik JA, Hackman RC, Nadeem SQ, Hiemenz JW, White MH, Flowers ME, Bowden RA. Nocardiosis after bone marrow transplantation: a retrospective study. *Clin Infect Dis* 1997;24(6):1154–60.
- [2] Choucino C, Goodman SA, Greer JP, Stein RS, Wolff SN, Dummer JS. Nocardial infections in bone marrow transplant recipients. *Clin Infect Dis* 1996;23(5):1012–9.
- [3] Daly AS. Systemic nocardiosis following allogeneic bone marrow transplantation. *Transpl Infect Dis* 2003;5(1):20.
- [4] Minero MV, Marín M, Cercenado E, Rabadán PM, Bouza E, Muñoz P. Nocardiosis at the turn of the century. *Medicine* 2009;88(4):250.
- [5] Meier B, Metzger U, Mller F, Siegenthaler W, Lthy R. Successful treatment of a pancreatic nocardia asteroides abscess with amikacin and surgical drainage. *Antimicrob Agents Chemother* 1986;29(1):150–1.
- [6] Parenti DM, Steinberg W, Kang P. Infectious causes of acute pancreatitis. *Pancreas* 1996;13(4):371.
- [8] Peleg AY, Husain S, Qureshi ZA, Silveira FP, Sarumi M, Shutt KA, Kwak EJ, Paterson DL. Risk factors, clinical characteristics, and outcome of nocardia infection in organ transplant recipients: a matched case-control study. *Clin Infect Dis* 2007;44(10):1307–14.
- [9] Wang H, Seo Y, LaSala PR, Tarrand JJ, Han XY. Nocardiosis in 132 patients with cancer. *Am J Clin Pathol* 2014;142(4):513–23.
- [10] Uhde KB, Pathak S, McCullum Jr I, Jannat-Khah DP, Shadomy SV, Dykewicz CA, Clark TA, Smith TL, Brown JM. Antimicrobial-resistant nocardia isolates, United States, 1995–2004. *Clin Infect Dis* 2010;51(12):1445–8.
- [11] Lerner PI. Nocardiosis. *Clin Infect Dis* 1996;22(6):891–905.