



4-1-2017

Anterior Cervical Infection: Presentation and Incidence of an Uncommon Postoperative Complication.

George M. Ghobrial

Thomas Jefferson University, george.ghobrial@jefferson.edu

James S. Harrop

Thomas Jefferson University, james.harrop@jefferson.edu

Rick C. Sasso

Indiana University; Indiana Spine Group

Chadi A. Tannoury

Boston University Medical Center

Tony Tannoury

Boston University Medical Center

See next page for additional authors

[Let us know how access to this document benefits you](#)

Follow this and additional works at: <https://jdc.jefferson.edu/neurosurgeryfp>

 Part of the [Neurology Commons](#), and the [Surgery Commons](#)

Recommended Citation

Ghobrial, George M.; Harrop, James S.; Sasso, Rick C.; Tannoury, Chadi A.; Tannoury, Tony; Smith, Zachary A.; Hsu, Wellington K.; Arnold, Paul M.; Fehlings, Michael G.; Mroz, Thomas E.; De Giacomo, Anthony F.; Jobse, Bruce C.; Rahman, Ra'Kerry K.; Thompson, Sara E.; and Riew, K Daniel, "Anterior Cervical Infection: Presentation and Incidence of an Uncommon Postoperative Complication." (2017). *Department of Neurosurgery Faculty Papers*. Paper 86. <https://jdc.jefferson.edu/neurosurgeryfp/86>

Authors

George M. Ghobrial, James S. Harrop, Rick C. Sasso, Chadi A. Tannoury, Tony Tannoury, Zachary A. Smith, Wellington K. Hsu, Paul M. Arnold, Michael G. Fehlings, Thomas E. Mroz, Anthony F. De Giacomo, Bruce C. Jobse, Ra'Kerry K. Rahman, Sara E. Thompson, and K Daniel Riew

Anterior Cervical Infection: Presentation and Incidence of an Uncommon Postoperative Complication

Global Spine Journal
2017, Vol. 7(1S) 12S-16S
© The Author(s) 2017
Reprints and permission:
sagepub.com/journalsPermissions.nav
DOI: 10.1177/2192568216687546
journals.sagepub.com/home/gsj



George M. Ghobrial, MD¹, James S. Harrop, MD, FACS¹, Rick C. Sasso, MD^{2,3}, Chadi A. Tannoury, MD⁴, Tony Tannoury, MD⁴, Zachary A. Smith, MD⁵, Wellington K. Hsu, MD⁵, Paul M. Arnold, MD, FACS⁶, Michael G. Fehlings, MD, PhD⁷, Thomas E. Mroz, MD⁸, Anthony F. De Giacomo, MD⁹, Bruce C. Jobse, BA⁴, Ra'Kerry K. Rahman, MD^{10,11}, Sara E. Thompson, MS⁵, and K. Daniel Riew, MD^{12,13}

Abstract

Study Design: Retrospective multi-institutional case series.

Objective: The anterior cervical discectomy and fusion (ACDF) affords the surgeon the flexibility to treat a variety of cervical pathologies, with the majority being for degenerative and traumatic indications. Limited data in the literature describe the presentation and true incidence of postoperative surgical site infections.

Methods: A retrospective multicenter case series study was conducted involving 21 high-volume surgical centers from the AOSpine North America Clinical Research Network, selected for their excellence in spine care and clinical research infrastructure and experience. Medical records for 17 625 patients who received cervical spine surgery (levels from C2 to C7) between January 1, 2005, and December 31, 2011, inclusive, were reviewed to identify the occurrence of 21 predefined treatment complications. Patients who underwent an ACDF were identified in the database and reviewed for the occurrence of postoperative anterior cervical infections.

Results: A total of 8887 patients were identified from a retrospective database analysis of 21 centers providing data for postoperative anterior cervical infections (17/21, 81% response rate). A total of 6 postoperative infections after ACDF were identified for a mean rate of 0.07% (range 0% to 0.39%). The mean age of patients identified was 57.5 (SD = 11.6, 66.7% female). The mean body mass index was 22.02. Of the total infections, half were smokers (n = 3). Two patients presented with myelopathy, and 3 patients presented with radiculopathic-type complaints. The mean length of stay was 4.7 days. All patients were treated aggressively with surgery for management of this complication, with improvement in all patients. There were no mortalities.

Conclusion: The incidence of postoperative infection in ACDF is exceedingly low. The management has historically been urgent irrigation and debridement of the surgical site. However, due to the rarity of this occurrence, guidance for management is limited to retrospective series.

¹ Thomas Jefferson University, Philadelphia, PA, USA

² Indiana University, Indianapolis, IN, USA

³ Indiana Spine Group, Indianapolis, IN, USA

⁴ Boston University Medical Center, Boston, MA, USA

⁵ Northwestern University, Feinberg School of Medicine, Chicago, IL, USA

⁶ Kansas University Medical Center, Kansas City, KS, USA

⁷ Toronto Western Hospital, Toronto, Ontario, Canada

⁸ Cleveland Clinic, Cleveland, OH, USA

⁹ Boston University, Boston, MA, USA

¹⁰ Springfield Clinic, LLC, Springfield, IL, USA

¹¹ Southern Illinois University, Springfield, IL, USA

¹² Columbia University, New York, NY, USA

¹³ New York-Presbyterian/The Allen Hospital, New York, NY, USA

Corresponding Author:

James S. Harrop, Thomas Jefferson University, 909 Walnut Street, Third Floor, Philadelphia, PA 19107, USA.

Email: James.harrop@jefferson.edu



This article is distributed under the terms of the Creative Commons Attribution-NonCommercial-NoDerivs 4.0 License (<http://www.creativecommons.org/licenses/by-nc-nd/4.0/>) which permits non-commercial use, reproduction and distribution of the work as published without adaptation or alteration, without further permission provided the original work is attributed as specified on the SAGE and Open Access pages (<https://us.sagepub.com/en-us/nam/open-access-at-sage>).

Keywords

lumbar spine, durotomy, cerebrospinal fluid leak, complications, trauma, thoracolumbar

Introduction

The anterior cervical discectomy and fusion (ACDF) is one of the most commonly performed spinal surgeries,¹ affording the surgeon the flexibility to treat a variety of cervical pathologies, with a low rate of major complication.² However, due to the nature of the anterolateral corridor of the neck, intraoperative traction on the esophagus has resulted in a dysphagia rate as high as 71%.^{3,4} One of the most feared complications of the anterior cervical approach is esophageal perforation, which is uncommonly reported as a result of inadvertent injury due to the proximity of the esophagus to the working corridor of the sharp instruments used in cervical discectomy and fusion.²

Overall, the ACDF is well-tolerated and an ideal choice for single or multilevel degenerative disease with several surgical goals: decompression of the neural elements, restoration of cervical lordosis, the removal of anterior compressive etiologies, and arthrodesis. Postoperative morbidity is relatively low, attributed to the minimal soft tissue and muscular dissection afforded by the anterolateral Smith-Robinson approach as compared to posterior midline subperiosteal dissections, which result in the elevation and retraction of posterior paraspinal musculature. As such, more and more surgeons find themselves performing a greater proportion of ACDFs in ambulatory surgery centers on a case-by-case basis.⁵ As such, greater attention is focused toward limiting postoperative pain and complications.

Given the limited data on this rare complication, the authors conduct a multi-institutional retrospective database review to determine the reported frequency of rare complications reported in cervical spinal surgery, namely, the incidence of postoperative infection in ACDF.

Methods

A retrospective multicenter case series study was conducted involving 21 high-volume surgical centers from the AOSpine North America Clinical Research Network, selected for their excellence in spine care and clinical research infrastructure and experience. Medical records for 17 625 patients who received cervical spine surgery (levels from C2 to C7) between January 1, 2005, and December 31, 2011, inclusive, were reviewed to identify the occurrence of 21 predefined treatment complications. The complications included reintubation requiring evacuation, esophageal perforation, epidural hematoma, C5 palsy, recurrent laryngeal nerve palsy, superior laryngeal nerve palsy, hypoglossal or glossopharyngeal nerve palsy, dural tear, brachial plexopathy, blindness, graft extrusion, misplaced screws requiring reoperation, anterior cervical infection, carotid artery injury or cerebrovascular accident, vertebral artery injuries, Horner's syndrome, thoracic duct injury, quadriplegia, intraoperative death, revision of arthroplasty, and pseudomeningocele.

Trained research staff at each site abstracted the data from medical records, surgical charts, radiology imaging, narratives, and other source documents for the patients who experienced one or more of the complications from the list. Data was transcribed into study-specific paper case report forms. Copies of case report forms were transferred to the AOSpine North America Clinical Research Network Methodological Core for processing, cleaning, and data entry.

Descriptive statistics were provided for baseline patient characteristics. Patients who had undergone an ACDF were identified in the database and reviewed for the occurrence of postoperative anterior cervical infections. A paired *t* test was used to analyze changes in clinical outcomes at follow-up compared to preoperative status.

Results

A total of 8887 patients were identified from a retrospective database analysis of 17 centers providing data for postoperative anterior cervical infections (17/23, 74% response rate). A total of 6 postoperative infections after ACDF were identified for a mean rate of 0.07% (range 0% to 0.39%). The mean age of patients identified was 57.5 years (SD = 11.6, 66.7% female). The mean body mass index was 22.02. Of the total infections, half were smokers (*n* = 3). Two patients presented with myelopathy and 3 presented with radiculopathic-type complaints. One patient presented initially prior to cervical fixation with a cervical fracture. Surgeries were performed ranging from C3 to T1, with the most common level treated being C5-C6 (*n* = 5). Discectomy and fusion was performed in 5 cases, whereas in 1 patient a corpectomy was performed (16.7%). The mean operative duration was 125 minutes, with a mean blood loss of 85 mL, and no transfusions were required during surgery. In none of the cases were esophageal injuries identified. The mean length of stay was 4.7 days. All patients were treated aggressively with surgery for management of this complication, with improvement in all patients. There were no mortalities.

Discussion

The incidence of postoperative infection after ACDF is exceedingly rare, with a mean incidence of 0.07% in this multi-institutional study. This complication is found to be lower than expected with previously reported rates ranging from 0.1% to 1.6% in the literature.^{1,6} Fountas and colleagues¹ report in a retrospective series of 1015 patients only one postoperative wound infection (0.15%). In one retrospective series of anterior cervical discectomy without fusion, Bertalanffy and colleagues reported only one postoperative infection out of 450 (0.2%) presenting as an anterior cervical epidural abscess requiring reoperation.⁷ With so few reported infections, statistically significant risk factors were not identifiable in our study, nor in

prior retrospective series. It is not surprising that as the size of the population of surgical patients is retrospectively studied, the lower the incidence of surgical site infection with ACDF. Certainly, the retrospective design of these studies is a significant limitation as patients with a postoperative infection could have presented for complication management elsewhere at different centers and not have been tracked.

Most commonly, postoperative infections occur at the operative site,^{1,2,7-11} while those originating in the vertebral bone with subsequent spread to the adjacent disc space^{12,13} or adjacent levels through the epidural plexus⁷ occur less commonly. Infections of the anterior cervical spine carry several unique concerns when compared to midline posterior spinal exposures. Due to the adjacent location of various critical structures in the neck to the vertebral and prevertebral compartments, the potential for severe inflammation, mass effect from pyogenic abscess formation, and ultimately airway compromise makes this complication an urgent issue to manage (Figure 1).

Patients with postoperative infection may or may not present with the classic triad of fever, surgical site pain, and neurologic deficit. Persistent leukocytosis is particularly common with esophageal perforation, and clinical concern is warranted in the case of fevers and leukocytosis unresponsive to broad-spectrum antibiotics.¹⁴ Further diagnostic support may be provided by an elevated C-reactive protein, which would be expected to routinely normalize in approximately 6 days after surgery.¹⁵ Clinical suspicion of a cervical spinal infection in a stable patient should be followed by an immediate magnetic resonance imaging of the spine to confirm abscess. Urgent surgical evacuation is recommended in the case of wound drainage or abscess formation due to the concern for rapid neurological worsening from a space occupying abscess in the spinal canal, or epidural abscess formation.

No study has evaluated timing for the evacuation of surgical site infection in the neck, and clinical judgment should be guided by the patient's oxygenation and airway status. Regarding the formation of epidural abscess from an underlying osteodiscitis, guidance regarding urgent treatment is limited to class III evidence in the literature and no clear statistical benefit has been shown with early versus delayed (>24 hours) surgical evacuation of a cervical spinal infection treatment due to very small populations of study.¹⁶⁻²²

Esophageal Perforation

Postoperative spinal infections following ACDFs are rare, with a reported incidence in the literature ranging from 0.1% to 1.6%, with the majority of guidance in the literature derived from retrospective studies.^{1,6} Factors thought to increase the risk of postoperative infection include esophageal perforation or Zenker's diverticulum, 2 conditions that would provide a conduit for gastrointestinal flora to the anterior cervical wound bed, as well as postoperative bacteremia and systemic infections.⁸ It is prudent that in the event of a suspected wound infection that an esophageal perforation is ruled out, as

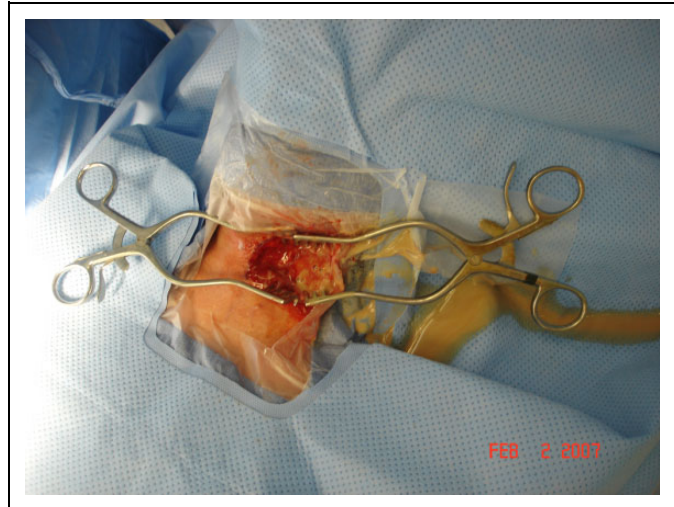


Figure 1. Intraoperative photograph demonstrating copious purulent drainage on reoperation after a prior one-level ACDF was performed. Urgent surgical evacuation is recommended by the authors due to the potential for airway compromise by inflammation and compression by an expansile purulent abscess.

irrigation and debridement of a wound infection will lead to reaccumulation of infection. Symptoms of perforation commonly include increasing postoperative neck pain, erythema, fevers, wound drainage, dysphagia, and elevated C-reactive protein and erythrocyte sedimentation rate. Esophageal perforation is much more serious and could rapidly prove fatal if not promptly diagnosed, as the swelling and infection can expand at a much more rapid rate.¹

Most commonly, postoperative infections occur in the early period of a few weeks,^{1,12,23} although delayed presentations have been reported.⁸ An increased surgical complexity, such as with the number of levels fused, translates into a greater number of surgical implants and bone graft, all of which are foreign bodies that can theoretically increase the risk for postoperative cervical spine infections. Therefore, in the setting of recurrent fevers in the postoperative setting after ACDF, the authors recommend a formal evaluation of swallowing function, which can include a direct fiber-optic evaluation or radiographic study, to be directed by an otolaryngologist. Prior study has shown that leukocytosis is invariably persistent in the postoperative setting with esophageal perforation.¹⁴ Moreover, in the case of a suspected esophageal perforation on clinical or direct fiber-optic evaluation, barium esophagogram has been shown to be an effective test for the diagnosis of esophageal leak.²⁴

Cervical spine surgery has undergone a paradigm shift toward a decompression of anterior compressive etiologies while simultaneously providing a continually less invasive surgical plan. The use of allograft bone instead of autograft bone graft has seen increased use in a push to improve postoperative ambulation and lower donor site pain and morbidity from the harvest of iliac crest tricortico cancellous autograft bone.²⁵ Iliac crest autograft harvest sites represent an additional source of pain and potential site of postoperative infection.^{10,26}

Surgical technique and implantation has also undergone a gradual change in focus toward decreasing intraoperative destruction of the soft tissues as well as limiting postoperative irritation and swelling of the prevertebral tissues and esophagus by the implants.²⁷

Inadequate fixation or pseudoarthrosis can result in eventual migration of the hardware and potentially erosion and perforation of the esophagus in extreme cases.²⁸⁻³¹ Screw migration and esophageal perforation has even been reported to result in a delayed fusion.³¹ Arguably, the number one cause of esophageal perforation is technical error. The push behind the recent attention to limiting morbidity from the modified Smith-Robinson approach has been sparked in part by the economic benefit to perform these procedures in a low-cost center, such as an ambulatory surgery center.⁵

Limitations

Postoperative anterior cervical spinal infections are rare, and conceivably could be higher than the 0.05% incidence found in this study, where data was collected prospectively. There were no cases of recurrent infection, although long-term follow-up of these patients were unavailable and additional infections could have been treated in other tertiary care centers. Postoperative tracking of complications in retrospective studies are unreliable as many patients may settle for follow-up care at local spinal care centers, particularly if symptoms due to an anterior cervical infection warranting urgent evaluation were present such as a neurologic deficit or airway compromise. When considering the fact that surgical site infections could take several weeks to manifest, well after hospital discharge, the rate of infection could be significantly higher than tracked by this inpatient analysis. The exact cause of the postoperative infections reported in the survey were not available as well as any potential risk factors for postoperative infection, which are interesting questions not fully investigated by this study.

Conclusion

The incidence of postoperative infection in anterior cervical discectomy and fusion is exceedingly low. The management has historically been urgent irrigation and debridement of the surgical site. However, due to the rarity of this occurrence, guidance for management is limited to retrospective series.

Authors' Note

This study was ethically approved by the Institutional Ethics Committees (IEC) at all participating sites.

Declaration of Conflicting Interests

The author(s) declared the following potential conflicts of interest with respect to the research, authorship, and/or publication of this article: Tony Tannoury reports grants from AOSpine North America during the conduct of the study; Wellington K. Hsu reports grants from AOSpine North America during the conduct of the study, personal fees from Medtronic, personal fees from Stryker, personal fees from Bacterin, personal fees from Graftys, personal fees from

Ceramtec, personal fees from Relievent, personal fees from Bioventus, personal fees from Globus, personal fees from SpineSmith, outside the submitted work; Michael G. Fehlings reports grants from AOSpine North America during the conduct of the study; Thomas E. Mroz reports other from AO Spine during the conduct of the study, personal fees from Stryker, personal fees from Ceramtec, other from Pearl Diver, outside the submitted work; Bruce C. Jobse reports grants from AOSpine North America during the conduct of the study; Sara E. Thompson reports grants from AOSpine North America during the conduct of the study; K. Daniel Riew reports personal fees from AOSpine International, other from Global Spine Journal, other from Spine Journal, other from Neurosurgery, personal fees from Multiple Entities for defense, plaintiff, grants from AOSpine, grants from Cerapedics, grants from Medtronic, personal fees from AOSpine, personal fees from NASS, personal fees from Biomet, personal fees from Medtronic, nonfinancial support from Broadwater, outside the submitted work; George M. Ghobrial reports grants from AOSpine North America, during the conduct of the study; James S. Harrop reports grants from AOSpine North America, during the conduct of the study; personal fees from Depuy spine, personal fees from Tejin, Asterias, Bioventus, outside the submitted work; Rick C. Sasso reports grants from AOSpine North America, during the conduct of the study; personal fees from medtronic, grants from medtronic, grants from K2, outside the submitted work; Chadi A. Tannoury reports grants from AOSpine North America, during the conduct of the study; Zachary A. Smith reports grants from AOSpine North America, during the conduct of the study; Paul M. Arnold reports grants from AOSpine North America, during the conduct of the study; other from Z-Plasty, other from Medtronic Sofamore Danek, other from Stryker Spine, other from FzioMed, other from AOSpine North America, other from Life Spine, other from Integra Life, other from Spine Wave, other from MIEMS, other from Cerapedics, other from AOSpine North America, outside the submitted work; Anthony F. De Giacomo reports grants from AOSpine North America, during the conduct of the study; Ra'Kerry K. Rahman reports grants from AOSpine North America, during the conduct of the study; in addition, Dr. Rahman has a patent Deformity System & Pedicle Screws pending.

Funding

The author(s) disclosed receipt of the following financial support for the research, authorship, and/or publication of this article: This study was sponsored by AOSpine North America Inc, a 501(c)3 nonprofit corporation.

References

1. Fountas KN, Kapsalaki EZ, Nikolakakos LG, et al. Anterior cervical discectomy and fusion associated complications. *Spine (Phila Pa 1976)*. 2007;32:2310-2317. doi:10.1097/BRS.0b013e318154c57e.
2. Tew JM Jr, Mayfield FH. Complications of surgery of the anterior cervical spine. *Clin Neurosurg*. 1976;23:424-434.
3. Anderson KK, Arnold PM. Oropharyngeal dysphagia after anterior cervical spine surgery: a review. *Global Spine J*. 2013;3:273-286. doi:10.1055/s-0033-1354253.
4. Chen CJ, Saulle D, Fu KM, Smith JS, Shaffrey CI. Dysphagia following combined anterior-posterior cervical spine surgeries. *J Neurosurg Spine*. 2013;19:279-287. doi:10.3171/2013.6.SPINE121134.

5. Baird EO, Egorova NN, McAnany SJ, Qureshi SA, Hecht AC, Cho SK. National trends in outpatient surgical treatment of degenerative cervical spine disease. *Global Spine J.* 2014;4:143-150. doi:10.1055/s-0034-1376917.
6. Christiano LD, Goldstein IM. Late prevertebral abscess after anterior cervical fusion. *Spine (Phila Pa 1976).* 2011;36:E798-E802. doi:10.1097/BRS.0b013e3181fc9b09.
7. Bertalanffy H, Eggert HR. Complications of anterior cervical discectomy without fusion in 450 consecutive patients. *Acta Neurochir (Wien).* 1989;99:41-50.
8. Jin SW, Kim SH, Choi JI, Ha SK, Lim DJ. Late infection from anterior cervical discectomy and fusion after twenty years. *Korean J Spine.* 2014;11:22-24. doi:10.14245/kjs.2014.11.1.22.
9. Sasso RC, Garrido BJ. Postoperative spinal wound infections. *J Am Acad Orthop Surg.* 2008;16:330-337.
10. Miller LE, Block JE. Safety and effectiveness of bone allografts in anterior cervical discectomy and fusion surgery. *Spine (Phila Pa 1976).* 2011;36:2045-2050. doi:10.1097/BRS.0b013e3181ff37eb.
11. Ozkan N, Wrede K, Ardeshiri A, et al. Cervical spondylodiscitis- a clinical analysis of surgically treated patients and review of the literature. *Clin Neurol Neurosurg.* 2014;117:86-92. doi:10.1016/j.clineuro.2013.11.029.
12. Basu S, Sreeramalingam R. Adjacent level spondylodiscitis after anterior cervical decompression and fusion. *Indian J Orthop.* 2012;46:360-363. doi:10.4103/0019-5413.96367.
13. Kulkarni AG, Hee HT. Adjacent level discitis after anterior cervical discectomy and fusion (ACDF): a case report. *Eur Spine J.* 2006;15(suppl 5):559-563. doi:10.1007/s00586-005-0003-x.
14. Khoo SY, Deimel GW, Park JG. 87-year-old woman with painful swallowing. *Mayo Clin Proc.* 2010;85:e86-e89. doi:10.4065/mcp.2010.0352.
15. Hegde V, Meredith DS, Kepler CK, Huang RC. Management of postoperative spinal infections. *World J Orthop.* 2012;3:182-189. doi:10.5312/wjo.v3.i11.182.
16. Ghobrial GM, Viereck MJ, Margiotta PJ, et al. Surgical management in 40 consecutive patients with cervical spinal epidural abscesses: shifting towards circumferential treatment. *Spine (Phila Pa 1976).* 2015;40:E949-E953. doi:10.1097/BRS.0000000000000942.
17. Adogwa O, Karikari IO, Carr KR, et al. Spontaneous spinal epidural abscess in patients 50 years of age and older: a 15-year institutional perspective and review of the literature: clinical article. *J Neurosurg Spine.* 2014;20:344-349. doi:10.3171/2013.11.SPINE13527.
18. Ghobrial GM, Beygi S, Viereck MJ, et al. Timing in the surgical evacuation of spinal epidural abscesses. *Neurosurg Focus.* 2014;37:E1. doi:10.3171/2014.6.FOCUS14120.
19. Shousha M, Boehm H. Surgical treatment of cervical spondylodiscitis: a review of 30 consecutive patients. *Spine (Phila Pa 1976).* 2012;37:E30-E36. doi:10.1097/BRS.0b013e31821bdfb2.
20. Schimmer RC, Jeanneret C, Nunley PD, Jeanneret B. Osteomyelitis of the cervical spine: a potentially dramatic disease. *J Spinal Disord Tech.* 2002;15:110-117.
21. Reihnsaus E, Waldbaur H, Seeling W. Spinal epidural abscess: a meta-analysis of 915 patients. *Neurosurg Rev.* 2000;23:175-204.
22. Shousha M, Heyde C, Boehm H. Cervical spondylodiscitis: change in clinical picture and operative management during the last two decades. A series of 50 patients and review of literature. *Eur Spine J.* 2015;24:571-576. doi:10.1007/s00586-014-3672-5.
23. Korovessis P, Repantis T, Vitsas V, Vardakastanis K. Cervical spondylodiscitis associated with oesophageal perforation: a rare complication after anterior cervical fusion. *Eur J Orthop Surg Traumatol.* 2013;23(suppl 2):S159-S163. doi:10.1007/s00590-012-1092-y.
24. Swanson JO, Levine MS, Redfern RO, Rubesin SE. Usefulness of high-density barium for detection of leaks after esophagogastrectomy, total gastrectomy, and total laryngectomy. *AJR Am J Roentgenol.* 2003;181:415-420. doi:10.2214/ajr.181.2.1810415.
25. Skeppholm M, Olerud C. Pain from donor site after anterior cervical fusion with bone graft: a prospective randomized study with 12 months of follow-up. *Eur Spine J.* 2013;22:142-147. doi:10.1007/s00586-012-2456-z.
26. Schnee CL, Freese A, Weil RJ, Marcotte PJ. Analysis of harvest morbidity and radiographic outcome using autograft for anterior cervical fusion. *Spine (Phila Pa 1976).* 1997;22:2222-2227.
27. Wojewnik B, Ghanayem AJ, Tsitsopoulos PP, et al. Biomechanical evaluation of a low profile, anchored cervical interbody spacer device in the setting of progressive flexion-distraction injury of the cervical spine. *Eur Spine J.* 2013;22:135-141. doi:10.1007/s00586-012-2446-1.
28. Gazzeri R, Tamorri M, Faiola A, Gazzeri G. Delayed migration of a screw into the gastrointestinal tract after anterior cervical spine plating. *Spine (Phila Pa 1976).* 2008;33:E268-E271. doi:10.1097/BRS.0b013e31816b8831.
29. Qian Y, Xu G, Zhang J, Zhao X, Wen D. Anterior migration of spinal cord after cervical corpectomy. *Eur Spine J.* 2012;21(suppl 4):S396-S399. doi:10.1007/s00586-011-1843-1.
30. Sahjpal RL. Esophageal perforation from anterior cervical screw migration. *Surg Neurol.* 2007;68:205-209. doi:10.1016/j.surneu.2006.09.032.
31. Tsermoulas G, Bhattathiri PS. Anterior migration of prosthesis following cervical arthroplasty. *Br J Neurosurg.* 2013;27:132-133. doi:10.3109/02688697.2012.703354.