

4-26-2017

OSA and Primary Snoring: Palatal Surgery and Office-Based Procedures

Adam Vasconcellos, MD

*Department of Otolaryngology- Head and Neck Surgery, Thomas Jefferson University Hospital,
adam.vasconcellos@jefferson.edu*

Let us know how access to this document benefits you

Follow this and additional works at: <http://jdc.jefferson.edu/otograndrounds>Part of the [Otolaryngology Commons](#)

Recommended Citation

Vasconcellos, MD, Adam, "OSA and Primary Snoring: Palatal Surgery and Office-Based Procedures" (2017). *Department of Otolaryngology - Head and Neck Surgery Faculty, Presentations and Grand Rounds*. Presentation 72.

<http://jdc.jefferson.edu/otograndrounds/72>

This Article is brought to you for free and open access by the Jefferson Digital Commons. The Jefferson Digital Commons is a service of Thomas Jefferson University's [Center for Teaching and Learning \(CTL\)](#). The Commons is a showcase for Jefferson books and journals, peer-reviewed scholarly publications, unique historical collections from the University archives, and teaching tools. The Jefferson Digital Commons allows researchers and interested readers anywhere in the world to learn about and keep up to date with Jefferson scholarship. This article has been accepted for inclusion in Department of Otolaryngology - Head and Neck Surgery Faculty, Presentations and Grand Rounds by an authorized administrator of the Jefferson Digital Commons. For more information, please contact: JeffersonDigitalCommons@jefferson.edu.

OSA and Primary Snoring: Palatal Surgery and Office-Based Procedures

Adam Vasconcellos, MD


Department of Otolaryngology, Head & Neck Surgery


Thomas Jefferson University Hospital

April 26, 2017

Disclosures

- None









The NEW ENGLAND JOURNAL of MEDICINE

ORIGINAL ARTICLE

The Association between Sleep Apnea and the Risk of Traffic Accidents

J. Terán-Santos, M.D., A. Jimenez-Gomez, M.D., J. Cordero-Guevara, M.D., and *the Cooperative Group Burgos–Santander
N Engl J Med 1999; 340:847-851 | March 18, 1999 | DOI: 10.1056/NEJM199903183401104

- Case population N = 102 drivers receiving emergency care after accidents
- Control pop n = 152 from primary care centers, matched age/sex
- Mean age 44, men 77%
- AHI 10+ = OR 6.3 of traffic accident

The Science of Sleep



- 1836: Charles Dickens “The Pickwick Papers”



- Late 1800s: Doctors began to lump sleep apnea syndromes together using the term “Pickwickian Syndrome”
- 1960s: multiple reports to suggest that obesity is not essential for sleep related breathing problems

The Science of Sleep

**Christian
Guilleminault**

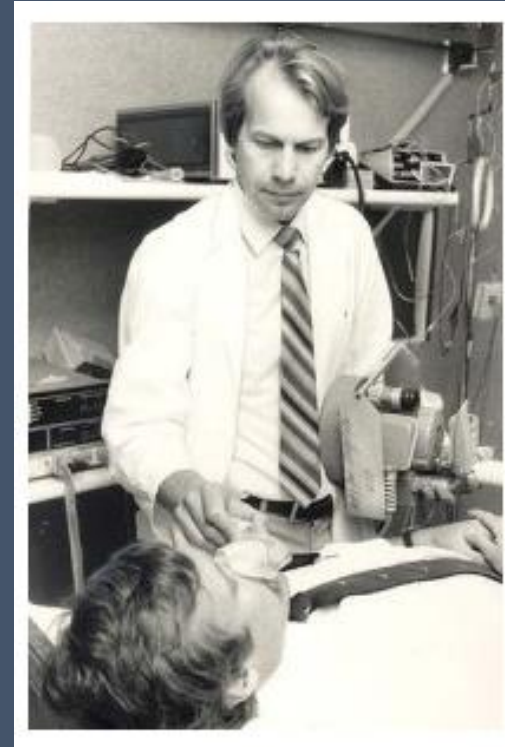


**William
Dement**

- 1970 – first sleep clinic established at Stanford
- Observed correlation of prolonged pauses (apneas) in sleep with blood pressure rises
- Guilleminault documented reversal of cardiac arrhythmias, HTN with tracheostomy
- Defined OSAS and later, AHI

The Science of Sleep

- 1978: Remmers et al: obstruction in apnea commonly at level of soft palate / oropharynx, not the larynx
- 1980: Colin Sullivan applied positive pressure air via nasal passages to a patient with severe OSAS



The Promise of Sleep

- General well-being
- Insulin metabolism
- Cardiovascular health
- Cognitive functioning



The Plan

What I'll cover:

- OSA and Primary Snoring
- Anatomical Sites of Obstruction
- DISE Interpretation
- Minimally Invasive Techniques for Primary Snoring
- Palatal Surgery for OSA

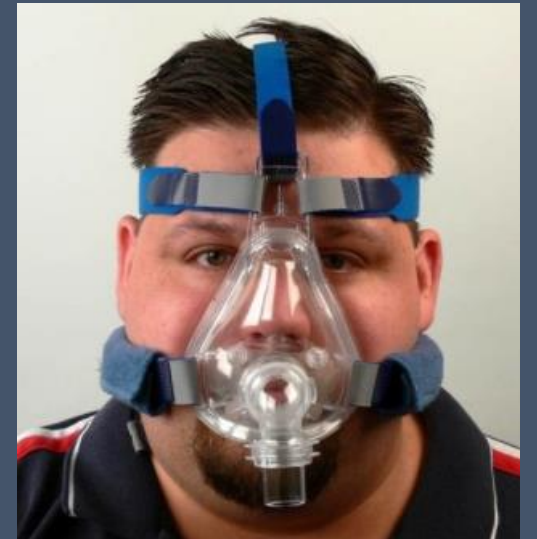The Plan

What I'll cover:

- OSA and Primary Snoring
- Anatomical Sites of Obstruction
- DISE Interpretation
- Minimally Invasive Techniques for Primary Snoring
- Palatal Surgery for OSA

Not for today

- Upper Airway Stimulation
- Extra-Palatal Sites of Intervention
- Kids
- CPAP

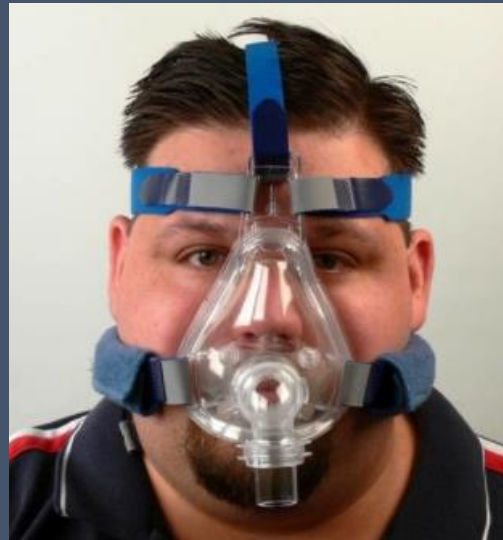

The Stats on OSA

- Dx Criteria (ICSD-2):
 - ≥ 5 / hour resp events
 - Apnea, Hypopnea, or RERA
 - Respiratory effort
 - Symptoms
 - ≥ 15 / hour resp events
 - Respiratory effort
 - No symptoms
- Estimated 5-10% of US population
 - Higher prevalence:
 - Male gender
 - BMI >30
 - Age 40+
 - Neck circumference >17 in male, >14.5 in female
 - Comorbid Conditions:
 - HTN, smoking, ETOH, anatomic characteristics (i.e. retrognathia, tonsillar hypertrophy), family history

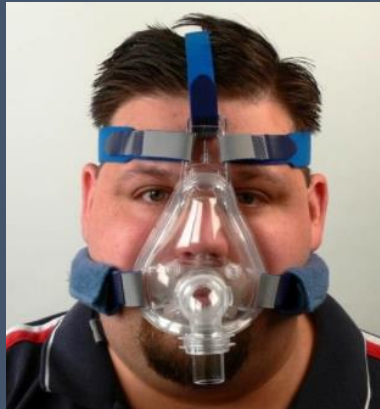Typical Patient Presentation

- Daytime fatigue
- Waking up at night
- Ultimatum from a bed partner
 - Reports of apnea
 - Snoring
- Can't deal with this:



Typical Patient Presentation

- Daytime fatigue
- Waking up at night
- Ultimatum from a bed partner
 - Reports of apnea
 - Snoring
- Can't deal with this:
- CPAP Compliance: 4 hours/night
5 nights/week
 - Est 50-70% noncompliance
 - Nasal congestion
 - Facial discomfort
 - Air leaks
 - Abdominal bloating
 - Claustrophobia
 - Social
- Many are never referred to us...



Patient Workup

- In-office exam of anatomical sites of obstruction
- Polysomnography (if not already performed)
 - CPAP Trial
- Drug Induced Sleep Endoscopy (DISE)

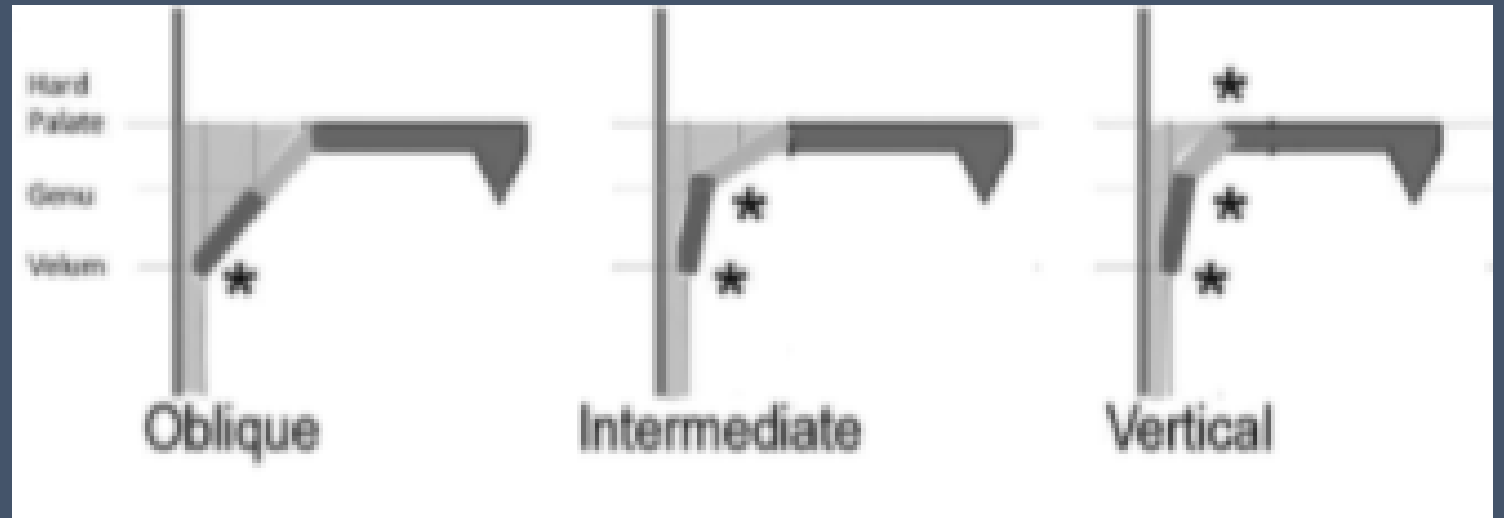
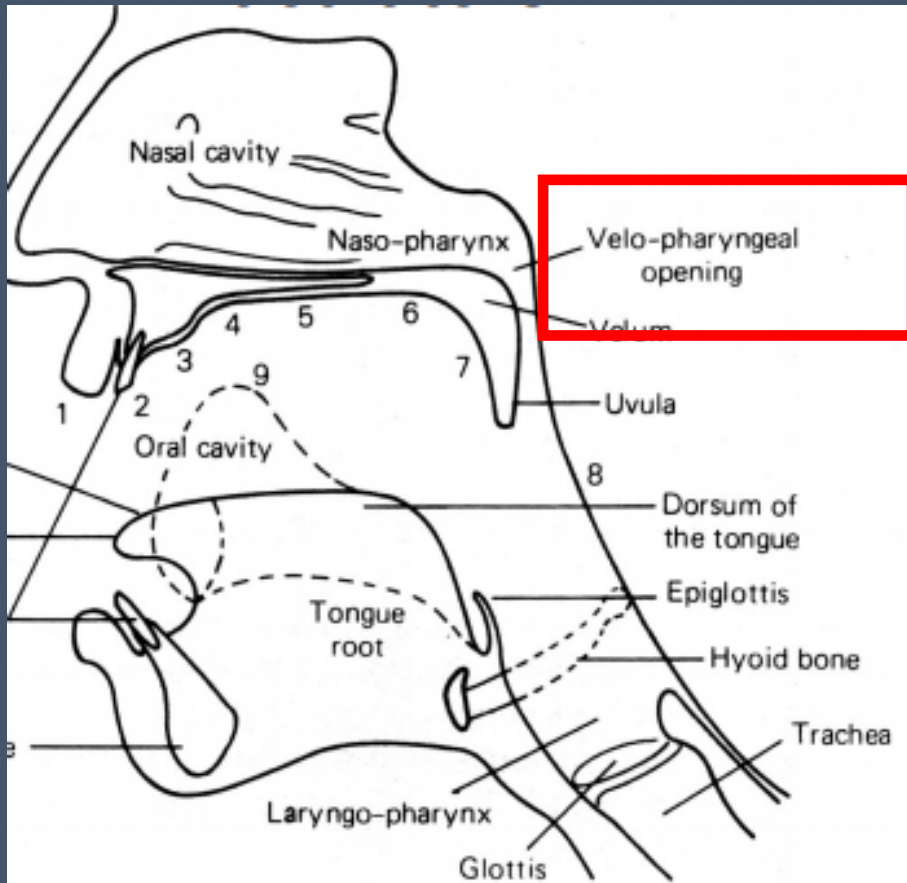
Anatomical Sites of Obstruction

- Nasal
- Velum
- Oropharynx
- Tonsils
- Tongue Base
- Epiglottis

Anatomical Sites of Obstruction

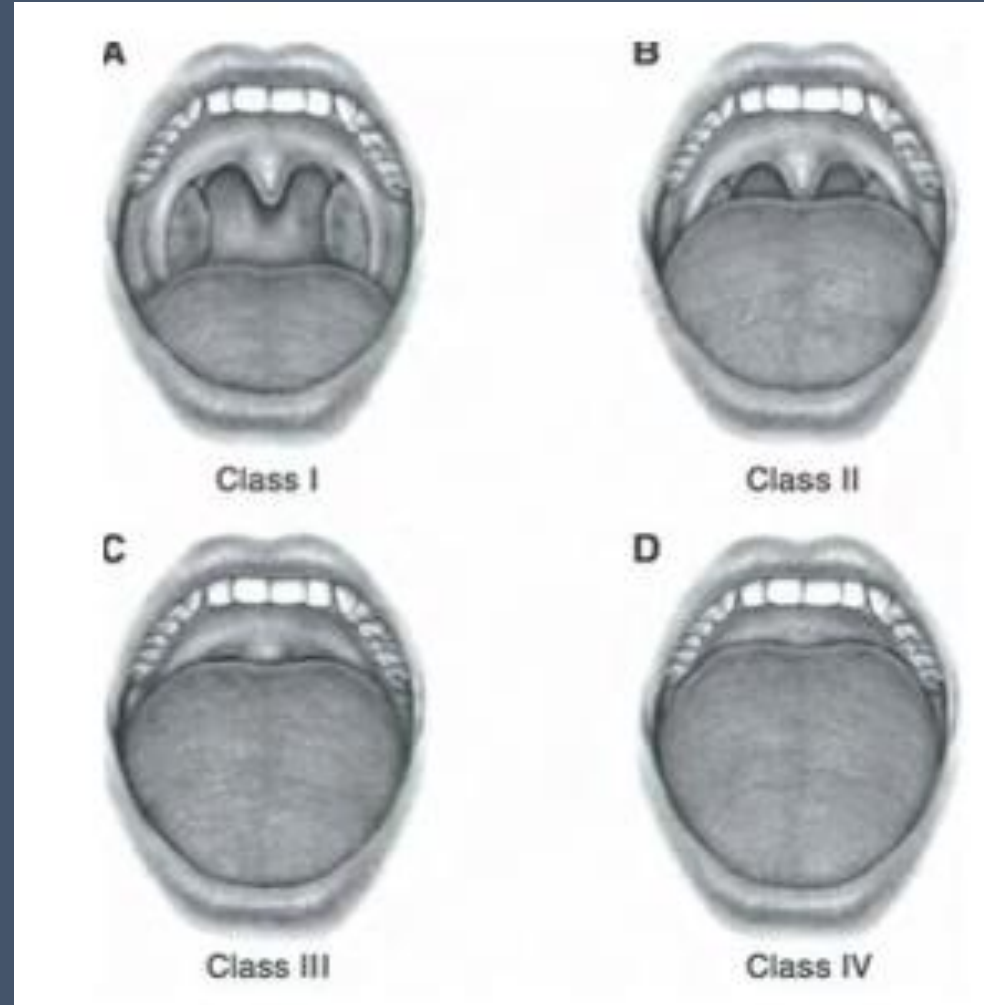
- Nasal
- Velum
- Oropharynx
- Tonsils
- Tongue Base
- Epiglottis

Anatomical Sites of Obstruction: Velum



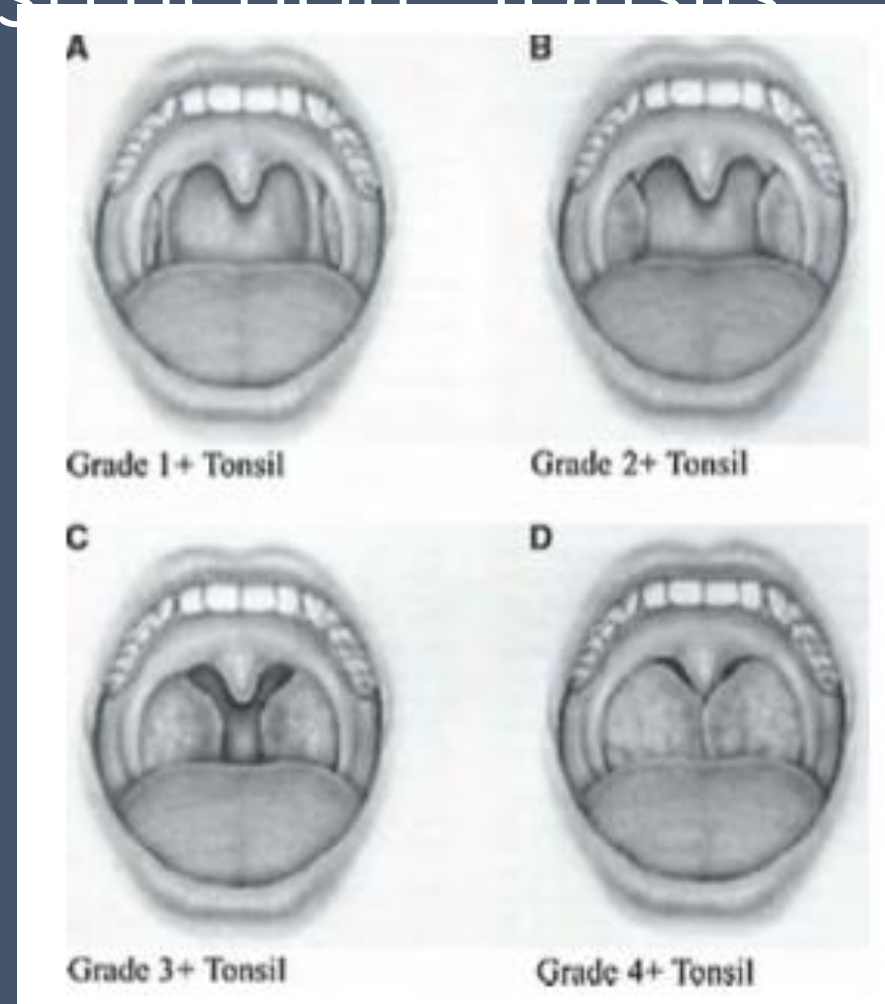
Anatomical Sites of Obstruction: Oropharynx

Friedman classification:
tongue in neutral
position





Anatomical Sites of Obstruction: Tonsils

- Classification of Tonsil Size



Modified Friedman staging system

	Friedman Palate Position	Tonsil Size	BMI
Stage I	1	3, 4	<40
	2	3, 4	<40
Stage II	1, 2	1, 2	<40
	3, 4	3, 4	<40
Stage III	3	0, 1, 2	<40
	4	0, 1, 2	<40
Stage IV	1, 2, 3, 4	0, 1, 2, 3, 4	>40

All patients with significant craniofacial or other anatomic deformities.

BMI = Body Mass Index.

Drug Induced Sleep Endoscopy (DISE)

- Assist surgeon to develop **anatomically focused** plan of care
- Anatomical location, severity, pattern of collapse
- Mimics sleep state with real time pulse oximetry
- **Not perfect, but it's the best we have**

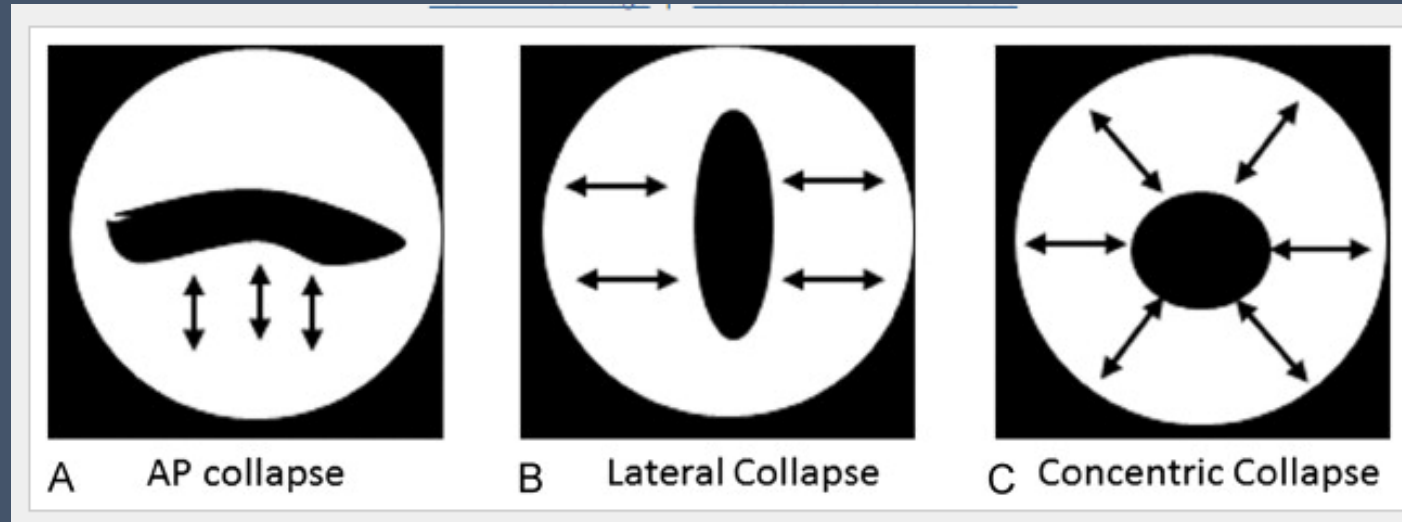
Drug Induced Sleep Endoscopy (DISE)

- Assist surgeon to develop **anatomically focused** plan of care
- Anatomical location, severity, pattern of collapse
- Mimics sleep state with real time pulse oximetry
- **Not perfect, but it's the best we have**
- Identification of airway sites in need of surgery
- Outpatient selection for snoring treatments
- Adjunct during nasal surgery

Sedation Goals with DISE (Propofol)

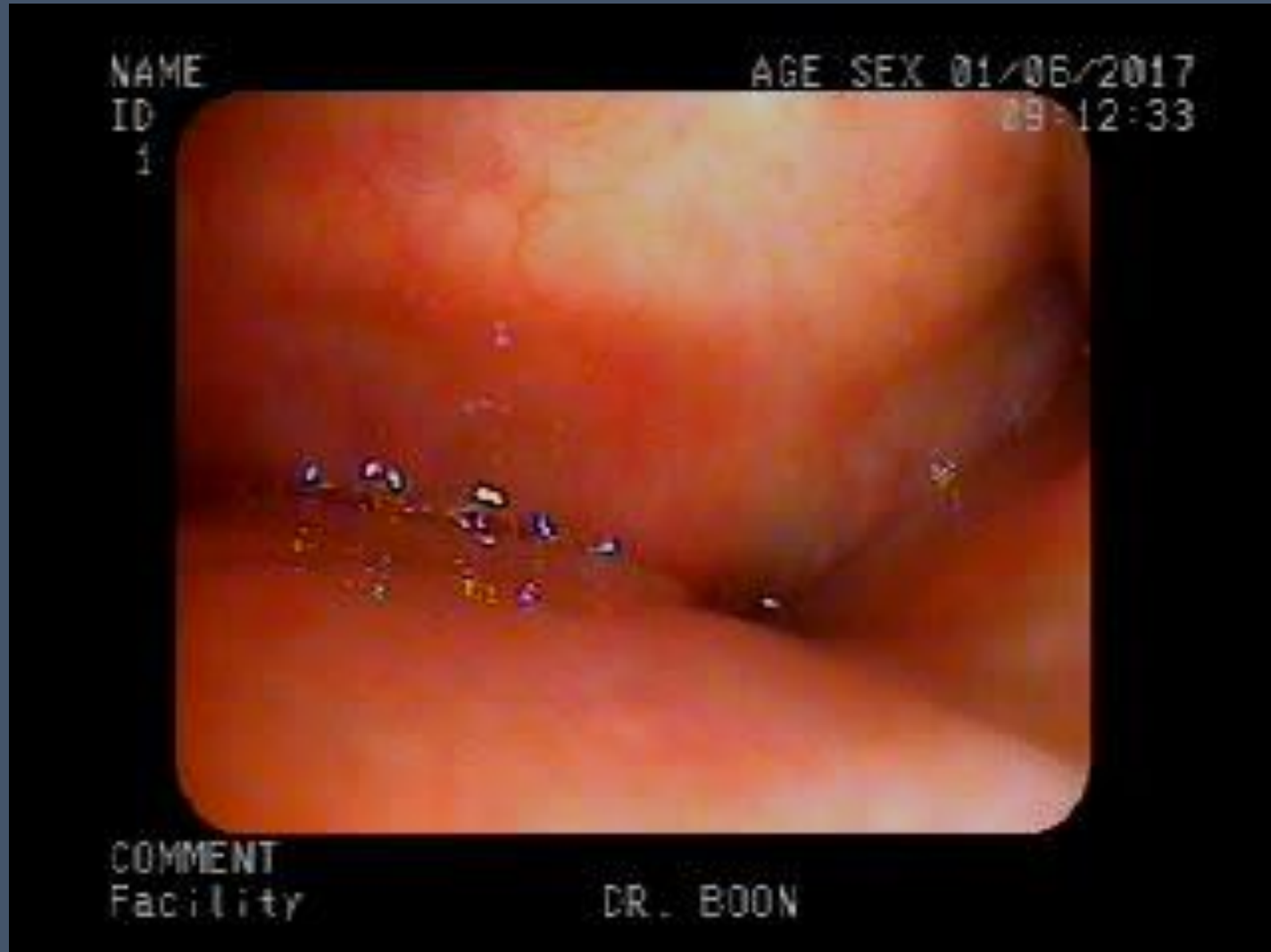- Patient asleep with steady breathing
- Nonarousable to verbal stimuli
- Arousable to sternal rub
- Snoring and apneas with mild desaturations (pulse O₂ > 85%)

Patterns of Collapse

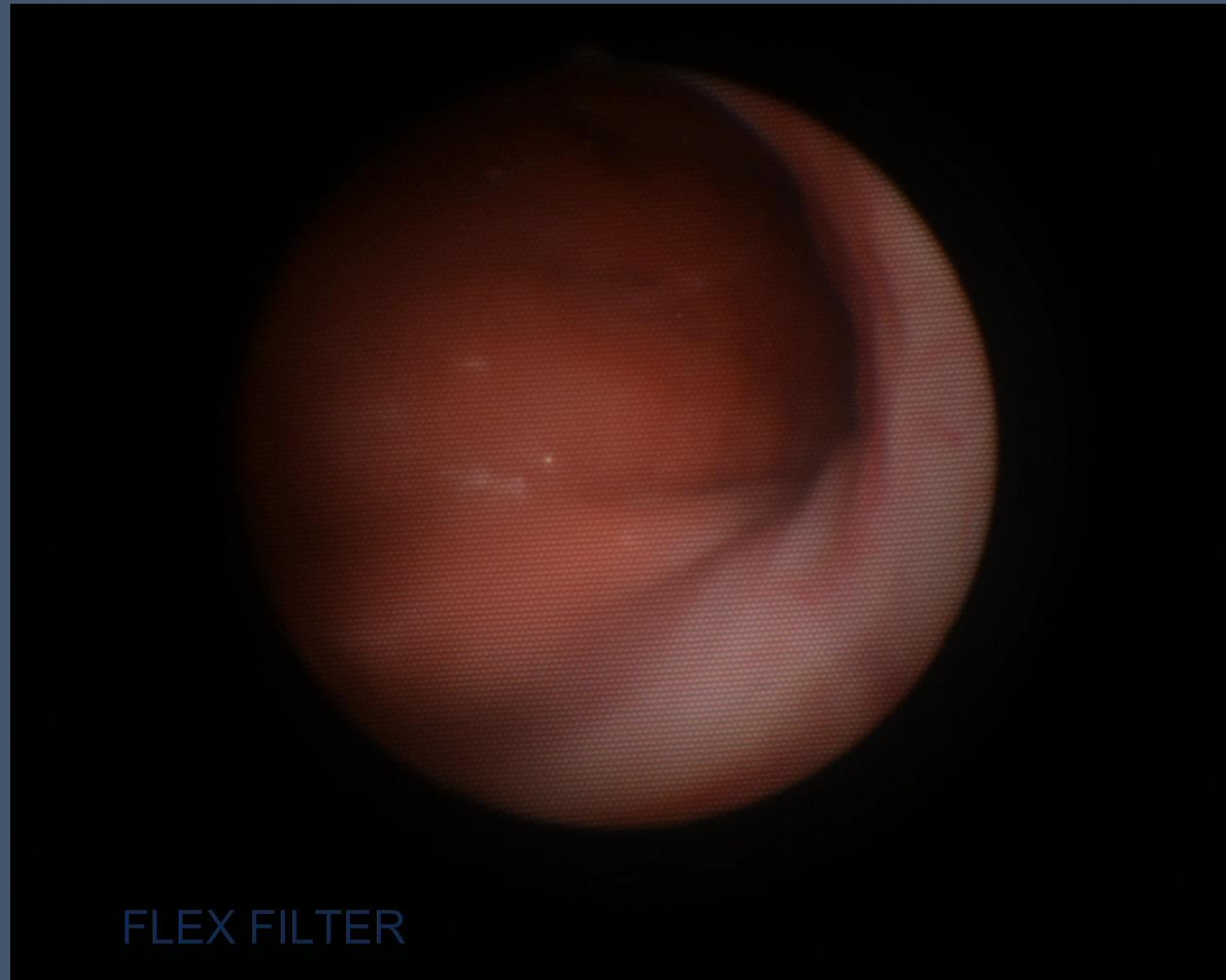


- VOTE scoring: no collapse – complete collapse (0-2)
- Indicate predominate type of collapse
- Subsites: velopharynx, oropharynx, tongue base, epiglottis

AP Collapse of Velopharynx



Concentric Collapse of Velopharynx Lateral Collapse of Oropharynx



DISE Finding	OSA Severity	Possible CPAP Alternatives
Palatal Flutter or Vibration	UARS, mild, moderate, severe	Palatal stiffening
Uvula prolapse	UARS, mild, moderate, severe	Partial uvulectomy
AP partial or total palatal collapse	Moderate-severe	Standard UPPP Inspire
Circumferential partial/total palatal collapse	Moderate-severe	Expansion pharyngoplasty
Tonsil Collapse Lateral oropharyngeal wall collapse	UARS, mild, moderate-severe	Tonsillectomy Expansion pharyngoplasty Oral appliance

Preoperative Drug Induced Sleep Endoscopy Improves the Surgical Approach to Treatment of Obstructive Sleep Apnea

Annals of Otolaryngology, Rhinology & Laryngology
1-5

© The Author(s) 2017

Reprints and permissions:

sagepub.com/journalsPermissions.nav

DOI: 10.1177/0003489417703408

journals.sagepub.com/home/aor



Colin Huntley, MD¹, David Chou², Karl Doghramji, MD³, and Maurits Boon, MD¹

- N = 87 patients with postoperative polysomnogram results
- Preoperative DISE (n=50): 8% multilevel surgery; 86% success* rate
- No preop DISE (n=37): 59.5% multilevel surgery; 51.4% success rate
- Success = 50% reduction from preop AHI; postop AHI < 20
- ESP: concentric collapse velum
- MMA: maxillary constriction
- Inspire: AP velum collapse
- TORS BOT: lingual tons hypertrophy or epiglottic collapse

Office-Based Procedures to Address Snoring

Does Snoring Intensity Correlate with the Severity of Obstructive Sleep Apnea?

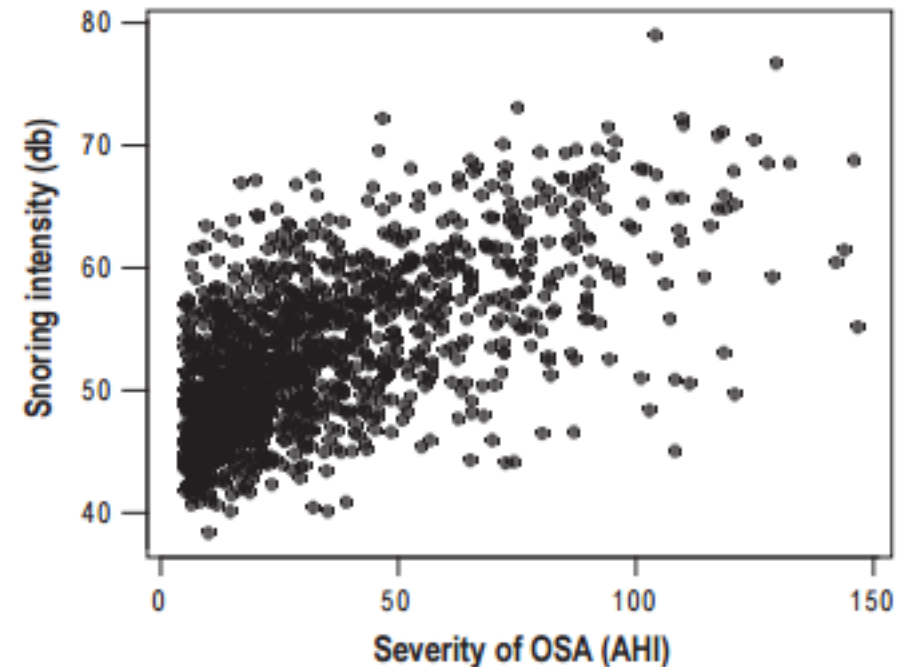
Nimrod Maimon, M.D.¹; Patrick J. Hanly, M.D.²

¹Department of Medicine, Respiriology Unit, Soroka University Medical Center, Ben-Gurion University, Beer-sheva, Israel;

²Department of Medicine, University of Calgary, Alberta, Canada

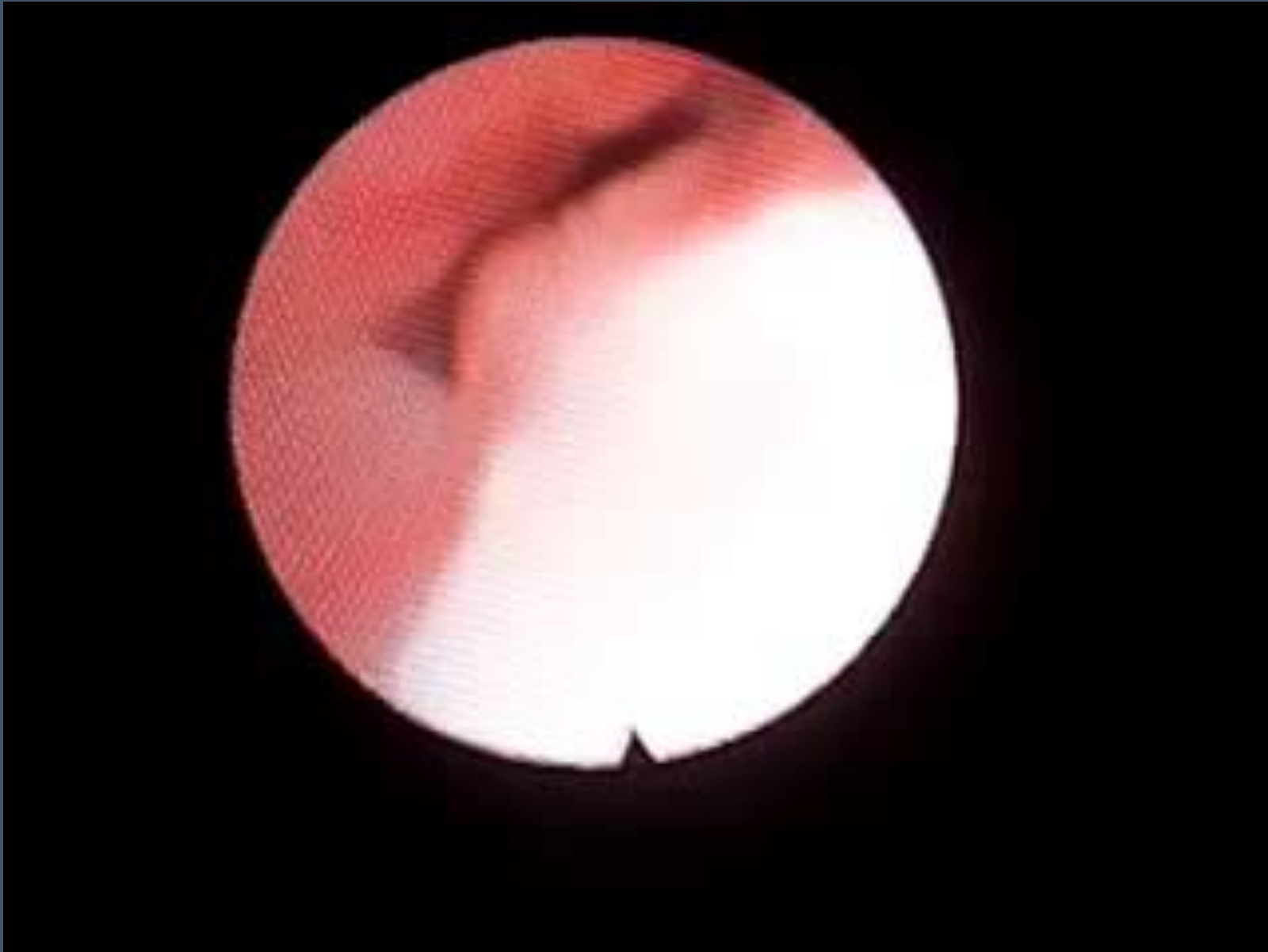- N = 1643, habitual snorers referred for polysomnography
 - 65% male, mean age 48, mean BMI 30.9
- Snoring intensity (db) increased progressively as AHI increased ($r = -0.66$, $p < 0.01$)

Figure 1—Correlation between severity of OSA and snoring intensity

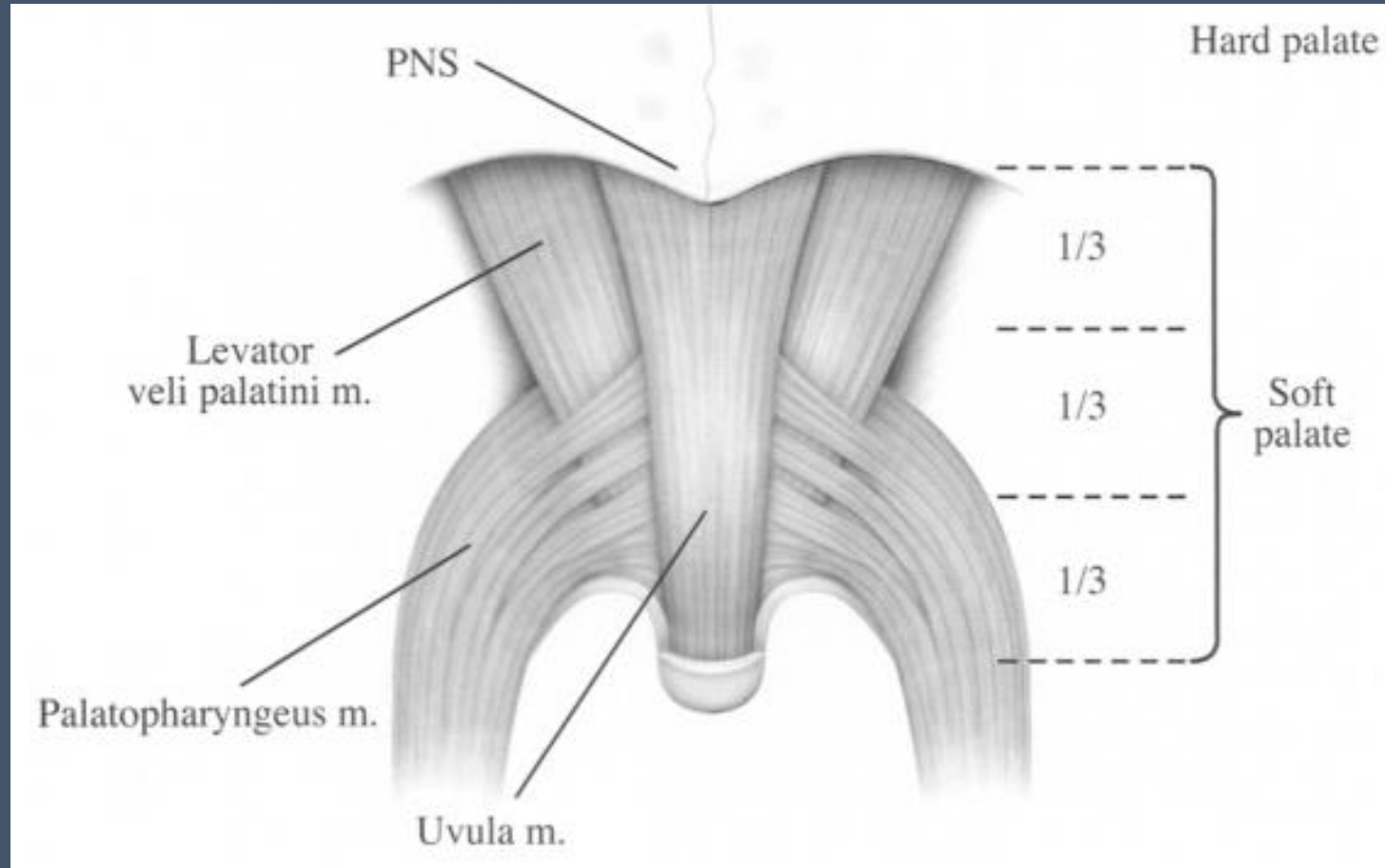


Primary Snoring

- Absence of apneas / hypopneas
- Palatal: 80-85%
- Vibration of soft tissues
- Theme of intervention: stiffen the palate

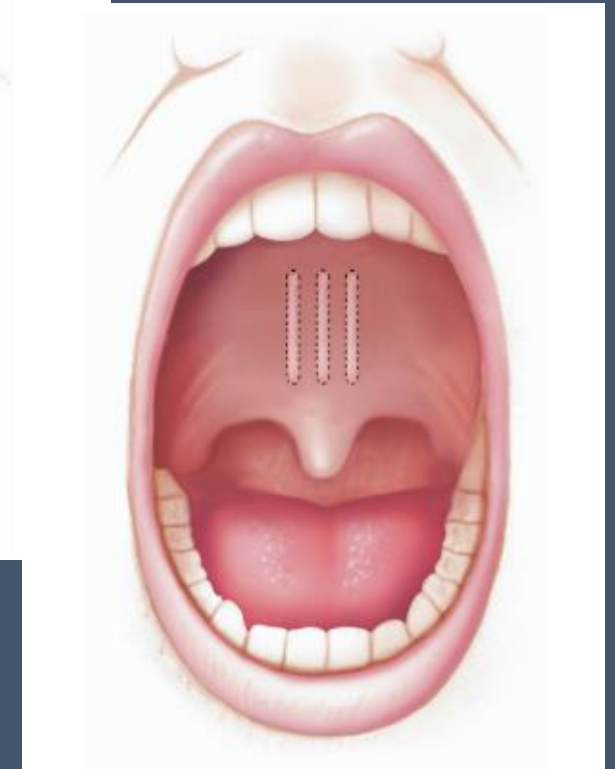
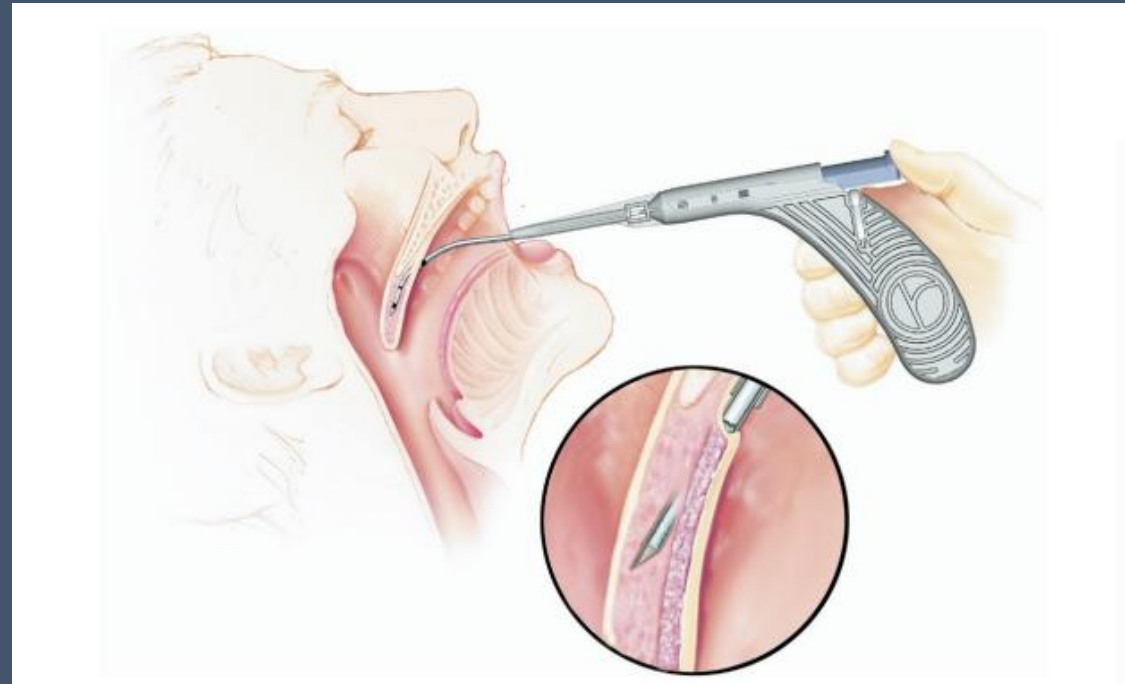


Muscular Anatomy of the Soft Palate



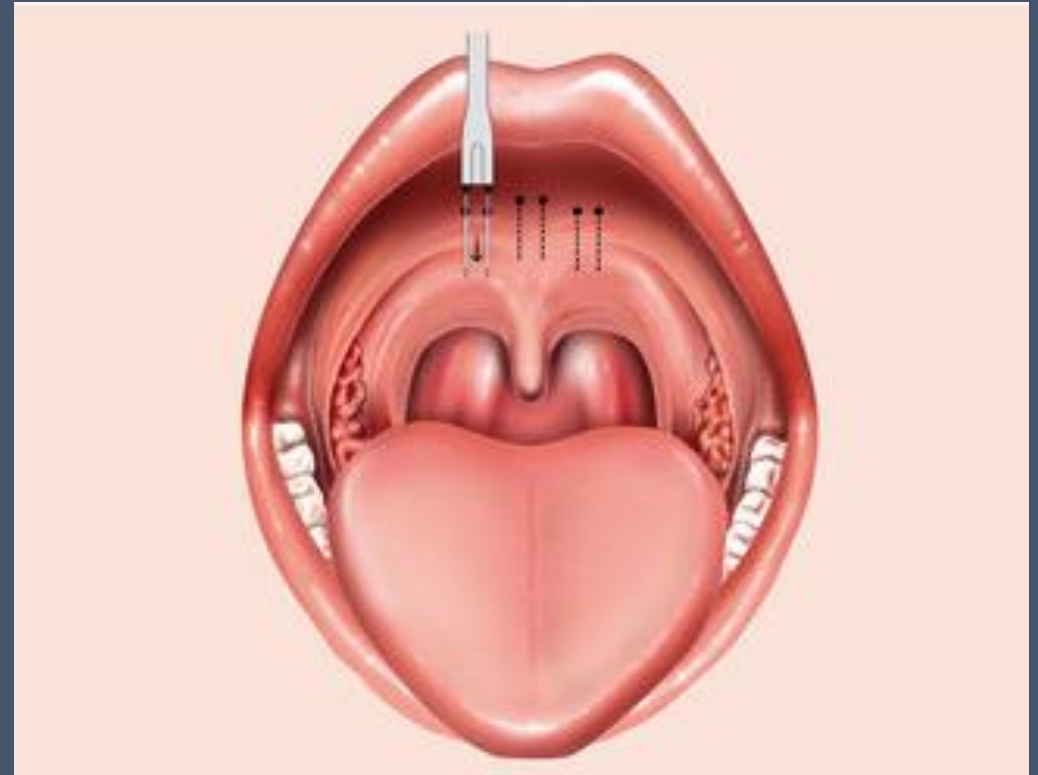Pillar Soft Palate Implant

- **Primary snoring, mild OSA**
- Braided polymer implants
- 18mm x 1.5mm
- Positioned near hard/soft palate junction
- One central, two paramedian



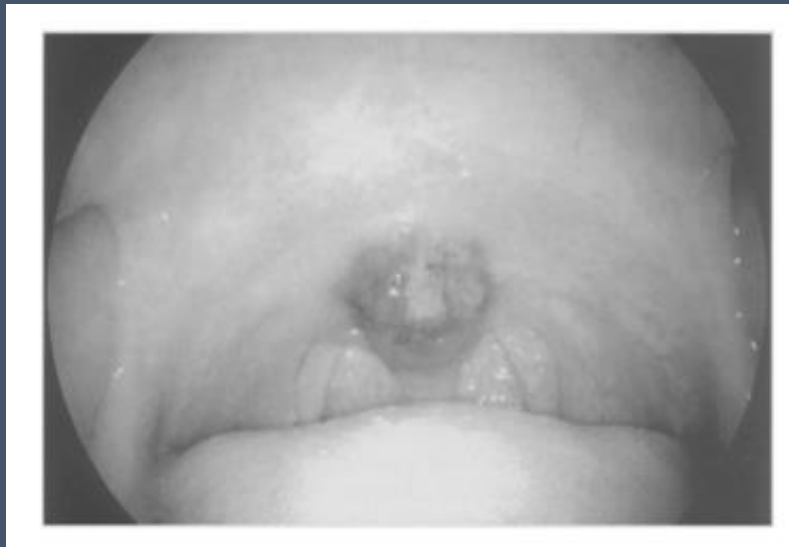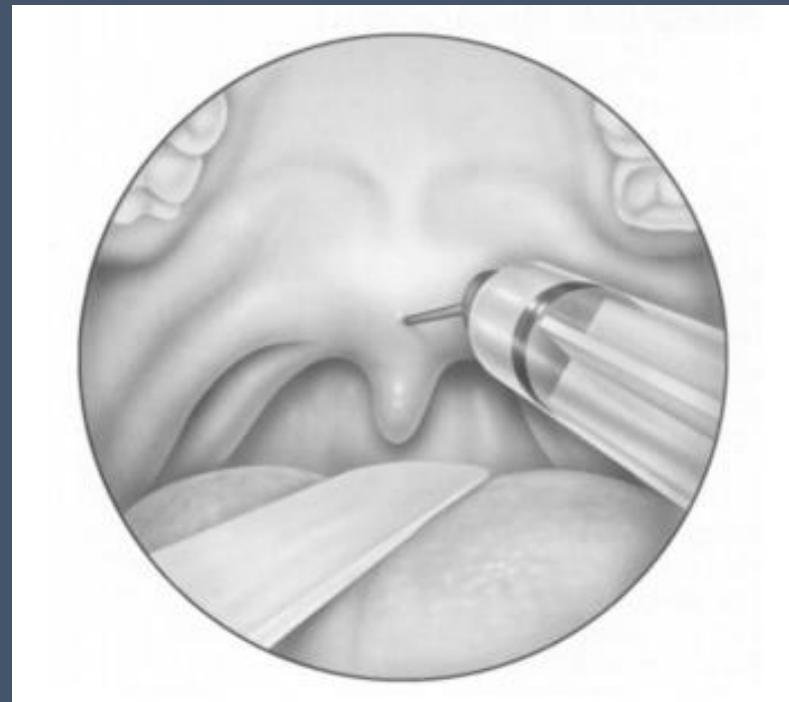Radiofrequency Tissue Ablation and Coblation

- **Primary snoring**
- RF energy delivered to palate with 22-gauge needle electrode
- Needle inserted into **muscle** of soft palate, entry point near junction of hard palate
- Coblation
- One central, two paramedian



Injection Snoreplasty

- **Primary snoring**
- Soft palate sclerotherapy
- 3% sodium tetradecyl sulfate, now ethanol used as well
- Single midline **submucosal** plane
27g needle, middle soft palate
- Expected mucosal sloughing, scarring to develop over 4-6 weeks
- Reinjection: paramedian

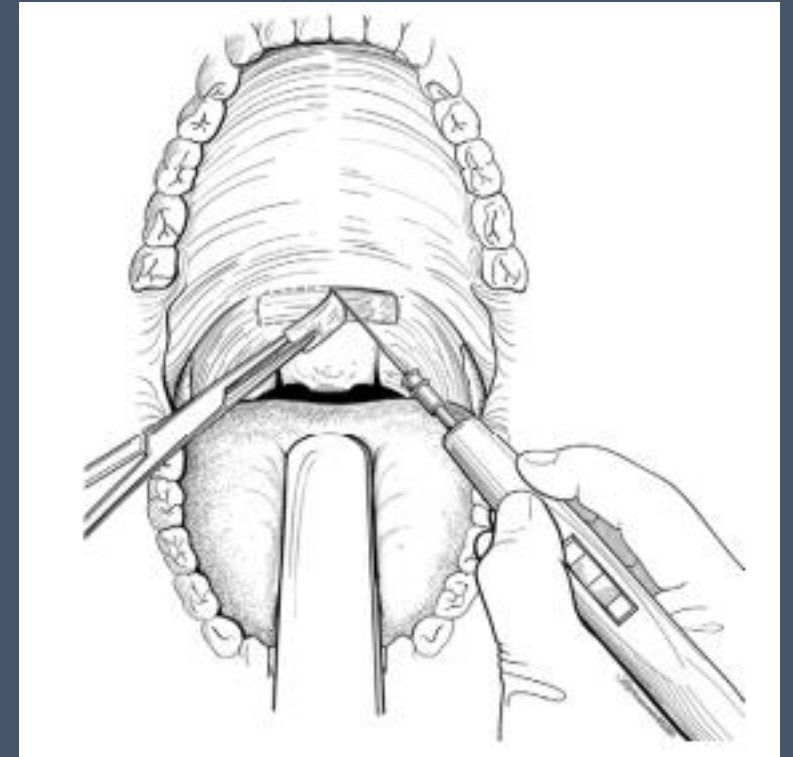
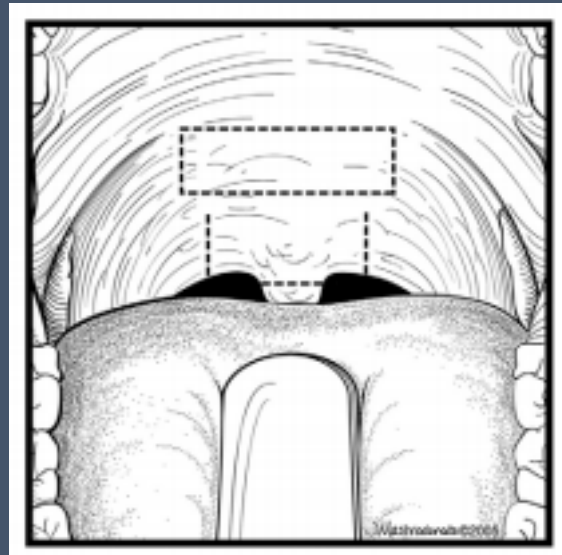


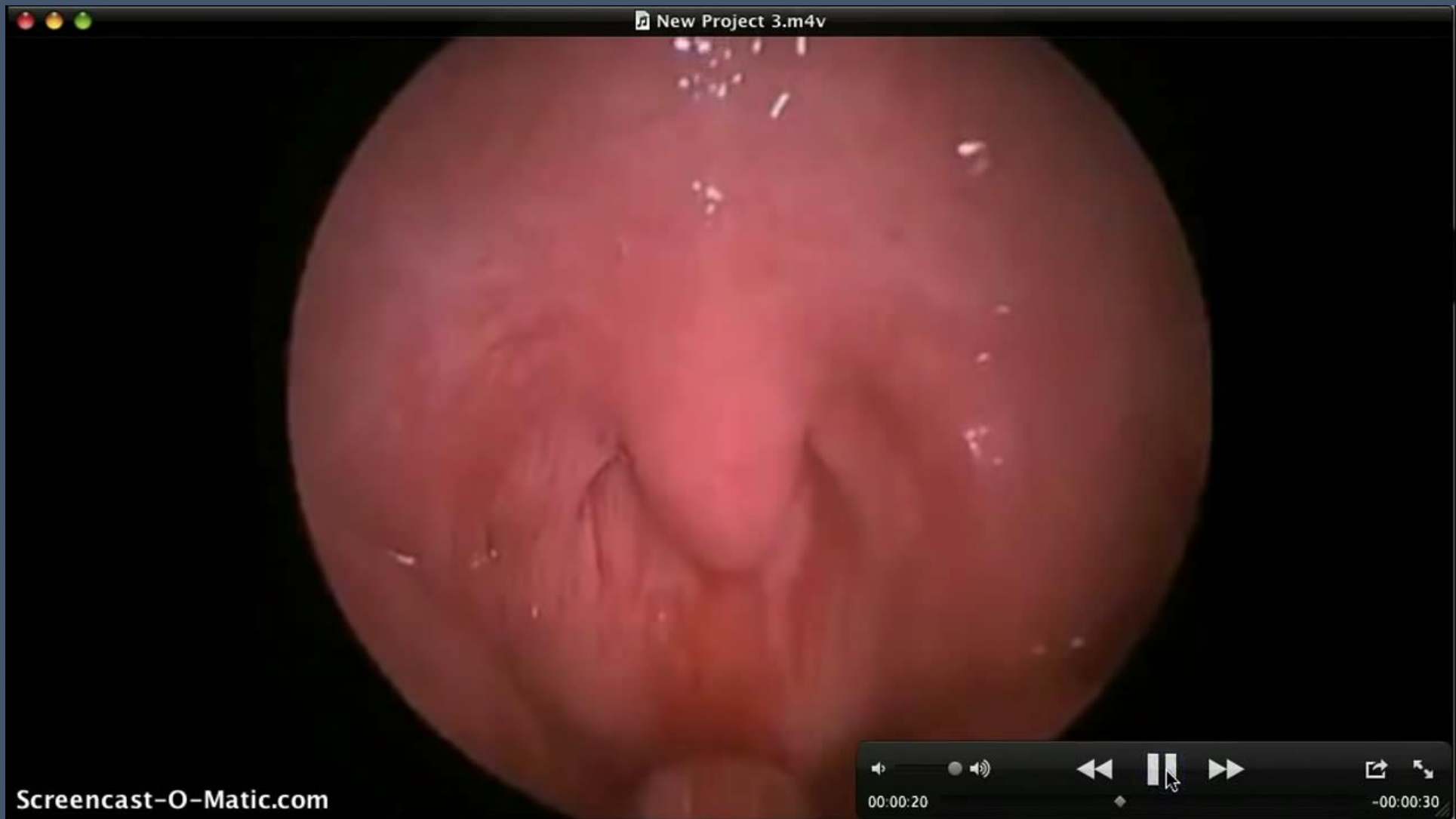Office-Based Procedures

- Local anesthesia
- Less pain
- Reported efficacy of approximately 80%
- Good candidates: **obliquely oriented palate; long transverse distance between posterior pillars**
- Standalone, or adjuncts
- Cost – Primary Snoring
 - \$300 Injection Snoreplasty
 - \$1500-\$2200 for Pillar implant
- RF: mucosal ulceration
- Injections: mult treatments possible
- Pillar: risk extrusion (3-30%)
- Minimal if any effect on AHI
- Minimal if any aid with CPAP tolerance

Anterior Palatoplasty (Modified Caotery-Assisted Palatal Stiffening)

- **AP collapse, Snoring or Mild OSA**
- Local anesthesia in the office, or under GA
- Mucosa only, expose underlying muscle
- Widen airway, direct scar formation



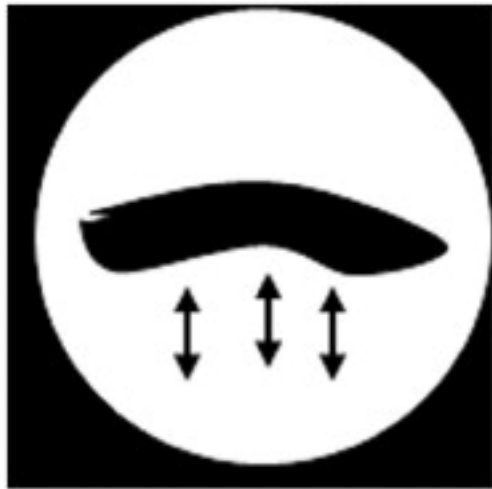


Anterior palatoplasty for the treatment of OSA: Three-year results

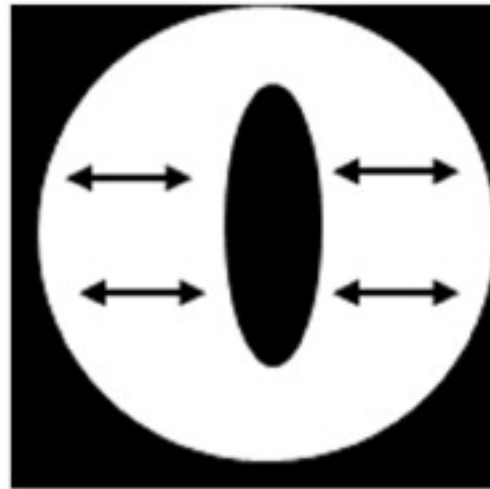
**Kenny P. Pang, FRCSEd, FRCSI(OTO), MBBS,
Raymond Tan, FRCS(Glas), MBBS, Puravi Puraviappan, MS(ORL), and
David J. Terris, MD, Paragon, Singapore; Kuala Lumpur, Malaysia; and Augusta, GA**

- N = 77; BMI < 33, Friedman II, AHI 1-30, tonsil grade 1-2
 - 38 snorers, 39 OSA
 - +/- tonsillectomy
 - <25% BOT collapse via Muller maneuver
- Mean f/u: 33.5 mo
- **AHI mean 25 -> 9.9**
- **Snore Visual Analog Scale 8.4 → 2.5**

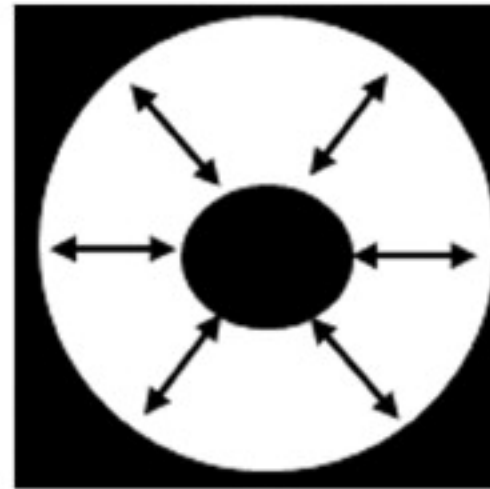
Palatal Surgery for OSA



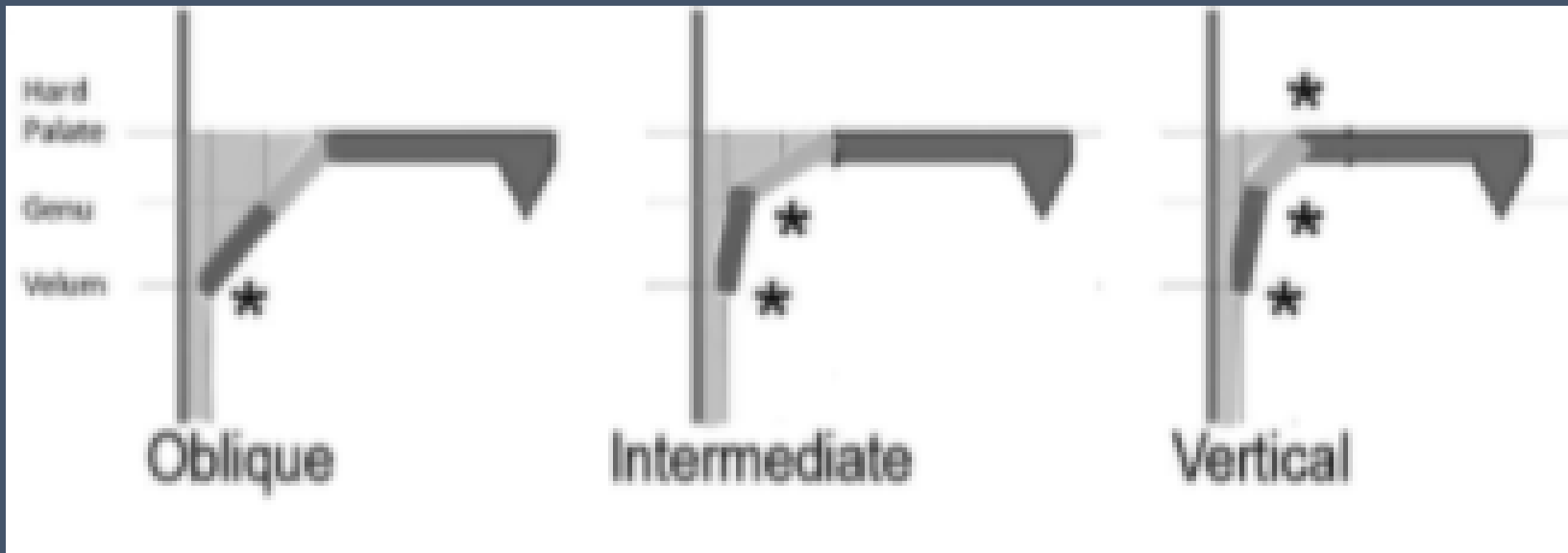
A AP collapse



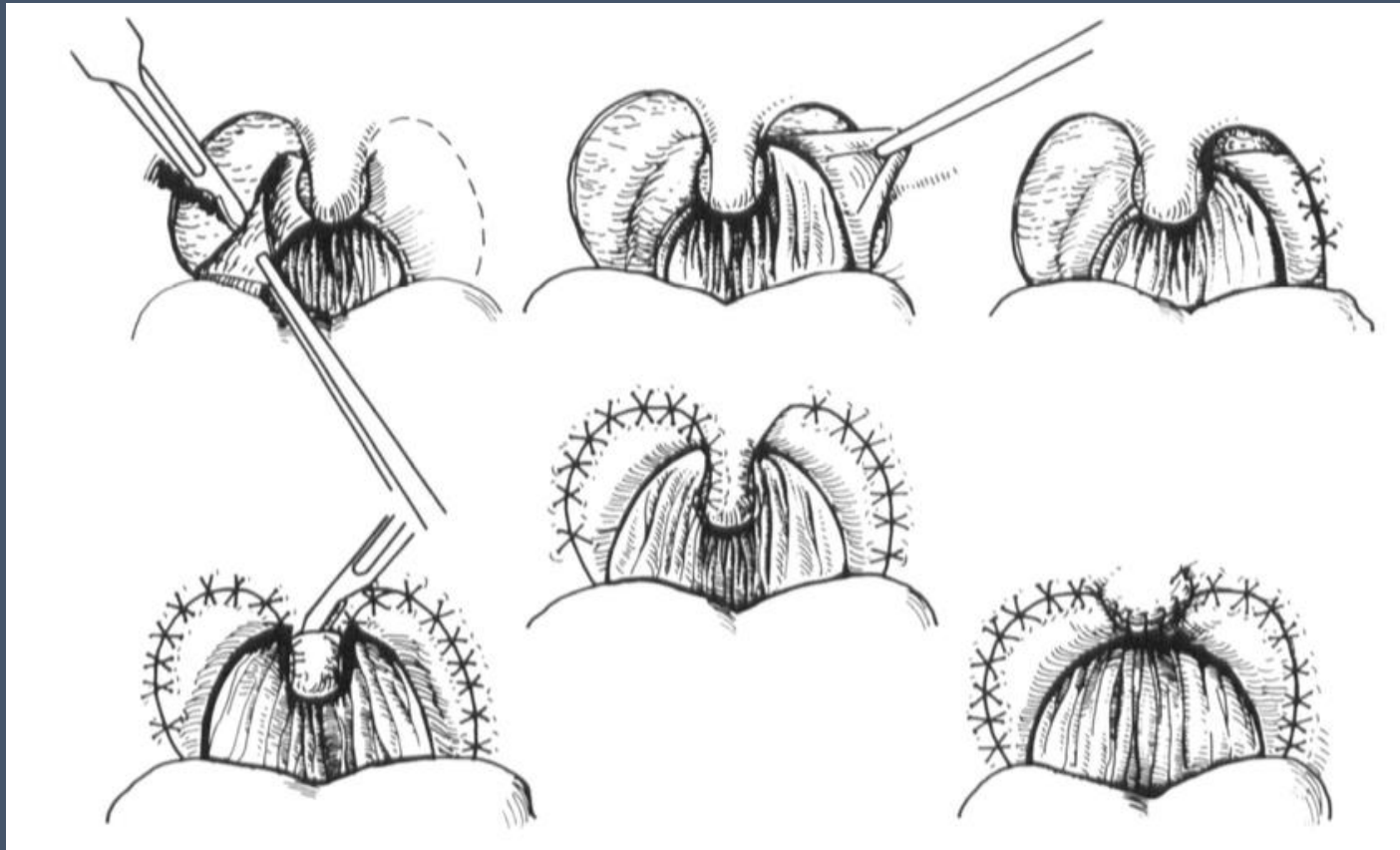
B Lateral Collapse



C Concentric Collapse

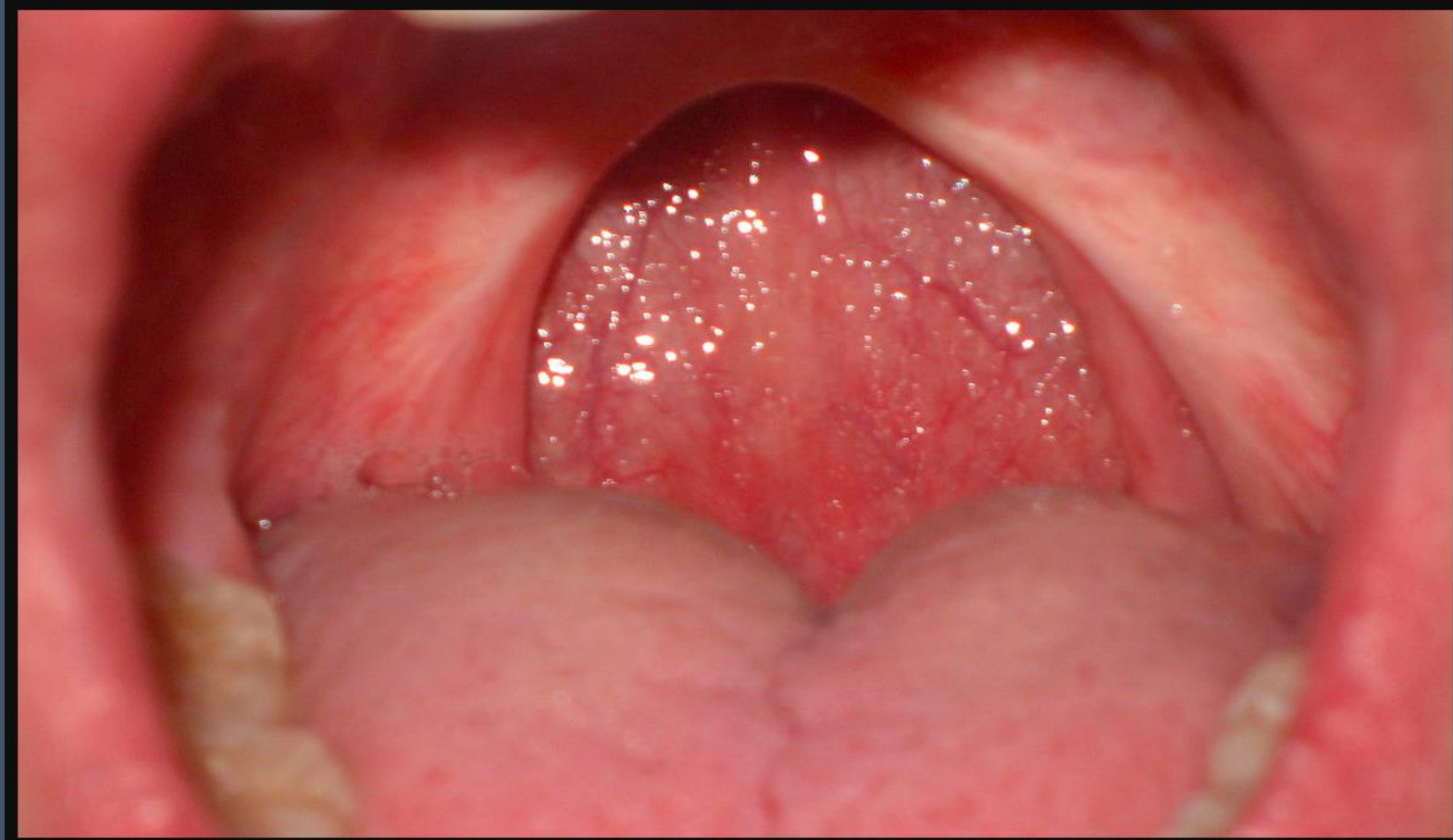


Uvulopalatopharyngoplasty (UPPP)

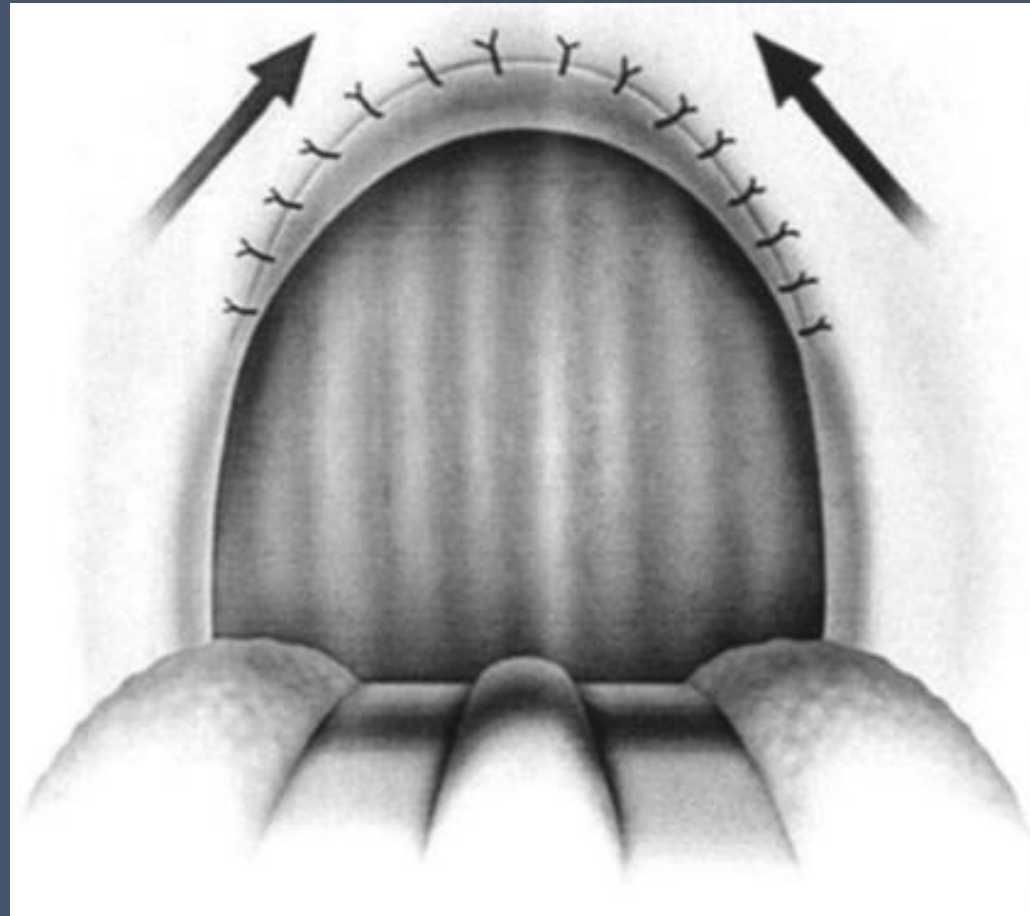


- **Obliquely oriented palate with primary AP collapse**
- Rims of anterior and posterior pillar mucosa trimmed, approximated
- Redundant posterior pharyngeal wall mucosa resected

Uvulopalatopharyngoplasty (UPPP)

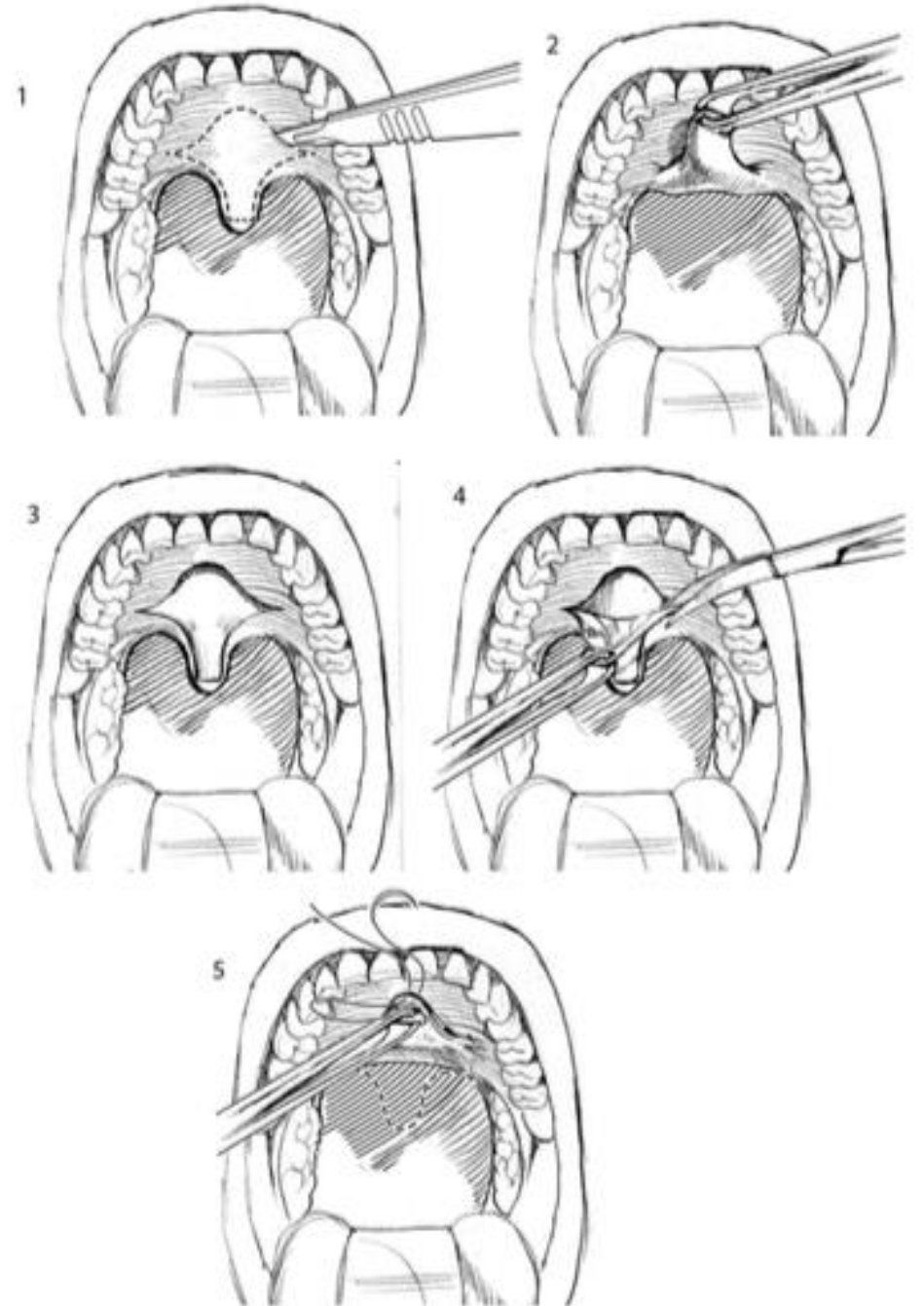


Uvulopalatopharyngoplasty (UPPP)



Uvulopalatal Flap

- **Obliquely oriented palate with primary AP collapse**
- Diamond-shaped incision through mucosal layer only.
- Mucosa/glandular tissue removed
- Tip of uvula approximated to hard/soft palate junction



Uvulopalatal Flap for Obstructive Sleep Apnea: Short-Term and Long-Term Results

Chairat Neruntarat, MD

- Prospective study, n = 83 pts evaluated 6mo and 48+ mo postoperatively
- 6 mo: 69.9% success
- 48+ months: 51.8% success
- BMI > 30, AHI > 45 independently associated with failure

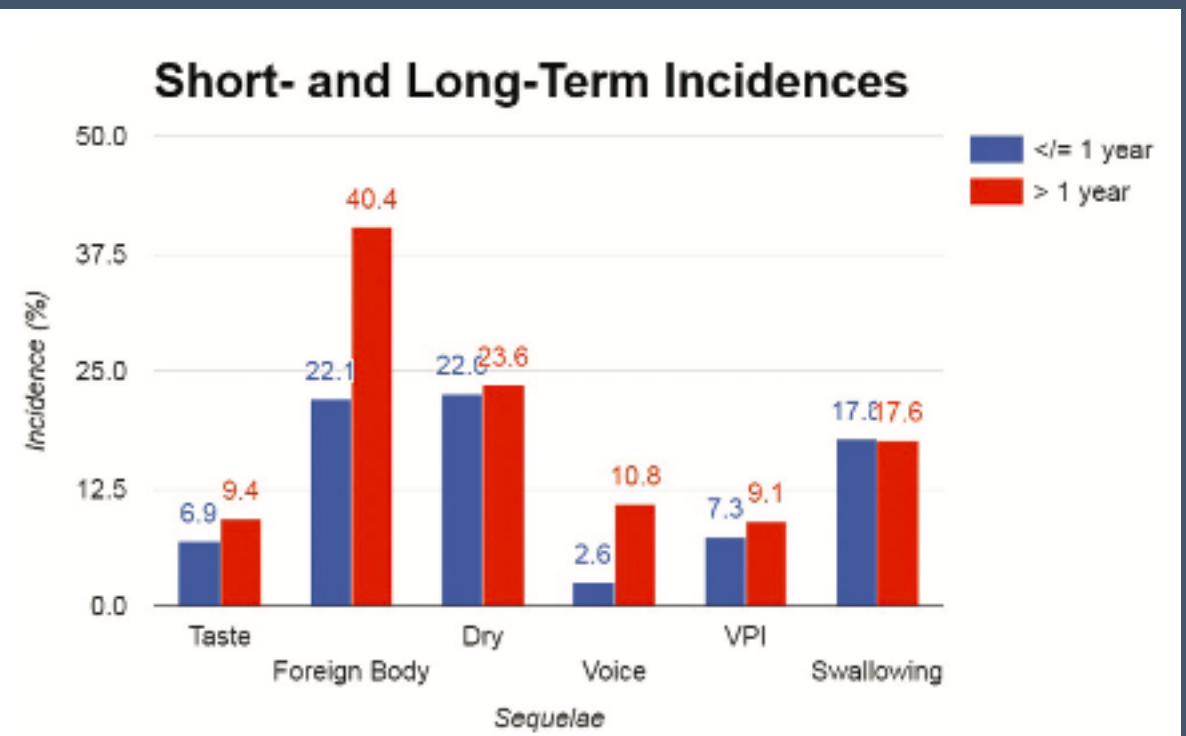
- *Success: >50% AHI reduction, final AHI <20

Long-Term Incidence of Velopharyngeal Insufficiency and Other Sequelae following Uvulopalatopharyngoplasty

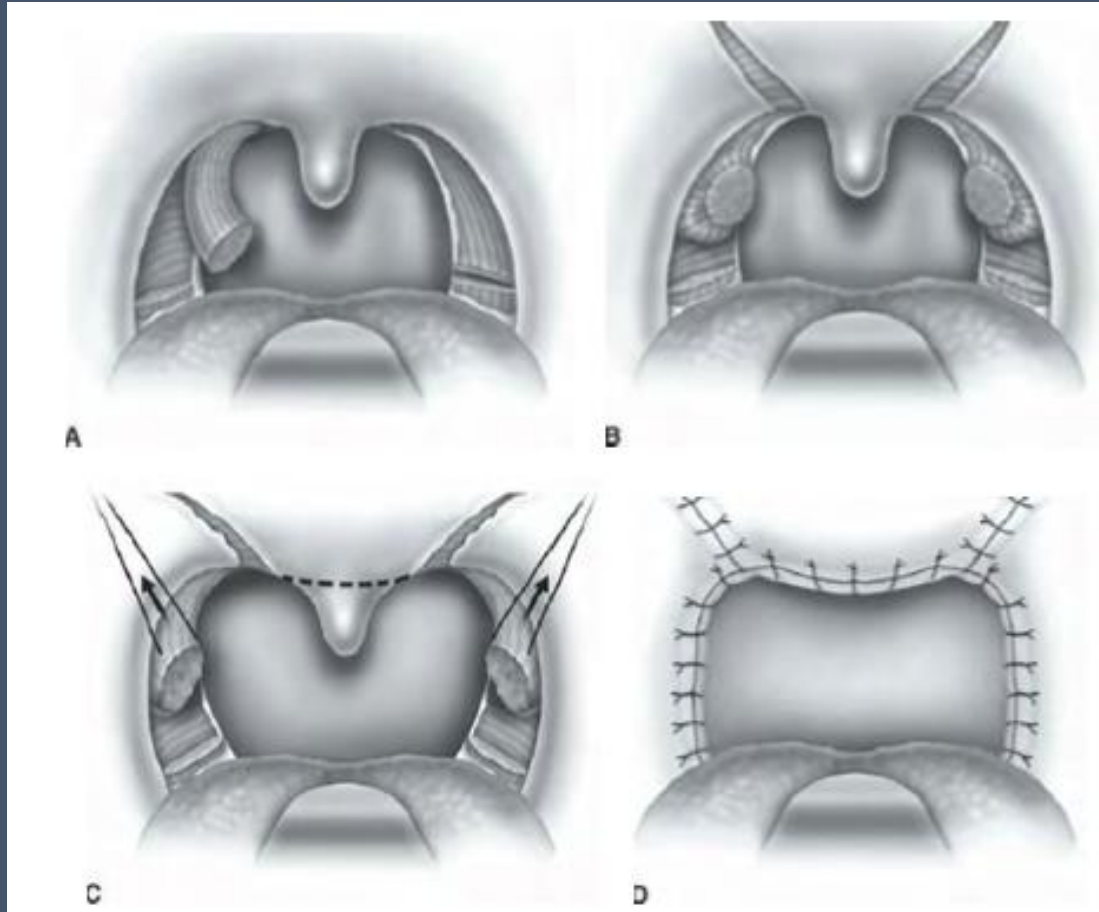
Jessica A. Tang, MD¹, Anna M. Salapatas, MS¹,
Lauren B. Bonzelaar, MD¹, and Michael Friedman, MD^{1,2}

Otolaryngology—
Head and Neck Surgery
2017, Vol. 156(4) 606–610
© American Academy of
Otolaryngology—Head and Neck
Surgery Foundation 2017
Reprints and permission:
sagepub.com/journalsPermissions.nav
DOI: 10.1177/0194599816688646
http://otojournal.org
SAGE

- Meta-analysis of 24 studies of patients having underwent UPPP or mUPPP
- Observed complications;
 - VPI (24 studies, n = 191)
 - Dysphagia (7 studies, n = 83)
 - Taste dist (4 studies, n = 10)
 - Voice changes (7 studies, n = 46)
 - Foreign body (9 studies, n = 427)
 - Dry pharynx (7 studies, n = 150)



Expansion Sphincter Pharyngoplasty



- **Concentric, Lateral collapse**
- Palatopharyngeus muscle transected at inferior end
- Fascia attachment preserved to underlying horizontal constrictors
- Tunnel palatopharyngeus m. **antero-supero-laterally**
- Incision anterior surface of soft palate (last upper molar)

REVIEW ARTICLE

Expansion sphincter pharyngoplasty for the treatment of OSA: a systemic review and meta-analysis

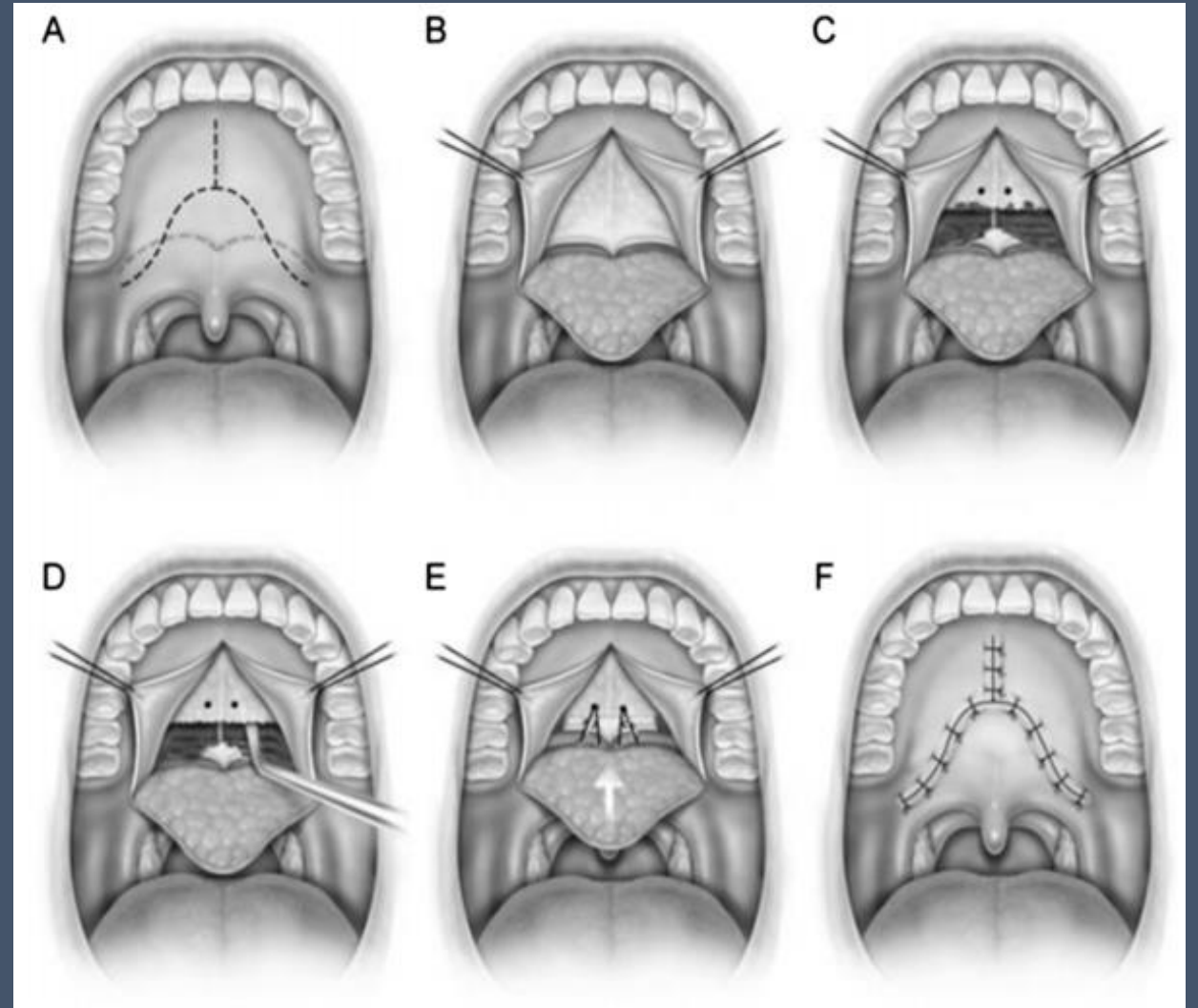
Kenny P. Pang¹ · Edward B. Pang² · Ma Thin Mar Win³ · Kathleen A. Pang² ·
B. Tucker Woodson⁴

	<i>N</i>	Age	BMI	Intervention	Pre-op AHI	Post-op AHI	Success rate	f/u
Pang 2007	45	42.1	28.7	EP vs UPPP	44.2 ± 10.2	12 ± 6.6	82.6	6
Sorrenti 2012	85	42.7	–	EP	33.3	11.7	89.2	36
Vicini 2014	24	54.2	27.2	TORS/EP vs TORS/UPPP	38.5 ± 14.3	9.9 ± 8.6	–	9
Ulualp 2014	50	8	32	EP vs TA	60.5 ± 38.5	2.4 ± 3.9	80	6
Carrasco 2015	53	43.9	27.5	EP vs UPPP	27.7 ± 7.5	6.5 ± 5.2	90	6.9

Success rates (in all articles) defined as 50 % reduction of pre-operative AHI and an AHI <20, except Ulualp (2014), success rate defined as post-operative AHI <5

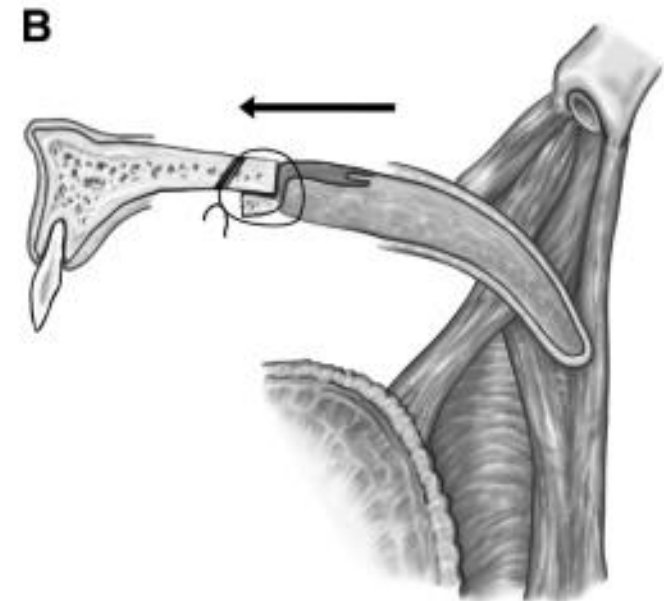
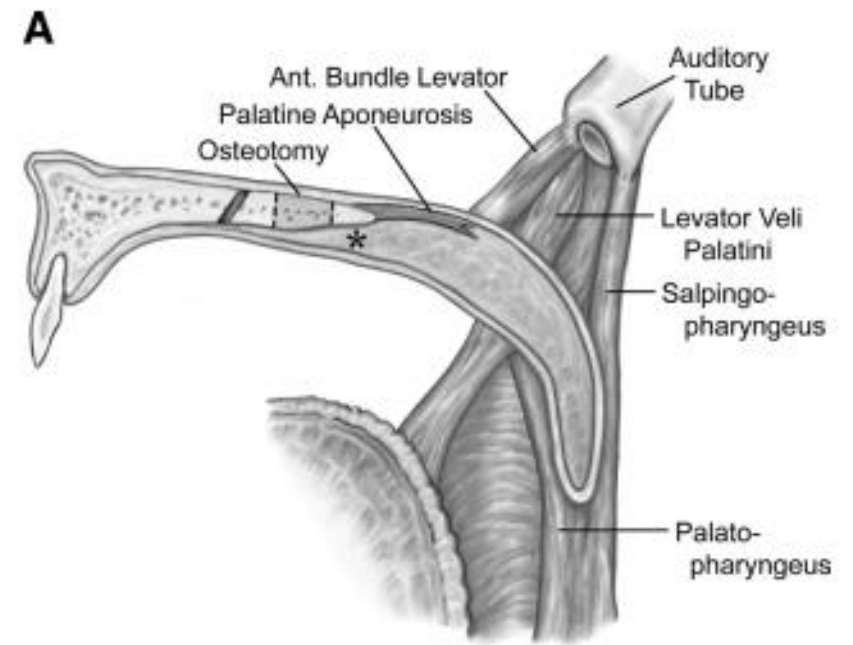
Transpalatal Advancement Pharyngoplasty

- **posteriorly-based hard-soft palate junction**
- Turns “vertically-oriented” palate into obliquely oriented palate
- Lateral flaps medial to greater palatine foramen, over hamulus
- Posterior osteotomy, with 1-2 mm rim of bone



Transpalatal Advancement Pharyngoplasty

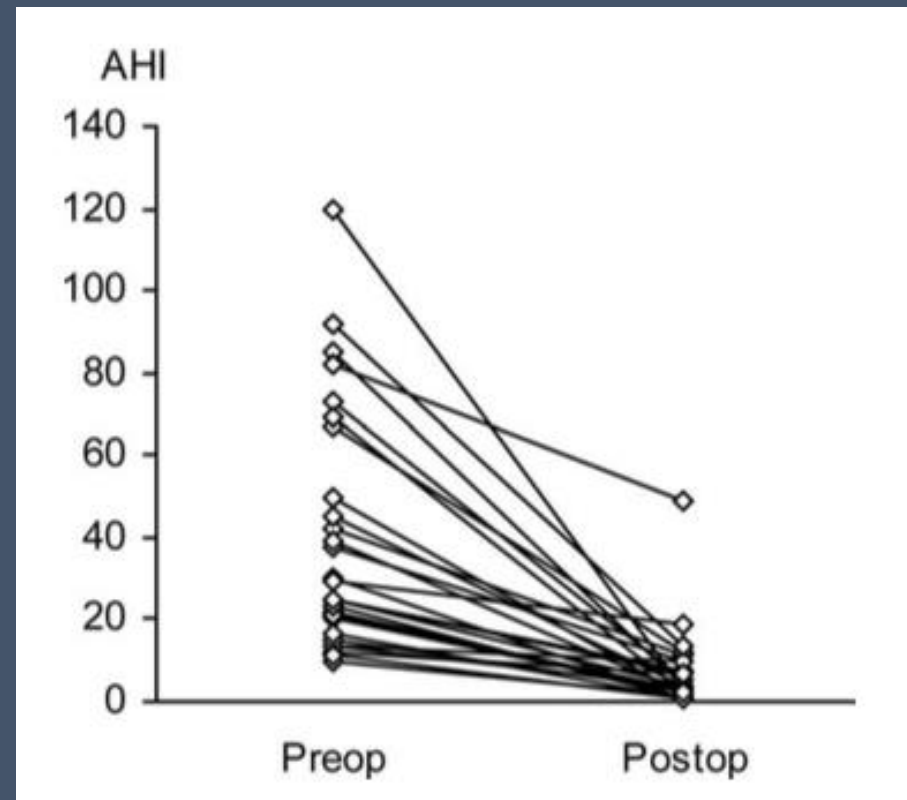
- Sutures through palate drill holes into tensor aponeurosis laterally
- Strong rim of bone supports the sutures



Tonsillectomy in Adults With Obstructive Sleep Apnea

Thorbjörn Holmlund, MD; Karl A. Franklin, MD, PhD; Eva Levring Jäghagen, DDS, PhD;
Marie Lindkvist, PhD; Torbjörn Larsson, MD; Carin Sahlin, PhD; Diana Berggren, MD, PhD

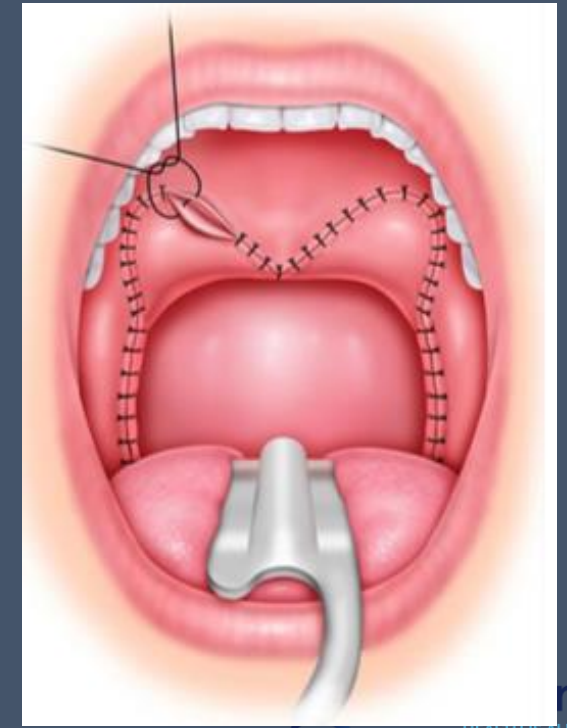
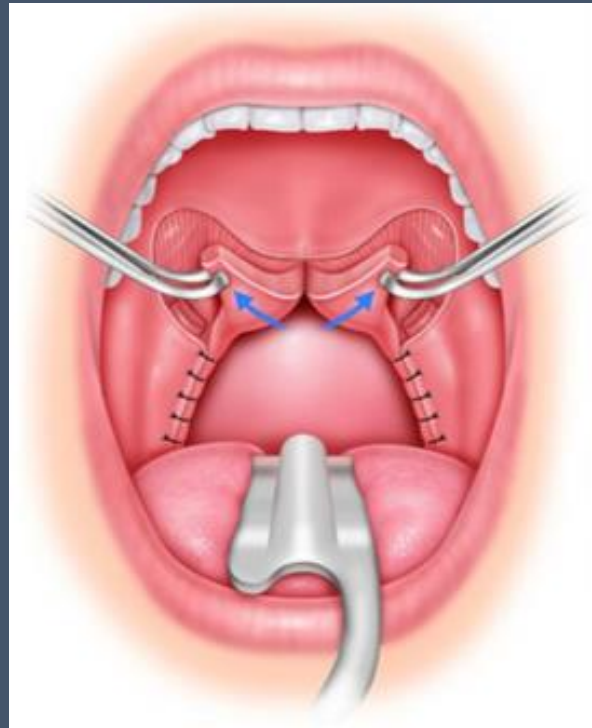
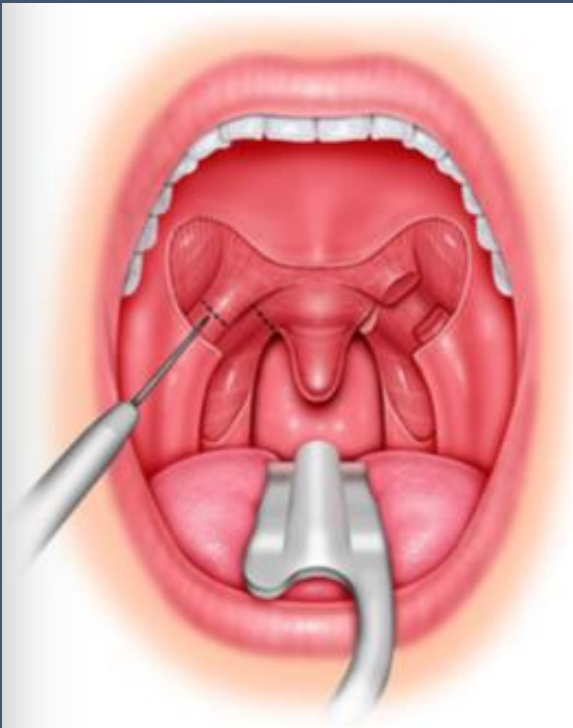
- N = 28; AHI > 10, Tonsil size 3-4
- Mean age 33; BMI 32
- f/u 6mo
- AHI mean 40 -> 7
- ESS mean 11 -> 6



Z-Palatopharyngoplasty

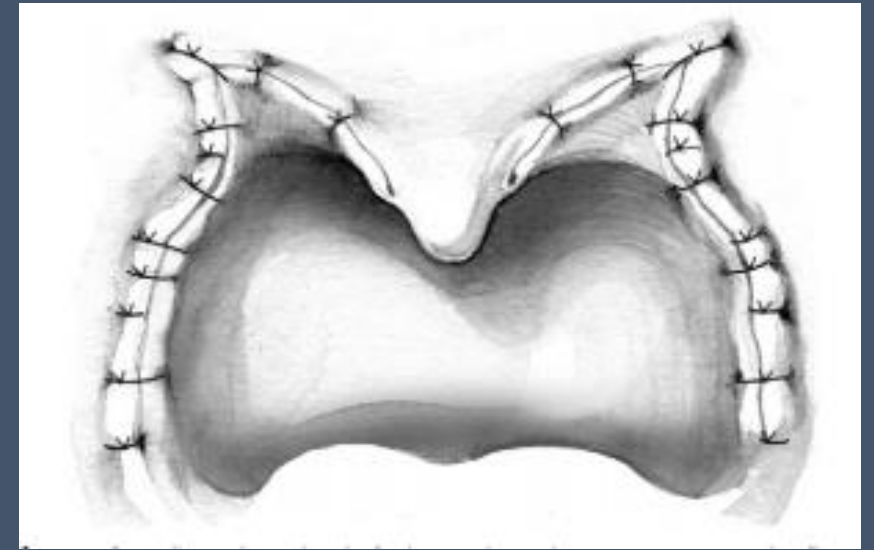
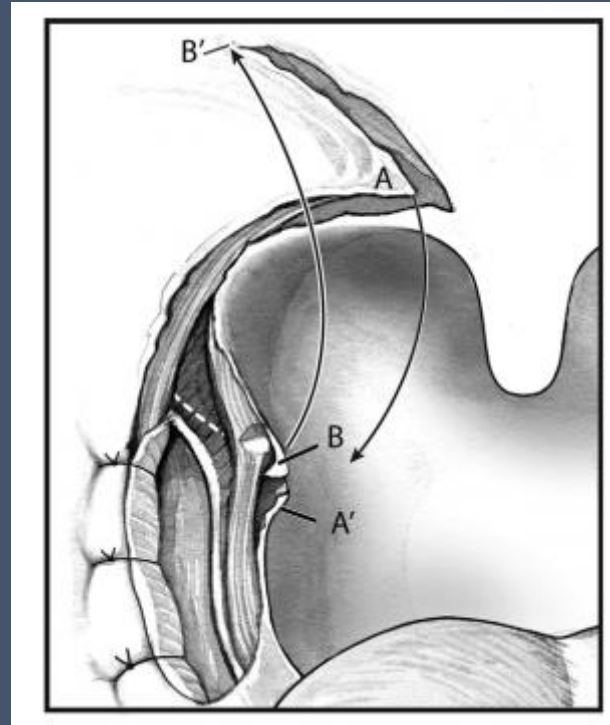
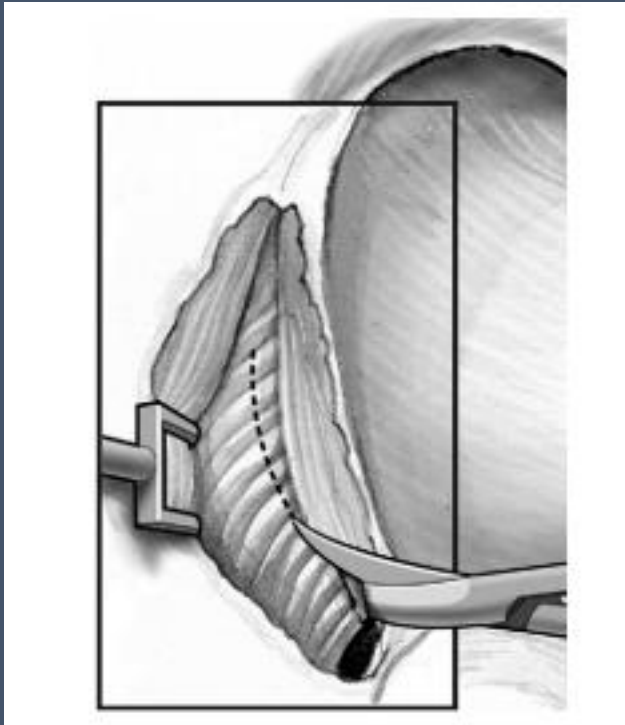
- AP collapse
- Transect palatoglossus and palatopharyngeus muscles

- Uvula and palate split in midline



Friedman 2015

Lateral Pharyngoplasty



- Lateral pharyngeal collapse
- Divide superior constrictor

- Transverse subtotal resection of palatopharyngeus
- Closure in Z-plasty fashion

Conclusions and Future Directions

- **Healthy sleep** is essential
- Many go **untreated or undertreated by CPAP**, and surgical options exist
- **Everyone's anatomy is different:** Tailored approach to patient and anatomy

Special Thanks!



Dr. Boon

Special Thanks!



Dr. Boon



Colin

Special Thanks!



Dr. Boon



Colin

The Talented and Incredibly Good-Looking PGY-3 Class

References

1. Friedman M, Hwang MS. Z-palatopharyngoplasty. *Oper Tech Otolaryngol Neck Surg*. 2015;26(2):90-94. doi:10.1016/j.otot.2015.03.008.
2. Friedman M, Ibrahim H, Joseph NJ. Staging of obstructive sleep apnea/hypopnea syndrome: a guide to appropriate treatment. *Laryngoscope*. 2004;114(3):454-459. doi:10.1097/00005537-200403000-00013.
3. Fujita S, Conway W, Zorick F, Roth T. Surgical correction of anatomic abnormalities in obstructive sleep apnea syndrome: uvulopalatopharyngoplasty. *Otolaryngol - Head Neck Surg*. 1981;89(6):923-934. doi:10.1177/019459988108900609.
4. Holmlund T, Franklin KA, Levring J, Ghagen E, et al. Tonsillectomy in adults with obstructive sleep apnea. *Laryngoscope*. 2016;126(12):2859-2862. doi:10.1002/lary.26038.
5. Huntley C, Chou D, Doghramji K, Boon M. Preoperative Drug Induced Sleep Endoscopy Improves the Surgical Approach to Treatment of Obstructive Sleep Apnea. *Ann Otol Rhinol Laryngol*. 2017;3489417703408. doi:10.1177/0003489417703408.
6. Kohn JL, Boyd Gillespie M. Drug-induced sleep endoscopy. *Oper Tech Otolaryngol Neck Surg*. 2015;26(2):66-73. doi:10.1016/j.otot.2015.03.004.
7. Maimon N, Hanly PJ. Does snoring intensity correlate with the severity of obstructive sleep apnea? *J Clin Sleep Med*. 2010;6(5):475-478.
8. Neruntarat C. Uvulopalatal flap for obstructive sleep apnea: Short-term and long-term results. *Laryngoscope*. 2011;121(3):683-687. doi:10.1002/lary.21157.
9. Pang KP. Lateral pharyngoplasty in the treatment of obstructive sleep apnea. *Oper Tech Otolaryngol - Head Neck Surg*. 2006;17(4):226-229. doi:10.1016/j.otot.2006.10.008.
10. Pang KP, Pang EB, Win MTM, Pang KA, Woodson BT. Expansion sphincter pharyngoplasty for the treatment of OSA: a systemic review and meta-analysis. *Eur Arch Oto-Rhino-Laryngology*. 2016;273(9):2329-2333. doi:10.1007/s00405-015-3831-2.
11. Pang KP, Tan R, Puraviappan P, Terris DJ. Anterior palatoplasty for the treatment of OSA: Three-year results. *Otolaryngol - Head Neck Surg*. 2009;141(2):253-256. doi:10.1016/j.otohns.2009.04.020.
12. Pang KP, Terris DJ. Injection snoreplasty. *Rhinol Sleep Apnea Surg Tech*. 2007;13(3):319-321. doi:10.1007/978-3-540-34020-1_34.
13. Pang KP, Terris DJ. Modified cautery-assisted palatal stiffening operation: New method for treating snoring and mild obstructive sleep apnea. *Otolaryngol - Head Neck Surg*. 2007;136(5):823-826. doi:10.1016/j.otohns.2006.11.014.
14. Pang KP, Woodson BT. Expansion sphincter pharyngoplasty in the treatment of obstructive sleep apnea. *Oper Tech Otolaryngol - Head Neck Surg*. 2006;17(4):223-225. doi:10.1016/j.otot.2006.10.008.
15. Tang JA, Salapatas AM, Bonzelaar LB, Friedman M. Long-Term Incidence of Velopharyngeal Insufficiency and Other Sequelae following Uvulopalatopharyngoplasty. *Otolaryngol Neck Surg*. 2017;194599816688646. doi:10.1177/0194599816688646.
16. Teran Santos, Jimenez-Gomez A C-GJ. The association between sleep apnea and the risk of traffic accidents. *N Engl J Med*. 1999;340:847-851.
17. Troell RJ, Li KK, Powell NB, Riley RW. Radiofrequency of the soft palate in snoring and sleep-disordered breathing. *Oper Tech Otolaryngol - Head Neck Surg*. 2000;11(1):21-23. doi:10.1016/S1043-1810(00)80006-8.
18. Tucker Woodson B. A method to describe the pharyngeal airway. *Laryngoscope*. 2015;125(5):1233-1238. doi:10.1002/lary.24972.
19. Walker RP. Palatal implants for snoring and sleep apnea. *Oper Tech Otolaryngol - Head Neck Surg*. 2006;17(4):238-241. doi:10.1016/j.otot.2006.10.001.
20. Woodson BT. Transpalatal advancement pharyngoplasty. *Rhinol Sleep Apnea Surg Tech*. 2007;339-346. doi:10.1007/978-3-540-34020-1_37.

