

11-1-2013

Abdominal intercostal hernia: a rare complication after blunt trauma.

Phi D Nguyen, B.A.
Thomas Jefferson University

Michael J. Pucci, MD
Thomas Jefferson University, michael.pucci@jefferson.edu

Jay S. Jenoff, MD
Thomas Jefferson University, Jay.Jenoff@jefferson.edu

Scott W. Cowan, MD
Thomas Jefferson University, Scott.Cowan@jefferson.edu

[Let us know how access to this document benefits you](#)

Follow this and additional works at: <https://jdc.jefferson.edu/gibbonsocietyprofiles>

 Part of the [History of Science, Technology, and Medicine Commons](#), and the [Surgery Commons](#)

Recommended Citation

Nguyen, B.A., Phi D; Pucci, MD, Michael J.; Jenoff, MD, Jay S.; and Cowan, MD, Scott W., "Abdominal intercostal hernia: a rare complication after blunt trauma." (2013). *Department of Surgery Gibbon Society Historical Profiles*. Paper 19.
<https://jdc.jefferson.edu/gibbonsocietyprofiles/19>

This Article is brought to you for free and open access by the Jefferson Digital Commons. The Jefferson Digital Commons is a service of Thomas Jefferson University's [Center for Teaching and Learning \(CTL\)](#). The Commons is a showcase for Jefferson books and journals, peer-reviewed scholarly publications, unique historical collections from the University archives, and teaching tools. The Jefferson Digital Commons allows researchers and interested readers anywhere in the world to learn about and keep up to date with Jefferson scholarship. This article has been accepted for inclusion in Department of Surgery Gibbon Society Historical Profiles by an authorized administrator of the Jefferson Digital Commons. For more information, please contact: JeffersonDigitalCommons@jefferson.edu.

Brief Reports

Brief Reports should be submitted online to www.editorialmanager.com/amsurg. (See details online under "Instructions for Authors".) They should be no more than 4 double-spaced pages with no Abstract or sub-headings, with a maximum of four (4) references. If figures are included, they should be limited to two (2). The cost of printing color figures is the responsibility of the author.

In general, authors of case reports should use the Brief Report format.

Abdominal Intercostal Hernia: A Rare Complication after Blunt Trauma

Abdominal intercostal hernia (AIH) is uncommonly reported in the literature with only 20 cases reported to date.¹⁻³ We report a case of a delayed incarcerated AIH secondary to blunt trauma from a motor vehicle accident in which the colon and diaphragm herniated through an associated chest defect that was repaired successfully through a transabdominal approach using primary repair of the defect in combination with onlay porcine patch reinforcement.

A 62-year-old man was seen in the thoracic surgery clinic for evaluation of a chronic left-sided chest wall defect with associated chest wall hernia. The patient was involved in a motor vehicle accident 5 years prior, when he sustained multiple left-sided rib fractures and a splenic injury. He underwent emergent splenectomy through a midline laparotomy and left thoracotomy to repair a lung injury. Over the last 2 years, a large bulge developed in his left chest, which increased in size when coughing and was associated with severe burning pain. Physical examination revealed a lateral chest wall defect involving ribs 7 to 9 with an associated incarcerated hernia, which increased in size with Valsalva and coughing. On imaging, there was evidence of fracture and separation of portions of the seventh through ninth left ribs with elevation of the patient's left hemidiaphragm (Fig. 1). Chest computed tomography scan revealed herniation of both the diaphragm and colon into the chest wall defect (Fig. 2).

The AIH was approached transabdominally through a left subcostal incision. After adhesiolysis, a portion of the left colon and associated omentum were reduced out of the defect. The defect measured 3 × 3 cm and was lined by herniated, attenuated diaphragm. Figure-of-eight 2-0 Prolene sutures were used to approximate the edges of diaphragm. Next, a porcine tissue graft

(Strattice; LifeCell Corporation, Branchburg, NJ) was sewn circumferentially as an onlay patch using interrupted Prolene sutures to cover and exclude the defect. Postoperatively, the patient developed a sterile intra-abdominal collection, which was drained percutaneously and otherwise recovered well. The patient's symptoms resolved after the procedure.

Herniation of either thoracic or abdominal contents through intercostal spaces is a rare occurrence. These hernias, named intercostal hernias, typically result from a traumatic injury or failure of healing a thoracic incision. A risk factor for the development of any type of intercostal herniation is trauma to the chest wall, especially as a result of rib fracture. Although not necessary for the development of the hernia, more than 50 per cent of intercostal abdominal hernias have involved rib fractures.² Although pleural or lung herniation is more common, there have been approximately

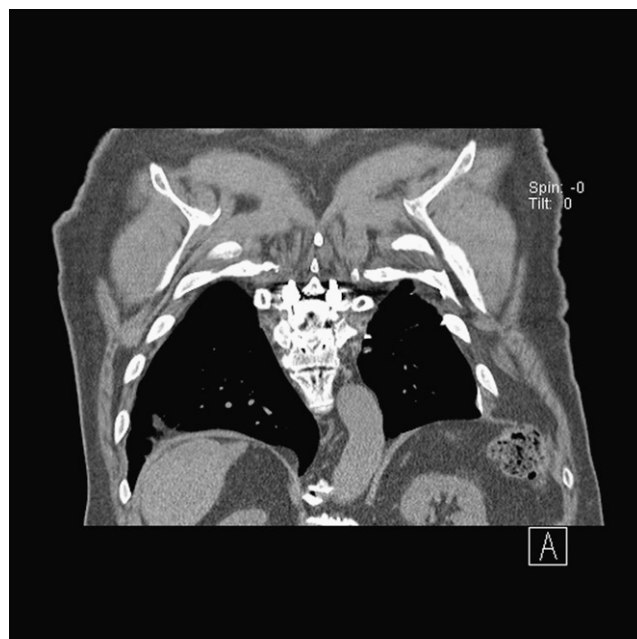


FIG. 1. Coronal view computed tomography scan of the chest demonstrating left-sided chest wall deformity and elevation of left hemidiaphragm.

Address correspondence and reprint requests to Scott W. Cowan, M.D., Department of Surgery, Thomas Jefferson University, 607 College Building, 1025 Walnut Street, Philadelphia, PA 19107. E-mail: scott.cowan@jefferson.edu.

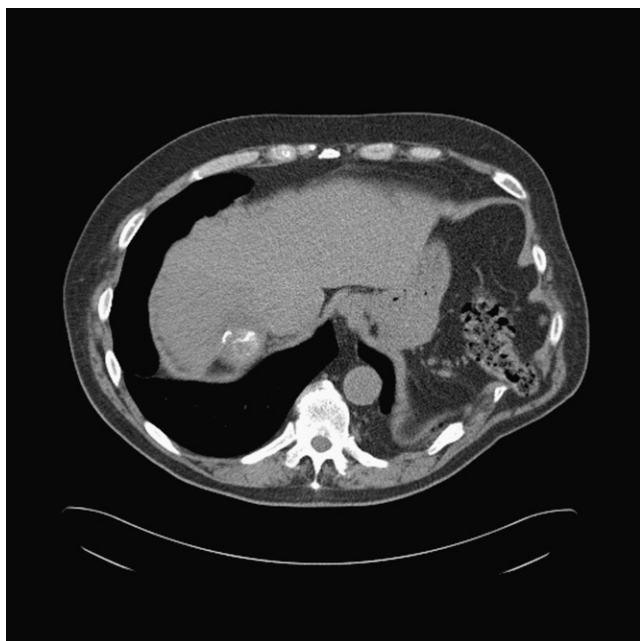

FIG. 2. Axial view computed tomography scan of the chest displaying colon and diaphragm herniation.

20 cases reported of abdominal contents herniating through intercostal spaces.¹⁻³ The hypothesized cause of these hernias is multifactorial. A weakness in the thoracic wall and the natural pressure gradient between the intra-abdominal and intrathoracic spaces contribute to this unique situation.

Terminology of these hernias is variable in the literature. In general, abdominal intercostal hernia describes the circumstance when abdominal contents herniate through the intercostal spaces. However, this is a nonspecific term and does not delineate whether a diaphragmatic defect is present. More accurate terminology has been used in the circumstance where there is an abdominal intercostal hernia with an associated diaphragmatic defect, named transdiaphragmatic intercostal hernia.^{2, 4} The majority of reported cases of intercostal hernias are considered transdiaphragmatic, whereas far fewer cases exist without an associated defect in the diaphragm such as in our patient.¹⁻⁴

Although trauma was the primary contributing factor responsible for development of the AIH, progression

likely occurred as a result of an obesity-related increase in intra-abdominal pressure. Also, the patient's history of splenectomy may have played a role because there was no organ adjacent to the defect to help prevent colonic herniation.

Acute and chronic traumatic transdiaphragmatic hernias should be repaired once diagnosed. Operative treatment has been described through both abdominal and thoracic approaches, dictated primarily by timing between injury and diagnosis. In our patient with a posttraumatic intercostal hernia with an intact diaphragm, the transabdominal approach was chosen as a result of his prior thoracotomy and concern for pleural adhesions. The patient's prior splenectomy allowed excellent visualization and safe reduction of the hernia contents. The use of a porcine onlay patch primarily functioned as a buttress to the primary repair.

In conclusion, the cause of AIH is usually multifactorial and indications for intervention should be dictated by acuity, symptoms, and overall operative risk. Operative repair should follow standard herniorrhaphy principles, including complete reduction of sac contents, primary closure if possible, and the use of tension-distributing patch materials.

Phi D. Nguyen, B.A.

Michael J. Pucci, M.D.

Jay S. Jenoff, M.D.

Scott W. Cowan, M.D.

*Department of Surgery
Thomas Jefferson University
Philadelphia, Pennsylvania*

REFERENCES

1. Thomasson J, Maxwell R. Intercostal hernias. *Am Surg* 2010; 76:E125-7.
2. Unlu E, Temizoz O, Cagli B. Acquired spontaneous intercostal abdominal hernia: case report and a comprehensive review of the world literature. *Australas Radiol* 2007;51:163-7.
3. Kurer MA, Bradford IM. Laparoscopic repair of abdominal intercostal hernia: a case report and review of the literature. *Surg Laparosc Endosc Percutan Tech* 2006;16:270-1.
4. Chaar CI, Attanasio P, Dettterbeck F. Disruption of the costal margin with transdiaphragmatic abdominal herniation induced by coughing. *Am Surg* 2008;74:350-3.