

Anti-resorptive agent-related osteonecrosis of the jaw: Position Paper 2017 of the Japanese Allied Committee on Osteonecrosis of the Jaw

Japanese Allied Committee on Osteonecrosis of the Jaw: Toshiyuki Yoneda^{1,a}, Hiroshi Hagino^{1,b}, Toshitsugu Sugimoto^{1,c}, Hiroaki Ohta^{2,d}, Shunji Takahashi^{1,e}, Satoshi Soen^{2,f}, Akira Taguchi^{3,g}, Toshihiko Nagata^{4,i}, Masahiro Urade^{5,j}, Takahiko Shibahara^{5,k}, Satoru Toyosawa^{6,h}

¹The Japanese Society for Bone and Mineral Research, ²The Japan Osteoporosis Society, ³The Japanese Society of Oral and Maxillofacial Radiology, ⁴The Japanese Society of Periodontology, ⁵The Japanese Society of Oral and Maxillofacial Surgeons, ⁶The Japanese Society of Oral Pathology,

^aDivision of Hematology and Oncology, Indiana University School of Medicine, ^bSchool of Health Science, Faculty of Medicine, Tottori University, ^cInternal Medicine 1, Shimane University Faculty of Medicine, ^dClinical Research Centers for Medicine, International University of Health and Welfare, ^eDepartment of Medical Oncology, The Cancer Institute Hospital Of JFCR, ^fDepartment of Orthopedic Surgery and Rheumatology, Kindai University Nara Hospital, ^gDepartment of Hard Tissue Research, Graduate School of Oral Medicine, Matsumoto Dental University, ^hDepartment of Oral Pathology, Osaka University Graduate School of Dentistry, ⁱDepartment of Periodontology and Endodontology, School of Dentistry, Tokushima University, ^jDepartment of Oral and Maxillofacial Surgery, Hyogo College of Medicine, ^kDepartment of Oral & Maxillo-Facial Surgery, Tokyo Dental College.

This is the author's manuscript of the article published in final edited form as:

Yoneda, T., Hagino, H., Sugimoto, T., Ohta, H., Takahashi, S., Soen, S., ... & Toyosawa, S. (2017). Antiresorptive agent-related osteonecrosis of the jaw: Position Paper 2017 of the Japanese Allied Committee on Osteonecrosis of the Jaw. *Journal of bone and mineral metabolism*, 35(1), 6-19. <https://doi.org/10.1007/s00774-016-0810-7>

Disclosure of Conflicts of Interest (COI) by Authors

Toshiyuki Yoneda: Consultant fee (Daiichi-Sankyo); Hiroaki Ohta: Lecture fee (Pfizer), Manuscript fee (Medical Review Co., Ltd.); Toshitsugu Sugimoto: Lecture fee, Consultant fee (Asahi Kasei Pharma, Pfizer), Research grant (Astellas Pharma, Eisai, Ono Pharmaceutical, Daiichi-sankyo, Chugai Pharmaceutical, Eli Lilly Japan); Satoshi Soen: Lecture fee (Asahi Kasei Pharma, Astellas Pharma, Eisai, MSD, Ono Pharmaceutical, Daiichi-Sankyo, Takeda Pharmaceutical, Chugai Pharmaceutical, Teijin Pharma), Research Grant (Eisai, Daiichi-Sankyo, Takeda Pharmaceutical); Shunji Takahashi: Lecture fee (Eisai, Daiichi-Sankyo), Research grant (AstraZeneca, Daiichi-Sankyo, Chugai Pharmaceutical, Novartis Pharma, Bayer, Parexel International); Akira Taguchi: Lecture fee (Asahi Kasei Pharma, MSD, Ono Pharmaceutical, Daiichi-Sankyo, Takeda Pharmaceutical, Chugai Pharmaceutical, Teijin Pharma), Consultant fee (Asahi Kasei Pharma); Hiroshi Hagino: Lecture fee (Asahi Kasei Pharma, EA Pharma, MSD, Daiichi-Sankyo, Taisho Toyama Pharmaceutical, Takeda Pharmaceutical, Chugai Pharmaceutical, Pfizer), Research Grant (Chugai Pharmaceutical); Masahiro Urade: None; Takahiko Shibahara: None; Satoru Toyosawa: None; Toshihiko Nagata: None

Abstract

Anti-resorptive agent-related osteonecrosis of the jaw (ARONJ) is an intractable, although rarely occurs, complication in cancer patients with bone metastases and patients with osteoporosis who are treated with anti-resorptives including bisphosphonates and denosumab. Despite that more than 10 years have passed since the first cases of ARONJ was reported, our understanding of the epidemiology and pathophysiology of ARONJ still remains limited and data of ARONJ supported by evidence-based medicine are still poorly accumulated. However, diagnosis and staging of ARONJ, identification of risk factors, and development of preventive and therapeutic approaches have significantly advanced over the last a decade. The Position Paper 2017 is an updated version of the Position Paper 2010 of the Japanese Allied Committee on Osteonecrosis of the Jaw”, which is now consisted of six Japanese academic societies. The Position Paper 2017 describes new diagnostic definition for ARONJ according to AAOMS proposal, summarizes our current understandings of the pathophysiology of ARONJ based on literature search and suggests how physicians and dentists/oral surgeons should manage ARONJ, Further, the appropriateness of discontinuation of anti-resorptives (drug holiday) before, during and after invasive dental treatments is extensively discussed. More importantly, the manuscript also proposes for the first time the importance of interactive communication and co-operation between physicians and dentists/oral surgeons for successful treatment of ARONJ patients. It is expected that the Position Paper 2017 will be a guide to improve the management of ARONJ patients in Japan.

I. Background

Bisphosphonates (BPs), which possess high chemical affinity to bone and specifically inhibit osteoclastic bone resorption, have been widely and safely used for the treatment of bone metastases and osteoporosis in which osteoclastic bone resorption is excessively increased. In 2003, Marx first reported many cases of BP-related osteonecrosis of the jaw (BRONJ) in cancer patients with bone metastasis and patients with osteoporosis who were treated with BPs [1]. BRONJ is a rare but an intractable disease. Since its pathophysiology remains unclear, physicians, dentists and oral surgeons have had difficulties in the management of BRONJ patients from early days until recently. However, our understanding of BRONJ is gradually and consistently advancing by analytical reviews of accumulating clinical and preclinical data on BRONJ over the last several years. In this context, it is particularly notable that recent clinical studies have showed that the occurrence of BRONJ is significantly decreased by blocking oral infection via extensive oral health control [2-4], suggesting that infection is a key step of the development of BRONJ.

Denosumab, a human IgG2 monoclonal antibody against receptor activator of nuclear factor-kappa B ligand (RANKL) [5], is a new therapeutic agent for osteoporosis and bone metastases with the half-life of approximately one month. Different from BPs that promote apoptosis in osteoclasts, denosumab inhibits osteoclastic bone resorption without causing apoptosis in osteoclasts. Further, denosumab does not deposit and persist in bones for a long period of time as do BPs, and thus the effects of denosumab are reversible. These pharmacological properties of denosumab initially led us to assume that ONJ unlikely occurs by treatment with denosumab. To our surprise, however, patients treated with denosumab also developed ONJ (DRONJ) clinically indistinguishable from BRONJ at almost the same incidence as BRONJ [6].

Since both BP and denosumab, which show anti-bone resorption effects via different molecular mechanism of action, are associated with ONJ, anti-resorptive agent-related ONJ (ARONJ) [7] has been suggested as a comprehensive term representing both BRONJ and

DRONJ. Meanwhile, the American Association of Oral and Maxillofacial Surgeons (AAOMS) proposes the term, medication-related ONJ (MRONJ), based on the observations that anti-angiogenic inhibitors and molecularly-targeted drugs such as tyrosine kinase inhibitors also are infrequently associated with ONJ or increase the incidence of BRONJ/DRONJ in cancer patients receiving BPs or denosumab, although global consensus has not been established yet [8]. In this position paper, the term ARONJ will be used according to the proposal of the International Task Force on Osteonecrosis of the Jaw [2] of which the Japanese Society for Bone and Mineral Research is a member.

Since the first position paper on BRONJ was published by the Japanese Allied Committee on Osteonecrosis of the Jaw in 2010 [9], it has been passed 6 years, during which DRONJ has emerged, numerous and diverse ARONJ cases have been reported, and clinical and preclinical studies on ONJ have been accumulating, thereby increasing our understanding of ONJ and improving management of ONJ. The Position Paper 2017 is an updated and revised version of the Position Paper 2010 attempting to provide the latest clinical and basic information of ARONJ and propose a consensus for management of ARONJ in Japan.

The paper is compiled by the Japanese Allied Committee on Osteonecrosis of the Jaw, which consists of diverse members of bone specialists, including physicians, orthopedic surgeons, rheumatologists, obstetricians, medical oncologists, oral surgeons, periodontologists, dental radiologists, oral pathologists, and cancer biologists. The Japanese Allied Committee on Osteonecrosis of the Jaw was organized through a collaboration of six academic societies: the Japanese Society for Bone and Mineral Research, Japan Osteoporosis Society, Japanese Society of Periodontology, Japanese Society of Oral and Maxillofacial Radiology, Japanese Society of Oral and Maxillofacial Surgeons, and the Japanese Society of Clinical Oral Pathology.

II. Anti-resorptive agent-related osteonecrosis of the jaw (ARONJ)

1. Uniqueness of the jaw bone

There are several unique anatomical and microbiological characteristics in the jaw bone that could be responsible for the specific occurrence of ARONJ in jaw bones. These characteristics are not found in bones in other parts of the body.

- 1) The teeth erupt on the jaw bone breaking through the oral epithelium, allowing infectious factors, agents and microbes in the oral cavity directly invade into the jaw bone via the gap between epithelium and teeth or via root canal.
- 2) The oral mucosa covering the jaw bone is thin and infection caused by mucosal injury spreads to the jaw bone beneath the mucosa.
- 3) More than 800 types of resident bacteria (10^{11} to $10^{12}/\text{cm}^3$) inhabit in dental plaques as sources of infection in the oral cavity.
- 4) Inflammations due to tooth decay, pulpitis, periapical lesions, and periodontal diseases extend to the jaw bone.
- 5) The jaw bone exposes to the oral cavity following invasive dental treatments including tooth extraction, leading to infection.

Thus, the environments around jaw bone have a predisposition to readily get bacterial infection [10], which may be the reason why ARONJ occurs specifically in the jaw bone.

2. Diagnosis of ARONJ

AAOMS proposed additional diagnostic criteria for ONJ in 2014 and the Allied Committee agreed to adopt these new diagnostic criteria. Accordingly, ARONJ is definitely diagnosed when the following three conditions are met.

- 1) Patients have history of treatment with BP or denosumab.

- 2) Patients have no history of radiation therapy to the jaw bone. Bone lesions of ARONJ must be differentiated from cancer metastases to the jaw bone by histological examinations.
- 3) Exposure of alveolar bone in the oral cavity, jaw and/or face is continuously observed for longer than 8 weeks after first detection by medical or dental experts. Or the bone is palpable in the intra- or extra-oral fistula for longer than 8 weeks [8]. These criteria do not apply to a patient in Stage 0.

3. Incidence of ARONJ

The incidence of ARONJ varies depending on studies. There are no reliable epidemiologic data that are derived from evidence-based medicine. This position paper follows the data cited by the International Task Force on ONJ [2].

1) Patients with osteoporosis

① BRONJ

The incidence is 1.04 to 69 per 100,000 patients treated with oral administration per year, and 0 to 90 per 100,000 patients treated with intravenous administration per year. The incidence of ONJ in osteoporotic patients treated with oral/intravenous nitrogen-containing BPs ranges from 0.001% to 0.01%, which is estimated to be almost the same or slightly higher than the incidence (0.001%) of ONJ in the general population.

② DRONJ

The incidence is 0 to 30.2 per 100,000 patients per year.

2) Cancer patients

The incidence of ONJ in cancer patients is higher than that in patients with osteoporosis. Prospective studies of the incidence of ONJ have been conducted in cancer patients treated with zoledronic acid or denosumab. Of 5,723 patients with breast, prostate and other solid cancers and multiple myeloma, 52 patients (1.8%) treated with denosumab and 37 patients (1.3%) treated with zoledronic acid (i.e., 89 cancer patients in total) developed ONJ in 3 year follow-up [6, 11].

3) Incidence of ARONJ in Japan

① BRONJ

In nationwide surveys, The Japanese Society of Oral and Maxillofacial Surgeons found 263 patients with BRONJ from the year of 2006 to 2008 [12] and 4,797 from the year of 2011 to 2013 [13]. Approximately 40% of patients with BRONJ from 2006 to 2008 and half of those from 2011 to 2013 developed BRONJ following oral BP administration [12, 13]. These results in Japan differ from the results obtained in other countries showing higher incidence of BRONJ in patients treated with intravenous BPs than oral BPs. The incidence of BRONJ in Japan is unknown, since data of the total number of patients treated with BPs are unavailable at the present time.

② DRONJ

A study conducted by a pharmaceutical company (Daiichi Sankyo) after denosumab was launched in the market reported that 120 cancer patients treated with denosumab from April 17, 2012 to July 31, 2015 developed DRONJ, and 58 of these patients had been treated with BPs before denosumab.

Twenty patients with osteoporosis treated with denosumab from June 11, 2013 to December 31, 2015 developed DRONJ, and 15 of them had received BPs before denosumab.

4. Clinical manifestations and staging of ARONJ

Clinical manifestations and staging of ARONJ are summarized in Table 1. Paresthesia in the chin, including the lower lip (Vincent's symptom) of patients treated with BP is an early sign of ARONJ before alveolar bone exposure is detected.

1) Stage 0

The 2012 Position Paper (in Japanese) proposed that cases with ONJ-like clinical manifestations but no alveolar bone exposure can be diagnosed as Stage 0 ONJ. It is reported that Stage 0 ONJ accounts for 25-30% of ONJ, however, that half of Stage 0 cases heal without progression to Stage 1 [14]. Accordingly, the International Task Force on ONJ does not include Stage 0 in ONJ, concerning it may cause over-diagnosis [2, 15]. On the other hand, the AAOMS proposes that Stage 0 should be diagnosed and treated as a pre-ONJ [8]. This Position Paper includes Stage 0 in ONJ in agreement with the proposal of AAOMS from therapeutic points of view. However, it is strongly recommended that the diagnosis of Stage 0 should be cautiously made to avoid over-diagnosis.

2) Differences in clinical characteristics between BRONJ and DRONJ

Clinical manifestations are indistinguishable between BRONJ and DRONJ at the present time. There is not sufficient information accumulated yet on imaging and histopathological characteristics of DRONJ that allows us to compare with those of BRONJ [16]

Incidence of DRONJ in cancer patients is reported to be less than 2% and equivalent to that of BRONJ [6, 11]. In contrast, incidence of DRONJ in osteoporosis patients is unknown.

3) Serum biochemical markers for bone turnover and ARONJ

Value of serum biochemical markers of bone turnover is decreased by the treatment with BP and denosumab. Thus, it is expected that these markers are potentially useful for diagnosis, follow-up and assessment of therapeutic effects in patients with ARONJ [17]. However, most

clinical studies found no significant correlation between changes in these serum bone turnover markers and the occurrence and progression or healing of ARONJ [2]. Therefore, currently-used bone turnover markers unlikely have diagnostic value for ARONJ.

4) Imaging

For patients under the treatment with low-dose anti-resorptives and with no evident clinical manifestations of ARONJ, intraoral and panoramic radiographs in conjunction with clinical manifestations are sufficient for diagnosis (Figure 1). Intraoral radiographs, which have high resolution, can reveal the site of infection in detail.

For cancer patients being treated with high-dose anti-resorptives, it is recommended that intraoral radiographs of all existing teeth and panoramic radiographs should be undergone to identify potential sites of infection even if they have no signs of ONJ, since they potentially have increased risk for developing ONJ.

For patients who are clinically suspected to have developed ONJ, computed tomography (CT) and dental cone-beam CT are helpful to detect early changes in trabecular and cortical bones of the jaws and assess the sequestra, fistula formation, periosteal responses and involved teeth. However, use of dental cone-beam CT is limited to localized lesions and supplemental to CT. CT must be combined with intraoral and panoramic radiographs. For cases in which differential diagnosis between ONJ and malignant tumors are required, use of CT and MRI, rather than dental cone-beam CT, is recommended.

MRI, which allows assessment of changes in the bone marrow, may be useful for diagnostic evaluation of ONJ. For patients with ONJ who are under conservative and/or surgical treatments, the characteristics and extents of bone changes surrounding exposed bone can be assessed by CT and dental CT. MRI is useful for assessment of surrounding soft tissues, in addition to bones. Existing teeth that may be causes of infection can be detected by intraoral radiographs [18].

Recent studies have proposed that hybrid SPECT/CT may be useful for distinguishing ONJ lesions from unaffected healthy bone at the time of surgical interventions of ONJ [19, 20]. Simple PET using ^{18}F -FDG and PET/CT may be also useful for assessment of ONJ lesions.

At present, no specific differences in images between BRONJ and DRONJ have been described.

5) Histopathological findings in ARONJ

Although histopathological definition for diagnosis of ARONJ is yet to be established, several features of ARONJ are noted. The major histopathological finding of BRONJ is characterized by chronic osteomyelitis accompanied with osteonecrosis. In BRONJ lesions, there are relatively large osteoclasts detaching from the bone surfaces, which is similarly seen in bones treated with BPs [21] (Figure 2A). Trabecular bone exhibits mosaic-pattern lines of bone remodeling (Figure 2B), with increased thickness and decreased osteon density (osteon number/bone area). These histological views resemble those of bones in which osteoclastic bone resorption is inhibited by BP [22]. On the other hand, trabeculae bones with active inflammation demonstrate extensive osteoclastic bone resorption with resorption lacunae. Of note, *Actinomyces* colonies (resident bacteria in the oral cavity) are frequently present in contact with necrotic bones in ONJ lesions (Figure 2B, insert), raising the possibility that *Actinomyces* play a role in the pathogenesis of BRONJ [23].

A histopathological study on DRONJ published by a Japanese group showed that numbers of osteoclasts are decreased and immature osteoclasts with few nuclei are increased in DRONJ lesions presumably due to the action of denosumab [24]. However, whether these histopathological features are unique to DRONJ and distinct from those of BRONJ are currently unknown.

5. Risk factors for ARONJ

Proposed risk factors for ARONJ are listed in Table 2. Of these risk factors, invasive dental treatments such as tooth extraction, dental implant and apical/periodontal surgery are definitely local risk factors for ARONJ. It should, however, be noted that the list is not made based on robust medical evidence but the summary of published reports the Allied Committee investigated. Here, risk factors that are newly listed are discussed.

1) Dental implants and ARONJ

Recent reports suggest that implants inserted before patients with cancer or osteoporosis are treated with BPs are unlikely associated with subsequent occurrence of BRONJ if oral health is appropriately managed [25, 26]. However, dental implantation performed during or after BP treatment is a potential risk factor for BRONJ.

It is unknown whether dental implants are risk factors in patients receiving denosumab. Dental implant for cancer patients who are on the treatment with anti-resorptives is not recommended and alternative dental measures are recommended. On the other hand, dental implant in patients with osteoporosis may be performed in case physicians and dentists agree that dental implants are essential to improve systemic and oral health of patients.

2) New therapeutic agents and ARONJ

In Table 2, denosumab, ibandronate and anti-angiogenic agents and tyrosine kinase inhibitors are newly listed. Since the Position Paper 2010 was published, denosumab was launched in 2012 in Japan and has been widely used in the treatment of bone metastases and osteoporosis with infrequent occurrence of DRONJ.

Ibandronate was also launched as a new BP for the treatment of osteoporosis in Japan. A prospective study performed in Japan showed that there is no significant difference in the incidence of ONJ between osteoporotic patients treated with intravenous and oral ibandronate [27], suggesting that the route of administration does not influence the occurrence of BRONJ associated with ibandronate.

Anti-angiogenic agents and tyrosine kinase inhibitors, which are essentially administered as adjuvants in the treatment of cancer patients, have been shown to cause, although very rarely, by themselves or increase the incidence of ARONJ due to BP or denosumab [28].

6. Mechanism of ARONJ

The mechanism responsible for ARONJ is not fully understood. In particular, it is a major question why the incidence of ARONJ is so low in osteoporotic patients, despite that millions of patients receive BP or denosumab. It is also unknown why ARONJ spontaneously develops in patients who are treated with anti-resorptives, but receive no invasive dental treatments. These issues can't be explained only by the mechanisms currently proposed. Animal models in which ONJ is induced by administration of BP or RANKL inhibitors, followed by tooth extraction, have recently been developed in mice, rats, dogs and pigs [29-31]. It is expected that these animal models allow us to determine the pathophysiology and mechanism of ARONJ and develop new therapeutic interventions for ARONJ. Here, the mechanisms already described in the literature are summarized. Complex interactions of these mechanisms together with additional yet-unknown mechanisms are assumed to lead to the development and progression of ARONJ [29].

- 1) Inhibition of bone remodeling and excessive inhibition of osteoclast activity by anti-resorptives
- 2) Increased predisposition to oral bacterial infection due to BP administration
- 3) BP suppression of remodeling and migration of oral epithelial cells
- 4) Changes in immune surveillance by anti-resorptives
- 5) Anti-angiogenic effects of BP
- 6) Others

III. Dental treatments and discontinuation of anti-resorptives

1. Dental treatments of patients who are to receive anti-resorptives

Before starting administration of anti-resorptives, physicians need to explain to patients not only the benefits of anti-resorptives for bone metastases and osteoporosis but also risks of anti-resorptives for ONJ. It is wise to request patients to visit a dentist to control oral health to prevent the occurrence of ONJ. During dental treatments of these patients, interactive communication and close cooperation between physicians and dentists are essential. It is most appropriate that physicians inform dentists of the current status, clinical courses, therapeutic history and prognosis of the primary disease. Ideally, all dental treatments are expected to be completed 2 weeks before starting anti-resorptive treatment. However, in case anti-resorptive treatment can't be delayed because of progression of bone metastases or high risk for fracture, administration of anti-resorptives in parallel with dental treatments may be acceptable. During treatment with anti-resorptives, physicians instruct patients to routinely visit a dentist to have oral examination. Dentists should inform physicians of the results of oral examinations and dental treatments as soon as they are done, so that there is no delay in anti-resorptive administration by physicians. It is also helpful if physicians inquire patients the status of their oral cavity and teeth at their visit.

2. Dental treatments of patients receiving anti-resorptives

1) Discontinuation of BPs before starting dental treatments

It is controversial whether discontinuation (drug holiday) of BPs for a certain period of time before starting invasive dental treatments is effective at preventing or decreasing the occurrence of BRONJ. The arguments are as follows:

- ① There is little clinical evidence that short-term discontinuation of BPs helps prevent the occurrence of BRONJ resulting from invasive dental treatments.

- ② Based on the physiochemical properties of BPs that deposit and persist in the bone for a long period of time [5], it appears unlikely that short-term drug holiday of BPs prevents BRONJ.
- ③ Survey conducted by the Japan Osteoporosis Society showed no changes in incidence of BRONJ in osteoporotic patients even if BPs or denosumab are discontinued before dental treatments [32, 33].
- ④ In osteoporotic patients who had BP drug holiday, there are exacerbations of osteoporosis including decreased bone mineral density and increased incidence of fractures [32-34].
- ⑤ Given extremely low incidence of BRONJ in osteoporosis, the benefits of BP for fracture prevention outweigh the risks for BRONJ [35].
- ⑥ Several recent studies reported that infection is a key event for BRONJ and that extensive infection control before invasive dental treatments decreases BRONJ [3]. Of particular note, this study also shows that BRONJ did not occur even in cancer patients who previously had BRONJ at other sites in the oral cavity if infection is properly controlled. These results suggest that infection control is most important for prevention of BRONJ.
- ⑦ The American Dental Association estimated an incidence of ARONJ in patients with osteoporosis is, at the highest, up to 0.1% and suggests that the benefits of anti-resorptives for fracture prevention outweigh the risks for ARONJ. Discontinuation of anti-resorptives is unlikely to decrease the risk for ARONJ, but rather increase negative effects such as increased fractures [7].

These pieces of background collectively suggest that discontinuation (drug holiday) of BP before starting invasive dental treatments is not logically supported.

In contrast, however, the advisory board of the Food and Drug Administration (FDA) (<http://>

www.fda.gov/downloads/AdvisoryCommittees/CommitteesMeetingMaterials/Drugs/DrugSafetyandRiskManagementAdvisoryCommittee/UCM270958.pdf), AAOMS [8, 17] and other groups [36, 37] described that the incidence of BRONJ increased in patients with osteoporosis who are treated with BPs for longer than 4 years in retrospective studies with small number of cases. From these results, AAOMS recommended that discontinuation of anti-resorptives for approximately 2 months before invasive dental treatments needs to be considered in case patients receive anti-resorptives for longer than 4 years and have low risk for fractures but potential high risk for BRONJ with a consultation with physicians [8]. The Japanese Society of Oral and Maxillofacial Surgeons, and other academic societies including the Korean Society for Bone and Mineral Research, the Korean Association of Oral and Maxillofacial Surgeons [38], and the International Association of Oral and Maxillofacial Surgeons (IAOMS) support the AAOMS proposal. Thus, no consensus has been reached yet regarding whether drug holiday of BP before invasive dental treatments is adequate and necessary for prevention of BRONJ. Prospective clinical studies should be performed under the cooperation of allied teams of physicians, dentists and oral surgeons, hopefully at international levels to include as many as BRONJ cases, to address this important issue. Whatever the results of the studies, however, it is most important that invasive dental treatments for patients who are receiving anti-resorptives are conducted with careful and meticulous surgical techniques under elaborative planning in conjunction with extensive control of oral infection.

2) Suggested dental treatments of patients with cancer and osteoporosis who are receiving BPs

There are many review articles that propose the practical approaches to prevent the occurrence of BRONJ in patients who are receiving BPs during dental treatments [2-4, 7, 8]. The Position Paper 2017 proposes the followings as an example. Dental experts will need to educate patients on the importance of daily oral sanitation including how to clean the oral cavity after each meal and rinse their mouth with antibacterial mouthwash. In parallel, dentists make efforts to eliminate causes of infection such as dental plaque, calculus, tooth decays,

remaining roots, periodontitis, apical lesions, ill-fitting dentures, crowns and inlays as much as possible. Subsequently, dentists can begin conservative dental treatments without discontinuation of BPs. In case, however, invasive dental treatments such as removal of teeth responsible for BRONJ are inevitable, antibacterial agents are administered to patients in advance and invasive dental treatments should be restricted to as minimum extent and area as possible without discontinuation of BPs. At the end of the invasive treatments, remaining sharp edges of alveolar bones should be smoothed, and surgical wounds are to be closed primarily with mucoperiosteal flap lined by the periosteum.

3) Suggested dental treatment of patients with cancer and osteoporosis who are receiving denosumab

Denosumab has significantly superior benefits for cancer patients with bone metastases than does zoledronic acid [11]. The incidence of DRONJ was found to be equivalent to that of BRONJ in cancer patients [6]. Occurrence of DRONJ in patients with osteoporosis under treatment with denosumab is also reported in Japan, although the incidence is extremely low [39]. Similar to patients treated with BPs, dentists conduct conservative dental treatments without drug holiday. Invasive dental treatments, if inevitable, can be conducted without drug holiday following appropriate infection control. A recent case report showed uneventful healing of tooth extraction sockets by closing the sockets with oral mucosa to prevent secondary infection in patients under denosumab [40]. Interestingly, another case report from Japan described that DRONJ in colon cancer patients with bone metastases healed after discontinuation of denosumab [41], suggesting that the actions of denosumab are reversible. Given that denosumab is administered to osteoporotic patients once every 6 months and the half-life of denosumab is approximately one month, there is room to consider the timing and plan of dental treatments between the 6 month intervals.

Of note, intriguing experimental results in a mouse model in which administration of osteoprotegerin (OPG)-Fc or zoledronic acid caused ONJ were recently reported [31]. In this

model, ONJ was spontaneously healed by discontinuation of OPG-Fc, while ONJ was not healed by discontinuation of zoledronic acid. Since OPG-Fc has RANKL inhibitory action similar to denosumab, these findings are consistent with the notion that the effects of denosumab are reversible.

4) Discontinuation of anti-resorptives after invasive dental treatments

Anti-resorptives may interfere with the healing of surgical wounds, especially epithelialization of wounds [29]. In this case, it may be required to temporarily discontinue the administration of anti-resorptives or change to alternative therapeutic drugs unassociated with ONJ until surgical wounds completely heal. Continuation or discontinuation of anti-resorptives needs to be decided depends on fracture risk evaluated by the “Guidelines on the prevention and treatment of osteoporosis 2015” [42] and the status of the healing of surgical wounds in the oral cavity under agreement between physicians and dentists.

5) Timing of resuming the administration of anti-resorptives

Timing of re-starting administration of anti-resorptives after drug holiday is dependent on the balance between healing of surgical wounds and control of the primary disease. If fracture risk or bone metastasis is well-controlled, it is recommended that the treatment with anti-resorptives is resumed approximately two months after invasive dental treatments, when the alveolar bones damaged are expected to heal. However, if fracture risk is high or bone metastasis progresses during drug holiday and re-administration of anti-resorptives is urgent, and if there are no signs of infection around surgical wounds, two weeks after the invasive dental treatments, when epithelialization of the surgical site is almost complete, may be the earliest timing. Dentists are expected to immediately inform physicians of healing of surgical wounds, so that administration of anti-resorptives is resumed without delay.

3. Dental treatment of pediatric patients treated with BPs for osteogenesis imperfecta (OI)

Intravenous injection of pamidronate is most commonly used for treatment of pediatric patients

with OI. There are no reports of BRONJ in these patients following dental treatments including tooth extraction [43, 44]. Denosumab has also beneficial effects on OI [45]. It is unknown whether these pediatric OI patients developed DRONJ following invasive dental treatments.

IV. Management of ARONJ

Management of BRONJ by dentists and oral surgeons has markedly improved. In contrast, there is still much less information on the management of DRONJ. Since inhibitory effects of denosumab are transient and reversible, it seems that prognosis of DRONJ is less serious than BRONJ. However, since the differences in the pathophysiological characteristics between DRONJ and BRONJ are currently unclear, it is recommended that BRONJ and DRONJ are essentially treated in similar manners.

The therapeutic recommendations described below are a summary of case studies and opinions of experts previously published and are not validated by evidence-based medicine.

1. Goal of treatment of ARONJ

Treatment of ARONJ should be performed along with the following three principles:

- 1) Blockade of ONJ extension
- 2) Maintenance of QOL of patients by relieving symptoms including pain, pus discharge and paresthesia and by control of infection
- 3) Education and routine follow-up for oral health care in patients by dental experts.

2. Treatment of ARONJ

- 1) Choice of conservative or surgical treatments

Treatment of ARONJ varies with the stage of the disease. However, regardless of stages, it is required to treat dental and periodontal diseases, maintain and improve oral health with

antibacterial mouthwash, and systemically administer antibacterial agents. Importantly, isolated sequestra must be eliminated to promote healing of soft tissues and prevent further extension of ONJ.

Therapeutic strategies according to ARONJ stage are summarized in Table 3. Until several years ago the first-line treatment for ARONJ was conservative approaches and surgical therapies were performed only when ONJ advancement and prevailing of infection could not be prevented by conservative ways. However, many recent clinical case studies showed that Stage 2 and Stage 3 ARONJ are cured better by surgical than conservative therapies [46], leading to a trend to prefer surgical approaches to conservative ones [3, 4, 8, 13]. To make surgical approaches successful, complete elimination of ARONJ lesions and closure of surgical wounds with systemic administration of antibacterial agents are critical. If patients have a history of malignant tumor, all necrotic bones removed will need to be examined by histopathology to exclude that excised ARONJ lesions are tumor metastases to the jaws. Isolated sequestra should be completely removed without exposing healthy bones surrounding ARONJ lesions, regardless of disease stage. Further, since tooth extraction *per se* is unlikely to exacerbate existing ARONJ lesions, removal of affected teeth in exposed necrotic bones is recommended. For Stage 1 ARONJ, however, conservative approaches are still recommended [47]. Notably, however, the same authors recommended surgical therapies if ARONJ advances to Stage 2 or 3 [48]. Thus, improvement of surgical techniques and control of infection are requisites for better and successful management of ARONJ.

2) Administration of antibacterial agents

There are no evidence-based recommendations for what kinds of antibacterial agents are chosen and how long these agents are administered for ARONJ treatment. The survey conducted by the Japanese Society of Oral and Maxillofacial Surgeons showed that various classes of antibacterial agents were given intravenously, orally or mixed for a varying period of time. Of interest, a study from a Japanese group reported that 2- to 10-week administration

of sitafloxacin resolved or cured some cases of Stage 2 and Stage 3 BRONJ [49]. However, long-term administration of antibacterial agents may not be recommended considering acquisition of drug-resistance in the future use of antibacterial agents.

3) Treatment with parathyroid hormone (Teriparatide)

Systemic administration of low-doses of recombinant parathyroid hormone (teriparatide) is shown to resolve ONJ symptoms and promote cure [50]. Studies in Japan have also shown that bone regeneration and healing in ONJ lesions are improved by teriparatide [51, 52]. However, these results are all derived from case reports but not prospective randomized controlled studies and thus do not provide yet robust medical evidence to endorse the use of teriparatide for ARONJ treatment. It should also be noted that administration of teriparatide is a contra-indication for patients with metastatic bone tumor and there is also strict restriction for its total dose and period of administration. Thus, the advantages and benefits of teriparatide administration in the treatment of ARONJ still need to be validated.

4) Other treatments

Low-intensity laser therapy, hyperbaric oxygen therapy and local administration of platelet-derived growth factor (PDGF) have also been attempted, but their efficacies are uncertain at present [2, 4].

3. Administration of anti-resorptives to patients under ARONJ treatments

It is unknown whether discontinuation or continuation of anti-resorptives is adequate in patients who suffer from ARONJ. Discontinuation of anti-resorptives in cancer patients with progressive bone metastases seems inadequate. On the other hand, for patients with osteoporosis, excluding those with high fracture risk, discontinuation of anti-resorptives may be recommended until the treatments of ARONJ are completed. In support of validity of drug holiday during ARONJ treatments, a study reported that resolution of ARONJ is faster by six months in patients who had drug holiday than those who continued to receive anti-resorptives

after surgical treatments for ARONJ [53].

4. Importance of the cooperation between physicians and dentists in ARONJ treatment

Survey results of the Japan Osteoporosis Society indicated that dentists frequently requested discontinuation of anti-osteoporotic agents unrelated with ARONJ and nearly 30% of these agents were drugs other than BPs or denosumab [32, 33]. Therefore, dentists should recognize that not all anti-osteoporotic agents are associated with ARONJ. On the other hand, the same survey showed that 62% of physicians have not requested oral health care to dentists and 72% have not consulted with dentists before starting administration of anti-resorptives [33]. These results suggest a lack of communications and interactions between physicians and dentists in the treatments of patients with ARONJ, creating the circumstances in which incidence of ARONJ is still increasing in Japan. ARONJ is a disease that possesses both medical and dental aspects that require harmonious and systematic managements by both physicians and dentists. The Allied Committee strongly recommends that the team consisting of medical and dental experts is organized for establishment of preventive and therapeutic approaches for ARONJ.

V. Future perspectives

Despite that more than 10 years have passed since the first report of BRONJ was published, our understanding of the epidemiology and pathophysiology of ARONJ still remains limited. It is almost certain that new anti-resorptive agents with distinct molecular mechanisms of actions and pharmacokinetics from those of currently-available anti-resorptives will emerge and be used for treatment of osteoporosis and bone metastases in the near future, inducing the occurrence of ONJ of different clinical characteristics from BRONJ and DRONJ. To properly control these future situations, identification of risk factors and understanding of pathophysiological mechanisms of ARONJ are mandatory. The most enigmatic issue at present is why the incidence of ARONJ in patients with osteoporosis is only one per 10,000 to

100,000 people per year. If the risk factors listed in Table 2 are associated with the occurrence of ARONJ, the incidence of ARONJ are most likely much higher, suggesting that yet-unknown mechanisms or risk factors contribute to ARONJ. Further, the mechanism of ARONJ that spontaneously occurs in patients receiving anti-resorptives without invasive dental treatments also needs to be uncovered.

Pre-clinical animal models are an essential tool to determine the mechanism of diseases to enable to design mechanism-based therapeutic interventions. Several animal models of ARONJ have been developed over the last several years and have significantly advanced our understanding of the pathophysiology of ARONJ [29-31]. However, these animal models only partially represent the pathologic conditions of human ARONJ and clinical relevance of these animal models is yet far satisfactory. Thus, animal models of ARONJ that more closely resemble human ARONJ need to be established to further advance ARONJ research and treatments. It is also noted that there are many hurdles to overcome to extrapolate the results obtained in animal models to patients.

There are also many challenging issues to be addressed. At cellular levels, our understandings of the effects of anti-resorptives on the differentiation, proliferation and motility of oral epithelial cells that play a critical role in closure of tooth extraction sockets to protect alveolar bone from exposure to oral cavity are poor. Further, responses of immune cells and hematopoietic stem cells in bone marrow that directly or indirectly contribute to bone remodeling to anti-resorptives are also still unclear.

Clinical issues to be addressed include, 1) significance and effects of drug holiday of anti-resorptives with respect to ARONJ prevention, 2) choice and regimen of antibacterial agents for ARONJ prevention, 3) drug resistance induced as a consequence of long-term use of antibacterial agents, 4) development of imaging techniques for better detection of margins of ARONJ lesions to facilitate surgical treatments, 5) definitive criteria for making decisions for conservative, surgical or combined approaches for ARONJ treatment according to the stage

of ARONJ, 6) evidence-based effectiveness of medicinal therapies for ARONJ including teriparatide and other bone-modifying agents, and 7) validation of therapeutic value of hyperbaric oxygen and low-intensity laser.

Recently, necrosis of the external auditory canal associated with the treatment with BPs have been reported, although cases are extremely few [54], The Pharmaceuticals and Medical Devices Agency (PMDA) of Japan lists it as a serious adverse effect and alerts users to those adverse effects.

Patients should not receive any disadvantages during the treatments of osteoporosis, bone metastases and ARONJ due to a lack of communications between physicians and dentists [55]. One reason for increasing occurrence of ARONJ in Japan could be attributable to poor interest and understanding of dental treatments by physicians. In the meantime, dentists must recognize that the incidence for ARONJ is extremely low and anti-resorptives are safe and beneficial drugs for fracture prevention and suppression of bone metastases. Dentists are expected to correctly and accurately know the mechanism of action and indication of anti-resorptives and should not turn down dental treatments of ARONJ patients by unnecessarily and non-scientifically concerning ARONJ occurrence. It is inappropriate to request physicians for modification of therapeutic strategies of osteoporosis during dental treatments. The Allied Committee proposes to establish intimate cooperative environments that allow physicians and dentists to share the epidemiologic, pathophysiologic, diagnostic and therapeutic information of patients to provide the best treatments for patients with ARONJ.

VI. Conclusion

ARONJ, although rarely occurs, is an intractable complication in cancer patients with bone metastases and patients with osteoporosis who are treated with anti-resorptives. Data of ARONJ supported by evidence-based medicine are still poorly accumulated. However, diagnosis and staging of ARONJ, identification of risk factors, and development of preventive

and therapeutic approaches have significantly advanced over the last a decade. In particular, the reports showing that extensive infection control in the oral cavity before invasive dental treatments decreases or prevents occurrence of ARONJ are encouraging for physicians who prescribe anti-resorptives and dentists/oral surgeons who treat ARONJ. For successful treatment of each individual case of ARONJ, the best therapeutic options should be chosen with informed consent under the agreement of a collaborative team of physicians, dentists, oral surgeons and co-medical and -dental staffs who share consolidated information on the patient.

Finally, it should be noted that this Position Paper 2017 describes summaries of bodies of current information on ARONJ available in literature but does not provide proposals supported by evidence-based medicine.

References

1. Marx RE (2003) Pamidronate (Aredia) and zoledronate (Zometa) induced avascular necrosis of the jaws: a growing epidemic. *J Oral Maxillofac Surg* 61:1115-1117
2. Khan AA, Morrison A, Hanley DA, Felsenberg D, McCauley LK, O'Ryan F, Reid IR, Ruggiero SL, Taguchi A, Tetradis S, Watts NB, Brandi ML, Peters E, Guise T, Eastell R, Cheung AM, Morin SN, Masri B, Cooper C, Morgan SL, Obermayer-Pietsch B, Langdahl BL, Al Dabagh R, Davison KS, Kendler DL, Sándor GK, Josse RG, Bhandari M, El Rabbany M, Pierroz DD, Sulimani R, Saunders DP, Brown JP, Compston J; International Task Force on Osteonecrosis of the Jaw (2015) Diagnosis and management of osteonecrosis of the jaw: a systematic review and international consensus. *J Bone Miner Res* 30:3-23
3. Otto S, Tröltzsch M, Jambrovic V, Panya S, Probst F, Ristow O, Ehrenfeld M, Pautke C (2015) Tooth extraction in patients receiving oral or intravenous bisphosphonate administration: A trigger for BRONJ development? *J Craniomaxillofac Surg* 43:847-854
4. Campisi G, Fedele S, Fusco V, Pizzo G, Di Fede O, Bedogni A (2014) Epidemiology, clinical manifestations, risk reduction and treatment strategies of jaw osteonecrosis in cancer patients exposed to antiresorptive agents. *Future Oncol* 10:257-275
5. Baron R, Ferrari S, Russell RG (2011) Denosumab and bisphosphonates: different mechanisms of action and effects. *Bone* 48:677-692
6. Saad F, Brown JE, Van Poznak C, Ibrahim T, Stemmer SM, Stopeck AT, Diel IJ, Takahashi S, Shore N, Henry DH, Barrios CH, Facon T, Senecal F, Fizazi K, Zhou L, Daniels A, Carrière P, Dansey R (2012) Incidence, risk factors, and outcomes of osteonecrosis of the jaw: integrated analysis from three blinded active-controlled phase III trials in cancer patients with bone metastases. *Ann Oncol* 23:1341-1347
7. Hellstein JW, Adler RA, Edwards B, Jacobsen PL, Kalmar JR, Koka S, Migliorati CA, Ristic H; American Dental Association Council on Scientific Affairs Expert Panel on Antiresorptive Agents (2011) Managing the care of patients receiving antiresorptive

- therapy for prevention and treatment of osteoporosis: executive summary of recommendations from the American Dental Association Council on Scientific Affairs. *J Am Dent Assoc* 142:1243-1251
8. Ruggiero SL, Dodson TB, Fantasia J, Goodday R, Aghaloo T, Mehrotra B, O'Ryan F (2014) American Association of Oral and Maxillofacial Surgeons Position Paper on Medication-Related Osteonecrosis of the Jaw-2014 Update. *J Oral Maxillofac Surg* 72:1938-1956
 9. Yoneda T, Hagino H, Sugimoto T, Ota H, Takahashi S, Soen S, Taguchi A, Toyosawa S, Nagata T, Urade M (2010) Bisphosphonate-related osteonecrosis of the jaw: Position paper from the allied task force committee of Japanese Society for Bone and Mineral Research, Osteoporosis Society Japan, Japanese Society of Periodontology, Japanese Society for Oral and Maxillofacial Radiology and Japanese Society of Oral and Maxillofacial Surgeons. *J Bone Miner Metab* 28: 365-383
 10. Hinson AM, Smith CW, Siegel ER, Stack BC Jr (2014) Is bisphosphonate-related osteonecrosis of the jaw an infection? A histological and microbiological ten-year summary. *Int J Dent* 2014:452737
 11. Lipton A, Fizazi K, Stopeck AT, Henry DH, Brown JE, Yardley DA, Richardson GE, Siena S, Maroto P, Clemens M, Bilynsky B, Charu V, Beuzeboc P, Rader M, Viniegra M, Saad F, Ke C, Braun A, Jun S (2012) Superiority of denosumab to zoledronic acid for prevention of skeletal-related events: a combined analysis of 3 pivotal, randomised, phase 3 trials. *Eur J Cancer* 48:3082-3092
 12. Urade M, Tanaka N, Furusawa K, Shimada J, Shibata T, Kirita T, Yamamoto T, Ikebe T, Kitagawa Y, Fukuta J (2011) Nationwide survey for bisphosphonate-related osteonecrosis of the jaws in Japan. *J Oral Maxillofac Surg* 69:e364-e371
 13. Japanese Society of Oral and Maxillofacial Surgeons (2015) Nationwide survey for BRONJ management. (In Japanese)
 14. Fedele S, Porter SR, D'Aiuto F, Aljohani S, Vescovi P, Manfredi M, Arduino PG, Broccoletti R, Musciotto A, Di Fede O, Lazarovici TS, Campisi G, Yarom N (2010) Nonexposed variant

- of bisphosphonate-associated osteonecrosis of the jaw: a case series. *Am J Med* 123:1060-1064
15. Khan A, Morrison A, Cheung A, Hashem W, Compston J (2016) Osteonecrosis of the Jaw (ONJ) diagnosis and management in 2015. *Osteoporos Int* 27:853-859,
 16. Boquete-Castro A, Gómez-Moreno G, Calvo-Guirado JL, Aguilar-Salvatierra A, Delgado-Ruiz RA (2016) Denosumab and osteonecrosis of the jaw. A systematic analysis of events reported in clinical trials. *Clin Oral Implants Res* 27:367-375
 17. Marx RE, Cillo JE Jr, Ulloa JJ (2007) Oral bisphosphonate-induced osteonecrosis: risk factors, prediction of risk using serum CTX testing, prevention, and treatment. *J Oral Maxillofac Surg* 65:2397-2410
 18. Taguchi A, Akiyama H, Koseki T, Shimizutani K (2013) Recognition of bisphosphonate-related osteonecrosis of the jaw among oral and maxillofacial radiologists: results from a questionnaire-based survey in Japan. *Oral Radiol* 29: 98-104
 19. Miyashita H, Shiba H, Kawana H, Nakahara T (2015) Clinical utility of three-dimensional SPECT/CT imaging as a guide for the resection of medication-related osteonecrosis of the jaw. *Int J Oral Maxillofac Surg* 44:1106-1109
 20. Assaf AT, Zrnc TA, Remus CC, Adam G, Zustin J, Heiland M, Friedrich RE, Derlin T (2015) Intraindividual comparison of preoperative (99m)Tc-MDP SPECT/CT and intraoperative and histopathological findings in patients with bisphosphonate- or denosumab-related osteonecrosis of the jaw. *J Craniomaxillofac Surg* 43:1461-1469
 21. Weinstein RS, Roberson PK, Manolagas SC (2009) Giant osteoclast formation and long-term oral bisphosphonate therapy. *N Engl J Med* 360:53-62
 22. Favia G, Pilolli GP, Maiorano E (2009) Histologic and histomorphometric features of bisphosphonate-related osteonecrosis of the jaws: an analysis of 31 cases with confocal laser scanning microscopy. *Bone* 45:406-413
 23. De Ceulaer J, Tacconelli E, Vandecasteele SJ (2014) Actinomyces osteomyelitis in bisphosphonate-related osteonecrosis of the jaw (BRONJ): the missing link? *Eur J Clin Microbiol Infect Dis* 33:1873-1880

24. Matsushita Y, Hayashida S, Morishita K, Sakamoto H, Naruse T, Sakamoto Y, Yamada SI, Yanamoto S, Fujita S, Ikeda T, Umeda M (2016) Denosumab-associated osteonecrosis of the jaw affects osteoclast formation and differentiation: Pathological features of two cases. *Mol Clin Oncol* 4:191-194
25. Holzinger D, Seemann R, Matoni N, Ewers R, Millesi W, Wutzl A (2014) Effect of dental implants on bisphosphonate-related osteonecrosis of the jaws. *J Oral Maxillofac Surg* 72:1937, e1-e8
26. Matsuo A, Hamada H, Takahashi H, Okamoto A, Kaise H, Chikazu D (2016) Evaluation of dental implants as a risk factor for the development of bisphosphonate-related osteonecrosis of the jaw in breast cancer patients. *Odontology* 104:363-371
27. Nakamura T, Ito M, Hashimoto J, Shinomiya K, Asao Y, Katsumata K, Hagino H, Inoue T, Nakano T, Mizunuma H (2015) MOVEST Study Group. Clinical efficacy and safety of monthly oral ibandronate 100 mg versus monthly intravenous ibandronate 1 mg in Japanese patients with primary osteoporosis. *Osteoporos Int* 26:2685-2693
28. Ramírez L, López-Pintor RM, Casañas E, Arriba L, Hernández G (2015) New non-bisphosphonate drugs that produce osteonecrosis of the jaws. *Oral Health Prev Dent* 13:385-393
29. Allen MR (2015) Medication-Related Osteonecrosis of the Jaw: Basic and Translational Science Updates. *Oral Maxillofac Surg Clin North Am* 27:497-508
30. Aghaloo TL, Cheong S, Bezouglaia O, Kostenuik P, Atti E, Dry SM, Piri FQ, Tetradis S (2014) RANKL inhibitors induce osteonecrosis of the jaw in mice with periapical disease. *J Bone Miner Res* 29:843-854
31. de Molon RS, Shimamoto H, Bezouglaia O, Piri FQ, Dry SM, Kostenuik P, Boyce RW, Dwyer D, Aghaloo TL, Tetradis S (2015) OPG-Fc but not zoledronic acid discontinuation reverses osteonecrosis of the jaws (ONJ) in mice. *J Bone Miner Res* 30:1627-1640
32. Taguchi A, Shiraki M, Tsukiyama M, Miyazaki T, Soen S, Ohta H, Nakamura T, Orimo H (2015) Impact of osteonecrosis of the jaw on osteoporosis treatment in Japan: Results of a questionnaire-based survey by the adequate treatment of osteoporosis (A-TOP)

- research group. *Calcif Tissue Int* 97:542-550
33. Taguchi A, Shiraki M, Sugimoto M, Ohta H, Soen S (2016) Lack of cooperation between physicians and dentists during osteoporosis treatment may increase fractures and osteonecrosis of the jaw. *Curr Med Res Opin* 32:1261-1268
 34. Curtis JR, Westfall AO, Cheng H, Dezell E, Saag KG (2008) Risk of hip fracture after bisphosphonate discontinuation: implications for a drug holiday. *Osteoporos Int* 19:1613-1620
 35. Black DM, Rosen CJ (2016) Postmenopausal osteoporosis. *N Engl J Med* 374:254-262
 36. Chiu WY, Chien JY, Yang WS, Juang JM, Lee JJ, Tsai KS (2014) The risk of osteonecrosis of the jaws in Taiwanese osteoporotic patients treated with oral alendronate or raloxifene. *J Clin Endocrinol Metab* 99:2729-2735
 37. Barasch A, Cunha-Cruz J, Curro FA, Hujoel P, Sung AH, Vena D, Voinea-Griffin AE; CONDOR Collaborative Group, Beadnell S, Craig RG, DeRouen T, Desaranayake A, Gilbert A, Gilbert GH, Goldberg K, Hauley R, Hashimoto M, Holmes J, Latzke B, Leroux B, Lindblad A, Richman J, Safford M, Ship J, Thompson VP, Williams OD, Yin W (2011) Risk factors for osteonecrosis of the jaws: a case-control study from the CONDOR dental PBRN. *J Dent Res* 90:439-444
 38. Kim KM, Rhee Y, Kwon YD, Kwon TG, Lee JK, Kim DY (2015) Medication related osteonecrosis of the jaw: 2015 Position statement of the Korean Society for Bone and Mineral Research and the Korean Association of Oral and Maxillofacial Surgeons. *J Bone Metab* 22:151-165
 39. Sugimoto T, Matsumoto T, Hosoi T, Miki T, Gorai I, Yoshikawa H, Tanaka Y, Tanaka S, Fukunaga M, Sone T, Nakano T, Ito M, Matsui S, Yoneda T, Takami H, Watanabe K, Osakabe T, Shiraki M, Nakamura T (2015) Three years of denosumab treatment in Japanese postmenopausal women and men with osteoporosis: Results from a 1-year open-label extension of the denosumab fracture intervention randomized placebo controlled trial (DIRECT). *Osteoporosis Int* 26:765-774
 40. Matsumoto A, Sasaki M, Schmelzeisen R, Oyama Y, Mori Y, Voss PJ. Primary wound

- closure after tooth extraction for prevention of medication-related osteonecrosis of the jaw in patients under denosumab. *Clin Oral Invest* PMID: 26924135. DOI: 10.1007/s00784-016-1762-y
41. Ohga N, Yamazaki Y, Tsuboi K, Kitagawa Y (2015) Healing of osteonecrosis of the jaw (ONJ) after discontinuation of denosumab in a patient with bone metastases of colorectal cancer: a case report and hypothesis. *Quintessence Int* 46:621-626
 42. Guidelines on the prevention and treatment of osteoporosis 2015. The Committee for Development of the Guidelines on the Prevention and Treatment of Osteoporosis. Japan Osteoporosis Society. (In Japanese)
 43. Chahine C, Cheung MS, Head TW, Schwartz S, Glorieux FH, Rauch F (2008) Tooth extraction socket healing in pediatric patients treated with intravenous pamidronate. *J Pediatr* 153:719-720
 44. Maines E, Monti E, Doro F, Morandi G, Cavarzere P, Antoniazzi F (2012) Children and adolescents treated with neridronate for osteogenesis imperfecta show no evidence of any osteonecrosis of the jaw. *J Bone Miner Metab* 30:434-438
 45. Hoyer-Kuhn H, Semler O, Schoenau E (2014) Effect of denosumab on the growing skeleton in osteogenesis imperfecta. *J Clin Endocrinol Metab* 99:3954-3955
 46. Carlson ER (2014) Management of antiresorptive osteonecrosis of the jaws with primary surgical resection. *J Oral Maxillofac Surg* 72:655-657
 47. Bodem JP, Kargus S, Engel M, Hoffmann J, Freudlsperger C (2015) Value of nonsurgical therapeutic management of stage I bisphosphonate-related osteonecrosis of the jaw. *J Craniomaxillofac Surg* 43:1139-1143
 48. Bodem JP, Schaal C, Kargus S, Saure D, Mertens C, Engel M, Hoffmann J, Freudlsperger C (2016) Surgical management of bisphosphonate-related osteonecrosis of the jaw stages II and III. *Oral Surg Oral Med Oral Pathol Oral Radiol* 121:367-372
 49. Ikeda T, Kuraguchi J, Kogashiwa Y, Yokoi H, Satomi T, Kohno N (2015) Successful treatment of bisphosphonate-related osteonecrosis of the jaw (BRONJ) patients with sitafloxacin: new strategies for the treatment of BRONJ. *Bone* 73:217-222

50. Chan HL, McCauley LK (2013) Parathyroid hormone applications in the craniofacial skeleton. *J Dent Res* 92:18-25
51. Ohbayashi Y, Miyake M, Sawai F, Minami Y, Iwasaki A, Matsui Y (2013) Adjunct teriparatide therapy with monitoring of bone turnover markers and bone scintigraphy for bisphosphonate-related osteonecrosis of the jaw. *Oral Surg Oral Med Oral Pathol Oral Radiol* 115:e31-e37
52. Kakehashi H, Ando T, Minamizato T, Nakatani Y, Kawasaki T, Ikeda H, Kuroshima S, Kawakami A, Asahina I (2015) Administration of teriparatide improves the symptoms of advanced bisphosphonate-related osteonecrosis of the jaw: preliminary findings. *Int J Oral Maxillofac Surg* 44:1558-1564
53. Hinson AM, Siegel ER, Stack BC Jr (2015) Temporal correlation between bisphosphonate termination and symptom resolution in osteonecrosis of the jaw: a pooled case report analysis. *J Oral Maxillofac Surg* 73:53-62
54. Thorsteinsson AL, Vestergaard P, Eiken P (2014) External auditory canal and middle ear cholesteatoma and osteonecrosis in bisphosphonate-treated osteoporosis patients: a Danish national register-based cohort study and literature review. *Osteoporos Int* 25:1937-1944
55. Akintoye SO, Hersh EV (2016) Impact of communication between physicians and dentists on the incidence of jaw osteonecrosis caused by bone anti-resorptives. *Curr Med Res Opin* 18:1-2

Legends to Figures

Figure 1: Macroscopic pictures and panorama radiographic images of ARONJ

A: Stage 0: a 62-year-old female. Alendronate was administered for osteoporosis. No teeth were removed, and there was neither bone exposure in the oral cavity, pus discharge nor pain. The patient complained numbness in the right mental region.

B: Stage 1: a 73-year-old breast cancer patient. Denosumab was administered for bone metastases. The right mandibular premolar was extracted without discontinuation of denosumab, resulting in delayed healing. There was bone exposure around tooth extraction socket (arrow), but were no pus discharge and no pain.

C: Stage 2: a 78-year-old male. Ibandronate was administered for osteoporosis. No teeth were removed. There were pain in the right maxillary molar and buccal alveolar bone exposure (arrow, mirror image) associated with right maxillary sinusitis (asterisk).

D: Stage 3: a 68-year-old breast cancer patient. Zoledronic acid and denosumab were administered for bone metastases. No teeth were removed. There were buccal alveolar bone exposure in the maxillary and mandibular molar (arrow) and fistula formation in the submandibular skin. Panoramic image showed mixing of osteosclerosis and osteolysis around left mandibular molar (asterisk), and associated left maxillary sinusitis (arrowhead).

Provided by Dr. Shibahara.

Figure 2: Histopathologic picture of BRONJ in a breast cancer patient treated with BP.

A: Multinucleated large osteoclasts detaching from the bone surfaces.

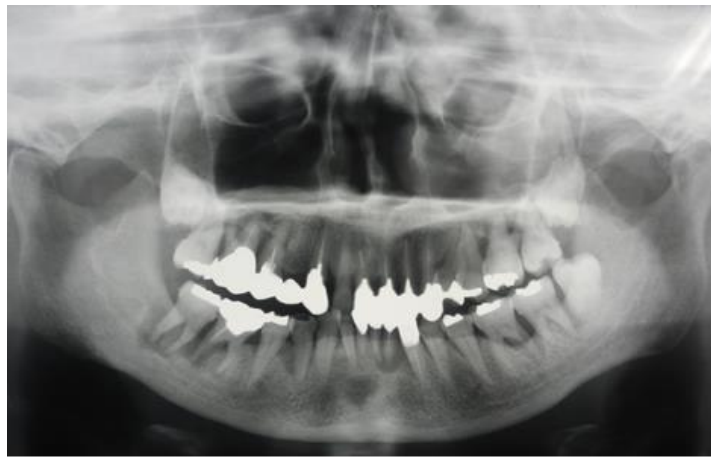B: Necrotic bones showing mosaic pattern lines of bone remodeling and bacterial aggregates attached to necrotic bones (Insert: massive *Actinomyces* growing in ARONJ lesions).

Provided by Dr. Toyosawa.

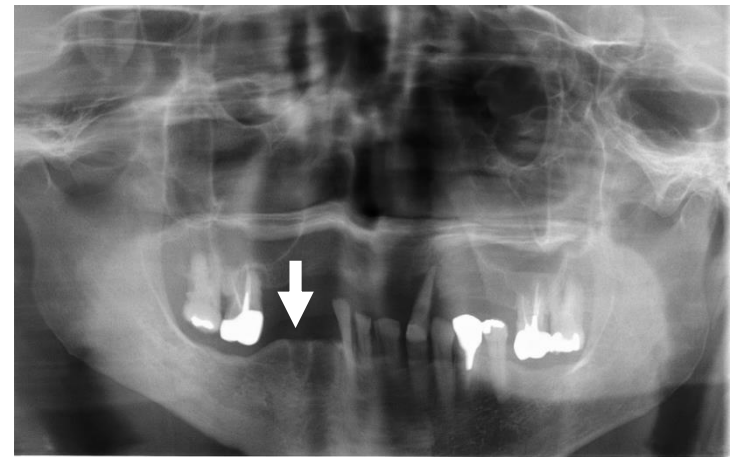
[Contact information: Office of the Japanese Society for Bone and Mineral Research. E-mail
(jsbmr@ac-square.co.jp)]

Figure 1

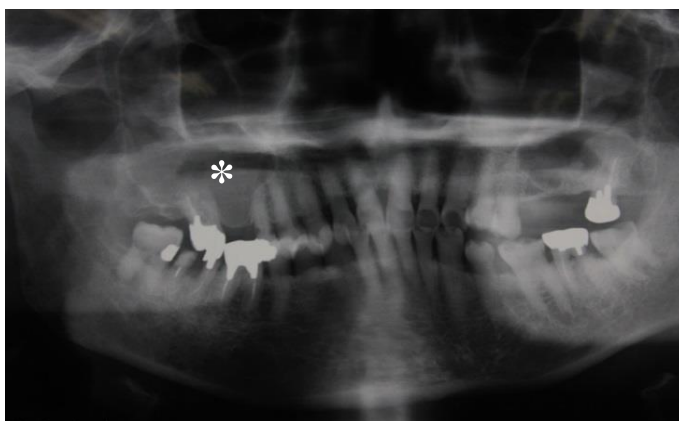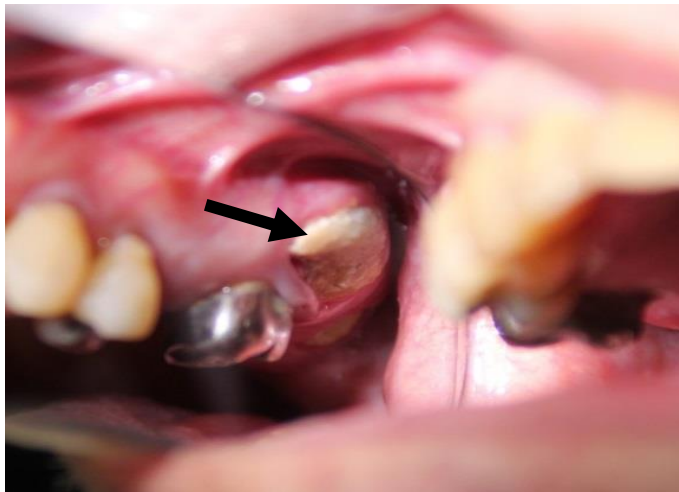
A



B



C



D

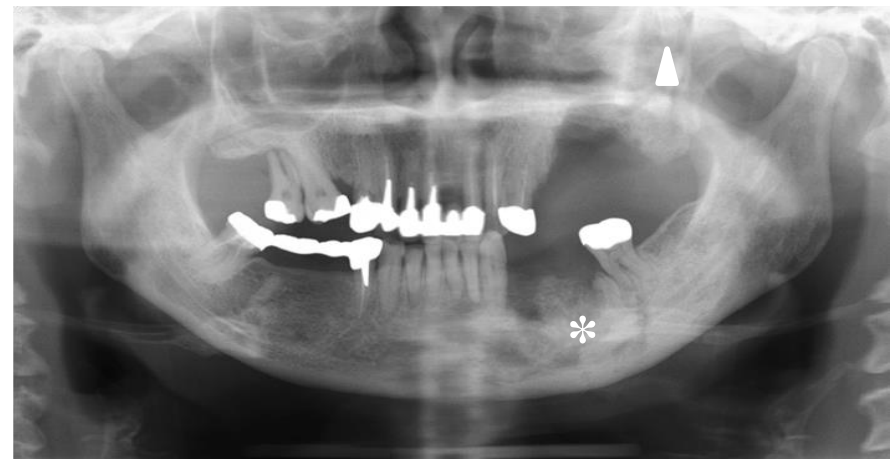
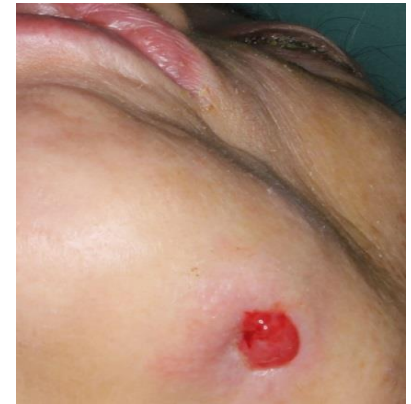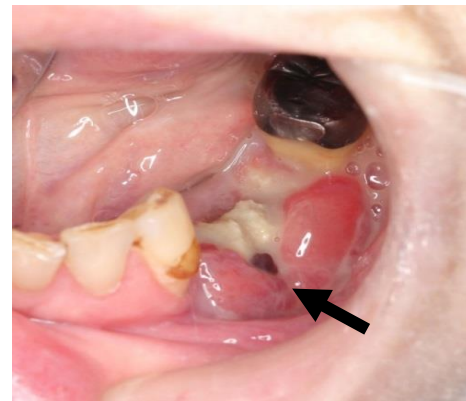


Figure 2

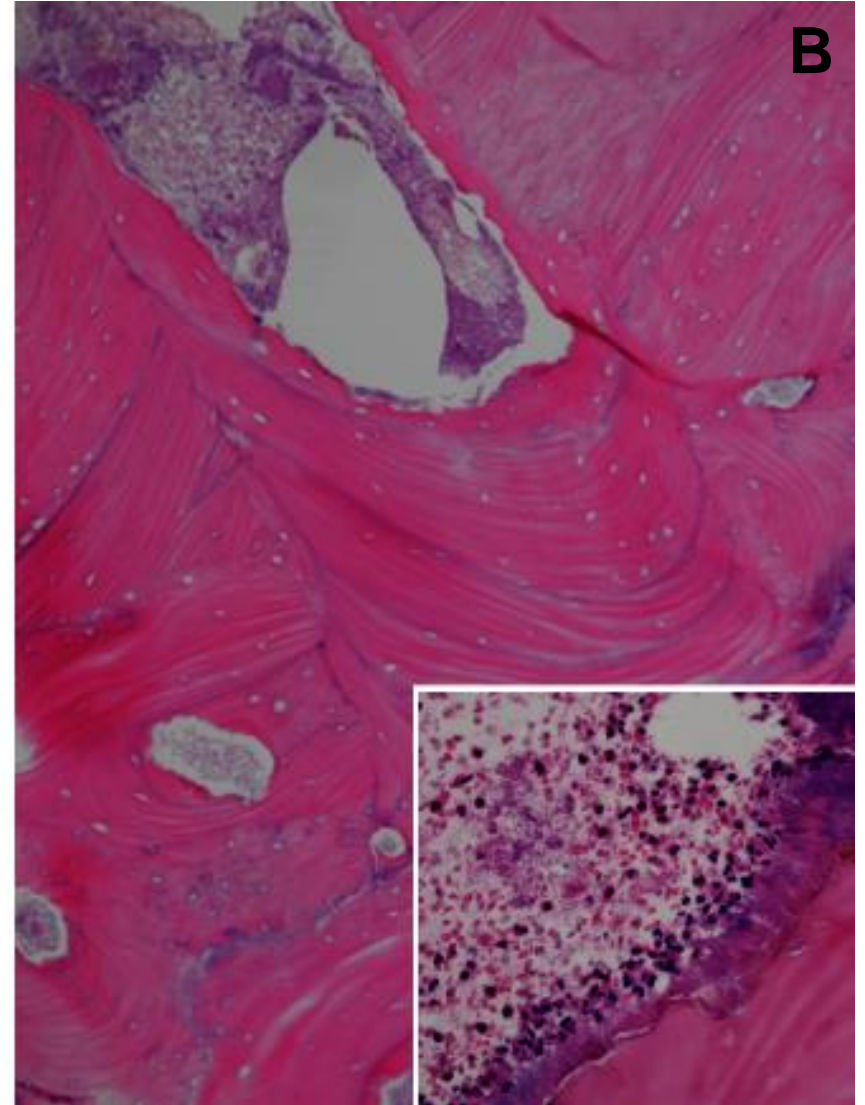
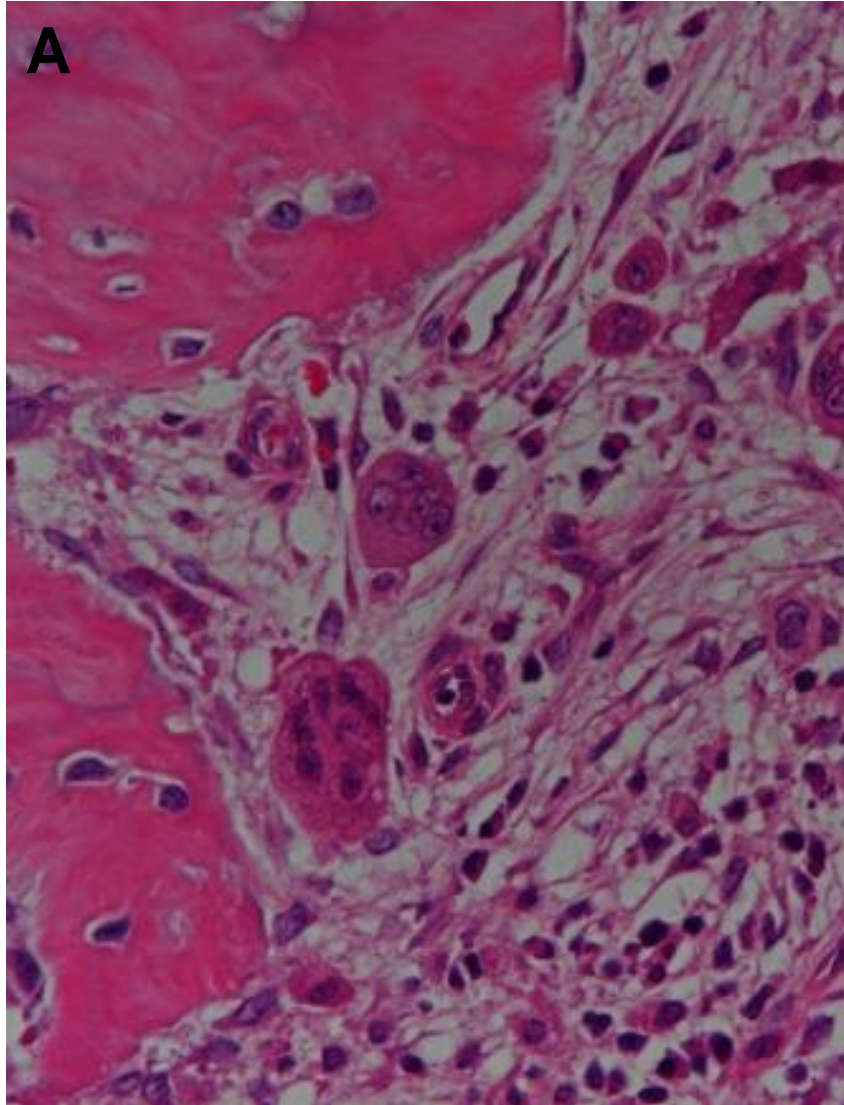


Table 1 Stage of ARONJ: Clinical symptoms and imaging findings

Stage 0*	Clinical symptoms: no bone exposure/necrosis, deep periodontal pocket, loose tooth, oral mucosal ulcer, swelling, abscess formation, trismus, hypoesthesia/numbness of the lower lip (Vincent's symptom), non-odontogenic pain Imaging findings: Sclerotic alveolar bone, thickening and sclerosis of lamina dura, remaining tooth extraction socket
Stage 1	Clinical symptoms: asymptomatic bone exposure/necrosis without sign of infection, or fistula in which the bone is palpable with a probe Imaging findings: Sclerotic alveolar bone, thickening and sclerosis of lamina dura, remaining tooth extraction socket
Stage 2	Clinical symptoms: bone exposure/necrosis with infection, or fistula in which the bone is palpable with a probe. Pain in the bone-exposed site associated with redness with/without pus discharge Imaging findings: image mixing diffuse osteosclerosis and osteolysis from the alveolar bone to jaw bone, thickening of the mandibular canal, periosteal response, maxillary sinusitis, and sequestration
Stage 3	Clinical symptoms: bone exposure/necrosis associated with pain, infection or at least one of the following symptoms, or fistula in which bone is palpable with a probe. Bone exposure/necrosis over the alveolar bone (e.g. reaching the mandibular inferior edge or mandibular ramus, or reaching the maxillary sinus or mandibular ramus or the cheek bone). As a result, pathologic fracture or extraoral fistula, nasal/maxillary sinus fistula formation, or advanced osteolysis extending to the mandibular inferior edge or maxillary sinus. Imaging findings: osteosclerosis/osteolysis to the surrounding bone (cheek bone, palatine bone), pathologic mandibular fracture, and osteolysis extending to the maxillary sinus floor

Note: Care should be taken to avoid overdiagnosis because half of Stage 0 ARONJ cases do not progress to ONJ [14].

Table 2. Risk factors for ARONJ

1. Local

- Invasive dental treatments including bone (e.g. tooth extraction, dental implants, apical/periodontal surgery)
- Ill-fitting denture and excessive bite force
- Poor sanitation in the oral cavity, periodontal disease and gingival abscess inflammatory disease, including apical periodontitis
- Common site: mandible > maxilla, mandibular torus, palatal torus, and mylohyoid line torus
- Root canal and orthodontic treatments are not considered to be risk factors.

2. Anti-resorptive agents

- Nitrogen-containing bisphosphonates (BPs) > Non nitrogen-containing bisphosphonates (BPs)
 - Nitrogen-containing BPs: zoledronate (Zometa), alendronate (Teiroc, Fosamac, Bonalon), risedronate sodium (Actonel, Benet), pamidronate (Aredia), incadronate (Bisphonal), minodronate (Bonoteo, Recalbon), ibandronate (Bonviva)
 - Non nitrogen-containing BPs: etidronate (Didronel)
- Denosumab (Ranmark, malignant tumor) (Pralia, osteoporosis)
- Drugs for malignant tumor > Drugs for osteoporosis
 - Drugs for malignant tumor: (Zometa, Aredia, Teiroc, Ranmark)
 - Drugs for osteoporosis (Didronel, Fosamac, Bonalon, Actonel, Benet, Bonoteo, Recalbon, Bonviva and Pralia)
- Dose and administration period

(Trade names are given in parentheses. For generic drugs, refer individual agent)

3. Systemic

- Cancer (breast, prostate, lung, renal and colon cancer, multiple myeloma, and other cancers)
- Diabetes, rheumatoid arthritis, hypocalcemia, hypoparathyroidism, osteomalacia, vitamin D deficiency, renal dialysis, anemia, and Paget's disease of bone

4. Congenital

- SNPs in MMP-2 and cytochrome P450-2C genes

5. Lifestyle

- Smoking, drinking and obesity

6. Co-administered agents

- Anticancer agents, corticosteroids and erythropoietin
- Angiogenic inhibitors (e.g. thalidomide, sunitinib, bevacizumab, and lenalidomide)
- Tyrosine kinase inhibitors

Note: These factors are proposed to be risk factors for ARONJ but no evidence is demonstrated.

Table 3. Treatment of ARONJ

Stage 0 and Stage 1	Use of anti-microbial mouthwash, rinsing and cleaning of fistula and periodontal pocket, and topical application or injection of local anti-microbial agents
Stage 2	Combination of anti-microbial mouthwash and agents; intractable case: combination of multiple anti-microbial agents, long-term anti-microbial administration, continuous administration of intravenous anti-microbial agents, removal of sequestra, curettage of necrotic bones and osteotomy
Stage 3	Removal of sequestra, curettage of necrotic bones, osteotomy, extraction of tooth in exposed bone/necrotic bone as source of infection, maintenance of nutrition with supplements and infusions, and marginal or segmental resection of expanding necrotic bones

Note: Isolated sequestra are removed without exposing bones outside lesions, regardless of disease stage. A tooth with symptoms in exposed necrotic bones is extracted, extraction itself unlikely exacerbates the necrosis.