

# Portal Hypertension and Ascites Due to an Arterioportal Fistula: Sequela of a Remote Traumatic Liver Laceration

Benjamin M. Hulkower, MD<sup>1</sup>, Sabah Butty, MD<sup>2</sup>, and Marwan Ghabril, MD<sup>3</sup>

<sup>1</sup>Departments of Internal Medicine and Pediatrics, Indiana University School of Medicine, Indianapolis, IN

<sup>2</sup>Department of Interventional Radiology, Indiana University School of Medicine, Indianapolis, IN

<sup>3</sup>Department of Gastroenterology and Hepatology, Indiana University School of Medicine, Indianapolis, IN

## ABSTRACT

Arterioportal fistulas (APFs) are a group of vascular disorders, in which systemic arteries communicate with the portal circulation, presenting as a congenital syndrome or more commonly acquired from iatrogenic instrumentation or abdominal trauma. We report the case of a 58-year-old man who developed ascites without underlying risk factors for portal hypertension, which was attributed to an APF found on imaging, manifesting 43 years after sustaining a liver laceration. After angiographic embolization of the APF, the patient's ascites resolved completely. The prolonged latent period between the patient's abdominal trauma and eventual presentation with ascites highlights the need to consider vascular malformations in the differential diagnosis of unexplained noncirrhotic portal hypertension.

## INTRODUCTION

Arterioportal fistulas (APFs) are a rare group of vascular disorders, in which systemic arteries communicate with the portal circulation. Arterioportal fistulas can be congenital, resulting from diseases with telangiectatic vessels, arteriovenous malformations, or aneurysms, or they can be acquired. The latter typically result from iatrogenic fistulization secondary to instrumentation, blunt or penetrating abdominal trauma, and rarely from hepatocellular malignant neoplasia.<sup>1-3</sup> If symptomatic, depending on the location and volume of shunted blood, they can manifest clinically as diarrhea, intestinal ischemia, cirrhosis, cavernous hemangiomas, or with symptoms of portal hypertension such as gastrointestinal bleeding or ascites. In the absence of underlying liver disease, liver function tests are typically normal at presentation.<sup>3</sup>

## CASE REPORT

A 58-year-old man was transferred to our institution following admission at an outside facility for further workup and management of unexplained ascites. On initial presentation, he reported experiencing 2 months of progressive abdominal distention and mild diffuse abdominal discomfort, accompanied by nausea, fatigue, myalgia, and cold extremities over the same 2-month period. He denied confusion, weight loss, or symptoms of gastrointestinal bleeding. His medical history was significant for urethral stricture with a prior corrective urologic procedure as a child, and his surgical history was notable for remote tonsillectomy. He denied taking any medications prior to evaluation for his abdominal distention, and he also denied a family history of liver disease or consumption of alcohol, tobacco, or illicit substances.

Physical exam findings were remarkable for abdominal distention with shifting dullness, but absence of hepatosplenomegaly, asterixis, or telangiectasia. Laboratory tests revealed a platelet count of 260/ $\mu$ L; international normalized ratio, 1.28; alkaline phosphatase 78 U/L; alanine aminotransferase, 90 U/L; aspartate aminotransferase, 53 U/L;

ACG Case Rep J 2016;3(4):e121. doi:10.14309/crj.2016.94. Published online: September 14, 2016.

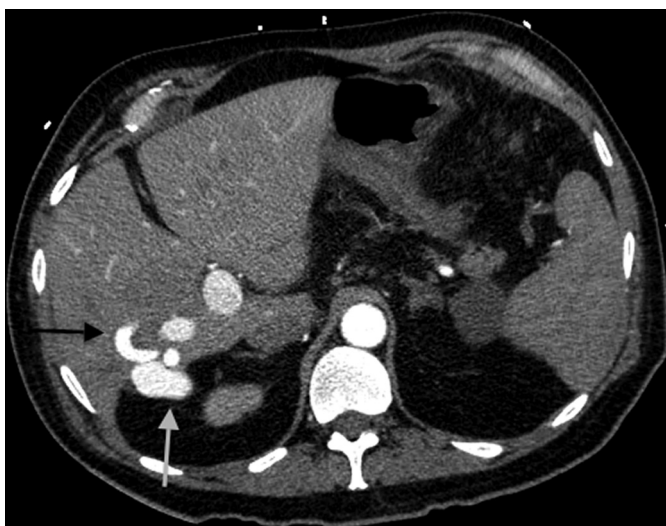**Correspondence:** Marwan Ghabril, MD, Division of Gastroenterology and Hepatology, Indiana University School of Medicine, 702 Rotary Cir, Suite 225, Indianapolis, IN 46202 (mghabril@iu.edu).



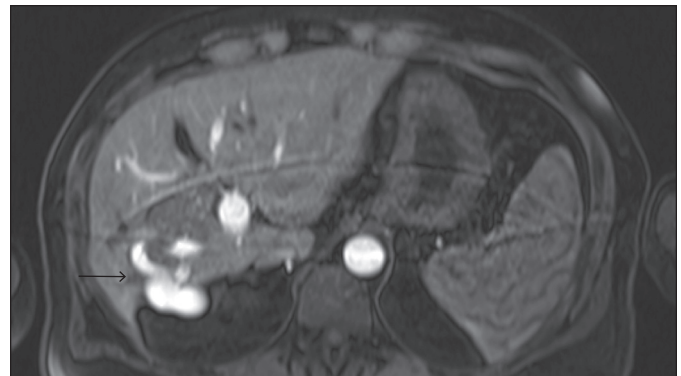Copyright: © 2016 Hulkower et al. This work is licensed under a Creative Commons Attribution-NonCommercial-NoDerivatives 4.0 International License. To view a copy of this license, visit <http://creativecommons.org/licenses/by-nc-nd/4.0>.

total bilirubin 1.0 mg/dL; and albumin 3.1 g/dL. Laboratory testing for causes of chronic liver disease was nondiagnostic, including viral hepatitis serology, iron studies, ferritin level, ceruloplasmin level, serum protein electrophoresis, and titers for antinuclear and antismooth muscle and antimitochondrial antibodies. Diagnostic paracentesis revealed a clear fluid with total protein of 1.2 g/L, albumin of <1 g/L, and a serum to ascites albumin gradient of >2.1 g/L, with no evidence of peritonitis by cell counts or culture. Fluid cytology revealed reactive mesothelial cells and mixed inflammatory cells. Initial imaging included an abdominal ultrasound with Doppler, demonstrating a normal appearing liver with patent vasculature but intermittent flow reversal in the portal system. A venous-phase abdominal computerized tomography (CT) without and with intravenous contrast was normal. A liver biopsy was also performed and showed preserved parenchymal architecture with focal macrovesicular steatosis involving less than 1% of hepatic parenchyma and no inflammatory infiltrate. He underwent upper endoscopy and was found to have small non-bleeding esophageal varices.

During his admission, he developed dyspnea and subsequently underwent arterial-phase chest CT to rule out a pulmonary embolus. The unexplained dyspnea resolved quickly and spontaneously, and the CT revealed no acute pulmonary process. However, it incidentally demonstrated a large enhancing vascular structure in the posterior aspect of the right hepatic lobe as well as atrophy of the right hepatic lobe (Figure 1). Based on this finding, an arteriovenous malformation was suspected as the etiology of his portal hypertension. Abdominal magnetic resonance angiography demonstrated an APF involving the right hepatic artery, segment 7, to the



**Figure 1.** Enhanced CT of the chest remarkable for the presence of an abnormally hypertrophied segment 7 artery (black arrow) with arterialization of the portal venous system (white arrow), suggestive of an arterial venous fistula.



**Figure 2.** T1-weighted axial volumetric interpolated breath-hold examination arterial-phase magnetic resonance image demonstrating the arterial venous fistula (arrow).

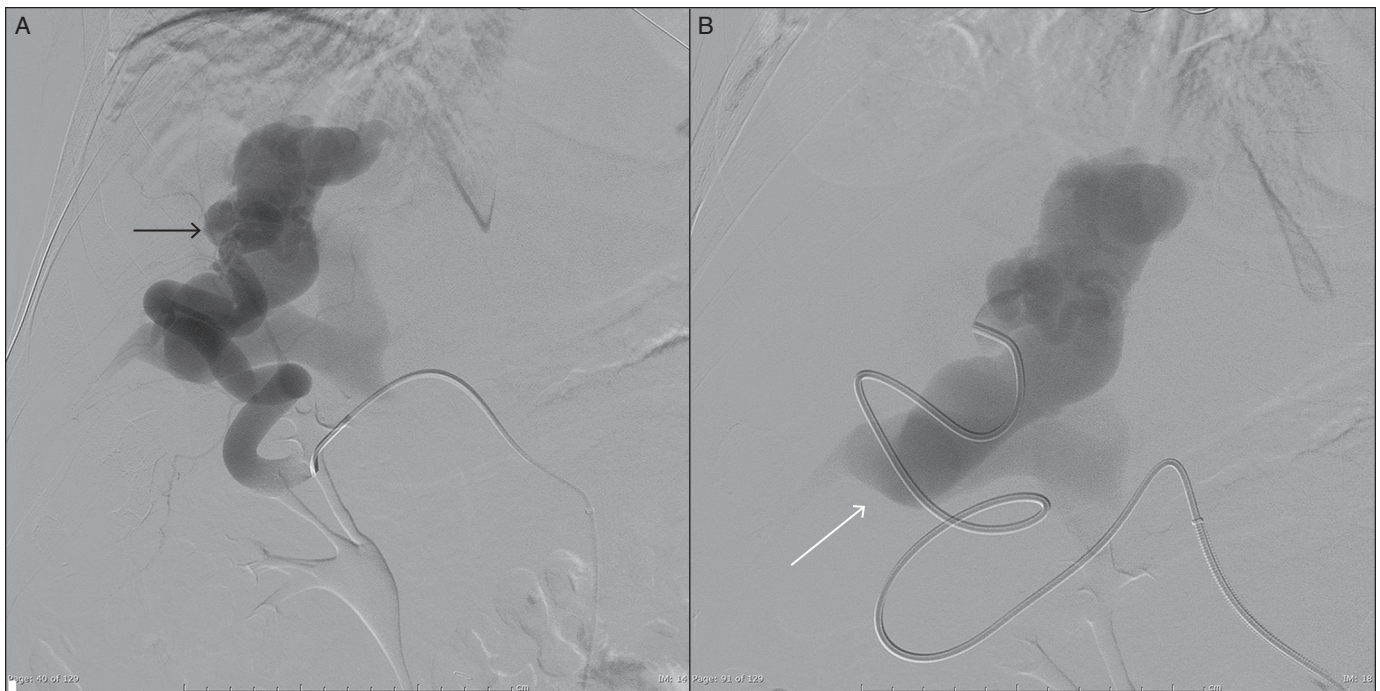
right portal vein with near-complete atrophy of the right hepatic lobe (Figure 2). After further discussion with the patient, he recalled sustaining a liver laceration from blunt abdominal trauma at the age of 15, which was deemed the likely etiology of the vascular malformation.

After the diagnosis was established, the patient underwent angiography with confirmation of hepatic artery, segment 7 APF (Figure 3), followed by coil embolization of the distal right hepatic artery fistula, with only limited residual filling defect of the APF (Figure 4).

Over the next 2 days of hospitalization, our patient noted significant improvement in abdominal discomfort, distention, and nausea, with complete resolution of ascites within 4-5 days of embolization. After embolization, repeat liver function tests normalized with alanine aminotransferase, 26 U/L; aspartate aminotransferase, 19 U/L; and albumin 3.6 g/dL prior to discharge. He had sustained clinical resolution up to 5 years of clinical follow-up, including resolution of varices on subsequent endoscopy.

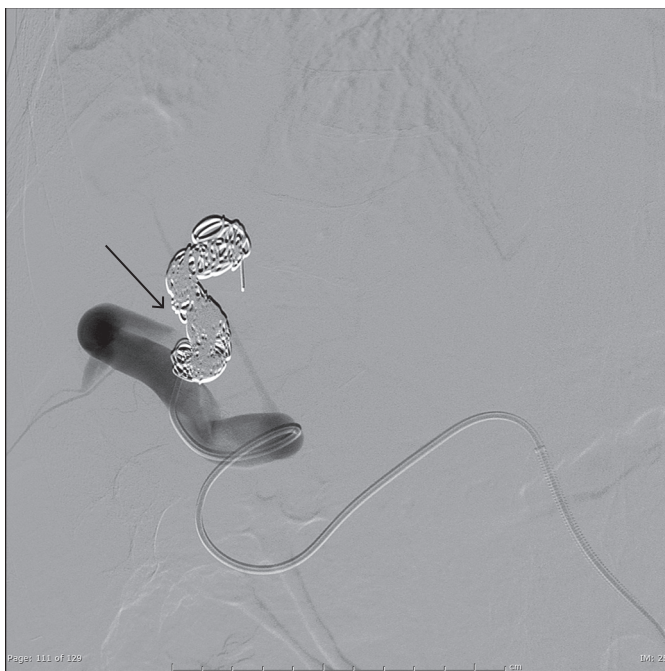
## DISCUSSION

In this patient with unexplained ascites without a known congenital vascular malformation syndrome, history of intraabdominal surgery, or underlying liver disease, we presume that the etiology of the APF was related to the remote liver laceration. While the approach to intervention depends on the underlying cause and location of the fistula, surgical treatment has largely given way to radiological intervention with several case reports demonstrating complete and sustained resolution of the symptoms of acquired APF after coil embolization, as was the case with our patient.<sup>4,5</sup> The prolonged period between the history of abdominal trauma and eventual presentation of ascites 43 years later is a striking characteristic of this case. It highlights the need to consider vascular malformations as a potential cause of otherwise unexplained noncirrhotic



**Figure 3.** (A) Angiogram demonstrating the presence of a large complex arterial venous fistula (black arrow) resulting in (B) hypertrophy of the portal vein (white arrow), suggestive of secondary portal venous hypertension.

portal hypertension. Finally, it underscores the importance of obtaining both arterial and venous phases in cross-sectional imaging of the abdomen in the course of investigation for this presentation.



**Figure 4.** Postembolization angiogram resulting in occlusion of the hepatic segment 7 arterial portal fistula (arrow).

## DISCLOSURES

Author Contributions: BM Hulkower wrote the manuscript. S. Butty reviewed and edited the manuscript. M. Ghabril reviewed and edited the manuscript and is the article guarantor.

Financial disclosure: None to report.

Informed consent was obtained for this case report.

Received November 30, 2015; Accepted March 16, 2016

## REFERENCES

1. Wolf S, Berger H, Jauch KW. Arterioportal fistula with portal hypertension after liver trauma and resection: A case report and review of the literature. *Hepatogastroenterology*. 1998;45(21):821-6.
2. Kirchgatterer A, Baldinger C, Lenglinger F, et al. Portal hypertension due to traumatic hepatic arterioportal fistula: Report of successful embolization. *Eur J Gastroenterol Hepatol*. 1998;10(12):1057-9.
3. Vauthey JN, Tomczak RJ, Helmberger T, et al. The arterioportal fistula syndrome: Clinicopathologic features, diagnosis, and therapy. *Gastroenterology*. 1997;113(4):1390-401.
4. Ishigami K, Yoshimitsu K, Honda H, et al. Coil embolization of arterioportal fistula that developed after partial gastrectomy. *Cardiovasc Intervent Radiol*. 1999;22(4):328-30.
5. Taourel P, Perney P, Bouvier Y, et al. Angiographic embolization of intrahepatic arterioportal fistula. *Eur Radiol*. 1996;6(4):510-3.