

Washington University School of Medicine Digital Commons@Becker

Open Access Publications

2017

Nothing but NET: A review of neuroendocrine tumors and carcinomas

Bryan Oronsky

EpicentRX Inc.

Patrick C. Ma

West Virginia University

Daniel Morgensztern

Washington University School of Medicine in St. Louis

Corey A. Carter

Walter Reed National Military Medical Center

Follow this and additional works at: https://digitalcommons.wustl.edu/open_access_pubs

Recommended Citation

Oronsky, Bryan; Ma, Patrick C.; Morgensztern, Daniel; and Carter, Corey A., "Nothing but NET: A review of neuroendocrine tumors and carcinomas." *Neoplasia*. 19, 12. 991-1002. (2017).

https://digitalcommons.wustl.edu/open_access_pubs/6314

This Open Access Publication is brought to you for free and open access by Digital Commons@Becker. It has been accepted for inclusion in Open Access Publications by an authorized administrator of Digital Commons@Becker. For more information, please contact engeszer@wustl.edu.

Nothing But NET: A Review of Neuroendocrine Tumors and Carcinomas

Bryan Oronsky^{*}, Patrick C. Ma[†], Daniel Morgensztern[‡] and Corey A. Carter[§]

^{*}EpicentRx Inc, 4445 Eastgate Mall, Suite 200, San Diego, CA 92121, USA; [†]West Virginia University, Mary Babb Randolph Cancer Center, 8901 Wisconsin Ave., PO Box 9162, Morgantown, WV 26506, USA; [‡]Washington University School of Medicine, Division of Oncology, 660 S. Euclid, Box 8056, St. Louis, MO 63110, USA; [§]Walter Reed National Military Medical Center, 8901 Wisconsin Ave., Bethesda, MD 20889, USA

Abstract

This review covers the diverse topic of neuroendocrine neoplasms (NENs), a relatively rare and heterogeneous tumor type, comprising ~2% of all malignancies, with a prevalence of <200,000 in the United States, which makes it an orphan disease (Basu et al., 2010).¹ For functional purposes, NENs are divided into two groups on the basis of clinical behavior, histology, and proliferation rate: well differentiated (low grade to intermediate grade) neuroendocrine tumors and poorly differentiated (high grade) neuroendocrine carcinoma (Bosman et al., 2010)²; this histological categorization/dichotomization is highly clinically relevant with respect to impact on treatment and prognosis even though it is not absolute since a subset of tumors with a low-grade appearance behaves similarly to high-grade lesions. Given the relative dearth of evidenced-based literature about this orphan disease as a whole (Modlin et al., 2008),³ since the focus of most articles is on particular anatomic subtypes of NENs (i.e., gastroenteropancreatic or pulmonary), the purpose of this review is to summarize the presentation, pathophysiology, staging, current standard of care treatments, and active areas of current research.

Neoplasia (2017) 19, 991–1002

Introduction

Neuroendocrine neoplasms (NENs) are a heterogeneous group of malignancies with a varied, confusing histology and nomenclature to match. The term “neuroendocrine” is applied to widely dispersed cells with “neuro” and “endocrine” properties.¹ The “neuro” property is based on the identification of dense core granules (DCGs⁴) that are similar to DCGs present in serotonergic neurons, which store monoamines. (Unlike neurons, however, NE cells do not contain synapses.) The “endocrine” property refers to the synthesis and secretion of these monoamines.⁵ The neuroendocrine (NE) system includes endocrine glands, such as the pituitary, the parathyroids, and the NE adrenal, as well as endocrine islet tissue embedded within glandular tissue (thyroid or pancreatic) and scattered cells in the exocrine parenchyma, such as endocrine cells of the digestive and respiratory tracts, which belong to what is known as the diffuse endocrine system.⁵ Historically, well-differentiated NENs are referred to as carcinoid tumors, a term that has led to errors in communication and confusion, as discussed below.

Given the body-wide distribution of NE cells, NENs have been described in the central nervous system, respiratory tract, the larynx, gastrointestinal (GI) tract, thyroid, skin, breast, and urogenital system.³ The GI tract and lungs are the most common primary tumor sites.⁶

In current practice, based on clinical behavior, histology, and proliferation rate, NENs are generally categorized, similar to lymphomas², as low-grade indolent tumors versus high-grade aggressive carcinomas²; this dichotomization is highly relevant for prognosis and treatment choice.⁷ The indolent tumors, befitting the “indolent” descriptor, tend to

Address all correspondence to: Dr. Bryan Oronsky, EpicentRx, Inc., 4445 Eastgate Mall, Suite 200, San Diego, CA 92121.

E-mail: boronsky@epicentrx.com

Received 9 August 2017; Revised 6 September 2017; Accepted 7 September 2017

© 2017 The Authors. Published by Elsevier Inc. on behalf of Neoplasia Press, Inc. This is an open access article under the CC BY-NC-ND license (<http://creativecommons.org/licenses/by-nc-nd/4.0/>).

1476-5586

<https://doi.org/10.1016/j.neo.2017.09.002>

follow a prolonged clinical course with a low risk of distant metastases even in the absence of treatment, whereas the aggressive carcinomas, closely related to pulmonary small-cell carcinoma, are associated with rapid progression and poor long-term prognosis.⁸ However, an important point, emphasized in the review, is that this low-grade/high-grade dichotomization is not absolute since some histologic low-grade tumors may behave more like advanced progressive carcinomas⁹ that require systemic treatment with cytotoxic chemotherapy. Paradoxically, the rapidly dividing cells of high-grade aggressive carcinomas are potentially eradicable with multiagent chemotherapy, while the slow mitotic rate of the indolent lymphomas generally makes them resistant to treatment.¹⁰

The clinical rule of thumb (with exceptions) is that low-grade tumors are managed with surgical resection¹¹ while unresectable and symptomatic disease is treated with somatostatin analogs and/or interferon- α even though tumor regression with these agents is rare.¹² In contrast, etoposide/platinum-based chemotherapy is the mainstay of treatment for high-grade or metastatic neuroendocrine carcinomas (NECs)¹³; however, other agents and modalities are under active investigation. They include targeted agents like sunitinib and everolimus and the experimental epi-immunologic agent, RRx-001, as well as evolving modalities like peptide receptor targeted therapies and radioembolization. This review covers the presentation, pathophysiology, staging, current standard of care treatments, and active areas of current research for neuroendocrine tumors (NETs) and carcinomas.

Epidemiology

NETs account for about 0.5% of all newly diagnosed malignancies.¹⁴ The incidence, which is on the rise, possibly due to improved awareness, is approximately 5.86/100,000 per year¹⁴ with a female preponderance of around 2.5:1.¹⁵ The prevalence, which is estimated at 103,312 cases in the United States,¹⁶ meets criteria for orphan disease status^{3,17}: <200,000 for the whole population of the United States.¹⁸

The most frequent primary sites are the gastrointestinal tract (62%-67%) and the lung (22%-27%). Twelve percent to 22% of patients are metastatic at presentation.¹⁴ The majority of NENs arise sporadically, but association with the multiple endocrine neoplasia type 1 syndrome and familial clustering is recognized.¹⁴ Smoking or alcohol consumption does not appear to increase the risk of NENs.¹⁴ GI NETs are more common in African Americans than whites,¹⁹ while bronchial carcinoids predominantly affect Caucasians.²⁰

Rare diseases, like NETs, are sometimes classified as “zebras” on the basis of the aphorism “when you hear hoofbeats think horses not zebras” frequently invoked on the wards as a reminder or, more likely, a rebuke to the overzealous medical student that common diseases occur commonly while rare diseases or “zebras” occur rarely. Accordingly, perhaps in somewhat meta-ironic reference to this esoteric clinical aphorism (meta-ironic because, outside of the medical circle, presumably few have knowledge of this statement on and about rarity), the zebra has been adopted as the symbol for neuroendocrine awareness.

Histology

Well-differentiated NET cells, which produce abundant secretory granules with intense immunoreactivity of neuroendocrine markers such as chromogranin A (CgA) and synaptophysin (Syn), are characteristically arranged in a well-developed “organoid” or neuroendocrine shape with nesting, trabecular, or gyriform/serpentine growth patterns.²¹ The tumor cells are small with relatively uniform round to oval nuclei, inconspicuous nucleoli, and a fine to coarsely granular chromatin pattern often described as “salt and pepper”.²²

In contrast, NECs demonstrate a solid “sheetlike” proliferation of tumor cells with irregular nuclei, high mitotic features, and less cytoplasmic secretory granules.²¹ Immunocytochemical staining patterns for neuroendocrine markers are more limited (diffuse expression of Syn, faint or focal staining for CgA).²² Up to 40% of NECs contain elements of non-neuroendocrine histology; by definition, the neuroendocrine component has to exceed 30% for the tumor to be called an NEC; otherwise, it is classified as a mixed adenoneuroendocrine carcinoma.²³

Terminology and Classification

Confusion and obfuscation have surrounded the terminology of NETs ever since the pathologist Siegfried Oberndorfer invented the word carcinoid at the turn of the 20th century to mean “carcinoma-like”²⁴; the description was in reference to the benign behavior of morphologically atypical small bowel tumors²⁵ composed of argentaffin-positive and argyrophilic cells, so-called because they take up and reduce silver salts.

The word carcinoid has been criticized²⁶ 1) as an imprecise, generic, “non-user friendly” and obsolete “catch all”²⁷ that lumps together different tumors distinct in their etiology, prognosis, and management, leading to terminological confusion and diagnostic unreliability, and 2) as a straight misnomer²⁸ because despite the presence of innocuous-appearing cells with uniform nuclei and few mitoses, these tumors, to different degrees, behave malignantly (not benignly as Oberndorfer mistakenly assumed) with metastasis, local invasion, and recurrence after resection. The persistence of the term carcinoid and the confusion (and contention) surrounding its usage may be related to the lack of consensus and homogeneity with regard to taxonomy, terminology, and definitions of these loosely related tumors, especially in the GI and respiratory tracts, as detailed below; the semantic issues are magnified by the use of an alphabet soup of acronyms and a plethora of terms synonymous with carcinoid including APUDoma, argentaffinoma, enteroendocrine, tumors of the diffuse endocrine system, endocrine tumor, and argyrophilic cell carcinoma.²⁹

In 1928, Gosset and Masson characterized carcinoids as NETs on the basis of amine uptake and decarboxylation properties.³⁰

In 1963, Williams and Sandler classified carcinoids according to the embryonic divisions of the digestive tract, that is, foregut, (bronchopulmonary, stomach, duodenum, biliary, and pancreas), midgut (jejunum, ileum, appendix, and proximal colon), and hindgut (distal colon and rectum)²⁷ (Figure 1).

In 1972, Arrigoni et al. characterized a histologic variant of typical carcinoid tumor composed of large polymorphic nucleolated cells in gland-like arrangement as “atypical carcinoid.”³¹

In 1980, the World Health Organization (WHO)³² applied the term carcinoid to describe all NETs except pulmonary neuroendocrine tumors (pNETs), identified as a separate entity. However, this WHO classification only managed to sow more terminological confusion since pathologists, accordingly, applied the word carcinoid to all tumors of the endocrine system, while clinicians in general conflated it with the presence of carcinoid syndrome,³³ a constellation³⁴ of cutaneous and systemic signs and symptoms including flushing, diarrhea, and bronchospasm associated with the hypersecretion of vasoactive amines (e.g., serotonin and histamine) by the carcinoid tumor.

In 1999, the Travis-WHO classification³⁵ divided the spectrum of pulmonary and thymic NE tumors into four subtypes characterized by increasing aggressiveness: typical carcinoid tumors with a low

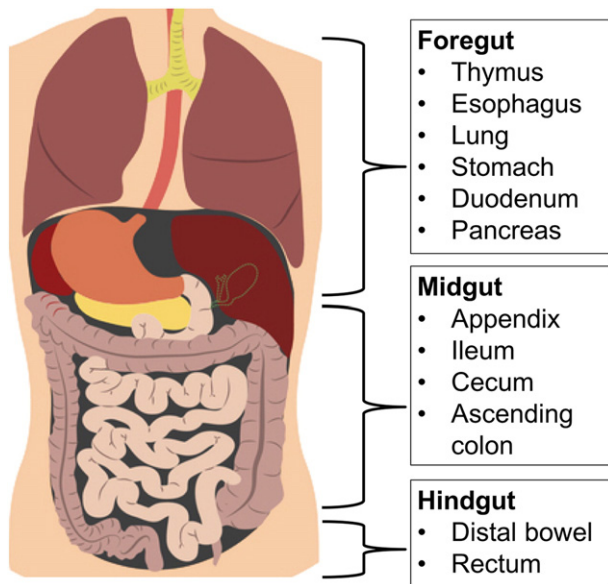


Figure 1. NETs may be divided by site of origin: foregut, midgut, and hindgut.

grade and long life expectancy, atypical carcinoid tumor with an intermediate differentiation and a more aggressive clinical course, and large-cell neuroendocrine carcinoma (LCNEC) and small-cell lung carcinoma (SCLC) with a high grade and a dismal prognosis.³⁶

In 2000, WHO prepared a revised gastroenteropancreatic (GEP) classification that eschewed the term carcinoid in favor of NET and identified three histologic categories irrespective of the site of origin³⁷:

- Well-differentiated neuroendocrine tumor with probably benign behavior
- Well-differentiated neuroendocrine tumor with uncertain behavior
- Poorly differentiated neuroendocrine carcinoma with high-grade malignant behavior

In 2004, the WHO divided neoplasms of the lung and thymus into three grades based on mitotic index and necrosis (Table 1).³⁸

Grade 3 NECs predict the development of metastatic dissemination even in tumors that are initially clinically localized. The GEP tract is the most common site for extrapulmonary NEC, accounting for 35% to 55% of all NECs outside the lung.³⁹

In 2010, the latest version of the WHO classification appeared, which redefined the entire group of tumors as NENs. GI NENs were subdivided according to their mitotic count or Ki67 index, associated with cellular proliferation (Table 2).

In 2015, the National Comprehensive Cancer Network (NCCN) recommended the inclusion of tumor differentiation, mitotic rate, and Ki-67 in the pathology report with specification of the particular classification and grading scheme to avoid confusion.⁴⁰

In line with the NCCN recommendations, it is important to highlight that (as with many tumor types) histologic grade does not

Table 2. WHO Classification for NENs of the GI Tract

Grade	Mitotic Count (per 10 HPFs)	Ki-67 Index, %
G1	<2	<2
G2	2-20	>2-20
G3	>20	>20

always correlate with clinical behavior; a subset of NENs with a low-grade histologic appearance may behave aggressively with rapid growth and metastases matching those of high-grade NEC.⁴¹ Therefore, in case of discordancy between differentiation and Ki-67 proliferation or when a purportedly low-grade tumor does not follow the predicted indolent course, clinical judgment and gestalt, per the NCCN, should trump histological appearance,⁴² which may lead to treatment of certain “low-grade” tumors with platinum-doublet chemotherapy.

In the absence of a simple, practical, and universally accepted system of nomenclature and classification, entrenched terms such as “carcinoid” and “atypical carcinoid” linger on especially in reference to pulmonary NENs; therefore, despite all the attempts at reclassification, familiarity with these older terms and histologic categories even if they are potentially misleading and confusing is beneficial.

Staging

No formal tumor-nodes-metastasis (TNM)-based staging systems were in use for GEP neoplasms until the American Joint Committee on Cancer formally adopted one in 2010 for all anatomic sites, which parallels the European Neuroendocrine Tumor Society (ENETS) TNM system published in 2006.⁴³ Although the staging criteria for both systems depend on assessment of size (T stage), the extent of invasion, and its relationship to anatomical landmarks similar to the staging of non-NECs of the same sites, differences between them, most notably with regard to the classification of appendiceal and pancreatic, complicate assessment. For pulmonary NENs, non-small-cell lung cancer staging criteria are applied (seventh edition of the TNM staging system).⁴⁴ Currently, no specific TNM staging system for thymic and urogenital NENs is in use.

Genetics

The majority of NENs are sporadic, but hereditary syndromes that predispose to it include multiple endocrine neoplasia type 1 (MEN-1), MEN-2, von Hippel-Lindau (VHL) syndrome, neurofibromatosis, and tuberous sclerosis.^{45,46} Mutations in the RET proto-oncogene are associated with MEN-2A.⁴⁷ Genomic studies in pancreatic NETs by Jiao et al. revealed mutations in mTOR pathway genes in 15% of patients,⁴⁸ which provides a rationale for the therapeutic use of mTOR inhibitors in this tumor type.⁴⁹

NETs are also highly vascularized, which makes inhibition of vascular endothelial growth factor (VEGF) signaling a relevant treatment option. The VHL gene is associated with the regulation of hypoxia-inducible factor (HIF); loss of VHL gene expression, which leads to constitutive HIF activation and increased expression of HIF targets, such as VEGF, has been linked to the development of pancreatic NETs.⁵⁰

Mutational analysis of pulmonary NENs has also demonstrated multiple genetic aberrations, including FGF2 mutations in large-cell NEC; KIT, PTEN, HNF1A, and SMO alterations in atypical carcinomas; JAK3, NRAS, RB1, and VHL1 mutations in SCLC; and SMAD4 mutations in typical carcinoids.⁵¹

Table 1. WHO Classification for NETs of the Lung and Thymus

Grade	Nomenclature in Use	Mitotic Count (per 10 HPFs)	Necrosis
G1	Carcinoid	<2	0
G2	Atypical carcinoid	2-10	Foci
G3	Poorly differentiated NEC	>10	Present

Types and Clinical Features

GEP-NETs

GEP-NETs, which characteristically present at age 50-60,⁵² are challenging to diagnose, particularly if asymptomatic, which is often the case, with incidental discovery usually during surgery for another reason (e.g., appendectomy).⁵³ If symptoms such as abdominal discomfort are present, they are usually vague and nonspecific, which may cause considerable delay and difficulty in diagnosis. GEP-NETs are subdivided into two categories: carcinoid tumors of the luminal GI tract and pancreatic NETs.

a. Appendiceal NENs⁵⁴

The diagnosis of these tumors is usually established postoperatively in the specimens of appendectomies. The majority of these tumors are benign. Carcinoid syndrome is rare (<1%). A large female preponderance is reported possibly due to a selection bias: higher rates of diagnostic laparoscopy are performed in premenopausal women who present with lower abdominal pain to distinguish between a broad range of gynecologic and nongynecologic conditions.

b. Gastric NENs^{55,56}

These rare tumors are classified into three types: Type I is associated with chronic atrophic gastritis type, with or without pernicious anemia. Type II is associated with Zollinger-Ellison syndrome and MEN-1 syndrome (see pancreatic NENs below). Type III tumors are sporadic, large, solitary, and invasive tumors that occasionally produce an atypical carcinoid syndrome mediated by histamine and serotonin. In contrast to the diffuse rash of typical carcinoid syndrome, the flush with Type III tumors is patchy red, serpiginous, and intensely pruritic.

c. Colorectal NENs

These rare tumors are associated with a more aggressive clinical course and a poorer prognosis than adenocarcinomas.⁵⁷ They are subclassified into two pathological types: small-cell carcinomas and moderately differentiated NECs.⁵⁸ Small-cell carcinoma of the colon and rectum shares similar morphologic and immunohistochemical features with small-cell lung cancer, while moderately differentiated NEC of the colon and rectum has a similar morphology to large-cell lung carcinoma with neuroendocrine features. The former is managed with chemotherapy; the latter, with surgery.

d. Pancreatic NENs (traditionally called islet-cell carcinomas)

These tumors involve pancreatic islet cells that may or may not produce various hormones; the functional tumors that are associated with a variety of clinical syndromes include:

- Insulinomas, a β -cell neoplasm of the pancreatic islets, and the most common GI NET, which may appear as part of the MEN-1 syndrome, are responsible for excessive insulin secretion, leading to symptoms of hypoglycemia and hypokalemia since insulin shifts extracellular K into the intracellular compartment.⁵⁹
- Gastrinomas, the second most common GI NET behind insulinomas, are usually located in the pancreas and duodenum; they occur predominately in older males and are responsible for Zollinger-Ellison syndrome or severe peptic ulcer disease, often

in the absence of obvious risk factors such as nonsteroidal anti-inflammatory drug intake, due to hypersecretion of acid from uncontrolled production of the peptide hormone gastrin. Twenty-five percent of gastrinomas are associated with MEN-1 syndrome.^{60,61}

- Pancreatic polypeptide-secreting tumors (Ppomas) are the third most common type of pancreatic NET. Unlike gastrinomas, vasoactive intestinal peptide-secreting tumors (VIPomas), or glucagonomas, no clinical syndrome is associated with these. Ppoma patients present with weight loss, jaundice, and abdominal pain. Elevated pancreatic polypeptide levels confirm the diagnosis.⁶²
- VIPomas, which arise from the pancreas in 90%⁶³ of adult cases, autonomously secrete VIP,⁶⁴ leading to a syndrome initially described by Verner and Morrison in 1958 of watery diarrhea, hypokalemia, and achlorhydria.⁶⁵ Like gastrinomas, insulinomas, glucagonomas, and somatostatinomas, VIPomas are associated with MEN-1 syndrome.⁶⁶
- Glucagonomas are extremely rare pancreatic tumors that overproduce the counterregulatory hormone glucagon. Glucagonoma syndrome is a paraneoplastic phenomenon with an estimated incidence of 1 in 20 million, characterized by the presence of the 4 D's: diabetes, dermatitis (necrolytic migratory erythema), deep vein thrombosis, and depression.⁶⁷
- Somatostatinomas are the least common NET primarily located in the pancreas and duodenum. Somatostatin is an inhibitory hormone that suppresses pancreatic, biliary, gastric, and intestinal secretions as well as gallbladder contractility. The triad of cholelithiasis, hyperglycemia, and steatorrhea characterizes somatostatinoma syndrome.⁶⁸ An elevated somatostatin level (>10 ng/ml) confirms the diagnosis.

Carcinoid Syndrome

The presence of carcinoid syndrome that results from the hypersecretion of amines and peptides often facilitates diagnosis of a NET. The enterochromaffin or Kulchitsky cells,⁶⁹ which are part of the diffuse neuroendocrine cells of the gut, synthesize serotonin from dietary tryptophan.

The classical carcinoid syndrome with watery diarrhea, flushing, bronchospasm, hypotension, and right-sided heart disease correlates with serotonin hypersecretion since properties of serotonin include vasodilation, bronchoconstriction, and smooth muscle contraction.⁷⁰ Serotonin receptors⁷¹ are also expressed on the subendocardial cells of heart valves, and elevated serum levels induce valvular disease.⁷² Involvement of the left side of the heart is uncommon due to metabolism of the serotonin during passage through the lungs.⁷³

Because the serotonin from small bowel tumors is drained by the portal vein and inactivated by monoamine oxidases in the liver before it reaches the systemic circulation, carcinoid syndrome⁷⁴ usually only occurs in the presence of liver or other distant metastases when the serotonin bypasses hepatic metabolism.⁷⁵ Confirmation of the diagnosis is based on the measurement of urinary 5-hydroxyindole acetic acid (5-HIAA), a serotonin metabolite, and plasma CgA,^{76,77} a glycoprotein that is secreted with serotonin. Hypoproteinemia is usually coincident with carcinoid syndrome due to depletion of tryptophan, an essential amino acid.⁷⁸ Since niacin (nicotinic acid) production is dependent on tryptophan, pellagra-like symptoms (diarrhea, dermatitis, and dementia) indicative of niacin deficiency are common.⁷⁹

NENs of the Genitourinary (GU) Tracts

These rare neoplasms, which occur primarily in the kidney and urinary bladder and usually present with abdominal or flank pain, abdominal mass, weight loss, and hematuria,⁸⁰ are more common in the female than the male GU tracts. In the genital tract of females, the most frequent site is the cervix, followed by the ovaries. NENs of the endometrium, vagina, and vulva have also been reported. Male GU neoplasms are even rarer. The prostate is the most common site. Other tumor locations include the testicles and small-cell NE carcinomas of the scrotum, penis, and penile urethra. Symptoms due to hormone production or carcinoid syndrome are rare, occurring in <10% of cases.^{81,82}

Pulmonary NETs

NETs of the lung comprise typical carcinoid, atypical carcinoid, LCNEC, and SCLC in order of worsening prognosis.⁸³ They arise from the amine precursor uptake decarboxylation system and share the same neuroendocrine (Kulchitsky) cell of origin with small-cell carcinoma of the lung.⁸⁴ The clinical presentation (i.e., signs and symptoms) varies depending on the anatomical location of the tumor and the biological aggressiveness⁸⁵ (Table 3).

At the more benign end of the spectrum, typical carcinoids, which comprise approximately 2% of lung NETs, tend to occur in younger patients (mean age, 45-50 years), with no significant predilection for gender or smoking history.⁸⁶ Signs and symptoms of centrally located carcinoids (the majority) include recurrent infections, chest pain, cough, wheeze, dyspnea, and pneumonia. Peripherally located carcinoids (the minority) are generally asymptomatic and tend to present incidentally.⁸⁷ Compared with GEP-NETs, ectopic hormone secretion and paraneoplastic syndromes such as Cushing's syndrome are more rare.⁸⁸ Carcinoid syndrome is almost exclusively seen in the context of liver metastases.⁷³

Unlike typical carcinoids, atypical carcinoids, which comprise 0.2% of lung NETs, are associated with a history of smoking and occur more frequently in men.⁸⁹ The average age for an atypical carcinoid patient is also about 10 years older (59 years in atypical carcinoids and 49 years in typical carcinoids).^{90,91} Given their more common peripheral location, atypical carcinoids tend to present later with symptoms than typical carcinoids. The incidence of carcinoid syndrome is reportedly higher, consistent with their propensity for metastasis.⁹²

At the other end of the clinical spectrum is SCLC, by far the most common lung NET (frequency of 20%,⁹³ which has decreased in the United States to 13%⁹⁴), with a survival typically measured in months.⁸⁶ SCLC, which is invariably associated with tobacco use, occurs predominately in older male patients (mean age, 65 years).⁹⁵ The association with heavy smoking is so well established that diagnosis in a lifetime nonsmoker is distinctly unusual and suspect.⁹⁶

Table 3. Criteria for the Classification of Pulmonary NETs (Adapted from Escuini)⁸⁴

	Typical Carcinoid	Atypical Carcinoid	LCNEC	Small-Cell Lung Cancer
Differentiation grade	Low	Intermediate	High	High
Mitotic count per 10 HPF fields (diameter with a ×40 objective)	<2	2-10	>10	>10
Necrosis	Absent	Focal	Extensive	Extensive
Lymph node metastases at diagnosis	10%-15%	50%	60%-80%	60%-80%
Distant metastases at diagnosis	3%-5%	20%-25%	40%	60%-70%
Association with smoking	No	Yes	Yes	Yes
Paraneoplastic syndromes	+	++	+	++++
Common anatomical location in the lung ¹⁶¹	Central	Peripheral	Peripheral	Hilar/perihilar

Fatigue, cough, dyspnea, decreased appetite, weight loss, pain, and hemoptysis are the most common presenting symptoms.⁹⁷ Extensive enlargement of mediastinal and hilar lymph nodes are typically visible on computed tomography (CT).⁹⁸ Metastases at the time of presentation to extrathoracic locations such as the bone, brain, liver, and adrenals are the rule.⁹⁸ Several paraneoplastic syndromes have been associated with SCLC: syndrome of inappropriate antidiuretic hormone, Cushing's syndrome, and neurologic paraneoplastic syndromes such as autoimmune neuropathies and encephalomyelitis.⁹⁷

LCNEC shares a similar clinical presentation and natural history to SCLC with some exceptions: 1) primary LCNECs tend to occur peripherally rather than centrally,⁹⁹ and 2) presentation of LCNECs with limited stage disease is more common than for SCLC (approximately 25% versus less than 5%). LCNEC patients are predominately male, and the median age is approximately 60 years.¹⁰⁰ Paraneoplastic syndromes are rare.¹⁰¹

Tumor Localization

To investigate NENs, several imaging methods are available including CT, magnetic resonance imaging, ultrasonography, scintigraphy, and positron emission tomography. Tumor localization is essential since surgery remains the optimal treatment in nonmetastatic disease.¹⁰²

The first-line imaging investigation in most patients with suspected bronchial NENs is chest radiography,¹⁰³ which is abnormal in 90% of patients, even though CT or magnetic resonance imaging is more sensitive and bronchoscopy provides the opportunity for biopsy.⁸³ These tumors, which tend to appear as circumscribed, centrally located lesions, are associated with radiographic findings of postobstructive pneumonia or mucus plugging.¹⁰⁴

GI endoscopy is the procedure of choice to diagnose rectal, duodenal, colonic, and gastric NETs.¹⁰⁵ In the early stages, small bowel tumors, in particular, are challenging to detect since they are typically small and confined to the intestinal wall. When barium studies or CT is inconclusive, angiography may be preferred because these tumors are hypervascular.⁵¹ Magnetic resonance imaging, CT scan, and ultrasonography are highly sensitive for the detection of liver metastases but generally have a lower sensitivity for the identification of extrahepatic sites.¹⁰⁶

Since GEP-NENs generally express somatostatin receptors¹⁰⁷ and since octreotide, the somatostatin mimic, which can be labeled with radionuclides such as 123-I or 111In, binds with high affinity to somatostatin receptors, somatostatin receptor scintigraphy is a sensitive method for the detection of the primary tumor and its metastases.¹⁰⁸

Tumor Markers

Commonly measured tumor markers in NENs include serum CgA and 5-HIAA, the final secreted product of serotonin, levels in a 24-hour urine sample.¹⁰⁹ Since serum CgA, which is a more sensitive and broadly applicable marker than urinary 5-HIAA, does not depend on serotonin secretion, it is preferred over 5-HIAA for bronchial and rectal tumors, which do not generally secrete serotonin.¹¹⁰

In addition to its value in making the diagnosis, plasma CgA levels correlate with tumor bulk, differentiation, and secretory activity, which, in turn, may predict treatment response¹¹¹ and overall survival (OS) (fast rising levels seem to indicate a poor prognosis).¹¹² Besides CgA and 5-HIAA, NENs are known to produce a plethora of bioactive amines and peptides such as 5-hydroxytryptamine, 5-hydroxytryptophan, serotonin, insulin, gastrin, glucagon, somatostatin, vasoactive intestinal peptide, growth hormone, adrenocorticotropic hormone, melanocyte-stimulating

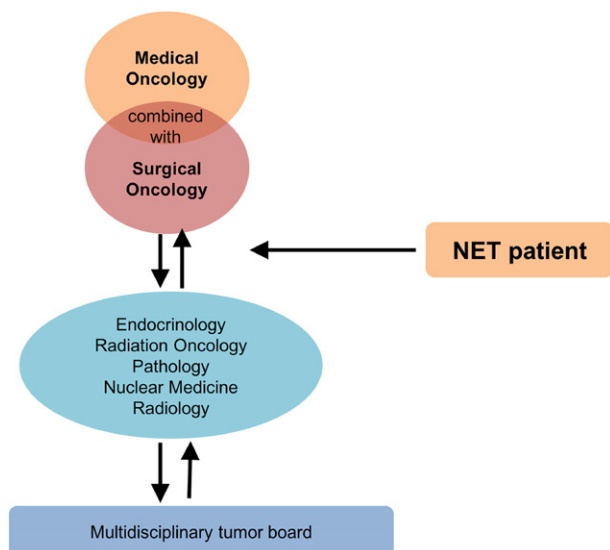


Figure 2. Neuroendocrine multidisciplinary team.

hormone, pancreatic polypeptide, calcitonin, substance P, pancreastatin, etc., resulting in relatively uncommon but unique clinical syndromes.¹¹³

Oncologic Management

As a heterogeneous and complicated tumor type, NENs require multidisciplinary care, inclusive of medical and radiation oncologists, surgeons, pathologists, endocrinologists, interventional radiologists, and possibly pulmonologists and gastroenterologists (Figure 2). In general, a two-tiered grading criteria dictate treatment even though the correspondence between histology and clinical behavior is in some cases imperfect, leading to a gray area not backed by clear guidelines or definitions.

Low-to-Intermediate NENs

The mainstay of treatment is surgery with curative intent, if possible; the need for adjuvant therapy is questionable.¹¹⁴ However, if surgery is not possible due to the extent and spread of disease, since most NETs are diagnosed after metastases have already developed, chronic medical management to both relieve symptoms and suppress tumor growth and spread is required.¹¹⁵ Surgery may still be indicated for palliative debulking to decrease tumor burden or help control hormone production. If feasible, complete metastectomy, especially when liver lesions are present, has been advocated.¹¹⁶

Another option with neuroendocrine liver lesions, given that the majority of them are hypervascular, is hepatic directed procedures, which include ablative therapy, transarterial embolization, transarterial chemoembolization, and selective internal radiation therapy with yttrium-90 microspheres.¹¹⁷

Systemic, i.e., nonsurgical non-liver directed, options approved include somatostatin analogs, peptide receptor radionuclide therapy (PRRT), low-dose interferon, everolimus, sunitinib, bevacizumab, and cytotoxic regimens.^{118,119}

a. Somatostatin analogs (SSAs)

Due to its extremely short half-life, on the order of 2 to 3 minutes, the peptide hormone somatostatin was never developed for use in the clinic.¹²⁰ However, the synthetic longer-acting analogs octreotide and lanreotide were approved for the treatment of GEP tumors. Originally

dosed to manage or prevent symptoms of hormone excess from carcinoid syndrome, the improvement in progression-free survival (PFS) from two placebo-controlled international studies (PROMID, using Octreotide, and CLARINET trial, using Lanreotide) in patients with unresectable or metastatic small bowel NETs established these SSAs as first-line agents for low-grade NETs.¹²¹ However, due to a weak evidence base and uncertainty in clinical practice guidelines, the optimal management strategy after progression on first line SSAs is undefined.

b. PRRT

Since the majority of GEP-NENs express somatostatin receptors, which are visualizable with diagnostic gallium or indium somatostatin positron emission tomography tracers, a subsequent step was to use the same receptor binding with radioactive isotopes such as yttrium-90 and/or lutetium-177 for treatment purposes.¹²² This so-called PRRT is not yet approved in the United States,¹²³ although it is readily available in Europe and Asia under local regulations. Results from recently completed phase 3 NETTER-1 study¹²⁴ of ¹⁷⁷Lu-DOTATATE (Lutathera) plus the somatostatin octreotide LAR, the current standard of care in GEP-NENs, versus octreotide LAR alone in patients with inoperable, progressive, somatostatin receptor-positive midgut (i.e., jejunum, ileum, appendix, and proximal colon) tumors demonstrated a clinically meaningful and statistically significant increase in PFS and objective response rate as well as the suggestion of a survival benefit (OS data are still immature) on the Lutathera cohort. In April 2015, the FDA granted fast-track designation to Lutathera.

c. Interferon alpha (IFN- α)

Early trials of IFN- α in hormonally functional NETs took place prior to the introduction of SSAs as first-line therapy; reduction of hormone output, resulting in significant palliation of symptoms such as flushing and diarrhea as well as improvement of tumor markers, was reported in over 50% of patients.^{125,126} Objective tumor response rates were on the order of 4% to 10%, with high rates of disease stabilization.

A suggestion of synergy between SSAs and IFN- α in small phase 1 studies resulted in three randomized clinical trials investigating SSAs alone versus in combination with IFN- α . In two of these studies, which compared subcutaneous octreotide alone to a combination with IFN- α , the 5-year survival rate was improved in the combination group; however, the differences were not statistically significant.^{127,128} Therefore, while IFN- α may be associated with an OS advantage, no definitive conclusions can be drawn. Moreover, the potential for side effects such as fevers, chills, myalgias, depression, and myelosuppression have limited its use in practice.¹²⁹

d. Everolimus

Multiple lines of evidence implicate aberrant signaling through the mechanistic pathway of rapamycin (mTOR) pathway to the development of NETs.¹³⁰ Additionally, altered expression of mTOR pathway components is associated with poorer clinical outcomes (e.g., PFS and OS). Therefore, the mTOR pathway has emerged as a promising therapeutic target.

In a randomized phase II trial called RADIANT-2, which evaluated the combination of the mTOR inhibitor everolimus and octreotide LAR versus octreotide LAR in 429 patients with advanced, progressive NET with carcinoid symptoms, median PFS was 16.4 months for the

combination compared with 11.3 months for octreotide LAR alone; while these results were not statistically significant, possibly due to a highly heterogeneous patient population, the suggestion was that adding everolimus to octreotide LAR leads to synergistic antiproliferative activity.¹³¹ However, in a subgroup analysis of lung NETs from RADIANT-2, everolimus + octreotide LAR was effective.

In the randomized phase III trial RADIANT-3, which compared treatment with everolimus or matching placebo in patients with advanced pNET, median PFS was 11 months in the everolimus arm versus 4.6 months in the placebo arm, a highly statistically significant difference that led to its approval in pNET.^{132,133}

In the phase III trial called RADIANT-4, which randomized 302 patients with advanced, progressive nonfunctional NETs of the lungs and GI tract 2:1 to either 10 mg everolimus daily or placebo, median PFS was significantly prolonged by 7.1 months and the risk of progression of the disease was reduced by 52% in everolimus-treated patients.¹³⁴

e. Sunitinib

Since NETs express VEGF and its receptor (VEGFR), sunitinib, a small molecule that inhibits VEGFR1, VEGFR2, and VEGFR3, has been tested in NETs. On the basis of an overall response rate of 16.7% in pNET patients and 2.4% in carcinoid patients in phase II, a phase III randomized study of 37.5 mg of sunitinib daily versus placebo in pNETs was initiated.¹³⁵ The PFS of patients randomized to the sunitinib arm was improved compared with those in the placebo arm (11.4 months versus 5.5 months, hazard ratio 0.42, $P < .001$), and the response rate was 9.3%, leading to FDA approval for the treatment of metastatic pNETs.¹³⁶

f. Bevacizumab

In a small phase II study, 44 patients were randomized to octreotide plus bevacizumab versus octreotide plus interferon alfa-2b; the bevacizumab arm demonstrated improved response rates and PFS, suggestive of benefit.¹³⁷ A randomized phase III cooperative group (SWOG 0518) comparison of octreotide and bevacizumab with octreotide and interferon alfa-2b in 400 carcinoid patients is ongoing. A phase II study (CALGB 80701) of everolimus ± bevacizumab in pNETs is also currently ongoing.¹³⁸

g. Cytotoxic agents

The role of chemotherapy in advanced, well-differentiated NETs is a subject of ongoing debate, with no accepted standard regimen. In general, low-grade tumors are associated with a poorer response to cytotoxic chemotherapy than high-grade tumors since the cells of low-grade tumors divide more slowly. However, this relationship is not absolute; low-grade tumors that exhibit a more aggressive pattern of growth and/or symptomatic clinical course may be managed with cytotoxic chemotherapy. While cytotoxic chemotherapy appears to produce high response rates in metastatic pNETs, non-pNETs are associated with lower response rates.¹³⁹ The evidence base for the use of chemotherapy in pNETs, GI-NENs, and bronchial (or thymic) NENs is discussed below.

1. pNETs

The nitrosourea streptozocin (STZ) was the first agent to demonstrate clinical effectiveness in pNETs. In the 1970s and

1980s, two randomized phase III trials that were based on nonradiologic response criteria such as improvement in tumor markers or reduction in hepatomegaly were conducted to confirm promising phase II results with STZ monotherapy.¹⁴⁰ The first of these trials reported response rates of 63% with STZ plus 5-fluorouracil (5-FU) versus 36% with STZ monotherapy.¹⁴¹ The second trial reported response rates of 69% with STZ plus doxorubicin versus 45% with STZ plus 5-FU.¹⁴² A more recent retrospective study of STZ, 5-FU, and doxorubicin in metastatic pNETs, which used objective radiologic response criteria, reported a response rate of 39%.¹⁴³

Single-agent dacarbazine (DTIC) is another cytotoxic with clinical evidence of objective activity in metastatic pNETs, demonstrating a response rate of 33% in a phase II trial. Nevertheless, these results were offset by a high rate of toxicity.¹⁴⁴ In fact, despite their activity, the substantial toxicity profiles of both DTIC and STZ limit their use in clinical practice.

A close relative of DTIC that also forms the DNA-alkylating metabolite monomethyl triazeno imidazole carboxamide,¹⁴⁵ oral temozolomide is similarly active in metastatic pNETs but with less toxicity. Combination regimens with thalidomide, everolimus, or bevacizumab have shown response rates of 25% to 45%.¹⁴⁶ However, the combination with capecitabine demonstrated the most synergy in a 2011 study with a response rate of 70% and overall PFS of 18 months.¹⁴⁷ This synergy is schedule dependent, with best results observed when capecitabine precedes temozolomide, possibly due to partial depletion of levels of MGMT, a DNA repair enzyme.¹⁴⁸

2. GI-NENs

The role of chemotherapy in low- or intermediate-grade gastrointestinal non-pancreatic neuroendocrine neoplasms (non-pNETs) is less certain given the lower response rates that have been observed in small clinical trials with streptozocin, 5-FU, capecitabine, temozolomide, and doxorubicin.¹⁴⁹ The general consensus, however, is that chemotherapy should be reserved for patients with no other therapeutic options. There are two notable exceptions: Metastatic goblet-cell tumors of the appendix, which express markers common to colorectal adenocarcinomas and, therefore, may be treated with the same FOLFOX chemotherapy regimen (5-FU, oxaliplatin, and leucovorin) used in colorectal cancer. The ENETS Guidelines 2012 advocate for the use of combination regimens incorporating a fluoropyrimidine.¹⁵⁰ Rapidly progressive, aggressive disease, with early, distant spread and behavior, on the whole, that is more similar to high-grade NECs or SCLC, or uncontrolled symptoms related to hormone secretion may warrant systemic chemotherapy such as platinum doublets and/or radiotherapy.¹⁵¹

3. Bronchial and thymic NENs

Given their pathological similarities to small-cell lung cancer, platinum-based doublets, mostly combinations with etoposide, are commonly used despite poor response rates and treatment outcomes since typical and atypical carcinoids tend to be less chemosensitive than SCLC. While clinical data for these tumor types are scant because they have not been studied independently of other NENs, temozolomide has shown activity. Results from a published phase II 36-patient neuroendocrine study with oral temozolomide given for 5 consecutive days every 28 days yielded 4 partial responses (31%) and 4 stable diseases (31%) among bronchial NENs and 5 stable diseases (71%) among thymic NENs.¹⁵²

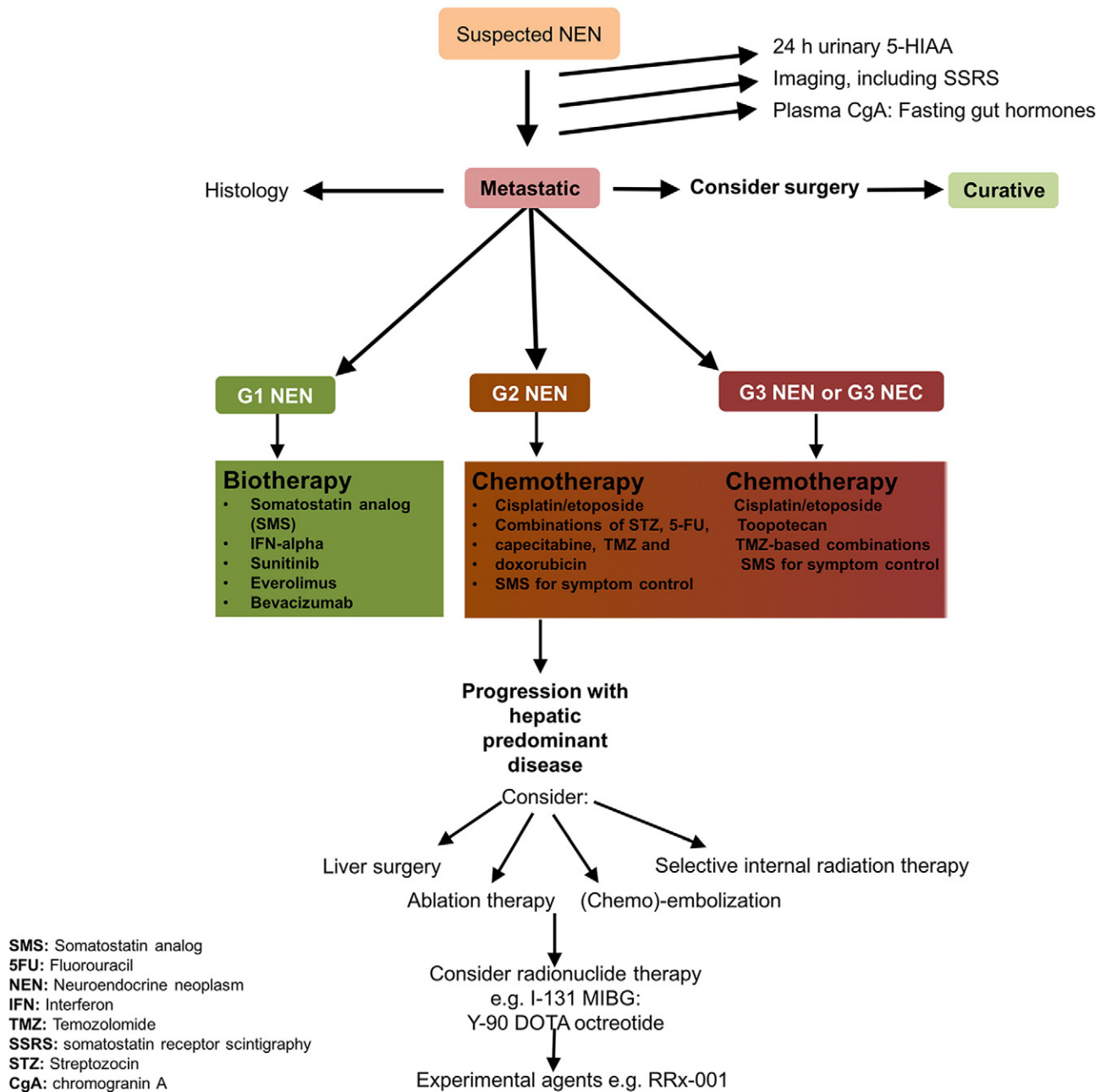


Figure 3. An algorithmic overview for the investigation and treatment of NENs.

Extrapulmonary High-Grade Neuroendocrine Tumors (HGNECs)

Strictly speaking, HGNECs are rare, aggressive tumors typically found in the GI and GU tracts and histologically defined by a high mitotic rate (>10 mitotic figures per 10 high-powered fields or a Ki-67 proliferative index >20%); their aggressive, rapidly progressive behavior resembles small- or large-cell lung cancer,¹⁵³ and treatment is accordingly extrapolated from the treatment paradigm of SCLC.³⁹

However, a subset of histologically low-grade, well-differentiated, or intermediately differentiated tumors follows a rapid clinical course with a biologically aggressive pattern of spread and proliferation that is reminiscent of high-grade NETs; in these cases, histology correlates less with grade than with stage; moreover, on the prima facie premise that what looks, acts, and quacks like a duck actually is a duck, it may be more appropriate to define and treat these tumors as HGNECs rather than NENs. Indeed, Sorbye et al. contend that tumors once considered

“moderately differentiated” or “intermediate grade” have been de facto migrated to the same category as small-cell carcinomas.³⁹

Tang et al. further blurred the boundaries between low- and high-grade tumors with a pathology study of 31 well-differentiated neuroendocrine tumors, which concluded, “...the current WHO G3 category contains both WD [well-differentiated]-NETs as well as PD-NECs (poorly differentiated neuroendocrine carcinomas).” The chief finding from the study is that tumors classified as well-differentiated constitute an inhomogeneous group, which may 1) undergo phenotypic progression and transform from low-grade to high-grade as they metastasize and 2) contain focal areas of poorly differentiated cells.¹⁵⁴

For metastatic disease that is classified as high grade on the basis of either histological characteristics or aggressive biological behavior, first-line treatment consists of platinum-based chemotherapy with response rates that range from 42% to 67% and a median survival of 15

to 19 months.^{155,156} Temozolomide is generally given in second line on the basis of a 25-patient NEC study where the response rate for temozolomide with or without capecitabine and bevacizumab after progression on cisplatin-based chemotherapy was 33% and the median OS was 22 months.¹⁵⁷ Topotecan has also been recommended in second line based on extrapolation from treatment of SCLC, but no independent confirmation of its activity in this setting is available. Clinical trials with sunitinib and everolimus are reportedly under way, but no results have been reported.³⁹

A newcomer to the treatment of high-grade NECs that deserves brief mention due to the uniqueness of its chemical structure, mechanism of action, and provenance, having been “spun off” from aerospace and defense research and development, which completely sets it apart from other so-called “targeted” agents such as everolimus and sunitinib, is the experimental epi-immunotherapeutic anticancer agent RRx-001.¹⁵⁸ Several published case reports have described clinical benefit (prolonged stable disease for over a year and improvement in carcinoid syndrome in HGNECs) and 3/4 durable partial responses in SCLC with RRx-001 in the context of a phase II clinical trial called QUADRUPLE THREAT (NCT02489903^{159–161}).

An algorithmic approach to the evaluation and treatment of NETs is provided in Figure 3.

Conclusion

NETs, a heterogeneous population of cancer subtypes and morphologies ranging from NENs and pNETs to small-cell lung cancer and large-cell NECs, are historically lumped together as a homogeneous group under one umbrella term on the basis of a single shared variable, the expression of neuroendocrine markers, such as CgA and Syn, which may or may not impact treatment management or clinical prognosis.

However, as a generic label of convenience, “neuroendocrine” may do more harm than good since it implies biologically “benign” behavior for tumors that are not reproducibly or reliably indolent; in fact, so-called well- or moderately differentiated NENs may, in some cases, defy their grade 1 or 2 histological classification and act more like grade 3 tumors instead of low-risk, slow-growing ones, with widespread and eventually fatal metastases. In these cases, based on their highly aggressive behavior, possibly secondary to evolution with higher-grade transformation of the original low-grade disease, as demonstrated by the previously discussed 2016 pathologic study of Tang et al., it may be more appropriate to reclassify these tumors as SCLC variants and treat them accordingly with platinum doublets rather than with analogs of somatostatin.¹⁵³

In the final analysis, however they are ultimately defined, NENs and carcinomas, as zebras of the oncology world that are fraught with heterogeneity, constitute a clinical conundrum, intrinsically complex and rendered even more so by a confused and cumbersome terminology, which is anathema to standardization and uniformity of treatment and outcome. Fortunately, a renaissance of chemotherapeutic agents, small molecules, and biological therapies that have progressed to clinical trials presages progress (and hope) in the treatment of these complicated and confounding tumors.

Funding

None.

References

- Basu B, Sirohi B, and Corrie P (2010). Systemic therapy for neuroendocrine tumours of gastroenteropancreatic origin. *Endocr Relat Cancer* **17**(1), R75-0.
- Bosman FT, Carneiro F, Hruban RH, and Theise ND (2010). World Health Organization (WHO) Classification of Tumours of the Digestive System. 4th ed. Geneva, Switzerland: WHO Press; 2010.
- Modlin IM, Oberg K, and Chung DC (2008). Gastroenteropancreatic neuroendocrine tumours. *Lancet Oncol* **9**, 61–72.
- Scalettar BA, Jacobs C, Fulwiler A, Prah L, Simon A, Hilken L, and Lochner JE (2012). Hindered submicron mobility and long-term storage of presynaptic dense-core granules revealed by single-particle tracking. *Dev Neurobiol* **72**(9), 1181–1195.
- Kaltsas GA, Besser GM, and Grossman AB (2004). The diagnosis and medical management of advanced neuroendocrine tumors. *Endocr Rev* **25**, 458–511.
- Anaizi A, Rizvi-Toner A, Valesin J, and Schey R (2015). Large cell neuroendocrine carcinoma of the lung presenting as pseudoachalasia: a case report. *J Med Case Reports* **9**, 56.
- Van Eeden S, Quaevlieg PF, Taal BG, Offerhaus GJ, Lamers CB, and Van Velthuisen ML (2002). Classification of low-grade neuroendocrine tumors of midgut and unknown origin. *Hum Pathol* **33**(11), 1126–1132.
- Asamura H, Kameya T, Matsuno Y, Noguchi M, Tada H, Ishikawa Y, Yokose T, Jiang SX, Inoue T, and Nakagawa K, et al (2006). Neuroendocrine neoplasms of the lung: a prognostic spectrum. *J Clin Oncol* **24**(1), 70–76.
- Nikou GC and Angelopoulos TP (2012). Current concepts on gastric carcinoid tumors. *Gastroenterol Res Pract* **2012**, 287825 [8 pages].
- Lewis MA and Hobday TJ (2012). Treatment of neuroendocrine tumor liver metastases. *Int J Hepatol* **2012**, 973946 [12 pages].
- Schurr PG, Strate T, Rese K, Kaifi JT, Reichelt U, Petri S, Kleinhans H, Yekebas EF, and Izbicki JR (2007). Aggressive surgery improves long-term survival in neuroendocrine pancreatic tumors an institutional experience. *Ann Surg* **245**(2), 273–281.
- Wolin EM (2012). The Expanding role of somatostatin analogs in the management of neuroendocrine tumors. *Gastrointest Cancer Res* **5**(5), 161–168.
- Patta A and Fakih M (2011). First-line cisplatin plus etoposide in high-grade metastatic neuroendocrine tumors of colon and rectum (MCRC NET): review of 8 cases. *Anticancer Res* **31**(3), 975–978.
- Taal BG and Visser O (2004). Epidemiology of neuroendocrine tumours. *Neuroendocrinology* **80**(Suppl 1), 3–7.
- Rindi G, Bordi C, Rappal S, La Rosa S, Stolte M, and Solcia E (1996). Gastric carcinoids and neuroendocrine carcinomas: pathogenesis, pathology, and behavior. *World J Surg* **20**(2), 168–172.
- Vinik A and Chaya C (2016). Clinical presentation and diagnosis of neuroendocrine tumors. *Hematol Oncol Clin North Am* **30**(1), 21–48.
- Abstracts Presented at the 7th Annual Meeting of the North American NeuroEndocrine Tumor Society, October 10–11, 2014, Nashville, Tennessee Pancreas journal, Volume 44, Issue 2; 2015 347–362.
- Boyce M and Thomsen L (2015). Gastric neuroendocrine tumors: prevalence in Europe, USA, and Japan, and rationale for treatment with a gastrin/CCK2 receptor antagonist. *Scand J Gastroenterol* **50**(5), 550–559.
- Avcu S, Özen Ö, Bulut MD, and Bora A (2009). Hepatic metastases of primary jejunal carcinoid tumor: a case report with radiological findings. *N Am J Med Sci* **1**(6), 305–308.
- Fink G, Krelbaum T, Yellin A, Bendayan D, Saute M, Glazer M, and Kramer MR (2001). Pulmonary carcinoid: presentation, diagnosis, and outcome in 142 cases in Israel and review of 640 cases from the literature. *Chest* **119**(6), 1647–1651.
- Klimstra DS, Modlin IR, Coppola D, Lloyd RV, and Suster S (2010). The pathologic classification of neuroendocrine tumors: a review of nomenclature, grading, and staging systems. *Pancreas* **39**, 707–712.
- Bosman FT, Carneim F, Hruban RH, and Theise ND (2010). WHO Classification of Tumours of the Digestive System. Lyon: IARC Press; 2010.
- La Rosa S, Marando A, Sessa F, and Capella C (2012). Mixed adenoneuroendocrine carcinomas (MANECs) of the gastrointestinal tract: an update. *Cancers (Basel)* **4**(1), 11–30.
- Modlin IM, Shapiro MD, and Kidd M (2004). Siegfried Oberndorfer: origins and perspectives of carcinoid tumors. *Hum Pathol* **35**(12), 1440–1451.
- Rosai J (2011). The origin of neuroendocrine tumors and the neural crest saga. *Mod Pathol* **24**, S53–S57.
- Modlin IM and Sandor A (1997). An analysis of 8305 cases of carcinoid tumors. *Cancer* **79**, 813–829.
- Williams E and Sandler M (1963). The classification of carcinoid tumours. *Lancet* **1**(7275), 238–239.
- Soga J (2009). The term “carcinoid” is a misnomer: the evidence based on local invasion. *J Exp Clin Cancer Res* **28**, 15.

- [29] Hajdu SJ and Tang P (2008). A note from history: the saga of carcinoid and oat-cell carcinoma. *Ann Clin Lab Sci* **38**(4), 414–417.
- [30] Masson P (1928). Carcinoids (argentaffin-cell tumors) and nerve hyperplasia of appendicular mucosa. *Am J Pathol* **4**, 181–212.
- [31] Arrigoni MG, Woolner LB, and Bernatz PE (1972). Atypical carcinoid tumors of the lung. *J Thorac Cardiovasc Surg* **64**, 413–421.
- [32] Creutzfeldt W (1996). Carcinoid tumors: development of our knowledge. *World J Surg* **20**(2), 126–131.
- [33] Chang S, Choi D, Lee SJ, Lee WJ, Park MH, Kim SW, Lee DK, and Jang KT (2007). Neuroendocrine neoplasms of the gastrointestinal tract: classification, pathologic basis, and imaging features. *Radiographics* **27**(6), 1667–1679.
- [34] Vinik A, Feliberti E, and Perry RR (2000). Carcinoid Tumors. [Updated 2014 Aug 1]. In: De Groot LJ, Beck-Peccoz P, Chrousos G, et al, editors. Endotext [Internet]. South Dartmouth (MA): MDText.com, Inc.; 2000 [Available from: <http://www.ncbi.nlm.nih.gov/books/NBK279162/>].
- [35] Pusceddu S, Catena L, Valente M, Buzzoni R, Formisano B, Del Vecchio M, Ducceschi M, Tavecchio L, Fabbri A, and Bajetta E (2010). Long-term follow up of patients affected by pulmonary carcinoid at the Istituto Nazionale Tumori di Milan: a retrospective analysis. *J Thorac Dis* **2**(1), 16–20.
- [36] Axiotis CA (2002). The neuroendocrine lung. In: Li Volsi V, Asa SL, editors. *Endocrine Pathology*. New York: Churchill Livingstone; 2002. p. 261–296.
- [37] Kloppel G (2011). Classification and pathology of gastroenteropancreatic neuroendocrine neoplasms. *Endocr Relat Cancer* **18**(Suppl 1), S1–16.
- [38] Travis WD (2004). The concept of pulmonary neuroendocrine tumours. In: Travis WD, Brambilla E, Muller-Hermelink HK, Harris CC, editors. *Pathology and Genetics of Tumours of the Lung, Pleura, Thymus and Heart*. Lyon, France: IARC Press; 2004.
- [39] Sorbye H, Strosberg J, Baudin E, Klimstra DS, and Yao JC (2014). Gastroenteropancreatic high-grade neuroendocrine carcinoma. *Cancer* **120**(18), 2814–2823.
- [40] Kulke MH, Shah MH, Benson AB, Bergsland E, Berlin JD, Blaszkowsky LS, Emerson L, Engstrom PF, Fanta P, and Giordano T, et al (2015). Neuroendocrine tumors, version 1.2015. *J Natl Compr Canc Netw* **13**(1), 78–108.
- [41] Farrell JM, Pang JC, Kim GE, and Tabatabai ZL (2014). Pancreatic neuroendocrine tumors: accurate grading with Ki-67 index on fine-needle aspiration specimens using the WHO 2010/ENETS criteria. *Cancer Cytopathol* **122**(10), 770–778.
- [42] Medscape reference [online]. available at <http://emedicine.medscape.com/article/2500010-overview>.
- [43] Kulke MH (2013). Are neuroendocrine tumors going mainstream? *J Clin Oncol* **31**(4), 404–405.
- [44] Grozinsky-Glasberg S, Shimon I, Korbonits M, and Grossmann AB (2008). Somatostatin analogues in the control of neuroendocrine tumours: Efficacy and mechanisms. *Endocr Relat Cancer* **15**, 701–720.
- [45] Gut P, Komarowska H, Czarnywojtek A, Waligorska-Stachura J, Baczyk M, Ziemnicka K, Fischbach J, Wrotkowska E, and Ruchala M (2015). Familial syndromes associated with neuroendocrine tumours. *Contemp Oncol (Pozn)* **19**(3), 176–183.
- [46] Di Domenico A, Wiedmer T, Marinoni I, and Perren A (2017). Genetic and epigenetic drivers of neuroendocrine tumours (NET). *Endocr Relat Cancer* **24**(9), R315–334.
- [47] Brandi ML, Gagel RF, Angeli A, Bilezikian JP, Beck-Peccoz P, Bordi C, Conte-Devolx B, Falchetti A, Gheri RG, and Libroia A, et al (2001). Guidelines for diagnosis and therapy of MEN type 1 and type 2. *J Clin Endocrinol Metab* **86**(12), 5658–5671.
- [48] Jiao Y, Shi C, Edil BH, de Wilde RF, Klimstra DS, Maitra A, Schlick RD, Tang LH, Wolfgang CL, and Choti MA, et al (2011). DAXX/ATRX, MEN1, and mTOR pathway genes are frequently altered in pancreatic neuroendocrine tumors. *Science* **331**, 1199–1203.
- [49] Bousquet C, Lasfargues C, Chalabi M, Billah SM, Susini C, Vezzosi D, Caron P, and Pyronnet S (2012). Clinical review: current scientific rationale for the use of somatostatin analogs and mTOR inhibitors in neuroendocrine tumor therapy. *J Clin Endocrinol Metab* **97**(3), 727–737.
- [50] Speisky D, Ducés A, Bieche I, Rebours V, Hammel P, Sauvanet A, Richard S, Bedossa P, Vidaud M, and Murat A, et al (2012). Molecular profiling of pancreatic neuroendocrine tumors in sporadic and Von Hippel–Lindau patients. *Clin Cancer Res* **18**(10), 2838–2849.
- [51] Vollbrecht C, Werner R, Walter RFH, Christoph DC, Heukamp LC, Peifer M, Hirsch B, Burbat L, Mairinger T, and Schmid KW, et al (2015). Mutational analysis of pulmonary tumours with neuroendocrine features using targeted massive parallel sequencing: a comparison of a neglected tumour group. *Br J Cancer* **113**, 1704–1711.
- [52] Horton KM, Kamel I, Hofmann L, and Fishman EK (2004). Carcinoid tumors of the small bowel: a multitechnique imaging approach. *AJR Am J Roentgenol* **182**, 559–567.
- [53] Goede AC, Caplin ME, and Winslet MC (2003). Carcinoid tumour of the appendix. *Br J Surg* **90**, 1317–1322.
- [54] Griniatsos J and Michail O (2010). Appendiceal neuroendocrine tumors: recent insights and clinical implications. *World J Gastrointest Oncol* **2**(4), 192–196.
- [55] Rindi G, Luinetti O, Cornaggia M, Capella C, and Solcia E (1993). Three subtypes of gastric argyrophil carcinoid and the gastric neuroendocrine carcinoma: a clinicopathologic study. *Gastroenterology* **104**, 994–1006.
- [56] Sitaraman SV and Goldfinger SE (2008). Clinical features of the primary carcinoid tumors. In: Tannabe KK, Whitcomb DC, editors. *UpToDate*. Waltham, MA: UpToDate; 2008.
- [57] Bernick PE, Klimstra DS, Shia J, Minsky B, Saltz L, Shi W, Thaler H, Guillem J, Paty P, and Cohen AM, et al (2004). Neuroendocrine carcinoma of the colon and rectum. *Dis Colon rectum* **47**, 163–169.
- [58] Nojima H, Seike K, Kosugi C, Shida T, Koda K, Oda K, Kamata S, Ishikura H, and Miyazaki M (2010). Advanced moderately differentiated neuroendocrine carcinoma of the rectum with favorable prognosis by postoperative chemoradiation. *World J Surg Oncol* **8**, 29.
- [59] Wolf P, Winhofer Y, Smajis S, Anderwald CH, Scheuba C, Niederle B, Gessl A, Luger A, Krebs M, and Koporek O (2015). Clinical presentation in insulinoma predicts histopathological tumour characteristics. *Clin Endocrinol (Oxf)* **83**(10), 67–71.
- [60] Yang R-H and Chu Y-K (2015). Zollinger-Ellison syndrome: revelation of the gastrinoma triangle. *Radiol Case Rep* **10**(1), 827. <https://doi.org/10.2484/rcr.v10i1.827>.
- [61] Nikou GC, Toubanakis C, Nikolaou P, Giannatou E, Marinou K, Safioleas M, and Karamanolis D (2005). Gastrinomas associated with MEN-1 syndrome: new insights for the diagnosis and management in a series of 11 patients. *Hepatogastroenterology* **52**(66), 1668–1676.
- [62] Mortenson M and Bold RJ (2002). Symptomatic pancreatic polypeptide-secreting tumor of the distal pancreas (PPoma). *Int J Gastrointest Cancer* **32**(2–3), 153–156.
- [63] Doherty GM (2005). Rare endocrine tumours of the GI tract. *Best Pract Res Clin Gastroenterol* **19**(5), 807–817.
- [64] Alvite-Canosa M, Alonso-Fernández L, Seoane-López M, Pérez-Grobas J, Berdeal-Díaz M, Carral-Freire M, Bouzon-Alejandro A, Gomez-Dovigo A, and Aguirrezabalaga-Gonzalez J, et al (2011). Benign pancreatic vipoma. *Rev Esp Enferm Dig* **103**(4), 224–225.
- [65] Verner JV and Morrison AB (1958). Islet cell tumor and a syndrome of refractory watery diarrhea and hypokalemia. *Am J Med* **25**(3), 374–380.
- [66] Levy-Bohbot N, Merlse C, Goudet P, Delemer B, Calender A, Jolly D, Thieffin G, and Cadiot G (2004). Prevalence, characteristics and prognosis of MEN 1-associated glucagonomas, VIPomas, and somatostatinomas: study from the GTE (Groupe des Tumeurs Endocrines) registry. *Gastroenterol Clin Biol* **28**(11), 1075–1081.
- [67] Castro PG, de Leon AM, Trancon JG, Martinez PA, Alvarez Perez JA, Fernandez Fernandez JC, Garcia Bernardo CM, Serra LB, and Gonzalez Gonzales JJ (2011). Glucagonoma syndrome: a case report. *J Med Case Reports* **5**, 402. <https://doi.org/10.1186/1752-1947-5-402>.
- [68] Soga J and Yakuwa Y (1999). Somatostatinoma/inhibitory syndrome: a statistical evaluation of 173 reported cases as compared to other pancreatic endocrinomas. *J Exp Clin Cancer Res* **18**, 13–22.
- [69] Lips CJ, Lentjes EG, and Hoppener JW (2003). The spectrum of carcinoid tumours and carcinoid syndromes. *Ann Clin Biochem* **40**(Pt 6), 612–627.
- [70] Robertson JIS (1990). Carcinoid syndrome and serotonin: therapeutic effects of ketanserin. *Cardiovasc Drugs Ther* **4**(1), 53–58.
- [71] Gustafsson BI, Tommeras K, Nordrum I, Loennechen JP, Brunsvik A, Solligård E, Fossmark R, Bakke I, Syversen U, and Waldum H (2005). Long-term serotonin administration induces heart valve disease in rats. *Circulation* **111**, 1517–1522.
- [72] Rajamannan NM, Caplice N, Anthikad F, Sebo TJ, Orszulak TA, Edwards WD, Tajik J, and Schwartz RS (2001). Cell proliferation in carcinoid valve disease: a mechanism for serotonin effects. *J Heart Valve Dis* **10**(6), 827–831.
- [73] de Vries H, Verschuere RC, Willems PH, Kema IP, and de Vries EG (2002). Diagnostic, surgical and medical aspect of the midgut carcinoids. *Cancer Treat Rev* **28**, 11–25.

- [74] Zuetenhorst JM and Taal BG (2005). Metastatic carcinoid tumors: a clinical review. *Oncologist* **10**(2), 123–131.
- [75] Maroun J, Kocha W, Kvols L, Bjarnason G, Chen E, Germond C, Hanna S, Poitras P, Rayson D, and Reid R, et al (2006). Guidelines for the diagnosis and management of carcinoid tumours. Part 1: The gastrointestinal tract. A statement from a Canadian National Carcinoid Expert Group. *Curr Oncol* **13**(2), 67–76.
- [76] Janson ET, Holmberg L, Stridsberg M, Eriksson B, Theodorsson E, Wilander E, and Oberg K (1997). Carcinoid tumors: an analysis of prognostic factors and survival in 301 patients from a referral center. *Ann Oncol* **8**, 685–690.
- [77] Ramage JK, Ahmed A, Ardill J, Bax N, Breen DJ, Caplin ME, Corrie P, Davar J, Davies AH, and Lewington V, et al (2012). Guidelines for the management of gastroenteropancreatic neuroendocrine (including carcinoid) tumours (NETs). *Gut* **61**, 6–32.
- [78] Graham GW, Unger BP, and Coursin DB (2000). Perioperative management of selected endocrine disorders. *Int Anesthesiol Clin* **38**(4), 31–67.
- [79] Castiello RJ and Lynch PJ (1972). Pellagra and the carcinoid syndrome. *Arch Dermatol* **105**(4), 574–577.
- [80] Murali R, Kneale K, Lalak N, and Delprado W (2006). Carcinoid tumors of the urinary tract and prostate. *Arch Pathol Lab Med* **130**, 1693–1706.
- [81] Raslan WF, Ro JY, Ordóñez NG, Amin MB, Troncoso P, Ayala AG, and Sella A (1993). Primary carcinoid of the kidney: immunohistochemical and ultrastructural studies of five patients. *Cancer* **72**, 2660–2666.
- [82] Mouloupoulos A, DuBrow R, David C, and Dimopoulos MA (1991). Primary renal carcinoid: computed tomography, ultrasound, and angiographic findings. *J Comput Assist Tomogr* **15**, 323–325.
- [83] Chong S, Lee KS, Chung MJ, Han J, Kwon OJ, and Kim TS (2006). Neuroendocrine tumors of the lung: clinical, pathologic, and imaging findings. *Radiographics* **26**(1), 41–57 [discussion 57–8].
- [84] Santra A, Dutta P, Pothal S, and Manjhi R (2013). Misdiagnosed case of bronchial carcinoid presenting with refractory dyspnoea and wheeze: a rare case report and review of literature. *Malays J Med Sci* **20**(3), 78–82.
- [85] Fisseler-Eckhoff A and Demes M (2012). Neuroendocrine tumors of the lung. *Cancers (Basel)* **4**(3), 777–798.
- [86] Rekhman N (2010). Neuroendocrine tumors of the lung, an update. *Arch Pathol Lab Med* **134**, 1628–1638.
- [87] Sánchez de Cos Escuin J (2014). Diagnosis and treatment of neuroendocrine lung tumors. *Arch Bronconeumol* **50**(9), 392–396.
- [88] McCaughan BC, Martini N, and Bains MS (1985). Bronchial carcinoids: review of 124 cases. *J Thorac Cardiovasc Surg* **89**(1), 8–17.
- [89] Valli M, Fabris GA, Dewar A, Hornall D, and Sheppard MN (1994). Atypical carcinoid tumour of the lung: a study of 33 cases with prognostic features. *Histopathology* **24**, 363–369.
- [90] Bosman FT, de la Riviere AB, Giard RW, Verhofstad AA, and Cramer-Knijnenburg G (1984). Amine and peptide hormone production by lung carcinoid: a clinicopathological and immunocytochemical study. *J Clin Pathol* **37**, 931–936.
- [91] Grote TH, Macon WR, Davis B, Greco FA, and Johnson DH (1988). Atypical carcinoid of the lung: a distinct clinicopathologic entity. *Chest* **93**, 370–375.
- [92] Marty-Ane CH, Costes V, Pujol JL, Alauzen M, Baldet P, and Mary H (1995). Carcinoid tumors of the lung: do atypical features require aggressive management. *Ann Thorac Surg* **59**(1), 78–83.
- [93] Pathology and genetics of tumours of the lung, pleura, thymus and heart. In: Travis W, Brambilla E, Muller-Hermelink H, Harris C, editors. World Health Organization Classification of Tumours. , Lyon, France: IARC Press; 2004.
- [94] Govindan R, Page N, Morgensztern D, Read W, Tierney R, Vlahiotis A, Spitznagel EL, and Piccirillo J (2006). Changing epidemiology of small-cell lung cancer in the United States over the last 30 years: analysis of the surveillance, epidemiologic, and end results database. *J Clin Oncol* **24**, 4539–4544.
- [95] Khuder SA, Dayal HH, Mutgi AB, Willey JC, and Dayal G (1998). Effect of cigarette smoking on major histological types of lung cancer in men. *Lung Cancer* **22**(1), 15–21.
- [96] Warren WH and Gould VE (1997). Differential diagnosis of small cell neuroendocrine carcinoma of the lung. *Chest Surg Clin N Am* **7**(1), 49–63.
- [97] Travis WD (2010). Advances in neuroendocrine lung tumors. *Ann Oncol* **21**(Suppl 7), vii65–vii71.
- [98] Krug LM, Kris MG, and Rosenzweig K (2015). Cancer of the lung: small cell and other neuroendocrine tumors of the lung. In: De Vita VT, Lawrence TS, Rosenberg SA, et al, editors. *DeVita, Hellman and Rosenberg's Cancer, Principles and Practice of Oncology*. 10th ed. USA: Wolters Kluwer Health; 2015.
- [99] Koobllall M, Crowther S, Moloney E, and Lane S (2015). Combined large cell neuroendocrine carcinoma of the lung. *J Cell Sci Ther* **6**, 216.
- [100] Travis WD and Krug LM (2006). Rusch, Large cell neuroendocrine carcinoma. In: Raghavan D, Brecher ML, Johnson DH, et al, editors. *Textbook of Uncommon Cancer*. Chichester: John Wiley & Sons, Ltd; 2006. p. 298–306.
- [101] Garcia-Yuste M, Matilla JM, Alvarez-Gago T, Duque JL, Heras F, Cerezal LJ, and Ramos G (2000). Prognostic factors in neuroendocrine lung tumors: a Spanish multicenter study. Spanish multicenter study of neuroendocrine tumors of the lung of the Spanish Society of Pneumology and Thoracic Surgery (EMETNE-SEPAR). *Ann Thorac Surg* **70**, 258–263.
- [102] Akerstrom G, Makridis C, and Johansson H (1991). Abdominal surgery in patients with midgut carcinoid tumours. *Acta Oncol* **30**, 547–553.
- [103] Jeung MY, Gasser B, Gangi A, Charneau D, Ducrocq X, Kessler R, Quoix E, and Roy C (2002). Bronchial carcinoid tumors of the thorax: spectrum of radiologic findings. *Radiographics* **22**(2), 351–365.
- [104] Hage R, de la Rivière AB, Seldenrijk CA, and van den Bosch JM (2003). Update in pulmonary carcinoid tumors: a review article. *Ann Surg Oncol* **10**(6), 697–704.
- [105] Thompson GB, Avan Heerden J, Martin JK, and Carney JA (1985). Carcinoid tumours of the gastrointestinal tract: presentation, management and prognosis. *Surgery* **98**, 1054–1063.
- [106] Kressel HY (1988). Strategies for magnetic resonance imaging of focal liver disease. *Radiol Clin North Am* **26**, 607–615.
- [107] de Herder WW and Lamberts SW (2002). Somatostatin and somatostatin analogues: diagnostic and therapeutic uses. *Curr Opin Oncol* **14**, 53–57.
- [108] Kwekkeboom DJ, Krenning EP, Bakker WH, Oei HY, Kooij PP, and Lamberts SW (1993). Somatostatin analogue scintigraphy in carcinoid tumours. *Eur J Nucl Med* **20**, 283–292.
- [109] Kapoor R, Bhattacharyya T, Gupta R, Mittal BR, and Kalra N (2014). A systematic review of management of neuroendocrine tumors: an experience from a tertiary care centre from India. *Clin Cancer Invest J* **3**, 363–372.
- [110] Kulke MH (2007). Clinical presentation and management of carcinoid tumors. *Hematol Oncol Clin North Am* **21**(3), 433–455 vii–viii.
- [111] Chou WC, Chen JS, Hung YS, Hsu JT, Chen TC, Sun CF, Lu CH, and Hwang TL (2014). Plasma chromogranin A levels predict survival and tumor response in patients with advanced gastroenteropancreatic neuroendocrine tumors. *Anticancer Res* **34**(10), 5661–5669.
- [112] Seregini E, Ferrari L, Bajetta E, Martinetti A, and Bombardieri E (2001). Clinical significance of blood chromogranin A measurement in neuroendocrine tumours. *Ann Oncol* **12**(Suppl 2), S69–72.
- [113] Ardill JES and Eriksson B (2003). The importance of the measurement of circulating markers in patients with neuroendocrine tumours of the pancreas and gut. *Endocr Relat Cancer* **10**, 459–462.
- [114] Kulke MH, Siu LL, Tepper JE, Fisher G, Jaffe D, Haller DG, Ellis LM, Benedetti JK, Bergsland EK, and Hobday TJ, et al (2011). Future directions in the treatment of neuroendocrine tumors: consensus report of the National Cancer Institute neuroendocrine tumor clinical trials planning meeting. *JCO* **29**(7), 934–943.
- [115] Oberg KE (2012). The management of neuroendocrine tumours: current and future medical therapy options. *Clin Oncol (R Coll Radiol)* **24**(4), 282–293.
- [116] Basuroy Ron, Srirajaskanthan Rajaventhana, and Ramage John K (2012). A multimodal approach to the management of neuroendocrine tumour liver metastases. *Int J Hepatol* **2012**, 819193 [13 pages].
- [117] Harring TR, Nguyen NTN, Goss JA, and O'Mahony CA (2011). Treatment of liver metastases in patients with neuroendocrine tumors: a comprehensive review. *Int J Hepatol* **2011**, 154541.
- [118] Eriksson B, Kloppel G, Krenning E, Ahlman H, Plockinger U, Wiedenmann B, Arnold R, Auernhammer C, Korner M, and Rindi G, et al (2008). Consensus guidelines for the management of patients with digestive neuroendocrine tumors—well-differentiated jejunal-ileal tumor/carcinoma. *Neuroendocrinology* **87**(1), 8–19.
- [119] Faggiano A, Lo Calzo F, Pizzi G, Modica R, and Colao A (2017). The safety of available treatments options for neuroendocrine tumors. *Expert Opin Drug Saf* **20**, 1–13.
- [120] Harris AG (1994). Somatostatin and somatostatin analogues: pharmacokinetics and pharmacodynamic effects. *Gut* **35**(3 Suppl), S1–S4.
- [121] Yao JC, Lagunes DR, and Kulke MH (2013). Targeted Therapies in neuroendocrine tumors (NET): clinical trial challenges and lessons learned. *Oncologist* **18**(5), 525–532.

- [122] Kwekkeboom DJ and Krenning EP (2016). Peptide receptor radionuclide therapy in the treatment of neuroendocrine tumors. *Hematol Oncol Clin North Am* **30**(1), 179–191.
- [123] Delbeke D and Graham MM (2013). Joint guidance on peptide receptor radionuclide therapy in neuroendocrine tumors. *J Nucl Med* **54**(5), 663.
- [124] Lopera Sierra M, Kwekkeboom D, Mariani MF, Bodei L, Santoro P, and Krenning EP (2014). 1165TiP NETTER-1: first pivotal phase III study evaluating ¹⁷⁷Lu-dotatate in midgut neuroendocrine tumours. *Ann Oncol* **25**(Suppl. 4), iv405. <https://doi.org/10.1093/annonc/mdu345.34>.
- [125] Oberg K, Funa K, and Alm G (1983). Effects of leukocyte interferon on clinical symptoms and hormone levels in patients with mid-gut carcinoid tumors and carcinoid syndrome. *N Engl J Med* **309**(3), 129–133.
- [126] Biesma B, Willemsse PH, Mulder NH, Verschueren RC, Kema IP, de Bruijn HW, Postmus PE, Sleijfer DT, and de Vries EG (1992). Recombinant interferon alpha-2b in patients with metastatic apudomas: effect on tumours and tumour markers. *Br J Cancer* **66**(5), 850–855.
- [127] Kölby L, Persson G, Franzén S, and Ahren B (2003). Randomized clinical trial of the effect of interferon alpha on survival in patients with disseminated midgut carcinoid tumours. *Br J Surg* **90**(6), 687–693.
- [128] Arnold R, Rinke A, Kose KJ, Muller HH, Wied M, Zamzow K, Schmidt C, Schade-Brittinger C, Barth P, and Moll R, et al (2005). Octreotide versus octreotide plus interferon-alpha in endocrine gastroenteropancreatic tumors: a randomized trial. *Clin Gastroenterol Hepatol* **3**(8), 761–771.
- [129] Mirvis E, Mandair D, Garcia-Hernandez J, Mohmaduvesh M, Toumpanakis C, and Caplin M (2014). Role of interferon-alpha in patients with neuroendocrine tumors: a retrospective study. *Anticancer Res* **34**(11), 6601–6607.
- [130] Chan J and Kulke M (2014). Targeting the mTOR signaling pathway in neuroendocrine tumors. *Curr Treat Options Oncol* **15**(3), 365–379.
- [131] Pavel ME, Hainsworth JD, Baudin E, Peeters M, Horsch D, Winkler RE, Klimovsky J, Lebwahl D, Jehl V, and Wolin EM, et al (2011). Everolimus plus octreotide long-acting repeatable for the treatment of advanced neuroendocrine tumours associated with carcinoid syndrome (RADIANT 2): a randomised, placebo-controlled, phase 3 study. *Lancet* **378**, 2005–2012.
- [132] Yao JC, Shah MH, Ito T, Bohas CL, Wolin EM, Van Cutsem E, Hobbday TJ, Okusaka T, Capdevila J, and de Vries EG, et al (2011). Everolimus for advanced pancreatic neuroendocrine tumors. *N Engl J Med* **364**, 514–523.
- [133] Liu E, Marincola P, and Öberg K (2013). Everolimus in the treatment of patients with advanced pancreatic neuroendocrine tumors: latest findings and interpretations. *Therap Adv Gastroenterol* **6**(5), 412–419.
- [134] Singh S, Carnaghi C, Buzzoni R, Pommier RF, Raderer M, Tomasek J, Lahner H, Valle JW, Voi M, and Bututeishvili-Pacaud L, et al (2016). Efficacy and safety of everolimus in advanced, progressive, nonfunctional neuroendocrine tumors (NET) of the gastrointestinal (GI) tract and unknown primary: a subgroup analysis of the phase III RADIANT-4 trial. *J Clin Oncol* **34**(Suppl. 4), 315. https://doi.org/10.1200/jco.2016.34.4_suppl.315.
- [135] Kulke MH, Lenz HJ, Meropol NJ, Posey J, Ryan DP, Picus J, Bergsland E, Stuart K, Tye L, and Huang X, et al (2008). Activity of sunitinib in patients with advanced neuroendocrine tumors. *J Clin Oncol* **26**, 3403–3410.
- [136] Raymond E, Dahan L, Raoul JL, Bang YJ, Borbath I, Lombard-Bohas C, Valle J, Metrakos P, Smith D, and Vinik A, et al (2011). Sunitinib malate for the treatment of pancreatic neuroendocrine tumors. *N Engl J Med* **364**, 501–513.
- [137] Yao JC, Phan A, Hoff PM, Chen HX, Charnsangavej C, Yeung SC, Hess K, Ng C, Abbruzzese JL, and Ajani JA (2008). Targeting vascular endothelial growth factor in advanced carcinoid tumor: a random assignment phase II study of depot octreotide with bevacizumab and pegylated interferon alpha-2b. *J Clin Oncol* **26**, 1316–1323.
- [138] Eads JR and Meropol NJ (2012). A new era for the systemic therapy of neuroendocrine tumors. *Oncologist* **17**(3), 326–338.
- [139] Kvols LK and Buck M (1987). Chemotherapy of endocrine malignancies: a review. *Semin Oncol* **14**, 343–353.
- [140] Strosberg JR (2014). Systemic treatment of gastroenteropancreatic neuroendocrine tumors (GEP-NETS): current approaches and future options. *Endocr Pract* **20**(2), 167–175.
- [141] Moertel CG, Hanley JA, and Johnson LA (1980). Streptozocin alone compared with streptozocin plus fluorouracil in the treatment of advanced islet-cell carcinoma. *N Engl J Med* **303**, 1189–1194.
- [142] Moertel CG, Lefkopoulo M, Lipsitz S, Hahn RG, and Klaassen D (1992). Streptozocin- doxorubicin, streptozocin-fluorouracil or chlorozotocin in the treatment of advanced islet-cell carcinoma. *N Engl J Med* **326**, 519–523.
- [143] Kouvaraki MA, Ajani JA, Hoff P, Wolff R, Evans DB, Lozano R, and Yao JC (2004). Fluorouracil, doxorubicin, and streptozocin in the treatment of patients with locally advanced and metastatic pancreatic endocrine carcinomas. *J Clin Oncol* **22**, 4762–4771.
- [144] Ramanathan RK, Cnaan A, Hahn RG, Carbone PP, and Haller DG (2001). Phase II trial of dacarbazine (DTIC) in advanced pancreatic islet cell carcinoma. Study of the Eastern Cooperative Oncology Group-E6282. *Ann Oncol* **12**(8), 1139–1143.
- [145] Moody CL and Wheelhouse RT (2014). The Medicinal Chemistry of Imidazotetrazine Prodrugs. *Pharmaceuticals (Basel)* **7**(7), 797–838.
- [146] Sharma J, Duque M, and Wasif Saif M (2013). Emerging therapies and latest development in the treatment of unresectable pancreatic neuroendocrine tumors: an update for clinicians. *Therap Adv Gastroenterol* **6**(6), 474–490.
- [147] Strosberg JR, Fine RL, Choi J, Nasir A, Coppola D, Chen DT, Helm J, and Kvols L (2011). First-line chemotherapy with capecitabine and temozolomide in patients with metastatic pancreatic endocrine carcinomas. *Cancer* **117**(2), 268–275.
- [148] Kotteas EA, Syrigos KN, and Wasif Saif M (2016). Profile of capecitabine/temozolomide combination in the treatment of well-differentiated neuroendocrine tumors. *Oncotargets Ther* **9**, 699–704.
- [149] D'Alpino Peixoto R, Noonan KL, Pavlovich P, Kennecke HF, and Lim HJ (2014). Outcomes of patients treated with capecitabine and temozolomide for advanced pancreatic neuroendocrine tumors (PNETs) and non-PNETs. *J Gastrointest Oncol* **5**(4), 247–252.
- [150] Pape UF, Perren A, Niederle B, Gross D, Gress T, Costa F, Arnold R, Denecke T, Plockinger U, and Salazar R, et al (2012). ENETS consensus guidelines for the management of patients with neuroendocrine neoplasms from the jejunum-ileum and the appendix including goblet cell carcinomas. *Neuroendocrinology* **95**(2), 135–156.
- [151] Filosso PL, Ferolla P, Guerrero F, Ruffini E, Travis WD, Rossi G, Lausi PO, and Oliaro A (2015). Multidisciplinary management of advanced lung neuroendocrine tumors. *J Thorac Dis* **7**(S2), S163–S171.
- [152] Ekeblad S, Sundin A, Janson ET, Welin S, Granberg D, Kindmark H, Dunder K, Kozlovacki G, Orlefors H, and Sigurd M, et al (2007). Temozolomide as monotherapy is effective in treatment of advanced malignant neuroendocrine tumors. *Clin Cancer Res* **13**(10), 2986–2991.
- [153] Strosberg JR, Coppola D, Klimstra DS, Phan AT, Kulke MH, Wiseman GA, Kvols LK, and North American Neuroendocrine Tumor Society (NANETS) (2010). The NANETS consensus guidelines for the diagnosis and management of poorly differentiated (high-grade) extrapulmonary neuroendocrine carcinomas. *Pancreas* **39**(6), 799–800.
- [154] Tang LH, Untch BR, Reidy DL, O'Reilly E, Dhall D, Jih L, Basturk O, Allen PJ, and Klimstra DS (2016). Well-differentiated neuroendocrine tumors with a morphologically apparent high-grade component: a pathway distinct from poorly differentiated neuroendocrine carcinomas. *Clin Cancer Res* **22**(4), 1011–1017.
- [155] Moertel CG, Kvols LK, O'Connell MJ, and Rubin J (1991). Treatment of neuroendocrine carcinomas with combined etoposide and cisplatin. Evidence of major therapeutic activity in the anaplastic variants of these neoplasms. *Cancer* **68**, 227–232.
- [156] Mityr E, Baudin E, Ducreux M, Sabourin JC, Ruffe P, Aparicio T, Lasser P, Elias D, Duvillard P, and Schlumberger M, et al (1999). Treatment of poorly differentiated neuroendocrine tumours with etoposide and cisplatin. *Br J Cancer* **81**, 1351–1355.
- [157] Welin S, Sorbye H, Sebjørgsen S, Knappskog S, Busch C, and Oberg K (2011). Clinical effect of temozolomide-based chemotherapy in poorly differentiated endocrine carcinoma after progression on first-line chemotherapy. *Cancer* **11**, 4617–4622.
- [158] Oronsky B, Scicinski J, Ning S, Peehl D, Oronsky A, Cabrales P, Bednarski M, and Knox S (2016). Rockets, radiosensitizers, and RRx-001: an origin story part I. *Discov Med* **21**(115), 173–180.
- [159] Carter CA, Schmitz B, Peterson PG, Quinn M, Degesys A, Jenkins J, Oronsky B, Scicinski J, Caroen S, and Reid TR, et al (2016). Immune reactivity and pseudoprogression or tumor flare in a serially biopsied neuroendocrine patient treated with the epigenetic agent RRx-001. *Case Rep Oncol* **9**(1), 164–170.
- [160] Carter CA, Oronsky B, Caroen S, Scicinski J, Degesys A, Cabrales P, Reid TR, and Brzezniak C (2016). Partial response in an RRx-001–primed patient with refractory small-cell lung cancer after a third introduction of platinum doublets. *Case Rep Oncol* **9**, 285–289.
- [161] Carter CA, Degesys A, Oronsky B, Scicinski J, Caroen SZ, Oronsky AL, Reid T, Cabrales P, and Roswarski J (2015). Flushing out carcinoid syndrome: beneficial effect of the anticancer epigenetic agent RRx-001 in a patient with a treatment-refractory neuroendocrine tumor. *Case Rep Oncol* **8**(3), 461–465.