

Fall 2003

Focal Spot, Fall/Winter 2003/2004

Follow this and additional works at: http://digitalcommons.wustl.edu/focal_spot_archives

Recommended Citation

Focal Spot, Fall/Winter 2003/2004, October 2003. Bernard Becker Medical Library Archives. Washington University School of Medicine.

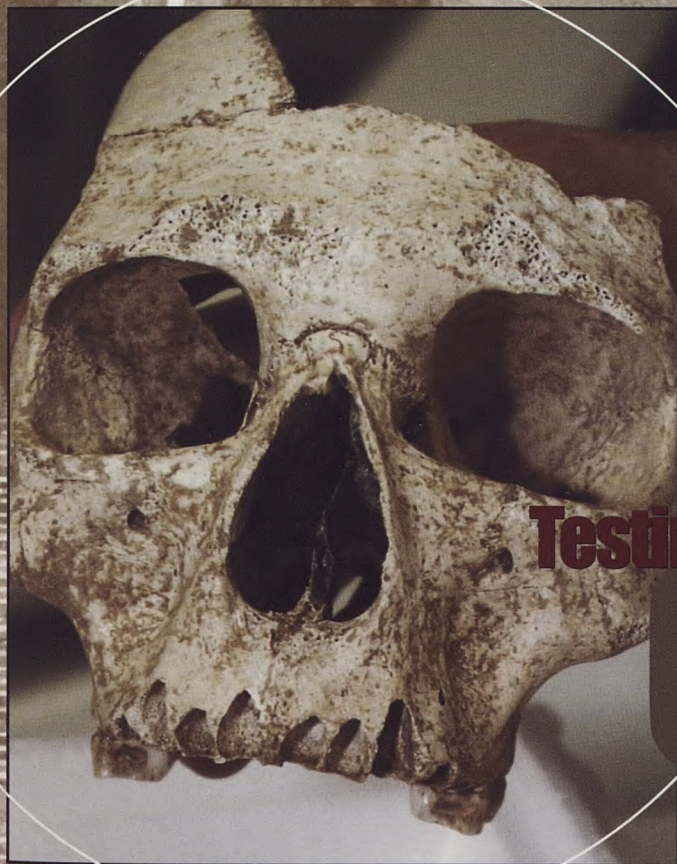This Book is brought to you for free and open access by the Focal Spot at Digital Commons@Becker. It has been accepted for inclusion in Focal Spot Archives by an authorized administrator of Digital Commons@Becker. For more information, please contact engeszer@wustl.edu.

FALL/WINTER 2003/2004

VOLUME 34, NUMBER 3

FOCAL SPOT

MALLINCKRODT INSTITUTE OF RADIOLOGY



Testing Theories of Our
Origins

This facial skeleton is part of a discovery found in Romania in a bear hibernation cave. While the fossil is still undergoing analysis, Washington University researchers believe it may be from a human who lived between 34,000 and 36,000 years ago, making it the earliest known modern human fossil in Europe. Turn to page 15 for more information.



CONTENTS

FOCAL SPOT

FALL/WINTER 2003/2004

VOLUME 34, NUMBER 3

BIOMED 21

4

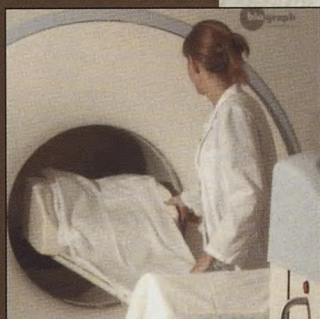
Washington University and the School of Medicine launched a strategic plan for developing a multidisciplinary approach to basic and clinical research, including an imaging facility dedicated to transferring laboratory concepts to clinical use.



TOOLS TO FIGHT LIVER CANCER

6

Radiologists and surgeons are collaborating on a new study to determine whether positron emission tomography and the radiopharmaceutical carbon-11-acetate can identify which patients with hepatocellular cancer are candidates for liver transplantation.



RSNA: COMMUNICATION FOR BETTER PATIENT CARE

10

Mallinckrodt Institute's role in the future of radiology was well represented at the 89th Scientific Assembly and Annual Meeting of the Radiological Society of North America.



TESTING THEORIES OF OUR ORIGINS

15

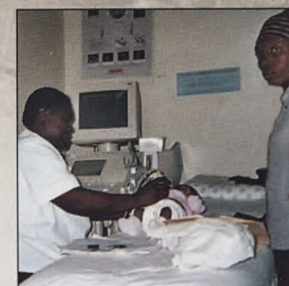Anthropologists were able to learn more about human evolution after prehistoric human bones found in a cave in Romania were brought to Mallinckrodt Institute for computed tomography scanning.




SOUTH AFRICA: A LAND OF CONTRASTS

20

As a Radiological Society of North America Visiting Professor, a Mallinckrodt Institute radiologist sees firsthand the urgent need for modern equipment and training in South African public hospitals.



2.....SPOT NEWS



24.....FYI

Visit the MIR web site at
www.mir.wustl.edu

ON THE COVER Mallinckrodt Institute has played an important role in helping anthropologists fill in one more piece of modern man's evolutionary puzzle. Illustration by R. G. Michaels.

SPOT NEWS

Michalski elected ACR fellow

Fellowship is one of the highest honors the American College of Radiology (ACR) bestows on a diagnostic radiologist, radiation oncologist, or medical physicist. Jeff Michalski, MD, associate professor of radiation oncology, recently joined the ranks of the approximately 10 percent of the 30,000 ACR members who have earned the distinction of fellowship.

Michalski is chief of the Clinical Division of the newly formed Department of Radiation Oncology. He specializes in genitourinary and pediatric radiation oncology and treats patients at Siteman Cancer Center in the Center for Advanced Medicine at Washington University Medical Center.


Since 1998, he has served on the Editorial Board of the *International Journal of Radiation Oncology, Biology, Physics* and on the Radiological Society of North America's Education Committee. He is chairman of the Image-Guided Radiation Therapy Committee of the Radiation Therapy Oncology Group and is a member of the ACR's Joint Economic Committee. Michalski completed a radiation oncology residency and fellowship at Washington University's Radiation Oncology Center and joined the faculty in 1991.

43-year cyclotron grant renewed

As principal investigator, Michael Welch, PhD, professor of radiology and of chemistry, received a \$2.2 million grant for support of Mallinckrodt Institute's "Cyclotron produced isotopes in biology and medicine" project. Subject to availability of funds from the National Institutes of Health (NIH), the grant could be renewed each year through 2008—for a grand total of \$11.4 million.

Michel Ter-Pogossian, PhD, received the initial NIH cyclotron grant in 1960, when the Institute's cyclotron began operation—the first of its kind in a United States medical center. Welch, cochief of the Division of Radiological Sciences and chief of the Radiological Chemistry Laboratory, believes the 43-year grant is Washington University's longest running research grant.

Under Ter-Pogossian's leadership, a team of scientists developed positron emission tomography (PET) in the early 1970s. PET is considered the most important breakthrough in modern medical technology by many clinicians and scientists. Cyclotrons produce the radionuclides for nuclear medicine imaging, particularly PET, used in the clinical management of patients and in biomedical research.




More than 1,300 people were in Forest Park to see and hear the Tour of Hope and five-time Tour de France champion Lance Armstrong in October. The 26-member Tour of Hope cycling team, sponsored by Bristol-Myers Squibb, made the 3,200-mile trip across the United States to promote cancer research. Timothy Eberlein, MD, Siteman Cancer Center director, (left) welcomed the Tour to St. Louis.

MIR part of brain exhibit

Brain: The World Inside Your Head, a traveling exhibition at the St. Louis Science Center, explores the fascinating dynamics, electrochemical workings, and diseases that occur inside our heads. The 12,000 square-foot interactive exhibit is open through May 2, 2004. Sponsored by Pfizer Inc. and produced in collaboration with the National Institutes of Health, *Brain* premiered at the Smithsonian Institution's Arts and Industries Building


in July 2001; the five-year tour includes 15 sites nationwide.

As part of the Science Center's focus on St. Louis' role in neurological research and clinical applications, Mallinckrodt Institute provided some visual and tactile components, including a display that chronicles the development of positron emission tomography (PET) in the early 1970s.



Second edition sonography reference available

Ultrasound: The Requisites, coauthored by William Middleton, MD, professor of radiology, is part of *The Requisites™ in Radiology* series published by Mosby Inc. The 610-page book provides a well-organized, concise overview of sonography, while addressing four main areas of ultrasound: general, vascular, obstetrics, and gynecology. Added attractions—new chapters on practical physics, general abdomen, extremities, lower genitourinary, and neck and chest; chapter summaries (called “Key Features”); more than 1,800 high quality, comprehensive illustrations; over 175 color Doppler images; and suggested reading lists at the end of each chapter—complement the focused, easy-to-read text. Reviewers have called *Ultrasound: The Requisites* “a must-have for radiology residents as well as general radiologists who want to stay abreast of clinical sonographic applications.” It is currently the best selling ultrasound textbook on the market.



William Middleton, MD, is shown at the 2003 RSNA meeting in Chicago where, for the first time, the second edition of *Ultrasound: The Requisites* and other radiology textbooks were available for attendees to peruse and purchase.

care. *America's Top Doctors* lists 4,254 physicians, who were selected from more than 20,000 candidates.

Diagnostic Radiology

DeWitte Cross, MD
Michael Darcy, MD
David Hovsepian, MD
William McAlister, MD
Barbara Monsees, MD
Stuart Sagel, MD

Nuclear Medicine

Barry Siegel, MD

Radiation Oncology

Robert Myerson, MD, PhD
Marie Taylor, MD

Joint Radiology Appointments

Diana Gray, MD
Robert Grubb, MD
Jeffrey Marsh, MD
Joel Perlmutter, MD
Gregorio Sicard, MD

America's top doctors named

It's official—Mallinckrodt Institute is staffed by some of America's top doctors, according to a directory of leading physicians in the United States and Canada. Castle Connolly Medical Ltd., the publishing company, polls thousands of physicians, asking to whom they would refer friends and family for medical

Distinguished teachers honored

Washington University medical students honored the best medical educators during the annual awards ceremony held in October at the Eric P. Newman Education Center. Among those honored were MIR's Mokhtar Gado, MD, professor of radiology; Sanjeev Bhalla, MD, assistant professor of radiology; and Joel Perlmutter, MD, professor of neurology, of neurological surgery, and of radiology.

Distinguished Service Teaching awards were presented to Gado by the Class of 2007 and to Perlmutter by the Class of 2005. Bhalla was named Lecturer of the Year by the Class of 2006.



Robin Haverman, RT, accepted a Community Collaborative Impact Award from Kerry Brooks, American Cancer Society Heartland Division, in recognition of Washington University's participation in the National Lung Screening Trial. David Gierada, MD, associate professor of radiology, is the University's principal investigator for this NCI-sponsored study to determine whether lung cancer deaths can be reduced by early detection.

BioMed 21




A

t a news conference in November, Chancellor Mark Wrighton announced a strategic plan for developing a multidisciplinary approach to basic and clinical research. In a nod to its potential for advancing biomedical research and clinical practice in the 21st century, the new initiative is called "BioMed 21." •

At the heart of BioMed 21 is the School of Medicine's internationally recognized Genome Sequencing Center, where more than one third of the human genome was decoded. According to the National Human Genome Research Institute (an affiliate of the National Institutes of Health) official statement, *A Vision for the Future of Genomics Research*, "More complex

genomic data...have transformed the study of virtually all life processes. The genomic approach of technology development...has introduced an important new dimension into biological and biomedical research." • BioMed 21 involves renovation of existing space and construction of two new facilities to house three new research units: the Genome Sci-



Artist's concept of the to-be-designed
translation research facility
on the southwest corner of
Euclid Avenue and Children's Place.

ences and Human Genetics Program, the Division of Clinical Sciences, and the Center for Biological Imaging. Collaborative research will include faculty from the University's schools of Medicine, Engineering, and Arts and Sciences; more than 50 new faculty members will be recruited. • It is in the Center for Biological Imaging that Mallinckrodt Institute's nearly 75

years of experience will be evident. According to Gilbert Jost, MD, chairman of the Department of Radiology and director of Mallinckrodt Institute, the center will help biological imaging progress from focusing on gross anatomy to the delicate molecular interactions that underlie cellular and genetic processes. To accomplish that goal, researchers will develop new

and improved imaging techniques for visualizing processes at the cellular level. And in the planning stages is an imaging facility dedicated to transferring imaging concepts from the laboratory to clinical use. • With BioMed 21, St. Louis will have the necessary tools to sustain its position as an international leader in plant and life sciences and in biomedicine. **MIR**



Tools to Fight LIVER CANCER

by Candace O'Connor

NOT ONLY IS HEPATOCELLULAR CANCER (HCC) A GROWING PROBLEM IN THE UNITED STATES, WITH 12,000 NEW CASES EACH YEAR, BUT IT HAS ALSO BECOME ONE OF THE MOST COMMON CAUSES OF CANCER DEATHS WORLDWIDE. A KEY REASON IS THE MARKED INCREASE IN CASES OF HEPATITIS C, A VIRAL INFECTION THAT CAN LEAD TO CIRRHOSIS OF THE LIVER AND OFTEN TO CANCER. AMONG THESE PATIENTS, SURGEONS CAN EXCISE THE TUMOR ONLY 10 PERCENT TO 15 PERCENT OF THE TIME, AND EVEN THEN THE RECURRENCE RATE IS CLOSE TO 50 PERCENT. PATIENTS WITH HCC HAVE HISTORICALLY FACED A DISMAL OUTCOME, WITH MEDIAN SURVIVAL RATES OF JUST THREE MONTHS TO SIX MONTHS. BUT RECENTLY, THAT PICTURE HAS BEEN CHANGING. "AN IMPORTANT NEW DEVELOPMENT IS THAT LIVER TRANSPLANTATION HAS BECOME CRITICALLY IMPORTANT FOR THESE PATIENTS IF THE DISEASE HAS NOT METASTASIZED," SAYS WILLIAM CHAPMAN, MD, CHIEF OF ABDOMINAL TRANSPLANTATION AND PROFESSOR OF SURGERY.

However, surgeons must be certain that no metastasis has occurred, and that is where Mallinckrodt Institute of Radiology (MIR) comes in. Chapman; Barry Siegel, MD, chief of MIR's Division of Nuclear Medicine; and several colleagues are recruiting patients for a new study to determine whether positron emission tomography (PET) and carbon-11 acetate, a promising radiopharmaceutical produced at the Institute, can help pinpoint those patients who would benefit from surgery.

"We are hoping, through this study, to develop a routine test that can be used to screen patients with HCC who are candidates for liver transplantation, identifying those who should and should not be going to the operating room," says Siegel, professor of radiology and of medicine.

11C-acetate and liver cancer

In 2003, a study from Hong Kong led by Chi-Lai Ho, MD, a former MIR resident, was published in the *Journal of Nuclear Medicine*. The study involved 57 patients with liver tumors and compared the use of FDG and 11C-acetate. "They found that the better differentiated tumors were easier to see with acetate, and the poorly differentiated tumors were easier to see with FDG," says Siegel. "That makes sense for a variety of biochemical reasons, and their results were very promising."

At about the time this study was published, Chapman joined the Washington University in St. Louis faculty. He and Siegel began discussing possible joint projects and, in light of the Hong Kong study results, decided to do a pilot study of acetate imaging

and FDG in staging the subgroup of HCC patients being considered for a liver transplant or other hepatic-directed therapies. They knew that using FDG alone in HCC had previously been limited because of false negatives.

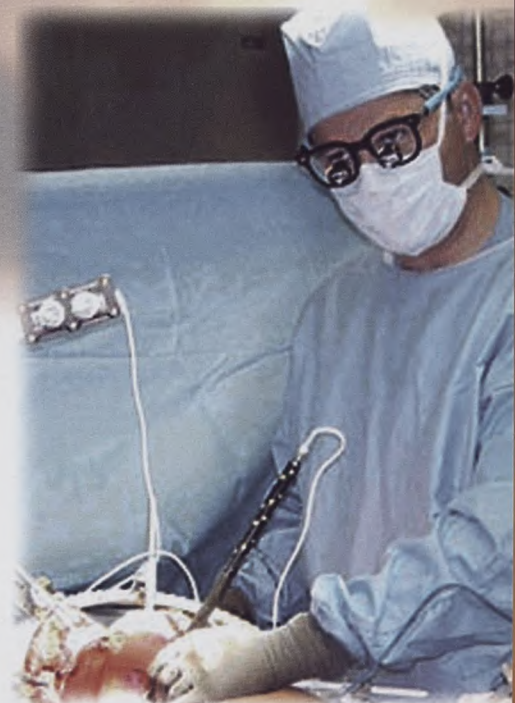
"In one third to one half of all cases, HCC will not trap FDG, but we still need to see whether the tumor has spread and where," says Chapman. "So the use of eleven C-acetate potentially could be a huge plus."

The study, which is funded by the Alvin J. Siteman Cancer Center, has three goals:

- estimate the sensitivity of PET with FDG and 11C-acetate in detecting HCC
- determine whether PET identifies any disease sites not detected by conventional imaging, such as CT scans or MRI
- assess the impact of FDG and 11C-acetate PET in managing HCC patients.

Potential impact

HCC has long been a disease with few therapeutic options, but recently the results of liver transplantation have been very favorable when the disease is detected early enough. Once HCC has metastasized, replacing the liver is actually counterproductive, since immunosuppressive drugs required after the transplant will



Surgeon William Chapman

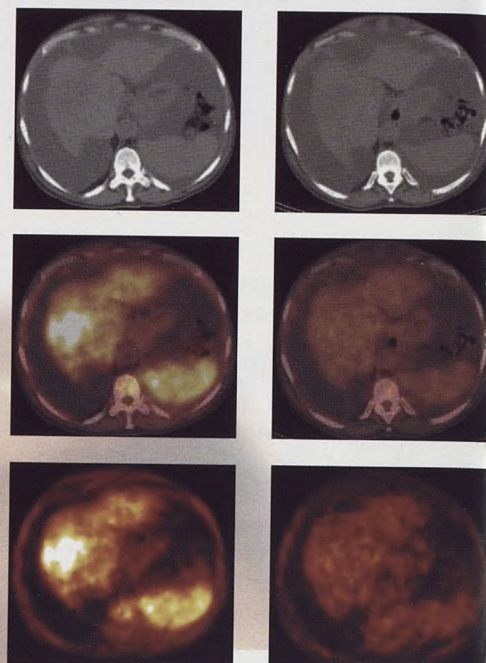
Tools to Fight LIVER CANCER

only encourage the growth of the metastatic disease.

But transplant results in patients with early-stage HCC have been so positive that the United Organ Sharing Network (UNOS) has changed its allocation procedures to give these patients higher priority, allowing them to be transplanted quickly. According to recent studies, when patients with hepatitis-C and with stage I or stage II HCC are transplanted, their five-year survival is around 70 percent—about the same as for patients with hepatitis-C who do not have cancer. And Washington University surgeons have had favorable results in patients with slightly more advanced cancers.

In their one-year study, Chapman and Siegel hope to sharpen the

These PET/CT images are of a 62-year-old man whose large hepatocellular carcinoma was first detected by CT imaging. Scans on left obtained with ^{11}C -acetate (AC); on right, with fluorodeoxyglucose (FDG). The PET/CT scan using AC shows uptake only in the liver. Instead of undergoing surgery, the patient is being treated with chemoembolization by Doctor Daniel Brown in the Institute's interventional radiology section. If chemoembolization reduces the size of the tumor, the patient will be a candidate for liver transplantation.



differentiation between early-stage and metastatic disease, so transplants will only go to those patients who can benefit from them. They will look at 30 patients with HCC who have been staged using conventional imaging studies and

determined to be potential transplantation candidates. Then these patients will undergo back-to-back PET studies on the PET/CT scanner, using both ^{11}C -acetate and FDG.

NEW STUDY TO DETECT PROSTATE CANCER RECURRENCE

To combat prostate cancer, the second-leading cause of cancer deaths among American men, physicians and surgeons have a great need for better imaging. Computed tomography (CT) scans do not work well; magnetic resonance imaging (MRI) is cumbersome and limited.

"When physicians think of cancer imaging these days, probably the first thing that comes to mind is positron emission tomography [PET, which was developed at Mallinckrodt Institute in the 1970s]," says Tom Miller, MD, PhD. "But unfortunately, the FDG tracer, which is extremely successful in most tumors, is just not effective in PET. So that has led us to find a different PET pharmaceutical that will work effectively."

In the first phase of their work, funded by the Alvin J. Siteman Cancer Center and the CaPCURE Foundation, Miller and his colleagues compared FDG with ^{11}C -acetate in 60 patients who underwent both types of imaging on the same

day. The results, published in the *Journal of Nuclear Medicine* in 2003, showed that ^{11}C -acetate was far superior to FDG.

With these findings, Miller and a group of colleagues applied for and received a grant from the National Cancer Institute; work began in September 2003. This time, their project will not involve FDG but will focus on ^{11}C -acetate only, targeting patients with new diagnoses of prostate cancer, in whom the conventional work-up showed no spread outside the prostate gland.

"We are studying whether the conventional imaging methods, including CT, perhaps missed the spread of disease outside the prostate. Can this new PET scan find a tumor in the lymph nodes of the pelvis or the abdomen? When there is such disease, the patient should not have radical surgery or even conventional radiation therapy," says Miller.

If a patient's PSA blood test is fairly low, it is unlikely that such metastasis has occurred. This new project is limited to newly diagnosed patients who have PSA test results of 10 or greater and Gleason biopsy scores of 7 or more. To date, four

patients have been tested; a suspicious lymph node that was not evident on the CT scan was found in one patient. Miller hopes to study 250 patients over the duration of the project.

Miller credits several Washington University departments, particularly the urology service, for their strong cooperation in referring patients to this project and his earlier studies. Doctors Gerald Andriole and Adam Keibel in urology, and Jeff Michalski in radiation oncology have been especially helpful.

"If this study works, those patients found to have unsuspected spread outside the prostate would be spared the morbidity of radical surgery. Those men who were planning to have radiation therapy might have a better chance of a cure if the radiation oncologist knows about the spread of the tumor," says Miller. "This study could have a big payoff for this fraction of men with prostate cancer."

Editor's Note: Physicians wishing to refer patients to this study can call 314-362-2809.

The results will provide important preliminary data as to the accuracy of PET in HCC. If it shows strong potential, Chapman and Siegel will move ahead on a multi-institutional trial to amass an even larger body of evidence. "PET has played a major role in the management of other liver tumors," says Chapman. "It is a standard technique for better selection and probably for improved patient outcomes. If we could find a better tracer to use, we are optimistic that PET would be even more beneficial and could help us more appropriately select patients who are eligible for surgery." **MIR**

Editor's Note: Physicians wishing to refer a patient for this study can call 314-362-7792.

The background of ^{11}C -acetate

^{11}C -acetate is available at only a few institutions; because of its short half-life (only 20 minutes), it must be prepared on site. Other tracers used in PET scanning, such as ^{18}F -Fluorodeoxyglucose (FDG), have a much longer half-life (110 minutes) and can be put on a truck or an airplane for regional distribution. In the St. Louis area, FDG is produced by several manufacturers, but Mallinckrodt Institute produces the tracer in its own cyclotron facility (under the direction of Michael Welch, PhD, cochief of MIR's Division of Radiological Sciences, and the supervision of Sally Schwarz, RPh) and distributes it throughout the area.

MIR's cyclotron also produces ^{11}C -acetate, but here the Institute is in much more select company. Only a handful of other centers in the United States can produce this radiopharmaceutical, including the University of California Los Angeles, the University of Michigan, and Vanderbilt University.

In fact, MIR's involvement with ^{11}C -acetate dates back 25 years to a collaboration between Welch and Steven Bergmann, MD, PhD, (then in the Washington University cardiology department but now director of nuclear cardiology at Columbia University) and other colleagues. They developed this new tracer—using it first for studies in isolated hearts, then in animal models and finally in humans—to study the oxidative metabolism of the myocardium.


During the mid 1980s, Siegel and Robert Gropler, MD, chief of MIR's cardiovascular imaging laboratory, showed the early uptake of ^{11}C -acetate in heart patients was proportional to myocardial blood flow. Gropler went on to demonstrate that this tracer was perhaps the best overall for showing whether heart tissue was viable. Today, he is a noted expert in using this tracer and other tools to characterize cardiac metabolism.

Other uses of radiopharmaceuticals in cancer

Both ^{11}C -acetate and FDG with PET have been used successfully in treatment planning for other forms of cancer. Tom Miller, MD, PhD, professor of radiology and of biochemical engineering, has studied FDG-PET to rate the size and shape of cervical tumors prior to therapy. Others have used this tracer to detect metastatic disease in colon cancer patients, a capability that has led to changes in their management fully 25 percent of the time. FDG has also proven valuable in patients with breast and lung cancer and melanoma. Radiologists have also done promising preliminary work with ^{11}C -acetate, using it to image kidney tumors that could not be seen as well with FDG.

Recent investigation by Miller has shown that ^{11}C -acetate is more effective in detecting prostate cancer recurrence; he is currently engaged in another study that will look at its use in finding lymph node metastases in newly diagnosed, high-risk prostate cancer patients.

Why does FDG work well in colon cancer but not in prostate? "FDG is an analog of glucose, a sugar. Since prostate cancer is well known to be slow growing, it doesn't have as great a need for energy, or for a lot of sugar. That is why it doesn't seem to work well with this otherwise successful tracer," says Miller.



RSNA

Communication for Better Patient Care

THE 89TH SCIENTIFIC ASSEMBLY AND ANNUAL MEETING OF THE RADIOLOGICAL SOCIETY OF NORTH AMERICA (RSNA) HIGHLIGHTED LEADING-EDGE RESEARCH AND STATE-OF-THE-ART TECHNOLOGY. IN THE OCTOBER 2003 ISSUE OF *RSNA NEWS*, GEORGE BISSET, MD, CHAIRMAN OF THE RSNA SCIENTIFIC PROGRAM COMMITTEE, SAID "THE IMPORTANCE OF THE SCIENTIFIC PROGRAM AT RSNA 2003 FOR RADIOLOGISTS IS THAT THEY CAN GET A PEEK AT THE FUTURE OF THE SPECIALTY."



THAT FUTURE WAS REFLECTED IN THE ABSTRACT TOPICS PRESENTED NOVEMBER 30 THROUGH DECEMBER 5, INCLUDING EMERGENCY RADIOLOGY, MULTIMODALITY IMAGING (SUCH AS PET-CT FUSION IMAGING FOR TUMORS), AND COMPUTER-ASSISTED DIAGNOSIS. AS SHOWN HERE, MALLINCKRODT INSTITUTE'S ROLE IN THE FUTURE OF RADIOLOGY WAS WELL REPRESENTED THROUGH FACULTY PARTICIPATION IN SCIENTIFIC SESSIONS, REFRESHER COURSES, AND EXHIBITS.

(left to right) Doctors Robert Gropler, Dennis Balfe, Vamsidhar Narra, Pamela Woodard, and William McAlister.

MIR PRESENTATIONS AT RSNA 2003

Ty Bae, MD, PhD, presiding officer and moderator, Gastrointestinal (abdominal CT: contrast medium administration).

Dennis Balfe, MD, moderator, Gastrointestinal (gallbladder and bile ducts: CT, MR).

Jay Heiken, MD, faculty, Scientific Program Committee; moderator, Gastrointestinal (focal liver lesions: detection and characterization—CT, MR).

David Hovsepian, MD, moderator, Gastrointestinal liver, biliary: interventional radiology.

Robert McKinstry, MD, PhD, moderator, Neuroradiology/head and neck (central nervous system wiring diagram I).

Christine Menias, MD, moderator, Gastrointestinal (emergency radiology: acute appendicitis, abdominal trauma).

Christopher Moran, MD, moderator, Neuroradiology/head and neck (all about aneurysms I).

Vamsidhar Narra, MD, presiding officer and moderator, Gastrointestinal (liver: hepatocellular carcinoma—CT, MR).

Joshua Shimony, MD, PhD, moderator, Neuroradiology/head and neck (trauma).

Barry Siegel, MD, director, PET in clinical practice minicourse: basic principles; director, PET in clinical practice minicourse: neurologic and cardiologic applications; director, PET in clinical practice minicourse: oncologic PET I; director and moderator, PET in clinical practice minicourse: Oncologic PET II.

Marilyn Siegel, MD, director, Screening for cancer minicourse: basic tenets of screening; director, Screening for cancer minicourse: lessons from mammography; director, Screening for cancer minicourse: CT colonography and total body imaging; director, Screening for cancer minicourse: lung cancer screening.

William Totty, MD, moderator, Musculoskeletal (sports injuries).

Franz Wippold, MD, moderator, Neuroradiology/head and neck (1.5 vs 3.0).

SPECIAL FOCUS SESSION

James Blaine, DSc, "Role of open source software in radiology."

REFRESHER COURSES

Dennis Balfe, MD, "Cross-sectional imaging of the biliary ducts (An interactive session)."

Farrokh Dehdashti, MD, "Oncologic PET: tumor diagnosis and status."

Perry Grigsby, MD, "PET imaging in radiation treatment: cervix II—clinical."

Robert Gropler, MD, "PET in clinical practice minicourse: neurologic and cardiologic applications—cardiac PET"; "Imaging myocardial infarcts with MR and PET."

Jay Heiken, MD, "Imaging of focal liver lesions with CT and MR."

David Hovsepian, MD, "Hysterosalpingography and selective salpingography (How-to-workshop)."

William McAlister, MD, "Case-based review of pediatric radiology—musculoskeletal: metabolic, dysplasias."



Elizabeth McFarland, MD, "Screening for cancer minicourse: CT colonography and total body imaging—CT colonography: techniques and interpretation"; "CT colonography."

William Middleton, MD, "There are nonhyperechoic lesions in the liver: What does that mean?"

Mark Mintun, MD, "Brain PET: approach to the image and use in dementia."

Barbara Monsees, MD, "Screening for cancer minicourse: lessons from mammography—Breast cancer screening: the track record"; "Problem-solving breast imaging: supplementary mammographic views, US, and MR."

Vamsidhar Narra, MD, "Imaging of focal liver lesions with CT and MR"; "Cross-sectional imaging of the biliary ducts (An interactive session)."

Barry Siegel, MD, "Oncologic PET: monitoring and predicting response to treatment."

Marilyn Siegel, MD, "Post-transplantation lymphoproliferative disorders: a primer—risk factors and incidence: chest post-transplantation lymphoproliferative disorders"; "Advanced CT in pediatrics—pediatric multislice CT: applications and techniques."

Sharlene Teefey, MD, "Update course in diagnostic radiology: findings at ultrasound—What do they Mean? musculoskeletal—This rotator cuff looks abnormal: What does that mean?"

Pamela Woodard, MD, "Cardiac MR/CT: read cases with the experts (An interactive session)"; "Cardiovascular MR: cardiac."

SCIENTIFIC SESSIONS

Ty Bae, MD, PhD; Victoria Chen; Charles Hildebolt, DDS, PhD; Jie Zheng, PhD, "Dynamic MR contrast enhancement characteristics of breast cancer: effect of contrast injection rate."

Ty Bae, MD, PhD; Yonghum Na, MS, "Automated detection of polyps from multi-slice CT images using 3D morphologic matching algorithm."

Ty Bae, MD, PhD; Fang Zhu, MD, PhD, "MR imaging to assess the progression of polycystic kidney disease: one-year follow-up study."

Ty Bae, MD, PhD; Fang Zhu, MD, PhD; Paul Commean; Saulo Klahr, MD, "Kidney volume measurement in PKD using MRI: comparison of ellipsoidal, boundary-tracing, and stereology methods."

RSNA RECOGNITION AWARDS

Resident Research Trainee Prize

Cheng Hong, MD, PhD, "Effects of heart rate and measurement methods on interscan variability of coronary artery calcium quantification on multi-detector row CT"

MIR EXHIBIT AWARD WINNERS

Cum Laude

Christine Menias, MD; Jennifer Lee, MD; Christine Appleton, MD; Sanjeev Bhalla, MD; Alvaro Huete, MD; Dennis Balfe, MD, "Shock viscera: multidetector row CT evaluation."

Certificate of Merit

Sanjeev Bhalla, MD, "CT evaluation of primary peritoneal neoplasms."

Khaled Elsayes, MD; Govind Mukundan, MD; Vamsidhar Narra, MD; Christine Menias, MD; Jay Heiken, MD, "MR imaging of the spleen: spectrum of abnormalities."

Michael Gelbart, MD; Ashesh Parikh, MD; Louis Gilula, MD; Wincha Chong, MD, "Flexor hallucis longus tenography: a novel approach to access."

Christine Menias, MD; Brett Gratz, MD; Jennifer Lee, MD; Dennis Balfe, MD, "Imaging Meckel's diverticulum: pictorial review."

Govind Mukundan, MD; Khaled Elsayes, MD; Vamsidhar Narra, MD; Srinivasa Prasad, MD; Cary Siegel, MD; Jeffrey Brown, MD, "Endovaginal MR imaging of female urethra."

Creed Rucker, MD; Christine Menias, MD; Sanjeev Bhalla, MD; Dennis Balfe, MD, "Blood in the belly: CT evaluation of hemoperitoneum."

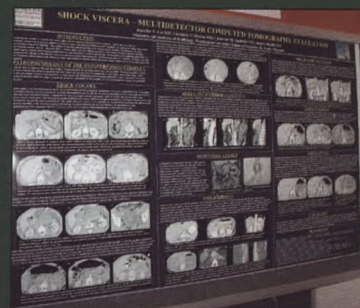
Excellence in Design

Sanjeev Bhalla, MD; Christine Menias, MD; Marilyn Siegel, MD; Fernando Gutierrez, MD, "Multi-detector row CT of the interatrial septum."

Christine Peterson, MD; Christine Menias, MD; Sanjeev Bhalla, MD; Dennis Balfe, MD, "Intussusception in adults: imaging features."

Sanjeev Bhalla, MD;

Amy Nordmann, MD; Christine Menias, MD; Stuart Sagel, MD; Fernando Gutierrez, MD, "Level 6 vessels: normal vessels and vascular variants that may mimic paraortic (Arch) lymphadenopathy."



RSNA

Steven Don, MD; Bruce Whiting, PhD; Charles Hildebolt, DDS, PhD; Glenn Fletcher, PhD; Joel Pomerantz, MD, "Computed radiography neonatal chest imaging: image contrast as a function of kVp and mAs."

Steven Don, MD; Glenn Fletcher, PhD; Charles Hildebolt, DDS, PhD; Lois Rutz, MS; Bruce Whiting, PhD, "Tissue-mimicking neonatal chest phantom."

Cheng Hong, MD, PhD; Thomas Pilgram, PhD; Fang Zhu, MD, PhD; Ty Bae, MD, PhD, "Effects of heart rate and measurement methods on interscan variability of coronary artery calcium quantification on multi-detector row CT."

Jin H. Kim, MD, PhD; Jin S. Kim; Ty Bae, MD, PhD, "Automated detection of pulmonary nodules from multi-slice CT images of varying slice thickness and reconstruction interval."

Edward Lee, MD, MPH; Marilyn Siegel, MD; Fernando Gutierrez, MD, "Chest radiographic findings of atrial septal occluders in pediatric patients."

Robert Malyapa, MD, PhD; Sasa Mutic, MS; Perry Grigsby, MD; Tom Miller, MD, PhD; Daniel Low, PhD, "A treatment planning study comparing brachytherapy and intensity modulated radiation therapy for cervical cancer."

Fang Zhu, MD, PhD; Ty Bae, MD, PhD, "MR imaging of plantar fasciitis before and after extracorporeal shock-wave therapy."

Fang Zhu, MD, PhD; Ty Bae, MD, PhD, "Hepatic cyst volume measurement in PKD using MRI in CRISP cohort."

SCIENTIFIC EXHIBITS

Louis Gilula, MD, "Fluoroscopically guided scapulothoracic injections."

Creed Rucker, MD; Christine Menias, MD; Sanjeev Bhalla, MD; Dennis Balfe, MD, "Blood in the belly: CT evaluation of hemoperitoneum."

Creed Rucker, MD; Christine Menias, MD; Sanjeev Bhalla, MD; Jay Heiken, MD; Dennis Balfe, MD, "Mimics of renal colic: clinically unsuspected diagnoses on renal stone protocol MDCT."

Christine Menias, MD; Jennifer Lee, MD; Christine Appleton, MD; Sanjeev Bhalla, MD; Alvaro Huete, MD; Dennis Balfe, MD, "Shock viscera: multi-detector row CT evaluation."

Christine Menias, MD; Christine Peterson, MD; Catherine Appleton, MD; Jennifer Lee, MD; Dennis Balfe, MD, "Abdominal manifestations of diabetes: multimodality review."

RSNA 2003 FACTS AND FIGURES

- Nearly 100 new companies exhibited for the first time at RSNA.
- Approximately 438,850 square feet used for exhibit space.
- More than 633 companies registered to exhibit.
- There were 76 Integrating the Healthcare Enterprise (IHE) workshops.
- Unaudited total attendance estimated at 58,959.
- 2003 meeting attendance was up by an estimated 4 percent as compared to the 2002 meeting.
- More than 2,100 scientific presentations were given during the six-day meeting.

Cynthia Santillan, MD; Christine Menias, MD; Sanjeev Bhalla, MD, "CT of urinary tract trauma: what the urologist wants to know."

Christine Menias, MD; Brett Gratz, MD; Jennifer Lee, MD; Dennis Balfe, MD, "Imaging Meckel's diverticulum: pictorial review."

Christine Peterson, MD; Christine Menias, MD; Sanjeev Bhalla, MD; Dennis Balfe, MD, "Intussusception in adults: imaging features."

Sanjeev Bhalla, MD, "CT evaluation of primary peritoneal neoplasms."

Sanjeev Bhalla, MD, "CT evaluation of non-neoplastic peritoneal conditions."

Christine Menias, MD; Christine Peterson, MD; Sanjeev Bhalla, MD; Srinivasa Prasad, MD; Dennis Balfe, MD, "Imaging abdominal sarcoid: spectrum of disease."

Kevin Lee, MD; Sanjeev Bhalla, MD; Christine Menias, MD; Jin Kim, MD, PhD; Fernando Gutierrez, MD, "Cardiac pseudomasses: normal structures that may mimic tumors and clot on CT and MR."

Sanjeev Bhalla, MD; Christine Menias, MD; Marilyn Siegel, MD; Fernando Gutierrez, MD, "Multi-detector row CT of the interatrial septum."

Andrew Bierhals, MD; Sanjeev Bhalla, MD; Madelyn Stazzone, MD; Fernando Gutierrez, MD, "CT and MRI findings in conditions that manifest with cyanosis and decreased pulmonary vascularity."

Sanjeev Bhalla, MD; Amy Nordmann, MD; Christine Menias, MD; Stuart Sagel, MD; Fernando Gutierrez, MD, "Level 6 vessels: normal vessels and vascular variants that may mimic paraortic (Arch) lymphadenopathy."

Sanjeev Bhalla, MD, "Chest radiographic manifestations of gastrointestinal disease."

Anil Khosla, MD; Khaled Elsayes, MD, "Pediatric oncologic imaging of spine."

Khaled Elsayes, MD; Paul Stavetig, MD; Govind Mukundan, MD; Anil Khosla, MD; David Rubin, MD, "Value of MR imaging for muscle denervation syndromes of the shoulder girdle."

Khaled Elsayes, MD; Govind Mukundan, MD; Vamsidhar Narra, MD; Aamer Farooki, MD; Jeffrey Brown, MD, "Adrenal masses: MR imaging features with pathologic correlation."

Khaled Elsayes, MD; Markus Lammle, MD; William Totty, MD; Paul Stavetig, MD; David Rubin, MD, "Value of MR imaging in muscle trauma."

Khaled Elsayes, MD; Govind Mukundan, MD; Vamsidhar Narra, MD; Christine Menias, MD; Jay Heiken, MD, "MR imaging of the spleen: spectrum of abnormalities."

Khaled Elsayes, MD; Paul Stavetig, MD; Vamsidhar Narra, MD; Jeffrey Brown, MD, "MR imaging of the peritoneum: spectrum of abnormalities."

Khaled Elsayes, MD; Vamsidhar Narra, MD; Christine Menias, MD; Jeffrey Brown, MD, "MR imaging of adrenal and extra-adrenal pheochromocytomas."

Khaled Elsayes, MD; Yuming Yin, MD; Vamsidhar Narra, MD; Markus Lammle, MD; Govind Mukundan, MD; Jay Heiken, MD, "Focal hepatic lesions: differential enhancement pattern approach with 3D gradient echo post contrast MR imaging."

Michael Gelbart, MD; Ashesh Parikh, MD; Louis Gilula, MD; Wincha Chong, MD, "Flexor hallucis longus tenography: a novel approach to access."

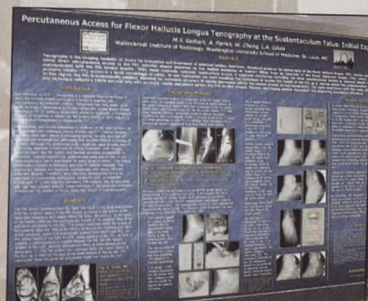Govind Mukundan, MD; Khaled Elsayes, MD; Vamsidhar Narra, MD; Srinivasa Prasad, MD; Cary Siegel, MD; Jeffrey Brown, MD, "Endovaginal MR imaging of female urethra."

Kianoush Rezaei, MD; Vamsidhar Narra, MD; Robert McKinstry, MD, PhD; Marilyn Siegel, MD; Jeffrey Brown, MD, "Practical MRI of the fetus: principles and applications."

CASE OF THE DAY

Sanjeev Bhalla, MD—Chest

Sanjeev Bhalla, MD—Gastrointestinal



The Annual MIR/RSNA Reception

APPROXIMATELY 200 FACULTY, ALUMNI, AND FRIENDS OF THE INSTITUTE HAD A CHANCE TO CATCH UP ON MIR NEWS AND TO SEE FORMER COLLEAGUES AT THE GOURMET BUFFET AND COCKTAIL RECEPTION HELD IN THE HYATT REGENCY'S CRYSTAL BALLROOM ON DECEMBER 1. THIS EVENT HAS BEEN CO-SPONSORED FOR THE PAST THREE YEARS BY MIR AND SIEMENS MEDICAL SOLUTIONS.



(Left to right) Doctors Ty Bae, assistant professor of radiology; Mary Mahoney; and Bruce McClennan, former chief of MIR's abdominal radiology



Alumnus Andrew Tievsky, MD, and William Totty, MD, professor of radiology



Siemens Medical Solutions' Professor Erich Reinhardt (left) and Tom McCausland (right) visit with Gilbert Jost, MD, director of Mallinckrodt Institute.



Isidro Huete, MD, MIR alumnus; Janet Brink; and (right) Gary Brink, director of radiology, Barnes-Jewish Hospital



Lawrence Tang, MD, diagnostic radiology cochief resident; Naveen Parti, MD, neuroradiology clinical fellow; and Peggy Jost



Alumni James Junker, MD, and David DiSantis, MD



Christine Menias, MD, assistant professor of radiology, and MIR alumnus Martin Abari, MD

RSNA

RSNA HISTORY

- The Radiological Society of North America (RSNA) was begun in December 1915 by four Midwestern radiologists—three of whom were from St. Louis.
- The regional Western Roentgen Society, as RSNA was originally called, was to be independent from the American Roentgen Ray Society (ARRS), the dominant radiology organization that was comprised mostly of radiologists from the Eastern states.
- The first meeting was held on December 15 and 16, 1915, in downtown Chicago because it was deemed a central location that was convenient for most Midwestern radiologists.
- The first Gold Medal Award was presented in 1917 to Heber Roberts, MD, a St. Louis radiologist and charter member of the Western Roentgen Society.
- The first issue of the *Journal of Roentgenology*, the new society's first medical publication, was published in 1918.
- The Western Roentgen Society was renamed the Radiological Society of North America in 1919; that same year, the *Journal of Roentgenology* was renamed the *Journal of Radiology*.
- In 1975 the RSNA Annual Meeting moved from its cramped quarters in Chicago's Palmer House hotel to the more spacious convention center called McCormick Place—more than 12,000 radiologists and exhibitors attended the six-day meeting.


Editor's Note: This information was extracted from the 25-part "History of the Radiological Society of North America," which is on the RSNA's web site at www.rsna.org/about/history.



(Left) Kevin McNery, MD, and Clark West, MD—former faculty in MIR's musculo-skeletal radiology



Patrick Lester, MD, and Edward Ragsdale, MD




(Left to right) Michael Vannier, MD, former chief of MIR's image processing laboratory; Robert Stanley, MD, former chief of MIR's abdominal radiology; and Ellen Vannier



Jeff Rueda, MD; Crammy Chung, MD; Sanjeev Bhalla, MD, assistant professor of radiology; and Karen Hightower, MD



(Left to right) Doctors Richard Wahl, Bob Davis, and Gilbert Jost



Testing Theories of Our Origins:

Is There a Neanderthal in our Past?

by Mary Jo Blackwood, RN, MPH, CHES

**A SILVERBACK GORILLA, ANCIENT POTTERY SHARDS,
A MUMMY,
THE ICE MAN.**

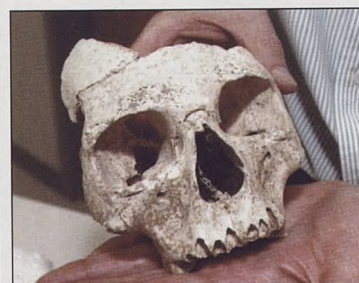
These are some of the computed tomography (CT) scanned subjects served by the Mallinckrodt Institute of Radiology at Washington University when patient hours are over for the day. The St. Louis Zoo has an excellent hospital but sometimes for a very large animal or a high resolution CT scan, they call on Mallinckrodt Institute. So does the Art Museum when a delicate scrap of ancient pottery needs virtual reconstruction to give direction to the restoration.

Testing Theories of Our Origins

With CT scanning and three-dimensional software, researchers and clinicians at Mallinckrodt Institute can recreate the image of the unbroken object. CT can look inside a delicate mummy and reveal worlds of information about the person and his history. The Ice Man, a prehistoric man found frozen in the snow high in the Tyrolean Alps, had to be kept in a controlled environment to delay deterioration. He was scanned in Austria and the raw data was sent to MIR's image processing lab to study the morphology of the tissue and to construct 3-D images of the organs and skeleton—giving us more information about how the Ice Man lived and died. CT technology, used primarily to aid the living, also gives us a better understanding of the dead or inanimate. So when prehistoric human bones found in a cave in Romania came to Washington University in St. Louis for study by Erik Trinkaus, PhD, professor of anthropology, Mallinckrodt Institute was called upon again for its contribution to solving age-old mysteries.

Human remains from the Peștera cu Oase cave in Romania

In February 2002, scuba divers discovered a previously unknown cave. Resting on the dry floor of the cave, they found evidence of hibernating bears and a largely complete, human, lower jawbone with teeth. They took the jaw to Romanian cave biologist Oana Moldovan, a professional colleague of Trinkaus. The jawbone was taken to Washington University, where it was CT scanned at Mallinckrodt Institute. Trinkaus then sent a small piece off to England for carbon dating. The results were astonishing. The jawbone dated to between 34,000 and 36,000 years ago, making it the earliest known human fossil in Europe. Last summer, Trinkaus was part of an expeditionary group that returned to the cave where, while measuring and mapping it, they found several facial and skull bone fragments lying on the cave floor. Those fragments are currently on loan to Trinkaus. Extensive study by Trinkaus has led him to conclude that the pieces found thus far appear to have come from three separate individuals. The jawbone,



Left: Researchers Marcia Ponce de León, Erik Trinkaus, Bruce Whiting, and Christoph Zollikofer ready the fossils for CT scanning.

or mandible, was designated Oase 1, with the pet name of *Ion* (Romanian for "John") and appears to be from an adult male. The parietal and facial bones, dubbed Oase 2 or "Vasile," appear to be from a similarly sized skull with some unerupted teeth, an adolescent male. A temporal bone containing the inner ear structures was categorized as Oase 3 or "Maria," because it does not fit either set of fragments and may have been from a female.

Two Swiss scientists who have done extensive work with skull reconstruction from fragments using CT three-dimensional imaging were in the United States and visited Trinkaus to assist with the CT scanning of the bones. Christoph Zollikofer, a biologist, and Marcia Ponce de León, an anthropologist, provided the CT scanning parameters to study the new pieces.

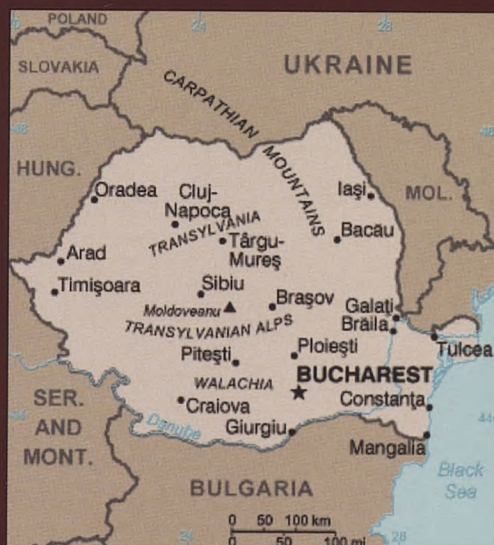Below: (left to right) A facial skeleton, a human jawbone, and a temporal bone.



History of CT Scanning at the Institute

COMPUTED TOMOGRAPHY (CT) WAS CO-INVENTED BY SIR GODFREY HOUNSFIELD WHO, IN 1971, BROUGHT A PROTOTYPE HEAD SCANNER TO MALLINCKRODT INSTITUTE, TO TEST ITS MEDICAL APPLICATIONS. HE LATER WON THE NOBEL PRIZE FOR HIS INVENTION, WHICH USHERED IN THE ERA OF HIGH TECHNOLOGY AND NONINVASIVE IMAGING. MALLINCKRODT INSTITUTE WAS THE FIRST RECIPIENT SITE OF CT SCANNERS USED FOR DIAGNOSING BRAIN ABNORMALITIES, AS WELL AS FOR WHOLE BODY SCANNING. RADIOLOGISTS AT THE INSTITUTE WROTE THE FIRST CT REFERENCE BOOK.

CT NOW HAS OTHER COMPLEMENTARY NONINVASIVE TECHNOLOGIES, SUCH AS MAGNETIC RESONANCE IMAGING (MRI), ULTRASOUND, DIGITAL MAMMOGRAPHY, AND A RELATIVELY NEW HYBRID, CT-PET (POSITRON EMISSION TOMOGRAPHY). THIS NEW SCANNER CAN PRODUCE CT AND PET SCANS DURING THE SAME APPOINTMENT. THE STRUCTURAL IMAGES FROM CT CAN BE COMBINED WITH THE FUNCTIONAL IMAGES FROM PET TO GIVE SHARPER, EVEN MORE DEFINITIVE DIAGNOSES. - MJB



Peștera cu Oase ("cave with bones") is in the southwestern portion of the Carpathian Mountains.



Testing Theories of Our Origins

The scanning took place in the evening after patient hours, coordinated by Charles Hildebolt, DDS, PhD, associate professor of radiology and adjunct associate professor of anthropology, and Bruce Whiting, PhD, assistant professor of radiology. All of the bones have now been CT scanned. Of particular interest has been the temporal bone. Visible within it on CT scan were all the structures of the inner ear: cochlea, semicircular canals, hammer, anvil and stapes. And all from someone who has been dead 35,000 years. Hildebolt explained that there is a suite of characteristics of the inner ear construction that may point more toward Neanderthals and others toward modern man.


Christopher Tincher, a radiology technologist for Barnes-Jewish Hospital, has been involved in both scanning sessions. The high resolution CT was done in three-quarter millimeter slices. Tincher worked his magic with the 3-D software to help reconstruct the pieces in three dimensions, fitting together the pieces that matched. "We generated a three-D virtual model of the pieces. When Professor Trinkaus and the team return to the cave next summer, they may find some more pieces that we can then incorporate into the model."

In the interim, Zollikofer and Ponce de León have taken copies of the CT scans back to Switzerland to begin reconstructing the skull. Hildebolt cautions that the fewer the fragments, the more hypothetical the reconstruction. While scientists generally assume facial symmetry with bone, other assumptions based on scant evi-

dence may be open to conjecture. If Trinkaus and colleagues find more fragments from the same skulls, they may correct or add credence to any models made thus far.

The importance of this cave find is enormous for several reasons. It proves evidence of modern humans in Europe much earlier than was previously documented. The bones provide some indication of burial habits of ancient man. But

Below: In the CT control room, Whiting, Charles Hildebolt, and Trinkaus study the fossil images on the monitor.

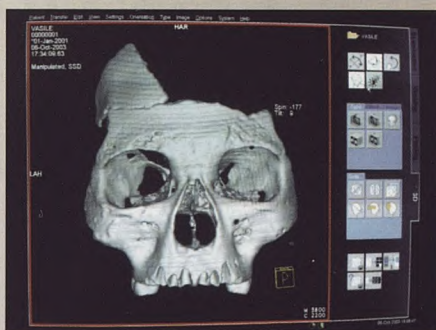

most importantly, they add information for one of the biggest debates in anthropology today: What happened to Neanderthals? As Hildebolt explains it, some scientists believe the replacement model—that one of the waves of humans coming out of Africa replaced Neanderthals and there are no Neanderthal genes left in modern man. The other theory—the continuity model—proposes that Neanderthal genes became assimilated over time and there's a little Neanderthal in all of us.

Trinkaus is a supporter of continuity, as is his colleague in the Department of Biology, Alan Templeton, PhD, whose recent paper in *Nature* demonstrates strong support for continuity. "My own specialty is genetics, and my analyses of much DNA sequence data shows that although the genetic data does confirm a major expansion of people out of Africa around one hundred thousand years ago, this expansion was characterized by at least some interbreeding and not complete replacement. I now have a paper in press that provides a formal statistical test to strongly reject total replacement. While genetic data doesn't answer all the questions, it must be integrated with fossil and archaeological data. I therefore find Erik's [Trinkaus] work extremely exciting and follow it with great interest."

According to Trinkaus and his Swiss colleagues, scientists knew that modern people—defined as modern because they had no brow

ridge and a clearly defined chin—existed in Europe more than 32,000 years ago but didn't really know what they looked like. One major surprise: The molars on the Oase 1 jaw are much larger than expected. Says Zollikofer, "The next older specimen we have with big molars like that is five hundred thousand years old, predating even Neanderthals." Adds Trinkaus, "We were lucky that the original cave entrance had been blocked, that the cave and bones were undisturbed, and that the cavers who found the jawbone realized its significance and thought to take it to Doctor Moldovan."



What's next? Trinkaus and colleagues plan to return to the cave next summer to thoroughly map it and find the original entrance. His anticipation? "We found the facial fragment resting face down on the dirt. There were some clean tooth sockets, indicating the teeth had fallen out relatively recently. We anticipate that if we dig down just a little where we found these pieces, we should find more pieces of the same face, along with teeth, which will make our picture of the skulls much more complete." Hildebolt, Tincher, and the rest of the team at Mallinckrodt Institute await the opportunity to be a part of that further discovery. ■■■■

Technologist Christopher Tincher demonstrates the 3-D reconstruction of the skull, using the facial skeleton and temporal bone.





South Africa

A LAND OF CONTRASTS

AN MIR RADIOLOGIST SEES FIRSTHAND THE URGENT NEED
FOR MODERN EQUIPMENT AND TRAINING IN SOUTH AFRICAN PUBLIC HOSPITALS.

BY ANNE KESSEN LOWELL

Doctor Marilyn Siegel's expertise in pediatric radiology has taken her around the world as a teacher and lecturer. Yet nothing in Siegel's globetrotting could have prepared her for the **EYE-OPENING, HEART-WRENCHING VISIT TO THE REPUBLIC OF SOUTH AFRICA** this past summer. As part of the Radiological Society of North America (RSNA) International Visiting Professor program, she joined two other RSNA members, doctors Scott Pretorius of the University of Pennsylvania and Annina Wilkes of Thomas Jefferson Hospital, on a teaching trip to South Africa in August 2003. A two-time recipient of Mallinckrodt Institute of Radiology's (MIR's) Teacher of the Year award, Siegel says simply, "I love teaching. This program seemed like a natural fit for me."

Above: The two faces of Capetown, South Africa

South Africa

RSNA's International Visiting Professorship was established in 1986. The program selects a three-member team who then lectures at a national radiology society meeting in a developing country. They also lecture, conduct clinical teaching sessions, and observe resident teaching methods at regional hospitals. In 2003, other International Visiting Professor teams traveled to Guatemala, El Salvador, and Kenya.

During the drive from the Johannesburg airport, Siegel was struck immediately by South Africa's contrasts: great wealth alongside abject poverty, pristine waterfront neighborhoods of custom-built mansions abutting vast areas of homemade shacks. "Apartheid may no longer exist as a policy," says Siegel, "but the social and economic inequalities are still visible." The stark contrast between living conditions of the wealthy (almost all white) South Africans and the poor black majority is evident in every sector of daily life: the economy, housing, and, perhaps of most importance, in health care.

The Visiting Professor team's first several days were spent at the South African Radiology Congress at the Midrand Conference Center in Gauteng Province, located between Johannesburg and the capital city of Pretoria. About 150 radiologists, or half the radiologists in South Africa, attended the Congress. (On a per capita basis, South Africa has one radiologist per 100,000 people, or one tenth of the per capita figure in the United States.) Over two days, the RSNA team covered topics in subspecialties of radiology. Siegel, a professor of radiology and of pediatrics, focused on computed tomography (CT)/magnetic resonance (MR) imaging of pediatric pelvic masses, pediatric renal masses, pediatric mediastinum, and ultrasonography (US)/CT imaging of the acute

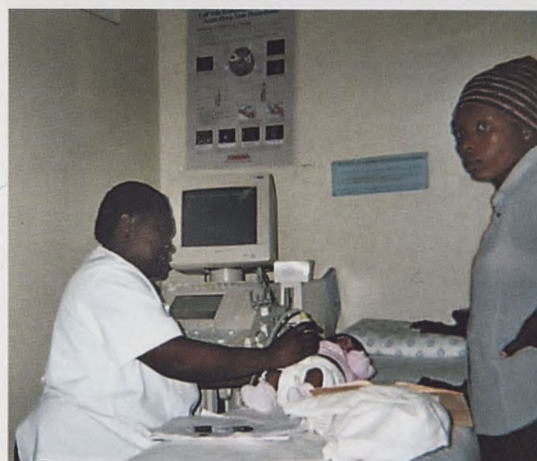abdomen. She also lectured on CT of adult hepatic masses.

At the close of the Congress, the team split up and visited regional hospitals around the country. Siegel went to Chris Hani Baragwanath Hospital in Soweto (an acronym for Southwestern Township). Located just outside of Johannesburg, Soweto is home to approximately 2.5 million black residents (population estimates range from one million to three million).

Soweto was the early home of Nelson Mandela as well as the site of the 1976 student uprising against apartheid, which brought international attention to South Africa and was considered the first step toward the dismantling of the apartheid system. Living conditions vary from modest brick homes to shacks. Forty-two percent of Sowetans are unemployed. Crime is rampant. Incidence rates of human immunodeficiency

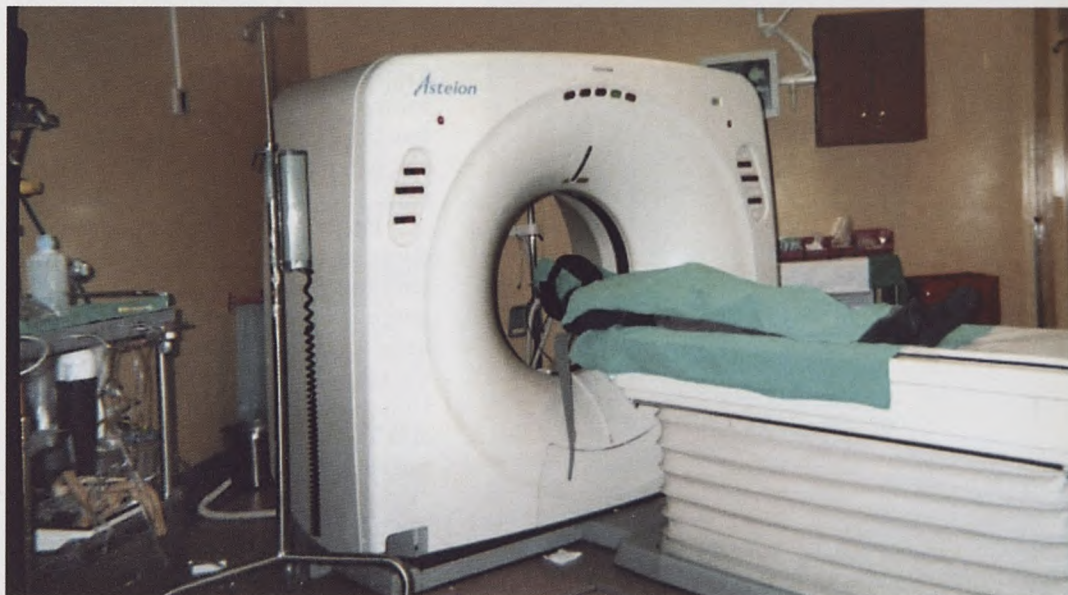


Above right: Pretorius, Siegel, and Wilkes at the South African Radiology Congress



Right: Mid 1990's ultrasound equipment

Below: Old generation nonhelical CT scanner



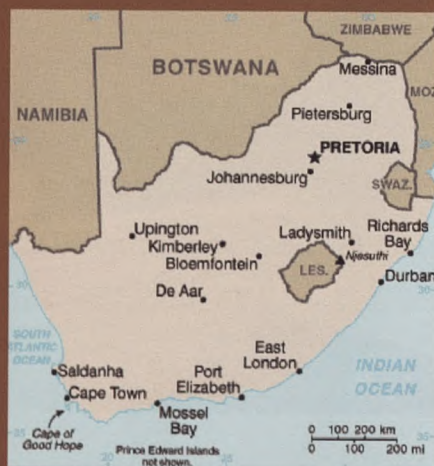South Africa

A LAND OF CONTRASTS

South Africa Facts and Figures

- > Area—1,219,912 square kilometers (slightly less than twice the size of Texas)
- > Population—42,800,000
- > Ethnicity—75.2% black; 13.6% white; 8.6% mixed race; 2.6% Indian
- > Infant mortality—60.84 deaths per 1,000 live births (rate in United States is 6.75/1,000)
- > Life expectancy at birth—46.56 years
- > HIV/AIDS prevalence—1 in 5 adults
- > People living with HIV/AIDS—5 million
- > HIV/AIDS orphans in Africa today—11 million
- > Population below poverty line—57%
- > World rank in TB prevalence—7th
- > Per capita government expenditures on health care—\$230 (per capita in United States is \$4,271)

Editor's Note: Above information was excerpted from following web sites: CIA Factbook, CBS News, and the World Health Organization.



ciency virus (HIV) and acquired immunodeficiency syndrome (AIDS) are among the highest in South Africa.

At Baragwanath Hospital, Siegel encountered the everyday medical crises devastating the South African population. "Baragwanath Hospital is an old military barracks," she notes. "Nearly one hundred barracks house adult and pediatric patients. The facilities resemble the large wards of public hospitals years ago."

Baragwanath Hospital is considered the largest medical facility in the southern hemisphere and one of the largest acute care hospitals in the world: In a typical year 145,000 inpatients and over a half million outpatients will be treated there. Because there are virtually no support services at the hospital, families provide everything from meals to nursing.

"Families bring their own blankets to hang up, to provide some measure of privacy. All the different patterns actually make the wards very colorful," says Siegel. However, that cannot hide the fact that patients languish on cots. This is evident and particularly sad in the pediatric wards. "There is nothing for these children to do—no game rooms, no radios or televisions, and few toys. They stare at the walls and ask when they can go home," she says.

Patients with AIDS occupy about 40 percent of the beds; patients with tuberculosis (TB), 20 percent. The remaining patients have a variety of diseases, including the usual diseases seen in the United States and Europe. "AIDS and TB create a huge demand for radiology services," says Siegel. "Patients wait so long to come to the hospital that they arrive with

advanced stages of disease and numerous serious complications. There are not enough resources, radiologists, or other specialists to take care of these patients."

Another major medical problem is the high incidence of trauma cases. In 2001, trauma-related admissions to Baragwanath Hospital included 5,049 motor vehicle accident victims, 4,995 cases of accident or injury, and 1,911 victims of gunshot wounds. As a comparison, according to the *Monthly Vital Statistics for Hospital Emergency Services* published by Buyers Guide to Hospital Emergency Services, the average number of trauma-related visits to all hospitals in Missouri during 2001 was 16,559.

At Baragwanath, Siegel lectured and taught the five staff radiologists and seven registrants. From the presentation of interesting cases, she gained a perspective on the enormous obstacles to instituting a modern radiological service at Baragwanath—or at any other regional hospital in South Africa.

Baragwanath, like virtually all of South Africa's regional hospitals, lacks modern equipment. There are, as Siegel discovered, only 74 MRI scanners in the country, and nearly all (except one or two) are used in private practices or private hospitals. Radiologists are forced to use invasive diagnostic procedures that in the United States were long ago replaced with noninvasive methods. "Where we would use MR imaging, they do angiograms to detect vascular disease," says Siegel. "They have to use excretory urograms to image the kidneys, because of the scarcity of sonographic and scintigraphic equipment, and myelograms for the diagnosis of disk disease. Where Mallinckrodt Institute has the sixth generation of radiology equipment,

"I LOVE TEACHING. THIS PROGRAM SEEMED LIKE A NATURAL FIT FOR ME."

MARILYN SIEGEL

South African hospitals are using third-generation to fourth-generation scanners, at best."

Similar to adults, children also undergo a large number of invasive diagnostic procedures. Although relatively rare in developed countries, hypertension and vascular diseases are common in the pediatric population in South Africa and other poor countries. Due to the lack of modern equipment, catheter angiography is the diagnostic test of necessity.

Not only are the fragile resources straining health care in South Africa, but there is an additional challenge facing radiology in that country. Radiologists are joining legions of professionals in medicine and other disciplines in an exodus to better paying jobs in other countries. As Siegel explains, "The country has no money, no modern scanners, and no resources. Nearly all newly trained radiologists are leaving for the United States, Australia, or Canada."

There is a painful irony behind the country's lack of modern medical equipment. The CT scanner was co-invented by an expatriate South African, Allan Cormack, who, along with Godfrey Hounsfield of the United Kingdom, won the Nobel Prize for Medicine in 1979 for their work. Another major breakthrough in the medical imaging field was invented in the 1990s by De Beers, the world's largest diamond mining company, and was used to scan South African miners for stolen dia-



Soweto's Baragwanath Hospital: emergency room (left) and patient waiting area

monds. The Statscan Critical Imaging System is a rapid, full-body, low-dose, digital X-ray system in use at many major United States trauma centers. Statscan quickly can detect multiple injuries in victims of serious accidents, which may have taken hours or even days to find with conventional X-ray methods. This equipment is being used in two hospitals and one research center in South Africa.

Siegel is convinced that basic improvements in training and equipment will greatly improve the quality and efficiency of health care in South Africa. She feels strongly that a more creative and longer-lasting approach to training is crucial. "The radiology community, both physicians and technologists, appreciates the International Visiting Professor program. They are delighted when an expert in an area of radiology comes to teach and are eager for new information. But sending three people for two weeks doesn't make a big impact," she notes.

Hopeful that a web-based radiology training tool might help train South African radiologists, Siegel points to a program being piloted at Mallinckrodt Institute that could be translated to international training. Gilbert Jost, MD, director of Mallinckrodt Institute and chairman of the Department of Radiology at Washington University in St. Louis School of Medicine, concurs that there is excellent promise in telemedicine. "RSNA is in the early

stages of developing a web-based application to support a digital teaching file," he explains. "The idea is to create a standard way to store radiology images that are used for teaching purposes, so teaching files can be shared from institution to institution. This is just one of many ways computers can be used for medical education, and the beauty of this approach is that successful educational applications can be used around the world. In the long run, it may be one of the most effective and economical ways to provide quality teaching in underdeveloped countries and in remote regional hospitals."

Combined with donations of modern equipment and more accessible teaching programs, a new generation of radiologists—who would remain in South Africa—could be trained soon. Other RSNA programs support this approach, such as "Teach the Teachers" that has opened ultrasound education centers in Nigeria and in South Africa.

Siegel says enthusiastically, "I'd love to go back!" Her first International Visiting Professor experience is not likely to be her last. Determined to stay involved in South Africa, she remains optimistic that her continued teaching can make a difference in patient care. **■**

FYI

In this section, the names of employees who are full-time faculty or staff or who have an appointment in the Department of Radiology or Department of Radiation Oncology are highlighted in boldface type.

PROMOTIONS

Farrokh Dehdashti, MD, associate professor of radiology, was promoted to professor of radiology, Division of Nuclear Medicine, Department of Radiology.

Steven Don, MD, assistant professor of radiology, was promoted to associate professor of radiology, Division of Diagnostic Radiology, Department of Radiology.

Michael Gelbart, MD, instructor in radiology, was promoted to assistant professor of radiology, Division of Diagnostic Radiology, Department of Radiology.

David Gierada, MD, assistant professor of radiology, was promoted to associate professor of radiology, Division of Diagnostic Radiology, Department of Radiology.

Robert Gropler, MD, associate professor of radiology, was promoted to professor of radiology, Division of Nuclear Medicine, Department of Radiology.

Fernando Gutierrez, MD, associate professor of radiology, was promoted to professor of radiology, Division of Diagnostic Radiology, Department of Radiology.

Benjamin Lee, MD, associate professor of radiology, was promoted to professor of radiology, Division of Diagnostic Radiology, Department of Radiology.

Cary Siegel, MD, assistant professor of radiology, was promoted to associate professor of radiology, Division of Diagnostic Radiology, Department of Radiology.

Cardiovascular MR Course

Under the direction of **Pamela Woodard, MD**, the Institute sponsored the annual cardiac MR training course, "Cardiovascular MR: Hands-on Experience" on August 12 through the 14th. Course faculty: MIR's **Fernando Gutierrez, MD**; **Vamsidhar Narra, MD**; **Robert Gropler, MD**; **Jie Zheng, PhD**; **Glenn Foster, RT**; **Richard Nagel, RT**; and **Deborah Delano, RN**; and **Orlando Simonetti, PhD**, Northwestern University.

For more information about this course, call (314) 747-3878.

NEW FACULTY

Linda Larson-Prior, PhD, research associate professor, Division of Radiological Sciences, Department of Radiology.

Fred Prior, PhD, research associate professor, Division of Radiological Sciences, Department of Radiology.

Douglas Rowland, PhD, research instructor in radiology, Division of Radiological Sciences, Department of Radiology.

GRANTS

Samuel Achilefu, PhD, associate professor of radiology, as co-principal investigator, received a \$419,999 subcontract award from the National Institutes of Health for research on "3-D photoacoustic computed tomography for molecular imaging." **Robert Kruger, PhD**, OptoSonics, Inc., is principal investigator for the NIH grant.

Carolyn Anderson, PhD, associate professor of radiology, as principal investigator, received a \$1.1 million grant from the National Cancer Institute, National Institutes of Health, for her research on "Labeling of octreotide with positron emitters." Co-investigators for the project, which began in 1994, are **Wen Ping Li, PhD**, research instructor in radiology; **Buck Rogers, PhD**, assistant professor of radiation oncology; and **Jason Lewis, PhD**, assistant professor of radiology.

Mark Conradi, PhD, professor of physics and of radiology, as principal investigator, received a two-year grant from The GEMI (Gas Enabled Medical Innovations) Fund of AGA Linde Healthcare. The \$150,000 grant supports research involving the development of MRI with perfluorinated gases.

Robert Mach, PhD, professor of radiology, as principal investigator, received a \$125,314 grant from the National Cancer Institute, National Institutes of Health, for research on "PET imaging of breast cancer via sigma-2 receptors." As principal investigator, Mach received a \$300,000 grant from the National Institute for Biomedical Imaging and Bioengineering, National Institutes of Health, for "PET radiotracers for imaging apoptosis." As principal investigator, Mach received a one-year grant of \$191,730 from the National Cancer Institute for research on "PET imaging of breast cancer via sigma-2 receptors."

Robert McKinstry, MD, PhD, assistant professor of radiology, as co-investigator and chairman of the Neuro-radiology Committee, received a grant from the National Institute of Neurological Disorders for the seven-year project "Silent cerebral infarct, a multicenter clinical trial." Principal investigator is **Michael DeBaun, MD, MPH**, Department of Pediatrics, Washington University in St. Louis.

APPOINTMENTS/ ELECTIONS

Samuel Achilefu, PhD, associate professor of radiology, was appointed as a member of the Scientific Advisory Board of Advanced Research Technologies-ART, Inc., the largest publicly-owned company specializing in the development of equipment for optical imaging of small animals and humans.

Kyongtae Bae, MD, PhD, assistant professor of radiology, was appointed associate editor of *Radiology*, the journal of the Radiological Society of North America.

Mark Conradi, PhD, professor of physics and of radiology, was elected a fellow of the American Physical Society.

Thomas Conturo, MD, PhD, associate professor of radiology and adjunct professor of physics and biomedical engineering, was appointed to a second term (2003-2004) as secretary of the Diffusion/Perfusion Study group of the International Society for Magnetic Resonance in Medicine.

Colin Derdeyn, MD, associate professor of radiology, was appointed to two-year terms as chairman of the American Heart Association Stroke Council's Membership and Communications Committee and as a member of the Leadership Committee.

Dione Farria, MD, MPH, assistant professor of radiology, was appointed co-director of the Siteman Cancer Center's Program for the Elimination of Cancer Disparities.

Jay Heiken, MD, professor of radiology, was appointed to one-year terms on the American College of Radiology's Commission on Research and Technology and the Committee on Body Computed Tomography.

Eric Klein, MS, associate professor of radiation oncology, was appointed to the Written Physics Exam Committee for the American Board of Radiology.

Robert Mach, PhD, professor of radiology, was elected to the Society of Nuclear Medicine's Board of Directors for the Radiopharmaceutical Science Council.

Robert McKinstry, MD, PhD, assistant professor of radiology, was elected to a third term as chairman of the Steering Committee for The MRI Study of Normal Brain Development, a seven-year, multicenter study funded by the National Institutes of Health.

Eduardo Moros, PhD, associate professor of radiation oncology, was elected vice president of the North American Hyperthermia Society for 2003-2004; he is the 2004-2005 president-elect.



Melson Lecture

Former MIR faculty member, James Brink, MD, presented the Eleventh Annual G. Leland Melson Visiting Professorship and Lecture on September 8. Brink, professor and interim chairman of the Department of Radiology, and chief of abdominal imaging, Yale University, presented "Multislice CT: radiation dose considerations and future directions."

Shown left to right are doctors Sharlene Teefey, Brink, Jay Heiken, and William Middleton.

Joel Perlmutter, MD, professor of neurology, of neurological surgery, and of radiology, was elected to a three-year term on the Standards Committee of the Huntington Study Group and to a two-year term on the Executive Committee of the Parkinson Study Group. He was appointed to a one-year

term on the American Academy of Neurology's Practice Parameters Subcommittee on Parkinson Disease. He was appointed to the Editorial Board of the journal *Movement Disorders*.

David Piwnica-Worms, MD, PhD, professor of radiology and of molecular biology and pharmacology, was elected president of the Society of Molecular Imaging for 2003-2004.

APPOINTMENTS/ELECTIONS

Continued from page 25

Sally Schwarz, RPh, research scientist of radiology, was elected to a three-year term as physician/scientist councilor for the Missouri Valley Chapter of the Society of Nuclear Medicine. She was appointed to a one-year term on the Society of Nuclear Medicine's Committee on Pharmacopeia.

Franz Wippold, MD, associate professor of radiology, was appointed to the Admission Committee of Washington University in St. Louis School of Medicine.

Pamela Woodard, MD, assistant professor of radiology, was elected secretary-treasurer for the North American Society of Cardiac Imaging, 2003-2005.

HONORS/ AWARDS

Thomas Conturo, MD, PhD, associate professor of radiology and adjunct professor of physics and biomedical engineering, was named meeting organizer for the International Society for Magnetic Resonance in Medicine workshop "Quantitative Cerebral Perfusion with MRI: A Technical Perspective" to be held in March 2004 in Venice, Italy.

Diana Gray, MD, professor of obstetrics/gynecology and of radiology, was an invited workshop presenter at the 2003 Professional Development Conference for Women in Medicine and Research: Successful Strategies for Women in Academic Medicine, Memphis, Tennessee, September 26-28.

Jerold Wallis, MD, associate professor of radiology, and Kevin O'Donnell, of Toshiba, Inc., were appointed co-leaders of the Nuclear Medicine working group of the IHE, a joint effort of radiological societies and industry devoted to "Integrating the Healthcare Enterprise."

Pamela Woodard, MD, assistant professor of radiology, moderated the Workshop Sessions: Basic Cardiac Imaging and Vascular Imaging at Cardiovascular Imaging 2003, the 31st Annual

Meeting and Scientific Sessions of the North American Society for Cardiac Imaging, Dallas, Texas, September 13. She also served as moderator for the Cardiovascular Disease in Women Special Session and for the MR and CT Angiography of Coronary Artery Disease Scientific Session at the American Heart Association Scientific Sessions, Orlando, Florida, November 10 and 11.

LECTURES

Samuel Achilefu, PhD, associate professor of radiology, presented "Near infrared molecular probes for imaging protein expression" at Imaging in 2020, Jackson Hole, Wyoming, September 7-11. He spoke on "Receptor-specific near infrared molecular probes for imaging aberrant protein expression in vivo" at the MGH Wellman Laboratories of Photomedicine Lecture Series, Boston, Massachusetts, September 30. He spoke on "Contrast agent-mediated optical imaging of tumors" at the Fall Meeting of the American Association of Physicists in Medicine, Missouri River Valley Chapter, St. Louis, Missouri, November 8. Achilefu presented "Lighting up tumors by optical methods" at the Roswell Cancer Institute Seminar, Buffalo, New York, December 1. He presented "The role of optical molecular probes in tumor imaging and organ function monitoring" as part of the Intramural Research Seminar Series, National Institute of Child Health & Human Development, National Institutes of Health, Bethesda, Maryland, December 8.



Probstein Lecture

Philip Kantoff, MD, director of the Lank Center for Genitourinary Oncology and chief of the Division of Solid Tumor Oncology, Dana Farber Cancer Institute, Harvard University, was guest speaker for the September 12th Norman K. Probstein Oncology Lecture. Kantoff spoke on "Prostate cancer: recent advances, future directions."

Shown with Kantoff is Carlos Perez, MD, Chairman of the Department of Radiation Oncology.

Carolyn Anderson, PhD, associate professor of radiology, spoke on "Copper-64-labeled biomolecules for tumor targeting" at Washington University in St. Louis, Chemistry Department, St. Louis, Missouri, October 9.

Jeffrey Bradley, MD, assistant professor of radiation oncology, presented "Implementing PET/CT into radiation treatment planning for lung cancer" at the Siemen's User Meeting, Salt Lake City, Utah, October 19.

Mark Conradi, PhD, professor of physics and of radiology, presented "Helium-3 imaging of ventilation and diffusion in lungs" and "NMR of gases" at the 7th International Conference on Magnetic Resonance Microscopy, Snowbird, Utah, September 15-19.

Colin Derdeyn, MD, associate professor of radiology, spoke on "Cerebral hemodynamics" at the 4th Annual International Meeting on Cerebral Revascularization, Saint Louis University, St. Louis, Missouri, October 9. He presented the Second Annual Hans Newton Lecture, "Role of cerebral hemodynamics in ischemic stroke," at the University of California, San Francisco, October 23. He spoke on "Methods of cerebral hemodynamic assessment, part 1: physiology" and "Methods of cerebral hemodynamic assessment: part 2: methods" at the Advances in Clinical MR and CT Symposium, University of California, San Francisco, October 24.

Diana Gray, MD, professor of obstetrics/gynecology and of radiology, presented "The keyhole bladder and other signs of fetal urinary tract disease" at the Department of Obstetrics/Gynecology and "Prenatal diagnosis/treatment of fetal urinary tract disorders" at the Department of Urology Grand Rounds, University of Michigan, Ann Arbor, December 4.

Jay Heiken, MD, professor of radiology, spoke on "Contrast enhancement and scan timing for multislice CT"; "Aortic endoluminal stent grafts: evaluation with multislice CT"; and "CT colonography: technique, results, and future directions" at Screening CT and Other Volumetric Imaging Applications, sponsored by Ospedale Maggiore di Milano and Yale University, Milan, Italy, September 26 and 27. He presented "Contrast enhancement and scan timing for multislice CT" at the MDCT Symposium, sponsored by Bracco, Inc., Vienna, Austria, November 22.

Jeff Michalski, MD, associate professor of radiation oncology, presented "Prostate cancer" at the 2003 Fall Meeting of the Wisconsin Society of Radiation Oncologists, Milwaukee, Wisconsin, September 26. He spoke on "Clinical planning target volume definition for

3D conformal and intensity modulated radiation therapy" at the 16th Annual Meeting of the Japanese Society for Therapeutic Radiology and Oncology, Tokyo, Japan, November 22. He presented "3D CRT dose escalation trial for cancer of the prostate RTOG 9406" at M. D. Anderson Cancer Center, Houston, Texas, December 17.

Joel Perlmutter, MD, professor of neurology, of neurological surgery, and of radiology, as the Rose Symposium in Physical Therapy Lecturer, presented "Parkinson disease, or how the basal ganglia can shake you up" at Washington University in St. Louis, Missouri, September 19. He spoke on "Parkinson disease and visual impairments" at the Lions Club, St. Louis, Missouri, September 25. Perlmutter presented "Parkinson disease" at the Mini Medical School, sponsored by Washington University in St. Louis, Missouri, November 6. He presented "Parkinson disease: new research" at the Parkinson Education Program, St. Louis, Missouri, November 23.

Carlos Perez, MD, professor of radiation oncology, spoke on "Irradiation in conservation therapy of carcinoma in situ"; "Conservation therapy in breast cancer: new techniques of radiation therapy"; and "Controversies in irradiation of stage T1-T2 breast cancer" at the Breast

Cancer Course, Santiago, Chile, October 1-4. He presented "Radiation therapy and chemotherapy in carcinoma of the head and neck" at the Consensus Conference on Therapy of Oropharyngeal and Oral Cavity, sponsored by the National Cancer Institute, Milan, Italy, November 2-6. He presented "Dose fractionation and its biological optimization in prostate cancer," "Dose fractionation and its biological optimization in cervix cancer," and "The contribution of radiation therapy to cancer treatment today" at the 14th Annual Residential Course, Catholic University Sacred Heart, Rome Italy, November 10-14.

Bradley Schlaggar, MD, PhD, assistant professor of neurology, of pediatrics, and of radiology, spoke on "Functional MRI and cognitive development" at the Central Society for Neuroscience Research Meeting, Alton, Illinois, September 13. He presented the Young Investigator Lecture, "Development of controlled visual lexical processing; fMRI studies," and "Differences in fMRI activation between adults and children in single word processing" at the Child Neurology Society Annual Meeting, Miami, Florida, October 3. Schlaggar presented "The developmental functional neuroanatomy of single word processing" at the University of California, Davis, October 20. He spoke on "fMRI and the development of single word reading" at the International Dyslexia Association Symposium, San Diego, California, November 12.

LECTURES

Continued from page 27

Barry Siegel, MD, professor of radiology and of medicine, presented "PET in oncology"—the J. S. Manchester Memorial Lecture, sponsored by Dalhousie University—and "Oncologic PET beyond FDG" at the joint meeting of the Atlantic Radiology Conference and the 66th Annual Scientific Meeting of the Canadian Association of Radiologists, Halifax, Nova Scotia, October 1-4. As visiting professor, he presented "PET for assessing response to therapy: FDG and beyond" at the Università di Milano-Bicocca, Istituto H.S. Raffaele, Milan, Italy, October 16. As guest speaker, he presented "Overview of PET imaging in oncology" and "PET imaging in women's cancer" at Diagnostic Radiology Update, sponsored by the University of Texas Southwestern Medical Center, Dallas, October 24-26. He spoke on "Current status of PET in clinical practice" at New Horizons in Cancer Care...The Future Is Now, the 2003 Regional Oncology Conference, sponsored by Banner Health®, Loveland, Colorado, November 7.

Marilyn Siegel, MD, professor of radiology and of pediatrics, spoke on "Multi-detector CT pediatrics," "High resolution CT of the pediatric chest," "CT of the pediatric airway," "CT/MRI of focal hepatic masses in children," and "MRI of genitourinary abnormalities" at Pediatric CT and MRI: Present and Future, the Harvard University Medical Continuing Education Course, Boston, Massachusetts, September 19 and 20. She presented the Royal College Lecture, "Pediatric multislice CT 2003"; "US/CT of common abdominal neoplasms in children"; "CT of congenital thoracic lesions"; and "Sonography of neonatal renal lesions" at the joint meeting of the Atlantic Radiology Conference and the 66th Annual Scientific Meeting of the Canadian Association of Radiologists, Halifax, Nova Scotia, October 1-4. Siegel presented "Pediatric CTA: advantages, applications and risks"; "Thoracic CTA: anatomic variants and pitfalls;" and "Congenital heart disease in adults: MDCT evaluation" at the 2003 Non-Invasive Vascular Imaging with MRA and CTA Symposium, New York City, New York, December 12-14.

Anurag Singh, MD, radiation oncology resident, presented "Monitoring the effect of 41°C hyperthermia on tumor hypoxia by Cu-ATM PET scanning" at the First International Congress on Stress Responses in Biology and Medicine, Quebec City, Canada, September 12. He spoke on "IMRT, PET, and cervical carcinoma" at the National Cancer Institute, Department of Radiation Oncology, Bethesda, Maryland, November 7.

Sheng-Kwei Song, PhD, assistant professor of radiology, spoke on "Differentiating axon and myelin injury in mouse CNS" at the Department of Biomedical Engineering, Case Western Reserve University, Cleveland, Ohio, November 20.

Wade Thorstad, MD, instructor in radiation oncology, presented "The role of metabolic imaging for radiotherapy target definition" at the meeting of the New England Chapter of the American Association of Physicists in Medicine, Boston, Massachusetts, October 28.

Franz Wippold, MD, associate professor of radiology, spoke on "Forensic radiology of mass casualty" at Westminster Christian Academy, St. Louis, Missouri, November 3.

Pamela Woodard, MD, assistant professor of radiology, presented "Spiral CT of pulmonary thromboembolic disease" at Cardiovascular Imaging 2003, the 31st Annual Meeting and Scientific Sessions of the North American Society for Cardiac Imaging, Dallas, Texas, September 13.

SYMPOSIA

In this section of FYI, only those faculty and staff who have Department of Radiology or Department of Radiation Oncology appointments are listed.

NORTH AMERICAN HYPERTHERMIA SOCIETY

*Annual Meeting
Quebec City, Canada
September 10-14, 2003*

Andrei Laszlo, PhD, coordinator, Mechanisms of Thermotolerance (A Multifaceted Discussion) Workshop.

Joseph Roti Roti, PhD, coordinator, Molecular Changes to Improved Clinical Responses: Advances in the Use of Hyperthermia to Improve Radiation Therapy Workshop.

William Straube, MS, co-coordinator, Recent Advances in Hyperthermia Workshop.

SCIENTIFIC SESSIONS

Bibianna Cha, BS; Petr Novak, PhD; William Straube, MS; Eduardo Moros, PhD; Robert Myerson, MD, PhD, "The making of a clinical SURLAS: designing a LINAC-SURLAS-patient portable interface."

Jacob Locke, MD, "Enhancement of radiosensitization by moderate hyperthermia and nonsteroidal anti-inflammatory drugs."

Eduardo Moros, PhD; Petr Novak, PhD; William Straube, MS; Robert Myerson, MD, PhD, "The making of a clinical SURLAS: description of a constructed system."

Petr Novak, PhD; Eduardo Moros, PhD; William Straube, MS; Robert Myerson, MD, PhD, "The making of a clinical SURLAS: preclinical laboratory performance testing."

William Straube, MS, "Apparent motion and temperature dependence of backscattered energy in ultrasonic images."

Mai Xu, MD, PhD; Robert Myerson, MD, PhD; Clayton Hunt, PhD; Shashi Kumar; Tej Pandita, PhD; Eduardo Moros, PhD; William Straube, MS; Joseph Roti Roti, PhD, "Effects of moderate hyperthermia on the DNA proteins, Mre11, Rad 50 and gH2AX."

ACADEMY OF MOLECULAR IMAGING

*2003 International Conference
Madrid, Spain
September 21-27, 2003*

Barry Siegel, MD, chairman, PET and PET/CT State-of-the-Art Session II; panel member, Round Table: Transatlantic Consensus: PET Indications.

SCIENTIFIC SESSIONS

Jeffrey Bradley, MD, "PET and PET/CT: the radiation oncologist's view."

Farrokh Dehdashti, MD, "PET in breast and gynecological cancers."


Stephen Moerlein, PhD; Joel Perlmutter, MD; Yuan-Chuan Tai, PhD; Richard Laforest, PhD; Michael Welch, PhD, "Imaging of cerebral D2 receptor binding in living primates using the MicroPET focus scanner."

Stephen Moerlein, PhD; Joel Perlmutter, MD; Yuan-Chuan Tai, PhD; Richard Laforest, PhD; Michael Welch, PhD, "MicroPET imaging of pre-synaptic dopaminergic tracers in living mouse brain."

Barry Siegel, MD, "PET and PET/CT for treatment planning and monitoring."

Scott Lecture

On October 20, Joseph Lee, MD, former chief of MIR's abdominal radiology, presented the Thirty-second Annual Wendell G. Scott Memorial Lecture. Lee, professor and chairman, Department of Radiology, University of North Carolina, spoke on "Imaging of abdominal lymph nodes from LAG to PET: the training of the radiologists of tomorrow."



CT AND MR BRAIN PERFUSION

*Third International Symposium
St. Louis, Missouri
October 10-12, 2003*

Kyongtae Bae, MD, PhD, panel member, CT/CTA/CT Perfusion.

Colin Derdeyn, MD, course chairman; moderator, Clinical Applications II: Chronic Hemodynamic Impairment;

Robert McKinstry, MD, PhD, member, Program Committee; panel member, Clinical Applications III: Brain Tumors/Angiogenesis.

William Powers, MD, member, Program Committee; panel member, Clinical Applications II: Chronic Hemodynamic Impairment.

Katie Vo, MD, panel member, MR Diffusion/Perfusion.

Joshua Shimony, MD, PhD, moderator, Quantitative Measurement of CBF, CBV, and MTT with CT and MR: What Are the Problems?

SYMPOSIA

Continued from page 29

SCIENTIFIC SESSIONS

Kyongtae Bae, MD, PhD, "CTA injection rates and modeling."

Colin Derdeyn, MD, "PET—Is it really the gold standard?"

Robert Grubb, MD, "Methods of assessment of hemodynamic impairment, association with stroke risk and clinical scenarios."

Robert McKinstry, MD, PhD, "DSC MRI of tumor perfusion: vascularity, permeability and pitfalls."

Jeffrey Neil, MD, PhD, "Pathophysiology—MR diffusion."

William Powers, MD, "Clinical context: imaging-related questions and issues."

Marcus Raichle, MD, "History of cerebral blood flow imaging."

Joshua Shimony, MD, PhD, "Definition of CBF, CBV, MTT and basic tracer kinetics."

METABOLIC PET IMAGING FOR A NEW RADIOTHERAPY

*Reggio Emilia, Italy
October 14 and 15, 2003*

Barry Siegel, MD, co-chairman, Clinical Aspects.

Carlos Perez, MD, co-chairman, General Overview.

SCIENTIFIC SESSIONS

Tom Miller, MD, PhD, "PET in gynecological cancer," "PET in Prostate cancer."

Carlos Perez, MD, "New strategies in radiotherapy," "Functional imaging in treatment planning in radiation therapy."

Barry Siegel, MD, "PET in oncology."

Marilyn Siegel, MD, "New trends in radiological imaging in oncology."

AMERICAN SOCIETY FOR THERAPEUTIC RADIOLOGY AND ONCOLOGY

*45th Annual Meeting
Salt Lake City, Utah
October 19-23, 2003*

Jeffrey Bradley, MD, panel member, Scientific Session: Functional Imaging.

Perry Grigsby, MD, panel member, Implementation of Intensity Modulated Radiation Therapy for Patients with Carcinoma of the Cervix.

Daniel Low, PhD, moderator, 4D-CT, Margins, and IMRT.

EDUCATION SESSIONS

Jeff Michalski, MD, "IMRT: biology, physics, philosophy, economics."

Sasa Mutic, MS, "CT simulation process and techniques."

SCIENTIFIC SESSIONS

Jeffrey Bradley, MD, "Acute and late toxicity results of RTOG 9311; a dose escalation study using 3D conformal radiation therapy in patients with inoperable non-small cell lung cancer"; "Evolving PET applications for radiation oncology."

Jeffrey Bradley, MD; James Purdy, PhD; Walter Bosch, DSc, "Toxicity and outcome results of RTOG 9311; a phase I/II dose escalation study using 3D CRT in patients with inoperable NSCLC."



Perez Lecture

As invited speaker for the Third Annual Carlos A. Perez Endowed Lectureship in Oncology on December 12, Herman Suit, MD, DPhil, distinguished professor, Department of Radiation Oncology, Harvard University, presented "Approaching the limits in radiation dose delivery."

Shown with Suit are Carlos Perez, MD, (left) and Todd Wasserman, MD.

Jeff Michalski, MD, "Toxicity following 3D radiation therapy for prostate cancer on RTOG 9406 dose level V"; "Economics issues in 3D CRT and IMRT."

Mai Xu, MD, PhD; Robert Myerson, MD, PhD; Clayton Hunt, PhD; Shashi Kumar; Eduardo Moros, PhD; William Straube, MS; Joseph Roti Roti, PhD, "Treatment of cells with Mre11 siRNA increases radiation sensitivity and reduces heat induced radiosensitization."

Mai Xu, MD, PhD; Joseph Roti Roti, PhD; Carlos Perez, MD, "Molecular mechanisms of radiosensitization induced by indomethacin."

POSTER PRESENTATIONS

Joseph Deasy, PhD, "Risk of radiation pneumonitis classified via dosimetric parameters."

Eric Klein, MS; Robert Drzymala, PhD; James Purdy, PhD, "Errors in radiation oncology: a study in pathways and dosimetric impact."

Robert Malyapa, MD, PhD, "Phase II study of irradiation and concurrent chemotherapy for locally recurrent cervical cancer."

Anurag Singh, MD, "Irradiation dose, lymph node size, and tumor control in carcinoma of the cervix."

Imran Zoberi, MD, "Non-randomized comparison of LDR and HDR brachytherapy for cervical cancer."

SOCIETY FOR NEUROSCIENCE

*33rd Annual Meeting
New Orleans, Louisiana
November 8-12, 2003*

SCIENTIFIC SESSIONS

Francis Miezín; Steven Petersen, PhD, "Different types of sustained and transient activity dissociated by practice."

Stephen Moerlein, PhD; Michael Welch, PhD; Joel Perlmutter, MD, "Absorbed radiation dosimetry of the PET D2 radioligand N-[C-11]methylbenperidol ([C-11]NMB)."

Erica Palmer; Eliza Burghund, PhD; Steven Petersen, PhD, "Sustained task-related activity and its action on transient trial-related activity."

Joel Perlmutter, MD; Stephen Moerlein, PhD; Yuan-Chuan Tai, PhD; Richard Laforest, PhD; Michael Welch, PhD, "Comparison of presynaptic dopaminergic tracers for microPET studies of mouse brain."

Bradley Schlaggar, MD, PhD; Steven Petersen, PhD, "fMRI reveals age-related differences in the development of single word reading."

POSTER PRESENTATIONS

Kevin Black, MD; Lori McGee-Minnich; Abraham Snyder, MD, PhD; Joel Perlmutter, MD, "[¹⁸F]fluorodopa PET correlates of novelty seeking in Parkinson disease."

Kevin Black, MD; Erbil Akbudak, PhD; Abraham Snyder, MD, PhD; Thomas Conturo, MD, PhD; Joel Perlmutter, MD, "Levodopa activation pharmacologic fMRI in Tourette's syndrome."

Tolmach Lecture

On November 7, 2003, Jerry Shay, PhD, professor, Department of Cell Biology, University of Texas Southwestern Medical Center, Dallas, presented the Twelfth Annual Leonard J. Tolmach Memorial Lecture.

Shown with Shay (left) is Joseph Roti Roti, PhD, chief of Radiation Oncology's Division of Radiation and Cancer Biology.



SYMPOSIA

Continued from page 31

Eliza Burgund, PhD; Bradley Schlaggar, MD, PhD; Steven Petersen, PhD, "Effects of stimulus and instruction type during three visual matching tasks: a mixed blocked and event-related fMRI study."

Debra Gusnard, MD; Abraham Snyder, MD, PhD; Harold Burton, PhD; Marcus Raichle, MD, "Metabolic topography of resting adult human cerebral cortex."

Lori McGee-Minich; Joel Perlmutter, MD, "Stimulus frequency affects tremor suppression in ET patients with deep brain stimulators."

Francis Miezin; Steven Petersen, PhD; Bradley Schlaggar, MD, PhD, "Mixed blocked/event-related designs separate transient and sustained activity in fMRI in children."

Stephen Moerlein, PhD; Joel Perlmutter, MD, "Globus pallidus activity in a primate model of dystonia and Parkinsonism."

Erica Palmer; Francis Miezin; Steven Petersen, PhD, "Top-down influence in silent and aloud reading."


Gaurav Patel; Abraham Snyder, MD, PhD; Erbil Akdubak, PhD; Maurizio Corbetta, MD, "Visuotopic organization of human visual attention areas."

Joel Perlmutter, MD, "STN stimulation-induced impairment in cognitive control in PD."

Abraham Snyder, MD, PhD; Debra Gusnard, MD; Marcus Raichle, MD, "fMRI whole-brain time course analysis: What are large draining veins telling us?"

Abraham Snyder, MD, PhD; Randy Buckner, PhD, "Evaluation of spatial normalization in nondemented and demented older adults," "Longitudinal change in whole-brain volume during aging and dementia of the Alzheimer type," "An anatomical double dissociation between nondemented aging and dementia of the Alzheimer type."

Tom Videen, PhD; Lori McGee-Minnich; Joel Perlmutter, MD, "Resting tremor affects cortical blood flow and may confound neuroimaging studies of PD patients with deep brain stimulators."



IN MEMORIAM

We sadly report the death of Armand Diaz, assistant professor emeritus of radiology, on October 9, 2003, from complications of chronic obstructive pulmonary disease. He was 76.

A native of Havana, Cuba, Diaz studied nursing before he came to the United States in the 1940s and became a naturalized United States citizen. After serving in the Korean War, he worked at Columbia-Presbyterian Medical Center in New York and later sold X-ray equipment internationally.

In 1968, Diaz joined the staff at Mallinckrodt Institute as technical administrator and later served as director of education for the Institute's

School of Radiography. During the 1970s and 80s, Diaz's technical expertise was especially beneficial as Mallinckrodt Institute received the nation's first computed tomography and magnetic resonance scanners. He was named assistant professor of radiology (technical administration) in 1990.

He is survived by his wife Rita, two daughters, and five grandchildren. Memorial contributions may be sent to the Radiology Education Fund, Jewish Hospital College of Nursing and Allied Health, 306 South Kingshighway, St. Louis, MO 63110.



WITH THE RECENT REVOLUTION IN MOLECULAR BIOLOGY, transgenic laboratory animal models have become an indispensable part of biomedical research. Identification and development of methods for analyzing and evaluating areas within animal models present a significant challenge. Noninvasive, nondestructive imaging procedures, such as magnetic resonance imaging (MRI), are valuable tools in this research.



The Institute's Biomedical Magnetic Resonance Laboratory, led by Joseph Ackerman, PhD, has received a National Institutes of Health grant to purchase an ultra-high field (11.75-tesla), small-animal MRI scanner. The scanner's associated improvements in signal-to-noise ratio and spectral dispersion provide important advantages in small-animal imaging.



The magnet for this powerful scanner will be housed in a newly constructed vault in the Mallinckrodt Institute of Radiology at Washington University Imaging Center's basement. The finished structure—approximately 1,350 square feet protruding from the southwest corner of the Imaging Center—will include a control room as well as computer, equipment, and instrument rooms.



FOCAL SPOT

MALLINCKRODT INSTITUTE OF RADIOLOGY

Address Service Requested

POSTMASTER, send distribution changes or address corrections to *Focal Spot* editor
Mallinckrodt Institute of Radiology at
Washington University
Campus Box 8131
510 South Kingshighway Blvd.
St. Louis, MO 63110
(314) 362-2866

Editor and Writer
Vicki Kunkler

Contributing Writers
Mary Jo Blackwood
Anne Kessen Lowell
Candace O'Connor

Photographers
Thomas Murry
Tim Parker
Michelle Wynn

Design
Purviance & Company
Marketing Communications

Printing
Swift Print Communications
LLC

Focal Spot magazine is distributed three times annually.

www.mir.wustl.edu

© Mallinckrodt Institute of Radiology, 2004

Non-Profit Organization
U.S. Postage
St. Louis, Missouri
Permit No. 2535

 Washington
University in St. Louis
SCHOOL OF MEDICINE

MIR Mallinckrodt Institute
of Radiology