

Summer 2009

## Focal Spot, Summer/Fall 2009

Follow this and additional works at: [http://digitalcommons.wustl.edu/focal\\_spot\\_archives](http://digitalcommons.wustl.edu/focal_spot_archives)

---

### Recommended Citation

Focal Spot, Summer/Fall 2009, July 2009. Bernard Becker Medical Library Archives. Washington University School of Medicine.

This Book is brought to you for free and open access by the Focal Spot at Digital Commons@Becker. It has been accepted for inclusion in Focal Spot Archives by an authorized administrator of Digital Commons@Becker. For more information, please contact [engeszer@wustl.edu](mailto:engeszer@wustl.edu).

SUMMER/FALL 2009

VOLUME 40, NUMBER 2

# FOCAL SPOT

LEKSELL GAMMA KNIFE

PERFECTION

MALLINCKRODT

RADIATION ONCOLOGY AT WASHINGTON UNIVERSITY

ELEKTA



Washington University in St. Louis Physicians

Keith M. Rich, M.D. Neurosurgery

Washington University in St. Louis Physicians

Tammie Benzinger, M.D.

## Sharpening THE Gamma Knife

WASHINGTON UNIVERSITY MEDICAL LIBRARY



3 2201 20363 3728

09/10

# Diagnostic Radiology Chief Residents

2009/2010



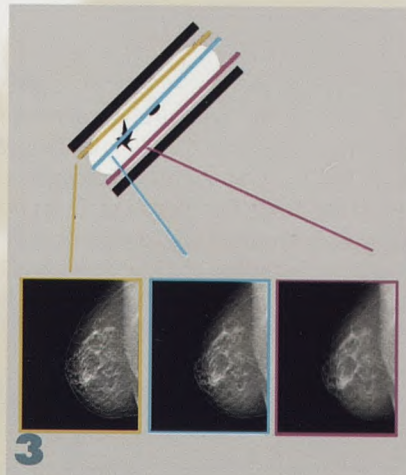



(LEFT TO RIGHT) **Matthew Gipson, MD; James Kelly, MD; Travis Henry, MD**


*Photograph by MIR Photography Lab*

# CONTENTS

FOCAL SPOT  
SUMMER/FALL 2009  
VOLUME 40, NUMBER 2



## 2.....SPOT NEWS



## 30.....FYI

Washington  
University in St. Louis  
SCHOOL OF MEDICINE

MIR Mallinckrodt Institute  
of Radiology

Visit the MIR web site at  
[www.mir.wustl.edu](http://www.mir.wustl.edu)

### 3 Less worry: new imaging approach tests mammography results

Breast-imaging specialists are conducting a study to determine if 3-D synthesized digital mammography can reduce the number of false-positive results.

### 7 Quality healthcare IT

The U.S. government's \$20 billion allocation for modernizing the nation's healthcare IT systems raises the question of how the funding should be spent.

### 10 Scanning the globe: advancing radiology services and education

A pediatric radiologist's work in Africa reinforces the need for improved clinical services and healthcare education in developing countries.

**ON THE COVER** Neurosurgeon Keith Rich and Neuroradiologist Tammie Benzinger are collaborating on research that may improve the outcomes of stereotactic radiosurgery. *Photograph by Tim Parker.*

### 15 Sharpening the Gamma Knife

Researchers are using an MRI technique that may identify which patients with brain cancer are the best candidates for Gamma Knife therapy.

### 20 Neandertals in the scanner

With an assist from the CCIR, a Smithsonian Institution paleontologist expands an important collection documenting man's evolution.

### 24 Let there be light

Researchers in the Optical Radiology Lab are using multimodal imaging to detect disease activity in minute detail.

### 28 Cancer Research Imaging Camp

The Institute hosts a one-week program for cancer researchers, which concentrates on cell-imaging techniques.

# SPOT NEWS

**In May 2009**, 40 fourth-graders from Flynn Park Elementary in the University City School District found that science can be fun and that nanotechnology is a part of daily life. As part of the Skills Development Component of Washington University's Program of Excellence in Nanotechnology (PEN), Carolyn Anderson, PhD, professor of radiology and of biochemistry and molecular biophysics, and her research team assisted the students in hands-on activities.



Above: Carolyn Anderson, PhD, leads students in an experiment called "Investigation of the UV-blocking abilities of different nanoparticles containing sunscreen lotions"—which assesses how much UV light passed through beads coated with lotions containing different protection factors.

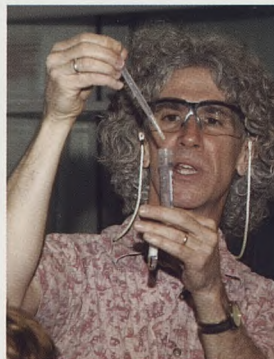
Right: In a segment called "testing the stain-repelling ability of normal and nanotechnology-enhanced fabric," Riccardo Ferdani, PhD, staff scientist, and students applied ketchup and coffee to two pieces of cloth—one made of plain cotton, the other coated with "nano-whiskers."



## Mallinckrodt Institute of Radiology Alumni

We'd like to keep in touch with you, and the fastest, easiest way is through e-mail. So, please send your e-mail address to the Director's Office at [carsont@mir.wustl.edu](mailto:carsont@mir.wustl.edu).

PEN grants, awarded by The National Heart, Lung, and Blood Institute of the National Institutes of Health, provide funding for advancing nanotechnology discoveries and applications to prevent, detect, diagnose, and treat cancer. Listed below are grant recipients and area of research:



Above: Christopher Sherman, MS, senior research technician, demonstrated dynamic light scattering in a nanoparticle solution before and after the addition of water.

- Emory University and Georgia Institute of Technology—"Detection and Analysis of Plaque Formation"
- The Burnham Institute, University of California at Santa Barbara, and The Scripps Institute—"Nanotherapy for Vulnerable Plaque"
- Harvard University, Massachusetts General Hospital, Massachusetts Institute of Technology, and Brigham and Women's Hospital—"Translational Program of Excellence in Nanotechnology"
- Texas A&M, Washington University in St. Louis, University of California at Santa Barbara,

University of California at Berkeley, and University of Texas Southwestern Medical Center at Dallas—"Integrated Nanosystems for Diagnosis and Therapy."

*Photography by Eileen Cler*



Left: Monica Shokeen, PhD MBA, instructor in radiology, and students watch as UV-beads change colors, a response to UV radiation.

# W<sup>LESS</sup> WORRY:

**New Imaging Approach May  
Significantly Decrease Mammography  
False-Positive Results**

by Mary Jo Blackwood, RN, MPH

**FOR THE WOMAN** who has a suspicious mammogram, dilemmas abound. When the mammogram identifies a suspicious abnormality but turns out to be benign, it's called a false positive. Of course, she's relieved. She doesn't have cancer. Getting to that diagnosis, however, may have required additional tests and procedures—all of which cost money and time and produce a great deal of anxiety.

**Almost 50 percent** of women have dense breast tissue; on a mammogram the dense glandular tissue may mask an underlying tumor, making it more difficult for the radiologist to interpret. Undetected abnormalities, although occurring at a low rate, can falsely reassure a patient.

## LESS WORRY: New Imaging Approach May Significantly Decrease Mammography False-Positive Results

**A**ccording to one study published in the *New England Journal of Medicine*, approximately one in four women will have a false-positive screening mammogram over a 10-year period. An abnormal screening mammogram then requires a diagnostic imaging workup, which may include additional tailored mammographic views and/or ultrasound. Some women may also undergo breast biopsy. Researchers want to reduce the number of false-positive screening mammograms while maintaining high sensitivity for detecting a malignancy.

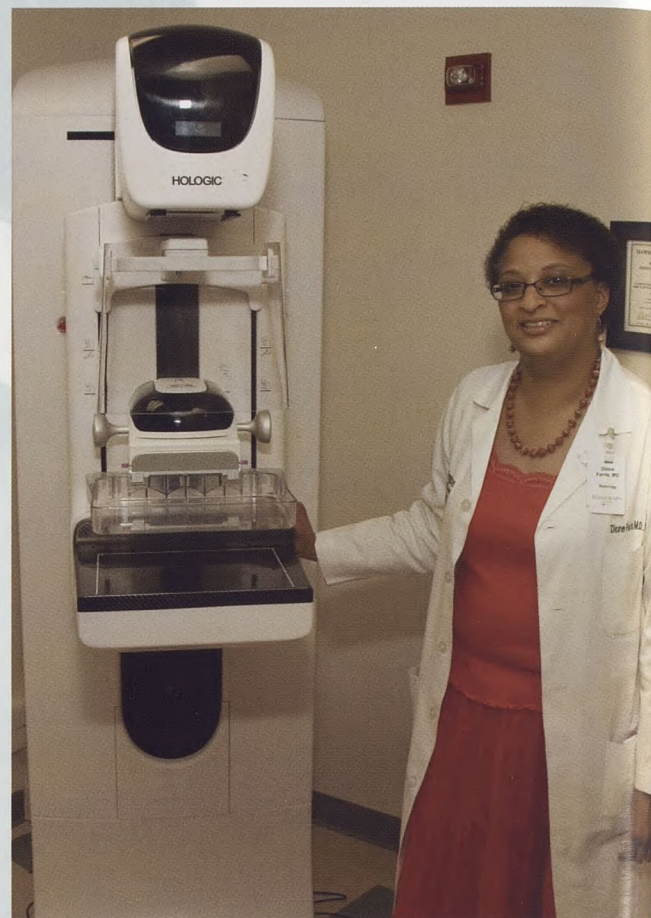**... to reduce the number of false-positive results and to point clinicians in the right direction for identifying cardinal features of malignant masses.**

A pilot study currently underway at Mallinckrodt Institute of Radiology (MIR) at Washington University School of Medicine is looking at the use of three-dimensional synthesized digital mammography—called tomosynthesis—to reduce the number of false-positive results and to point clinicians in the right direction for identifying cardinal features of malignant masses.

Dione Farria, MD, MPH, associate professor of radiology, is a specialist in breast imaging and the principal investigator in this study. “Our objective is to compare the results from conventional digital mammography to the results from three-dimensional tomosynthesis in reducing the numbers for patient recall for diagnostic workup of breast masses.

“Although conventional mammography can reduce breast cancer mortality by detecting the cancer in its earliest, most treatable stage, the technology has limitations, such as trying to acquire two-dimensional data from a three-dimensional object—the breast. As a result, there is superimposition of normal breast structures in the path of the X-ray beam, leading to a false-positive result. If a cancer is obscured, the superimposition of normal structures over an abnormality can lead to a false-negative result,” says Farria.

Most breast masses recalled from a screening mammogram are classified as benign after a diagnostic workup. By providing additional data to the radiologist regarding the features of the mass, tomosynthesis may be helpful in classifying more of these masses as benign at the time of the screening mammogram.



Dr. Dione Farria, with a full-field digital mammography unit housed in the Joanne Knight Breast Health Center in the Center for Advanced Medicine

### How 3-D tomosynthesis works

In conventional 2-D digital mammography, two screening images of the breast are acquired: one from above (craniocaudal view), one from the side (mediolateral oblique view). Tomosynthesis provides multiple images. Therefore, rather than two images, a series of 15 images are taken as the X-ray source moves in an arc above the patient's breast. Each image uses about one-fifteenth of the radiation dose of a conventional mammogram.

The imaging data is fed into a computer fitted with software that synthesizes it into 15 slices, allowing a more complete view of certain areas.

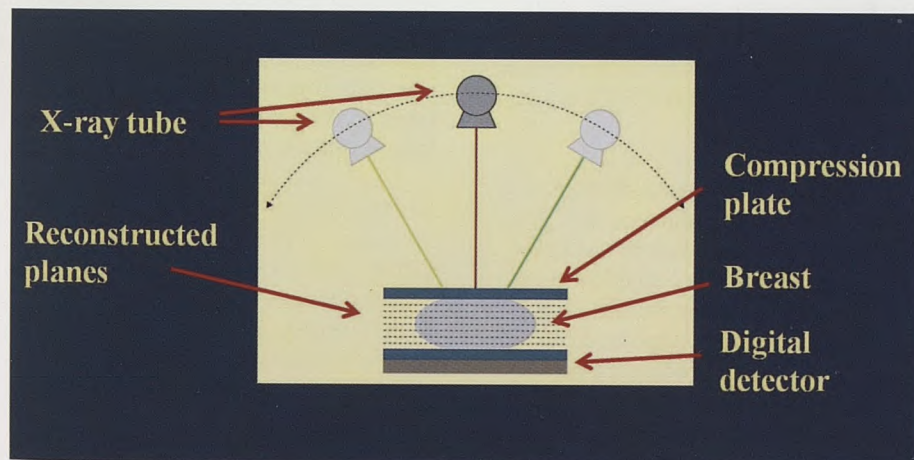
The tomosynthesis images are reconstructed using mathematical algorithms (similar to computed tomography reconstructions) to generate a set of 3-D, thinly-sliced images, which can be viewed individually as multiple images from the same breast or sequentially in a movie format that scrolls through the different planes of the breast, allowing for greater visibility of objects and lesion margins. Relative to conventional mammography, the tomosynthesis slices provide improved visibility within the cross section of breast tissue, while reducing the contrast and visibility of tissues in overlying planes.

### MIR's pilot study Phase I

This phase, which is already completed, included 12 healthy volunteers. By imaging healthy volunteers, the study investigators optimized image quality and reduced technical problems for Phase II of the study as well as for any future clinical studies.

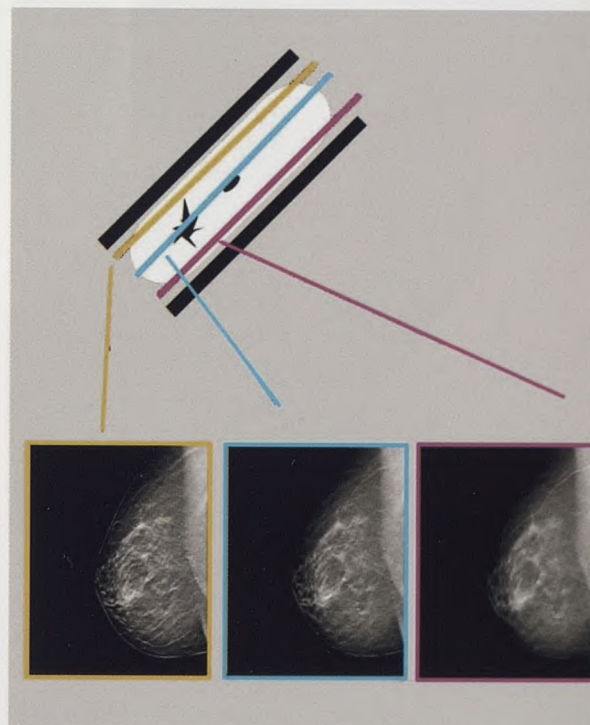
**Relative to conventional mammography, the tomosynthesis slices provide improved visibility within the cross section of breast tissue...**

Although tomosynthesis is similar to current 2-D digital imaging, none of the technologists involved in the pilot study had previously used tomosynthesis technology. They had to be knowledgeable about patient positioning and about the new software prior to imaging patients with abnormalities. Three dedicated breast-imaging technologists each imaged a minimum of four volunteers. During this training phase, system manufacturer personnel were on-site for troubleshooting and to provide additional training.



### ACQUISITION GEOMETRY FOR A MEDIOLATERAL OBLIQUE VIEW (MLO)

During imaging, 15 projection images are acquired as the X-ray tube moves from -7.5 to +7.5. Each projection image is a low dose mammogram, which images the breast from different angles. Fifteen projections are obtained, regardless of the breast size.



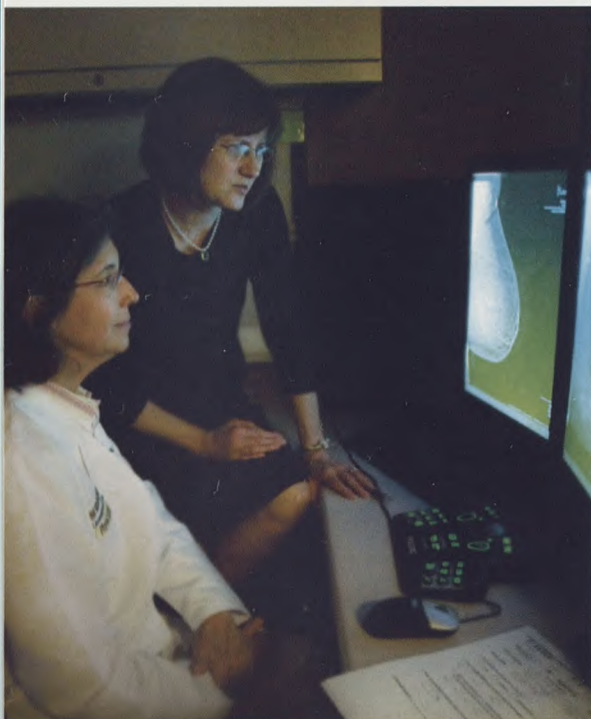### IMAGE RECONSTRUCTION

Based on the imaging data, reconstructed slices are obtained at different levels in the breast. The reconstructed slices are obtained at 1mm intervals. The number of reconstructed slices will vary with the breast thickness during compression. The interpreting radiologist views the reconstructed images in a cine or movie format.



## LESS WORRY: New Imaging Approach May Significantly Decrease Mammography False-Positive Results

Inclusion criteria for this phase of the study included females of any race or ethnicity, 35 to 80 years of age, prior screening done at Barnes-Jewish Breast Health Center. Exclusion criteria included men, prior history of breast conservation therapy, breast implants, pregnancy, current lactation, intolerance to breast compression.



Barbara Monsees, MD, chief of Breast Imaging, and (right) Kimberly Wiele, MD

### Phase II

This is a reader study of 100 cases, with 17 patients already participating. Each case includes a mass that was detected on screening or diagnostic mammography, is noncalcified, has never been biopsied or aspirated, and warrants further evaluation.

Cases will be read by four radiologists who are dedicated breast imagers with at least two years experience in digital breast imaging and with additional formal training in tomosynthesis interpretation. To reduce bias, these four readers do not participate in the standard clinical workup—which is conducted by two dedicated breast imagers with Mammography Quality Standards Act certification. This workup typically includes 2-D digital mammography tailored views and/or targeted ultrasound. Based on this workup, radiologists will determine the appropriate clinical management for the patient, who will undergo 2-D mammography and a tomosynthesis study of the breast that will be interpreted separately.

### Study implications

Says Farria: “Tomosynthesis helps with false negatives by increasing the number of cancers that breast imagers can detect, especially in women with dense breasts. Its biggest impact, however, should be in reducing recalls (false positives) by as much as thirty percent, according to preliminary research studies. Three-D tomosynthesis has great promise in differentiating overlapping normal

breast tissue from underlying lesions, but we need to collect more data on all types of breast lesions.”

Farria also wants to get a sense of whether certain cancer features better seen with tomosynthesis, such as margins, contours, and

**“Three-D tomosynthesis has great promise in differentiating overlapping normal breast tissue from underlying lesions...”**

size, may increase the breast imager’s ability to identify malignancies. That, in turn, may help to develop criteria for what makes a mass more likely to be malignant. Depending on the results, this pilot study of only 100 participants could spawn a larger study that may influence the number of women who have to endure the stress caused by false-positive mammograms.

*Editor’s note: On behalf of the Joanne Knight Breast Health Center, Dr. Farria received an \$8,000 award from the St. Louis Men’s Group Against Cancer to support testing of digital breast tomosynthesis. **MIR***



# Quality Healthcare *IT*

by Amy Thomas, MD, FAAP

The topic of United States healthcare reform is inspiring fierce debate. Politicians and citizens alike are committed to their parties' agendas and convinced of the other's flaws. But even the most opposed of ideologues agree on something: Our healthcare system is disorganized and fragmented, leading to frequent overtreatment and preventable medical errors. That's why, amid mudslinging over such contentious issues as socialism, corporate greed, and euthanasia, few people are complaining about the \$20 billion that President Obama has allocated for modernizing the nation's healthcare information technology (IT) systems. However, a growing contingent of healthcare professionals and opinion leaders are beginning to raise questions about how, specifically, this IT funding should be spent.

# Quality Healthcare IT

It is easier to think about buying things than it is to think about what you're going to do with it," says James Duncan, MD, PhD, an associate professor of radiology at Mallinckrodt Institute who is passionately advocating thorough consideration be given to where the IT dollars go.


In May, the medical journal *JAMA* ran a commentary, coauthored by Duncan and Ronald Evens, MD, former director of Mallinckrodt Institute and former president of Barnes-Jewish Hospital, on how the Obama administration's commitment to healthcare IT will fall short without a sizeable investment in determining how these new systems can deliver the kind of quality care they promise.

"Everybody talks about 'quality care,' but the question is, how do you define quality?" says Duncan. "In medicine, we tend to talk in generalities because it's not clear what we are measuring. When compared to basic medical research, few resources have been allocated to learning how to improve care."

**When compared to basic medical research, few resources have been allocated to learning how to improve care.**

"Before designing more systems to collect and organize data, we need to learn how it will be used to improve care. Most businesses wouldn't dream of making such a large investment in information technology without first having a clear plan as to how it will add value," Duncan adds.

"'More is not necessarily better' is a concept that has general acceptance among health-care



Ronald Evens, MD Photo courtesy of BJC Media Services

practitioners," says Evens. "The research of Jim Duncan and his colleagues can lead the field of medicine in identifying what procedures and practices are 'better' and which ones are not."

## Cars, Planes and...Patients?

In making his point, Duncan draws parallels between medicine

and other industries. Toyota, for example, has become world-famous for its ability to set and meet clear objectives. The Japanese car company operates as a learning organization—one that strives to continually improve its performance. This performance is based on two strategic concepts—quality of its plans and capacity to execute those plans. The quality

of a plan is measured by the probability that a plan will achieve its desired goal and quality of execution is measured by how well products conform to plans.

Duncan believes these principles can be applied to medicine. "We need to collect data on system performance, analyze that information to uncover the relevant patterns and use that knowledge to improve future performance," he says.

"Critics of a more systematized, objective approach to medicine argue that you can't compare car production to caring for sick people, because there is not the same level of unpredictability and risk," says Duncan, who vehemently disagrees.

"This mode of thinking actually comes out of the military," he explains. "What could be more dangerous and risk more human lives than trying to land an airplane filled with fuel and bombs on a small piece of metal in the middle of the ocean? Further, this ship contains a nuclear reactor and must operate in all types of weather conditions while maintaining a vigilant eye on a determined enemy. I don't think that what we do in medicine is any more complicated than these military feats and other complex human endeavors."

## Decision Support

Advanced technology systems, according to Duncan, should be designed around the idea that human behavior and error is largely predictable, regardless of what industry you're in. In medicine, a systematic approach is needed to understand why physicians do what they do under defined circumstances. Once this information is captured, it is incorporated into an electronic system that automatically prompts the user to the next step based on how the situation has been handled in the past.

"It's this idea of electronic information systems as decision support," says Duncan. "These intelligent information systems are really modeled after how humans think."



James Duncan, MD, PhD, in the interventional radiology suite at St. Louis Children's Hospital

Radiology may be an ideal specialty for demonstrating this concept. "Our stimuli are captured very well," says Duncan. "We have something to work with that allows us to define exactly what's going on and to make predictions about what should happen next. That is hard for the rest of medicine to do."

And these kinds of decision-support systems are much needed in our field, which has a tendency to over-test in the interest of collecting more information, Duncan adds. At some facilities, magnetic resonance, positron emission tomography and computed tomography scans are often performed in excess, unnecessarily exposing patients to radiation and driving up

healthcare costs. Information technology systems that offer decision support would let the physician know when enough data has been collected to make an informed decision.

"Radiology is a specialty with a foundation of new technology and its use for quality patient care," says Evens. "Radiologists will be enthusiastic about an evidence-based approach that can define how to ensure quality within our practice."

**The technology is there but we need to invest in people to study how we can improve and test those ideas.**

#### Next Steps

In order to make systems like these a reality, money must be invested in people who know how to develop them. "The technology is there," says Duncan, "but we need to invest in people to study how we can improve and test those ideas."

Duncan and Evens are not the only ones making this point. *Washington Monthly*, in its July/August cover story, looked at how different software systems can affect the success with which a hospital digitizes its medical records. The article touts the benefits of what is known as open-source software, for its ability to allow users to modify programs in accordance with each institution's unique needs, over proprietary software that limits the user's ability to modify the system.

"The proprietary systems have earned a bad reputation in the medical community for the simple reason

that they often don't work very well," reports *Washington Monthly*. "The programs are written by software developers who are far removed from the realities of practicing medicine. The result is systems which tend to create, rather than prevent, medical errors once they're in the hands of harried health care professionals."

Clearly, buying a bunch of shiny new computer systems isn't going to cut it. But recognizing that

and acting on it are two different things. One of the main obstacles to making operational research a priority within Obama's healthcare IT budget is that no one is in charge.

A move in the right direction would be the formation of a national committee to oversee the initiative, coach professionals, and document best practices. Some may argue that this is impossible in an industry notoriously mired in bureaucracy and fragmented interests.

To that, Duncan says, "Look at the systems used to train the Olympic athletes or any professional sports team. That's happening on a national scale. They get the best people they can find and continually train as individuals and as teams so that they can become better. Sports teams invest heavily in these training regimens and their systems that are far more scientific than those found in most of medicine. Shouldn't we make the same types of investments in improving our medical teams?" ■

# Healthcare

# Scanning THE GLOBE

A Mallinckrodt Institute pediatric radiologist works to advance radiology services and education in developing nations by Candace O'Connor



*Africa,*  
*February 15,*  
*2009*

*Drove to Maseru, capital of Lesotho, about four hours from Johannesburg, South Africa. Lots of rain at the border crossing. Rolling hills, big sky and puffy clouds. Some cows and sheep; people walking along the highway. Women carrying things on their heads....*

All photos courtesy of  
Rebecca Hulett Bowling, MD

## Memories of Africa

In her personal journal, pediatric radiologist Rebecca Hulett Bowling recorded her first impressions of Lesotho, the small, impoverished, mountainous nation where she spent a week in the spring of 2009. This trip to Africa was prompted by a friend—Teresa Fritts, MD, a pediatrician working with the Baylor International Pediatric AIDS Initiative in Lesotho—who invited Bowling to visit Maseru for two weeks to provide some training in pediatric imaging for the physicians at Queen Elizabeth

Hospital. These physicians—most with minimal radiology training—routinely had to read their own patients' X rays because the hospital's one staff radiologist had to spend his time on ultrasound and fluoroscopy studies.

It was her fourth medical trip overseas and her first to Africa, where the state of health care shocked and, at times, overwhelmed her. "Conditions at the hospital were so oppressive," she says. "It was dirty, dark, old, with cockroaches crawling on the walls. The signs, like 'Women's TB Ward,' were ancient—I sometimes felt that I was in a time warp. That hospital had the only CT

[computed tomography] scanner in Lesotho, and it had been broken for over a year."

Inevitably, Bowling, an assistant professor of radiology at Mallinckrodt Institute of Radiology (MIR), found herself thinking wistfully of American hospitals, especially St. Louis Children's Hospital (SLCH), with its state-of-the-art equipment and top-quality care. After completing her training at the University of Michigan in

1991, she spent 16 years at the University of Arizona in Tucson before joining the SLCH pediatric radiology staff in 2006. Along with her clinical work, she also heads the MIR pediatric radiology clinical fellowship program.

Among her memories of Africa are also the indelible images of patients, who were polite and touchingly grateful. There were mothers, wearing the trademark Lesotho straw hats and blanket-



*Africa, February 17, 2009.*

*We left the house at 7:30 a.m. and drove one-and-a-half hours to Mafetang in the hilly, green countryside. I gave a lecture to four physicians there, then we went in to town where we ate outside at a restaurant. It was a very hot day, and some women were cleaning the streets. They came up and waited, motioning that they wanted our leftover drinks when we were finished.*

# Scanning THE GLOBE

dresses that double as bedding when they are admitted to the hospital. And there were children, who had the charm and laughter of children everywhere—and loved to have their pictures taken.

“Once I was feeling unhappy about the facility and the things they didn’t have when I met a cute seven- or eight-year-old boy who was on crutches because of a broken leg,” says Bowling, an avid photographer. “He was happy to pose against a wall, with his little sister tagging along. It was nice that, on a day when so many depressing things were going on, there could be a few smiles.”

## Beginning the journey

A decade ago, Bowling heard about a medical mission to the Dominican Republic through her Baptist church in Tucson and

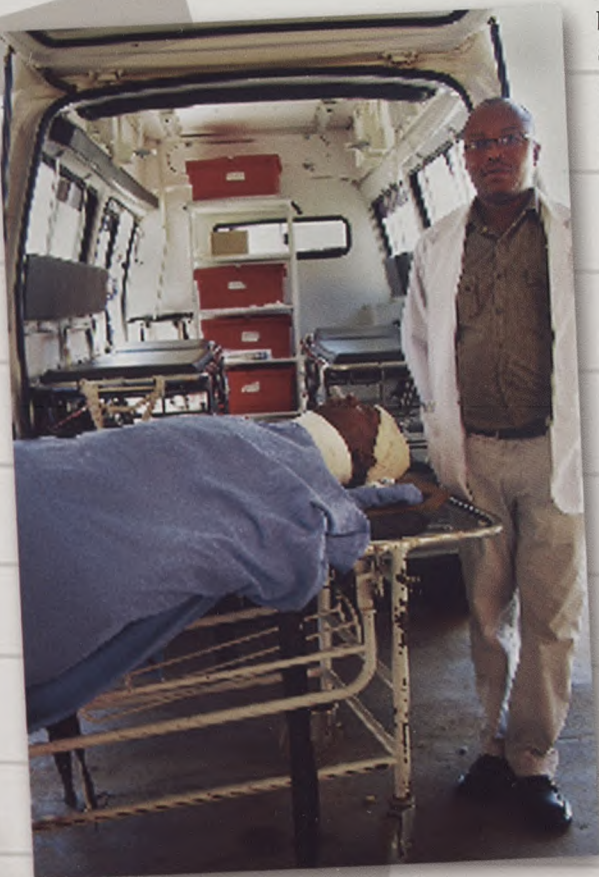decided to go as a general medical provider. She loved to travel and had always been curious about other cultures. Now she was eager to see how medicine was done in a different part of the world.

She traveled to rural clinics, where there was no radiology equipment of any kind, and provided basic care: checking vital signs, prescribing medication. Her help came in handy, as she treated many cases of diarrheal diseases, tropical parasites, and various infections. But she quickly realized that all of her work was only a short-term fix: these people needed more education to prevent future illnesses.

“We were putting a band-aid on things,” she says. “People needed to know how to stop these illnesses from recurring, such as washing their

hands or using an outhouse instead of the surrounding fields. The information they lacked was simple but important.”

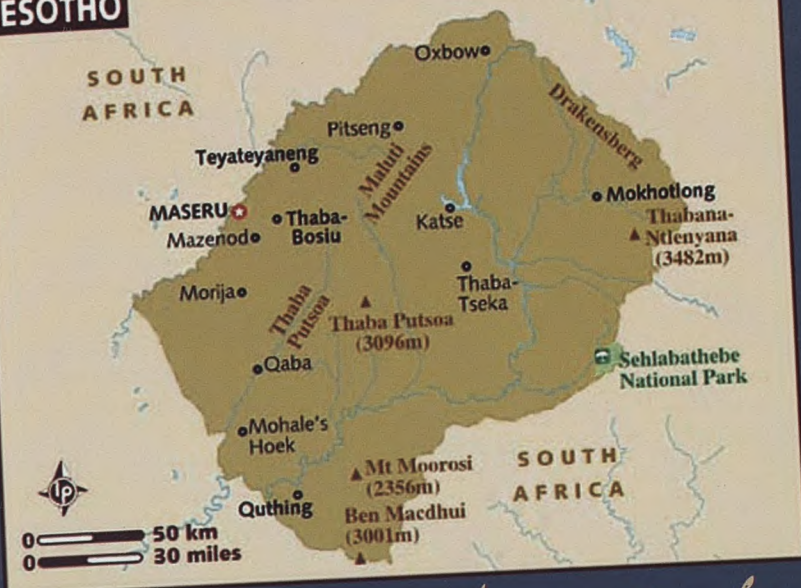So for her next overseas trip in 2002, Bowling signed up with a San Diego-based program—New Start—to spend two weeks at a hospital in Romania as the only radiologist in a group of 12 pediatricians. Her job was to educate the physicians there—most of



## Africa, February 22, 2009

*I went to another clinic in Lesotho for my last lecture; one of the doctors wanted me to look at some X rays. On the way to the light box, we passed the patient whose X rays I would be seeing: a young man in his 30s, wearing a soft neck collar and lying on a stretcher next to an old ambulance. On the X rays, I saw that he had a cervical spine fracture—a broken neck. In our hospitals at Washington University Medical Center, he would be in the Emergency Room, hooked up to an IV, fitted with a neck brace, and surrounded by many physicians.*

## LESOTHO



### LESOTHO: *The Kingdom in the Sky*

- Official name: Kingdom of Lesotho
- Former name: Basutoland
- Won independence from the United Kingdom in 1966
- Government: constitutional monarchy
- Population: estimated 1.8 million
- Geography: entirely surrounded by the Republic of South Africa; one of a few countries in the world with an altitude of 1,000 meters above sea level
- Economics: 40 percent of the population live below the international poverty line (\$1.25 US per day)

whom spoke English—about radiology for newborns in the hospital's Neonatal Intensive Care Unit. Did the premature babies have brain hemorrhaging? What was the X ray or ultrasound telling the physicians?

"I was impressed with what the hospital had," she says now. "They had a clean facility. While they did not have an MRI [*magnetic resonance imaging*] or a CT machine, they had decent, functional equipment, including ventilators, that was donated from other countries.

Of course, the equipment wouldn't be considered that good when compared to what we [*Mallinckrodt Institute*] have."

Two years later, she made another trip with the same organization, this time to Lithuania. There, her experience was much the same: The hospital was clean, with donated equipment—and this time they even had an old, but working, CT machine. And she began to feel that by training these physicians, she was making a small but significant difference in radiology education.



Doctors Teresa Fritts (left) and Rebecca Hulett Bowling with the owner of a game farm in Namibia.

### The kingdom in the sky

As Bowling discovered, the need for medical help in Lesotho is immeasurable, heartbreaking. Overall, the country has one of the highest rates of AIDS in the world, around 30 percent. Among patients with AIDS, the incidence of tuberculosis is a stunning 70 percent, which makes chest X rays vitally important. Yet there is only one physician for every 20,000 people; in the United States, there is one for every 400.

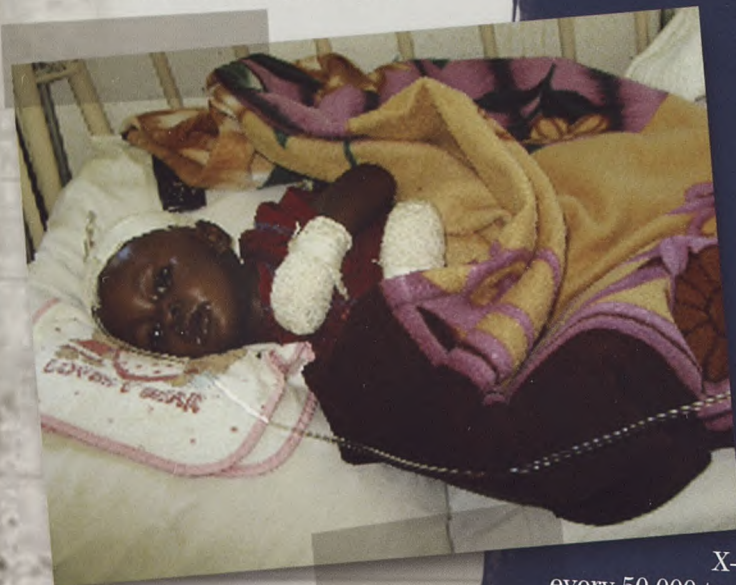"About thirty-five percent of Lesotho's working males go to South Africa to work in the mines for extended periods. And they become infected with the AIDS virus," Bowling says. "Then they bring the infection back to their own country. I met one mother there who had just lost the last of



# Scanning THE GLOBE

her four children to AIDS, and she was infected, too. It becomes a way of life."

Bowling gave lectures and read film after film, comparing her findings with those of the staff physicians. Her visit flew by. With Fritts planning a medical mission to Tanzania, Bowling hopes to once again provide more health-care education and clinical help in Africa.



Now she fervently appeals to other health-care providers to do the same.

"You can look at a place like Lesotho and say: 'There is such a huge problem. What can we do that will make a difference?' But there has been a start, and we **must** move forward. Physicians in the United States have the advantage of advanced medical training provided by top-rated facilities, like Washington University Medical Center, and should share that training with medical groups in developing countries. It could make a huge difference in the lives of millions of people." **MIR**

## RADIOLOGY IN THE *Developing world*

While industrialized nations have sophisticated technology and well-trained radiologists, the situation in developing nations is radically different.

Nearly two decades ago, Carl-Gustav Standertskjöld-Nordenstam of the University of Helsinki's Department of Public Health wrote: "Globally, however, radiology is a luxury. More than three-quarters of the world's population lives in circumstances in which the possibility of receiving even the most elementary radiological services is exceedingly remote..."<sup>1</sup>

In the developing world, there may only be one piece of

X-ray equipment for every 50,000 to one million people and one radiologist for every 100,000 to two million. "These statistics... mean that the scope of delivering satisfactory radiological services is severely limited," continues Standertskjöld-Nordenstam, "particularly as standards of both equipment and radiology often leave much to be desired."<sup>1</sup>

For several years, leading radiologists have been calling for change. "Radiology organizations in the United States must join with their counterpart societies around the world to help developing nations raise the level of their radiology

services," wrote C. Douglas Maynard, MD, in a 2001 issue of the journal *Radiology*.<sup>2</sup>

Now some major radiology organizations are taking action. The American College of Radiology (ACR) says it is "committed to facilitating improvements in radiological care throughout the world." In 2004, the ACR created a Committee on International Service, focused in part on improving radiology in developing nations. On its website ([www.acr.org](http://www.acr.org)), the ACR also offers a list of health organizations that provide international service opportunities.

The Radiological Society of North America has an international radiology e-mentoring program. And the International Society of Radiology has a global outreach program, called "GO RAD," intended to advance radiology education by collecting literature related to international radiology issues.

### References

1. Standertskjöld-Nordenstam C-G. *Radiology in an international perspective*. In: Pettersson H, ed. *The NICER Centennial Book 1995: A Global Textbook of Radiology*. Oslo, Norway: The NICER Institute; 1995:13-15.
2. Maynard CD. *Radiology: future challenges*. *Radiology*. 2001;219(2):309-312.

*Developing world*



# Sharpening<sup>THE</sup> Gamma Knife

## A NEW MRI TECHNIQUE

MAY IDENTIFY THE BEST CANDIDATES FOR THIS BRAIN CANCER TREATMENT AS WELL AS IMPROVE FOLLOW-UP CARE

BY ROBERT LOWES

Every year at Washington University Medical Center's Siteman Cancer Center, dozens of patients with metastatic brain tumors lie down with their head resting inside a large metallic cylinder. Instead of going under the proverbial knife, they're going under the Gamma Knife<sup>®</sup>, a form of stereotactic radiosurgery.

## Sharpening <sup>THE</sup> Gamma Knife

**T**he Gamma Knife epitomizes what's good about non-invasive surgery, but good can always get better. Some metastatic brain tumors, for example, are more resistant to radiation treatment than are others and therefore warrant traditional surgery, but determining a tumor's toughness ahead of time can be challenging. Similarly, monitoring the aftermath of Gamma Knife treatment with follow-up magnetic resonance imaging (MRI) may be problematic because it's hard to distinguish radiation necrosis from recurrent tumor growth in the area of the brain that received the high dose of radiation.

Hopefully, a diagnostic tool to sharpen the use of the Gamma Knife could be in the wings. A team of researchers led by Tammie Benzinger, MD, PhD, associate professor of radiology, is studying whether a form of MRI called qBOLD—developed at Mallinckrodt Institute—can predict a brain tumor's response to radiation. Benzinger also expects to confirm her hunch that qBOLD can tell the difference between a born-again malignancy and its necrotic impersonator.

### **A clearer picture of oxygen consumption**

In the new pilot study, funded by the American Cancer Society, Benzinger is measuring how much blood-borne oxygen is used by healthy, cancerous, and necrotic brain tissue. Oxygen uptake appears to be a tell-tale proxy.

“Metastatic brain tumors generally consume more oxygen—and have higher metabolic rates—than do normal cells, apparently because they're so busy multiplying,” says Benzinger. “Then you have hypoxic tumors that are starving for oxygen, usually because they have outgrown their blood supply.”



Doctors Keith Rich and Tammie Benzinger in the Gamma Knife facility, which houses the Leksell Perfexion Gamma Knife®, the most technologically advanced equipment available.

“There's growing evidence to suggest that hypoxic tumors are harder to kill with radiation or chemotherapy,” she says. “The lower their oxygen level, the more resistance they have. Patients with these kinds of lesions may be better off with traditional surgery.”

Over the past two decades, radiologists have been able to get a rough idea about brain oxygen levels with blood-oxygen-level-dependent MRI, or BOLD for short. In essence, it images the amount of

deoxygenated hemoglobin, says Benzinger. "But BOLD only tells you how much blood is present in a given volume of brain. There's no quantification of oxygen extraction."

Enter a more precise version of BOLD dubbed qBOLD—the "q" stands for quantitative—developed by Dmitriy Yablonskiy, PhD, professor of radiology and of physics, and Xiang He, PhD, instructor in radiology. They first proposed the technique in a 2007 article in the journal *Magnetic Resonance in Medicine* and a year later published a second article (also in *MRM*) demonstrating how qBOLD calculated the percentage of bloodstream oxygen extracted by the brain tissue of lab rats—the so-called oxygen extraction fraction, or OEF. Direct measurement of blood oxygen levels, done invasively, showed that these OEF numbers were accurate.

Benzinger's research team is now taking qBOLD snapshots of metastatic brain tumors in humans before and after Gamma Knife treatment, all with the goal of determining their particular OEF. Such information could help clinicians identify the more hypoxic tumors that should not be treated with Gamma Knife and adjust the radiation dose for less hypoxic ones. Performing the radiation procedures in the study are neurosurgeons—and coinvestigators—Keith Rich, co-medical director of the St. Louis Gamma Knife Center at Siteman Cancer Center, and Sarah Jost, at the Swedish Neuroscience Institute in Seattle, Washington.

At the same time, Joel Garbow, PhD, research associate professor of radiology, is supervising qBOLD studies of lab mice that also are

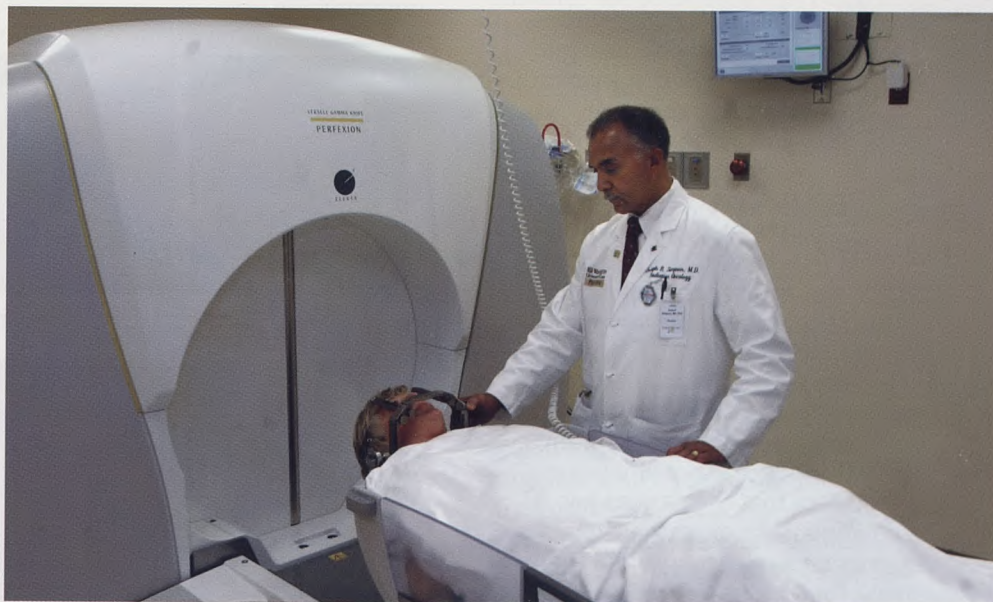
undergoing Gamma Knife treatment for brain tumors. A motivation for performing experiments in rodents is the ability to subsequently examine brain tissue under a microscope (correlative histology), helping to provide validation of the qBOLD method that can be extended directly to human subjects. Other collaborators are Parinaz Mas-soumzadeh, PhD, post-doctoral fellow, and He and Yablonskiy, who designed the MRI sequence.

The research team anticipates that hypoxic tumors will display a higher OEF than their well-oxygenated counterparts. After all, what qBOLD tells them is not necessarily overall oxygen consumption, but the percent pulled from the bloodstream. "A poorly vascularized tumor might use nearly all of the scarce oxygen there is," says Garbow. "By contrast, a highly vascularized tumor will consume more oxygen, but it's a lower percentage of what's available."

To put OEF into the context of blood supply, the team is conducting MRI perfusion studies of human and laboratory rodents. It's among several standard MRI techniques being deployed in the study, says Benzinger. "By itself, qBOLD may not be definitive. It's one component of multiple exams, adding extra value."

### **Solving the look-alike problem**

Gamma Knife radiation has become a favored weapon against metastatic brain cancer due to its ability to minimize collateral damage to healthy tissue while delivering a powerful dose of destruction to a tumor. The Gamma Knife aims 192 beams of gamma radiation at the tumor from different directions. Each individual beam is too weak to harm healthy tissue, much less malignant tissue. But when the 192 beams converge, they generate enough energy to eradicate the tumor.



Joseph Simpson, MD, PhD, co-medical director of the St. Louis Gamma Knife Center. Gamma Knife is a minimally invasive treatment option for conditions such as meningiomas, pituitary adenomas, trigeminal neuralgia, and arteriovenous malformations. Photo courtesy of BJC Media Services.

# Sharpening THE Gamma Knife



"In some cases, it may be the best option for a solitary metastasis," says Benzinger. "If you have multiple metastases, though, you may be a candidate for whole-brain radiation, or a combination of that and the Gamma Knife."

Even though the Gamma Knife is designed with safety in mind, some patients treated this way nevertheless experience radiation necrosis that affects brain tissue adjacent to the tumor. It's a complication that may surface months or years after treatment and result in brain tissue swelling and subsequent neurologic injury.

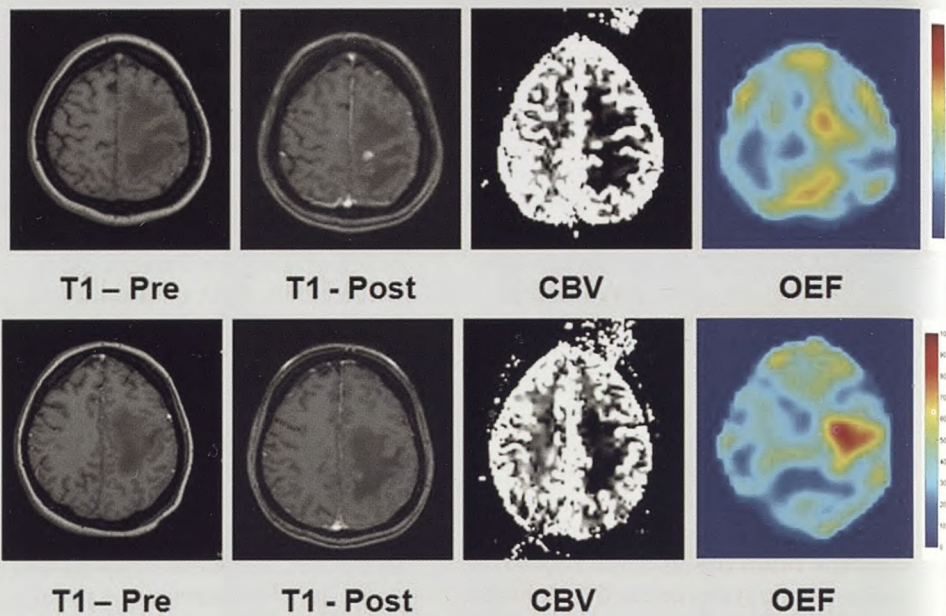
Steroids relieve some of these symptoms. However, what often vexes neurosurgeons and radiation oncologists about radiation necrosis is that current imaging techniques—namely, MRI and positron emission tomography—

may be unable to distinguish radiation necrosis from a current tumor, especially if the tissue in question is smaller than a centimeter. Diagnosis is even harder when a suspicious region of the brain consists of both recurring cancer and once healthy but now necrotic tissue. A biopsy can distinguish between the two conditions, but that means additional surgery that surgeons and patients would like to avoid.

"If a patient has a recurrent tumor, the standard treatment is removing it during a craniotomy," says Benzinger. Knowing prior to surgery that the patient has radiation necrosis rather than a recurrent tumor may avoid the need for a biopsy.

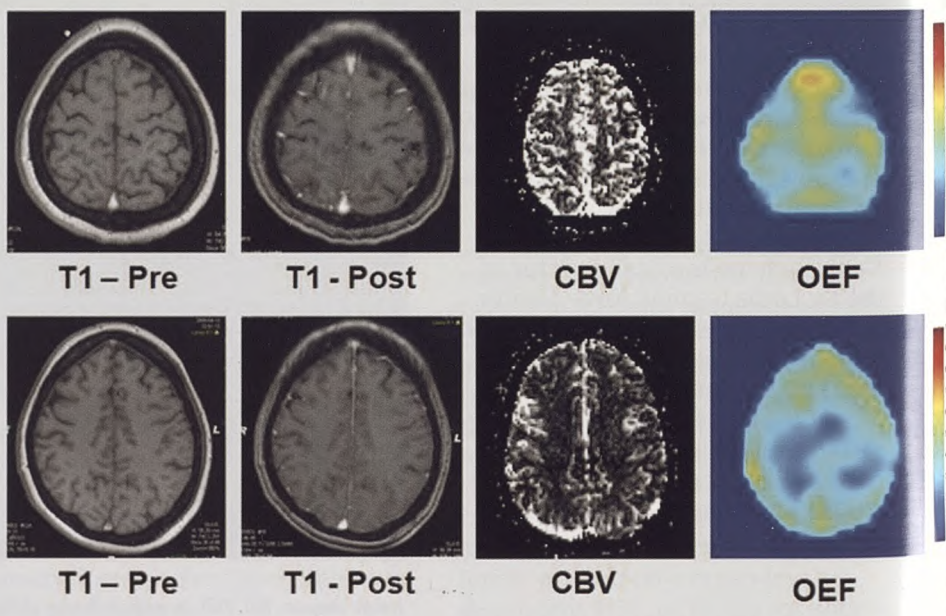


Xiang He, PhD



Above: T1 pre- and post-contrast. CBV and OEF is shown of same scan prior to stereotactic radiosurgery (SRS) therapy with lesion (first row) and vasogenic edema (second row) for a 48-year-old woman with metastatic non-small cell lung cancer.

Below: 6 months post-SRS. Same patient and similar slices as shown above. Note reduction of the lesion and edema.



"On the other hand, if physicians conclude that a patient has radiation necrosis when in fact the tumor is coming back," Benzinger adds, "patients may not get the follow-up surgery they need."

Benzinger expects qBOLD MRI to tell these two look-alike conditions apart, based on measurable differences in oxygen uptake. Brain tissue killed by radiation, she says, is likely to post a lower OEF than healthy tissue since it no longer needs oxygen. Garbow's animal studies will help to assess the technique's accuracy.

"By examining tissue under a microscope, we can easily distinguish necrosis from tumor," says Garbow. "So if we study the qBOLD data in vivo and tentatively conclude that a certain area of the brain is mostly necrotic, we can confirm that later with histological analysis."

This component of the study will build on research—coauthored by Garbow and Jost, among others—on characterizing radiation necrosis in lab mice, an article that recently appeared in the *International Journal of Radiation Oncology \*Biology\*Physics*. "We think we'll be able to quickly translate our results from the animal side to the human side," says Garbow.

### **The widening scope of qBOLD**

Benzinger says she's delighted by how quickly qBOLD, which is just a few years old, has become a clinical research tool. "Often there are long lags between the development of bench science and its application in animal and human studies," she says.

(left to right)  
Researchers Parinaz Massoumzadeh, Dmitriy Yablonskiy, and Joel Garbow, with the small-bore MRI scanner used to image animal models.

While her team looks forward to the initial findings of the qBOLD study, they're also setting the stage for future research. They're creating a permanent database of qBOLD images at MIR that will allow

researchers to track patients who've undergone Gamma Knife radiation. That's important, says Benzinger, since radiation necrosis may emerge years later. "We can look back at the early imaging data and see what might have predicted the necrosis," she says.

Benzinger hopes to secure additional research grants that would let her expand the study to include other satellite research sites besides the one in Seattle. "Neurosurgeons across the country who use the Gamma Knife could send us qBOLD data, and we'd process it," she says.

The study may expand in another way—examining how a patient's genetic profile factors into a tumor's oxygen uptake and resistance to Gamma Knife radiation. The fledgling databank would store that information as well.



qBOLD promises to keep Benzinger busy. She's collaborating with other Washington University researchers who are examining whether the technique can benefit studies of traumatic brain injury in children and neurocognitive disorders associated with HIV. Eventually, she'd like to use the technique in studies of patients with Alzheimer's disease. "It's not clear what's happening metabolically to their brain tissue before it atrophies," she says. "qBOLD might help us to understand what's going on in the early stages of Alzheimer's disease."

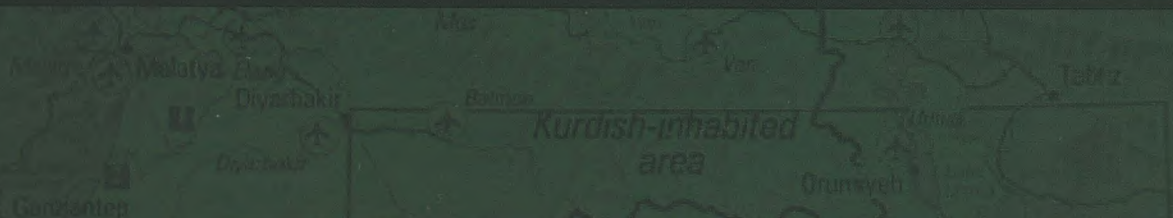
Yet another possible research path is using qBOLD to identify which brain tumors are best targeted with anti-angiogenic drugs, which inhibit blood-vessel formation. The ideas are bold—befitting the potential of qBOLD. **MIR**

# Neanderthals

by Vicki Kunkler

## IN THE SCANNER

*Imaging links to human evolution*



**Mesopotamia**, the land between the Euphrates and Tigris rivers, the cradle of civilization. This ancient territory, which today corresponds to Iraq, northeastern Syria, and parts of southeastern Turkey and southwestern Iran, was home to some of the world's most highly developed urban societies. Relics from the ruling empires—Sumer, Akkadian, Babylonian, Assyrian, Achaemenid, Persian, and Sussanid—eventually were housed in Baghdad's National Museum of Iraq.

In 2003, at the beginning of the Iraq War, looters ransacked the National Museum, carrying off hundreds of priceless antiquities. The museum reopened in 2009, having recovered about half of the missing relics, and is now under tight security. However, Iraq's hundreds of archaeological sites, dotted throughout the countryside, didn't fare as well.

Among the most notable objects taken from the archaeological digs are the nine adult Neandertal (the preferred word usage) skeletons that were discovered by Ralph Solecki and his team from Columbia University during cave excavations in the Zagros Mountains between 1957 and 1961. The skeletons, of varying ages and composition, were found in the Shanidar Cave

**"RESEARCHERS IN THE U.S. CAN GATHER DATA FROM THIS CAST COLLECTION EASILY, WITHOUT HAVING TO TRAVEL ABROAD"**

in Iraqi Kurdistan. Today, one of the skeletons and endocasts of the others are at the Smithsonian Institution; the other original skeletons are in the National Museum of Iraq, but their conditions are not known.

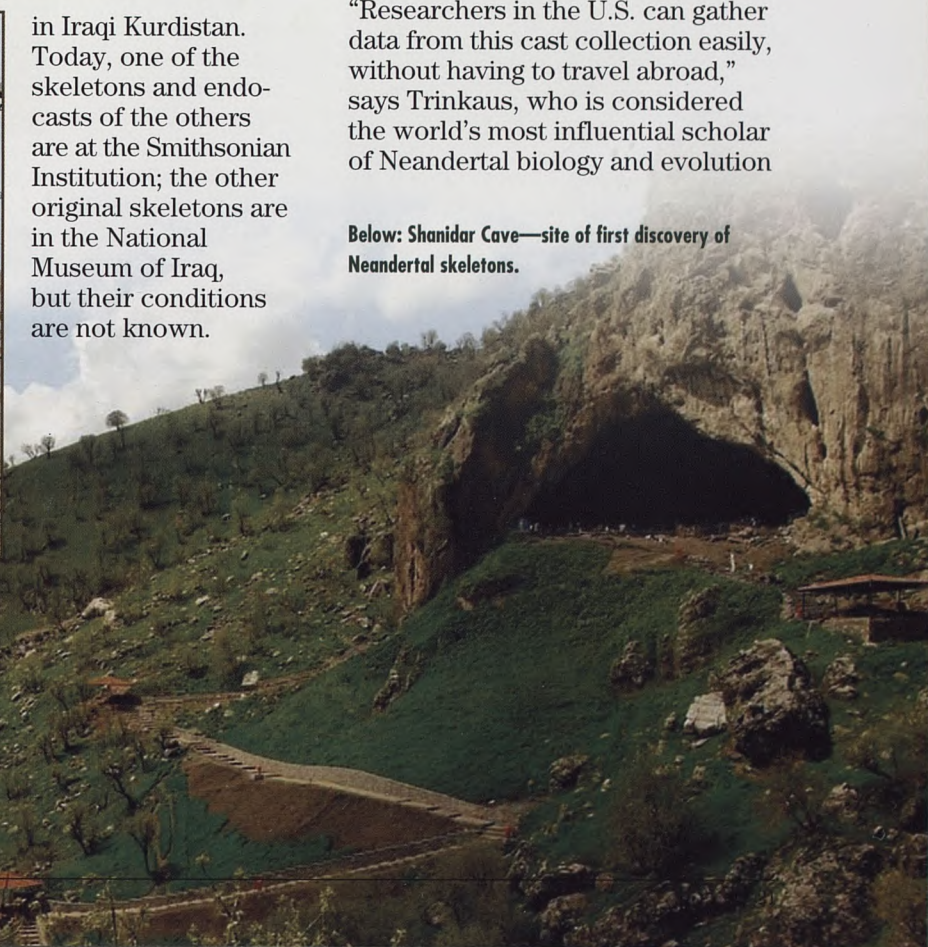
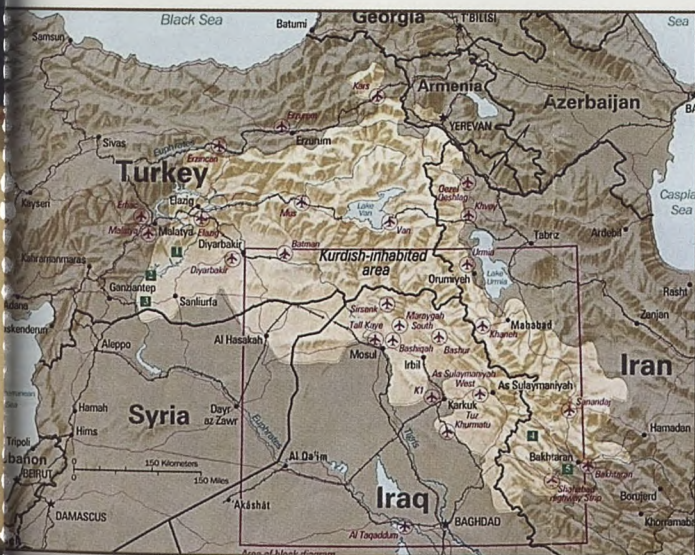

Erik Trinkaus, PhD, holding a Neandertal skull from his collection. Photo by Joe Angeles, Washington University in St. Louis.

Erik Trinkaus, PhD, professor of anthropology at Washington University in St. Louis, has one of the United States' largest collections of epoxy, polyester, and plaster replicas of Neandertals and early humans: skulls, arms, legs, hands, and feet used for research and as a teaching repository.

"Researchers in the U.S. can gather data from this cast collection easily, without having to travel abroad," says Trinkaus, who is considered the world's most influential scholar of Neandertal biology and evolution

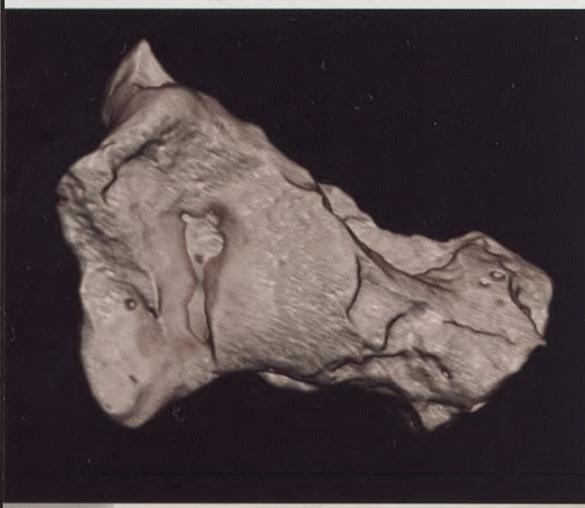
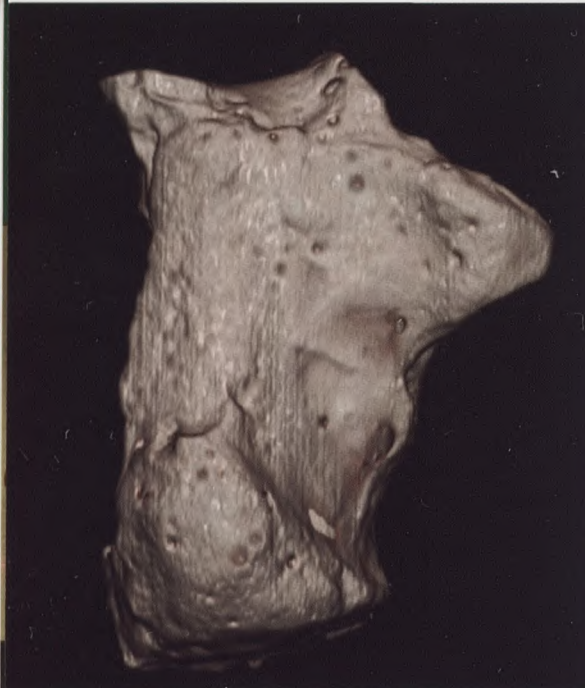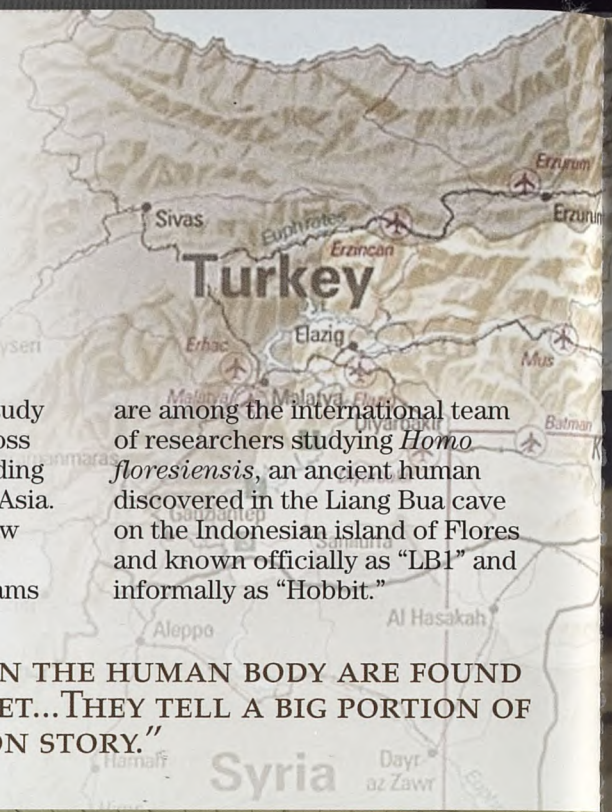
Below: Shanidar Cave—site of first discovery of Neandertal skeletons.





# Neandertals

## IN THE SCANNER

3-D computed tomography (CT) reconstructions. Spiral CT can acquire data at 500m field of view, with a detailed field of view at 50m.

and has been involved in the study of original human remains across Europe, southwest Asia (including the Shanidar fossils), and east Asia. In late March 2009, Matthew Tocheri, PhD, a paleontologist with the Human Origins Programs

are among the international team of researchers studying *Homo floresiensis*, an ancient human discovered in the Liang Bua cave on the Indonesian island of Flores and known officially as "LB1" and informally as "Hobbit."

**"HALF OF THE BONES IN THE HUMAN BODY ARE FOUND IN THE HANDS AND FEET...THEY TELL A BIG PORTION OF THE HUMAN EVOLUTION STORY."**

at the Smithsonian Institution's National Museum of Natural History, arrived in St. Louis. For Tocheri, whose research focuses on the form and function of primates' hands and feet, Trinkaus' collection offered a "key to understanding how the hands and feet have evolved within the hominin lineage."



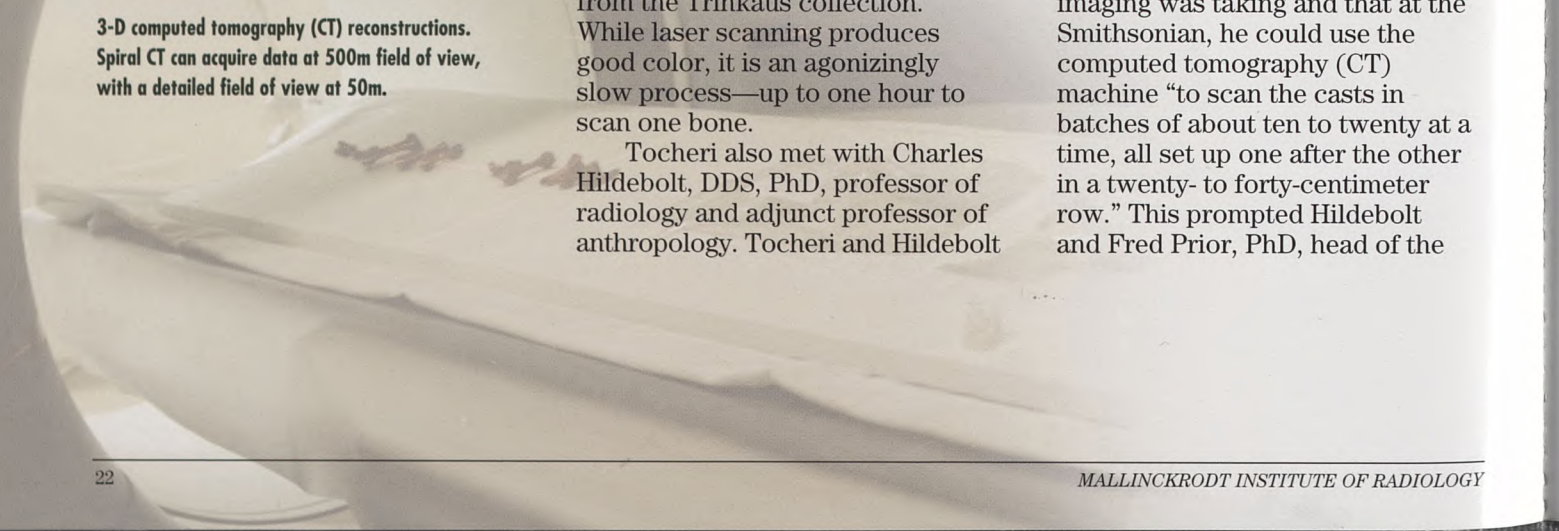
Real-time images are shown on the computer monitor in the CT control room. (Standing, left to right) Charles Hildebolt, PhD; Matthew Tocheri, PhD; Bruce Whiting, PhD. (seated) Timothy Street, RT(R)(CT).


"Half of the bones in the human body are found in the hands and feet," he says. "They tell a big portion of the human evolution story."

Tocheri planned to use a laser scanner to capture detailed measurements of nearly 250 specimens from the Trinkaus collection. While laser scanning produces good color, it is an agonizingly slow process—up to one hour to scan one bone.

Tocheri also met with Charles Hildebolt, DDS, PhD, professor of radiology and adjunct professor of anthropology. Tocheri and Hildebolt

During their meeting, Tocheri mentioned how long the laser imaging was taking and that at the Smithsonian, he could use the computed tomography (CT) machine "to scan the casts in batches of about ten to twenty at a time, all set up one after the other in a twenty- to forty-centimeter row." This prompted Hildebolt and Fred Prior, PhD, head of the





Matthew Tocheri arranging Neandertal hand bones on the CT scanner bed

Electronic Radiology Lab, to contact John Kotyk, PhD, associate director of the Center for Clinical Imaging Research (CCIR).

The CCIR is a state-of-the-art biomedical imaging facility that provides the latest in advanced imaging technology, equipment, and expertise to support basic and translational inpatient and outpatient clinical research. Kotyk quickly offered to provide time on the high-resolution, 64-slice spiral CT scanner, which can capture comparative and volumetric data, and the expertise of Timothy Street, lead CT technologist.

And that's how Neandertals ended up in the CT scanner at Mallinckrodt Institute and the Smithsonian Institution was able to expand their important collection documenting links to man's evolution. **MIR**

# Over the years

Over the years, Mallinckrodt Institute of Radiology's (MIR's) reputation for innovative research and radiology expertise has brought many archaeological discoveries to its doors, figuratively and literally.

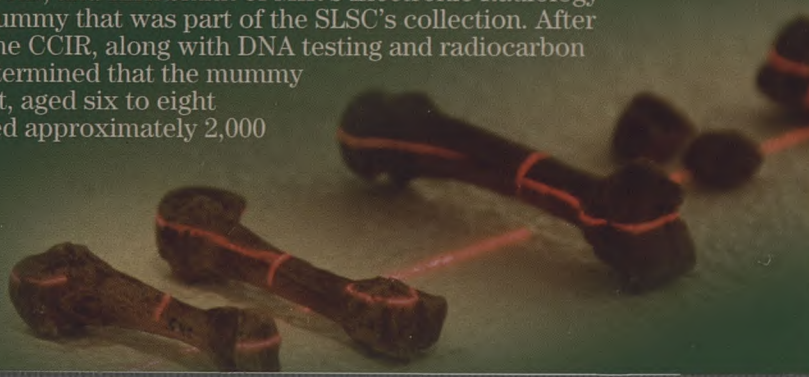
**In 1988**, Glen Conroy, PhD, professor of anthropology at Washington University, and Michael Vannier, MD, then director of MIR's Image Processing Lab, traveled to South Africa on a grant from the Leakey Foundation to collect CT data from the Taung Child, a 2.5 million-year-old specimen discovered in the lime pits of South Africa's Taung quarry.

**In 1993**, William Murphy, MD, then cochief of MIR's musculoskeletal section and a noted forensic radiologist, traveled to Innsbruck, Austria, to examine CT scans taken of the 53 centuries-old Iceman uncovered in the snow in the Tyrolean Alps in 1991. Later, the electronic raw data from the CT scans would be air-expressed to MIR so a 3-D imaging team could study the morphology of the tissue.

**In 2002**, a human jawbone with teeth was found in a bear cave in Romania. Romanian cave biologist Oana Moldovan sent the specimen to Erik Trinkaus, PhD, professor of anthropology, who along with Charles Hildebolt, DDS, PhD, professor of radiology and adjunct professor of anthropology, and Bruce Whiting, PhD, research assistant professor of radiology, coordinated the 36,000 year-old specimen's CT scanning in MIR's Center for Clinical Imaging Research (CCIR). The discovery provided evidence of modern humans in Europe much earlier than was previously documented.

**In 2004**, endocasts of the skull of an ancient hominin (called "LB1" or "Hobbit") found on the Indonesian island of Flores, came to MIR. Researchers Charles Hildebolt, DDS, PhD; Kirk Smith, senior research engineer in MIR's Electronic Radiology Lab; and Dean Falk, PhD, professor of anthropology at Florida State University, used CT images taken in the CCIR to compare the Hobbit skull to endocasts of a pygmy, a chimpanzee, a contemporary human, and a microcephalic human.

**In 2006**, in collaboration with the Saint Louis Science Center (SLSC), a team of international researchers, including Charles Hildebolt, DDS, PhD, and Kirk Smith of MIR's Electronic Radiology Lab, studied a mummy that was part of the SLSC's collection. After CT scanning in the CCIR, along with DNA testing and radiocarbon dating, it was determined that the mummy was a male infant, aged six to eight months, who lived approximately 2,000 years ago.






LET THERE BE

# LIGHT

OPTICAL IMAGING

*Use of optical imaging as an important complement in medicine*

by Amy Thomas, MD, FAAP



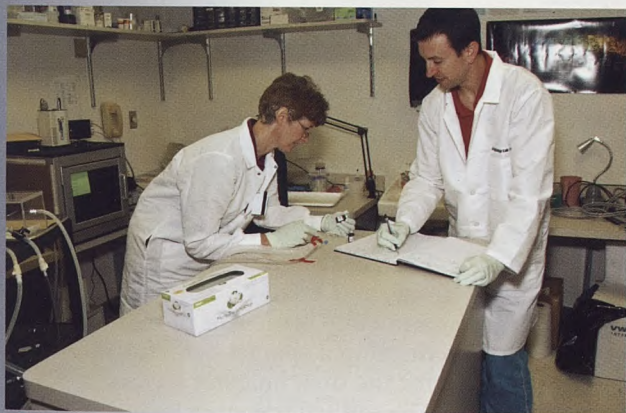
*Graphic interpretation  
of a caspase-3 enzyme.*

The diagnostic technique of optical imaging goes back centuries, to the earliest days of medicine, when the sun served as a light source that allowed physicians to detect disease with just their own eyes. But despite its long history and evolution into a sophisticated modality, optical imaging has lagged behind more popular imaging methods due to the limited number of human studies and FDA-approved optical molecular probes. While MRI (magnetic resonance imaging), CT (computed tomography)—and among the more medically savvy, PET (positron emission tomography)—have become household names, optical imaging, often referred to as DOT (diffuse optical tomography), remains largely unknown outside the medical


community. Researchers at Mallinckrodt Institute are hoping to change this.

Optical imaging, which sends light waves through the body to detect tissue abnormalities, is a relatively low-cost, noninvasive imaging modality with limited adverse effects for the patient. Light passes easily through bodily structures and is well tolerated in large doses. Imaging of this kind is highly sensitive and affords unrivaled resolution.

“Optical imaging in its current form is a new modality that’s not well known in most radiology groups,” says Samuel Achilefu, PhD, chief of Mallinckrodt Institute’s Optical Radiology Lab. This is unfortunate, according to Achilefu and other advocates for the increased use of optical imaging in medicine. Achilefu says of his preferred modality, “We’re like orphans looking for partners to help us grow.”



Above: Gail Sudlow, research technician, and Walter Akers, PhD, instructor in radiology, in the Optical Imaging Application Lab



Left: Postdoctoral Research Associate Adam Bauer with part of the DOT system used for fluorescent imaging of tumors in preclinical models without the use of radiation



Samuel Achilefu, PhD, in the Molecular Optical Biology Lab

By “partners,” Achilefu means areas of medicine for which optical imaging can serve as a useful complement. Nuclear imaging is proving to be one of those areas. Achilefu and his team are actively researching the benefits of multimodal imaging that combines optical imaging with nuclear imaging methods, such as PET, and they are optimistic.

“By integrating the two modalities, we can gather additional information simultaneously,” explains Achilefu. “PET scans provide easy, quick imaging of the whole body, which is good for finding tumors, while optical imaging can report molecular events relevant to the disease, such as how—and if—a tumor is responding to treatment at early stages.” Achilefu and his colleagues recently received funding from the National Institutes of Health (NIH) for this work.

## MULTIMODAL IMAGING

Despite technological advances that have rendered imaging an invaluable diagnostic and treatment tool, to date there is no single modality that tells the whole story. Each imaging method contributes

# LET THERE BE LIGHT

a different piece of the puzzle: MR and CT provide anatomic detail with high spatial resolution; nuclear imaging and optical imaging provide information about disease activity at the cellular and molecular levels.

The concept of combining two imaging techniques in one machine, allowing physicians to diagnose and customize treatment based on a single scan, is not new. The best-known example of multimodal imaging is PET/CT fusion, which combines the detection of metabolic activity in the body by PET scanning with anatomic information obtained by CT in order to locate disease activity. Physicians are able to ensure that the molecular information gathered through PET scanning corresponds directly to the anatomic structure identified on the CT scan. Mallinckrodt Institute researchers are showing that a less commonly used approach to multimodal imaging—combining two molecular methods, such as optical imaging and nuclear imaging—may be even more accurate and effective.

By taking advantage of current techniques in PET scanning, Achilefu's lab uses a common imaging agent that generates signals detectable by both optical imaging and by PET. Known as a MOMIA (monomolecular multi-

modality imaging agent), the contrast agent is a fused molecule that contains the signaling properties for both optical imaging and nuclear imaging. The signals detected are coming from the same source but provide different, complementary information about the location and activity of disease. "Once we know where the tumor is, which can be determined with PET/CT scanning, we can use optical imaging to determine what else is happening at the molecular level," says Achilefu.

## DUAL RESPONSE

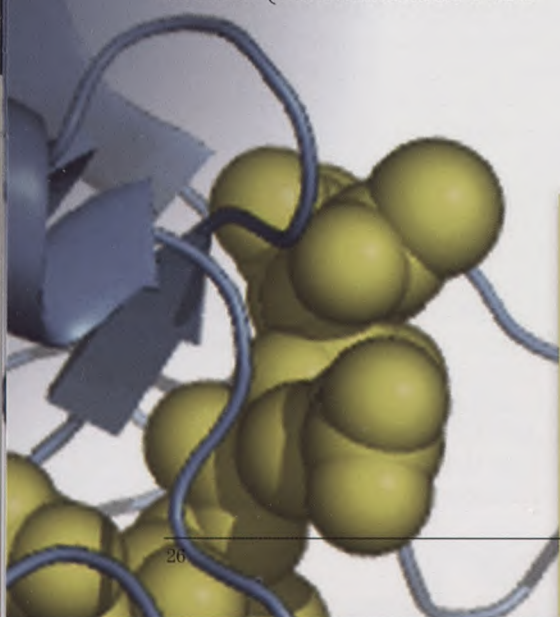A combination PET/optical scan performed with a dual-function contrast agent gives physicians a highly sensitive and specific view of tumor location and activity. Patients are injected with an imaging agent that "speaks the language" of both modalities: The agent concentrates in tumors and emits radioactive signals to be detected by PET. The agent also contains a molecule that will emit fluorescent light in the presence of dying tissue, and these emissions are detected by an optical scan.

The fluorescent emissions are generated by caspase-3, an enzyme up-regulated in human tissue undergoing apoptosis (cell death). The enzyme is activated at the early stages of cell death and triggers the cell's autodestruct system when the cell has undergone irreversible damage, as in the case of tumor cells exposed to chemotherapy or radiation. "We're still quantifying this process through research, but we believe that tumor

cells responding to treatment have several fold excess caspase-three activity as compared with normal tissue," says Achilefu. "Doctor David Piwnica-Worms [*chief of Mallinckrodt Institute's Molecular Imaging Center*] has previously demonstrated the potential use of caspase-three as a reporter of early cell death."

The caspase-3 enzyme recognizes and cleaves (or cuts) a specific peptide sequence that is present on the fluorescent probe contained within the MOMIA. Cleaving of MOMIA by caspase-3 activates the fluorescent probe, resulting in the spontaneous emission of light. Achilefu is collaborating with Joseph Culver, PhD, assistant professor of radiology, and Yuan-Chuan Tai, PhD, associate professor of radiology, to develop a special detection scheme for the dual imaging methods. The optical imaging device will be mounted to current PET/CT scanners for localizing tumors and detecting the light emission taking place in the presence of dying tissue.

"This gives us a measurement other than size to determine tumor response to treatment," says Achilefu. "Currently, MRI and CT are used to provide a baseline of the tumor size and is repeated after several weeks or months to see whether the tumor is getting



Left: Staff scientists Duanwen Shen, PhD, and Sharon Bloch, PhD, in the Microscopy Lab, which houses the nation's first confocal microscope

Below: Adam Bauer, PhD, and Metasebya Solomon, graduate student, with a laser diode prototype used in an infant brain imaging study funded by the NIH



smaller; tumor size is a key parameter to assess treatment response. Thus, by incorporating optical imaging into the repertoire of patient care, we can provide faster measurement of how treatment is progressing." When a tumor is not responding to a chosen therapy, physicians can move forward with other treatments that may be effective, without waiting months to decide the next steps.

Optical imaging is considered a highly sensitive method of detecting disease activity and "can detect change as small as a single molecule," says Achilefu. "Nuclear imaging is also very sensitive, looking at changes at

the nanomolar or picomolar level." In comparison, standard MR and CT looks at changes on a millimolar scale—in other words, optical imaging and nuclear imaging are looking at events one million to one billion times smaller than what MR and CT can see.

### NEXT STEPS

Achilefu's lab is currently conducting studies to optimize the performance of MOMIAs in localizing tumors and their ability to identify responding tumors at early stages of treatment. Their goal is to stratify patents. Toxicology studies are also in progress to determine whether its MOMIA is safe. Parallel work by Culver and Tai to develop a dual PET-optical imaging scanner will accelerate the translation of this technology from small animals to humans.

On another front, the optical radiology team, in collaboration with their NIH colleagues, is looking closely at the breakdown of copper, an isotope already used widely in PET imaging. Copper is known to decay into zinc and nickel, and now Mallinckrodt Institute researchers have found that zinc enhances fluorescent emissions. The team believes that optical imaging of these fluorescent emissions could complement the use of copper in PET scanning by extending the ability to detect a tumor after the initial images are obtained. For example, a patient undergoes a PET scan to locate a tumor; optical images following the initial tumor localization can detect continued activity in the tumor. This could possibly be used in real time to help confirm the tumor location for a biopsy.

"Through optical imaging, copper transformation may potentially improve biopsies by detecting the complementary fluorescence signal

long after the radioactivity has decayed," says Achilefu. "And this could be another paradigm shift in imaging, where subsequent tissue analysis by in vivo fluorescence imaging precludes the need to control radioactive emissions."

With its high sensitivity and unrivaled resolution, optical imaging may be the key to providing the comprehensive molecular imaging not available to date. By investigating the endless potential of this noninvasive modality, Achilefu and his team hope to advance the current practice of medicine from many angles. **MIR**

## OPTICAL RADIOLOGY

Lab faculty and senior staff

- SAMUEL ACHILEFU, PhD
- WALTER AKERS, PhD
- MIKHAIL BEREZIN, PhD
- SHARON BLOCH, PhD
- JOSEPH CULVER, PhD
- BARRY EDWARDS, PhD
- HYERAN LEE, PhD
- DUANWEN SHEN, PhD
- MAI XU, MD, PhD
- YUNPENG YE, PhD
- ZONGREN ZHANG, PhD

# CANCER RESEARCH IMAGING CAMP 2009

AN EDUCATIONAL  
OPPORTUNITY FOR BASIC  
CANCER RESEARCHERS

BY VICKI KUNKLER

*Additional funding for Cancer Research Imaging Camp 2009 was received from the Alvin J. Siteman Cancer Center at Barnes-Jewish Hospital and Washington University School of Medicine.*

Photography by MIR Photography Lab



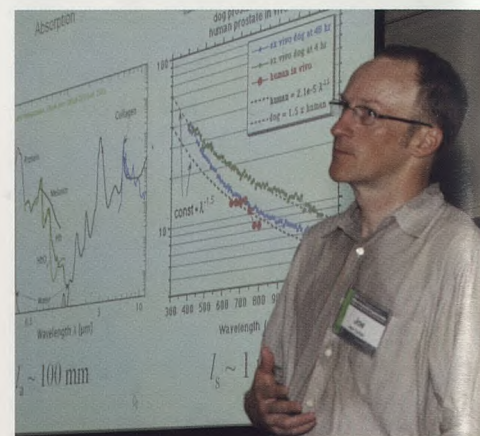
(second from left) William Spees, PhD, Division of Radiological Sciences, demonstrated the small-bore magnetic resonance scanner.

**In June**, the National Cancer Institute, in partnership with the American Association for Cancer Research, sponsored the annual Cancer Research Imaging Camp—a special intensive course on *in vivo* and live cell-imaging techniques. Twenty post-doctoral fellows and early career-level faculty involved in fields related to basic cancer biology attended the one-week program of seminars at the Knight Executive Center on Washington University's Danforth Campus. Hands-on lab sessions focusing on optical imaging, magnetic resonance, ultrasound, X ray/computed tomography, and positron emission tomography were held at Mallinckrodt Institute's East Building.

## IMAGING CAMP FACULTY

### WASHINGTON UNIVERSITY/ MALLINCKRODT INSTITUTE

- Samuel Achilefu, PhD
- Joseph Ackerman, PhD
- John Engelbach
- Joel Garbow, PhD
- Richard Laforest, PhD




Joseph Culver, PhD, Optical Radiology Lab

### OTHER INSTITUTIONS

- Cristian Badea, PhD, Duke University
- Robert Gilles, PhD, Moffitt Cancer Center
- Kenneth Krohn, PhD, University of Washington
- Anne Menkens, PhD, National Cancer Institute
- Dean Sherry, PhD, University of Texas, Dallas
- Bonnie Sloane, PhD, Wayne State University
- Simon Watkins, PhD, University of Pittsburgh

Attila Ntziachristos, A. G. Yodh, Mitchell Schnall,  
and Britton Chance  
PNAS March 14, 2000 vol. 97 2767-2772.  
Indocyanine green administered to humans at  
0.25mg/kg which is 0.32  $\mu$ Mole/kg.



Michael Welch, PhD, Division of Radiological Sciences

**SEMINARS/LABS**

**Samuel Achilefu, PhD**, "Biological applications of optical imaging and optical probes"

**Cristian Badea, PhD**, "Fundamentals of computed tomography"

**Joseph Culver, PhD**, "Image processing and data analysis—optical"

**John Engelbach**, "Animal handling and anesthesia, radiation safety"

**Kathy Ferrara, PhD**, "Fundamentals of ultrasound physics and imaging"; "Biological applications of ultrasound"

**Joel Garbow, PhD**, "Fundamentals of magnetic resonance and MRI"

**Robert Gilles, PhD**, "Biomarkers and radiomics"

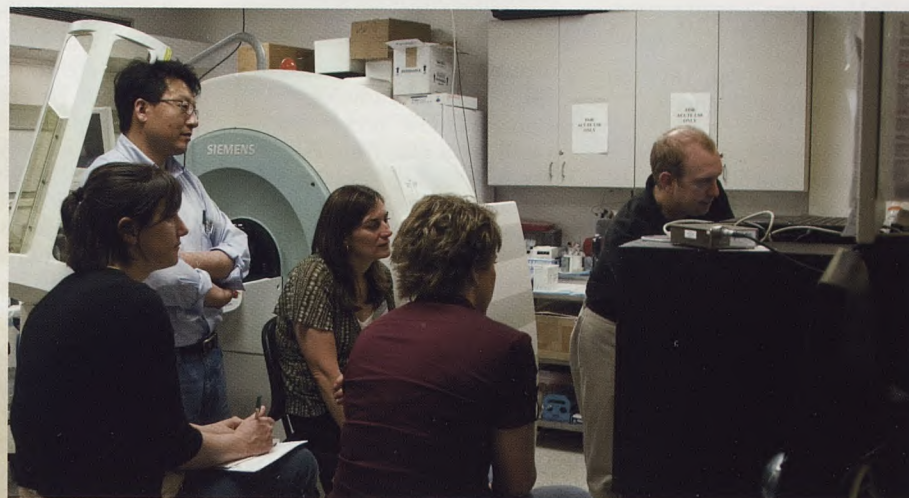
**John Gore, PhD**, "Multimodal imaging"

**Richard Laforest, PhD**, "Fundamentals of SPECT and PET"



Top, Right: (far left) Attila Kovacs, MD, Washington University's Department of Internal Medicine, discussed ultrasound technology.

Above: (far right) Richard Laforest, PhD, Radiological Chemistry Lab, in the positron emission tomography research facility



**Robert Mach, PhD**, "SPECT/PET imaging and probes"

**Sabrina Ronen, PhD**, "MR spectroscopy"

**Dean Sherry, PhD**, "MR imaging agents"

**Kooreh Shoghi, PhD**, "Image processing and data analysis—PET/SPECT"

**William Spees, PhD**, "Image processing and data analysis—MR"

**Charles Springer, PhD**, "Biological applications of MR"

**Lihong Wang, PhD**, "Photoacoustic tomography"

**Simon Watkins, PhD**, "Fundamentals of optical imaging and optical probes"

**Michael Welch, PhD**, "Molecular imaging, translating to humans" **NIH**



*In this section, the names of employees who are full-time faculty or staff or who have an appointment in the Department of Radiology are highlighted in boldface type.*

## NEW FACULTY

**Jennifer Demertzis, MD**, instructor in radiology, Musculoskeletal Radiology, Division of Diagnostic Radiology.

**Punita Gupta, MD**, instructor in radiology, Division of Diagnostic Radiology, Barnes-Jewish St. Peters Hospital.

**Joong Hee Kim, PhD**, instructor in radiology, Biomedical Imaging Lab, Division of Radiological Sciences.

**Yi Su, PhD**, instructor in radiology, Neuroimaging Lab, Division of Radiological Sciences.

## FIRST-YEAR FELLOWS

**Abdulnasser Alhajeri, MD, PhD**, endovascular neurosurgical clinical fellow, received an undergraduate degree, a doctoral degree, and a medical degree from the College of Medicine and Medical Sciences, Arabian Gulf University. He completed an internship and radiology training at Salmania Medical Complex; additional training at University College Hospital and at St. Vincent University Hospital, Ireland; a diagnostic neuroradiology fellowship at University of Texas Southwestern Medical Center; and a pediatric neuroradiology fellowship at Children's Hospital-Dallas.

**Jonathan Baker, MD**, musculoskeletal radiology clinical fellow, received an undergraduate degree from Saint Louis University, Missouri, and a medical degree from Washington University in St. Louis. He completed additional training at Forest Park Hospital, Missouri, and a diagnostic radiology residency (chief, resident, 2008-2009) at Mallinckrodt Institute.

**Udaykamal Barad, MBBS**, interventional radiology clinical fellow, received a medical degree from BJ Medical College-Gujarat University. He completed an internship at Gujarat University Hospital and a residency at BJ Medical College, India.

**Chris Baughman, MD**, abdominal imaging clinical fellow, received an undergraduate degree and a medical degree from Vanderbilt University, Tennessee. He completed an internship and a residency at Case Western Reserve University/Metro-Health System, Ohio.

**Kitty Cain, MD**, cardiothoracic imaging clinical fellow, received an undergraduate degree from the University of California, Berkeley, and a medical degree from Temple University, Pennsylvania. She completed an internship at Drexel University Hospital, Pennsylvania, and a residency at Western Pennsylvania Hospital.

**Seth Cardall, MD**, magnetic resonance imaging clinical fellow, received an undergraduate degree from Brigham Young University, Utah, and a medical degree from the University of California, Los Angeles. He completed additional training at Mayo Clinic, Arizona, and a diagnostic radiology residency at Mallinckrodt Institute.

**Benjamin Dahl, MD**, diagnostic neuroradiology clinical fellow, received an undergraduate degree from St. John's University, Minnesota, and a medical degree from Creighton University, Nebraska. He completed an internship and a residency at Saint Louis University, Missouri.

**Josser Delgado, MD**, diagnostic neuroradiology clinical fellow, received an undergraduate degree from Wesleyan University and a medical degree from Mount Sinai School of Medicine. He completed an internship at Cabrini Medical Center/Mount Sinai School of Medicine, New York, and an internship at Massachusetts General Hospital, Boston.

**Michael Farber, MD**, abdominal imaging clinical fellow, received an undergraduate degree and a medical degree from the University of Missouri, Columbia. He completed additional training at Hennepin County Medical Center, Minnesota, and a residency at the University of Minnesota.

**Elizabeth Herf, MD**, breast imaging clinical fellow, received an undergraduate degree from Bucknell University, Pennsylvania, and a medical degree from Saint Louis University, Missouri. She completed an internship at St. Joseph's Hospital/Marshfield Clinic, Wisconsin, and a residency at Saint Louis University Hospital, Missouri.

**Travis Hillen, MD**, musculoskeletal radiology clinical fellow, received an undergraduate degree from Blackburn University, Illinois, and a medical degree from the University of Missouri, Columbia. He completed additional training at University Hospitals, Missouri, and a diagnostic radiology residency (chief resident, 2008-2009) at Mallinckrodt Institute.

**Susan Holley, MD, PhD**, breast imaging clinical fellow, received an undergraduate degree from Yale University, Connecticut, and a medical degree and a doctoral degree from Duke University, North Carolina. She completed additional training at Barnes-Jewish Hospital, Missouri, and a diagnostic radiology residency at Mallinckrodt Institute.

**Douglas Hughes, MD**, cardiothoracic imaging clinical fellow, received undergraduate degrees and an MBA from Texas Southern University and a medical degree from Howard University, Washington, DC. He completed an internship at the University of Texas, Houston, and a residency at the University of Texas Medical Branch.

**Edward Hwang, MD, MBA**, diagnostic neuroradiology clinical fellow, received an undergraduate degree and a medical degree from Georgetown University, Washington, DC. He completed additional training at St. Vincent Hospital, New York, and a diagnostic radiology residency at Mallinckrodt Institute.

**Bharathidasan Jagadeesan, MBBS**, diagnostic neuroradiology clinical fellow, received a medical degree from Madras Medical College, India. He completed a residency at All India Institute of Medical Sciences, and additional training and a residency at Hennepin County Medical Center/University of Minnesota.

**Alok Jaju, MBBS**, received a medical degree from Government Medical College and Hospital, India. He completed an internship at Government Medical College and Hospital and a radiology residency at Lokmanya Tilak Municipal Medical College and General Hospital, India.

**Shalin Jhaveri, MD**, abdominal imaging clinical fellow, received an undergraduate degree from Case Western Reserve University, Ohio, and a medical degree from Temple University, Pennsylvania. He completed additional training at Mercy Hospital of Pittsburgh and a residency at Western Pennsylvania Hospital.

**Eric Johnson, MD**, diagnostic neuroradiology clinical fellow, received an undergraduate degree from Rhodes College and a medical degree from the University of Tennessee. He completed an internship and a residency at University of Tennessee/Methodist Healthcare.

**Kartikeya Kantawala, MD**, pediatric radiology clinical fellow, received an undergraduate degree from Mithibai College and a medical degree from Lokmanya Tilak Municipal Medical College, India. He completed an internship and a residency at Lokmanya Tilak Municipal General Hospital, India. He completed one year of nuclear medicine training and an abdominal imaging fellowship at Mallinckrodt Institute.

**Marcus Kessler, MD**, pediatric radiology clinical fellow, completed premedical studies at and received a medical degree from the University of Cologne, Germany. He completed an internship at the Clinics of the City of Cologne, Germany; a diagnostic radiology residency at Hospital Holweide, Germany; a pediatric radiology residency at Pediatric Hospital Amsterdamer Strasse, Germany; and a nuclear medicine residency (chief resident, 2008-2009) at Mallinckrodt Institute.

**David Loy, MD, PhD**, endovascular neurosurgical clinical fellow, received an undergraduate degree, a medical degree, and a doctoral degree from the University of Louisville, Kentucky. He completed a surgical internship at the University of Louisville, and four years of diagnostic radiology training and a diagnostic neuroradiology fellowship at Mallinckrodt Institute.

**Abouelmagd Makramalla, MBBCh**, interventional radiology clinical fellow, received a medical degree from Faculty of Medicine, Cairo University, Egypt. He completed an internship at Cairo University and a radiology residency at National Cancer Institute, Cairo University.

**Prakash Masand, MBBS**, magnetic resonance imaging clinical fellow, received an undergraduate degree from Jaihind College, and a medical degree from Topiwala National Medical College, India. He completed an internship and a residency at Nair Hospital, India; a pediatric radiology clinical fellowship, a cardiothoracic imaging clinical fellowship, and a diagnostic neuroradiology clinical fellowship at Mallinckrodt Institute.

**Kelsey Moran, MD**, diagnostic neuroradiology clinical fellow, received an undergraduate degree from the University of Nebraska and a medical degree from Washington University in St. Louis. He completed additional training at St. John's Mercy Medical Center, Missouri, and a diagnostic radiology residency at Mallinckrodt Institute.

**Daniel Nissman, MD, MPH**, musculoskeletal radiology clinical fellow, received an undergraduate degree from Carnegie Mellon University, Pennsylvania; a master's degree from North Carolina State University; a Master in Public Health degree from the University of North Carolina School of Public Health; and a medical degree from the University of North Carolina. He completed an internship at University of North Carolina Hospitals and a residency at the Medical University of South Carolina.

**Rosana Ponisio, MD**, diagnostic neuroradiology clinical fellow, received a medical degree from the National University of La Plata, Argentina, and completed additional training at the University Institute of Biomedical Sciences, Argentina.

**Constantine Raptis, MD**, magnetic resonance imaging clinical fellow, received an undergraduate degree from the University of Chicago, Illinois, and a medical degree from the University of Pennsylvania. He completed additional training at Barnes-Jewish Hospital, Missouri, and a diagnostic radiology residency at Mallinckrodt Institute.

**Perry Grigsby, MD, MBA**, professor of radiation oncology and of radiology, as a four-time recipient, was selected by the Association of Residents in Radiation Oncology as 2008-2009 Teacher of the Year, in recognition of his excellence in teaching and support of residency training. Grigsby also received the 2009 Distinguished Alumni Award from the University of Kentucky.

## FIRST-YEAR FELLOWS

*Continued from page 31*

**Brandon Repko, MD**, interventional radiology clinical fellow, received an undergraduate degree from Indiana University and a medical degree from Jefferson Medical College, Thomas Jefferson University, Pennsylvania. He completed additional training at Mercy Hospital of Pennsylvania and a residency at Pennsylvania State University-Hershey Medical Center.

**Alexander Sevrakov, MD**, abdominal imaging clinical fellow, received a medical degree from I.M. Sechenov Moscow Medical Academy, Russia. He completed additional training at the University of Illinois and a diagnostic radiology residency at Mallinckrodt Institute.

**Wendy Silcox, MD**, breast imaging clinical fellow, received an undergraduate degree from the University of Illinois at Chicago and a medical degree from the University of Illinois, College of Medicine. She completed an internship and a residency at Aurora St. Luke's Medical Center.

**Anand Singh, MD**, musculoskeletal radiology clinical fellow, received an undergraduate degree from Duke University, North Carolina, and a medical degree from the University of Alabama, Birmingham. He completed an internship at Santa Clara Valley Medical Center, California, and a diagnostic radiology residency at Mallinckrodt Institute.

**Adam Smith, MD**, diagnostic neuroradiology clinical fellow, received an undergraduate degree and a medical degree from the University of Tennessee. He completed an internship at the University of Tennessee, Memphis, and a residency at Saint Louis University, Missouri.

**Sushilkumar Sonavane, MBBS**, abdominal imaging clinical fellow, received an undergraduate degree and a medical degree from Seth Gordhandas Sunderdas Medical College, India. He completed additional training at King Edward Memorial Hospital, India, and residencies at Sri HBM General Hospital, at Dr. RNCM General Hospital, and at LTMMC & LTM General Hospitals, India. He completed a pediatric radiology fellowship at Mallinckrodt Institute.

**Jason Stephenson, MD**, musculoskeletal radiology clinical fellow, received an undergraduate degree from Stanford University, California, and a medical degree from Washington University in St. Louis. He completed additional training at St. John's Mercy Medical Center, Missouri, and a diagnostic radiology residency (chief resident, 2008-2009) at Mallinckrodt Institute.

**Angela Tai, MD**, abdominal imaging clinical fellow, received an undergraduate degree from McGill University, Canada, and a medical degree from Mount Sinai School of Medicine, University of New York. She completed an internship at Cabrini Medical Center/Mount Sinai School of Medicine and a residency at Brigham and Women's Hospital/Harvard University, Massachusetts.

**Heather Tauschek, MD**, breast imaging clinical fellow, received an undergraduate degree from Seattle Pacific University, Washington, and a medical degree from Cornell University, New York. She completed additional training at the University of Hawaii and a diagnostic radiology residency at Mallinckrodt Institute.

**Livnat Uliel, MD**, interventional radiology clinical fellow, received an undergraduate degree and a medical degree from Technion Israel Institute of Technology. She completed an internship and a residency at The Chaim Sheba Medical Center, Israel.

**Rakesh Varma, MBBS**, interventional radiology clinical fellow, received an undergraduate degree from DG Ruparel College, and a medical degree from Seth Gordhandas Sunderdas Medical College/King Edward Memorial Hospital, India. He completed additional training at Seth Gordhandas Sunderdas Medical College/King Edward Memorial Hospital and at LTMMC & LTM General Hospital, India.

**Thomas Watson, MD**, diagnostic neuroradiology clinical fellow, received an undergraduate degree and a medical degree from the University of Missouri, Columbia. He completed additional training at the University of Missouri, Columbia, and a diagnostic radiology residency at Mallinckrodt Institute.

**Catherine Young, MD, JD**, breast imaging clinical fellow, received an undergraduate degree and a law degree from the University of Texas, Austin, and a medical degree from Tulane University, Louisiana. She completed additional training at Tulane University and a diagnostic radiology residency at Mallinckrodt Institute.

**Vincent Zata, MD**, cardiothoracic imaging clinical fellow, received an undergraduate degree and a medical degree from Saint Louis University, Missouri. He completed an internship at Forest Park Hospital, Missouri, and a residency at Saint Louis University Hospital, Missouri.

## FIRST-YEAR DIAGNOSTIC RADIOLOGY RESIDENTS

**Adam Belanger, MD,** received an undergraduate degree from Boston University and a medical degree from Mount Sinai School of Medicine of New York University. He completed an internship at Mount Sinai Hospital.

**Manu Goyal, MD,** received an undergraduate degree from the University of Illinois at Chicago; a master's degree from University of Oxford, United Kingdom; and a medical degree from Pritzker School of Medicine, University of Chicago. He completed an internship and a neurology residency at Barnes-Jewish Hospital, St. Louis, Missouri.

**James Head, MD,** received an undergraduate degree and a medical degree from Duke University, North Carolina. He completed an internship at Moses H. Cone Memorial Hospital, North Carolina.

**Robert Honey, MD,** received an undergraduate degree from Texas Christian University and a medical degree from University of Texas, Houston. He completed additional training at Colorado Health Foundation.

**Jane Karimova, MD,** received a medical degree from Kazan State Medical University, Russia. She completed an internship at the University of Tennessee, College of Medicine.

**Chad Lonsford, MD,** received an undergraduate degree from Texas A&M University and a medical degree from the University of Texas, Houston. He completed additional training at MacNeal Memorial Hospital, Illinois.

**Ignacio Lopez-Costa, MD** received a medical degree from Pontificia Universidad Catolica de Chile, Santiago. He completed an internship at Metropolitan Hospital Center, New York.

**Jeffrey Maxwell, MD,** received an undergraduate degree from North Carolina State University and a medical degree from Duke University, North Carolina. He completed additional training at LDS Hospital/Intermountain Medical Center, Utah.

**Kelby Napier, MD, PhD,** received an undergraduate degree from Eastern Kentucky University and a medical degree and doctoral degree from the University of Louisville, Kentucky. He completed an internship at the University of Louisville.

**Christopher Norbet, MD,** received an undergraduate degree from Davidson College, North Carolina, and a medical degree from the University of Miami, Florida. He completed additional training at John Peter Smith Hospital, Texas.

**James Duncan, MD, PhD,** associate professor of radiology and of surgery, was appointed as the first medical director of Vascular Access at St. Louis Children's Hospital, where he also serves as director of Pediatric Interventional Radiology. He will work closely with the Vascular Access skilled nursing staff to monitor quality and safety as well as to develop new approaches to vascular access.

**Robin Quazi, MD,** received an undergraduate degree from the University of California, Berkeley, and a medical degree from New York Medical College. He completed an internship at St. Luke's Roosevelt Hospital, New York.

**Patrick Rhoades, MD,** received an undergraduate degree from Illinois College and a medical degree from Southern Illinois University (SIU) School of Medicine. He completed an internship at SIU School of Medicine and Affiliated Hospital.

**Steven Sauk, MD,** received an undergraduate degree from Yale University, Connecticut, and a medical degree from the David Geffen School of Medicine, University of California, Los Angeles. He completed an internship at Olive View/UCLA Medical Center.

**Elizabeth Sheybani, MD,** received an undergraduate degree and a medical degree from Washington University in St. Louis. She completed additional training at St. John's Mercy Medical Center, Missouri.

**Ting Tao, MD, PhD,** received an undergraduate degree, a medical degree, and a doctoral degree from Washington University in St. Louis. She completed an internship at St. Louis Children's Hospital, Missouri.

**Colin Thompson, MD** received an undergraduate degree from Arizona State University and a medical degree from Saint Louis University, Missouri. He completed an internship at St. Mary's Health Center, Missouri.

**Michael Yu, MD,** received an undergraduate degree from Haverford College, Pennsylvania, and a medical degree from Albert Einstein College of Medicine, New York. He completed an internship at Long Island Jewish Medical Center, New York.

**Daniel Zurcher, MD,** received an undergraduate degree from Brigham Young University, Utah, and a medical degree from Washington University in St. Louis. He completed additional training at Santa Clara Valley Medical Center, California.

## FIRST-YEAR NUCLEAR MEDICINE RESIDENTS

**Tejaswini Deshmukh, MD**, received an undergraduate degree from Vivekananda College, and a medical degree from Seth Gordhanadas Sundradas Medical College and King Edward Memorial Hospital, India. She completed a radiology residency at Lokmanya Tilak Municipal General Hospital and King Edward Memorial Hospital, India.

**Andrew Homb, MD**, received an undergraduate degree and a master's degree from the University of Tulsa, Oklahoma, and a medical degree from Southern Illinois University School of Medicine. He completed an internship at Baylor College of Medicine, Texas, and a radiology residency at the University of Louisville, Kentucky.

**Jonathan McConathy, MD, PhD**, received an undergraduate degree from the University of North Carolina, Chapel Hill, and a medical degree and a doctoral degree from Emory University, Georgia. He completed additional training at Emory University, and a diagnostic radiology residency at Mallinckrodt Institute.

## GRANTS

**Samuel Achilefu, PhD**, professor of radiology and of biochemistry and molecular biophysics, and **Joseph Culver, PhD**, assistant professor of radiology, as principal investigators, received a \$1.9 million grant from the National Institutes of Health (NIH) for "Molecular probes and methods for fluorescence lifetime tomography and microscopy." Coinvestigators for the four-year grant are **Walter Akers, PhD**, instructor in radiology; **Mikhail Berezin, PhD**, instructor in radiology; and **Hyeran Lee, PhD**, instructor in radiology. As principal investigators, **Achilefu and Culver** received a \$760,000 NIH grant for "Multimodal DOT-PET molecular probes and tandem system." Coinvestigators for the two-year grant are **Yuan-Chuan Tai, PhD**, associate professor of radiology; **Barry Edwards, PhD**, assistant professor of radiology; and **Carolyn Anderson, PhD**, professor of radiology, of biochemistry and molecular biophysics, and of chemistry. **Achilefu** received a one-year NIH supplement of \$130,252 for "Near infrared Ph-sensitive molecular probes for microscopy of cells and tissues."

**Colin Derdeyn, MD**, professor of radiology and of neurology and neurological surgery, was elected to a one-year term as president of the Society of NeuroInterventional Surgery (SNIS). Formed in 1992, SNIS members include interventional neuroradiologists, interventional neurologists, and endovascular neurosurgeons. As the leader in neurointerventional surgery procedures and practice, SNIS promotes excellence in patient care, provides education, supports research, influences health care policy, and fosters the growth of the medical specialty.

Derdeyn also was appointed to one-year terms as a member of the Executive Committee of the American Society of Neuroradiology and a member of the Stroke Common Data Element Working group of the National Institute of Neurological Disorders and Stroke.

**Carolyn Anderson, PhD**, professor of radiology, of biochemistry and molecular biophysics, and of chemistry, as principal investigator, received a four-year grant of \$1.2 million from the National Institutes of Health for "Receptor-targeted copper radiopharmaceuticals for cancer imaging and therapy."

**Linda Larson-Prior, PhD**, research associate professor, received an \$80,000 grant from the James S. McDonnell Foundation for "Motor-learning and sleep: an ECoG study." **John Zempel, MD, PhD**, Department of Neurology, is coinvestigator for the two-year study.

**Lawrence Tarbox, PhD**, research assistant professor of radiology, received a one-year grant of \$45,000 from the National Institutes of Health/National Cancer Institute (NIH/NCI), via a subcontract with Siemens Corporate Research, Inc., for "ATV phase 2 development." He also received a \$55,919 grant from NIH/NCI, via a subcontract with SAIC (Science Applications International Corporation), for "XIP maintenance."

**Pamela Woodard, MD**, associate professor of radiology, received a \$120,000 grant from Astellas Pharma, Inc. to study "Feasibility of detecting myocardial ischemia by first-pass contrast MRI using regadenoson." Coinvestigators are **Robert Gropler, MD**, professor of radiology, of medicine, and of biomedical engineering; **Cylen Javidan-Nejad, MD**, associate professor of radiology; and **Ibrahim Saeed, MD**, Department of Internal Medicine.

**Jie Zheng, PhD**, assistant professor of radiology, as principal investigator, received a \$418,000 grant from the National Institutes of Health for "Methods for the quantification of myocardial oxygen consumption with 17O MRI." Coinvestigator for the two-year grant is **Dana Abendschein, PhD**, Department of Internal Medicine; collaborator, **Robert Gropler, MD**, professor of radiology, of medicine, and of biomedical engineering; and consultant **Wei Chen, PhD**, University of Minnesota.

## APPOINTMENTS/ ELECTIONS

**Bennett Greenspan, MD**, assistant professor of radiology, was elected to a one-year term as vice-president of the American Board of Science in Nuclear Medicine. He was named to one-year terms as a member of the Commission of Education and a member of the Government Affairs Committee.

**Marcus Kessler, MD**, pediatric radiology clinical fellow, was appointed to the Magnetic Resonance Committee of the Society of Pediatric Radiology.

**Linda Larson-Prior, PhD**, research associate professor, was elected to a five-year term as treasurer of the Academic Women's Network at Washington University School of Medicine.

**Robert McKinstry, MD, PhD**, associate professor of radiology, was appointed to a two-year term as a member of the Research Committee of the American Society of Pediatric Radiology.

**Bruce Whiting, PhD**, research assistant professor of radiology, was elected to a second term as president of the Optical Society of Greater St. Louis.

## LECTURES

**Samuel Achilefu, PhD**, professor of radiology and of biochemistry and molecular biophysics, as plenary speaker, presented "Lighting up tumors with optical molecular probes" at the University of Tokyo, Japan, May 15. He spoke on "Functional and molecular optical imaging of tumors" at the 57<sup>th</sup> Annual Meeting of the Association of University Radiologists, Arlington, Virginia, May 12. He spoke on "Flip-flopping contrast mechanisms in optical molecular imaging" at the 2009 Nano-Biophotonics Summer School, University of Illinois, Urbana, June 8. As session chair and invited speaker, Achilefu presented "Nanoparticles and nanomolecules in tumor imaging" at Engineering Conferences International, Advances in Optics for Biotechnology, Medicine and Surgery XI—Clinical Challenges and Research Solutions, Burlington, Vermont, June 28.

**Delphine Chen, MD**, assistant professor of radiology, spoke on "Evaluation of radio-labeled isatins for imaging apoptosis with positron emission tomography," at Memorial Sloan-Kettering Cancer Center, New York City, New York, May 11.

**Colin Derdeyn, MD**, professor of radiology and of neurology and neurological surgery, presented the plenary lecture "Stenting and Aggressive Medical Management for the Prevention of Recurrent Ischemic Stroke (SAMMPRIS) Trial rationale and update" at the annual meeting of the American Society of Neuroradiology, Vancouver, British Columbia, May 19. He spoke on "Patient selection for intracranial angioplasty" at the annual meeting of the World Federation of Interventional and Therapeutic Neuroradiology, Montreal, Quebec, July 2.

**Jay Heiken, MD**, professor of radiology, presented, as refresher course topics, "Western experience with hepatocellular carcinoma" and "Western experience with CT colonography" at the Asian Congress of Abdominal Radiology, Seoul, Republic of Korea, June 5 and 6. He spoke on "Anatomic landmarks in the peritoneum" and moderated the postgraduate course "Imaging beyond morphology: quantification methods" at the European Society of Gastrointestinal and Abdominal Radiology, Valencia, Spain, June 23-26.

**Geetika Khanna, MD**, spoke on "Evidence based approach to imaging of pediatric scoliosis" at the 52<sup>nd</sup> Annual Meeting and Postgraduate Course, Society of Pediatric Radiology, Carlsbad, California, April 21-25.

**Vamsi Narra, MD**, associate professor of radiology, presented "MRA of the abdominal aorta and renal arteries"; "MR of focal hepatic lesions"; "MR of the biliary tract"; "MR of solid renal lesions—recent advances, trends, and the role of biopsy"; and "New advances—MRI in oncology TIM with continuous moving table" at the 13<sup>th</sup> Annual Clinical Magnetic Resonance Society Meeting, Orlando, Florida, June 25-28. He spoke on "Emerging MR applications for the gastroenterologist" and participated in the panel discussion "Selected cases of interest to the interventional endoscopist: diagnostic and staging algorithms, determination of respectability, endoscopic palliation, and medical oncology" at the St. Louis Live Therapeutic Endoscopy Course, St. Louis, Missouri, July 17.

**Marilyn Siegel, MD**, professor of radiology and of pediatrics, presented "US neonatal head: hemorrhage & ischemia," "US neonatal head: congenital anomalies," "Pediatric mediastinal masses," "CT/MR pediatric renal masses," "CT/MR pediatric pelvic masses," "CTA thoracic vascular anomalies," and "CTA adult congenital heart disease" at the 39<sup>th</sup> Jornada Paulista de Radiologia (JPR' 2009), Sao Paulo, Brazil, April 1 and May 1. She spoke on "Ultrasound, CT imaging of liver fibrosis" at the Clinical Research Workshop: Cystic Fibrosis and the Liver, National Institutes of Health, Bethesda, Maryland, June 8 and 9. Siegel presented "Hepatic tumor CTA/MRA with path correlation," "Pediatric bone

## LECTURES

*Continued from page 35*

marrow," and "MDCT of congenital thoracic vascular anomalies" at the International Symposium on Pediatric Radiology and the Southeastern Radiology Meeting, sponsored by the Latin American Society of Pediatric Radiology and the Brazilian College of Radiology, Rio de Janeiro, Brazil, July 23-25. She spoke on "US and CT of the acute pediatric abdomen" and "CT of congenital lung lesions: peds to adults" at the 2009 Society of Computed Body Tomography & Magnetic Resonance Summer Practicum, Williamsburg, Virginia, August 9-13.

**Barry Siegel, MD**, professor of radiology and of medicine, spoke on "PET-CT in lung cancer and SPN," "PET-CT in breast cancer," and "PET-CT in colorectal cancer" at the International Symposium of PET-CT in Oncology, Rio de Janeiro, Brazil, July 25.

**Lawrence Tarbox, PhD**, research assistant professor of radiology, spoke on "Informatics infrastructure to support a research imaging center," "Introduction to ITK/VTK, from an XIP™ perspective," and "Building and hosting applications using XIP™ tools" at the Society for Imaging Informatics in Medicine 2009 Annual Meeting, Charlotte, North Carolina, June 4-7.

## SYMPOSIA

*In this section of FYI, only those faculty and staff who have Department of Radiology appointments are listed.*

## SOCIETY OF NUCLEAR MEDICINE

*56<sup>th</sup> Annual Meeting  
Toronto, Ontario  
June 14-18, 2009*

**Carolyn Anderson, PhD**, "Development of metal chelate-based radiopharmaceuticals for PET and SPECT"; "Imaging and biomedicine: What is MI?"; "What is molecular imaging? An overview."

**Delphine Chen, MD; Dong Zhou, PhD; Wenhua Chu, PhD; Phillip Herrbrich; Jacquelyn Engle; Lynne Jones; Justin Rothfuss; Michael Welch, PhD; Robert Mach, PhD**, "Comparison of radiolabeled isatin analogs for imaging caspase-3 activation with positron emission tomography."

**Joseph Culver, PhD**, "Molecular imaging modalities: optical."

**Riccardo Ferdani, PhD; Carolyn Anderson, PhD**, "Evaluation of <sup>64</sup>Cu-DOTA-KCCYSL and <sup>64</sup>Cu-CB-TE2A-KCCYSL peptides as PET imaging agents for ErbB-2 expressing breast carcinomas."

**Bennett Greenspan, MD**, "SPECT/CT in cardiac applications."

**Robert Gropler, MD**, "Beyond perfusion: molecular imaging markers of ischemic memory"; "The translational challenge: how to expand the clinical utilization of molecular imaging"; "Cardiac PET perfusion and function: nuts and bolts."

**Pilar Herrero, MS; Zhude Tu, PhD; Shihong Li, Terry Sharp; Carmen Dence, MS; Robert Mach, PhD; Robert Gropler, MD**, "Initial in-vivo assessment of a new F-18 fatty acid analog as a radiotracer of myocardial fatty acid metabolism."

**Pilar Herrero, MS; Robert Gropler, MD**, "The PPAR $\alpha$  activator fenofibrate fails to alter myocardial metabolism in healthy individuals despite marked peripheral effects."

**Pilar Herrero, MS; Robert Gropler, MD**, "Impact of gender on the myocardial metabolic response to diabetic therapy."

**Robert Mach, PhD**, "F-18 radiopharmaceuticals: tricks of the trade."

**Robert Mach, PhD; Zhude Tu, PhD; Jinbin Xu; Shihong Li; Aviv Hagooley; Lynne Jones**, "Comparison of the sigma-2 receptor radiotracer, [<sup>18</sup>F]ISO-1, with the thymidine analogs [<sup>18</sup>F]FLT and [<sup>18</sup>F]FMAU for imaging the proliferative status of solid tumors."

**Henry Royal, MD**, "Physician competency: the role of lifelong learning"; "Lymphatic drainage in the chest"; "Hospital preparedness: the management and treatment of radiation injuries"; "ABNM: practice performance assessment"; "Possible scenarios and consequences."

**Koresh Shoghi, PhD; Terry Sharp; Brian Finck; Pilar Herrero, MS; Robert Gropler, MD; Michael Welch, PhD**, "Differential efficacy of metformin and rosiglitazone monotherapy on myocardial substrate metabolism."

**Zhude Tu, PhD; Shihong Li; Terry Sharp; Pilar Herrero, MS; Carmen Dence, MS; Robert Gropler, MD; Robert Mach, PhD**, "Radiosynthesis and initial evaluation of [<sup>18</sup>F]FAA as a PET tracer for studying myocardial fatty acid metabolism."

**Michael Welch, PhD**, "Radiopharmaceutical sciences"; "History of nuclear medicine in the Saint Louis/Missouri area."

**Alexander Zheleznyak; Thaddeus Wadas, PhD; Christopher Sherman, MS; Carolyn Anderson, PhD**, "<sup>64</sup>Cu-RGD and micro PET as an imaging biomarker for osteoclast number in mouse models of negative and positive osteoclast regulation."

**Delphine Chen, MD**, assistant professor of radiology received the 2009 Mark Tetalman Memorial Award, which is funded by the Society of Nuclear Medicine (SNM) Education and Research Fund. The award honors research accomplishments of a young investigator who is pursuing a career in molecular imaging/nuclear medicine.

# Fellows and Residents

2008/2009

# 08/09



(SEATED, LEFT TO RIGHT) Doctors Jonathan McConathy; Susan Holley; Collins Liu; Vincent Mellnick; Kathryn Fowler; Catherine Young; Motoyo Yano; Travis Hillen, diagnostic radiology chief resident; Jason Stephenson, diagnostic radiology chief resident; Jennifer Gould, diagnostic radiology residency program director; Gilbert Jost, director, Mallinckrodt Institute; Travis Henry, Matthew Gipson; James Kelly; Constantine Raptis; Cylen Javidan-Nejad, cardiothoracic imaging fellowship program director; Monika Prost; Catherine Glynn; Gretchen Smith; Joanna Fair.

(SECOND ROW) Doctors Heather Tauschek; Jakob Schutz; Cade McDowell; Truitt Balart; Seth Cardall; Edward Hwang; Yasha Kadkhodayan; Alex Hofling; Jonathan Sehy; Desi Dennis; Sushil Sonavane; Steve Repka; Norna Ludeman; Jessica Huang; Celine Buckley; Robert Stachecki; Jay Desai; Jessica Lee; Kristy Wolske; Victoria Chen; Clinton Jokerst; Sanjeev Bhalla, residency program assistant director; Caitlyn Lopez; Prakash Masand; Paul Frohnert; Jonathan Weiss; Jennifer Salcman; Patrick Cox; Sara Dyrstad; Alok Jaju; Kavita Gorantla; Sridi Peddi.

(THIRD ROW) Doctors Alan Lobo; Robert Cargile; Kelsey Moran; John Burkett; Benjamin Pettus; Rex Parker; Russell Allman; Thomas Watson; Joseph Ippolito; Mitchell Gulati; Yihua Zhou; Nicholas Rhodes; Douglas Kitchin; Alexander Ho; Monika Tataria; Amy Fowler; Jennifer Sharp; JoAnne Lacey, diagnostic radiology resident mentor; William Grande; Ferenc Czeyda-Pommersheim; Alexander Sevrukov.

Photograph by MIR Photography Lab



# FOCAL SPOT

MALLINCKRODT INSTITUTE OF RADIOLOGY AT WASHINGTON UNIVERSITY IN ST. LOUIS

Change Service Requested

**POSTMASTER,**  
send changes to  
*Focal Spot* editor  
Mallinckrodt Institute  
of Radiology at  
Washington University  
Campus Box 8131  
510 South Kingshighway Blvd.  
St. Louis, MO 63110  
(314) 362-2866

---

Editor and Writer  
Vicki Kunkler

---

Contributing Writers  
Mary Jo Blackwood, RN, MPH  
Robert Lowes  
Candace O'Connor  
Amy Thomas, MD

---

Photographers  
Eileen Cler  
Kimberly Kania  
Tim Parker  
Michelle Wynn

---

Design  
Purviance & Company  
Marketing Communications

---

Printing  
Columbine Printing Company

---

*Focal Spot* magazine is distributed three times annually.

---


[www.mir.wustl.edu](http://www.mir.wustl.edu)

© Mallinckrodt Institute of Radiology, 2009

Non-Profit Organization  
U.S. Postage PAID  
St. Louis, Missouri  
Permit No. 2535



 Washington  
University in St. Louis  
SCHOOL OF MEDICINE

 Mallinckrodt Institute  
of Radiology