

Winter 2008

Focal Spot, Winter 2007/2008

Follow this and additional works at: http://digitalcommons.wustl.edu/focal_spot_archives

Recommended Citation

Focal Spot, Winter 2007/2008, January 2008. Bernard Becker Medical Library Archives. Washington University School of Medicine.


This Book is brought to you for free and open access by the Focal Spot at Digital Commons@Becker. It has been accepted for inclusion in Focal Spot Archives by an authorized administrator of Digital Commons@Becker. For more information, please contact engeszer@wustl.edu.

WINTER 2007/2008

VOLUME 38, NUMBER 3

FOCAL SPOT

MALLINCKRODT INSTITUTE OF RADIOLOGY AT WASHINGTON UNIVERSITY



Lending Expertise in Unexpected Places

MIR AT THE **ZOO**

WASHINGTON UNIVERSITY MEDICAL LIBRARY




3 2201 20351 0090



AuntMinnie.com—a leading online resource for radiology professionals—annually presents The Minnie awards to recognize excellence in radiology. Mallinckrodt Institute received the 2007 Minnie for Best Radiologist Training Program. Shown with the award are the 2007-2008 diagnostic radiology chief residents (left to right) Jennifer Demertzis, MD; Sara Rohr, MD; and Meghan Lubner, MD.

CONTENTS


FOCAL SPOT
WINTER 2007/2008
VOLUME 38, NUMBER 3



12



23



18



18 Imaging Sciences Pathway

As imaging continues to play an important role in medicine and research, Washington University's initiative for undergraduate and graduate students offers cross-training among several disciplines.

23 Taking Radiology Services to the Next Level

MIR's expanded services at Barnes-Jewish West County Hospital provide referring physicians and their patients with the same high level of service available at Washington University Medical Center—and it's closer to home.

ON THE COVER Humboldt penguins, from South America's Pacific Coast, are among the many endangered species that are part of the Saint Louis Zoo's cooperative breeding programs with zoos around the world. Photograph by Gil Courson, lightspeedphotos.com; courtesy of the Saint Louis Zoo.

2.....SPOT NEWS



27.....FYI

3 RSNA—Connecting Radiology

Mallinckrodt Institute was front and center at the largest medical meeting in the world, as Gilbert Jost, MD, presided at the Radiological Society of North America's 93rd annual meeting in Chicago.

12 Lending Expertise in Unexpected Places

In a long-standing collaboration, MIR's radiologists use their knowledge of human conditions and diseases to help Saint Louis Zoo veterinarians diagnose and treat animals with similar problems.

Washington
University in St. Louis
SCHOOL OF MEDICINE

MIR Mallinckrodt Institute
of Radiology

Visit the MIR web site at
www.mir.wustl.edu

SPOT NEWS

BioMed 21 update

At its completion, the 700,000 square-foot BJC Institute of Health at Washington University will be the largest building on the Washington University School of Medicine (WUSM) campus. Situated in the southwest corner of Euclid Avenue and Children's Place, the Institute will serve as home base for Washington University's innovative research initiative—BioMed 21—that was launched in 2003. BioMed 21 creates a multidisciplinary research environment designed to accelerate scientific discovery into clinical care.

The Institute of Health, supported in part by a \$30 million gift from BJC HealthCare to WUSM, will house BioMed 21 laboratories and support facilities, WUSM's academic Department

of Pathology and Immunology and Department of Obstetrics and Gynecology, and five newly created Interdisciplinary Research Centers. The targeted move-in date is December 2009.

Artist's rendering of the BJC Institute of Health at Washington University



MIC receives additional funding

The National Cancer Institute has awarded a five-year, \$10 million grant to the Molecular Imaging Center (MIC) to fund a second cycle of research and for support of postdoctoral and graduate students. Research at the MIC, which is headed by David Piwnica-Worms, MD, PhD, professor of radiology and of molecular biology and pharmacology, includes tracing the spread of gene therapy for cancer as well as collaborative imaging efforts such as neuroscience, cardiovascular disease, and immunology.

Faculty elected to leadership positions

Jay Heiken, MD, professor of radiology and chief of the Institute's Abdominal Imaging section, was elected to a one-year term as president of the International Cancer Imaging Society. Established in 1998, the Society promotes education in oncological imaging and stimulates research in the study of human tumor behavior.

Robert McKinstry, MD, PhD, chief of Mallinckrodt Institute's Pediatric Radiology section and radiologist-in-chief at St. Louis Children's Hospital, was elected to a three-year term as member-at-large of the Washington University School of Medicine Faculty Practice Plan (FPP) Board of Directors. McKinstry, associate professor of radiology, was elected to the position


vacated by Daniel Picus, MD, professor of radiology and chief of the Institute's Division of Diagnostic Radiology, who completed two consecutive terms on the Board.

Bruce Whiting, PhD, research professor of radiology in the Institute's Electronic Radiology Laboratory, was elected to a one-year term as president of the Optical Society of Greater St. Louis. The Society, now in its twenty-fourth year, promotes education and communication of optical sciences and technology.

Monsees and Wippold receive faculty awards

In January, 18 Washington University School of Medicine faculty received the first Distinguished Faculty Awards for excellence in clinical care, community service, research, and teaching. The awards are cosponsored by the Dean's office, the Office of Faculty Affairs, Central Administration, and the Executive Committee of the Faculty Council.


Among the honorees were Barbara Monsees, MD, professor of radiology and of women's health and chief of the Institute's Breast Imaging section, who received the Clinical Fellow Mentoring Award, and Franz Wippold, MD, professor of radiology and chief of MIR's Neuroradiology section, who received a Distinguished Clinician Award.



Barbara Monsees, MD, and School of Medicine Dean Larry Shapiro, MD.



Left to right: Dean Larry Shapiro, MD; Franz Wippold, MD; Aaron Hamvas, MD; and Diana Gray, MD, associate dean for faculty affairs.



RSNA

Connecting Radiology

THE 93RD SCIENTIFIC ASSEMBLY AND ANNUAL MEETING
OF THE RADIOLOGICAL SOCIETY OF NORTH AMERICA

NOVEMBER 25-NOVEMBER 30, 2007
McCORMICK PLACE
CHICAGO, ILLINOIS



“This year’s theme, “Connecting Radiology,” embodies RSNA’s goal of putting professionals in touch with a nearly limitless wealth of information. ... In addition, “Connecting Radiology” acknowledges the challenges and opportunities we face as digitalization moves us into the future.”

—from the welcoming message by Gilbert Jost, MD, 2007 RSNA president



RSNA

It was a jam-packed week of activities—scientific, technological, and social—during the 93rd Scientific Assembly and Annual Meeting of the Radiological Society of North America (RSNA). As the 62,501 healthcare specialists arrived in Chicago, there was no doubt that RSNA retained its distinction as “the largest medical meeting in the world.” And at the helm of that meeting was Gilbert Jost, MD, director of Mallinckrodt Institute of Radiology (MIR) and the first MIR faculty member to head RSNA.

Photography by Mickey Wynn and Kimberly Kania, MIR Photography Laboratory.

MIR PRESENTATIONS AT RSNA 2007

CASE OF THE DAY

Travis Henry, MD; Kristopher Cummings, MD; Sanjeev Bhalla, MD; Cylen Javidan-Nejad, MD; Pamela Woodard, MD, “Cardiac.”

EDUCATION EXHIBITS AND SCIENTIFIC POSTERS

Rashid AL-Sukaiti, MD; Christine Menias, MD; Kathryn Robinson, MD; Christine Peterson, MD; Daniel Brown, MD; Jennifer Gould, MD, “Pancreatic non-functional islet cell tumor (NFICT) and its hepatic metastases: multidetector CT.”

Sanjeev Bhalla, MD; Kristopher Cummings, MD; Andrew Bierhals, MD, PhD; Christine Menias, MD; Fernando Gutierrez, MD; Alvaro Huete, MD, “What’s that? Reviewing the spectrum of congenital lung disease in the adult detected on MDCT.”

Sanjeev Bhalla, MD; Kristen Taunton; Aidan Callinan, MBBS; Savvas Nicolaou, MD, “Screening for blunt vascular neck injuries in major trauma.”

Wincha Chong, MD; Christine Menias, MD; Vamsidhar Narra, MD, “MRI of the acute abdomen: a pictorial review.”

David Cipolla, MD; Janice Lee, MD; Jesse Chusid, MD; Sanjeev Bhalla, MD; Deborah Reede, MD; Rakesh Shah, MD, “The mosaic pattern on high-resolution CT: radiographic findings and differential diagnosis.”—CUM LAUDE AWARD

Kristopher Cummings, MD; Cylen Javidan-Nejad, MD; Andrew Bierhals, MD, PhD; Fernando Gutierrez, MD; Sanjeev Bhalla, MD; Pamela Woodard, MD, “Patterns of delayed left ventricular myocardial contrast-enhancement in the differentiation of non-ischemic cardiomyopathies (NICM) in cardiac MRI.”—CERTIFICATE OF MERIT AWARD

Aaron Friedkin, MD; Khaled Elsayes, MD; Ronald Bude, MD; Christine Menias, MD; Joel Platt, MD, “Imaging of the placenta: a multimodality pictorial review with emphasis on new advances in cross-sectional imaging.”

RSNA 2007 MEETING FACTS

- 758 technical exhibits, occupying 535,300 square feet
- 122 first-time exhibitors
- 1,765 scientific papers in 16 subspecialties
- 257 refresher courses
- 1,498 education exhibits and 604 scientific posters
- Attendees: 16,347 physicians; 11,246 healthcare professionals; 2,079 technologists; 119 nurses
- More than 100,000 room nights at 70 downtown Chicago hotels

Amy Hara, MD; Paul Swartz, MD; Alvin Silva, MD; Christine Menias, MD, “Is that small bowel loop abnormal at CT? Avoiding the pitfalls, improving accuracy at CT evaluation of the small bowel.”

Abraham Jeon, MD; Jesse Chusid, MD; Sanjeev Bhalla, MD; Deborah Reede, MD; Arfa Khan, MD; Rakesh Shah, MD, “On the edge: a structured approach to the differential diagnosis of peripheral lung opacities.”

Janice Lee, MD; Abraham Jeon, MD; Jesse Chusid, MD; Sanjeev Bhalla, MD; Deborah Reede, MD; Rakesh Shah, MD, “A pictorial essay: pulmonary manifestations in acquired immune deficiency syndrome.”

Meghan Lubner, MD; Sara Rohr, MD; Jennifer Demertzis, MD; Jennifer Gould, MD; Christine Menias, MD; Sanjeev Bhalla, MD, “A model for satisfying the ACGME systems-based practice core competency in radiology.”

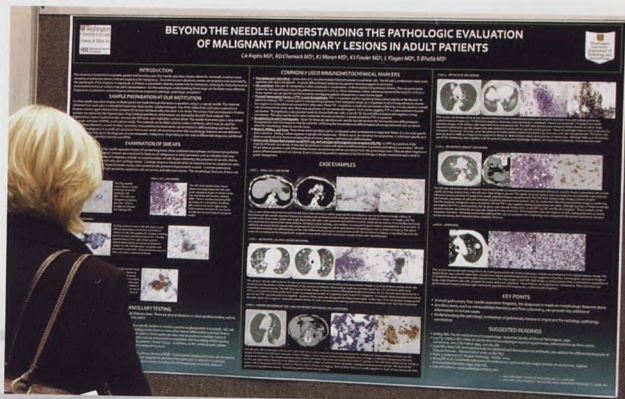
Meghan Lubner, MD; Christine Menias, MD; Jeffrey Carezza, MD; Benjamin Tan, MD; Sam Lubner; Perry Pickhardt, MD, “Complications of therapy in the oncologic patient.”—CERTIFICATE OF MERIT AWARD

Meghan Lubner, MD; Christine Menias, MD; Jeffrey Carenza, MD; Benjamin Tan, MD; Sam Lubner; Perry Pickhardt, MD, "Abdominal emergencies in the oncologic patient."

Meghan Lubner, MD; Christine Menias, MD; Christine Peterson, MD; Sanjeev Bhalla, MD, "Imaging features of traumatic hernias: a pictorial review."

Justin Mackey, MD; Jesse Chusid, MD; Sanjeev Bhalla, MD; Arfa Khan, MD; Deborah Reede, MD; Rakesh Shah, MD, "Pulmonary hypertension: an overview and approach to differential diagnosis."

Kelsey Moran, MD; Constantine Raptis, MD; Kathryn Fowler, MD; Christine Menias, MD; Vamsidhar Narra, MD; Sanjeev Bhalla, MD, "Getting outside the heart of the matter: emerging non-cardiac magnetic resonance imaging applications."



Constantine Raptis, MD; Rebecca Chernock, MD; Kelsey Moran, MD; Kathryn Fowler, MD; Lourdes Ylagan, MD; Sanjeev Bhalla, MD, "Beyond the needle: understanding the pathologic evaluation of malignant pulmonary lesions in adult patients."

Venkateswar Rao Surabhi, MBBS; Srinivasa Prasad, MD; Anuradha Rao, MD; Ravi Kaza, MBBS; Philip Valente, MD; Christine Menias, MD, "Solid primary ovarian neoplasms: cross-sectional imaging findings with pathological correlation."

Pamela Woodard, MD; Michael Barry, MD; Joseph Craft, MD; Pilar Herrero, MS; Kyongtae Bae, MD, PhD; Robert Gropler, MD, "Use of PET and CT to discriminate between ischemic and non-ischemic cardiomyopathy."

Catherine Young, MD, JD; Christine Menias, MD; Carlos Restrepo, MD; Srinivasa Prasad, MD; Sanjeev Bhalla, MD, "CT of acute esophageal emergencies: a pictorial review."

FOCUS SESSION
David Rubin, MD, "MR imaging for sports injuries: do you need an arthrogram? (an interactive session). Candidate 2: you do need an arthrogram."

Srinivasa Prasad, MD; Venkateswar Rao Surabhi, MBBS; Vamsidhar Narra, MD; Peter Humphrey, MD; Christine Menias, MD; Neal Dalrymple, MD, "Recent advances in the cytogenetics and the molecular biology of the urinary bladder cancers: impact on diagnosis and management."

Srinivasa Prasad, MD; Venkateswar Rao Surabhi, MBBS; Anuradha Rao, MD; Ravi Kaza, MBBS; Philip Valente, MD; Christine Menias, MD, "A pattern-based algorithmic approach to ovarian neoplasms: role of cross-sectional imaging."

Srinivasa Prasad, MD; Venkateswar Rao Surabhi, MBBS; Christine Menias, MD; Carlos Restrepo, MD; Jaishree Jagirdar; Kedar Chintapalli, MD, "Bugs and cancers in the belly: a select review of virus-induced malignant neoplasms of the abdomen and the pelvis."

INFORMATICS
Fred Prior, PhD, "National Cancer Institute, Cancer Biomedical Informatics Grid Imaging Workspace—XIP: eXtensible imaging platform development program."

Lawrence Tarbox, PhD, "National Cancer Institute, Cancer Biomedical Informatics Grid Imaging Workspace—XIP: eXtensible imaging platform applications"; "National Cancer

Institute, Cancer Biomedical Informatics Grid Imaging Workspace—XIP: eXtensible imaging platform developer tools."

PLENARY SESSION

Sasa Mutic, MS, "Physics symposium: organ motion in radiation therapy—use of imaging systems for patient modeling."

REFRESHER COURSES

Sanjeev Bhalla, MD, "Current CT techniques for imaging medical emergencies: thoracic emergencies."

Jay Heiken, MD, "CT of the acute abdomen (an interactive session): bowel obstruction and ischemia."

Eric Klein, PhD; Craig Stevens, MD, PhD, "Minicourse: radiation oncology physics—transition to heterogeneity corrections."

Christine Menias, MD, "Current CT techniques for imaging medical emergencies: CT of acute abdominal vascular emergencies"; "Imaging of the gallbladder and biliary tree: diagnosing malignant lesions."

Jeff Michalski, MD; Vamsidhar Narra, MD, "BOOST: prostate—anatomy and oncology."

Sasa Mutic, MS, "Minicourse: image optimization for treatment planning—CT, MR, PET: PET review."

Albert Nemcek, MD; Alex Powell, MD; William Stavropoulos, MD; Michael Darcy, MD, "Case-based review of interventional radiology: vascular interventions (in conjunction with the Society of Interventional Radiology)."

William Palmer, MD; Louis Gilula, MD, "Musculoskeletal interventional procedures."

MIR PRESENTATIONS AT RSNA 2007

REFRESHER COURSES *continued*

Carl Rossi, MD; Jeff Michalski, MD, "BOOST: prostate—integrated science and practice session (ISP)."

Geoffrey Rubin, MD; Pamela Woodard, MD, "Cardiac CT mentored case review: part II (in conjunction with the North American Society of Cardiac Imaging)."

Barry Siegel, MD, "Categorical course in diagnostic radiology: clinical PET and PET/CT imaging—abdominopelvic PET/CT and the Medicare PET registry: the National Oncologic PET Registry."



(left) John Pearson, Siemens Medical Solutions, and (middle) Lawrence Tarbox, PhD, with a visitor to the Informatics area in Lakeside Learning Center

Marilyn Siegel, MD, "Pediatric vascular imaging with CT and MR thoracoabdominal."

Wade Thorstad, MD, "Radioimmunotherapy."

Pamela Woodard, MD; Vincent Ho, MD, MBA, "Cardiac CT mentored case review: part I (in conjunction with the North American Society of Cardiac Imaging)."

SCIENTIFIC SESSIONS

Kyongtae Bae, MD, PhD; Fang Zhu, MD, PhD; Cheng Tao, MD; Thomas Pilgram, PhD; JinMo Goo, MD, PhD; David Gierada, MD, "Chest (lung nodules, management and volumetric analysis): is there significant difference in volumetric measurements of pulmonary nodules performed with five different vendor programs?"


Kyongtae Bae, MD, PhD; Brian Seeck, MD; Cheng Hong, MD, PhD; Charles Hildebolt, DDS, PhD; Masayuki Kanematsu, MD; Pamela Woodard, MD, "Cardiac (CT): the effect of body weight, height, body-mass index, body-surface area, and obesity on contrast enhancement in cardiac multidetector CT."

Sanjeev Bhalla, MD; Christine Menias, MD; Alison Cahill, MD, "ISP: chest (pulmonary embolism: pregnancy, dose issues, and CAD)—imaging of PE in the pregnant patient: is V/Q more robust than CT?"

Cheri Canon, MD; Christine Menias, MD, "Gastrointestinal (acute abdomen)."

Ellen Chung, MD; Angela Levy, MD; Markku Miettinen, MD; Marilyn Siegel, MD, "Pediatric (abdomen) gastrointestinal stromal tumors in the pediatric population: imaging features with clinicopathologic comparison."

Lawrence Goodman, MD; Paul Stein, MD; Fadi Matta, MD; Dirk Sostman, MD; Thomas Wakefield, MD; Pamela Woodard, MD, "Chest (pulmonary embolism—diagnosis and dual energy CT): CT venography and compression ultrasound are diagnostically equivalent: Data from PLOPED II."



Louis Gilula, MD

Milton Guiberteau, MD; Barry Siegel, MD, "ISP: nuclear medicine (National Oncologic PET Registry—oncologic PET/CT)."

Jay Heiken, MD; Lisa Ho, MD, "Gastrointestinal (liver: focal lesions)."

MIR'S 2007 RSNA GRANT RECIPIENTS

- **Toshiba Research Scholar Grant—Jeffrey Linn, MD,** "Noninvasive characterization of NFκB activation in non-alcoholic fatty liver disease."
- **Philips Research Seed Grant—Marilyn Siegel, MD,** "Hyperpolarized Helium-3 MRI assessment of bronchiolitis obliterans in pediatric lung transplant recipients."

Marshall Hicks, MD; Daniel Brown, MD, "Vascular/interventional (ablation)."

Bruce Hillner, MD; Barry Siegel, MD; Edward Coleman, MD; Anthony Shields, MD, PhD; Ilana Gareen, PhD; Lucy Hanna, MS; Sharon Stine; Dawei Liu, PhD, "ISP: nuclear medicine (National Oncologic PET Registry—oncologic PET/CT):—the impact of positron emission tomography on expected management of patients with cancer: initial results from the National Oncologic PET Registry (NOPR)."

Cylen Javidan-Nejad, MD; Parinaz-Massoumzadeh, PhD; Bruce Whiting, PhD; Thomas Pilgram, PhD; David Gierada, MD, "Chest (emphysema: imaging and analysis)—the severity of emphysema affects the impact of radiation dose reduction in quantitative CT analysis of emphysema."

Donna Lesniak, BS; Brian Seeck, MD; Thomas Todoran, MD; Michael Barry, MD; Peter Rao, MD; Pamela Woodard, MD, "Effects of contrast osmolality on heart rate during coronary CT angiography."

Michael Lev, MD; Colin Derdeyn, MD, "Neuroradiology/head and neck (carotid artery disease)."

Meghan Lubner, MD; Kathryn Robinson, MD; Christine Menias, MD; Sanjeev Bhalla, MD, "ISP: emergency radiology (vascular emergencies I)—CT features of traumatic injury to the abdominal aorta."

Elizabeth McFarland, MD, "Gastrointestinal (CT colonography): bowel preparation."

Robert McKinstry, MD, PhD; Erin Simon-Schwartz, MD, "Pediatric (neuroradiology)."

Heber MacMahon, MD; Sanjeev Bhalla, MD, "Chest (lung nodules, CAD)."

Parinaz Massoumzadeh, PhD; Madelyn Stazzone, MD; Fred Prior, PhD; Bruce Whiting, PhD, "Physics (MRI: image quality/reproducibility)—quantifying the spatial resolution of MR protocols using a surface-spread function."

Jeffrey Olsen; Ryan Tierney, MD; Matthew Powell, MD; Perry Grigsby, MD, "Radiation oncology and radiobiology (gynecologic malignancies): acute toxicity of postoperative concurrent chemoradiation for endometrial and cervical cancer."

Constantine Raptis, MD; Sanjeev Bhalla, MD, "Cardiac (multimodality) bicuspid aortopathy: aortic dilatation does not predict aortic stenosis."

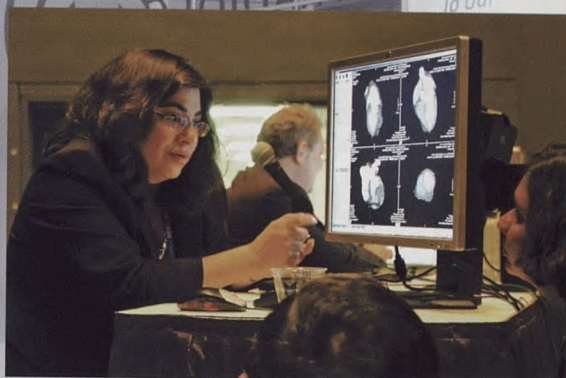David Rubin, MD; Michael Mulligan, MD; Rebecca Loredo, MD, "Musculoskeletal (whole-body imaging applications)."

Luigi Solbati, MD; Sharlene Teefey, MD, "Gastrointestinal (ultrasound contrast: liver)."

Sushilkumar Sonavane, MD; Marilyn Siegel, MD; Sheela Delvanayagam, MD; Charles Hildebolt, DDS, PhD, "Pediatric (obesity/miscellaneous): comparison between ultrasonography and magnetic resonance imaging in assessment of abdominal adipose tissue thickness."

Sushilkumar Sonavane, MD; Marilyn Siegel, MD; Sheela Delvanayagam, MD; Charles Hildebolt, DDS, PhD, "Pediatric (obesity/miscellaneous): MRI abdominal fat volume correlation with liver fat content by MR-spectroscopy and anthropometric measurements."

Madelyn Stazzone, MD; Parinaz Massoumzadeh, PhD; Fred Prior, PhD; Bruce Whiting, PhD, "Physics (various modalities: nuclear medicine, optical MR imaging)—comparison of non-3D true-FSIP images acquired using rapid interleave overlap technique (RIOT) with standard 3D true-FSIP sequences: is there measurable improvement in image quality?"



Pamela Woodard, MD
CONNECTING RADIOLOGY

Cheng Tao, MD; Fang Zhu, MD, PhD; Thomas Pilgram, PhD; David Gierada, MD; Jin Goo, MD, PhD; Kyongtae Bae, MD, PhD, "Chest (lung nodules, management and volumetric analysis) variability in 3D volumetric measurement of pulmonary nodules in screening chest MDCT: comparison of variability measured with five different vendor programs."

Norbert Wilke, MD; Pamela Woodard, MD, "Cardiac (CT)."

Pamela Woodard, MD; Hajime Sakuma, MD, "Cardiac (MR)."



(left to right) **Madelyn Stazzone, MD; Parinaz Massoumzadeh, PhD; Bruce Whiting, PhD**

RSNA PRESIDENT'S WEEK *in brief*

R. GILBERT JOST, MD
2007 RSNA President



SUNDAY, NOVEMBER 25

To kick off the week's activities, in Arie Crown Theater, Jost presented the President's Address, "The evolution of the digital age and its impact on radiology's future." He noted that radiologists must be able to adapt to the rapid advancements being made in radiology.




Eugene P. Pendergrass
New Horizons Lecture
"Major Trends in the Imaging Sciences"



MONDAY, NOVEMBER 26

Above: Jost introduced Elias Zerhouni, MD, director of the National Institutes of Health, who delivered the Eugene P. Pendergrass New Horizons Lecture, "Major trends in the imaging sciences."

Left: More than 2,500 radiology residents from around the world attended RSNA 2007. At the Hyatt Regency, Jost welcomed residents to the annual reception.



TUESDAY, NOVEMBER 27

Above, left: James Thrall, MD, radiologist-in-chief at Massachusetts General Hospital and professor of radiology at Harvard Medical School, was one of three recipients of RSNA's highest honor, the Gold Medal. Thrall, shown with Jost, is highly regarded for his understanding of the programming intricacies of various applications.

Above, right: Among the guests were MIR's former codirectors of the Division of Radiological Sciences, Michael Welch, PhD (left) and Marcus Raichle, MD, shown with the Josts.



President Jost and Peggy Jost greet guests as they arrive at the President's Dinner, held in the historic Palmer House Hilton, the Grande Dame of Chicago's hotels.



WEDNESDAY, NOVEMBER 28

Above: (left to right) Robert Hattery, MD, 2006 RSNA president; Peggy Jost; James Borgstede, MD, University of Colorado Health Sciences Center; Gilbert Jost, MD; and Diane Hattery.

WEDNESDAY, NOVEMBER 28

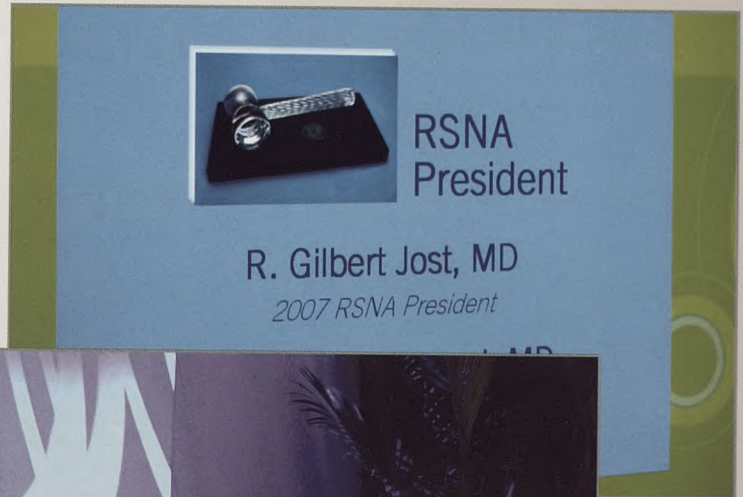
Above: The Leadership Recognition reception was held in Stanley Field Hall of the Field Museum of Natural History.



FRIDAY, NOVEMBER 30

Above: 2007 RSNA President Jost received an Award of Appreciation and a ceremonial gavel from 2008 RSNA President Theresa McLoud, MD.

Right: President Jost during his "Closing Remarks" presentation.



The Annual
MIR
Reception at
RSNA

ON NOVEMBER 26,
 MIR FACULTY, ALUMNI,
 AND FRIENDS RETURNED TO
 THE SPECTACULAR PRESTON
 BRADLEY HALL IN THE
 CHICAGO CULTURAL CENTER
 FOR COCKTAILS AND A
 GOURMET BUFFET.



Above: (seated) Myron Wojtowycz, MD; MIR Alumnus Clark West, MD; Patricia Danz.



Right: John Kotyk, PhD, research associate professor of radiology, and (right) Kenneth Clark, MS, MBA, Electronic Radiology Laboratory project manager.



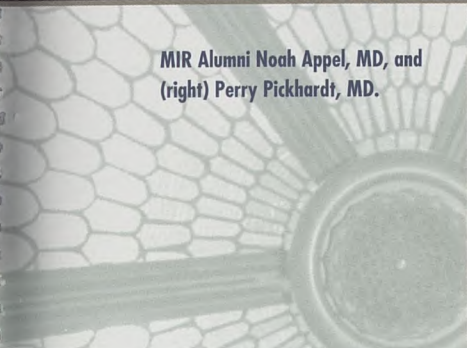
Above: Christine Peterson, MD, assistant professor of radiology, and (right) Michelle Miller-Thomas, MD, neuroradiology clinical fellow



Right: MIR Alumni David Kim, MD, and (right) Hal Bennett, MD



Nirvikar Dahiya, MD, abdominal imaging clinical fellow, and (right) Michael Lin, instructor in radiology.



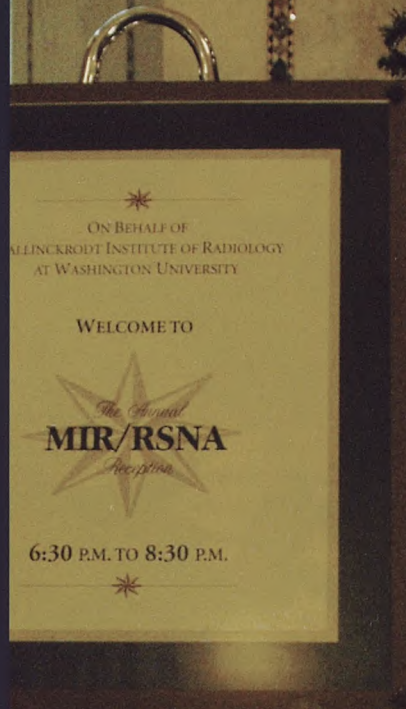
MIR Alumni Noah Appel, MD, and (right) Perry Pickhardt, MD.



Above: (left to right) Bruce McClennan, MD, former chief of MIR abdominal imaging; Ruben Koehler, MD, former chief of MIR abdominal imaging; Myo Kyaw, MD, former MIR abdominal imaging clinical fellow; Ronald Evens, MD, former director of MIR; and Robert Stanley, MD, former chief of MIR abdominal imaging.



Left: MIR Alumni Kevin McEnery, MD, and (right) William Conway, MD



Lending Expertise in Unexpected Places

MIR AT THE

by Mary Jo Blackwood, RN, MPH, and Vicki Kunkler

For more than two decades, Mallinckrodt Institute of Radiology (MIR) has collaborated with one of our city's treasured resources—the Saint Louis Zoo. You might say it is just being neighborly. After all, MIR and Washington University Medical Center are just across



Frank Fischer, bird keeper at the Saint Louis Zoo, and David Rubin, MD, with one of the Zoo's Humboldt penguins.

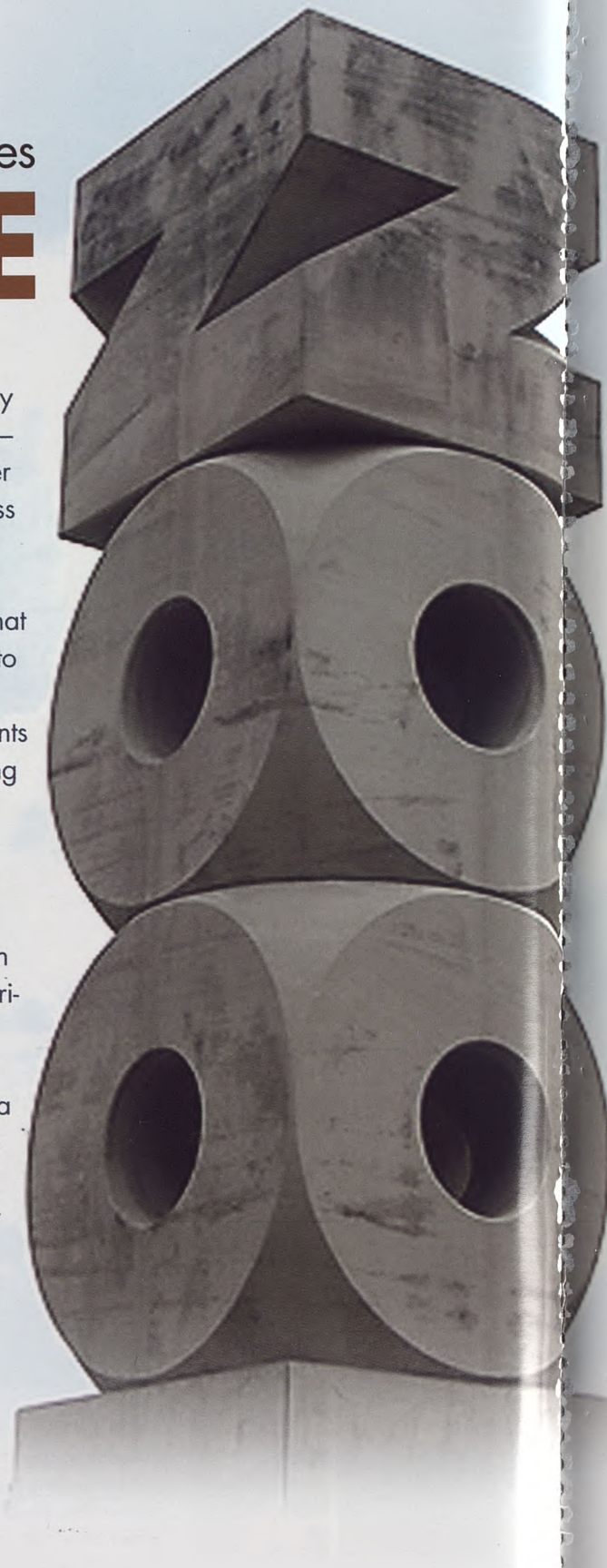
the park (Forest Park that is) from the Zoo. The same expertise that MIR radiologists use to provide the highest quality care for patients is extended to keeping animal friends hale and thriving.

zookeepers had noticed that when the gazelle wanted to look to the side, he turned his whole body instead of only his head. After studying the films, we determined that the animal had a broken neck—very unusual in an animal that otherwise seemed perfectly healthy,” says David Rubin, MD, chief of MIR’s Musculoskeletal Radiology section.

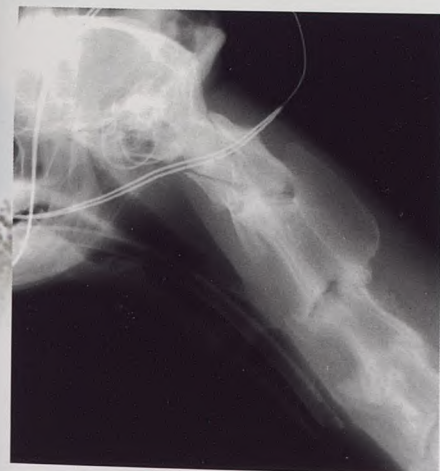“I realized that I had something to add to the care of these animals. Although the veterinarians were experts in the areas of the gazelle’s anatomy and animal disease, they rarely deal with spinal fractures—which is something I see every week in our human patients.”

the park (Forest Park that is) from the Zoo. The same expertise that MIR radiologists use to provide the highest quality care for patients is extended to keeping animal friends hale and thriving.

“My involvement with the Zoo started three years ago when two of the Zoo’s veterinarians came to my office with X rays of the cervical spine of a Cuvier’s gazelle. The



The Zoo's infirmary—officially called the Endangered Species Research Center and Veterinary Hospital—cares for the Zoo's 22,805 inhabitants, providing preventive, medical, and surgical care while also overseeing the genetic testing and breeding programs. An on-site team of health-care experts includes two full-time veterinarians, two veterinary residents, a veterinary pathologist, three animal health technicians, and a quarantine manager. Animal specialists, including a veterinary dentist, a veterinary ophthalmologist, and a veterinary radiologist—Michael Muhlbauer, DVM, of Veterinary Imaging Specialists in St. Louis—contribute their services.



Historically the Zoo has called on physicians (including Washington University specialists) who treat human patients to supplement the subspecialty treatment of ailing animals. “The Zoo performs about forty X rays each month; at MIR, it's in the hundreds per day,” says Rubin. “The Zoo veterinary staff meets monthly with Doctor Muhlbauer to review all of the animal radiographs, so I started attending those meetings.”

The Zoo infirmary can perform conventional X-ray procedures with a stationary unit, a portable machine, and a mammography unit that is used for small animals and birds. Although the veterinarians often use a basic ultrasound unit, Muhlbauer brings a more sophisticated portable unit to the Zoo whenever it is needed. At Rubin's suggestion, Barnes-Jewish Hospital donated a used fluoroscope to the Zoo. This equipment displays real-time images that can be used to monitor the progress of different imaging or therapeutic procedures, including contrast studies of the gastrointestinal and urinary tract as well as fracture reductions and fixations.

However, the Zoo does not have its own magnetic resonance (MR) or computed tomography (CT) scanner, mainstays of

Top, left: Counted among the rarest of gazelles, Cuvier's gazelles live in hills, plateaus, and forests ranging from Morocco to Algeria.

Bottom, left: This lateral projection of the cervical spine of an anesthetized Cuvier's gazelle shows a nondisplaced fracture of the first cervical vertebra (C1).



Left to right: Melanie King, animal health technician; Mike Adkesson, DVM, veterinary resident; and Randy Junge, DVM, director of animal health, perform a liver biopsy on a bird. Photo courtesy of the Saint Louis Zoo.

advanced radiological imaging in humans. A local veterinary practice has a small-bore CT scanner that the Zoo can use for smaller animals.

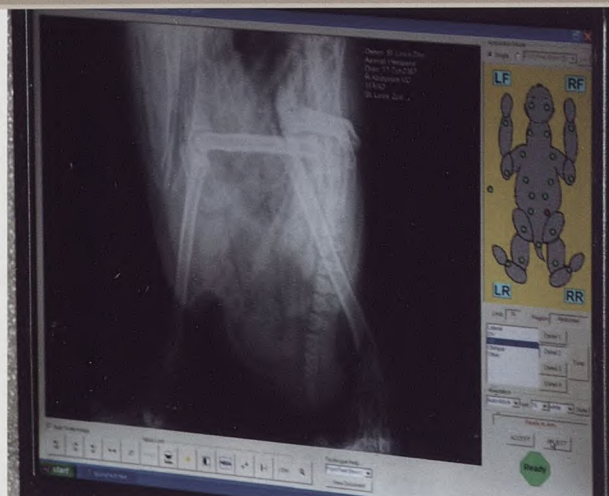
“Our city has a wonderful zoo—one of the few in the country that has no admission fee, so they rely on donations to purchase items such as radiological equipment. They do a wonderful job, and we wanted to help,” explains Rubin. Initially, he coordinated efforts to use the CT scanners at Washington University Medical Center as part of necropsies (the autopsy procedure done on all deceased Zoo animals). Information from these CT scans has proven helpful for determining an animal's cause of death and for identifying premonitory conditions that may affect the care and breeding of related animals housed at the Zoo.

MIR AT THE ZOO



On rare occasions when there is a diagnostic dilemma that cannot be solved with traditional tools, diagnostic imaging has been performed on live, medium-sized animals, using the sophisticated imaging equipment at Washington University Medical Center and always after patient hours.

Rubin says that most of the work at the Zoo goes on behind the scenes: Many rare and endangered animals are bred at the Saint Louis Zoo as part of cooperative programs with other zoos worldwide. The Zoo also helps animal welfare



Left: During the Zoo's penguin roundup to check for ingested coins, cardboard tubes are used to gently immobilize penguins while they are being X-rayed. Here, a penguin is standing in front of the X-ray detector; the yellow box is a portable X-ray generator.

Right: This image—displayed on a laptop computer running software especially designed for veterinary use with a portable direct radiography unit—shows the lower body of a penguin being screened; fortunately, this penguin had not ingested any coins.

groups in the St. Louis area—such as The Wild Canid Survival and Research Center, more commonly known as Wolf Sanctuary—to keep their population of rescued or protected animals healthy.

“I really like the opportunity to apply what I know about human conditions to the different anatomy and physiology of the various animals at the Zoo. The imaging procedures performed at the Zoo are less sophisticated than those used for human patients, and part of the challenge is to obtain as much information as possible from these more basic, traditional tests. Having a limited diagnostic armamentarium

also gives the Zoo staff the opportunity to be much more creative in the way they examine and treat the animals as compared to the way physicians handle their human patients,” says Rubin. “For now, I think I have as much to learn from the animals and their caretakers at the Zoo as I have to offer them in terms of my knowledge of radiology and of human conditions.”

Although his clinical, teaching, and administrative responsibilities at Mallinckrodt Institute keep him busy, Rubin intends to continue donating his time and expertise to the Saint Louis Zoo. Now that's being a good neighbor.

Saint Louis Zoo Facts

- The interest in a zoological park began with the construction of an elliptical bird cage (called the Flight Cage) for the 1904 Louisiana Purchase Exposition (commonly called the St. Louis World's Fair) in Forest Park.
- The Zoo was officially established in 1910, and Missouri State legislation provided that “the Zoo shall forever be free.”
- The Zoo now occupies 90 acres and is home to 22,805 animals (and more than 800 species), many of which are considered rare or endangered.
- The Zoo annually hosts more than 3 million visitors.
- Zagat Survey's *U.S. Family Travel Guide* named the Saint Louis Zoo as the nation's “#1 zoo.”
- The Zoo was one of the first zoos in the world to exhibit animals in naturalistic settings.
- Saint Louis Zoo was the site of the first zoo tissue banks for preserving tissues from dead specimens for future scientific study.

Information compiled from Britannica Online Encyclopedia and from the Saint Louis Zoo web site.

Animals and their human-like conditions

One of the reasons MIR's expertise has been so helpful is that humans have a lot in common with our animal friends. Many of the conditions the Zoo veterinarians see also are encountered in the human population.

DOMESTIC VIOLENCE

Animal families or groups can become aggressive with each other, even when they are closely monitored. For example, the Zoo had a male stork who would repeatedly attack his mates. This behavior resulted in the stork being moved into separate quarters, to live as a confirmed bachelor. Animal trauma victims end up on the Zoo's X-ray table; many of their human counterparts are treated at the Knight Emergency and Trauma Center at Washington University Medical Center.

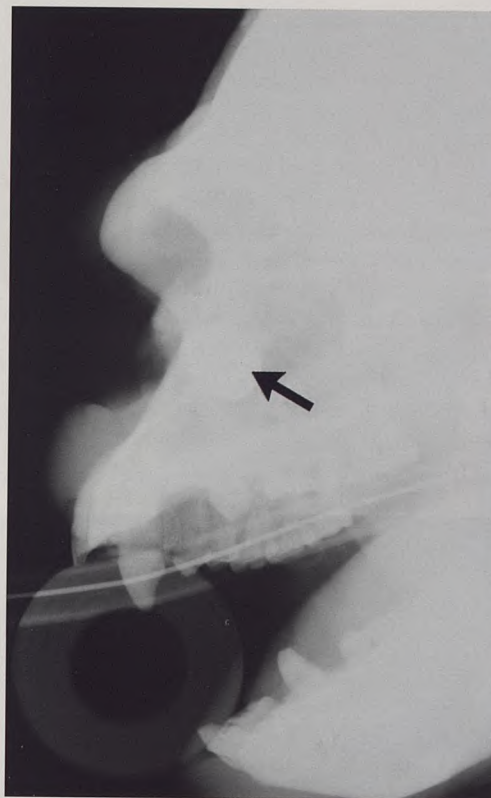
ACCIDENTS

Animals have accidents. They run into fences and walls. The clumsy and elderly ones may just fall or trip. Because the animals cannot tell their keepers what happened or where they hurt, it often comes down to a review of the X rays to identify and manage the injuries. Fractures and open wounds in animals are managed according to the same principles—and with surprisingly similar techniques—as used for humans.

INGESTION OF FOREIGN MATERIALS

Despite the customized diets that are meticulously researched and prepared for the Zoo animals, some of the animals occasionally ingest foreign materials, including parts of their habitats and debris left behind by visitors and other animals. Different objects cause different medical problems, from poisoning to bowel obstructions.

A particular danger is the coins that are thrown into several pools contained in Penguin and Puffin Coast, a popular attraction. It has become such a problem that several times per year the penguins are rounded up and X-rayed to check for coin ingestion. And just as in humans, kids will be kids—one juvenile chimpanzee found a penny on the ground and promptly stuck it up her nose!



Above: A lateral X ray of an anesthetized juvenile chimpanzee shows the location of a penny (arrow) that she pushed up her nose.

Right: At one time, more than 1 million chimpanzees lived in central and western Africa—now only 150,000 survive, due in part to loss of habitat and the Ebola virus. Photo by Michael Jacob, Saint Louis Zoo.



Animals and their human-like conditions *...continued*

GERIATRIC DISEASES

As Rubin explains, “We don’t often see these types of cases in wild animals, because at some point an aging animal either can’t get enough food to survive or it becomes food for a healthier, younger foe. However, in the protected environment of a zoo, many animals live longer than they would otherwise, and they develop the same spectrum of age-related disorders as do humans: heart disease, arthritis, poor dentition, and so on. These conditions require the same radiological tests for diagnosis, staging, and follow-up as are used for humans.”

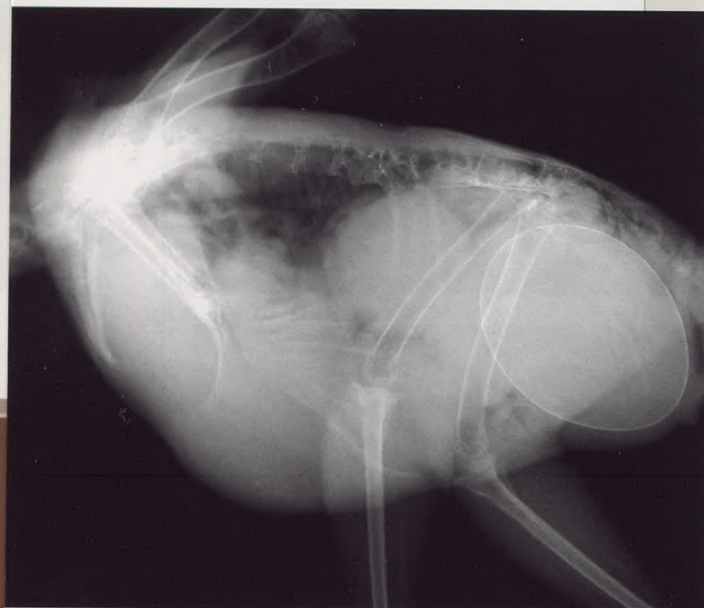

LABOR AND DELIVERY

Just as in humans, complications during birth also happen in animals. Sometimes the problem is that the pregnancy is unexpected. For example, an X ray of one bird who was acting ill showed a large egg stuck in the pelvic canal (called egg binding). The veterinarians were able to lubricate the canal and extract the egg: end of the bird’s illness. Recently, a reptile developed generalized body bloating and lumpiness. Diagnostic imaging showed that she was full of eggs. As soon as all of the eggs were laid, the problem disappeared.

Top: The piping guan is native to South America and spends most of its life in the tropical forest canopy. Photo by Chuck Dresner, Saint Louis Zoo.

Bottom: The large lateral projection is a stuck egg. In the wild, this condition is often fatal as the bird can develop egg peritonitis (infection in the body cavity).



Saint Louis Zoo Hospital

- The hospital is a 17,000-square-foot complex comprised of central treatment areas, research laboratories, an animal quarantine wing, and administrative space.
- The hospital’s research focuses primarily on breeding programs.
- 125 consultants (veterinarians, medical doctors, dentists, biologists) are ready to assist with cases on an ongoing basis.
- On average, 200 patients per year are X-rayed.
- More than 2,500 animals receive medical visits from the veterinarians each year.
- About 300 animals each year are anesthetized for examinations and medical procedures.
- The hospital has 12 separate ventilation systems. Each area (quarantine, necropsy, operating, offices, etc.) has a separate air supply.
- The veterinary program has 6 students each year who work in 6-week to 8-week rotations.
- In a one-year period, the hospital filled 1,451 prescriptions and treated 1,812 animals (of which 30 percent were mammals; 30 percent, reptiles; and 40 percent, birds).

For more information, go to www.stlzoo.org.

A Memorable Patient

Louis Gilula, MD, professor of radiology and of medicine and a former liaison with the Saint Louis Zoo, began his stewardship by consulting on the case of a Speke's gazelle (an endangered mammal native to Somalia). After undergoing diagnostic radiology examinations, the gazelle was diagnosed with osteomyelitis (an inflammation of the bone).

In 1992, Gilula met one of his most memorable Zoo patients: a 33-year-old gorilla named Fred, who was limping and showing signs of chronic back pain. Fred was the dominant male of a troop of five Western lowland gorillas from the tropical forests of equatorial Africa. He was part of the Zoo's Species Survival Plan, a nationwide zoological cooperative breeding program for endangered species. At 300-plus pounds and standing more than five and a half feet tall, Fred was formidable. But Fred embodied the moniker given to lowland gorillas—Gentle Giants—and was the perfect patient.

A series of radiological examinations, performed after patient hours at Mallinckrodt Institute,



Left: After scanning Fred's hips and arm, Louis Gilula, MD, diagnosed degenerative arthritis.

Above: Fred, as he appeared on the cover of the Summer 1992 issue of *Focal Spot* magazine.

showed that Fred was suffering from osteoarthritis (a noninflammatory degenerative joint disease) in his hip and had a bulging disc in the middle of his neck. According to follow-up reports from the Zoo team, painkillers were prescribed to relieve some of Fred's discomfort from the arthritis and surgery was always an option. Fred lived for several years following his visit to MIR. **MIR**

*IMAGING SCIENCES PATHWAY **TRAINING SCIENTIFIC LEADERS OF THE FUTURE**

by Candace O'Connor

*MOLECULAR BIOLOGY *ENGINEERING *PHYSICS *CHEMISTRY *MATHEMATICS

Finding solutions for the complex biomedical problems of the future will not be easy. In this new world of research, scientists will have to work at the intersection of several fields: molecular biology, engineering, physics, mathematics and chemistry.

“We see this as a new paradigm for education”


Paradigm

They will need a broad education in basic biological issues, as well as technological know-how. How do universities create the kind of interdisciplinary curriculum needed to train this new crop of “renaissance scientists”?

With this cross-training goal in mind, an innovative Imaging Sciences Pathway (ISP) began in 2006 at Washington University School of Medicine, under the auspices of the Division of Biology and Biomedical Sciences (DBBS). Doctoral students from various fields take key classes together; they also work on research projects with one mentor from their primary field and another mentor from a different discipline. Undergraduates from the University’s Danforth Campus also participate, taking classes and doing summer or academic-year research.

“We see this as a new paradigm for education,” says Philip Stahl, PhD, ISP director and professor and head of the Department of Cell Biology and Physiology. “We get undergraduates interested in imaging early on, and we also attract graduate students from all over the campus, giving them a breadth of knowledge that will permit them to work on the next generation of problems.”

“We want biophysics majors to be good in biophysics,” adds Carolyn Anderson, PhD, codirector of the ISP and professor of radiology. “But if they are interested in imaging, they also should understand the instrumentation and the biology behind how a contrast agent works. Engineers need a sense of the biology, while biologists should know a little of the math, so they can all speak the same language.”



(Left to right) Philip Stahl, PhD; Dee Owyong, Cell Biology’s manager of administrative services; and Carolyn Anderson, PhD, are shown in the Farrell Learning and Teaching Center, at the top of the stairway leading to the second-level hearth area.

While other medical schools have graduate programs in imaging sciences, and some engineering schools (including Washington University’s Department of Electrical and Systems Engineering) have certificate-granting programs for their own students, Washington University’s ISP may be the first of its kind in the country. The undergraduate component is one novel feature, the student mix from so many disciplines is another, and a third is the broad base of the program, which covers imaging from contrast agents to instrumentation and its applications from bench to bedside.

The ISP has attracted widespread interest on both the medical and Danforth campuses. To date, some 60 faculty members have signed up to serve as mentors; eight graduate students are currently enrolled, along with 16 undergraduates. Anderson says she has met dozens of new faculty from “across the Park,”—referring to the Danforth campus—whom she had not known before. Clearly, the ISP has catalyzed the development of an imaging sciences community at Washington University.

Interest

Gilbert Jost, MD, professor and head of the Department of Radiology and director of Mallinckrodt Institute of Radiology, is an avid proponent of the ISP. "There is no question that imaging will play an increasingly important role in medicine and scientific discovery in the years ahead. However, we need to train a new breed of imaging scientists for the future, individuals who are skilled not only in the biological sciences but also in the physical sciences, such as chemistry, physics and mathematics, and in computer science and engineering. The ISP is an important first step in this direction."



Gilbert Jost, MD



Ralph Quatrano, PhD

ISP BEGINNINGS

The program evolved from a meeting held in Jost's office in 2003. As part of the National Institutes of Health (NIH) Roadmap initiative, curriculum grants were newly available. Anderson agreed to spearhead the application for an interdisciplinary science curriculum grant, which was funded in September 2004. Meanwhile, Stahl had been interested in developing an educational program that could boost the imaging component of BioMed 21, the University's innovative research initiative designed to create mechanisms for quickly transferring scientific discovery into patient treatment.

Jost and Stahl agreed to a joint focus on imaging, and Anderson and Stahl formed an advisory committee of potential collaborators from areas such as engineering, medicine, the College of Arts & Sciences, and the DBBS to develop

an application for a full-scale training grant. After an unsuccessful bid for a Howard Hughes award, they applied for another NIH Roadmap Initiative grant, with important assistance from Dee Owyong, Cell Biology's manager of administrative services. To the delight of all participants, this proposal was successful.

"How biology integrates with the physical sciences and engineering is the path forward in the next few decades," says Ralph Quatrano, PhD, professor and chairman of the Department of Biology, who also serves as director of the undergraduate Pathway program. "Imaging sciences is the perfect example of a field where this kind of integration will enhance technological breakthroughs. The ISP is the approach that the DBBS is taking to integrate these fields in order to train the next generation of biomedical scientists."

THE ISP PROGRAM

At the graduate level, the program is open to students in the DBBS as well as those in chemistry, physics, mathematics, biomedical engineering, computer science, electrical and systems engineering and mechanical engineering. Students should apply by their second year of study, although they can begin ISP courses during their first year. Course requirements include the following:

- one-semester, weekly seminar series in imaging sciences and engineering
- course in molecular cell biology (offered through either the DBBS or the Department of Biomedical Engineering)
- course called the "Principles and Applications of Biological Imaging"
- choice of courses that focus on contrast agents for imaging or biological imaging technology.

The content of the Principles and Applications course is still “a work in progress,” says Anderson. In spring 2006, when it was first offered, there were seven students (six from engineering and one from chemistry) so talking about the instrumentation first, followed by its biological application, went smoothly. This year, 17 students signed up, half of them from biology, and the biologists struggled with the heavy dose of technology up front.

The freshman seminar, which is offered pass/fail, includes lectures by imaging experts from various fields: radiology, cardiology; mechanical engineering; neurology; physics, and biomedical engineering. A question-and-answer session follows the seminar, allowing eager students to pepper the speaker with ideas.

These young students also enjoy the research component of the program, says Anderson. At a 2007 symposium, 11 of 16 poster

“... and the students who stuck it out have been happy with the program.”

“Doctor Joseph Culver [a physicist and assistant professor of radiology] and I taught the course together and have already written an alternate syllabus for next year that will intersperse the applications with the biology,” says Anderson. “I think we have learned a lot this semester, and the students who stuck it out have been happy with the program.”

For ISP undergraduates, who come from the same disciplines as their graduate counterparts, the course requirements are not strenuous. An introductory freshman/sophomore seminar introduces prospective Pathway students to imaging research currently underway, while juniors and seniors are encouraged to take one of the three graduate courses offered.

presentations related to imaging research. “We are a research university, and I believe that all undergraduates should have their hands on a serious research project,” says Stahl. “That doesn’t mean they are not going to take Greek or a modern language or other courses of interest to them.”

Henry Biggs, PhD, associate dean and director of undergraduate research, appreciates this focus. “I have been impressed with how doctors Anderson and Stahl have made a concerted effort to span student levels, colleges, even campuses,” he says. “At the undergraduate level, this has led not only to new research opportunities that our office is understandably excited about, but also to new courses that position our students excellently for their scientific futures.”

INSTRUCTORS FOR THE ISP FRESHMAN SEMINAR

COURSEMASTER

Ralph Quatrano, PhD,

BIOLOGY

Kathryn Miller, PhD

BIOMEDICAL ENGINEERING

Mark Goldberg, MD

CARDIOLOGY

Samuel Wickline, MD

MECHANICAL ENGINEERING

Philip Bayly, PhD

NEUROLOGY

Mark Goldberg, MD

Steven Petersen, PhD

PHYSICS

Mark Conradi, PhD

James Miller, PhD

RADIOLOGY

Carolyn Anderson, PhD

Gilbert Jost, MD


Koresh Shoghi, PhD

Opportunity

THE FUTURE OF THE PROGRAM

Funding from the NIH grant ends in 2010, but Anderson and Stahl hope that the ISP will be ongoing, with even more elements to offer students. They now are in the early stages of offering a distance-learning component by videotaping lectures and putting them on the Internet for use by affiliated investigators. In spring 2007, a student at the University of California-Berkeley took Anderson's contrast imaging course by distance-learning—and got the highest grade in the class.

They also are working on plans to offer a doctoral program in imaging sciences in 2009. With this degree, graduates could work in academia, in biotech companies, or in any firm that wants to apply imaging expertise to biological problems.



Henry Biggs, PhD

For now, Anderson, Stahl, and their collaborators are pleased with the ISP's progress. "These interdisciplinary pathways are ever more important as the boundaries between disciplines blur," says Mary Sansalone, PhD, dean of the School of Engineering and Applied Science, "and many of the challenging problems are at the interfaces between disciplines. This pathway in imaging is particularly important to engineering as it is one of our strategic areas for faculty hiring and is the focus of much student interest."

One example of the benefit that comes from this cross-pollination is an engineering doctoral student who made a presentation on a hard-science view of receptor biology at a symposium last summer. When the student admitted that he



Mary Sansalone, PhD

working on quantum dots and optical techniques. The student and Achilefu are now working together.

"We hope that students will take advantage of this experience

"...this has led not only to new research opportunities that our office is understandably excited about, but also to new courses that position our students excellently for their scientific futures."

needed more information on the biology itself, Anderson asked whether he wanted to be linked to a faculty member who could help him. She put him in touch with Samuel Achilefu, PhD, professor of radiology and chief of Mallinckrodt Institute's Optical Radiology Laboratory, where researchers are

in imaging," says Stahl. "We want to continue to create a new group of leaders in biological sciences and imaging—a more multi-disciplinary and interdisciplinary group than ever before—who hopefully will become the scientific leaders of the future." **MIR**




TAKING RADIOLOGY SERVICES TO THE

LEVEL

SPOTLIGHT ON **MIR** AT
BARNES-JEWISH
WEST COUNTY HOSPITAL

NEXT

by Mary Jo Blackwood, RN, MPH



When Mallinckrodt Institute of Radiology (MIR) assumed responsibility for radiological services at Barnes-Jewish West County Hospital (BJWCH) 15 years ago, it started with a small, general radiology group—that has grown considerably over time—led by Robert Levitt, MD, associate professor of radiology. As the patient base has grown in west St. Louis County, the staffing emphasis has evolved into a subspecialty model, due in part because Washington University School of Medicine has been expanding its operations to cater to a variety of specialty groups that need specific radiology expertise for diagnosis and treatment. Based on that expansion, BJWCH now is included in the medical education rotations for residents and clinical fellows.

TAKING RADIOLOGY
SERVICES TO THE

NEXT LEVEL BJWCH

RADIOLOGY SERVICES AT BJWCH

AVAILABLE NOW

- X rays
- GI/ GU contrast studies, including defecography
- Ultrasound, including arterial and venous Dopplers
- Conventional MRI
- Wide-bore (10 centimeters larger than conventional MRI), high-field strength (1.5 Tesla) MRI with a specially built table mechanism to accommodate patients weighing up to 500 pounds
- MR angiograms
- CT
- CT angiograms
- CT urography
- 3-D imaging and advanced visualization
- Nuclear medicine, including thallium stress test and stress echo
- Bone densitometry
- PET
- Mammography

COMING IN 2008

- Ultrasound-guided biopsy
- Musculoskeletal ultrasound
- CT-guided biopsy
- 64-slice CT (high speed) for cardiac and advanced vascular imaging
- Colonography (virtual colonoscopy)
- MRI of prostate and female urethra
- Pediatric radiology

Many Washington University specialists and private practice physicians in West County want the MIR expertise for their patients—but without having the patients travel to Washington University Medical Center (an even more important consideration in light of the Highway 64/40 construction).

“The community demands a high level of service. Enhanced radiology is a welcome addition to West County because it provides

Center are available at BJWCH, including neuroradiology, musculoskeletal, cardiac, thoracic, abdominal, mammography, and nuclear medicine. Imaging done at the Medical Center can be readily accessed at BJWCH, now that all images are digital and can be viewed on radiology workstations. Plus, a second opinion is just an e-mail or a telephone call away, making it easier for collaboration among different staff members.

“The community demands a high level of service. Enhanced radiology is a welcome addition to West County because it provides the same expertise that is available at the Washington University Medical Center...”

the same expertise that is available at the Washington University Medical Center. Even without highway construction, the enhanced service at the county facility makes sense. Many of our patients live in West County,” says Gilbert Jost, MD, head of the Department of Radiology and director of MIR.

Daniel Picus, MD, chief of MIR’s Division of Diagnostic Radiology, shares Jost’s enthusiasm. “MIR has always provided excellent services at Barnes-Jewish West County Hospital. We have a great team of radiologists there and are expanding on that base to increase the depth and breadth of coverage. It’s an incredible opportunity to provide the same quality of radiology services available at Barnes-Jewish and Children’s hospitals to patients who would like to stay in the county.”

The radiologists who interpret diagnostic images and nuclear medicine studies at Washington University Medical Center are the same radiologists who are looking at the radiology studies done at BJWCH. All subspecialty imaging services available at the Medical

Interdepartmental perspectives and consultation for tumor boards and patient care conferences are shared with BJWCH radiology staff via webcast.

These days, Vamsi Narra, MD, associate professor of radiology, divides his time between Washington University Medical Center and BJWCH. Narra, who is cochief of body magnetic resonance imaging (MRI), has a new title: Radiology Chief of Clinical Operations at BJWCH. While he’s looking forward to the new radiology services coming to the West County hospital, Narra’s also excited about what’s already there.

“Today, we have interpretation for all subspecialties at BJWCH, and we offer a wide range of imaging as well. Some of the more standard imaging are X rays, GI/GU contrast studies, ultrasound, MRI, CT [*computed tomography*], mammography, and nuclear medicine, including thallium stress tests, bone densitometry, and PET [*positron emission tomography*]. It’s the not-so-common technology we provide that makes the West County facility special.”

969 N. Mason Road

First Floor

- Plastic Surgery International, Suite 100
- Bodyaesthetic Plastic Surgery & Skincare Center, Suite 170
- BJWCH Imaging Center, Suite 110
- Bennett Frank, M.D., Suite 155
- Michael Weiss, DPM & Assoc., Suite 180
- West County Medical Specialists, Suite 145
- Escandon, Lemann, Silverman Neurology, Suite 140
- Barnes West Medical Consultants, Suite 160

Second Floor

- Washington University Center for Dermatologic and Cosmetic Surgery, Suite 200
- Washington University Dermatology, Suite 220
- Karen Forsman, M.D., Dermatology LLC, Suite 235
- Pain Management Center, Suite 240
- Advantage Pulmonary and Sleep Medicine, Suite 250
- BJWCH Sleep Disorders Center/ EEG Lab, Suite 260

Physician Office Building 1

First Floor

- Kamal Demetry, Suite 102
- Pain Prevention & Rehabilitation Center, Suite 103
- Colliers Turley Martin Tucker, Suite 109
- The Clinical Research Center, L.L.C., Suite 112
- Associated Specialist In Medicine, Suite 115
- BJWCH Pulmonary Function Testing Laboratory, Suite 116
- Washington University Surgery, Suite 120
- Washington University Urology, Suite 122
- Washington University Neurology, Suite 123
- Washington University Aesthetic Surgery Center, Suite 124

Second Floor

- Washington University Thoracic Associates, Suite 201
- GI Consultants, Suite 206
- Oral and Maxillofacial Surgery and Dental Implant, Suite 207
- Washington University Pediatric Psychiatry, Suite 210
- Washington University Neurosurgery, Suite 211
- Tempo Surgical, Inc., Suite 214
- Washington University Pediatric Eye Center, Suite 219

Ground Level

- BJWCH Radiology, Suite G-02
- Orthopedic Care of St. Louis, Suite G-03

Physician Office Building 3

First Floor

- BJWCH Phlebotomy Lab, Suite 100
- Heart Care Institute, Suite 100
- Washington University Pediatric Specialists, Suite 110
- BJWCH Radiology, Suite 120

Second Floor

- Heart Care Institute Rehabilitation Center, Suite 200
- BJWCH Education & Nutrition Counseling Services, Suite 200
- Washington University Renal Center, Suite 205
- STAR Center, BJWCH Physical Therapy, Suite 220

Physician Office Building 2

First Floor

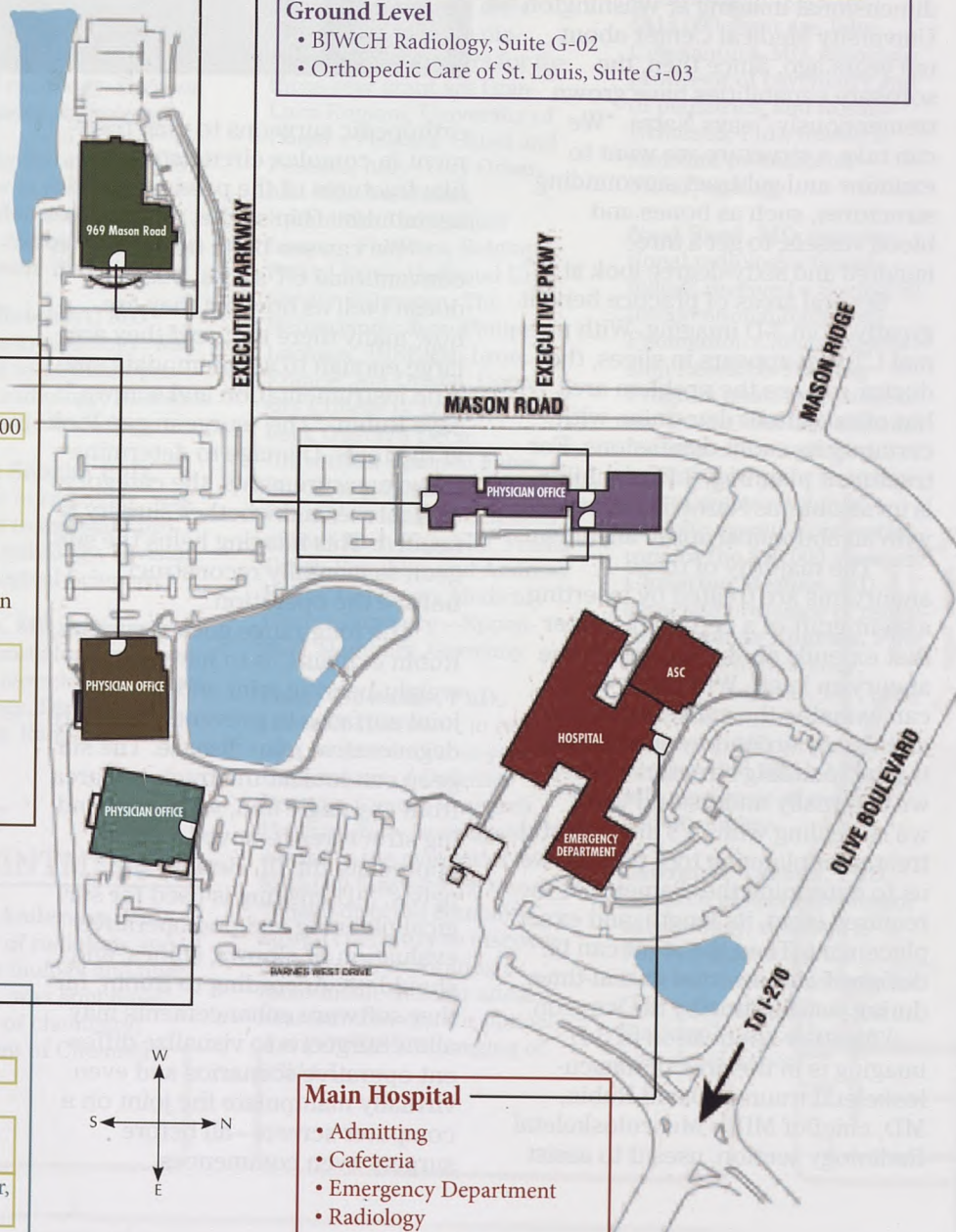
- Siteman Cancer Center, Suite 100

Second Floor

- Washington University Medicine Multi-specialty, Suite 200
- Washington University Eye Center, Suite 250
- BJWCH Radiology, Suite 210

Main Hospital

- Admitting
- Cafeteria
- Emergency Department
- Radiology
- Patient Rooms
- Ambulatory Surgical Center



TAKING RADIOLOGY
SERVICES TO THE

NEXT LEVEL BJWCH

3-D IMAGING AND ADVANCED VISUALIZATION

Leading-edge capabilities at BJWCH not readily available at other medical facilities in West County, such as 3-D imaging and vascular CT, have already provided physicians and surgeons with important tools. “We started using advanced visualization and three-dimensional imaging at Washington University Medical Center about ten years ago. Since then, the software capabilities have grown tremendously,” says Narra. “We can take a structure we want to examine and subtract surrounding structures, such as bones and blood vessels, to get a three hundred and sixty-degree look at it.”

Several areas of practice benefit greatly from 3-D imaging. With normal CT that appears in slices, the doctor can see the problem area but often cannot determine with certainty its exact dimensions. For treatment planning, 3-D capability is invaluable, as Narra demonstrated with an abdominal aortic aneurysm.

“The majority of these aneurysms are treated by inserting a stent graft of a certain diameter that extends above and below the aneurysm itself. With three-D, we can examine the entire aneurysm all the way around by subtracting the surrounding structures. Then we can really understand what we’re dealing with. It’s a wonderful treatment planning tool that allows us to determine the diameter of the required stent, its length, and exact placement. Then the stent can be designed and inserted in real-time, during visualization by the surgeon.”

Another application of 3-D imaging is in the area of musculoskeletal trauma. David Rubin, MD, chief of MIR’s Musculoskeletal Radiology section, uses it to assist



orthopedic surgeons to plan treatment in complex circumstances like fractures of the pelvis and acetabulum (hip socket).

“We can see bone fragments on conventional CT slices, but that doesn’t tell us how big they are, how many there are, or if they are large enough to accommodate specific instrumentation and screws,” says Rubin. “The surgeon can look at the three-D image to determine those measurements, the category of fracture, and whether surgery is needed. This imaging helps the surgeon to mentally reconstruct before the operation.”

The long-range goal of surgery, Rubin explains, is to have a stable weight-bearing joint and smooth joint surfaces to prevent premature degenerative joint disease. The surgeon can look at the fractured area from any angle and, with surrounding structures removed, better appreciate the fit. Besides the pelvis, 3-D imaging is used for surgical planning and postoperative evaluation of elbows, spines, and shoulders. According to Rubin, further software enhancements may allow surgeons to visualize different operative scenarios and even virtually manipulate the joint on a computer screen—all before surgery even commences.

Vamsi Narra, MD, and (right) Robert Levitt, MD, are in the Imaging Center at 969 North Mason Road, just across the street from BJWCH.

OTHER TECHNOLOGIES ON THE WAY

Currently, BJWCH is equipped with a 16-slice CT scanner. After a new 64-slice, high-speed scanner (a necessity for studies of the beating heart) is installed, advanced imaging—including cardiac CT—will be part of the imaging routine. This new service will be helpful for patients of cardiologists in the West County area.

Musculoskeletal ultrasound, ultrasound-assisted biopsies, and other procedures will be added, followed by other medical and surgical specialties. Siteman Cancer Center West will be in BJWCH’s Physician’s Office Building 2. Later this year, an additional CT scanner for diagnostic imaging and treatment planning will be in place. A linear accelerator for radiation oncology, allowing more radiological support for area oncologists, will be installed.

“By the end of the year, most Washington University specialties, including pediatrics, will have a presence at BJWCH, and we want our radiology services to be responsive to their needs,” says Narra. **MIR**

In this section, the names of employees who are full-time faculty or staff or who have an appointment in the Department of Radiology are highlighted in boldface type.

NEW FACULTY

Tetsuya Mori, PhD, visiting assistant professor, Division of Radiological Sciences.

Kathryn Robinson, MD, instructor in radiology, Division of Diagnostic Radiology.

Akash Sharma, MD, instructor in radiology, Division of Nuclear Medicine.

PROMOTIONS

Tammie Benzinger, MD, PhD, instructor in radiology, was promoted to assistant professor of radiology, Division of Diagnostic Radiology.

Andrew Bierhals, MD, PhD, instructor in radiology, was promoted to assistant professor of radiology, Division of Diagnostic Radiology.

Delphine Chen, MD, instructor in radiology, was promoted to assistant professor of radiology, Division of Nuclear Medicine.

DeWitte Cross, MD, associate professor of radiology, was promoted to professor of radiology, Division of Diagnostic Radiology.

Colin Derdeyn, MD, associate professor of radiology, was promoted to professor of radiology, Division of Diagnostic Radiology.

James Duncan, MD, PhD, assistant professor of radiology, was promoted to associate professor of radiology, Division of Diagnostic Radiology.

Richard Laforest, PhD, assistant professor of radiology, was promoted to associate professor of radiology, Division of Radiological Sciences.

Matthew Parsons, MD, instructor in radiology, was promoted to assistant professor of radiology, Division of Diagnostic Radiology.

Christine Peterson, MD, instructor in radiology, was promoted to assistant professor of radiology, Division of Diagnostic Radiology.

Valerie Reichert, MD, instructor in radiology, was promoted to assistant professor of radiology, Division of Diagnostic Radiology.

Koresh Shoghi, PhD, instructor in radiology, was promoted to assistant professor of radiology, Division of Radiological Sciences.

Katie Vo, MD, assistant professor of radiology, was promoted to associate professor of radiology, Division of Diagnostic Radiology.

JOINT APPOINTMENT

Carolyn Anderson, PhD, professor of radiology and of molecular biology and pharmacology, was appointed professor of chemistry, Department of Chemistry.

GRANTS

Maurizio Corbetta, MD, professor of neurology, of radiology, and of anatomy and neurobiology, as coordinator, received a \$4.2 million European Union FPT: Collaborative Projects grant for research on "BrainSynch: large-scale interactions in brain networks and their breakdown in brain diseases." Collaborators for the three-year grant are Gian-Luca Romani, University of Chieti e Pescara, Chieti and Pescara, Italy; Guy Orban and Wim Vanduffel, Katholieke Universiteit Leuven, Flanders, Belgium; Pascal Fries, Radboud University, Nijmegen, The Netherlands; Jean-Philippe Lachaux, INSERM, Lyon, France; Jon Driven, University College of London, England; Gustavo Deco, Universitat Pompeu Fabra, Barcelona, Spain; Milan Palus, Academy of Sciences of the Czech Republic, Praha, Czech Republic; and Andreas Engel, University Medical Center Hamburg—Eppendorf, Hamburg, Germany.

Barry Edwards, PhD, research instructor in radiology, received a three-year Department of Defense Prostate Cancer Research Program New Investigator Award in the amount of \$225,000 for research on "Phage-directed combinatorial chemistry to discover peptides incorporating a radio-metal chelator and a near-infrared dye for optical and PET/SPECT imaging of PSMA."

Debra Gusnard, MD, assistant professor of radiology and of psychiatry, as principal investigator, received a two-year grant from the National Institutes of Health, National Institute on Deafness and Other Communication Disorders, for research on "Neurobiology of affective prosody perception in autism." Coinvestigators for the \$418,000 grant are John Constantino, MD, associate professor of psychiatry and of pediatrics, and Rosalie Uchanski, PhD, research assistant professor of otolaryngology.

Nael Saad, MD, interventional radiology clinical fellow, received a Society of Interventional Radiology Foundation Clinical Fellowship Research Training Program grant for research on "Portal vein embolization for future liver remnant hypertrophy prior to trisegmentectomy: choice of embolic agent." Coinvestigators for the \$10,000 grant are **Christine Menias, MD**, associate professor of radiology; **Thomas Pilgram, PhD**, instructor in radiology; **William Chapman, MD**, professor of surgery; **Steven Strasberg, MD**, professor of surgery; and **Daniel Picus, MD**, professor of radiology and of surgery.

Lawrence Tarbox, PhD, research assistant professor of radiology, received a \$39,644 grant from the National Cancer Institute for "XIP (eXtensible Imaging Platform) clinical research host development."

APPOINTMENTS/ ELECTIONS

Kevin Black, MD, associate professor of psychiatry, of neurology, of radiology, and of anatomy and neurobiology, was appointed to the National Institutes of Health study section, Clinical Neuroscience and Disease (CND-E90s).

Bennett Greenspan, MD, instructor in radiology, was elected to a three-year term on the Board of Directors of the Society of Nuclear Medicine. He was elected to a one-year term as secretary/treasurer of the American Board of Science in Nuclear Medicine.

Jason Lewis, PhD, assistant professor of radiology, was appointed associate editor of the journal *Cancer Research* and was appointed to the Editorial Board of *Current Radiopharmaceuticals*.

Joel Perlmutter, MD, professor of neurology, of radiology, and of physical therapy, was appointed to the Institute of Medicine of the National Academies' Committee on Conflict of Interest in Medical Research, Education, and Practice.

Linda Peterson, MD, associate professor of medicine and of radiology, was elected to the Executive Committee of the Faculty Council of Washington University in St. Louis.

Fred Prior, PhD, research associate professor of radiology, was named chair of the Georgetown University Biomedical Informatics External Advisory Board.

Yoram Rudy, PhD, professor of biomedical engineering, cell biology, and physiology, of medicine, and of pediatrics and research professor of radiology, was elected to a two-year term as president of the Cardiac Electrophysiology Society.

Barry Siegel, MD, professor of radiology and of medicine, was appointed network deputy cochair of the American College of Radiology Imaging Network (ACRIN) Steering Committee. He continues to serve as medical director of the ACRIN PET Core Laboratory.

Jeffrey Zacks, MD, associate professor of psychology and of radiology, was elected to a five-year term on the Governing Board of the Psychonomic Society. He was appointed to a three-year visiting professorship at Northumbria University, Newcastle upon Tyne, England.

HONORS/AWARDS

Louis Gilula, MD, professor of radiology, of orthopaedic surgery, and of plastic and reconstructive surgery, organized and chaired the International Wrist Investigators' Workshop, Seattle, Washington, September 26.

Linda Peterson, MD, associate professor of medicine and of radiology, was moderator for "Meet the Experts: Obesity Management and Heart Disease" at the American Heart Association Annual Scientific Session, Orlando, Florida, November 7.

LECTURES

Carolyn Anderson, PhD, professor of radiology, of molecular biology and pharmacology, and of chemistry, presented "A new generation of radiometal-based radiopharmaceuticals for PET oncological imaging" at the International Conference on Clinical PET and Molecular Nuclear Medicine (PET 2007), Bangkok, Thailand, November 12. She spoke on "Non-invasive imaging of osteoclasts in osteolytic bone metastases" at Vanderbilt University Institute of Imaging Sciences, Nashville, Tennessee, December 7.

Kevin Black, MD, associate professor of psychiatry, of neurology, of radiology, and of anatomy and neurobiology, as invited lecturer, presented "Is psychogenic dystonia a valid diagnosis?" at the First Congress on Controversies in Neurology, Berlin, Germany, September 8.

Jeffrey Brown, MD, professor of radiology, as visiting professor, spoke on "Body MRI: Should it replace CT?"; "MR imaging of cholangiocarcinoma and gallbladder cancer"; and "A physician's guide to financial success" at Michigan State University, East Lansing, September 25. He spoke on "Nephrogenic systemic fibrosis: an overview" at the 19th Annual International Conference on Magnetic Resonance Angiography, Istanbul, Turkey, October 3. Brown presented "Effective investment strategies for physicians, part 1: innovations in finance" and "Effective investment strategies for physicians, part 2: financial planning" at the American College of Radiology Course: Strategies for Professional and Financial

Success from Training to Retirement, Phoenix, Arizona, November 3 and 4. He spoke on "Gadolinium-based contrast media and nephrogenic systemic fibrosis" at Taichung Veterans General Hospital, Taichung, Taiwan, and at the Radiology Society of the Republic of China, Taipei, Taiwan, November 13.

Maurizio Corbetta, MD, professor of neurology, of radiology, and of anatomy and neurobiology, as keynote speaker, presented "Intrinsic brain activity: a key to understand the mind?" at the Italian Society of Neuroscience, Verona, Italy, September 28. He presented "Sense of space and body in rehabilitation" at the James S. McDonnell Foundation Workshop, Cognitive Neuroscience and Rehabilitation: Touch, Space, & Body Awareness, Wellesley, Massachusetts, October 31—November 2.

Colin Derdeyn, MD, professor of radiology and of neurology and neurological surgery, spoke on "The effect of aneurysms, AV malformations, and distal stenoses: the decision to intervene on a bifurcation internal carotid stenosis" and "Intracranial intervention: mainstream or last chance?" at VIVA 2007, Las Vegas, Nevada, September 24 and 25. He presented "Endovascular neuro intervention" at the Comprehensive Brain Anatomy and Neurological Assessment Course, St. Louis, Missouri, November 16.

Louis Gilula, MD, professor of radiology, of orthopaedic surgery, and of plastic and reconstructive surgery, spoke on "Cervical nerve block—approach for safety" at the International Skeletal Society Meeting, Budapest, Hungary, October 11.

Bennett Greenspan, MD, instructor in radiology, presented "Read with the experts—cases in general nuclear medicine" and "Laboratory accreditation—new directives and new directions" at the 29th Annual Meeting of the Missouri Valley Chapter, Society of Nuclear Medicine, St. Louis, October 14.

Jay Heiken, MD, professor of radiology, presented "Optimizing contrast delivery" and participated in a Protocol Panel discussion at MDCT 2007, the Fourth Annual MDCT National Symposium, sponsored by the Society of Body Computed Tomography and Magnetic Resonance, Boston, Massachusetts, September 15 and 16. He presented "Distinguishing benign from malignant liver tumors" and "CT colonography for colorectal cancer screening: current status" at the International Cancer Imaging Society: Meeting and 7th Annual Course, Brugge, Belgium, October 1-3. Heiken spoke on "CT colonography technique" at the 8th International Symposium: Virtual Colonoscopy, Boston, Massachusetts, October 15-17. As visiting professor, he presented "Acute mesenteric ischemia: MDCT evaluation" and "Cystic pancreatic neoplasms: diagnosis and management" at Michigan State University, East Lansing, November 6.

Tamara Hershey, PhD, assistant professor of psychiatry, of neurology, and of radiology, spoke on "Glycemic extremes and the developing brain" at the Emerging Issues in Pediatric Nutrition Symposium, Chapel Hill, North Carolina, December 13.

John Kotyk, PhD, research associate professor of radiology, spoke on "Imaging and translational research at Washington University" at the Joint Molecular Imaging Conference 2007, sponsored by the Academy of Molecular Imaging and the Society for Molecular Imaging, Providence, Rhode Island, September 8. He presented "Imaging biomarkers overview at Washington University" at the IEEE-NIH BISTI Life Science Systems and Applications Workshop 2007: Novel Technologies and Applications of Biomarkers, National Institutes of Health, Bethesda, Maryland, November 8 and 9.

Richard Laforest, PhD, associate professor of radiology, presented "Imaging techniques for imaging dirty PET nuclides" at the University of Missouri, Columbia, October 22.

Jason Lewis, PhD, assistant professor of radiology, spoke on "Cu-ATSM: a radiopharmaceutical for the PET imaging of hypoxia" at Dalton Discussion 10: Applications of Metals in Medicine and Healthcare, University of Durham, United Kingdom, September 3-5.

Robert McKinstry, MD, PhD, associate professor of radiology, spoke on "Imaging of stroke evolution" at the Missouri Society for Radiologic Technologists, 4th District Meeting, St. Louis, September 15. He presented "Improving MRI throughput and workflow" at the Society for Chiefs of Radiology Departments at Children's Hospitals meeting, Chicago, Illinois, October 12.

Yoram Rudy, PhD, professor of biomedical engineering, cell biology, and physiology, of medicine, and of pediatrics and research professor of radiology, presented "Molecular basis of cardiac action potential repolarization" at the Workshop on Regulation of Transport Phenomena in the Cardiac System, Antalya, Turkey, September 16-20. He presented "Noninvasive ECG Imaging (ECGI) for cardiac arrhythmias—status and prospects" at An International Symposium on Ventricular Arrhythmias, sponsored by the University of Pennsylvania School of Medicine, Philadelphia, October 26 and 27. He spoke on "A novel noninvasive imaging modality for cardiac electrophysiology" at the Department of Biomedical Engineering, University of Michigan, Ann Arbor, November 28. Rudy presented "The molecular basis of cardiac repolarization" at the Department of Medicine (Cardiology), Stanford University, California, December 5. He spoke on "Noninvasive electrocardiographic imaging (ECGI) of cardiac electrophysiology and arrhythmia" at the Cardiovascular Institute Seminar, Stanford University, California, December 5, and at the Cardiovascular Research Conference, sponsored by the University of Wisconsin, Madison, December 18. He presented "The molecular basis of cardiac repolarization: mechanistic insights from computational biology" at the Department of Physiology, University of Wisconsin, Madison, December 19.

Barry Siegel, MD, professor of radiology and of medicine, spoke on "Role of PET and PET/CT" and cochaired the Clinical Applications: From Diagnosis to Therapy Session at the 3rd International Meeting of Metabolic PET Imaging for a New Radiotherapy, Reggio Emilia, Italy, September 30 and October 1. As visiting professor, he presented "PET in oncology: monitoring and predicting response to therapy" and "PET and PET/CT in women's cancers" at the A. D. and Ouida Sears Seminar in Radiology: PET and PET/CT in Oncology, sponsored by The Baylor University Medical Center Department of Radiology and Baylor Health Care System, Dallas, Texas, October 23 and 24.

Marilyn Siegel, MD, professor of radiology and of pediatrics, spoke on "CT of adult congenital heart disease" at the American Roentgen Ray Society Course, Cardiac CT Angiography, Minneapolis, Minnesota, September 7 and 8. She presented "Role of CT and MRI in therapy monitoring" at the 3rd International Meeting of Metabolic PET Imaging for a New Radiotherapy, Reggio Emilia, Italy, September 30 and October 1. Siegel spoke on "Pediatric hip sonography," "Pediatric spinal ultrasonography," "Sonography of cystic renal disease," and "Sonography of the pediatric female pelvis" at the Asian Federation of Societies for Ultrasound in Medicine and Biology, Bangkok, Thailand, November 18-20. She presented "CT of congenital heart disease in adults" and "CT of mediastinal vascular anomalies" at the National Diagnostic Imaging Symposium, Orlando, Florida, December 2.

LECTURES

Continued from page 29

Yuan-Chuan Tai, PhD, assistant professor of radiology, presented "Virtual pin-hole PET and its applications" at the Department of Energy (DOE) Workshop on New Frontiers of Science: DOE Fueling the Future of Nuclear Medicine, Cambridge, Massachusetts, September 11.

Lawrence Tarbox, PhD, research assistant professor of radiology, presented "XIP status report and demonstration" at caBIG In Vivo Imaging Workspace Fall Meeting, St. Louis, Missouri, October 11.

Jerold Wallis, MD, associate professor of radiology, presented the Ralph Robinson Memorial Lecture, "Advances in instrumentation," at the 29th Annual Meeting of the Missouri Valley Chapter, Society of Nuclear Medicine, St. Louis, October 13.

SYMPOSIUM

In this section of FYI, only those faculty and staff who have Department of Radiology appointments are listed.

SOCIETY FOR NEUROSCIENCE

*37th Annual Meeting
San Diego, California
November 3-7, 2007*

Todd Braver, PhD, chair, Aging and Cognition.

Bradley Schlaggar, MD, PhD, chair, Development of Cognition.

SCIENTIFIC PROGRAM

Todd Braver, PhD, "Age-related changes in sustained and neural mechanisms of cognitive control in task-switching."

Todd Braver, PhD; Deanna Barch, PhD, "Role of temporo-parietal junction in emotional processing."

Nico Dosenbach; Deanna Barch, PhD; Marcus Raichle, MD; Steven Petersen, PhD; Bradley Schlaggar, MD, PhD, "Using functional

connectivity MRI to study cognitive development: the emergence of distinct task control networks in a typical population."

Nico Dosenbach; Steven Petersen, PhD; Bradley Schlaggar, MD, PhD, "Using functional connectivity MRI to study cognitive development: the abnormal structure of distinct task control networks in Tourette syndrome."

Adrian Epstein; Larry Bretthorst; Joshua Shimony, MD, PhD; Abraham Snyder, MD, PhD; Jeffrey Neil, MD, "Evidence of the sub-ventricular zone in human preterm infants using DTI."

Michael Fox; Daniel Marcus, MD; Abraham Snyder, MD, PhD; Marcus Raichle, MD, "BrainSCAPE: a spontaneous correlation analysis processing environment for fMRI BOLD data."

Denise Head, PhD; Daniel Marcus, MD; Mark Mintun, MD, "Increased CSF tau and p-tau₁₈₁ correlate with brain volume loss in very mild Alzheimer's dementia but not in cognitively normal individuals."

Terrie Inder, MD; Jeffrey Neil, MD, "High resolution MRI changes correlate well with histological changes 24 hours following hypoxic-ischemic in post-natal day 7 mice."

Mark McAvoy, PhD; Linda Larson-Prior, PhD, "Power of ongoing BOLD activity depends on resting state condition."

Francis Miezin; Nico Dosenbach; Bradley Schlaggar, MD, PhD; Steven Petersen, PhD, "A functionally defined network of brain regions differentially active during error responses in humans."

Francis Miezin; Nico Dosenbach; Bradley Schlaggar, MD, PhD; Steven Petersen, PhD, "Defining functional areas in individual human brains using resting functional connectivity."

Steven Petersen, PhD; Bradley Schlaggar, MD, PhD, "Data derived from a large cross-sectional fMRI study of language development predict longitudinal measurements."

Andrew Prantner; Terrie Inder, MD; Jeffrey Neil, MD, "Immediate changes in diffusivity after intracerebral lipolysaccharide injection in rat pups at high magnetic field."

Gordon Shulman, PhD; Maurizio Corbetta, MD, "Discriminant analysis and MANOVA as methods for assessing topographic organization."

Gordon Shulman, PhD; Maurizio Corbetta, MD, "Manipulation of number of distracters and relation between portions of space in a spatial attentional task."



Scott Lecture

On October 25, Mark Mintun, MD, director of Mallinckrodt Institute's Center for Clinical Imaging Research and interim director of the Division of Radiological Sciences, was guest speaker for the Thirty-sixth Annual Wendell G. Scott Memorial Lecture. He spoke on "New horizons for imaging in the diagnosis and treatment of Alzheimer's disease."

Gilbert Jost, MD, director of Mallinckrodt Institute, presented Mintun (right) with a commemorative plaque.



Abraham Snyder, MD, PhD; Marcus Raichle, MD, "A developmental comparison of ventral and dorsal stream function using fMRI."

Sanjeev Vaishnavi; Adrian Epstein; Abraham Snyder, MD, PhD; Joshua Shimony, MD, PhD; Marcus Raichle, MD, "Evaluation of anatomical and functional connectivity following traumatic brain injury in humans."

Tom Videen, PhD; Samer Tabbal; Joel Perlmutter, MD; Tamara Hershey, PhD, "Effect of active contact location and disease asymmetry on cognitive response to STN DBS."

Justin Vincent; Abraham Snyder, MD, PhD; Michael Fox; Marcus Raichle, MD, "Evidence for three distinct bilateral frontoparietal associative brain systems revealed by spontaneous fMRI correlations."

Jinbin Xu; Wenchua Chu, PhD; Zhude Tu, PhD; Suwanna Vangveravong; Lynne Jones; Mark Mintun, MD; Robert Mach, PhD, "Dopamine D₂ and D₃ receptor density in rat striatum as a function of age."

Dongyang Zhang; Abraham Snyder, MD, PhD; Michael Fox; Tracy Nolan; Linda Larson-Prior, PhD; Marcus Raichle, MD, "Subject variability of spontaneous BOLD functional connectivity."

Last year, a partnership established at Washington University in St. Louis combined the top-level expertise of radiologists and cardiologists with the cutting-edge technology of CT and MR imaging. This joint venture created a new imaging group within Mallinckrodt Institute's Cardiothoracic Imaging section. Members of this cardiac imaging team, headed by radiologist Pamela Woodard, MD, and cardiologist Benico Barzilai, MD, participated in the 35th Annual Meeting of the North American Society for Cardiovascular Imaging (NASCI) in Washington, DC. Woodard is president of the NASCI Executive Committee. For more information about the Society, go online at www.nasci.org.

INVITED PRESENTATIONS

Sanjeev Bhalla, MD, Plenary session: Noncoronary Cardiac and Pericardial Imaging in the ED.

Cylen Javidan-Nejad, MD, Cardiovascular Boot Camp: Cardiac and Coronary Artery Anatomy.

Donna Lesniak, RN, Ancillary Staff Symposium: Patient Care in Cardiac Imaging.

Pamela Woodard, MD, Plenary Session: Delayed Contrast-enhanced Differentiation of Non-ischemic Cardiomyopathies.

SPECIAL HONOR

Thomas Todoran, MD, second place in the American Heart Association-sponsored Young Investigator Award Session.

ABSTRACTS

Michael Barry, MD; Joseph Craft, MD; John Mohart, MD; Brian Seeck, MD; Kyongtae Bae, MD, PhD; Robert Gropler, MD; Pamela Woodard, MD, "Use of PET and CT to discriminate between ischemic and non-ischemic cardiomyopathy."

Gautam Singh, MD; Pamela Woodard, MD; Brian Cupps, MD; Michael Pasque, MD; Joseph Billadello, MD; Philip Ludbrook, MD; Michael Beardslee, MD; Charles Canter, MD; Achi Ludomirsky, MD, "Myocardial scarring causes abnormal contractile mechanics in single ventricle after Fontan operation: a new insight by MRI studies."

Gautam Singh, MD; Steven Lorch, MD; Brian Cupps, MD; Deborah Hicks; Michael Pasque, MD; Mark Holland, PhD; Achi Ludomirsky, MD; Pamela Woodard, MD, "Accuracy of myocardial strain measurements in pediatric hearts by 2D speckle tracking echocardiography: a validation study with magnetic resonance imaging."

Thomas Todoran, MD; Peter Rao, MD; Brian Seeck, MD; Michael Barry, MD; Nina Asrani, MD; Donna Lesniak, RN; Thomas Pilgran, PhD; Majesh Makan, MD; Robert Gropler, MD; Pamela Woodard, MD, "Utility of 64-slice multidetector computed tomography for detection of coronary artery atherosclerosis in patients with negative exercise stress echocardiogram."

POSTER


Kristopher Cummings, MD; Sanjeev Bhalla, MD; Cylen Javidan-Nejad, MD; Fernando Gutierrez, MD; Pamela Woodard, MD, "The ABCs of VSDs: understanding ventricular septal defects." —*Bayer Poster Award, Honorable Mention*

IN MEMORIAM

Tom R. Miller, MD, PhD, passed away on Wednesday, October 3, at the age of 63. Although we are personally greatly saddened by Tom's death, the purpose of this remembrance is to celebrate his life. During his illness, Tom showed amazing resilience, overcoming each obstacle as best he could, always with a smile. He was as concerned about how his illness was affecting family and friends as he was about how it was affecting him. Although Tom's life was short, he would be the first to tell you how fortunate he was to have lived such a full life with a wonderful loving family, an exciting profession, and many, many professional and personal friends.

Tom was raised in Lawrenceville, a small town in southeastern Illinois. His father owned an appliance store that, among other things, sold and repaired televisions. This undoubtedly led to Tom's early interest in electronics and science. He earned his undergraduate degree from the California Institute of Technology, Pasadena, in 1966 and his PhD in nuclear physics from Stanford University in 1971. During his college years he became licensed as a civilian pilot. Although he gave up flying in his later years, he remained an aficionado of flight simulators and spent some of his leisure time "flying" on his computer.

After completing his PhD, Tom was awarded a Fulbright fellowship. He spent a year studying nuclear physics in Bombay, India, accompanied by his adventuresome wife, Karen Sue, who is from a small town in Montana. When he



returned from India, he served a year as a National Institutes of Health postdoctoral fellow at the University of Missouri, Columbia, followed by another year at M.D. Anderson Hospital and Tumor Institute, Houston, Texas. It was during this time that Tom decided he wanted to be more directly involved in patient care, so he enrolled in medical school at the University of Missouri, Columbia, in 1973 and received his MD in 1976.

Fortunately for Mallinckrodt Institute of Radiology (MIR), Tom selected Washington University for his combined training in diagnostic radiology and nuclear medicine, which began in 1977. In 1981, he joined the faculty of the MIR Division of Nuclear Medicine, rising to the rank of professor of radiology and of biomedical engineering in 1992.

While at MIR, Tom pursued his passions for research, patient care, and teaching. He was an exceptional individual who excelled in all three of these areas. He had a very successful academic

career that included more than 85 publications and multiple grants. Most recently his research involved the use of PET imaging in patients with cervical or prostate cancer. His expertise in patient care was recognized by his peers. He has been listed in *Best Doctors in America* since 1994.

Over the years, Tom received many honors and awards, including the Vikram Sarabhai Memorial Orator Award,

presented by the Indian Society of Nuclear Medicine, and both the Presidential Distinguished Educator and the Distinguished Service Awards from the Society of Nuclear Medicine (SNM).

Tom's greatest love was teaching. He was the program director of our nuclear medicine residency for many years. One of his favorite responsibilities was to prepare a few comments about each of our residents at the division's annual "graduation" dinner. We were always struck by his kindness and the deep personal connection he made with all of our residents.

You might think that excelling in research, patient care, and teaching was more than enough for one individual, but somehow Tom found time to do many other important jobs, such as being a member—and then chair—of the Nuclear Medicine Residency Review Committee, a member and chair of the American Board of Nuclear Medicine, and the Scientific Program Chair for the SNM. If there is one complaint that we had about

Tom, it is that he made all of the work that he did look so easy. Tom was always calm, collected, efficient, and organized. He had, by far, the cleanest desk in the Division of Nuclear Medicine.

Tom was also a member and served as a deacon of the First Presbyterian Church of Kirkwood. He was an avid reader of politics and history, a classical music lover, and a traveler, visiting all 50 states and more than 30 countries. Tom will be remembered by his family, colleagues, and friends as a gentle, kind, and caring man.


Tom has been an inspiration to others. He inspired his entire family to pursue advanced degrees. Karen Sue has her PhD in psychology; his daughter, Michelle, has her MD; and his son, Daniel, is pursuing a PhD in economics. No one would be surprised that Michelle has chosen a career in radiology and is now doing a neuroradiology fellowship at MIR.

Tom was understandably proud of his family and frequently commented on how fortunate he was to spend so much time with them during the last year of his life.

In the Division of Nuclear Medicine, Tom was an inspiration to all of us—physicians, technologists, scientists, and administrative staff—with his determined and optimistic approach to his serious illness. Few of us could handle similar adversity with Tom's grace and equanimity. We will all miss Tom's cheerful, optimistic, upbeat attitude toward life, a quality that he maintained until the very end. Our sincere condolences go to Tom's wife, his daughter, and son. □

—Henry D. Royal, MD
—Barry A. Siegel, MD

When Chicago's Sears Tower was completed in 1974, it was the world's tallest building (1,457 feet/110 stories). This dramatic shot was taken by Mickey Wynn, manager of the MIR Photography Lab, while she was attending the 93rd annual meeting of the Radiological Society of North America.



FOCAL SPOT

MALLINCKRODT INSTITUTE OF RADIOLOGY AT WASHINGTON UNIVERSITY IN ST. LOUIS

Address Service Requested

POSTMASTER, Send
distribution changes or
address corrections to
Focal Spot editor
Mallinckrodt Institute
of Radiology at
Washington University
Campus Box 8131
510 South Kingshighway Blvd.
St. Louis, MO 63110
(314) 362-2866

Editor and Writer
Vicki Kunkler

Contributing Writers
Mary Jo Blackwood
Candace O'Connor

Photographers
Robert Boston
Kimberly Kania
Tim Parker
Michelle Wynn

Design
Purviance & Company
Marketing Communications

Printing
Bender Inc.

Focal Spot magazine is distrib-
uted three times annually.

www.mir.wustl.edu

© Mallinckrodt Institute of
Radiology, 2007

Non-Profit Organization
U.S. Postage PAID
St. Louis, Missouri
Permit No. 2535

 Washington
University in St. Louis
SCHOOL OF MEDICINE

 Mallinckrodt Institute
of Radiology