

Spring 2004

Focal Spot, Spring 2004

Follow this and additional works at: http://digitalcommons.wustl.edu/focal_spot_archives

Recommended Citation

Focal Spot, Spring 2004, April 2004. Bernard Becker Medical Library Archives. Washington University School of Medicine.


This Book is brought to you for free and open access by the Focal Spot at Digital Commons@Becker. It has been accepted for inclusion in Focal Spot Archives by an authorized administrator of Digital Commons@Becker. For more information, please contact engeszer@wustl.edu.

SPRING 2004

VOLUME 35, NUMBER 1

FOCAL SPOT

MALLINCKRODT INSTITUTE OF RADIOLOGY



Clips & Coils

Treating Brain Aneurysms




The fall/winter 2003-2004 issue of *Focal Spot* provided a glimpse of the construction—an additional underground vault as well as control, computer, equipment, and instrument rooms—underway at the Scott Avenue Imaging Center in preparation for the delivery of a new magnetic resonance scanner. The massive, ultra-high field (11.75-tesla) scanner was recently installed, as shown here, and will aid research in the Biomedical Magnetic Resonance Laboratory.



CONTENTS

FOCAL SPOT
SPRING 2004
VOLUME 35, NUMBER 1



OPTICAL IMAGING: SHEDDING LIGHT ON HIDDEN TUMORS


4

Researchers in the Optical Radiology Laboratory work with high-resolution optical imaging systems interfaced with positron emission tomography, computed tomography, and magnetic resonance to develop better modalities for diagnosing and treating diseases.

IMPROVING THE ODDS FOR SURVIVING LUNG CANCER

8

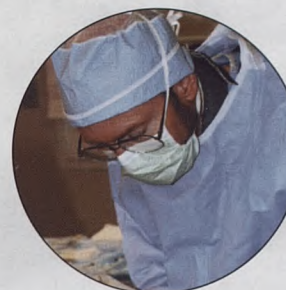A National Cancer Institute-funded multicenter study comparing the effectiveness of spiral computed tomography and chest X-ray screening combined with the investigation of advanced treatment modalities are part of a joint offensive to reduce lung cancer deaths.




CLIPS AND COILS

14

A large-scale study shows that patients with subarachnoid hemorrhage who live in the St. Louis area have a better survival rate because of the number of cases treated at Washington University Medical Center and the expertise of the Medical Center's neuroradiologists and neurosurgeons.



2.....SPOT NEWS




24.....FYI

TRACKING ELUSIVE PROSTATE CANCER

19

Two important nuclear medicine studies are using positron emission tomography and the radiopharmaceutical ^{11}C -acetate to diagnose recurrent prostate cancer and to determine metastases in newly diagnosed, high-risk patients.



Visit the MIR web site at
www.mir.wustl.edu

ON THE COVER Neurosurgeon Ralph Dacey and Interventional Neuroradiologist DeWitte Cross offer a joint approach to treating subarachnoid hemorrhage by using surgical and endovascular techniques. Photography by Tim Parker.


SPOT NEWS

36th Wilson Award presented

Kelsey Moran, a fourth-year Washington University in St. Louis medical student, received the 2003-2004 Hugh M. Wilson Award for Meritorious Work in Radiology. The award has been presented for 36 years in honor of Doctor Wilson, Mallinckrodt Institute's second director and an advocate of the advancement of education.

During his radiology rotation, Moran worked with Sanjeev Bhalla, MD, assistant professor of radiology and codirector of body computed tomography, on a compilation of "CT findings in unilateral Glenn/Fontan mimicking pulmonary embolisms." The manuscript detailed the difficulties encountered in using computed tomography (CT) to detect emboli in the pulmonary arteries—because of the location in the small or medium pulmonary arteries—of patients who have had a Glenn shunt inserted or have undergone the Fontan procedure to treat tricuspid atresia, a congenital heart disease.

According to Fernando Gutierrez, MD, professor of radiology, Moran demonstrated "his ability to work with other departments and come up with joint research. He worked with Doctor Ludbrook [Philip Ludbrook, professor of medicine and of radiology, and director of the Center for Adults with Congenital Heart Disease], putting together the necessary clinical data for the manuscript, and required very little supervision in getting the task done."



New MRI textbook available

Practical Guide to Abdominal & Pelvic MRI, a new textbook published by Lippincott Williams & Wilkins, is a handy reference for practicing radiologists, for residents preparing for board examinations, and for MRI technologists. According to coauthors Jeffrey Brown, MD, associate professor of radiology and codirector of magnetic resonance imaging (MRI), and former Mallinckrodt Institute Alumnus John Leyendecker, MD, assistant professor of radiology, Wake Forest University Baptist Medical Center, Winston-Salem, North Carolina, the book is a "see what you can do" rather than a "see what we can do" reference.

The 268-page book contains concise descriptions, high-quality illustrations, and the most common clinical cases encountered in daily practice. Its four sections cover essential physical principles, reviews of specific abdominal and pelvic MRI examinations, common differential diagnoses and aids for interpreting preoperative imaging studies, and abdominal and pelvic MRI anatomy reviews. Also included are sections covering MRI anatomy, terminology, and frequently asked questions.

WUSM retains national ranking

According to a *U.S. News & World Report* survey released April 2, 2004, Washington University in St. Louis School of Medicine (WUSM) ranked second in the nation—for the second consecutive year. Harvard University took first-place honors; following WUSM were Johns Hopkins University, Duke University and the University of Pennsylvania (tie), the University of California-San Francisco, and the University of Michigan.

U.S. News & World Report initiated the professional and graduate school rankings in 1987. WUSM annually has placed in the top 10 schools and, since 1998, has ranked first in student selectivity. WUSM departments and programs also earned high marks: physical therapy program ranked second; occupational therapy, third; pediatrics and medicine, seventh. A complete listing is online at news-info.wustl.edu/rankings.

Journal honors MIR reviewers


Since 1985, the Editorial Board of *Radiology*, a leading scientific journal, annually has honored the most prolific manuscript reviewers. The recipients of the 2003 Editor's Recognition Awards were announced in the journal's April 2004 issue. Among the recipients were the following MIR faculty:

With Special Distinction

- Louis Gilula, MD, professor of radiology, of orthopaedic surgery, and of plastic and reconstructive surgery

With Distinction

- Kyongtae Bae, MD, PhD, assistant professor of radiology and of biomedical engineering
- David Rubin, MD, associate professor of radiology.



Carlos Perez, MD

Perez named Radiation Oncology Teacher of the Year

The radiation oncology residents annually select the Teacher of the Year recipient by nominating and voting for the faculty member who makes a significant contribution to radiation oncology resident education during the academic year. The award traditionally is presented each year in December.

Carlos Perez, MD, professor of radiation oncology and chairman of the Department of Radiation Oncology, was selected as the 2003 Teacher of the Year. This is a special honor for Perez, as he also received the award in 1990.

He joined the MIR faculty in 1964 and was named director of the Radiation Oncology Center in 1976. In June 2001, he was named chairman of Washington University's newly formed Department of Radiation Oncology.

Perez is one of the world's most highly regarded radiation oncologists and has received many honors in recognition of his scientific contributions, including Gold Medal awards from the American College of Radiology, the American Society for Therapeutic Radiology and Oncology, and CRILA/Circulo do Radioterapeutas Ibero-Latinoamericanos, as well as the American Radium Society's Janeway Medal. He is coeditor of the textbook *Principles and Practice of Radiation Oncology*, now in its fourth edition and hailed as "the most comprehensive textbook of radiation oncology available."

Perlmutter receives honors

Joel Perlmutter, MD, professor of neurology, of neurological surgery, and of radiology, was named to the 2004-2005 Marquis® *Who's Who in Medicine and Healthcare*. The Marquis Who's Who biographical series has been published since 1989, and the medicine and healthcare vol-

ume provides information on the field's successful educators, researchers, clinicians, administrators, and industry leaders. Perlmutter, who heads the Department of Neurology's Movement Disorder section, is a nationally recognized expert in the study of physical and chemical factors associated with Parkinson disease and dystonia.

In April 2004, Perlmutter received the Mentor Award, presented by the Washington University in St. Louis School of Medicine's Academic Women's Network. The award has been presented annually since 1994 to faculty members who have served as outstanding mentors to the University's female faculty members or trainees.

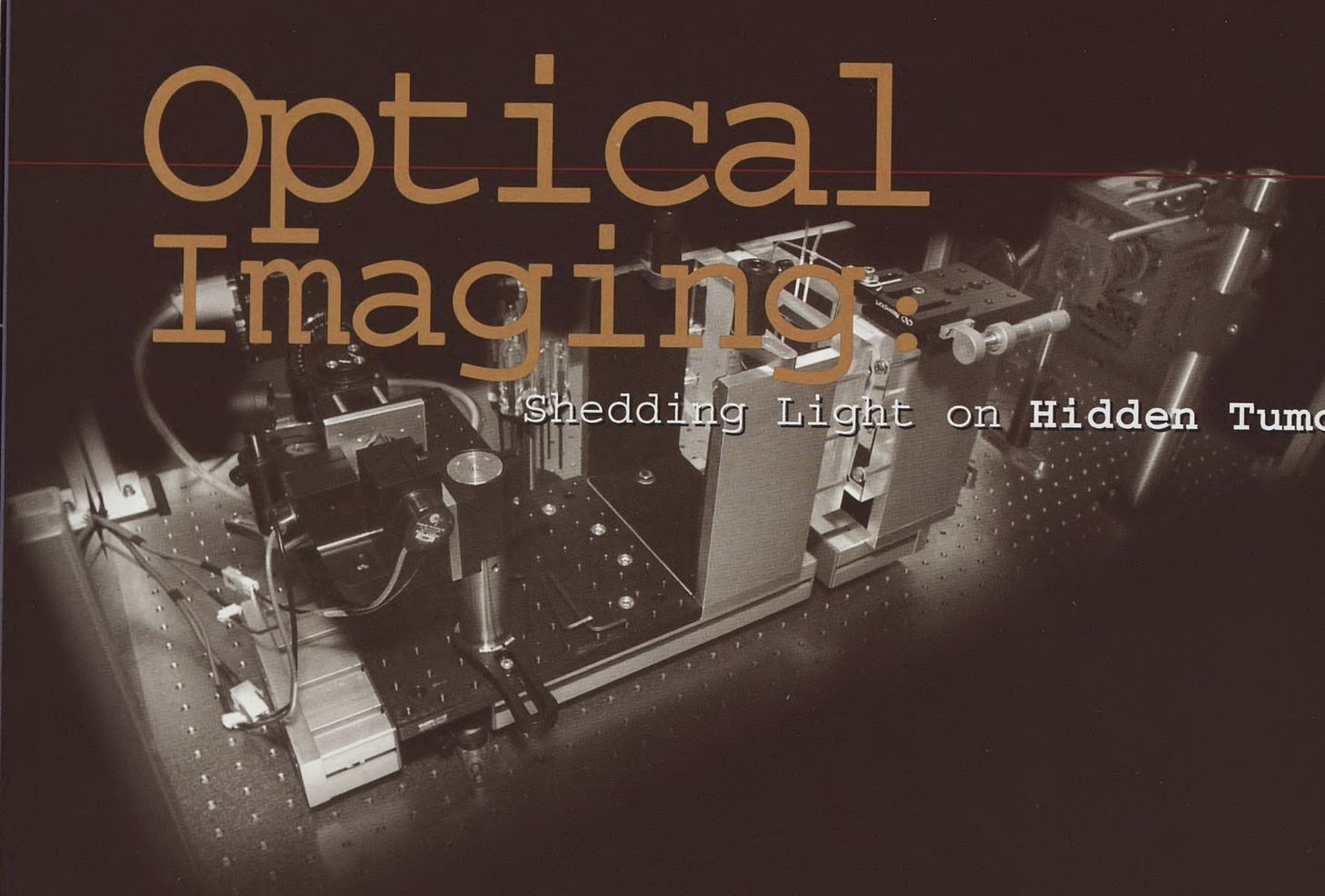
Society's Annual Meeting to be in St. Louis

The Society for Molecular Imaging (SMI), an international scientific education organization, will hold its third annual meeting September 9-12, 2004, at the Adam's Mark Hotel in St. Louis. The key focus of the meeting is new insights into mammalian biology acquired through imaging. Other topics include advanced molecular imaging approaches in biology and medicine, advances in positron emission tomography and single photon emission computed tomography, optical tomography and low-light imaging, and research and industrial collaborations. Early discounted registration rates are available on or before July 9, 2004. Register online (with credit card) at www.molecularimaging.org, or call (650) 216-6621 for more information.

David Piwnica-Worms, MD, PhD, professor of radiology and of molecular biology and pharmacology, is SMI president and chairman of the meeting. Joseph Ackerman, PhD, professor of chemistry, of medicine, and of radiology, and chief of the biomedical magnetic resonance imaging laboratory, and Michael Welch, PhD, professor of radiology, of chemistry, and of molecular biology and pharmacology, and cochief of the Division of Radiological Sciences, are meeting cochairmen.

Matching Program results announced

In June, 19 physicians will begin their first year of training in diagnostic radiology. These promising trainees come to MIR from excellent medical schools: Emory University (2); Harvard University (2); New York University (1); University of California, San Francisco (1); University of Iowa (1); University of Louisville (1); University of Pennsylvania (2); University of Washington (1); University of Wisconsin (1); Washington University in St. Louis (6); Yale University (1).



Optical Imaging:

Shedding Light on Hidden Tumors

THE LIGHT WE DON'T SEE CAN SAVE OUR LIVES.

It's absolutely amazing what we can do with light. In the visible light range, 400 to 750 nanometers (1 billionth of a meter), humans have body tissues that attract and absorb light: melanin, proteins, and oxyhemoglobin. This propensity for selective tissue absorption has led to the development of lasers for hair removal, spider vein dissolution, treatments for the rosacea "blush" of adult acne, and even removal of age spots—all very popular procedures with people needing these services. While these breakthroughs are valuable in themselves, light and optical imaging have now moved into important diagnostic and therapeutic realms.

■ BY MARY JO BLACKWOOD, RN, MPH, CHES ■

Near-Infrared Imaging

To look deeper into our bodies for the secrets of diagnostic and healing applications, we have to move away from the visible light range, away from the surface attractants. Samuel Achilefu, PhD, is interim chief of the Optical Radiology Laboratory at Mallinckrodt Institute of Radiology (MIR). His work revolves around the diagnostic applications of the near-infrared spectrum of light in the 750 to 900 nanometer range.

Researchers in the Optical Radiology Laboratory (ORL), established in 1999, work with high-resolution optical imaging systems. "We are gradually assembling the personnel and equipment we need. It takes a combination of several different technologies," says Achilefu, an associate professor of radiology. "Using optical spectroscopy in the visible wavelengths, we can penetrate only a few millimeters into tissues. However, when we perform optical imaging through diffused optical tomography, we can delve several centimeters into tissue, depending on the instrument and methodology."

In biological systems, researchers have found that light absorption and scattering are, in the right interpretive modes, indicative of physiologic states. Research on the brain with optical imaging has shown that hemoglobin spectroscopy of the different brain regions can reveal internal bleeding caused by head injury. In the breast, increased blood volume or vascularity can pinpoint tumors.

To look **deeper into our bodies...** we have to move away from the visible light range, away from the surface attractants.

How Optical Imaging Works

As Achilefu explains, light scatters when it hits tissue. Computer algorithms can correct for the scattering. An algorithm is a formula or set of rules for solving a particular problem—in this case, where the light would have gone had it not scattered. Using these algorithms to reconstruct the path of light after scattering can create slices of tissue as would a computed tomography (CT) scan or a magnetic resonance imaging (MRI) scan.

"The optical methods are highly sensitive and can detect minute

amounts of light-sensitive materials. In this lab, we are developing a state-of-the-art diffused optical tomography, or DOT, system and molecular beacons to use as a contrast agent for optical imaging. We now have the ability to study brain function, angiogenesis, and protein expression in tumors as well as metastases," says Achilefu.

As principal investigator, Achilefu received a National Institutes of Health-funded project to interface optical imaging and positron emission tomography

■ ■ ■ ■ ■
(Left to right) Researchers Sachin Patwardhan, Sharon Bloch, and Joseph Culver are shown with a diffused optical tomography (DOT) system developed and built in the Institute's Optical Radiology Laboratory.



Optical Imaging

(PET) imaging into a hybrid technology. Barry Siegel, MD, chief of the Division of the Division of Nuclear Medicine, and Michael Welch, PhD, cochief of the Division of Radiological Sciences, are active collaborators on the research. "We still have the problem of localization in deep tissue by optical methods. That's where PET comes in," says Achilefu. "We use PET to map the area to get a baseline. Then we can monitor the status of the disease by optical methods, picking up fluorescent traces

in the near-infrared region after the PET radioisotope decay. An advantage of optical imaging is that it is nonionizing, or nonradioactive."

Another promising interface is between CT or MRI scanning and optical imaging. CT has a high structural resolution; optical imaging delivers high functional information. According to Achilefu, CT will be performed in conjunction with optical imaging soon in humans. The imaging techniques scan the same tissue but are asking different questions. "CT asks where the margins of the tumor are. Optical interrogates the functional status of the cells at the margins. When patients with cancer are treated, we sometimes have to wait for months to observe the effectiveness of the treatment regimen, which can be manifested by reduction in tumor size, as evidenced by MRI or CT scans," says Achilefu. "Within days, optical imaging can detect the response of tumors to treatment. We can see—or not see—changes within weeks instead of months, which speeds up the process of finding effective interventions."

The Future of Optical Imaging

On a list of potential applications for optical imaging are brain function and cervical, colon, gastrointestinal (GI), prostate, and breast cancer, which present viable targets by non-invasive DOT or endoscopy. "Noninvasive breast imaging or spectroscopy in the NIR [*near-infrared*] wavelengths is particularly attractive; because of the breast's anatomy, a probe can be placed around it and illumination can be obtained from multiple directions: up, down, side-to-side, frontally. We can triangulate images and get much better three-dimensional identification," explains Achilefu. "In contrast, imaging deep organs noninvasively, such as the liver, is a challenge because of the attendant poor image resolution that results from multiple light scattering in deep tissues. We currently cannot scan different views of such organs by optical methods. Researchers in the ORL are working now on validation studies using small animals. In two years, we hope to be doing clinical testing with patients."

According to Achilefu, unlike MRI or PET, which use radioactive tracers, optical equipment does not. "Optical imaging can be performed safely in a physician's office and organ function can be monitored in real time. It is an exciting area."

He is especially interested in combining the diagnostic and therapeutic potential of optical methods. "Optical methods give us the opportunity to 'see and treat' diseases. The treatment arises from substances that are triggered by light to destroy only the diseased cells where it is



Samuel Achilefu is shown in the Optical Radiology Laboratory, in an area where researchers work on systems to combine magnetic resonance and optical imaging.

localized," says Achilefu. "This approach is called photodynamic therapy. In the ORL, we are developing these dual-role materials, which can be used to perform both imaging and treatment. I call these drugs 'diapeutics,' an acronym for combining diagnostic and therapeutic effects into one drug."

"The longer the wavelength, the lower the energy," he adds. "Diapeutics have two components that can absorb two different wavelengths. Activation of the drug at a longer wavelength helps the physician discern the exact nature of the problem without distracting surface absorptions. Then the light of a shorter wavelength can be used to treat the diseased tissue, working by photosensitive molecular excitation. Light of the appropriate wavelength produces free radicals that are toxic to surrounding cells. At some point, we will be able to do diagnosis and treatment by optical methods alone."

In the field of biological imaging, Mallinckrodt Institute's ORL is moving toward complete integration of multiple modes of imaging. Joseph Culver, PhD, an expert in DOT, recently joined the ORL and will play a vital role in the development of highly sensitive DOT systems. **MMR**

Achilefu and his colleagues are closely watching research at Johns Hopkins and Clemson universities where light absorbing and scattering parameters are being used as a noninvasive approach to distinguishing between breast cancers and benign tumors like fibroadenomas. Watch for more information in upcoming issues of *Focal Spot* magazine.

A closer look at the prototype DOT system to detect brain function and certain types of cancer.

Biomed 21

The ORL will play a major role in Biomed 21, Washington University School of Medicine's strategic plan for developing a multidisciplinary approach to basic and clinical research. Named for its potential for advancing research and clinical practice in the 21st century, BioMed 21 will include components such as the Genome Sequencing Center, The Genome Sciences and Human Genetics Program, the Division of Clinical Sciences, and the Center for Biological Imaging—where the ORL will shine.

Optical Imaging Laboratory

Samuel Achilefu, PhD, associate professor of radiology
and interim laboratory chief

Mikhail Berezin, PhD, research associate

Sharon Bloch, PhD, research associate

Joseph Culver, PhD, assistant professor of radiology


Kexian Liang, research technician

Nancy North, secretary

Sachin Patwardhan, PhD, research associate

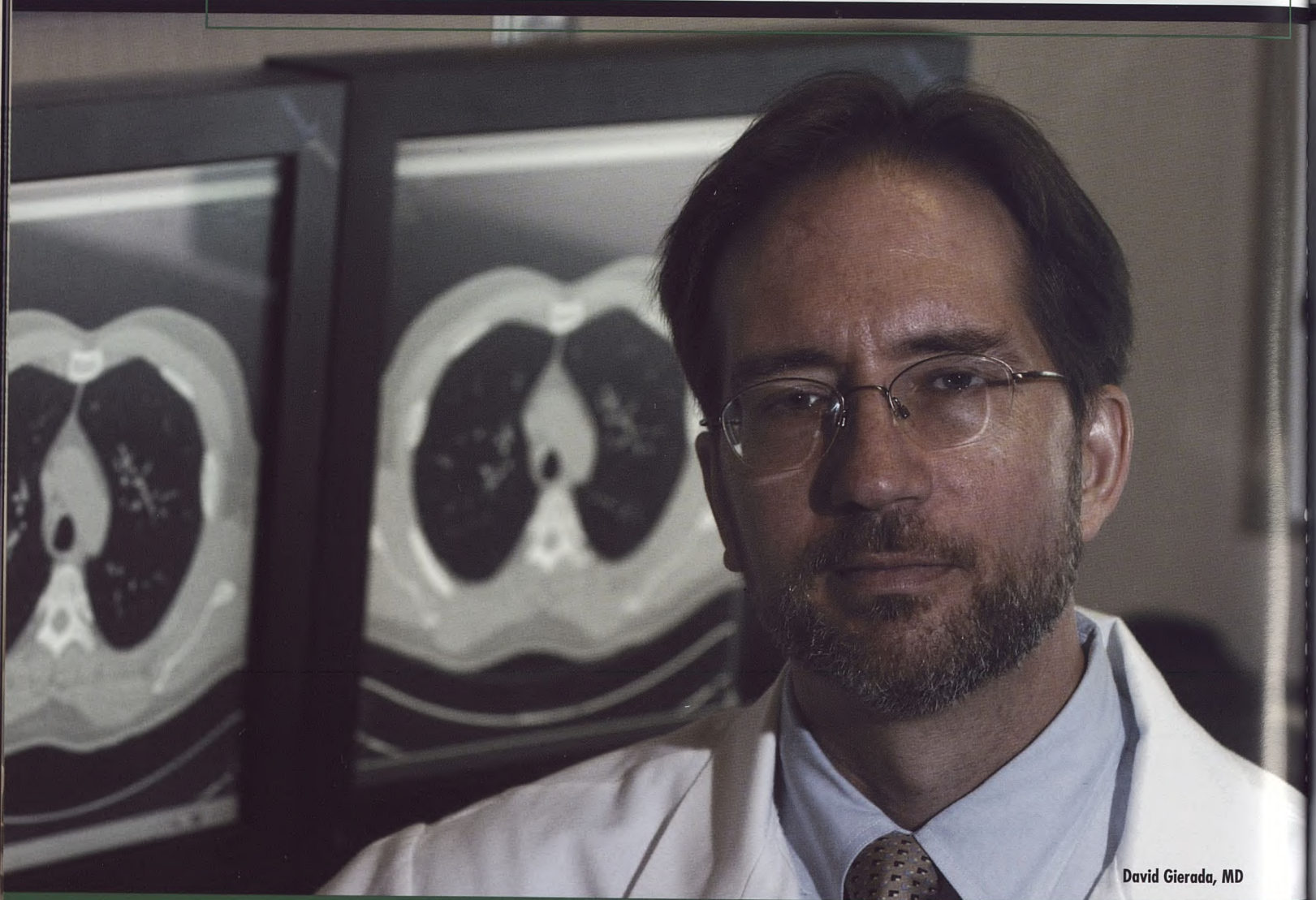Yunpeng Ye, PhD, research associate

Zongren Zhang, PhD, research associate



Improving the Odds for Surviving Lung Cancer

IMAGING AND COLLABORATION ARE KEY TO IMPROVING SURVIVAL RATES



David Gierada, MD

BY MARY JO BLACKWOOD, RN, MPH, CHES

THE TECHNOLOGY-FUELED WAR AGAINST LUNG CANCER IS HEATING UP.

UNLIKE MANY OTHER CANCERS, ITS DEATH RATES HAVE NOT DECLINED. REDUCING THE TOLL OF THIS DEVASTATING DISEASE CAN ONLY HAPPEN WITH A JOINT OFFENSIVE IN DIAGNOSIS AND TREATMENT. MALLINCKRODT INSTITUTE OF RADIOLOGY (MIR) AND THE DEPARTMENT OF RADIATION ONCOLOGY ARE PARTNERS IN THIS FIGHT, EACH CONTRIBUTING RESEARCH AND CONSULTATION TO THE OTHER FOR ENHANCED RESULTS.

IMPORTANCE OF EARLY DETECTION

Experience tells us that the earlier a catastrophic condition is detected, the more treatable it is and the better the outlook for cure. The rub comes in how we define "early." Concerning lung nodules, early can have several meanings: still small in size, confined to one area, or at an early stage. In 15 percent to 30 percent of the cases, by the time symptoms have led to detection, the cancer has already spread outside the lung.

NATIONAL LUNG SCREENING TRIAL

The National Lung Screening Trial (NLST) began in 2002, with a goal of comparing spiral computed tomography (CT) and chest X-ray screening for their effectiveness in reducing deaths from lung cancer. The NLST involves 30 sites across the country and combines data collected from the Prostate, Lung, Colorectal and Ovarian (PLCO) trial network that started 10 years ago and the American College of Radiology Imaging Network (ACRIN).

David Gierada, MD, an associate professor of radiology with expertise in chest radiology and CT imaging, is coprincipal investigator for the NLST at Washington University in St. Louis. He reports that the enrollment of 50,000 former or current smokers nationally was reached in February 2004—more than six months ahead of schedule. The St. Louis site has 3,800 participants enrolled.

Eligible participants are randomly assigned to receive either a chest X ray or a spiral CT scan. They receive an initial screening, with a repeat screening at years one and two. Then participants will receive follow-up tracking through 2009.

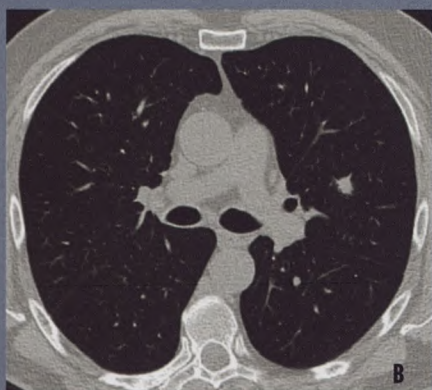
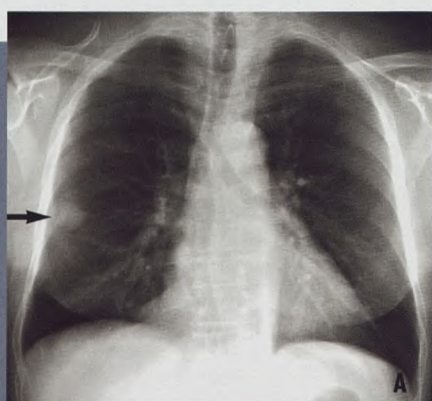
"Spiral CT allows identification of lung nodules at a smaller size than a chest X ray does, but we don't know whether these patients will survive longer. We expect the smaller tumor to be more treatable," says Gierada. "However, not all small tumors exhibit the same behavior. Some small tumors can spread early. Other tumors have a very slow growth rate; so even if they go undetected, they may not result in the patient's death, analogous to what is often observed with prostate cancer.

In addition to tumor size, the study gathers data on nodule characteristics and the staging of known cancers, which takes into account not only tumor size but lymph node involvement and any detected distant metastases. The higher the stage, the worse the survival outlook. Given all those tumor variables, and the fact that only a small percentage of NLST participants are expected to die from lung cancer during the course of the study, the NLST is looking for data from the 50,000 participants to determine whether one type of screening is more effective than the other at reducing lung cancer deaths.

In the NLST, if participants have positive screenings (defined as a nodule equal to or greater than 4 millimeters) that information is given to the patients and their primary physicians with recommendations for follow-up care. Unanswered questions still exist because most nodules are not cancerous. All positive test results are followed up to determine outcome. One option for patients is to be seen in the Surveillance of Pulmonary Indeterminate Nodules (SPIN) clinic. Patients may self-refer or be referred by their attending physicians. Nearly half of the

Improving the Odds for Surviving Lung Cancer

SPIN clinic patients come from the NLST. Patients are seen by Washington University thoracic surgeons and advanced nurse practitioners experienced in dealing with the issues. "We can do further testing with a variety of radiological techniques to help distinguish malignant tumor from benign nodule. If the nodule is cancerous, we assist in staging and identifying the appropriate treatment options," says Gierada.



Screening chest radiograph (Fig. A) and low dose CT scan (Fig. B) show lung cancers detected in two National Lung Screening Trial participants at Washington University in St. Louis. The right lung lesion on the chest radiograph measures 2 cm in diameter; the left lung lesion on the CT scan measures 1 cm in diameter.

Study participants return annually for screening and/or to update their medical history: What they did about the test's positive results, whether follow-up care resulted in a diagnosis of lung cancer, and what treatment they had. In addition to detecting cancer early, an important objective of the study is to minimize the number of procedures done on benign lesions.

There are additional benefits of the NLST. All the generated data can be used to determine what features of the identified nodules make them more or less likely to be malignant, such as the behavior of different sizes and shapes of nodules in different parts of the lung. The CT image data will be available to researchers through a centralized library, containing all CT scans performed at PLCO screening centers, and will be located and managed in MIR's Electronic Radiology Laboratory.

COORDINATION OF DIAGNOSIS AND TREATMENT

For patients who are diagnosed with lung cancer and will be treated at the Washington University Medical Center, a multidisciplinary group meets weekly to discuss possible treatment plans. Thoracic surgeons, medical oncologists, pathologists, radiation oncologists, and diagnostic radiologists all collaborate. When a case is presented, all group members contribute their data and discuss appropriate treatment. Diagnostic radiology plays an important role in helping to stage a tumor by employing a variety of techniques and directing treatment options.

IF THE NODULE IS CANCEROUS, WE

ASSIST IN STAGING AND
IDENTIFYING THE APPRO
PRIATE TREATMENT OPTIONS.

TREATING LUNG CANCER


The second critical piece in the war on lung cancer is the advancement of treatment modalities, particularly in the area of radiation therapy. According to Jeffrey Bradley, MD, assistant professor of radiation oncology, most patients with lung cancer benefit more from surgery. If the tumor is not operable, then radiation treatment is increasingly a good choice. Approximately three fourths of patients with lung cancer will need radiation treatment, with or without surgery. The Department of Radiation Oncology offers the latest in imaging and treatment for lung cancer. Three-dimensional conformal radiation therapy (3D-CRT), using a combined positron emission tomography (PET) and CT scanner, allows clinicians simultaneously to localize and target lung cancers more accurately and to deliver more effective doses of radiation to the tumor, while sparing adjacent healthy tissue.

CAD Differentiates Lung Nodules

"PET/CT is ideal for radiation planning," says Bradley, who sees patients at Siteman Cancer Center in the Center for Advanced Medicine. "Before three-D-CRT technology, treatment was more for symptom control than for cure. Parts of the tumors often received lower doses of radiation in order to spare healthy tissue nearby. We've found that since the development of three-D conformal therapy in the 1990s, delivery of radiation specifically to the tumor has been improved. And with small inoperable tumors, we may be achieving a higher cure rate, which has led to more aggressive treatment."

Bradley is basing this information on his retrospective study of 207 patients treated at Washington University Medical Center with 3D-CRT between 1991 and 1998. "For a patient with lung cancer whose tumor isn't treated with surgery, the traditional staging system may not be the right approach. Based on our findings, total tumor volume may be more important," he says.

Tumor volume refers to the total size of the tumor and any affected lymph nodes. When the study data was analyzed, age, tumor stage, and any adjunct chemotherapy were dropped out of the equation, leaving total tumor volume. The average survival rate for the 207 cases with



Ty Bae, MD, PhD

At Mallinckrodt Institute of Radiology, computer-aided diagnosis (CAD) is being used to aid in the automated detection and characterization of lung nodules and focal ground-glass opacities [*nonsolid opacities*]. Ty Bae, MD, PhD, associate professor of radiology, is at the forefront of this research. He sees CAD as an aid to the skilled radiological practitioner, contributing in four main areas to lung cancer diagnosis:

> **Computer algorithms simulate the human detection process.** The algorithm is a set of rules or steps a programmer designs, a decision tree that allows the program to do the job it is designed to perform. Says Bae, "There are certain radiological tasks that computers can do better than humans, like measuring area and volume, and having an almost unlimited ability to remember numbers and images from a previous study for comparison to the current study. But beyond that, the experienced radiologist is probably better overall at performing most diagnostic tasks."

> **Consistent performance.** Even skilled radiologists have a fatigue factor when going through hundreds of images to detect small modules. "If a radiologist reviews twenty cases in a day, he or she has to scrutinize a couple thousand images and has to detect and document nodules and other findings seen in each image. With CAD integration, the computer can help flag and document nodules for the radiologists, thus improving their diagnostic performance and work flow. The computer has been over ninety percent successful in identifying very small lesions, and it has no fatigue factor," says Bae.

The lung is a unique organ because it is full of air, which provides a good contrast to soft tissue. Within the lung tissue, structures are either vessels or nodules. "With CT scans, we are looking at very thin cross-sectional slices of the chest cavity. The pulmonary vessels are typically perpendicular to the image plane. On each image, a nodule is round, and so is a cross section of an artery. We differentiate the nodule and vessel by visually examining the structural continuity between adjacent slices. Our CAD system can easily track lung structures and evaluate their three-dimensionality mathematically, separating the nodules from the vessels over multiple slices," explains Bae.

> **Nodule characteristics.** Says Bae, "After a nodule is identified, then we must determine the characteristics that make it more or less likely to be cancerous. For instance, we look at calcification. If the nodule is completely calcified, it is benign. Unfortunately, most nodules are indeterminate without definite morphologic signature, so we repeat the CT scan after some time interval to follow their growth pattern. Rapid growth usually means cancer. The CAD program measures the difference in nodule volumes between the initial and follow-up CT scans and may detect early growth not obvious to the human eye—then the radiologist can act on it more quickly."

> **Reporting speed.** "After the detection, CAD can facilitate reporting the three-dimensional location and volume over many slices, time and time again—much more quickly than a human can," says Bae.

Bae and his research team is currently developing the tools needed for small-scale clinical studies at Mallinckrodt Institute in 2005 to evaluate the utility of CAD for improving the detection of lung nodule and focal ground-glass opacities.

Improving the Odds for Surviving Lung Cancer

all tumor sizes treated with 3D-CRT was 59% after one year and 41% after two years. Patients with tumor volumes of three cubic centimeters or less had a tumor-specific survival rate of 78% for both year one and year two, as compared with 51% after year one and 29% after year two for those patients with the largest tumors.

Bradley's study indicated that 3D-CRT may be a good alternative for patients whose tumors could be surgically treated but for whom surgery itself would be risky. It also suggested that patients with large tumors should be treated less aggressively, using radiation for symptom control.

Another treatment that shows great promise, according to Bradley, is the use of stereotactic high-dose radiation for patients who are prescribed a combination of surgery and radiation. Stereotactic radiation involves a number

MOST PATIENTS WITH LUNG CANCER BENEFIT MORE FROM SURGERY. IF THE TUMOR IS NOT OPERABLE, THEN RADIATION TREATMENT IS INCREASINGLY A GOOD CHOICE.

APPROXIMATELY THREE FOURTHS OF PATIENTS WITH LUNG CANCER WILL NEED RADIATION TREATMENT, WITH OR WITHOUT SURGERY.

of precisely aimed beams of ionizing radiation—each coming from different directions and meeting at a specific point—to deliver the radiation dose. “In order to deliver a stereotactic dose, lung movement during breathing must be controlled. The Department of Radiation Oncology has new equipment that immobilizes the chest and allows only shallow breathing for a short period. We plan to start treating patients with this technique soon, but still utilize the targeted three-D-CRT approach. It's the

most technologically advanced form of three-D-CRT,” he says.

Physicians in Japan and Germany have been using the technique for five years, and the reports are encouraging. “Physicians at the University of Indiana and at other medical facilities have begun treating patients with this technology. The Radiation Therapy Oncology Group (RTOG) is starting a long-term trial involving ten to twenty institutions to track the procedure's effectiveness,” says Bradley, who received his 3-D training in Germany.

Other areas being explored are 4D-CT simulations that control lung motion during breathing and can deliver a burst of radiation during the same position in the respiratory cycle. Says Bradley, “Everything we do in the Department of Radiation Oncology is based on imaging.”

Add the early detection technology being investigated at Mallinckrodt Institute of Radiology to the Department of Radiation of Oncology's image-based treatment modalities, and this war on lung cancer could be won. **MIR**



Jeffrey Bradley, MD

Facts, Figures, and Resources

- > Lung cancer is the leading cause of cancer death in both men and women in the United States.
- > Lung cancer is the **most preventable** type of cancer.
- > Smoking cigarettes, cigars, or a pipe is the **number one cause** of lung cancer; smoking accounts for 87% of lung cancers. The longer a person has smoked and the more cigarettes smoked per day, the greater the risk of developing lung cancer.
- > The incidence for lung cancer in African-American males is approximately **50 percent higher** than in their white counterparts; the death rate is 27 percent higher.
- > An estimated **174,000 people** in the United States will be newly diagnosed with lung cancer in 2004.
- > An estimated **160,000 people** in the United States will die from lung cancer in 2004—approximately 92,000 males and 68,000 females.
- > There are two major types of lung cancer: **non-small cell** (more common, usually metastasizes more slowly) and **small cell** (also called oat cell). Small cell lung cancer accounts for approximately 20 percent of all lung cancers and is usually caused by smoking.
- > Depending on the type and stage, lung cancer is usually treated by surgery, radiation therapy, or chemotherapy—**either alone or in combination**.
- > The number of Americans getting **lung cancer is decreasing**, primarily due to the decrease in adult smoking over the past 30 years.
- > Smoking among teenagers and adolescents has **increased in recent years**. The increase can cause a potential rise in lung cancer incidence in future years as this population ages.
- > Early-stage lung cancer **usually does not cause symptoms**. The following symptoms may occur but may not indicate lung cancer and could be signs of a less serious disease. If you do have these symptoms, see your physician for a proper diagnosis.
 1. chronic cough
 2. repeated bouts of pneumonia or bronchitis
 3. hoarseness
 4. weight loss/loss of appetite
 5. shortness of breath
 6. wheezing
 7. chest pain
 8. coughing up blood
- > **Risk factors** for lung cancer include tobacco use, secondhand smoke, personal and family history, gender, and cancer-causing agents such as arsenic, asbestos, or radon.

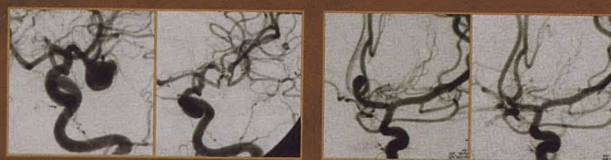
This information was excerpted from several sources, including the American Cancer Society and the American Lung Association. If you would like to read more about lung cancer, check out the following web sites:

American Cancer Society—www.cancer.org
Alliance for Lung Cancer, Advocacy, Support & Education—www.alcase.org
American Lung Association—www.lungusa.org
American Medical Association—www.ama-assn.org
National Cancer Institute—www.nci.nih.gov
National Heart, Lung, and Blood Institute—www.nhlbi.nih.gov/index.htm

Clips & Coils

High-volume centers show results in treatment of SAH.

by ANNE KESSEN LOWELL



Subarachnoid Hemorrhage [SAH] CAN BE A VIOLENT ASSAILANT. TYPICALLY CAUSED BY A RUPTURED ANEURYSM—A WEAK SPOT IN A BRAIN BLOOD VESSEL THAT BLEEDS INTO THE SPACE BETWEEN THE BRAIN AND SKULL—SAH AFFECTS THOUSANDS OF AMERICANS EACH YEAR AND, IN MANY CASES, RESULTS IN DEATH OR PERMANENT BRAIN OR NERVE DAMAGE.

A LARGE-SCALE STUDY LED BY DEWITTE CROSS, MD, ASSOCIATE PROFESSOR OF RADIOLOGY, OFFERS NEW HOPE TO PATIENTS WITH SAH, ESPECIALLY THOSE LIVING NEAR “HIGH-VOLUME” MEDICAL CENTERS. AS IS TRUE WITH MANY TYPES OF MEDICAL AND SURGICAL PROCEDURES, THE MORE SAH CASES TREATED AT A FACILITY, THE BETTER THE OUTCOMES TEND TO BE. BUT CROSS, WHO IS DIRECTOR OF INTERVENTIONAL NEURORADIOLOGY AT MALLINCKRODT INSTITUTE OF RADIOLOGY, AND THE MULTIDISCIPLINARY STUDY TEAM WERE STRUCK BY THE DRAMATIC IMPROVEMENT IN SAH-RELATED MORTALITY RATES BETWEEN HIGH-VOLUME AND LOW-VOLUME CENTERS.

Study results

In a retrospective study of more than 16,000 hospital admissions for SAH in 18 states, the researchers concluded that hospitals treating more than 35 SAH cases per year had a 40 percent lower mortality rate than did those hospitals treating less than 10 cases. And this is good news for St. Louis area-residents: Barnes-Jewish Hospital at Washington University Medical Center ranks among the high-volume centers, with about 150 admissions for SAH per year and about 200 patients with ruptured and unruptured cerebral aneurysms treated annually.

Specific causative factors could not be identified by the study data, but Cross believes several factors found at high-volume centers contribute to the improved SAH mortality rates.

- ◆ Large tertiary centers such as Barnes-Jewish Hospital offer a wider array of both surgical and noninvasive techniques and strategies.
- ◆ The centers have experienced neurosurgeons, interventional radiologists, and support staff.
- ◆ Physicians have access to the latest advances in diagnostic and treatment technology.

According to Cross, Washington University Medical Center has another advantage: a tremendous level of interdepartmental cooperation. And this is extremely important in cases, such as SAH, where there are two possible treatment options—one surgical, the other endovascular.

The Cerebral Aneurysm Treatment Team: (left right) doctors Christopher Moran, DeWitte Cross and Colin Derdeyn—neuroradiology; Ralph Derdeyn, Robert Grubb, and Michael Chicoine—neurological surgery. Not shown are doctors Keith Rich, Gregory Zipfel, and Joshua Dowling—neurological surgery; and Michael Diringer and Venkatesh Aiyagari—neurology; and Tracy Dobbie, RN.



Causes of SAH

Initially, there are two types of SAH cases: traumatic and spontaneous. Traumatic SAH is caused by an injury—in the United States, mostly from bicycle, motorcycle, or automobile accidents. According to the Brain Injury Association, approximately 373,000 people are hospitalized annually with brain injuries.

Spontaneous SAH is usually caused by the rupturing of an aneurysm and occurs most frequently in people between the ages of 35 years to 65 years. Weakening of the vessel wall can occur even in healthy people, but some common risk factors include smoking, high blood pressure, head trauma, and alcohol abuse. About two million Americans have brain aneurysms, and most of these aneurysms remain undetected and cause no harm. However, statistics show there are about 30,000 ruptured aneurysms every year in the United States. About half of those cases result in death caused by the sudden increase in pressure on the brain, resulting from the flow of

blood into the subarachnoid space. The pressure cuts off blood supply to the brain.

SAH survivors face a troubling prognosis: a recurrence of bleeding or other complications (resulting in a 50 percent mortality rate) or debilitating impairments affecting motor skills, vision, speech, or mental function. But these grim outcomes are dramatically improved if SAH, and the culprit aneurysm, can be diagnosed and treated quickly.

Treatment options

At Washington University Medical Center, patients with suspected SAH typically come first to the Charles F. Knight Emergency Center. Patients describe the headache pain typical of the SAH attack as the worst pain they have ever experienced. They may also suffer disorientation, vomiting, and loss of consciousness. Patients are evaluated immediately either by a computed tomography (CT) scan or spinal tap to confirm the SAH, then by a cerebral angiogram to locate the aneurysm.

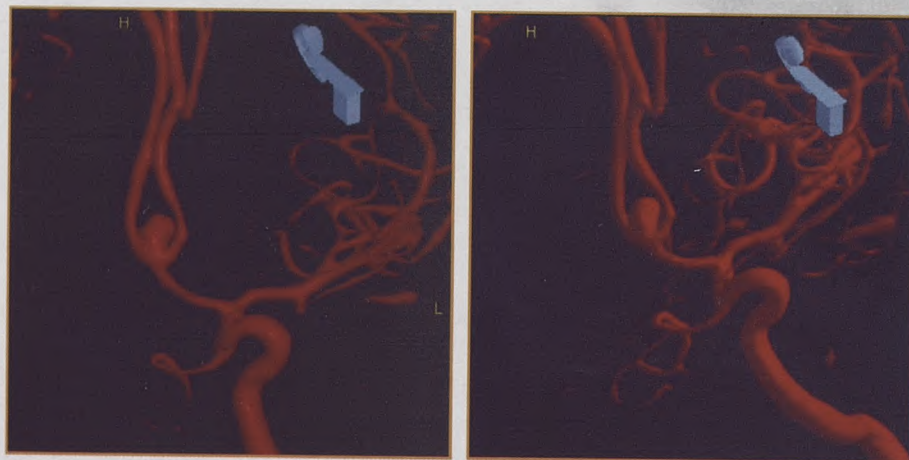
The next step involves the joint effort of interventional neuroradiologists and neurosurgeons like Cross and Ralph Dacey, MD, professor of neurosurgery and chairman of the medical school's Department of Neurological Surgery. Here the interplay of experience, access to and knowledge of the latest technology, and cooperation among disciplines work to determine the best course of action—surgical or noninvasive. Surgeons can perform a clip ligation (opening the skull and using a clip to close the offending aneurysm); interventional neuroradiologists can use a catheter and special metal coils to close the aneurysm.

The importance of teamwork

Cross explains the importance of teamwork at Washington University Medical Center: "One of our strengths in this field is our joint approach to SAH treatment, with the sole concern of what is best for the patient. Some patients are not candidates for noninvasive treatment, and surgery is the best option. But we have to act quickly—the sooner the bleeding is controlled, the less likely the chance of recurrence."

To decide which option is appropriate for a particular patient, the team evaluates four factors: location of the aneurysm, its shape, the clinical grade of the patient, and patient preference (if the patient is conscious and able to participate in the treatment choice). To date, about half of the SAH cases have been treated surgically.

Colorized 3D angiographic renderings of an anterior communicating aneurysm.

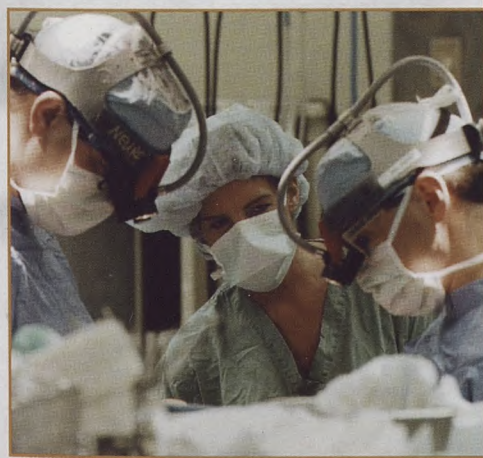

A noninvasive choice

The remaining 50 percent of cases have undergone endovascular coil embolization, a relatively new and minimally invasive radiology procedure benefiting from advances in microcatheter technology. Endovascular coil embolization uses tiny tubes inside arteries (microcatheters) to enter and treat the aneurysms. To treat SAH, the patient undergoes general anesthesia. A neuroradiologist threads a catheter through the femoral artery in the groin, making a small incision at the insertion site. This thin tube is maneuvered directly into the site of the ruptured aneurysm, using angiography during the procedure to guide the catheter. Angiography uses an injected contrast, which flows into the arteries, mapping the blood flow out of the rupture.

"These 'maps' are made even clearer by the use of advanced angiography, which gives us biplanar images during the procedure," says Cross. "I can see the catheter, the aneurysm, and the artery in several relational views as I am working."

Ralph Dacey, MD, (right) and a neurological surgery team



Resources

THE FOLLOWING LISTING DOES NOT IMPLY MALLINCKRODT INSTITUTE'S ENDORSEMENT OF THESE WEB SITES' CONTENT BUT IS INTENDED SOLELY FOR GUIDANCE ON WHERE TO BEGIN YOUR SEARCH FOR SAH INFORMATION.

- ◆ AMERICAN SOCIETY OF NEURORADIOLOGY (WWW.ASNR.ORG)
- ◆ AMERICAN ASSOCIATION OF NEUROLOGICAL SURGEONS (WWW.AANS.ORG)
- ◆ AMERICAN SOCIETY OF INTERVENTIONAL AND THERAPEUTIC NEURORADIOLOGY (WWW.ASITN.ORG)
- ◆ BRAIN INJURY ASSOCIATION (WWW.BIAUSA.ORG)
- ◆ BRAIN INJURY ASSOCIATION OF MISSOURI (WWW.BIAUSA.ORG/MISSOURI/BIA.HTM)

The SAH Study Researchers

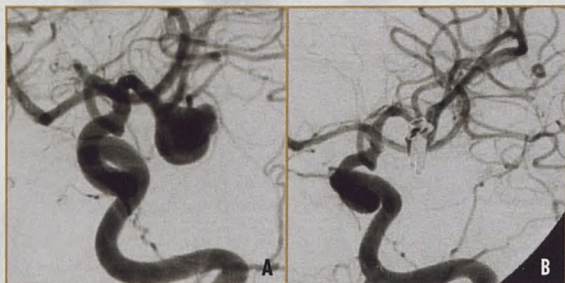
WASHINGTON UNIVERSITY

- ◆ DEWITTE CROSS, MD
- ◆ RALPH DACEY, MD
- ◆ COLIN DERDEYN, MD
- ◆ CHRISTOPHER MORAN, MD
- ◆ DAVID TIRSCHWELL, MD

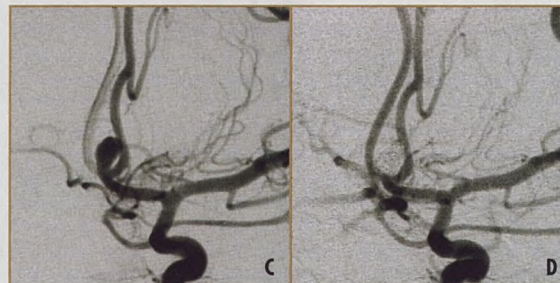
BOSTON SCIENTIFIC CORPORATION

- ◆ MARY ANN CLARK, MHA
- ◆ DANIEL TUDEN, PHD

Clips & Coils



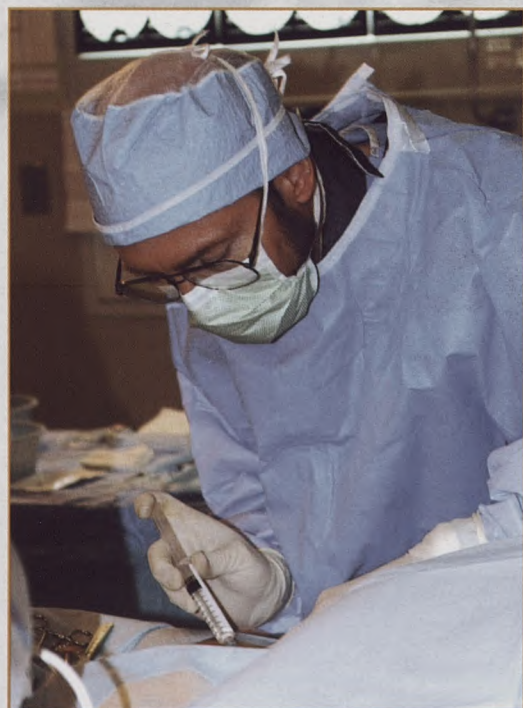(A and B) Left middle cerebral aneurysm before and after clipping.



(C and D) Anterior communicating aneurysm before and after coiling.

Next, tiny platinum coils are fed into the rupture to block the flow of blood. Platinum is used because the material does not interfere with the magnetic forces used in many imaging procedures, such as magnetic resonance imaging. Coils range in size from two to 20 millimeters in diameter and come in many shapes. They are inserted into the catheter as straight sections and curl up into their initial shape when deployed, then they are detached in the

Interventional Neuroradiologist DeWitte Cross prepares to insert an arterial catheter, to begin an endovascular aneurysm treatment procedure.



aneurysm using a minute jolt of electrical current. Imagine stretching a Slinky® (the wire toy that's been around since 1945) until it is straight, then letting it go—that is a platinum coil, enlarged many times over.

Cross explains the finesse involved in this procedure: First, a 'basket' with a complex coil shape is created within the aneurysm; then, helical-shaped coils are placed inside until the bleeding is controlled. "That's another advantage of being a high-volume treatment center, we have a large supply of various coil shapes and sizes," he says.

When the neuroradiologist is satisfied with the coil arrangement, the catheter is withdrawn and the small incision is sutured. The patient is taken to the hospital's Intensive Care Unit to be monitored for at least 24 hours and may be ready to return home as early as the next day in electively treated cases, while patients with SAH remain in the hospital longer for full recovery. With the surgical treatment, a longer hospital stay and significantly longer time to full recovery is required for elective aneurysm treatment.

Cross emphasizes that coils are not appropriate in every case. The re-treatment rate following the coils procedure is 10 percent, as compared to two percent for surgical clipping—so aneurysms that can be treated surgically with low rates of morbidity are often

clipped. However, there are advantages to the coil procedure in aneurysms that are difficult to treat surgically, including lower risks of permanent disability and lower mortality. The British medical journal *Lancet* reported in a 2002 multi-center study, mainly of anterior communicating aneurysms, that coiling resulted in a 22.6 percent reduction in the relative risk of disability or death over the neurosurgical clipping procedure.


21st century training

MIR's interventional neuroradiology fellowship program is training the next generation of specialists who will learn even better techniques and procedures. Equally important, says Cross, is that these trainees learn the importance of cooperation among disciplines and cross-specialization in their own careers. "We are a high-volume medical facility in part because of our advanced technology," he explains. "But our physicians and staff and the long-standing reputation of colleagues such as Doctor Dacey are what continue to bring surgical and radiology referrals to Washington University Medical Center. And, ultimately, that equates to lives saved." **MIR**

Tracking Elusive Prostate Cancer

A NEW STUDY AT MALLINCKRODT INSTITUTE USES ^{11}C -ACETATE AND PET TO DETERMINE TREATMENT FOR PATIENTS WITH PROSTATE CANCER.

After years of working in nuclear medicine on sophisticated computer applications such as reconstruction algorithms and display techniques for three-dimensional data, Tom Miller, pro-



fessor of radiology and of biomedical engineering, had seen this young field

of image processing reach successful maturity, in part through his own pioneering efforts. In 1997, he was ready for a new challenge that would combine physics and nuclear medicine. But, what should it be?

by Candace O'Connor

“I kind of stuck my head out of the door of my office and heard this swish-swish-swish sound,” he says, moving his head from side-to-side. “PET, PET, PET [*positron emission tomography*]. PET tumor imaging, PET oncology. You hear ‘PET’ echoing up and down the halls of Mallinckrodt Institute at a deafening pitch. It didn’t take a genius to figure out what I was going to do.”

So Miller decided to re-tool his career and focus on tumor-imaging research with PET, a technology developed at Mallinckrodt Institute of Radiology (MIR) in the 1970s. Soon that new interest led Miller to a

study of cervical cancer using PET and 18F-FDG, a radiopharmaceutical effective in tumor imaging.

More recently, Miller’s interest has resulted in two important studies of prostate cancer, the most commonly diagnosed cancer in men in the United States and the second-leading cause of cancer deaths in men over age 40. In a pilot study, now completed, Miller and a group of collaborators looked at the effectiveness of 11C-acetate, another radiopharmaceutical used in PET imaging, to diagnose recurrent prostate cancer. In a second study, still ongoing, investigators are testing whether PET and 11C-acetate can reliably determine the full extent of cancer present in high-risk patients who were recently diagnosed with prostate cancer.

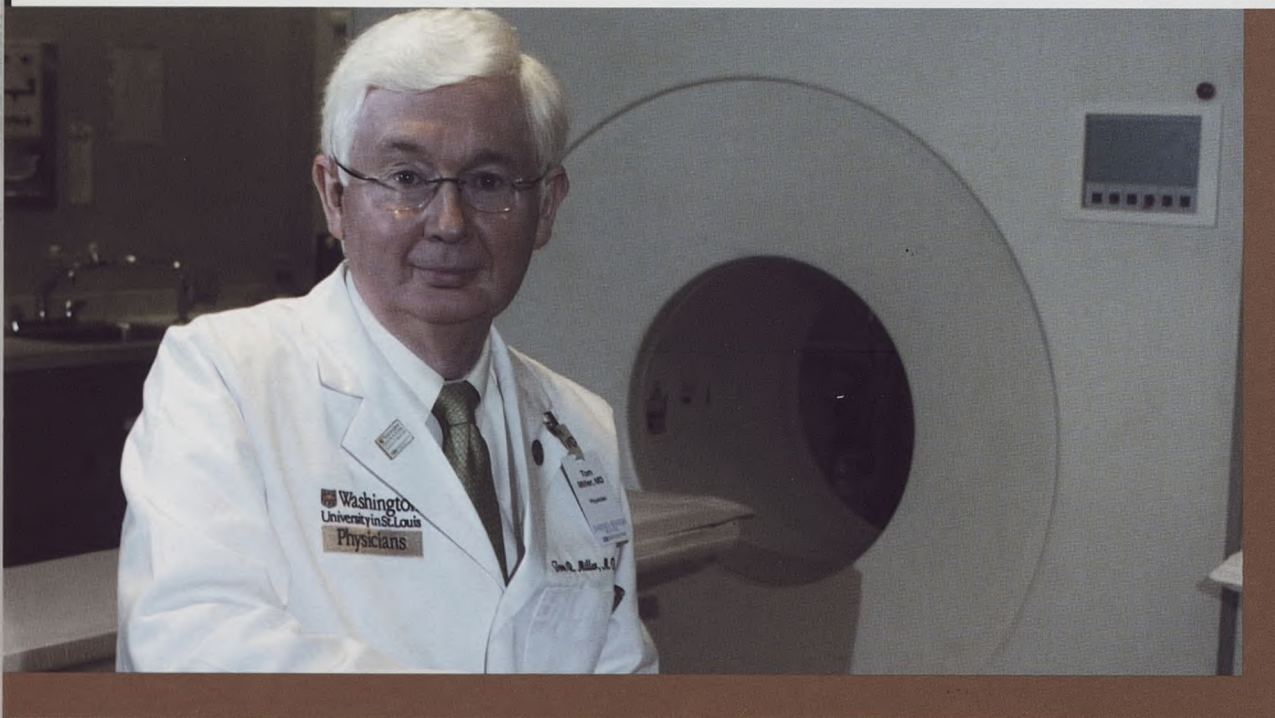
“Although prostate cancer is a major problem, we lack good imaging methods to detect the disease,” says Miller. “That is what we are addressing here: If we can find cancer metastasis that is missed by conventional imaging methods at the time of diagnosis, that discovery could lead to a major alteration in treatment for these patients. So we will have a big payoff if this method works.”

Prostate cancer screening

Diagnosing prostate cancer in its early stages used to be problematic—until William Catalona, MD, former head of the Division of Urologic Surgery at Washington University in St. Louis School of Medicine (WUSM), pioneered the prostate-specific antigen (PSA) test in the early 1990s. Widespread PSA screening has since led to the much earlier diagnosis of prostate cancer.

Screening works this way: When a man’s PSA level is elevated, prostate cancer may be present, and a biopsy is performed for confirmation. If that test is positive, the next step is to determine how the disease should be treated. Younger men with localized cancer often

Nuclear Medicine Physician Tom Miller earned a PhD degree in nuclear physics from Stanford University and an MD from the University of Missouri-Columbia. Prior to joining the MIR faculty in 1981, he completed a residency at the Institute.



undergo a radical prostatectomy; older men for whom surgery would be risky have primary treatment of radiation therapy.

The situation becomes more complicated when the cancer has spread beyond the prostate gland. For these patients, surgery would no longer provide a cure; instead, they may need systemic hormone therapy. Thus, if physicians know the cancer has metastasized, patients can avoid a risky surgical procedure, which would provide no benefit and has associated adverse effects, or a long course of radiation therapy.

However, it is sometimes difficult to tell whether a newly diagnosed patient has disease in the lymph nodes or in more distant sites. As part of the diagnostic exam, this patient should have a bone scan and an initial computed tomography (CT) scan to check if the disease has spread. Often, especially if the man's PSA level was relatively low, these tests show negative results; however, in some cases, these results may be misleading.

PET's role in detecting hidden cancer

While prostate cancer is generally a slow-growing disease, about 20 percent of patients—even those diagnosed through regular PSA testing—have a high-grade form of cancer with a more aggressive course. Recently, Mallinckrodt Institute physicians began providing radiologic services to the Veterans Administration (VA) Hospital in St. Louis. For reasons unclear at present, diagnostic testing is showing a higher-than-normal proportion of these veterans with high-grade prostate cancer.

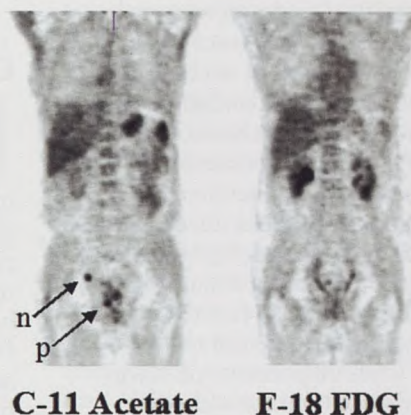
Such patients are more likely to have hidden disease at the time of diagnosis, although their initial workup and tests show nothing suspicious. "It's difficult to find," says Miller. "We're studying whether the lymph nodes can be detected when the CT results are already negative, but we are limiting our study to cases in which PET imaging could really make a difference."

PET is a potentially useful tool. Already, the combination of PET and 18F-FDG has proven effective in detecting many other forms of cancer, including lung, lymphoma, colon, breast, melanoma, esophagus, liver, cervical, and recurrent brain cancer. But FDG usually is not effective in detecting prostate cancer, probably because FDG is a sugar, an analog of glucose; prostate cancer has a low demand for energy since it grows so slowly.

Finding a new, more effective radiopharmaceutical to use with PET was a key need. Miller's study of cervical cancer with FDG was underway when a preliminary abstract in a medical journal reported that 11C-acetate PET seemed promising in detecting prostate cancer.

Miller, who had worked on computer imaging with 11C-acetate in measuring myocardial oxidative metabolism, was familiar with this agent. Better still, 11C-acetate, which has an extremely short half-life of around 20 minutes, was already being produced in the Institute's radiological chemistry laboratory for use in cardiac studies. Further, the urologic surgery staff at

Biopsy proven prostate recurrence following RT



With 11C-acetate, lymph with tumor (n) and prostate recurrence (p) is clearly indicated. With FDG, result is negative for both tumor and recurrence.

Barnes-Jewish Hospital could refer prostate cancer patients, as could the Department of Radiation Oncology's genitourinary service.

Miller obtained two, successive pilot grants of \$25,000 each from Siteman Cancer Center as well as a grant from the CaPCure Foundation to compare the effectiveness of 18F-FDG PET and 11C-acetate PET in patients who had undergone radical prostatectomy or radiation therapy and subsequently developed a rising PSA level—indicating a likely disease recurrence. Some 30 percent of these men will have local recurrences, while 70 percent will have distant disease with or without local recurrence.

In comparative studies of 46 patients using both radiopharmaceuticals—(30 men initially were treated with surgery; 16, with primary radiation)—investigators found that among those patients whose disease was confirmed by CT scan or biopsy, 30 percent were identified by 11C-

acetate PET, while only 9 percent were identified by 18F-FDG PET. Clearly, 11C-acetate PET was the much superior tool.

Current Study

Miller has now received National Institutes of Health (NIH) funding to continue investigating 11C-acetate PET. Over a five-year period, the research team plans to accrue 200 to 300 newly diagnosed, high-risk patients who have a PSA level of 10 or greater, a Gleason (biopsy) score of at least seven, and bone and CT scans negative for metastasis. Unlike patients whose initial PSA level is lower, men in this group are more likely to have cancer that has spread outside the prostate and has not shown up during the diagnostic workup.

"Despite intensive PSA screening, about ten percent to twenty percent of newly diagnosed cancer patients have advanced tumors,"

says Gerald Andriole, MD, chief of WUSM's Division of Urologic Surgery. "There is an urgent need to identify these patients prior to treatment. Carbon eleven-acetate scanning may be useful for these patients, as well as for men with recurrence after surgery or radiation therapy. If we are able to more precisely stage such patients, we can optimize their treatments."

Specifically, says Adam Kibel, MD, director of urologic oncology, "if we could identify those high-risk patients showing metastasis, they could be spared the morbidity of unnecessary surgery or radiation therapy. Also, high-risk patients whom we previously would not treat with curative intent now could be diagnosed as free of metastasis, and we could try to cure them."

There should be no problem recruiting enough patients, since the surgeons and radiation oncologists at Washington University Medical Center annually treat approximately 800 patients newly diagnosed with prostate cancer. The high-risk patients at the VA Hospital should provide another pool of patients, and the researchers also plan to contact some community urologists for referrals.

So far, eight men with newly diagnosed prostate cancer have been tested, using the medical center's combined PET/CT scanner. Cary Siegel, MD, an associate professor of radiology with CT expertise, is interpreting the patients' CT scans, while the study's nuclear medicine physicians are interpreting the PET scans.

Pilot Grants Collaborators

Nuclear Medicine

Farrokh Dehdashti, MD
Keith Fischer, MD
Tom Miller, MD, PhD
Barry Siegel, MD

Surgery

Gerald Andriole, MD
Adam Kibel, MD

Medical Oncology

Joel Picus, MD

Radiation Oncology

Jeff Michalski, MD

Radiological Sciences

Michael Welch, PhD

A Welcome Addition

Nobuyuki Oyama, MD, PhD, a urologist on sabbatical from Japan's Fukui University, who was working in Welch's laboratory. (Oyama, who had worked with 11C-acetate PET in Japan, not only wrote a grant proposal that resulted in additional funding from the CaPCure Foundation but also was first author on a paper published in 2003 in the *Journal of Nuclear Medicine*.)

Results to date have been encouraging. Among the study's eight patients, two men have shown evidence of cancer metastasis that was not apparent on the bone scan or on the CT scan. In one patient, the cancer had spread to a tiny lymph node near the prostate. The PET scan of the other patient showed affected lymph nodes in the abdomen and in the neck, with the neck node confirmed by ultrasound-guided biopsy.

"Unfortunately, this patient has documented metastatic cancer," says Jeff Michalski, MD, chief of Radiation Oncology's genitourinary service, "but because the metastasis was detected, he has avoided a long regimen of expensive, unnecessary radiation therapy that would not have provided any benefit. He is receiving hormone therapy, a dramatic change in his care."

With many more patients to be enrolled in the study, Miller and his colleagues are cautiously optimistic about 11C-acetate PET as an important prostate cancer tool. This radiopharmaceutical does have some inherent limitations: primarily, a 20-minute half-life that, unlike the 110-minute half-life of 18F-FDG, limits its use to an institution with an in-house cyclotron. *[Editor's note: Mallinckrodt Institute currently has two in-house cyclotrons and was the first medical facility in the*

United States to have a dedicated cyclotron.] MIR's radiological chemistry laboratory, headed by Michael Welch, PhD, is currently performing animal studies with a new radiopharmaceutical, 18F-Fluoroacetate, which has the advantages of 11C-acetate **plus** a nearly two-hour half-life.

Will patients with a positive PET scan have a worse long-term outcome than those patients whose PET scan was negative? There is currently no definitive answer to this question. But patients who participated in Miller's study will have follow-up care over several years, and their information could help change prostate cancer treatment and patient outcome. "If the study goes well," says Miller, "PET with carbon eleven-acetate could become a routine clinical test for men with a high-risk, new diagnosis of prostate cancer."

If this study's conclusions are as hoped for, adds Michalski, "we will be better able to tailor treatment to

those patients who are likely to benefit from it, to avoid the morbidity and toxicity for patients who will not benefit from treatment, to avoid unnecessary surgeries if patients have evidence of metastasis, and to identify a group of patients who require therapy that is either more aggressive or more innovative than what we have been able to provide."

*Editor's Note: Urologists who wish to refer patients to the 11C-acetate PET study or would like more information about the use of this test in the clinical setting may contact the study coordinators, Jennifer Frye and Helen Kaemmerer, at (314) 362-7021. **MIR***

Jeff Michalski, MD, also serves as director of the Clinical Division in the Department of Radiation Oncology.



FYI

In this section, the names of employees who are full-time faculty or staff or who have an appointment in the Department of Radiology or Department of Radiation Oncology are highlighted in boldface type.

NEW FACULTY

Michael Penney, MD, instructor in radiology, Division of Diagnostic Radiology (at Barnes-Jewish St. Peters Hospital), Department of Radiology.

Robert Steiner, MD, instructor in professor, Division of Diagnostic Radiology (at Barnes-Jewish St. Peters Hospital), Department of Radiology.

GRANTS

Samuel Achilefu, PhD, associate professor of radiology, as principal investigator, received a \$153,000 grant from the National Institutes of Health for research on "Novel monomolecular multimodality imaging agents. Coinvestigators for the one-year award are **Michael, Welch, PhD**, professor of radiology, of chemistry, and of molecular biology and pharmacology; **Barry Siegel, MD**, professor of radiology and of medicine; Gregory Lanza, MD, assistant professor of medicine; Samuel Wickline, MD, professor of medicine; and Brinton Chance, MD, University of Pennsylvania.

Kevin Black, MD, assistant professor, of psychiatry, of neurology, and of radiology, as site principal investigator, received a grant from the National Institute of Neurological Disorders for research on "Serotonergic antidepressant in Parkinson's disease." As site principal investigator, he also received a one-year grant from ACADIA Pharmaceuticals for "Phase 2, multi-center, placebo controlled, double blind trial of ACP-103 in the treatment of psychosis in Parkinson's disease (Clinical protocol # ACP-103-006)."

Thomas Conturo, MD, PhD, associate professor of radiology and adjunct professor of physics and biomedical engineering, as principal investigator, received a one-year grant of \$56,390 from Sun Microsystems, Inc. for research on "Computational hardware for MRI research and development." As principal investigator, he also received a one-year grant of \$8,000 from Mallinckrodt, Inc./Tyco Healthcare, Inc. to study "MRI compatibility of patient accessories in phantoms and animals."

Robert Gropler, MD, professor of radiology, of medicine, and of biomedical engineering, as principal investigator, received a \$3.7 million grant from the National Institutes of Health, for research on "Altered myocardial fatty acid metab-

olism in obesity." Coinvestigators for the five-year award are Pilar Herrero, MS, research scientist in radiology; Samuel Klein, MD, professor of medicine; and Linda Peterson, MD, assistant professor of medicine.

Joel Perlmutter, MD, professor of neurology, of neurological surgery, of radiology, and of physical therapy, as principal investigator, received a \$1.9 million grant from the National Institutes of Health (NIH) and a \$25,000 fellowship grant from Medtronic, Inc. for research on "Mechanisms of deep brain stimulation." Theodore Cicero, PhD, vice chancellor for research, as principal investigator, and Perlmutter, as co-principal investigator, received a \$1.8 million award from NIH for renovations needed to complete a 14,000 square feet, neuroclinical research unit.

Joshua Shimony, MD, PhD, assistant professor of radiology, as principal investigator, received a two-year grant of \$80,000 from the McDonnell Center for the Studies of Higher Brain Function for research on "Mapping neuronal connectivity in the human visual cortex and in the frontal-parietal region."

Marilyn Siegel, MD, professor of radiology and of pediatrics, received a one-year grant of \$5,000 from the Society for Pediatric Radiology for research on "Measurements of epicardial and visceral fat: correlation with treatment options."

APPOINTMENTS/ELECTIONS

Carolyn Anderson, PhD, associate professor of radiology, was elected to a two-year term as secretary/treasurer of the Society for Radiopharmaceutical Chemistry and Biology.

Colin Derdeyn, MD, associate professor of radiology, was appointed as a consultant to the Neurological Devices Panel of the Medical Devices Advisory Committee for the Food and Drug Administration's Center for Devices and Radiological Health.

Jay Heiken, MD, professor of radiology, was appointed to a one-year term on the American College of Radiology Imaging Network Gastrointestinal Disease Site Committee.

Susan Langhorst, PhD, CHP, assistant professor of radiology, was appointed to a two-year term as a member of the National Academies of Science Board on Radioactive Waste Management.

Linda Larson-Prior, PhD, research associate professor of radiology, was elected treasurer of the Executive Board of the Organization for Computational Neuroscience.


Robert McKinstry, MD, PhD, assistant professor of radiology, was appointed to a seven-year term as chairman of the Neuroradiology Committee and as a member of the Executive Committee of the Silent Cerebral Infarct Multicenter Trial, funded by the National Institute of Neurological Disorders. He was appointed codirector of the Mallinckrodt Institute Research Residency Training Program.

Eduardo Moros, PhD, associate professor of radiation oncology, was elected to a four-year term as president of the International Association for Hyperthermic Oncology, the international organization representing the North American Hyperthermia Society (NAHS), the European Society for Hyperthermic Oncology, and the Asian Society for Hyperthermic Oncology. He also was elected to a one-year term (2004-2005) as president of NAHS.

Bradley Schlaggar, MD, PhD, assistant professor of neurology, of radiology, of pediatrics, and of anatomy and neurobiology, was appointed consulting editor for the journal *Developmental Psychology*.

Biello Lecture

Former MIR faculty member, Landis Griffeth, MD, PhD, presented the Eighteenth Annual Daniel R. Biello Memorial Lecture on March 8. Griffeth, director of nuclear medicine in the Department of Radiology at Baylor University Medical Center (Texas), presented "Lymphoma: a model for PET's role in cancer management."



Griffeth (left) is shown with Barry Siegel, MD chief, Division of Nuclear Medicine, and coordinator of the Biello Lecture.

Barry Siegel, MD, professor of radiology and of medicine, was elected to a three-year term as a member-at-large of the Academy of Molecular Imaging Board of Directors.

Marilyn Siegel, MD, professor of radiology and of pediatrics, was appointed as a consultant to the Food and Drug Administration for pediatric cardiac and extracardiac vascular imaging using computed tomography and magnetic resonance angiography.

Bruce Whiting, PhD, research professor of radiology, was elected as the 2004 chairman of the St. Louis Chapter of the Engineering in Medicine and Biology Society of the Institute of Electrical and Electronics Engineers.

Pamela Woodard, MD, assistant professor of radiology, was elected to a two-year term as secretary-treasurer of the North American Society of Cardiac Imaging.

HONORS/ AWARDS

Thomas Conturo, MD, PhD, associate professor of radiology and adjunct professor of physics and biomedical engineering, was invited to serve as guest editor of the *Journal of Magnetic Resonance Imaging*'s special issue on "Quantitative cerebral perfusion imaging using MRI: a technical perspective."

HONORS/ AWARDS

Continued from page 25

Robert Malyapa, MD, PhD, assistant professor of radiation oncology, received the Radiation Therapy Oncology Group's (RTOG's) Simon Kramer New Investigator Award for his research project "Oncologic imaging of tumor hypoxia and correlating findings on Cu-ATSM PET scans to cellular markers that may predict for radiation response." The award was presented in January at the RTOG Winter Semi-Annual Meeting in New Orleans, Louisiana.

Stephen Moerlein, PhD, associate professor of radiology and of biological chemistry, and **Yuan-Chuan Tai, PhD**, assistant professor of radiology, received the Image of the Year Award for their research on "Quantitative neuroreceptor imaging of transgenic mice" at the Concorde Microsystems Inc. Users Meeting in March.

Douglas Rowland, PhD, research instructor of radiology, received the Best Dramatic Dynamic Image of the Year Award at the Concorde Microsystems Inc. Users Meeting in March. **Rowland; Richard Laforest, PhD**, assistant professor of radiology; **Yuan-Chuan Tai, PhD**, assistant professor of radiology; and **Michael Welch, PhD**, professor of radiology, of chemistry, and of molecular biology and pharmacology, used the microPET scanner to produce the award-winning gated cardiac images.

LECTURES

Carolyn Anderson, PhD, associate professor of radiology, presented "Copper-64-labeled biomolecules for tumor targeting" at Lawrence Berkeley Laboratory, Berkeley, California, January 28.

Sanjeev Bhalla, MD, assistant professor of radiology, as invited speaker, presented "Finding blue pearls: Eastern reflections on Western medicine" at the 51st Annual Alpha Omega Alpha Lecture, Washington University in St. Louis, Missouri, April 6.

Kevin Black, MD, assistant professor of psychiatry, of neurology, and of radiology, spoke on "Neuroimaging studies of dopaminergic function in Tourette Syndrome" at the Tourette Syndrome Association Young Investigators Symposium, Atlanta, Georgia, January 31.

Jeffrey Bradley, MD, assistant professor of radiation oncology, presented "Dose response and complications" at the Optimizing of Thoracic Irradiation: RTOG Symposium, sponsored by the Radiation Therapy Oncology Group, New Orleans, Louisiana, January 16. He spoke on "Current issues in conformal radiotherapy for

lung cancer: targeting tumors with FDG-PET" at the National Institutes of Health/National Cancer Institute, Bethesda, Maryland, March 31 and April 1. He presented "Radiation treatment planning with PET/CT" at the CMS Users Meeting, St. Louis, Missouri, April 25.

Jeffrey Brown, MD, associate professor of radiology, presented "Diagnosis and staging of cholangiocarcinoma and gallbladder cancer by MRI" at the 12th Annual WUSM Refresher Course and Update in General Surgery, St. Louis, Missouri, February 26.

Thomas Conturo, MD, PhD, associate professor of radiology and adjunct professor of physics and biomedical engineering, spoke on "Research and development of dynamic susceptibility contrast perfusion MRI for neurological studies" and "Beyond the tensor: measurement of displacement probabilities and other diffusion parameters in tissues" at the Symposium on Advanced Magnetic Resonance Imaging in Neuroscience, Istituto Nazionale Neurologico "Carlo Besta," Milan, Italy, March 24.

Maurizio Corbetta, MD, associate professor of neurology and of radiology, presented "The attention system of the human brain" to the Department of Neuroscience, Medical College of Wisconsin, Milwaukee, January 21. He spoke on "A strategy to investigate recovery of cognitive functions with functional brain imaging" at the International Symposium on Neuroimaging of Stroke Recovery, Columbia University, New York City, New York, February 2 and 3. He spoke on "Brain systems for the control of perception and action" at the Neuroscience Colloquium, sponsored by the French National Center for Scientific Research (CNRS), Lyons, France, February 6. Corbetta presented "From neurology to neuroscience: brain imaging studies of visual attention in the normal and damaged brain" at Brain Sciences Lectures, University of Chieti, Italy, February 10. He presented "Stroke recovery: a neuroimaging approach" at the Clinical Neuroscience Grand Round, Fatebenefratelli Hospital, Rome, Italy, February 12. Corbetta spoke on "Brain imaging studies of neurological recovery in brain and spinal cord injury" at the Clinical Neuroscience Grand Round, Southwestern Medical University, Dallas, Texas, March 3. He presented "The influence of action on visual cortex" at the International Conference on New Perspective in Vision, Isle of Mull, Scotland, April 14-16.

Colin Derdeyn, MD, associate professor of radiology, presented "Role of cerebral hemodynamics in ischemic stroke" and "Treatment of carotid atherosclerotic disease: medicine, surgery, or stent" at the Colorado Radiological Society meeting, Denver, January 15. He spoke on "A patient with complete carotid occlusion" at the St. Louis Vascular Surgery 29th Annual Meeting, St. Louis, Missouri, January 19. Derdeyn spoke on "Management of posterior circulation aneurysms" and "Selection of patients for

cerebral revascularization: the role of hemodynamic assessment" at the 7th Annual Joint Meeting of the American Association of Neurological Surgeons/Congress of Neurological Surgeons Joint Section on Cerebrovascular Disease and the American Society of Interventional and Therapeutic Neuroradiology, San Diego, California, February 2 and 3. He presented "The carotid occlusion surgery study" at Medical Grand Rounds, Alton Memorial Hospital, Alton, Illinois, February 18.

Steven Don, MD, associate professor of radiology, spoke on "Radiosensitivity of children: potential for overexposure in CR and DR and magnitude of doses in ordinary radiographic examinations" at the ALARA Concept in Pediatric CR and DR, Houston, Texas, February 28.

Louis Gilula, MD, professor of radiology, of orthopaedic surgery, and of plastic and reconstructive surgery, presented "Vertebroplasty in fractures with spinal cord impingement" at the Society of Skeletal Radiology, Tucson, Arizona, March 9. As visiting professor, he spoke on "Cervical spine trauma" at the Oregon Health and Science University, Portland, April 15.

Perry Grigsby, MD, professor of radiation oncology and of radiology, spoke on "Radiation therapy for cancer of the thyroid," "Multimodality management of cancer of the cervix," and "Treatment of endometrial cancer" at the 56th Annual Midwinter Radiation Oncology Conference, Los Angeles, California, January 23-25. He presented "New imaging techniques" at the 35th Annual Meeting of the Society of Gynecologic Oncologists, San Diego, California, February 9-11.

Jay Heiken, MD, professor of radiology, presented "CT colonography: technique, results and future directions"; "MDCT evaluation of small bowel obstruction"; "Characterization of hepatic masses with helical CT"; and "CT of the abdominal aorta: aneurysm rupture and post-operative complications" at Computed Body Tomography 2004: the Cutting Edge, sponsored by Johns Hopkins University, Orlando, Florida, February 12-15. He moderated a session on "Imaging of acute abdominal conditions" and spoke on "Imaging small bowel obstruction" at ARC 2004 Abdominal Radiology, presented by the Society of Gastrointestinal Radiologists and the Society of Uroradiology, Scottsdale, Arizona, March 7-12. He spoke on "Contrast medium administration and scan timing for MDCT" and "Aortic stent grafts: pre-operative and post-operative evaluation with MDCT" at New Advances in Non-Invasive Vascular Imaging 2004, San Francisco, California, April 3.

Cardiovascular MR Course

Twenty participants attended the 6th annual "Cardiovascular MR Course: Hands-on Experience," held in the Institute's East Building on January 20-22. Course faculty: **Pamela Woodard, MD**, course director; **Glenn Foster, RT**; **Robert Gropler, MD**; **Fernando Gutierrez, MD**; **Richard Nagel, RT**; **Vamsidhar Narra, MD**; Orlando Simonetti, PhD (Northwestern University); and Gary McNeal (Northwestern University and Siemens Medical Systems).

For more information about this course, call (314) 747-3878.

LECTURES

Continued from page 27

Charles Hildebolt, DDS, PhD, associate professor of radiology and adjunct associate professor of anthropology, spoke on "Effect of vitamin D and calcium on periodontitis," "Tips on writing grant proposals," and

"The new clinical trials program at the National Institutes of Dental and Craniofacial Research" at the Southern Illinois University School of Dental Medicine, Alton, Illinois, April 27.



Purdy Lecture

Thomas Mackie, PhD, professor of medical physics, human oncology, and of engineering physics at the University of Wisconsin, Madison, was guest speaker for the Second Annual James A. Purdy Medical Physics Lecture on April 30. Mackie spoke on "Tomotherapy and beyond."

(Left to right) Marilyn Purdy; James Purdy, PhD; Mackie; and Todd Wasserman, MD.

Richard Laforest, PhD, assistant professor of radiology, presented "Recent advances in microPET imaging of rodents" at the Site-man Cancer Center Oncologic Imaging Retreat, St. Louis, Missouri, March 13. He presented "An introduction to the microPET-FOCUS 120" at the microPET Users meeting, Orlando, Florida, March 27. He spoke on "Requirements for quantitative PET imaging" at the National Cancer Institute Advanced Technology Symposium, April 14.

Wayne Lamoreaux, MD, radiation oncology chief resident, presented "FDG-PET evaluation in patients with carcinoma of the vagina" at the 26th International Symposium on Radioactive Isotopes in Clinical Medicine and Research, Bad Gastein, Austria, January 13-16.

Jason Lewis, PhD, assistant professor of radiology, spoke on "Non-invasive measurement of hypoxia by imaging—Cu-ATSM" at Hypoxia: Importance in Tumor Biology, Non-Invasive Measurement by Imaging, and Value of its Measurement in the Management of Cancer Therapy, sponsored by the National Cancer Institute, Phoenix, Arizona, April 7.

Jacob Locke, MD, assistant professor of radiation oncology, presented "Enhancement of hyperthermic radiosensitization with Celecoxib: molecular targets" at the 95th Annual Meeting of the American Association for Cancer Research, Orlando, Florida, March 27-31. He presented "Celecoxib enhances hyperthermic radiosensitization" at the 93rd Annual Meeting of the American Association for Cancer Research—Radiobiology, Laguna, California, April 6-10.

Stephen Moerlein, PhD, associate professor of radiology and of biological chemistry, spoke on "Preparation of [C-11]β-CFT for PET measurement of dopamine transport activity" at the 2004 Annual Meeting of the American Pharmacists Association, Seattle, Washington, March 26-30.

Eduardo Moros, PhD, associate professor of radiation oncology, presented "The development of systems to expose cells and animals to electromagnetic radiation. Engineering experience and summary to biological results" at the Joint Graduate Program in Biomedical Engineering Spring 2004 Seminar Series, sponsored by the University of Memphis and the University of Tennessee Health Science Center, Memphis Tennessee, March 12.

Tej Pandita, PhD, assistant professor of radiation oncology, spoke on "Mammalian orthologue of Drosophila HAT influences ATM function and embryonic development" at the EMBO Workshop/58th Harden Conference—Telomeres and Genome Stability, sponsored by The Biochemical Society, London, England, April 3-7.

Carlos Perez, MD, professor of radiation oncology, presented "Chemoradiation in locally advanced carcinoma of the uterine cervix" and "Radiation therapy in the treatment of carcinoma of the uterine cervix" at Memorial Regional Hospital, Hollywood, Florida, February 7. He presented "Prognostic factors in early breast cancer," "Management of carcinoma of the rectum," and "Chemoradiation for locally advanced carcinoma of the uterine cervix" at XXI Renunión Nacional Médica del Instituto, Veracruz, Mexico, February 10-14. He spoke on "Radiopharmaceuticals in bone metastases" at the St. Louis Society of Medical Oncology, St. Louis, Missouri, February 17.

Joel Perlmutter, MD, professor of neurology, of neurological surgery, of radiology, and of physical therapy, spoke on "Parkinson's disease: new pathophysiological investigations" at Neuroscience Grand Rounds, St. John's Mercy Medical Center, St. Louis, Missouri, February 18. He presented "PET investigations of movement disorders" at the 2004 Annual Meeting of the Academy of Molecular Imaging, Orlando, Florida, March 27-31.

Joseph Roti Roti, PhD, professor of radiation oncology, presented "Heat shock effects on the DNA repair protein MRE11 and radiosensitization by clinically relevant thermal doses" and "Lack of biological effects from some electromagnetic radiations (i.e., cellular telephones) but not from others" at Experimental Radiation Oncology, sponsored by The University of Texas M.D. Anderson Cancer Center, Houston, Texas, February 12.

Douglas Rowland, PhD, research instructor of radiology, spoke on "Respiratory and cardiac gating: R4 and focus" at the Concorde Microsystems Inc. Users Meeting, Orlando, Florida, March 26.

Bradley Schlaggar, MD, PhD, assistant professor of neurology, of radiology, of pediatrics, and of anatomy and neurobiology, presented "The developmental functional neuroanatomy of lexical processing" at the Mental Retardation/Developmental Disabilities Research Center, Kennedy Krieger Institute, Baltimore, Maryland, February 2, and at the Vanderbilt University Institute of Imaging Science Seminar, Memphis, Tennessee, February 19.

Barry Siegel, MD, professor of radiology and of medicine, presented "Clinical applications of PET in oncology" at a meeting sponsored by Clinical Multi-Imaging PET-CT, Rio de Janeiro, Brazil, January 24. He presented "Overview of PET in oncology," "PET and lung cancer," "Assessing response to therapy with PET," and "Oncologic PET: beyond FDG" at the 4th Annual Snowbird 2004 Meeting, Clinical Nuclear Medicine: Focus on PET and PET/CT, Snowbird, Utah, March 21-26. He spoke on "PET artifacts/variants," "Pulmonary nodule and lung cancer," and "PET in women's imaging" at Clinical Nuclear Medicine, sponsored by Harvard Medical School, Boston, Massachusetts, April 27-30.

Marilyn Siegel, MD, professor of radiology and of pediatrics, spoke on "Pediatric CT angiography," "CT angiography of adult mediastinal vascular anomalies," and "Non-coronary cardiac CT" at the Advanced Topics in CT Scanning: CT Angiography, 3D Imaging, Virtual Imaging Course, sponsored by Johns Hopkins University, Los Angeles, California, March 26-28, and in Baltimore, Maryland, April 2-4.

Franz Wippold, MD, associate professor of radiology, presented "Imaging of the herniated lumbar disk" to the American Academy of Orthopaedic Surgeons, San Francisco, California, March 10.

SYMPOSIA

In this section of FYI, only those faculty and staff who have Department of Radiology or Department of Radiation Oncology appointments are listed.

AMERICAN COLLEGE OF CARDIOLOGY

*53rd Annual Scientific Session Exposition
New Orleans, Louisiana
March 7-9, 2004*

Pilar Herrero, MS, cochair, Positron Emission Tomography: Clinical Studies.

SYMPOSIA

Continued from page 29

POSTER PRESENTATIONS

Pilar Herrero, MS; Joon-young Kim, PhD; Terry Sharp; Carmen Dence, MS; Jason Lewis, PhD; Robert Gropler, MD; Michael Welch, PhD, "Assessment of myocardial perfusion and metabolism in normal and diabetic rats by microPET imaging."

Cheng Hong, MD; Pamela Woodard, MD; Kyongtae Bae, MD, PhD, "Assessment of coronary artery stent patency with in-stent contrast enhancement in multi-row detector computed tomography angiography."

ORAL PRESENTATIONS

Robert Gropler, MD, "Non-invasive imaging in the diabetic population: nuclear cardiology, electron beam computed tomography"; "Patients with the metabolic syndrome have a high prevalence of left ventricular diastolic dysfunction."

Pilar Herrero, MS; Zulfia Kisrieva-Ware, MD, PhD; Carmen Dence, MS; Robert Gropler, MD, "Impact of increased fatty acid delivery on myocardial fatty acid metabolism in obese young women."

INTERNATIONAL SOCIETY FOR MAGNETIC RESONANCE IN MEDICINE

Workshop on Quantitative Cerebral Perfusion Imaging with MRI: A Technical Perspective
Venice, Italy
March 21-23, 2004

Thomas Conturo, MD, PhD, Workshop organizer; session moderator, "Dynamic susceptibility contrast MRI theory."

ORAL PRESENTATIONS

Erbil Akbudak, PhD; Melanie Kotys; Dunja Memisevic; Thomas Conturo, MD, PhD, "Quadraticity and hematocrit dependence of Delta R2* AIF signals at 3T: a blood phantom study under physiologic conditions."

Erbil Akbudak, PhD; Melanie Kotys; Thomas Conturo, MD, PhD, "A dual sensitivity interleaved DSC EPI sequence for imaging brain perfusion with AIF sampling."

Thomas Conturo, MD, PhD; Erbil Akbudak, PhD; Melanie Kotys; Joanne Markham, MS, "Arterial input functions for dynamic susceptibility contrast MRI: requirements and signal options."

Melanie Kotys; Erbil Akbudak, PhD; Thomas Conturo, MD, PhD, "Optimal dose determination for Delta R2* and Delta phi arterial input functions using simulations."

POSTER PRESENTATIONS

Melanie Kotys; Erbil Akbudak, PhD; Thomas Conturo, MD, PhD, Effect of signal-to-noise ratio on signal saturation and dose dynamic range in bolus gadolinium Delta R2* and Delta phi arterial input functions."

Dunja Memisevic; Melanie Kotys; Erbil Akbudak, PhD; Thomas Conturo, MD, PhD, "A blood AIF phantom with physiologic pulsatility, velocity, oxygenation and temperature for gated-MRI bolus-Gd studies."

SOCIETY OF COMPUTED BODY TOMOGRAPHY AND MAGNETIC RESONANCE

27th Annual Course
Henderson, Nevada
March 22-26, 2004

CUM LAUDE RESEARCH ABSTRACT AWARDS

Kyongtae Bae, MD, PhD; Cheng Hong, MD; Srinivasa Prasad, MD; Mark Nolte; Paul Eisenbeis; Jay Heiken, MD, "Carbon dioxide enhanced CT imaging for the detection of pulmonary emboli: feasibility study in a porcine model."

Kyongtae Bae, MD, PhD; Srinivasa Prasad, MD; Jay Heiken, MD, "CT characterization of adrenal masses using histogram analysis method."

WORKSHOPS

Kyongtae Bae, MD, PhD, "Principles/X-ray dose: CT/PET: basic principles."

Jay Heiken, MD, "Endoluminal stent graft repair of abdominal aortic aneurysms: evaluation with MDCT."

Stuart Sagel, MD, "CT angiography for pulmonary embolism"; Interactive thoracic CT case discussions"; "Anatomic variants, anomalies and pitfalls in thoracic CT."

Marilyn Siegel, MD, "Imaging common pediatric abdominal masses."

Barry Siegel, MD, "PET in women's cancers."

PRESENTATIONS

Kyongtae Bae, MD, PhD; Victoria Chen; Jie Zheng, PhD; Charles Hildebolt, DDS, PhD; Prem Sri Barton, MD, "Dynamic MR contrast enhancement characteristics of breast cancer: effect of contrast injection rate."

Kyongtae Bae, MD, PhD;
Cheng Hong, MD, "Determining optimal scan delay in 16-MDCT angiography."

Kyongtae Bae, MD, PhD;
Gita Mody; Dennis Balfe, MD; Sanjeev Bhalla, MD; David Gierada, MD; Fernando Gutierrez, MD; Christine Menias, MD; Pamela Woodard, MD; Jin-Mo Goo, MD, PhD; Charles Hildebolt, DDS, PhD, "Display window settings for depiction of pulmonary emboli in CT: trends and variations among observers."

Jay Heiken, MD, "Imaging of small bowel obstruction with MDCT."

Marilyn Siegel, MD, "MR/CT of pediatric renal tumors," "CT of adrenal tumors."

SOCIETY OF INTERVENTIONAL RADIOLOGY

29th Annual Meeting
Phoenix, Arizona
March 25-30, 2004

Daniel Brown, MD, coordinator and moderator, Categorical Course: Enteric Access: Percutaneous vs. Endoscopic—Which Would You Want?

Wael Saad, MD, recipient, Travel Award.

Suresh Vedantham, MD, panelist, Categorical Course: Lessons Learned—Venous Insufficiency.

Thomas Vesely, MD, coordinator, Workshop: Venous Access; commentator, Central Venous Scientific Session.

CATEGORICAL COURSES

Daniel Brown, MD, "An enterostomy practice is good for your patients and you: how to target referrals and avoid trouble."

Michael Darcy, MD, "Palliative interventions for symptomatic fluid collections."

PLENARY SESSIONS

Michael Darcy, MD, "Ambulatory phlebectomy: tips and techniques."

Suresh Vedantham, MD, "Tumescent anesthesia: tips and techniques."

Thomas Vesely, MD, "Vascular access surveillance: go with the flow"; "Tips and tricks: mechanical thrombectomy."

SCIENTIFIC PRESENTATIONS

Dimitrios Papadouris, MD; Thomas Pilgram, PhD; Daniel Brown, MD, "Power injection of microcatheters: an in vitro comparison."

Wael Saad, MD; Michael Darcy, MD, "Stent-grafts in primary TIPS and in TIPS revisions: a single center experience."

Wael Saad, MD, "Hepatic artery PTA after liver transplantation: the fatal kink"; "The natural history of hepatic artery stenosis in liver transplant recipients"; "Transhepatic dilation of anastomotic biliary strictures in liver transplants: significance of a patent hepatic artery"; "Safety and efficacy of fluoroscopic versus ultrasound guided core liver biopsies in live liver transplant donors."

Thomas Vesely, MD, "Use of the peripheral cutting balloon to treat hemodialysis-related stenoses."

POSTER PRESENTATIONS

Wael Saad, MD, "Microbial contamination of bile following liver transplantations: de novo PTC versus indwelling biliary drains."

WORKSHOPS

Daniel Brown, MD, "Gastrointestinal IR: techniques and management."

Thomas Vesely, MD, "Hemodialysis access."

INTERNATIONAL CONGRESS OF HYPERTHERMIC ONCOLOGY

9th Scientific Meeting
St. Louis, Missouri
April 20-24, 2004

Katherine Bles, coordinator liaison, Local Arrangements Committee.

Andrei Laszlo, PhD, member, Local Arrangements Committee.

Jacob Locke, MD, cochairman, Workshop: Whole Body Hyperthermia Modulation of Therapeutic Responses.

Eduardo Moros, PhD, chairman, Local Arrangements Committee; chairman, Robinson Award Lecture; member, Organizing Committee; coordinator, Scientific Program Committee; cochairman, Non-invasive Thermometry/Imaging Special Lectures Session.

Robert Myerson, MD, PhD, cochairman, Plenary Symposium: New Randomized Phase III Trials; member, Local Arrangements Committee.

Joseph Roti Roti, PhD, chairman, Organizing Committee; chairman, Plenary Lecture: Advances in PET Imaging of Hypoxia; member, Local Arrangements Committee.

William Straube, MS, cochairman, Special Lecture: Advances in Hyperthermia/Thermal Therapy Devices.

SYMPOSIA

Continued from page 31

WORKSHOPS

Eduardo Moros, PhD, "Clinical SURLAS for superficial simultaneous thermoradiotherapy."

Robert Myerson, MD, PhD, "Monitoring the effect of 41°C hyperthermia on tumor hypoxia by Cu-ATSM PET scanning."

Robert VanderWaal, PhD, "Heat-shock induced overlap of euchromatin and heterochromatin DNA replication."

ORAL PRESENTATIONS

Jacob Locke, MD, "Differences in response to localized ultrasound versus waterbath hyperthermia: clinical implications."

Tej Pandita, PhD, "Genomic instability and enhanced radiosensitivity in Hsp70.1/3-deficient mice."

Michael Welch, PhD, "Advances in PET imaging of hypoxia."

Mai Xu, MD, PhD, "The effects of 41° hyperthermia on the DNA repair protein, MRE 11, correlate with radiosensitization in four human tumor cell lines."

MEETING SUMMARY

Eduardo Moros, PhD, "Highlights of physics/engineering presentations."

POSTER PRESENTATIONS

Bibianna Cha; Petr Novak, PhD; William Straube, MS; Robert Myerson, MD, PhD; Eduardo Moros, PhD, "Development of a Linac-SURLAS-patient interface transport."

Bibianna Cha; Petr Novak, PhD; William Straube, MS; Robert Myerson, MD, PhD; Eduardo Moros, PhD, "Designing an articulated arm for the LINAC-SURLAS-patient interface transport."

Andrei Laszlo, PhD, "Effects of heat shock on the state of phosphorylation of histone H2AX."

Eduardo Moros, PhD, "Study of the hyperthermic effects of underlying bone on power and temperature patterns in tissue-like phantoms exposed to planar ultrasound."

Robert Myerson, MD, PhD, "Simultaneous radiation therapy and hyperthermia in the elective treatment of subclinical disease in high risk breast carcinoma: comparison of post treatment normal tissue effects in heated and unheated portions of the chest wall"; "Modeling heat induced radiosensitization: clinical implications"; "Monitoring the effect of 41°C hyperthermia on tumor hypoxia by Cu-ATSM PET scanning."

Petr Novak, PhD; William Straube, MS; Bibianna Cha; Robert Myerson, MD, PhD; Eduardo Moros, PhD, "Preclinical evaluation of the SURLAS using a perfused phantom;"

Petr Novak, PhD; Anurag Singh, MD; Buck Rogers, PhD; Jacob Locke, MD; Andrea Zeug; William Straube, MS; Robert Myerson, MD, PhD; Eduardo Moros, PhD, "Performance of the SAHUS temperature controller in a perfused phantom and in vivo experiments."

Petr Novak, PhD; William Straube, MS; Bibianna Cha; Robert Myerson, MD, PhD; Eduardo Moros, PhD, "Software environment of the clinical SURLAS;"

Petr Novak, PhD; William Straube, MS; Bibianna Cha; Robert Myerson, MD, PhD; Eduardo Moros, PhD, "Safety features of the clinical SURLAS."

Petr Novak, PhD; Buck Rogers, PhD; Jacob Locke, MD; Anurag Singh, MD; Andrea Zeug; William Straube, MS; Robert Myerson, MD, PhD; Eduardo Moros, PhD, "Initial experience with the SAHUS—a small animal hyperthermia ultrasound system."

Tej Pandita, PhD, "Genomic instability and enhanced radiosensitivity in Hsp70.1/3-deficient mice."

Joseph Roti Roti, PhD, "Potential effects of short (1-5 second) thermoexposures (+15 degree C) on DNA repair."

William Straube, MS, "The effect of hyperthermia applicators on radiation surface dose for simultaneous thermoradiotherapy."

Robert VanderWaal, PhD, "Heat-shock induced overlap of euchromatin and heterochromatin DNA replication."

Mai Xu, MD, PhD, "The effects of 41° hyperthermia on the DNA repair protein, MRE 11, correlate with radiosensitization in four human tumor cell lines."

Andrea Zeug; Dominic Thompson; Petr Novak, PhD; Kate Mazzerella; Eduardo Moros, PhD; Jacob Locke, MD, "Comparison of ultrasound versus waterbath hyperthermia on HeLa xenografts."

MIR AT THE SCIENCE CENTER



Right: An actual human brain is included in the traveling exhibit, which is now at the Science Center in Kansas, City, Missouri, through September 11, 2004.



Left: The PET III head scanner, one of the last scanners built on-site at the Institute, was part of Mallinckrodt Institute's contributions to the Science Center's focus on neurological research in St. Louis. When the traveling portion of the exhibit was taken to Kansas City, the scanner was returned to its permanent home in the Scott Avenue Imaging Center.

Above: The large, purple, alien-looking structures that made up the traveling brain exhibit at the St. Louis Science Center have moved on but, from January 31 through May 2, they helped to explain the electromagnetic workings and diseases occurring daily in our heads. *Brain: The World Inside Your Head*, produced by Pfizer Inc. in collaboration with the National Institutes of Health, provided adults and children with fascinating information about the most complex structure in the known universe: the human brain.

FOCAL SPOT

MALLINCKRODT INSTITUTE OF RADIOLOGY

Address Service Requested

POSTMASTER, Send
distribution changes or
address address to
Focal Spot editor
Mallinckrodt Institute
of Radiology at
Washington University
Campus Box 8131
510 South Kingshighway Blvd.
St. Louis, MO 63110
(314) 362-2866

Editor and Writer
Vicki Kunkler

Contributing Writers
Mary Jo Blackwood
Anne Kessen Lowell
Candace O'Connor

Photographers
Thomas Murry
Tim Parker
Steve Truesdell
Michelle Wynn

Design
Purviance & Company
Marketing Communications

Printing
Swift Print Communications
LLC


Focal Spot magazine is distrib-
uted three times annually.

www.mir.wustl.edu

© Mallinckrodt Institute of
Radiology, 2004

Non-Profit Organization
U.S. Postage
St. Louis, Missouri
Permit No. 2535

 Washington
University in St. Louis
SCHOOL OF MEDICINE

 Mallinckrodt Institute
of Radiology