

Spring 2003

Focal Spot, Spring 2003

Follow this and additional works at: http://digitalcommons.wustl.edu/focal_spot_archives

Recommended Citation

Focal Spot, Spring 2003, April 2003. Bernard Becker Medical Library Archives. Washington University School of Medicine.

This Book is brought to you for free and open access by the Focal Spot at Digital Commons@Becker. It has been accepted for inclusion in Focal Spot Archives by an authorized administrator of Digital Commons@Becker. For more information, please contact engeszer@wustl.edu.

SPRING 2003

VOLUME 34, NUMBER 1

anizati
ge
ssouri
2535

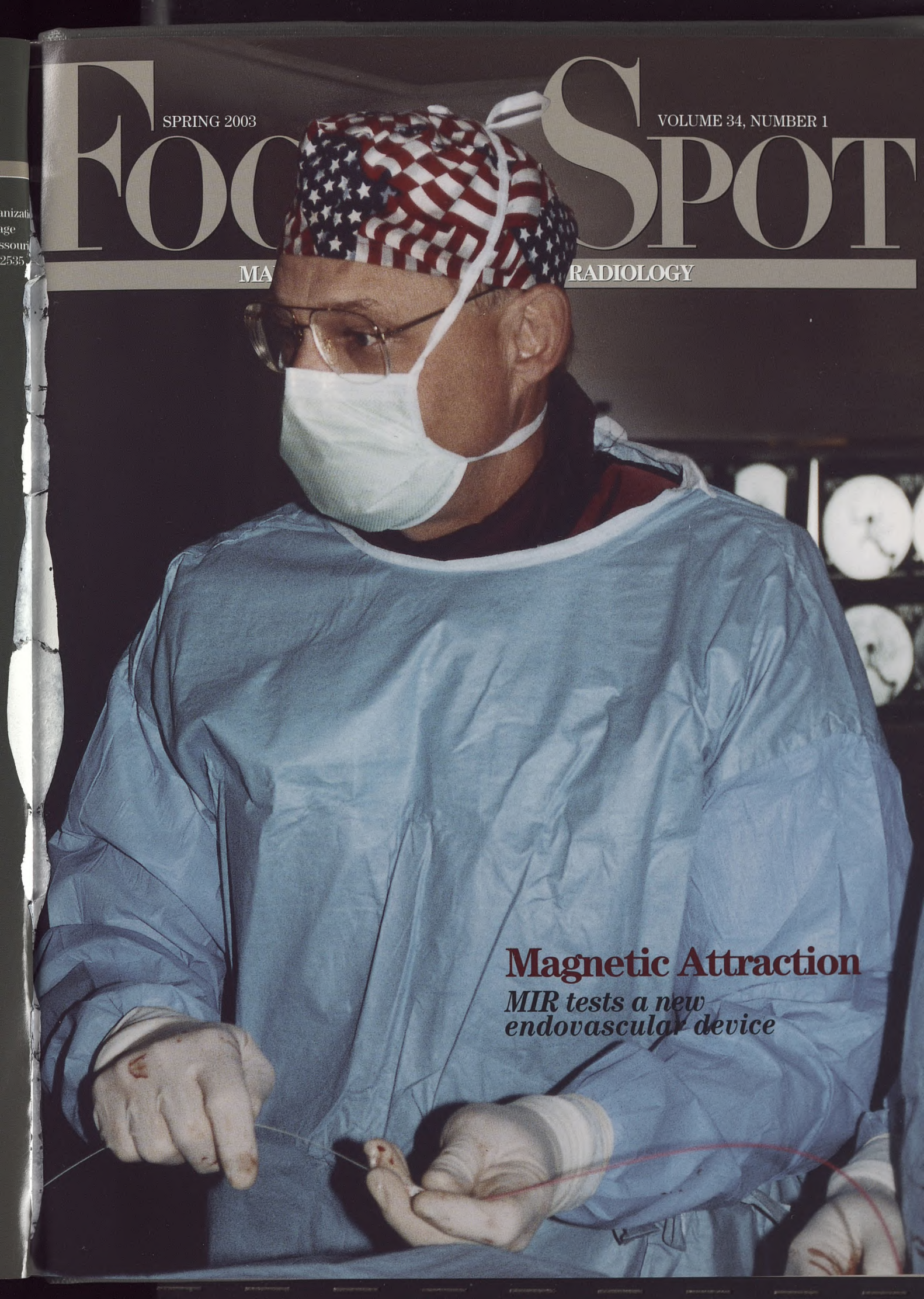FOCUS SPOT

MA

RADIOLOGY

Magnetic Attraction

*MIR tests a new
endovascular device*



If you have varicose veins, you don't have to undergo surgery to be rid of the pain, irritation, and cosmetic deformity.



no Veins, no Pain


Endovenous laser ablation is being performed as an outpatient procedure by Washington University interventional radiologists who are affiliated with the world-renowned Mallinckrodt Institute of Radiology.

Endovenous laser ablation has several advantages over vein stripping:

- No surgery.
- No hospital stay.
- No sedation or anesthesia.
- Resume normal activity the same day.
- Takes only 30 minutes.
- Leaves only a tiny scar.
- 97% successful in eliminating varicose veins.

Another plus is convenience. You'll be treated in the Center for Advanced Medicine, a new outpatient facility at the corner of Forest Park Boulevard and Euclid Avenue. Parking garages are just across the street.



 Washington
University in St. Louis


Physicians

MIR Mallinckrodt Institute
of Radiology

*If you have varicose veins,
call 314-362-2900 to schedule
a consultation with a physician.*

CONTENTS

FOCAL SPOT
SPRING 2003
VOLUME 34, NUMBER 1



LEADER OF THE PACS

4

The Picture Archiving and Communications System (PACS)—the latest advancement in diagnostic imaging technology—allows MIR's physicians to provide improved patient diagnosis, treatment, and care while increasing institutional efficiency.

HIPAA REGULATIONS AND THE PRIVACY RULE

10

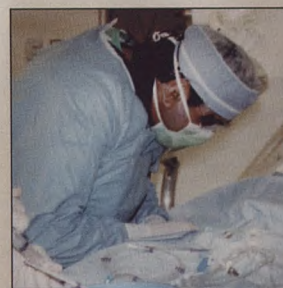For the first time in the history of the United States, a federal law gives patients more control of their medical information by regulating how health care providers create, secure, and share patients' protected health data.



MAGNETIC ATTRACTION: MIR TESTS A NEW ENDOVASCULAR DEVICE

14

Interventional neuroradiologists at Mallinckrodt Institute have an easier, more efficient way to treat neurological problems such as aneurysms: a magnetic-guided system to deliver therapeutic devices to the brain.



2.....SPOT NEWS



24.....FYI

SAVING YOUR EYES


20

Radiation oncologists and ophthalmologists at Washington University Medical Center are using radiation therapy as an effective conservation treatment for choroidal melanoma, the most common type of eye cancer in adults.



ON THE COVER Interventional neuroradiologist Christopher Moran uses the Telstar Magnetic Navigation System to successfully treat patients with aneurysms.
Photograph by Michelle Wynn.

SPOT NEWS



Botteron receives Presidential Award

For her magnetic resonance imaging (MRI) research in twins with mood disorders, Kelly Botteron, MD, associate professor of psychiatry (child) and of radiology, has received a Presidential Early Career Award for Scientists and Engineers. The award is conferred annually by the President in a ceremony at the White House. Botteron is the second Washington University faculty member to receive the award since its inception in 1996.

The Presidential Award is the highest honor given by the United States government to young scientists and engineers who show exceptional potential in their fields. The award program was established to enhance

the connection between fundamental research and the national goal of maintaining a leadership role in science and technology. Recipients are selected based on recommendations from 11 participating agencies, including the National Science Foundation, the National Aeronautics and Space Administration, the Environmental Protection Agency, and the Department of Health and Human Services/National Institutes of Health.

As part of the award, Botteron will receive funding for five years to support her research using three-dimensional MRI neuromorphometric techniques to examine genetic and environmental contributions to brain differences in children and adolescents with specific psychiatric disorders.

WUSM ranked second in U.S.

Washington University School of Medicine (WUSM) continued its tradition as one of the top five medical schools in the country, according to *U.S. News & World Report's* annual ranking of graduate and professional programs. Harvard University was ranked first; WUSM tied for second with Johns Hopkins University, followed by Duke University; the University of California, San Francisco; and Columbia, Stanford, and Yale universities.

For the sixth consecutive year, WUSM was ranked first in student selectivity and, for the third consecutive year, the physical therapy program was ranked first. Other top spots went to the internal medicine program (fourth), pediatrics (tied for sixth), molecular biology (tenth), neurosciences (sixth), occupational therapy (tied for third), and women's health (tied for ninth).

Now in its seventeenth year, the *U.S. News & World Report* rankings are based on varying criteria, including reputation, research activity, student selectivity, and academic surveys.

Heiken elected society president

Jay Heiken, MD, professor of radiology, chief of the abdominal imaging section, and codirector of body computed tomography, was elected the 2003-2004 president of the Society of Computed Body Tomography and Magnetic Resonance (SCBT/MR).

The SCBT/MR was established in 1977 to educate radiologists in the use of body computed tomography (CT) but subsequently broadened its focus in 1992 to include magnetic resonance (MR) imaging. Recently the Society opened its membership to include general members who are involved in the clinical practice of body CT and MR but do not fulfill the criteria for fellowship in the Society.

Mallinckrodt Institute faculty who are past presidents of SCBT/MR are Marilyn Siegel, MD, professor of radiology and of pediatrics; Dennis Balfe, MD, professor of radiology; and Stuart Sagel, MD, professor of radiology.

Second neuroradiology fellowship funded

Mallinckrodt Institute's interventional neuroradiology service has received a \$50,000 fellowship grant to support a second Endovascular Surgical Neuroradiology Fellowship position for the 2003-2004 academic year. The grant is administered jointly by the American Society of Interventional and Therapeutic Neuroradiology and the American Society of Neurological Surgeons/Congress of Neurological Surgeons Joint Section on Cerebrovascular Surgery. Funding is supported by the Boston Scientific Corporation/Target Therapeutics.

Colin Derdeyn, MD, associate professor of radiology, is director of the interventional neuroradiology fellowship program, which was the first of its kind to be approved by the Accreditation Council for Graduate Medical Education. The new fellowship is cosponsored by the departments of Radiology and Neurological Surgery.

Matching Program results announced

Sixteen physicians will join the Mallinckrodt Institute Diagnostic Radiology Residency Program; one of the 16 will participate in the Research Residency program. These promising trainees come from excellent medical schools: University of Wisconsin (1); University of Iowa (1); University of Pennsylvania (2); University of California, San Francisco (1); Emory University (2); Harvard University (1); University of Washington (1); Yale University (1); Washington University in St. Louis (5); and University of Louisville (1).

Two elected fellows

Dione Farria, MD, MPH, assistant professor of radiology, was elected a fellow of the American College of Preventive Medicine (ACPM), a national professional society for physicians committed to disease prevention and health promotion. ACPM members are uniquely trained in both clinical medicine and public health. Farria earned a national specialty board certification in Public Health/General Preventive Medicine in 1999. She is currently secretary of ACPM's Young Physicians Section. She recently was

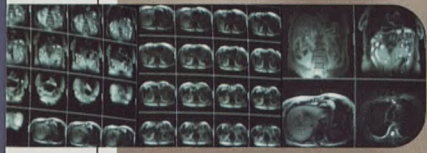
appointed to the American Cancer Society's Reach to Recovery Advisory Board, Heartland Division, and collaborated on *One Step at a Time*, a booklet and companion video that address women's concerns about breast cancer.

Steven Petersen, PhD, professor of neurology and neurological surgery, of psychology, of anatomy and neurobiology, and of radiology, was elected a fellow of the American Association for Advancement of Science (AAAS), the world's largest general scientific society. AAAS also publishes the renowned journal *Science*. Petersen is head of the neuropsychology laboratory, where behavioral and functional neuroimaging techniques—including functional MRI—are used to study the neural mechanisms involved in language, learning, memory, and attention. One current focus of his research is the normal and abnormal development of language, specifically the development of methods to statistically compare the imaging data of adults and of children.

Shimony receives foundation award

Joshua Shimony, MD, PhD, assistant professor of radiology, received the 2003-2004 Neuroradiology Education and Research Foundation/Boston Scientific—Target Fellowship in Cerebrovascular Disease Research. This prestigious award is sponsored by the American Society of NeuroRadiology, a unique collaboration of radiologists and scientists focusing on the specialty of neuroradiology.

The \$100,000 funding from the two-year fellowship will support Shimony's investigation of improved methods of measuring brain perfusion using dynamic susceptibility contrast (DSC) magnetic resonance imaging. He will apply these methods to the staging of patients with cerebral hemodynamic impairment.



MALLINCKRODT INSTITUTE OF RADIOLOGY (MIR) PHYSICIANS AND INFORMATION SYSTEMS EXPERTS ARE PARTICIPATING IN THE LATEST TECHNOLOGICAL REVOLUTION IN DIAGNOSTIC IMAGING. A Picture Archiving and Communications System, or PACS, is the backbone of a new technology that will soon relegate X-ray film and chemicals to the status of vacuum tubes and eight-inch floppy disks. MIR's physicians are demonstrating how this new technology can improve patient diagnosis, treatment, and care—and increase institutional efficiency.

Leader of the PACS

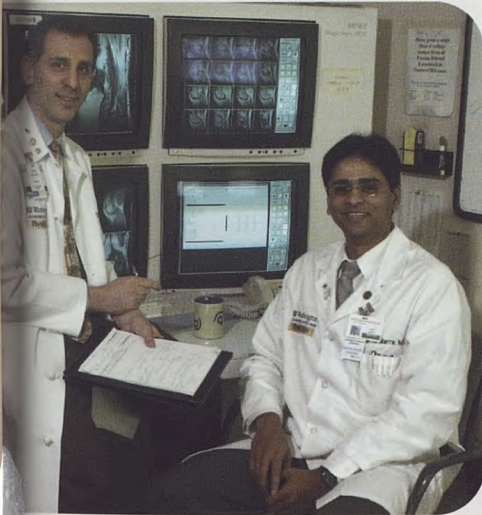
by

A N N E K E S S E N L O W E L L

PACS: A Snapshot

While a typical episode of a TV medical drama might have doctors shouting, "Where are the films?" and snapping an X ray into a view box, life with PACS at MIR is quite different.

MIR radiologists use banks of high-resolution computer terminals to load and view images. They can send images to referring physicians instantaneously—even if they are miles away—and confer on cases by telephone. And they can call up entire patient histories for comparison to new examinations.

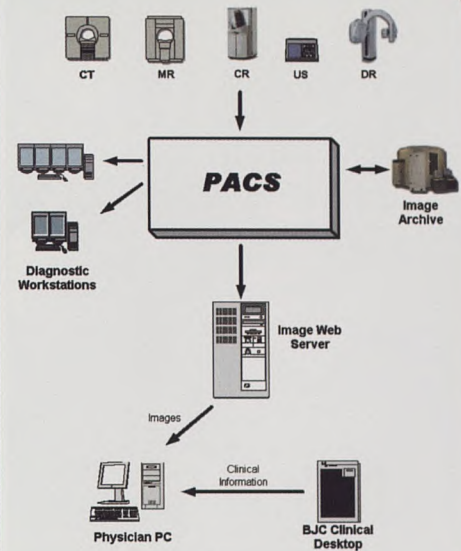


Pre-PACS

X-ray technology, the radiology standard of the past 100 years, is a multistep process. X rays produce the image of the anatomy being examined on film contained in a cassette. Once processed with

chemicals, a sheet of X-ray film can be interpreted by the diagnostic radiologist. The developed X ray must then be manually delivered to other physicians who wish to review the image. The advent of digital image acquisition made PACS possible. Digital radiography (DR) and computed radiography (CR) are two related technologies that acquire conventional X-ray images directly, using digital detectors. In seconds, the image is available for viewing on a high-resolution computer monitor.

But before PACS, digital exams had to be output to a sheet of film using a laser printer, in order to distribute copies to other physicians and to create an archival copy. The thousands of films produced each day required manual filing in warehouse-size libraries. Paper requests for films were collected several times daily; films were placed on a cart and wheeled to their destinations.



Left: David Rubin, MD (left) and Vamsidhar Narra, MD, at a PACS workstation on fifth floor of the Institute.



Laura Ruhwien and David Melson, shown at the back of the ImageWeb server in the Institute's East Building.

"We used to get films via 'Sneaker-Net,'" quips David Rubin, MD, chief of MIR's musculoskeletal radiology section. "It could take a day to get films from Barnes-Jewish West County Hospital to MIR."

PACS Enters the Picture

If film printing and storage is the horse-and-buggy pace for imaging technology, PACS provides warp speed. Digital radiology's electronic process opened up the potential for a new delivery system, bypassing the need for hard copy printouts, manual filing, and retrieval by cart. As computer technology advanced during the 1990s, computer scientists designed networks capable of compressing, storing, and delivering digital radiology images. Improvements in monitor resolution and the proliferation of high-speed networks spurred the development of PACS. Now, as soon as digital exams are completed, PACS simultaneously sends them to the radiologist for diagnosis, then places the exams in an electronic archive, and allows them to be accessed by physicians over a secure network.

Vamsidhar Narra, MD, codirector of MIR's body magnetic resonance imaging group, believes PACS has transformed radiology practice. "PACS has immensely improved our ability to look at images quickly, without being restricted by distance. It has had a direct impact on patient care."

The size and quality of the network and supporting software in PACS is key. MIR's Information Systems group dedicated years of effort to design a PACS network that could manage the huge volume of images coming through the system daily. As one of the largest radiology centers in the world, MIR processes about 1,250 exams—which, in turn, produces more than 97,000 images—through PACS every day.

Laura Ruhwien, director of information systems, describes the challenges of creating a solution to fit MIR's unique demands, "When we started working on PACS, none of the vendors could handle the volume of images in our system. Our strategy has been a 'best of breed approach.' We select the best vendor in each area and use our in-house expertise to customize the applications to meet our needs."

There are more than 75 digital imaging devices at four locations (MIR, Center for Advanced Medicine, Barnes-Jewish Hospital, and Barnes-Jewish West County Hospital) sending images to the PACS. To handle the volume, several servers at each site receive images and deliver them to radiologists in minutes. At the same time, images are archived on backup tapes in two separate locations.

ImageWeb: special delivery

PACS provides primary functions within the radiology department: providing images for diagnostic interpretation and sending them to the electronic archive. To provide electronic image access to other physicians, MIR is deploying a secure, high-speed, web-based delivery system called ImageWeb.

Although the deployment of this system is not complete, the goal is to allow MIR radiologists and referring physicians to call up patient exams from dozens of workstations equipped with special software that are distributed throughout the BJC HealthCareSM system, or from their homes. And with the integration of ImageWeb with Clinical Desktop, BJC's enterprise-wide electronic medical record, a wide spectrum of clinical information—lab values, histories, clinical notes, radiology reports, and now radiology images—will all be available.

Eventually, as cost, translation software, and security technology allow, MIR radiologists may be able to consult on cases in remote locations, extending MIR expertise around the globe. The technology also allows simultaneous viewing of images, a feat not possible before PACS. Urgent-care patients in the emergency department with multiple medical needs may have their tests analyzed by the ER physician and the neurologist at once, drastically reducing the time to diagnosis and treat multiple injuries.

PACS IS HELPING RADIOLOGISTS AT MIR AND THROUGHOUT THE BJC SYSTEM TO OPERATE WITH GREATER EFFICIENCY.

A history lesson

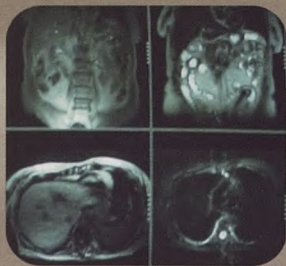
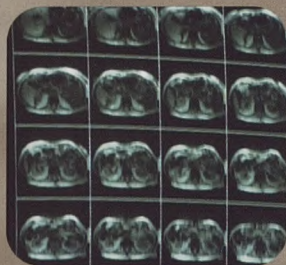
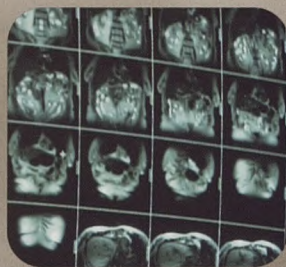
With PACS, radiologists can bring up a patient's history of exams for comparison to the latest images, known as "pre-fetching." "With PACS, I can compare exams with prior films," says Narra. "This is especially important for followup of certain cancers, in measuring disease processes." Although currently PACS can only bring up digital images taken at Barnes-Jewish or Barnes-Jewish West County hospitals, future generations may allow an entire radiologic history to be viewed, including exams from any institution.

Digital images can be measured and manipulated to a very high degree of accuracy using PACS. Measuring features on X-ray film or digital printout requires radiologists to manually place rulers against the film and eyeball the measurements. With PACS, diagnosticians have much higher precision, using mouse-driven measurement and the computer's calculation tools. PACS also allows contrast adjustment on screen, to highlight particular areas of concern.

HIPAA

PACS helps MIR comply with the federal government's tough new patient safety and privacy regulations, known as the Health Insurance Portability and Accountability Act, or HIPAA. Electronic archiving of images prevents patient records from being lost; patient data is encrypted in the system to prevent unauthorized viewing of information. Patient confidentiality is always in the forefront during technical design of PACS, and dedicated network equipment prevents hackers from gaining entry into the system.

Leader of the PACS



Radiologic examinations shown on PACS.

Improved institutional efficiency

PACS is helping radiologists at MIR and throughout the BJC system to operate with greater efficiency. Although cost savings is not the primary motivation behind PACS, rapid access to images, coordination, and elimination of lost films all help to improve the bottom line. Eventually, as print images are phased out, printing and processing costs will drop dramatically. Estimates on cost savings vary, but according to some computer specialists a single tape costing \$70 can store about 1,300 exams, which if processed on film would cost over \$4,000.

Managing the workload for 75 staff radiologists, 29 fellows, and 66 residents is no easy task. Enter PACS, with its capability to organize and manage daily workflow. Each day, PACS distributes a list of exams to be read by radiologists at their workstations. With mouse and keyboard, MIR staff can interpret exams, dictate cases, consult with referring physicians, and complete cases efficiently. Future enhancements to the system may include load balancing—taking the case-load of individual radiologists into account throughout the day as PACS distributes cases.

MIR CONTINUES TO IMPROVE THE PACS TECHNOLOGY AND TO ADOPT NEW STRATEGIES TO UNLOCK ITS POTENTIAL.

At MIR and every major medical institution, before the advent of PACS, lost films were at best an annoyance and at worst a liability. Virtual storage, simultaneous sharing, and on-call availability of PACS means images are seldom lost.

Gary Brink, director of radiology at Barnes-Jewish Hospital, has tracked improvements in department efficiency with PACS. "Prior to PACS, only sixty percent of diagnostic reports were completed within twenty-four hours. Today we have an eighty-one percent completion rate in that timeframe. And because of lost films and long delays in returns of loaned films, we could not bill for exams that were not officially completed. The non-billed list is now less than one tenth of one percent of total volume."


Electronic storage offers other advantages over the film library: images do not decay over time, and storage space needs are drastically reduced. MIR currently stores electronic images on tapes, accumulating two terabytes of data every six months. A terabyte contains one thousand times the storage space of a gigabyte. The equivalent physical storage space needed for films would be several hundred square feet. With institutional space needs growing rapidly, freeing up space provides more room for staff and patient needs and reduces facility expenses. Eventually, storage needs will be described in petabytes—a quantity equal to one thousand times a terabyte.

PACS: The Next Frontier

MIR continues to improve the PACS technology and to adopt new strategies to unlock its potential. The current challenge is to expand the imaging integration with BJC HealthCare's patient information system, Clinical Desktop, in a step toward a totally electronic medical record. David Melson, MIR's manager of imaging applications, believes the department is up to the challenge. "We are tackling an enterprise-wide solution; few institutions are attempting such a large and complex effort. It will be an exciting development," he says.

Narra and Rubin agree that rolling PACS seamlessly into Clinical Desktop will offer unmatched efficiency and convenience for clinicians and referring physicians. Adding voice transcription and load balancing features to the system will also be a significant advantage.

Gilbert Jost, MD, director of Mallinckrodt Institute and chairman of the Department of Radiology, is pleased with the progress so far. "We still have a lot of work to do, but we have come a long way," he says. "A decade ago, the idea of managing our images electronically was only a pipe dream, but today it is becoming a reality. Certainly the evolution of PACS technology is one of the most important developments in the history of our specialty, and it is satisfying to see it taking hold here at Mallinckrodt Institute." 




Gilbert Jost, MD

A close-up, blurred photograph of a computer keyboard with a blue color cast. The keys are out of focus, creating a bokeh effect with light reflecting off the surfaces.

HIPAA

Regulations and the Privacy Rule

by Vicki Kunkler



In 1996

when then-President Clinton signed into law The Health Insurance Portability and Accountability Act (HIPAA), the legislation was hailed as a sweeping change affecting the efficiency and effectiveness of the United States health care system. Simply put, HIPAA is about creating, securing, and sharing protected health information.

The intent of this law was to ensure that employees who lost or changed jobs could maintain their health insurance. Title II of HIPAA required that all electronic processing and tracking of patient information be regulated by nationwide standards adopted by the U.S. Department of Health and Human Services. Title II made it easier for health plan administrators, physicians, hospitals, and other health care providers to process claims and collateral transactions electronically.

The legislation also provided guidelines for making health insurance more affordable and, in turn, accessible for U.S. citizens. Congress was given a deadline to enact privacy legislation to ensure that medical records and patient health information were protected from inappropriate disclosure and use—a watershed event because there was no federal regulation, only widely diverse state laws, for health information privacy and security.

The Standards for Privacy of Individually Identifiable Health Information (the Privacy Rule) became effective on April 14, 2001, and provided guidelines for entities providing health care, including health plans, health care clearinghouses, hospitals, and pharmacies. All health care providers (except small health plans) who transmit medical information electronically had to be HIPAA-compliant by April 14, 2003; small health plans were given a one-year extension.

CONFIDENTIAL



WHAT DOES THIS LAW REALLY DO?

For the first time, patients have more control over their medical information. And patients have a federal guarantee that their medical records and personal health information cannot be shared with anyone without their specific authorization. Conversely, a revocation of consent must also be in writing by the patient. Patients can now make informed choices about how their medical information is to be used. Patients also have the right to examine a copy of their own health records and to request that appropriate corrections be made to those records.

The law will hold any violator of patient privacy accountable through civil and criminal penalties. Specific language is provided for health care entities about safeguards for protecting health information privacy and about boundaries for the use and release of health records. And the law provides an important and necessary balance regarding public disclosure of some forms of health data in order to protect the health of all U.S. citizens, such as disaster relief circumstances.

WHO HAS TO COMPLY?

As required by Congress, the Privacy Rule covers health plans, health care clearinghouses, and all health care providers who handle financial and administrative transactions electronically. These covered entities, as they are called under HIPPA, are subject to the new privacy standards; if covered entities use outside contractors (called business associates under HIPPA) to perform some functions, the business associates also are bound by HIPAA/Privacy Rule regulations.

HOW DOES THIS LAW AFFECT THE USE OF PATIENT INFORMATION TO TRAIN HEALTH CARE PROVIDERS?

A specific portion of the law provides for "conducting training programs in which students, trainees, or practitioners in areas of health care learn under supervision to practice or improve their skills as health care providers." Medical trainees are permitted access to patients' medical information on a "minimum necessary use" basis.



HOW WILL THESE REGULATIONS AFFECT THE DELIVERY OF HEALTH CARE?

The Department of Health and Human Services asserts that covered entities are provided with “substantial discretion as to how to implement the minimum necessary standard and how to appropriately and reasonably limit access to the use of identifiable health information within the covered entity.” The short response is that HIPAA and the Privacy Rule recognize that health care providers are in the best position to know and determine who needs access to personal health information in order to treat the patient.

HOW WILL RADIOLOGY AND RADIATION ONCOLOGY DEPARTMENTS BE AFFECTED?

HIPAA impacts all aspects of radiology and radiation oncology, including billing and collections, imaging technology, documentation, teleradiology, patient contact, and treatment planning. Employees in all areas of the departments must receive training in HIPAA compliance, including physicians, technologists, medical physicists, information systems personnel, administrative employees, and business managers.

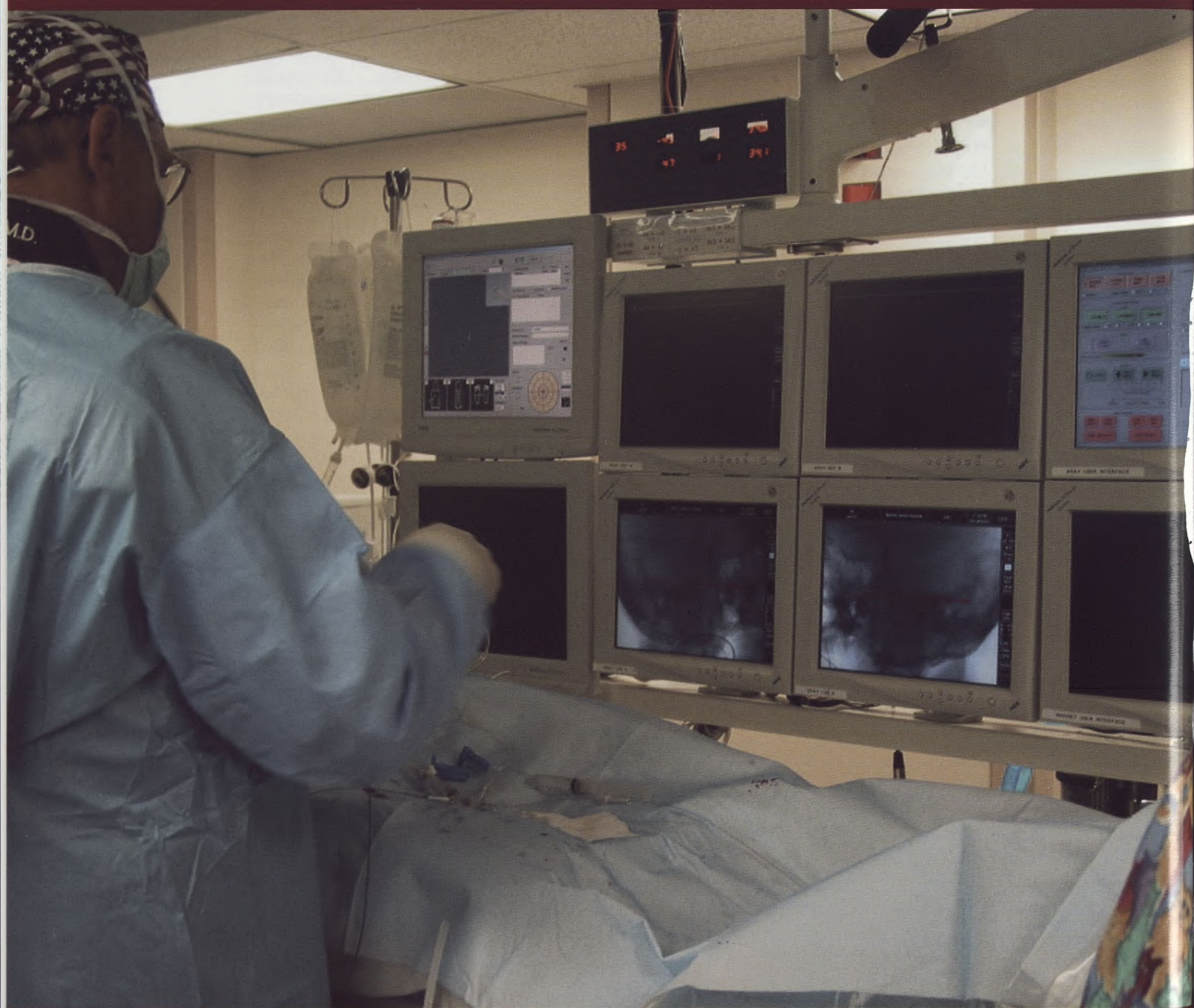Radiology departments are in especially good positions in regard to HIPAA compliance. The past decade has brought tremendous change in radiology technology, especially in computer-based systems—a virtual digital revolution. The installation of all-digital imaging in large radiology centers has forced those departments to institute even more stringent measures to protect their patients’ privacy while delivering the best quality health care. ■■■

Note: This article is a compilation of information from several sources, including United States Department of Health & Human Services (www.hhs.gov); American College of Radiology (www.acr.org); Radiological Society of North America (www.rsna.org); Decisions in Imaging Economics (www.imagingeconomics.com); and Office for Civil Rights (<http://aspe.os.dhhs.gov>).

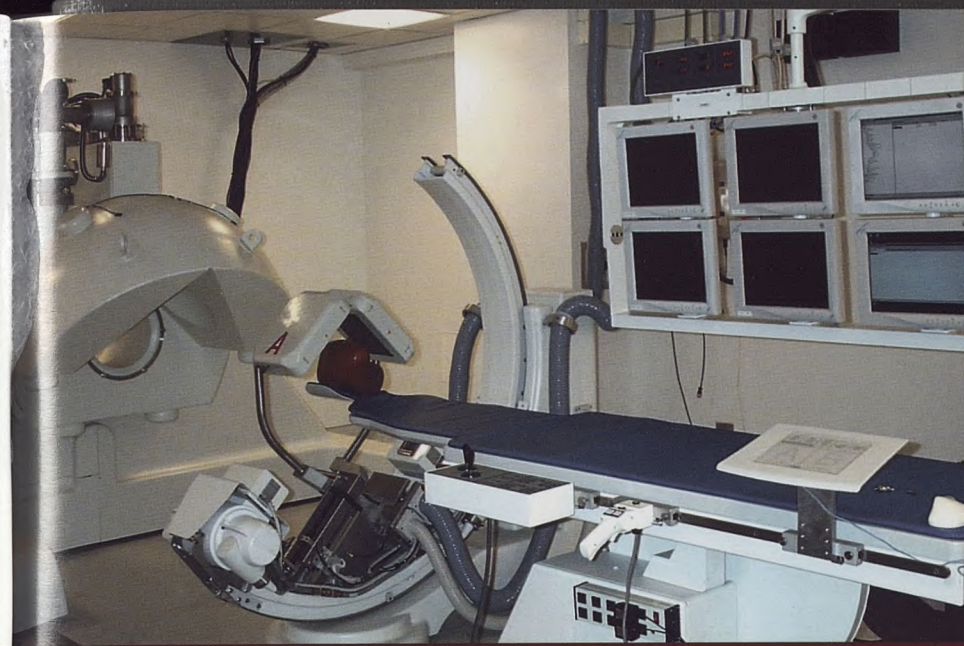
CONFIDENTIAL

Magnetic ATTRACTION:

MIR TESTS A NEW **ENDOVASCULAR DEVICE**



BY CANDACE O'CONNOR



Suddenly, the 75-year-old Illinois woman began having severe headaches that seemed to start deep inside her head. Imaging studies revealed the problem: a bulging, 12-millimeter aneurysm that would need treatment before it ruptured. On this March morning, she will undergo an innovative procedure, now in clinical trial, performed by Christopher Moran, MD, an interventional neuroradiologist at Mallinckrodt Institute of Radiology (MIR). He will use a magnetic guidance system called Telstar to maneuver a guidewire and catheter up from the patient's thigh, through her blood vessels, to the aneurysm, which Moran will fill with soft platinum micro-coils. Ideally, that should cause the aneurysm to clot, and blood flow should return to its normal path.

The Telstar Magnetic Navigation System is the latest refinement in the fast-growing field of endovascular surgery, which started in the 1970s. Then interventional radiologists tried placing large catheters in a patient's neck vessels as close as possible to the site of arteriovenous malformations (AVMs) or meningiomas, which they hoped to plug up with bits of gelfoam, surgical sponge, or tiny silicone beads. But this procedure had a serious limitation: It relied on blood flow to sweep the foam or sponge along—and sometimes that flow would take the material to the wrong place.

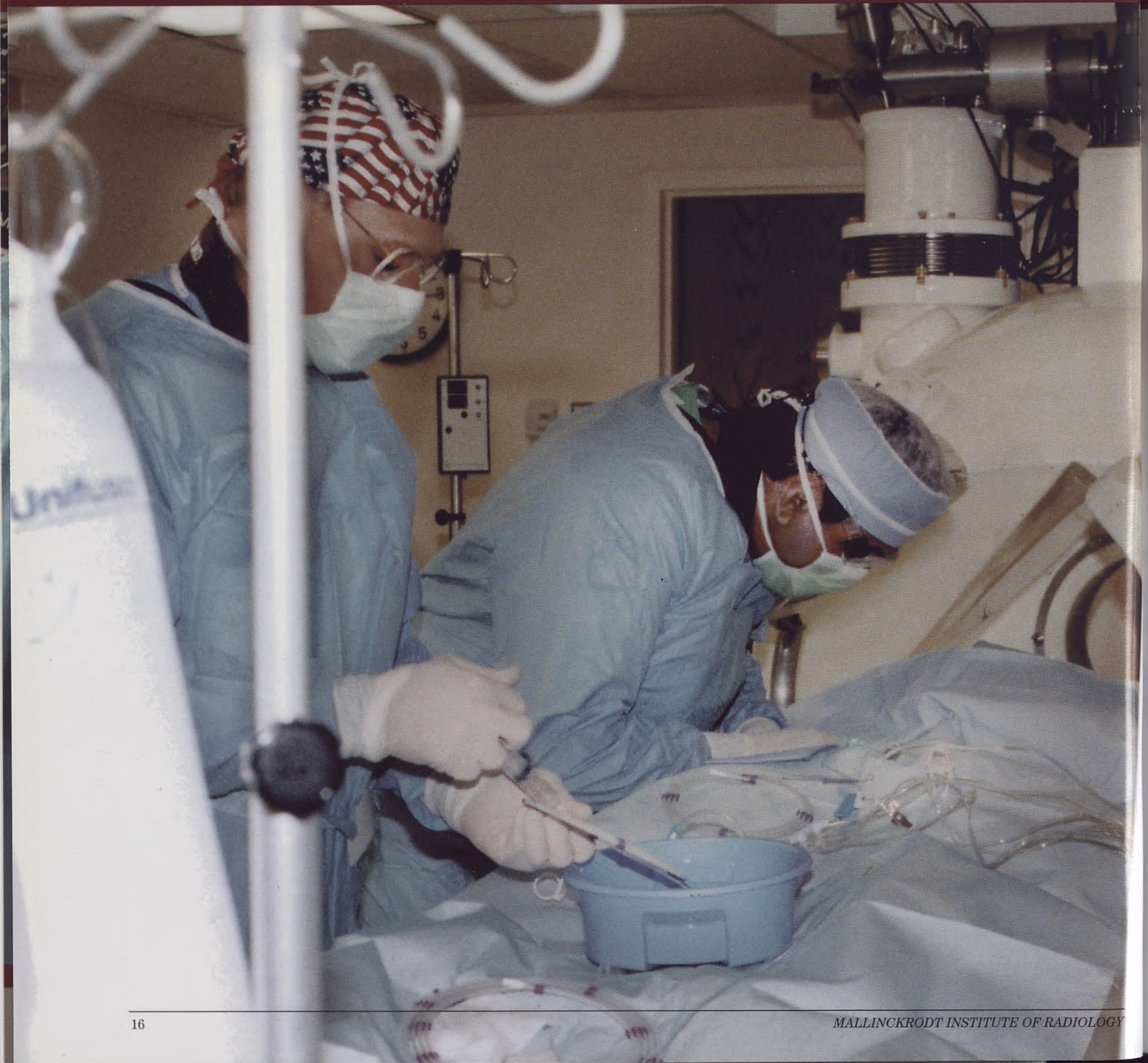
By the early 1990s, something new was available: microcatheters less than a millimeter wide. Not only were these microcatheters half or one third the size of the earlier catheters, they were also made of silicone and extremely flexible. "Like a piece of well-cooked angel hair pasta," says Moran, professor of radiology. "You couldn't push them; it was like pushing wet spaghetti. But the microcatheters were so flexible that the flow would take them to the AVM."

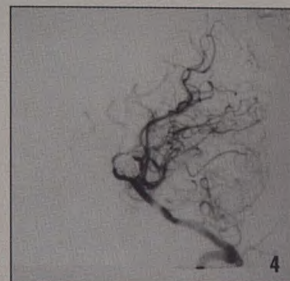
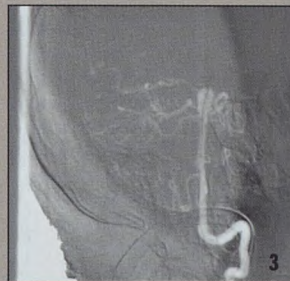
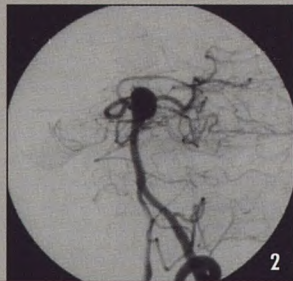
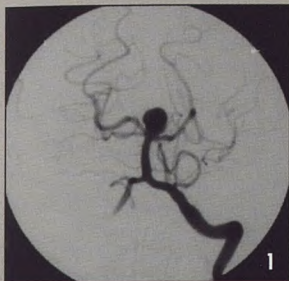
Left: Doctor Christopher Moran monitors the path of the magnetic guidewire.
Above: The Telstar Magnetic Navigation System. Photo courtesy of Stereotaxis, Inc.

Moran and Arvind Nehra, MD, prepare the catheter, guidewires, and micro-coils used in this endovascular procedure.

Another innovation followed: smaller versions of the guidewires that had existed for several decades. With these wires, which have tips bent into a "J" shape, physicians were able to twist the guidewire to select a vessel supply-

ing the lesion, snake the wire to the area, and push the catheter over the wire. Then they could retract the wire and use the catheter to administer material designed to obstruct the blood vessel, such as medications, glues, particles, or





coils. Yet this process is tricky, since the guidewire is difficult to maneuver and can twist or kink. There are also attendant risks, primarily the accidental perforation of a blood vessel or an aneurysm's weak spot—a complication that can be fatal.

Clearly, it is crucial to get to the aneurysm as quickly and safely as possible. That's where Telstar comes in, the product of a young St. Louis company called Stereotaxis, Inc., located in the Center for Emerging Technologies on Forest Park Avenue.

In the late 1980s, University of Virginia researchers began looking at the use of magnets in treating tumors, a concept that intrigued neurosurgeon Ralph Dacey, MD, then on the Virginia staff and now the neurosurgery department chairman at Washington University School of Medicine (WUSM). With Dacey's support, Stereotaxis has since worked closely with WUSM investigators, including Moran, to test evolving magnetic guidance concepts.

The patient, prepped and anesthetized, is lying on an operating room table, with a helmet-shaped magnet ready overhead as the medical team goes to work. The physician makes an incision in the patient's thigh, then slips a magnet-tipped wire into her femoral artery, through a tortuous maze of blood vessels and into her brain. During this time, the team checks their progress on fluoroscopic "road maps" projected on nearby monitors. Every so often, they need to make a sharp turn with the wire, and Moran brings the superconducting magnet into play. It does not pull the wire along but rather directs it, helping Moran and Arvind Nehra, MD, an interventional neuroradiology fellow, to navigate the wire safely and accurately around these difficult bends.

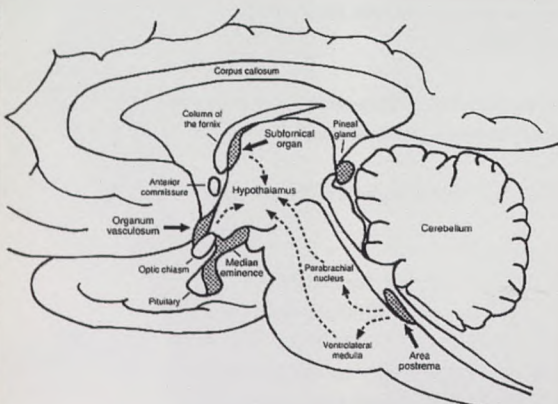
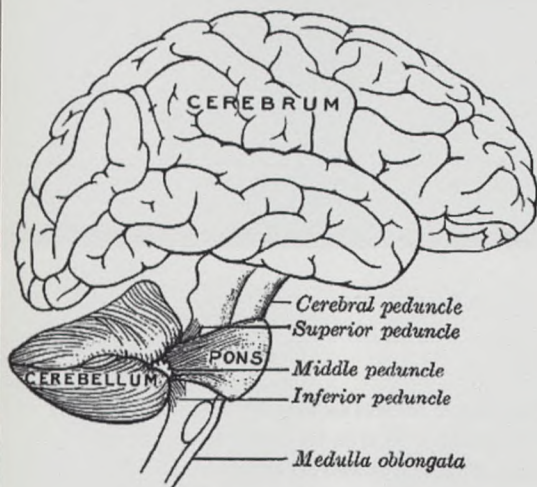
1) AP pretreatment. The area postrema (AP) on the back of the medulla is one of the few areas in the brain where the blood-brain barrier is lacking. The dark round mass in the center of the image is the aneurysm.

2) Lateral view pretreatment. Aneurysm is clearly visible.

3) During placement of micro-catheter and guidewire in aneurysm (white portion of image).

4) Micro-coils have been placed in the aneurysm.

Mallinckrodt Institute researchers and Moran, who joined the MIR faculty in 1978 after completing a residency in diagnostic radiology and a fellowship in neuroradiology, began working with Stereotaxis in the late 1990s to test a magnetic guidance prototype in animal studies. "We had to show that the guidewire would move where we wanted it to," says Moran. "Even more basically, we didn't know how well we would be able to see in this environment, how good the images would be.



When we first saw that the guidewire turned, that the X rays and the magnet worked together, I remember saying ‘holy cow, this thing really *does* work.’”

In 2002, both WUSM and Rush-Presbyterian-St. Luke’s Medical Center in Chicago began a clinical trial of the Telstar device, with the goal of accruing 30 patients. So far WUSM has recruited ten patients; with the complement of Chicago’s patients, the trial is nearly complete. The treatment these patients have received comes from a first-generation Telstar system, in which the magnet is powered by liquid helium cooled to absolute zero. The next generation Stereotaxis system, called Artis Axion Niobe Magnetic Navigation, will be powered by stable permanent magnets. Despite some initial problems with maneuverability, says Moran, Telstar has in general worked very well.

Not only do these devices have myriad applications in patients with neurological problems—including aneurysms, occlusions, AVMs, and potentially intra-arterial stroke therapies, and gene therapy—they are also used extensively in cardiac procedures. Recently, the Food and Drug Administration approved Telstar for electrophysiology procedures in patients suffering from irregular heartbeat. Washington University is acquiring a Niobe unit for use in its cardiology department, as will the University of Oklahoma,

which already has a Telstar system reserved for cardiology procedures. Other applications, such as renal arteriograms, are future considerations.

A gray, amoeba-like shape appears on the roadmap: the aneurysm. With more than six feet of guidewire now retracted, the catheter is in place and Moran begins placing coil after coil, in a range of sizes. Soon the coils fill every space in the aneurysm, which begins to turn black on the fluoroscopic monitor. Moran calls for repeated arteriograms to chart his success. In the end, he will use 11 of the Slinky®-like coils to complete the job. Two hours later, the procedure is finished. On the screen, the blood flow is plainly visible, back on its normal path.

The standard criterion for treating aneurysms is a surgical procedure in which the neurosurgeon drills a hole in the patient’s skull, penetrates to the aneurysm, and clips it off—an effective solution. However, this is also highly invasive; to reach the aneurysm, the surgeon must displace sensitive brain tissue, and even then the aneurysm itself sometimes blocks the surgeon’s view. In some cases, endovascular surgery is a better

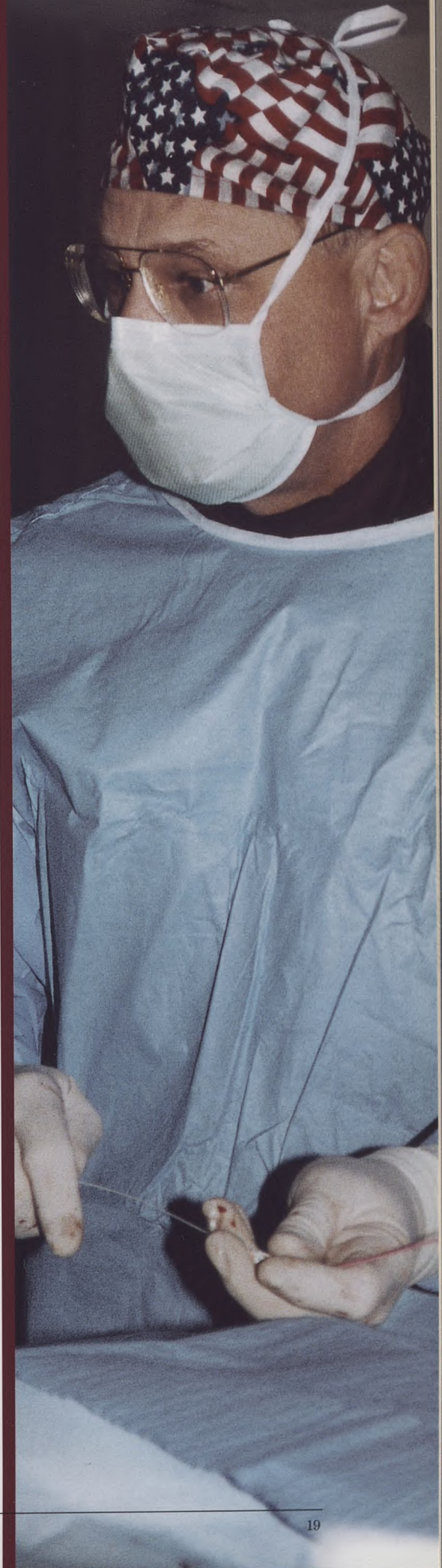approach, especially for hard-to-reach neurovascular defects. And increasingly, patients are choosing this less-invasive approach over conventional surgery.

In fact, the growing interest in this field has led recently to a neuroradiology boom. When Moran joined the American Society of Neuroradiology in 1978, it had only 300 members; now there are 6,000—a growing number of these members are interventional neuro-radiologists like Moran. “Prior to 1995, we were probably doing fifty procedures per year,” he says, “and now we are doing three hundred and fifty—that’s one-and-a-half cases per day, really a major advance.”

That could mean fierce competition for patients among the nation’s 6,000 neurosurgeons, but Moran says that at Washington University the two groups work collegially. Each Friday morning, neuroradiologists Moran; DeWitte Cross, MD; and Colin Derdeyn, MD, meet with the neurosurgeons—Dacey; Michael Chicoine, MD; Robert Grubb, MD; Keith Rich, MD—to discuss what is best for each patient. Sometimes they decide that endovascular surgery, with or without Telstar, is the best approach. In other cases, such as middle cerebral bifurcation aneurysms, conventional neurosurgery is necessary.


Most of the time, patients who have had an endovascular procedure stay overnight in the intensive care unit and go home the next day. Perhaps 99 percent of all complications in endovascular surgery (primarily arterial perforations or the formation of clots on the catheters or guidewires) occur during the surgery itself, so the aftermath is usually uneventful. Patients come back for an arteriogram three to six months later, then at 18 months or two years. Some 10 percent of the time the coils have compacted, and the patient will have to undergo a new procedure in which more coils are added.

In this case, the patient will go home soon, free from her blinding headaches. “It went great, couldn’t have been better,” says Moran jubilantly. Patients who have undergone this procedure are always pleased, he adds. “After the anesthetic wears off, they ask how the procedure went, how the magnetic guidance did, and they are happy to hear it all went well. These patients feel they’ve contributed something to the advancement of science, and I think they take a certain satisfaction from that.” **TIME**



SAVING YOUR EYES

Radiation therapy is being used to treat ocular melanoma while preserving the eye.



ocular melanoma, or cancer of the eye, is one of the rarest forms of cancer. But choroidal melanoma, a tumor affecting the pigmented portion (choroid) of the eye tissue, is the most common type of eye cancer in adults. Over time, the tumor can enlarge, cause vision loss, and spread to other parts of the body.

by Vicki Kunkler

App
dia
Am
cen
has
sur
Nov
oph
Uni
rec
as
tre
cho

tre
fift
gist
wit
tech
the
sou
tre
pro
and
lar
reg
bra
tre
rad
ogis
bra

Approximately 2,000 cases are diagnosed per year in North America and for more than a century, the standard treatment has been enucleation—or surgical removal of the eye. Now, radiation oncologists and ophthalmologists at Washington University Medical Center are recommending radiation therapy as an effective, conservation treatment for medium-size choroidal melanoma.

“Radiation has been used to treat ocular melanoma for around fifty years,” says radiation oncologist Hsiu-san Lin, MD, PhD, “but within the past twenty years, the technique has been refined with the availability of better radioactive sources and the advent of practical treatment planning software.” Lin, professor of radiation oncology and associate professor of molecular microbiology, heads the bistate region’s only active eye plaque brachytherapy center. The center’s treatment team is comprised of a radiation oncologist, an ophthalmologist, a medical physicist, and a brachytherapy technologist.

In eye plaque brachytherapy, small radioactive seeds are embedded in a plaque—a bowl-shaped device made of gold—that is fitted to each patient. Patients receive either local or general anesthesia during the surgery to implant the plaque, which takes one to two

hours. The ophthalmologist makes a small incision in the membrane (conjunctiva) covering the outside of the eye and sutures the plaque onto the surface of the eye over the base of the tumor. The conjunctiva is then sutured back into place over the plaque.



SYMPTOMS AND DIAGNOSIS OF CHOROIDAL MELANOMA

SYMPTOMS



- May be no symptoms; most choroidal melanomas are found during routine eye examinations.
- May see flashes of light.
- May experience distortion or loss of vision.
- Misting of the lens of the eye (cataract).
- May detect floating objects (floaters) in vision.

DIAGNOSIS

- Usually determined by a complete eye examination performed by eye cancer specialists.
- Diagnostic radiology examinations, such as ultrasound, fluorescein angiography, computed tomography, or magnetic resonance.
- Specialized photography (to examine the circulation within the tumor).
- Biopsies occasionally necessary.

Above: Radioactive seeds are implanted in the plaque. (Note: nonradioactive seeds were used for photo purposes).

SAVING YOUR EYES



Doctors Lin (above) and Harbour have clinical offices in the Center for Advanced Medicine at Washington University Medical Center.

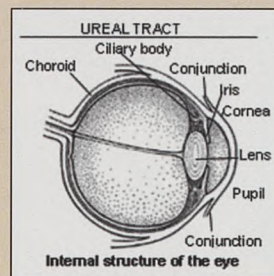
High doses of ionizing radiation from the radioactive iodine (I25) seeds can be directed via the plaque to the tumor, while sparing healthy surrounding tissue. The cells begin to die and, in most cases, the tumor begins to shrink within two to three months of therapy. Surgery—taking less than an hour—is required to remove the plaque and is usually performed within three to seven days following implantation.

“Most importantly, the eye is preserved, there is no cosmetic disfiguration, some visual function is retained, and no harm is caused to the other eye,” says Lin. “Our success rate in eradicating the tumor in the eye is ninety-five percent, and the rate of tumor recurrence is quite low with brachytherapy.”

Lin works closely with William Harbour, MD, associate professor of ophthalmology and director of the Ocular Oncology Service at Barnes Retina Institute at Washington University Medical Center. On average, Harbour refers 30 patients annually for eye plaque brachytherapy.

ARE YOU AT RISK?

- Median age of patients is 55 years.
- Incidence is equal in male and female population.
- More common in people of northern European descent.
- Incidence somewhat higher in Sunbelt area of United States.



Under Harbour’s leadership, Washington University was one of 43 clinical centers in

the United States and Canada that participated in the Collaborative Ocular Melanoma Study (COMS). Initiated in 1986, the study was supported by the National Eye Institute and the National Cancer Institute, both affiliated with the National Institutes of Health. One of the COMS goals was to determine through a randomized, controlled clinical trial whether patients with medium-size choroidal melanomas treated with eye plaque brachytherapy would survive as long as those patients who underwent enucleation. A medium-size tumor was defined as 2.5 millimeters to 10.0 millimeters in apical height and 16.0 millimeters or less in basal diameter.

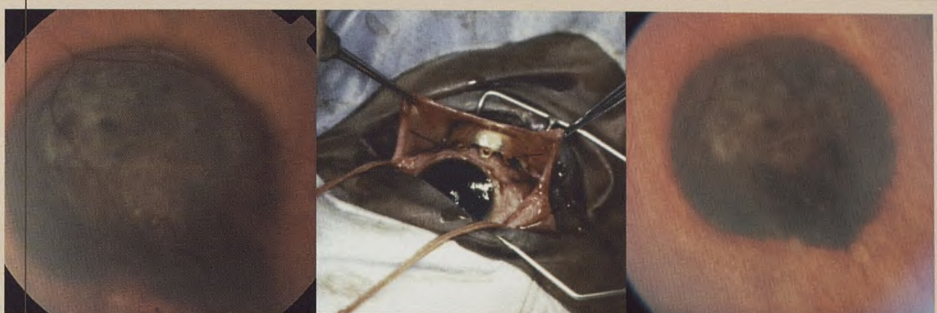From the more than 8,700 patients screened, there were 1,317 patients enrolled and clinically observed through mid 2000. Patients consented to be randomly assigned to undergo either enucleation or brachytherapy. The initial COMS findings

published in 2001 reported the same survival rates for patients who had radiation therapy as for those patients who had the diseased eye surgically removed. As a result of this study, most ocular oncology centers are recommending more brachytherapy and less enucleation in appropriate patients.

Another issue to consider is the patient's quality of life. In brachytherapy, there is a chance of vision loss in the irradiated eye, but most patients retain useful vision. In less than five percent of patients, severe radiation complications require that the eye be removed. Patients undergoing brachytherapy have generally responded more positively to quality of life studies than have patients undergoing enucleation.

"Due in large part to the outstanding collaborative relationships that we have with Doctor Lin's group, our Ocular Oncology Service has grown into one of the top ten referral centers nationally for the treatment of eye cancer," says Harbour. **III**

Editor's note: The Washington University Ocular Oncology Service at Barnes Retina Institute provides more information about eye cancer on their website: <http://eyetumor.wustl.edu>.



BRACHYTHERAPY VERSUS ENUCLEATION

BRACHYTHERAPY

Pros

- Preservation of eye.
- No cosmetic disfiguration.
- 80% or higher success rate, on average.
- Complications to other eye or other facial anatomy virtually eliminated.
- When successful, tumor is destroyed.
- Destroys tumor about 90% of time.

Cons

- May cause vision loss to treated eye due to radiation damage.
- Added costs for radioactive plaque, longer hospital stay, and second surgery to remove plaque.
- May be some dryness in eye, which can be alleviated with eye drops.

ENUCLEATION

Pros

- Maximize local tumor control.
- Higher success rate for large tumors.

Cons

- Immediate loss of eye.
- Prosthesis needed.
- Reduced visual field when looking straight ahead.
- Loss of depth perception.
- Prosthesis does not move as well as natural eye.

Above left: Prior to treatment with brachytherapy: The melanoma is shown in the back of the eye, under the retina.

Above middle: Intraoperative view of a plaque in place.

Above right: Two years following brachytherapy: There is tumor regression/shrinkage with good local control.

FYI

In this section, the names of employees who are full-time faculty or staff or who have an appointment in the Department of Radiology or Department of Radiation Oncology are highlighted in boldface type.

PROMOTIONS

Erbil Akbudak, PhD, research instructor in radiology, was promoted to assistant professor of radiology, Division of Radiological Sciences, Department of Radiology.

Jason Lewis, PhD, research instructor in radiology, was promoted to assistant professor of radiology, Division of Radiological Sciences, Department of Radiology.

Christopher Moran, MD, associate professor of radiology, was promoted to professor of radiology, Division of Diagnostic Radiology, Department of Radiology.

David Reichert, PhD, research instructor in radiology, was promoted to assistant professor of radiology, Division of Radiological Sciences, Department of Radiology.

David Rubin, MD, assistant professor of radiology, was promoted to associate professor of radiology, Division of Diagnostic Radiology, Department of Radiology.

Joshua Shimony, MD, PhD, instructor in radiology, was promoted to assistant professor of radiology, Division of Diagnostic Radiology, Department of Radiology.

Victor Song, PhD, instructor in radiology, was promoted to assistant professor of radiology, Division of Radiological Sciences, Department of Radiology.

Katie Vo, MD, instructor in radiology, was promoted to assistant professor of radiology, Division of Diagnostic Radiology, Department of Radiology.

Dmitriy Yablonskiy, PhD, DSc, assistant professor of radiology, was promoted to professor of radiology, Division of Radiological Sciences, Department of Radiology.

NEW FACULTY

Madelyn Stazzone, MD, assistant professor of radiology, Division of Diagnostic Radiology, Department of Radiology.

GRANTS

Dione Farria, MD, MPH, assistant professor of radiology, is principal investigator for Washington University in the multicenter Digital Mammographic Imaging Screening Trial (DMIST). The two-year trial is funded by the National Cancer Institute and the American College of Radiology Imaging Network. Coinvestigators are **Kimberly Wiele, MD**, assistant professor of radiology; **Prem Sri Barton, MD**, asso-

ciate professor of radiology; **Maria Schmidt, MD**, assistant professor of radiology; and **Barbara Monsees, MD**, professor of radiology and chief of Mallinckrodt Institute's breast imaging section.

Daniel Low, PhD, associate professor of radiation oncology, received a \$1.1 million grant from the National Institutes of Health for research on "Lung trajectory mapping for IMRT." Coinvestigators for the four-year grant are **Joseph Deasy, PhD**, assistant professor of radiation oncology and of biomedical engineering; **David Politte, DSc**, research instructor in radiology; **Bruce Whiting, PhD**, research assistant professor of radiology; and **Jeffrey Bradley, MD**, assistant professor of radiation oncology.

Eduardo Moros, PhD, associate professor of radiation oncology and head of physics research, and **William Pickard, PhD**, senior professor of electrical engineering, are principal investigators for Washington University for the three-year study "Integrated approaches to determine molecular and subcellular effects in response to non-lethal EM radiation exposure." The Office of Naval Research provided total funding of \$960,088 for three centers: Washington University, Harvard University, and University of Illinois, Chicago.

Victor Song, PhD, assistant professor of radiology, as principal investigator, received a three-year grant of \$538,305 from the National Multiple Sclerosis Society for research on "In vivo characterization of CNS white matter injury." Song, along with **Joseph Ackerman, PhD**, professor of chemistry, of medicine, and of radiology, and **John Russell, PhD**, professor of molecular biology and pharmacology, are coinvestigators for a five-year Multiple Sclerosis Research Center Award. **Anne Cross, MD**, professor of neurology, is the Washington University principal investigator for the \$844,897 grant from the National Multiple Sclerosis Society.

Dmitriy Yablonski, PhD, DSc, professor of radiology and of physics, as principal investigator, received a grant of \$1.5 million from the National Institutes of Health/National Heart, Lung, and Blood Institute for research on "Quantitation of lung ventilation and structure by ³He MR." Coinvestigators for the five-year grant are **Mark Conradi, PhD**, professor of physics and of radiology; **David Gierada, MD**, assistant professor of radiology; **Joel Cooper, MD**, professor of surgery; **Stephen Lefrak, MD**, professor of medicine; **Amir Amini, PhD**, associate professor of medicine; **Larry Brethorst, PhD**, research associate in radiology; and **Ty Bae, MD, PhD**, assistant professor of radiology. **Charles Hildebolt, DDS, PhD**, associate professor of radiology, is statistician for the grant.

APPOINTMENTS/ ELECTIONS

Thomas Conturo, MD, PhD, associate professor of radiology and adjunct professor of physics and of biomedical engineering, was elected to a one-year term as secretary of the Diffusion/Perfusion Study Group of the International Society for Magnetic Resonance in Medicine.

Colin Derdeyn, MD, associate professor of radiology, was elected to a one-year term as treasurer of the American Society of Interventional and Therapeutic Neuroradiology. He was elected to a two-year term as chairman of the Membership Committee of the American Stroke Association (American Heart Association Stroke Council).

Dione Farria, MD, MPH, assistant professor of radiology, was elected to a one-year term as secretary of the Young Physicians Section of the American College of Preventive Medicine.

Jay Heiken, MD, professor of radiology, chief of abdominal imaging, and codirector of body computed tomography, was appointed to an indefinite term as chairman of the Gastrointestinal Section of the Radiological Society of North America's Scientific Program Committee.

Gilbert Jost, MD, professor of radiology and director of Mallinckrodt Institute, was appointed chairman of the Barnes-Jewish Hospital (BJH) Medical Executive Committee. He also was appointed to the BJH Board of Directors.

Robert McKinstry, MD, PhD, assistant professor of radiology, was re-elected to a second term as chairman of the Steering Committee for The MRI Study of Normal Brain Development, a National Institutes of Health-sponsored, multicenter study funded by the National Institute of Neurological Disorders and Stroke and the National Institute of Child Health and Human Development.

Dmitriy Yablonski, PhD, DSc, professor of radiology and of physics, was appointed to the editorial board of *MRM (Magnetic Resonance in Medicine)*, an official journal of the International Society for Magnetic Resonance in Medicine.

HONORS/ AWARDS

Elizabeth McFarland, MD, associate professor of radiology, received funding of \$10,000 through the Barnes-Jewish Hospital Foundation for continued research on CT colonoscopy.

LECTURES/ PRESENTATIONS

Jeffrey Brown, MD, associate professor of radiology, chief of the clinical research laboratory, and cochief of body magnetic resonance imaging, presented "Abdominal MRI" at Texas A&M University, Corpus Christi, February 8.

Maurizio Corbetta, MD, associate professor of neurology and of radiology, spoke on "Relationship between BOLD-fMRI and behavioral performance" at the Winter Brain Conference Symposium, Snowbird, Utah, January 27. He presented "Neural systems for attentional control in the human brain" at the Johns Hopkins Psychology Colloquium, Baltimore, Maryland, February 5. Corbetta spoke on "Neural plasticity in the adult human brain" and "Neural correlates of recovery after stroke" at the American Academy of Neurology 55th Annual Meeting, Honolulu, Hawaii, March 30 and 31.



Biello Lecture

The Seventeenth Annual Daniel R. Biello Memorial Lecture was presented on March 10 by Mark Mintun, MD, professor of radiology in MIR's Division of Nuclear Medicine. Mintun (left), shown with Barry Siegel, MD, division chief of nuclear medicine, spoke on "Molecular imaging of the brain: FDG and beyond."

LECTURES/PRESENTATIONS

Continued from page 25

Colin Derdeyn, MD, associate professor of radiology, presented "Rationale for the new EC/IC bypass trial" at Grand Rounds, Carbondale Memorial Hospital, Southern Illinois University, Carbondale, Illinois, December 13, 2002. He spoke on "Acute stroke interventional management: need for imaging triage" and "Surgical and endovascular cerebral revascularization: pathophysiology of ischemic stroke" at the 6th Annual Joint Meeting of the American Association of Neurological Surgeons/Congress of Neurological Surgeons Joint Section on Cerebrovascular Disease and the American Society of Interventional and Therapeutic Neuroradiology, Phoenix, Arizona, February 16 and 17.

Michael Gelbart, MD, instructor in radiology, as invited lecturer, presented "MR arthrography," "MR shoulder," "MR elbow," "Arthritis," and "Vertebroplasty" at the Universidad Catolica, Santiago, Chile, January 6-17.

Louis Gilula, MD, professor of radiology and of surgery, as visiting professor, presented "Introduction to vertebroplasty" and "Technical aspects of vertebroplasty" at the Oregon Health and Science University, Portland, January 10, and at Hahnemann University Hospital/Drexel University College of Medicine, Philadelphia, Pennsylvania, February 13 and 14. As visiting professor, he spoke on "Less recognized wrist conditions that should be known" at the University of California San Diego Naval Hospital, San Diego, March 6. Gilula spoke on "Introduction to vertebroplasty," "Cervical spine nerve blocks," "Lumbar spine nerve blocks," and "Lumbar discography" at Skeletal Radiology 2003, Scottsdale, Arizona, April 6-10.

Jay Heiken, MD, professor of radiology, chief of abdominal imaging, and codirector of body computed tomography, presented the 20th Annual John S. Dunn, Sr. Lecture—"CT colonography: What are the issues?"—at the Houston Radiological Society, Houston, Texas, January 27. As visiting professor, he spoke on "Hepatic masses: characterization with CT and MRI" and "CT of the abdominal aorta: aneurysm rupture and postoperative complications" at Baylor College of Medicine and the University of Texas Medical Center, Houston, January 27.

Daniel Low, PhD, associate professor of radiation oncology, spoke on "A method for the four-dimensional measurement of normal and cancerous lung during free breathing" at the Biomedical Imaging Research Opportunities Workshop, Bethesda, Maryland, January 31 and February 1, 2003. He presented "4D imaging at MIR" at the Image Guided Therapy Workshop, Massachusetts General Hospital, Boston, February 7 and 8.

Robert McKinstry, MD, PhD, assistant professor of radiology, presented "Diffusion tensor MR imaging in neuroradiology" at the Greater St. Louis Society of Radiologists meeting, St. Louis, Missouri, January 21.

Carlos Perez, MD, professor of radiation oncology and chairman of the Department of Radiation Oncology, presented "Modern radiation therapy of prostate cancer" at the 5th Annual Palm Beach Cancer Symposium, Delray Beach, Florida, March 29.

Stuart Sagel, MD, professor of radiology, chief of chest radiology, and codirector of body computed tomography, as invited speaker, presented "CT angiography for pulmonary embolism," "Anatomic variants and pitfalls in thoracic CT," and "CT of non-vascular mediastinal masses" at the Chicago Radiological Society and Northwestern University, Chicago, Illinois, February 20 and 21.

Barry Siegel, MD, professor of radiology and of medicine, and chief of the Division of Nuclear Medicine, as visiting professor, presented "Applications of PET in oncology" at Grand Rounds and "FDG-PET artifacts and variants" at the Diagnostic Radiology Resident Conference, Yale University, New Haven Connecticut, February 6 and 7. He spoke on "PET scanning of cancer: current clinical indications" at the Scripps Cancer Center's Annual Conference, Clinical Hematology & Oncology 2003, San Diego, California, February 15-18. As visiting professor, Siegel presented "PET in lung cancer" at the Robert Wood Johnson University Hospital, New Brunswick, New Jersey, March 20.

Yuan-Chuan Tai, PhD, assistant professor of radiology, spoke on "Development of high resolution PET systems for small animal imaging" at the National Institute of Radiological Sciences, Chiba, Japan, April 1.

SYMPOSIA

In this section of FYI, only those faculty and staff who have Department of Radiology or Department of Radiation Oncology appointments are listed.

IMRT PRACTICUM AT SEA January 11-18, 2003

IMRT DELIVERY SYSTEMS

Daniel Low, PhD, "Vendor specific issues: NOMOS."

IMRT RESOURCE REQUIREMENTS

James Purdy, PhD, "Impact on medical physicists."

IMRT THERAPY PLANNING SYSTEMS

Daniel Low, PhD, "Vendor specific issues: CMS."

CLINICAL ISSUES FOR IMRT PLAN EVALUATION

Daniel Low, PhD, "Patient-specific quality assurance: perspective 1."

TRANSITIONING FROM 2D AND 3D CONFORMAL RADIOTHERAPY TO IMRT

James Purdy, PhD, "Impact on medical physicists."

RADIATION THERAPY ONCOLOGY GROUP (RTOG)

Houston, Texas
January 23-26, 2003

Jeff Michalski, MD, chair, Image-guided Radiotherapy.

James Purdy, PhD, ITC Report.

COMMITTEE REPORTS

Jeffrey Bradley, MD, Lung cancer: Functional imaging—PET in combined modality II; Open protocols: Lung; Inoperable NSCLC: Active—T/Cbo + 3D HDIF CRT dose escalation.

Jeff Michalski, MD, Brain tumor: 3-D dose escalation; Genitourinary: Phase III dose/conformal RT; Closed studies: RTOG 9406; Closed protocols: Prostate (9406); Protocols in development: Prostate; Open protocols: Brain—Phase I dose escalation in GBM.

Marie Taylor, MD, Breast cancer: RTOG 95-17: Toxicity analysis and progress of cosmesis scoring.

SOCIETY OF GASTROINTESTINAL RADIOLOGISTS SOCIETY OF URO RADIOLOGY

Abdominal Radiology
Course 2003
Cancun, Mexico
February 16-21, 2003

Jay Heiken, MD, comoderator, Multidetector CT: recent advances.

Senturia Lecture

On February 10, Howard Forman, MD, MBA, vice chairman of the Department of Diagnostic Radiology and director of the MD/MBA Program at Yale University, presented the Ninth Annual Hyman R. Senturia Lecture.

Forman, a former Mallinckrodt Institute diagnostic radiology resident, spoke on "The drug wars and Medicare: prognostications about the future of diagnostic radiology?"



WORKSHOPS

Dennis Balfe, MD, "Cross-sectional imaging of the peritoneum and internal hernias."

Jay Heiken, MD, "Small bowel obstruction: a practical approach."

Sharlene Teefey, MD, "Portal hypertension and TIPS."

ONCOLOGY II—RENAL NEOPLASMS

Marilyn Siegel, MD, "CT of complex renal cysts: recognizing malignant lesions."

GI INFECTIONS AND INFLAMMATORY CONDITIONS

Dennis Balfe, MD, "Pancreatitis: a ubiquitous problem."

SYMPOSIA

Continued from page 27

SOCIETY OF COMPUTED BODY TOMOGRAPHY AND MAGNETIC RESONANCE

*26th Annual Course
Rancho Mirage, California
March 24-28, 2003*

Jay Heiken, MD, course director.

Stuart Sagel, MD, moderator, Thoracic Imaging.

SCIENTIFIC SESSION

Ty Bae, MD, PhD, "Optimizing contrast enhancement for CT and MR."

WORKSHOPS

Ty Bae, MD, PhD, "Imaging of the coronary arteries with MDCT."

Dennis Balfe, MD, "Cross-sectional anatomy of the retroperitoneum"; "CT of the bile ducts."

Stuart Sagel, MD, "Anatomic variants and pitfalls in thoracic CT," "CT angiography for pulmonary embolism: alternative/additional diagnosis," "Problematic thoracic CT cases."

Marilyn Siegel, MD, "MDCT in pediatric patients: applications, protocols, and risks"; "CTA of congenital thoracic anomalies."

FOCUS: THORACIC IMAGING

Stuart Sagel, MD, "CT of non-vascular mediastinal masses."

INTERACTIVE CASE SESSIONS

Jay Heiken, MD, "Abdominal imaging."

Stuart Sagel, MD, "Chest imaging."

SOCIETY OF INTERVENTIONAL RADIOLOGY

*28th Annual Scientific Meeting
Salt Lake City, Utah
March 27 - April 1, 2003*


Michael Darcy, MD, moderator, Creating Opportunity from Change.

David Hovsepian, MD, coordinator, Conscious Sedation/Pain Management Workshop.

Thomas Vesely, MD, coordinator, Venous Access Workshop.

PLENARY SESSION


Michael Darcy, MD, "Creating opportunity from change—the Presidential Address."



ALUMNI NEWS

Thomas Lipscomb, MD, is the recipient of the 2002 Gold-Headed Cane, the highest honor given by the Tarrant County (Texas) Medical Society. He is the 52nd recipient of the cane, which is a replica of one from the Royal College of Physicians in London that was continuously carried from 1689 to 1823 by the most outstanding physician. The Tarrant County cane has gold bands engraved with the name of each year's recipient; each fall the cane is passed on to the new honoree.

Lipscomb was a senior assistant resident in diagnostic radiology at Mallinckrodt Institute (1968 to 1969) and an instructor in radiology (1969 to 1970), working with William McAlister, MD, MIR's chief of pediatric radiology. Lipscomb retired in 2002 from Radiology Associates in Fort Worth, where he was the area's first full-time pediatric radiologist. He established the first pediatric radiology department at Fort Worth Children's Hospital and, in 1980, was appointed staff radiologist at Cook Children's Hospital. In 1989 the two hospitals merged, and Cook Children's Medical Center now serves all of North Central and West Texas.



 **Washington**
University in St. Louis
SCHOOL OF MEDICINE

MIR Mallinckrodt Institute
of Radiology

...heavy smoker?

- *Do you have a history of long-term or heavy cigarette smoking?*
- *Are you between the ages of 55 and 74?*
- *Are you concerned about the high risk of lung cancer due to smoking?*

Lung cancer is the leading form of cancer in the United States—and cigarette smoking is the leading cause of this disease. An estimated 169,000 new cases are expected this year.

Now you can help in the fight against lung cancer. Mallinckrodt Institute of Radiology at Washington University in St. Louis is participating in the National Lung Screening Trial. This study is part of a nationwide National Cancer Institute effort to determine whether lung cancer deaths can be reduced by early detection with standard chest X rays or spiral computed tomography (CT) before symptoms appear. Eligible participants will receive a free lung cancer screening test.

**For more information or to volunteer for this study, call
Volunteer for Health at (314) 362-1000
or toll free at 1-866-362-5656.**

FOCAL SPOT

MALLINCKRODT INSTITUTE OF RADIOLOGY

Address Service Requested

Send distribution changes or address corrections to
Focal Spot editor
Mallinckrodt Institute of Radiology at
Washington University
Campus Box 8131
510 South Kingshighway Blvd.
St. Louis, MO 63110
(314) 362-2866 or e-mail to
kunklerv@mir.wustl.edu

Editor and Writer
Vicki Kunkler

Contributing Writers
Anne Kessen Lowell
Candace O'Connor

Photographers
Tim Parker
Michelle Wynn

Design
Purviance & Company
Marketing Communications

Printing
Swift Print Communications
LLC


Focal Spot magazine is distributed three times annually.

© Mallinckrodt Institute of Radiology, 2003

Non-Profit Organization
U.S. Postage
St. Louis, Missouri
Permit No. 2535

ARCHIVES
SERIALS DEPT., MEDICAL LIBRARY
WASH. U. SCHOOL OF MEDICINE
CAMPUS BOX 8132

 Washington
University in St. Louis
SCHOOL OF MEDICINE

 Mallinckrodt Institute
of Radiology