

Fall 2003

## Focal Spot, Fall/Winter 2002/2003

Follow this and additional works at: [http://digitalcommons.wustl.edu/focal\\_spot\\_archives](http://digitalcommons.wustl.edu/focal_spot_archives)

---

### Recommended Citation

Focal Spot, Fall/Winter 2002/2003, October 2003. Bernard Becker Medical Library Archives. Washington University School of Medicine.

This Book is brought to you for free and open access by the Focal Spot at Digital Commons@Becker. It has been accepted for inclusion in Focal Spot Archives by an authorized administrator of Digital Commons@Becker. For more information, please contact [engeszer@wustl.edu](mailto:engeszer@wustl.edu).




FALL/WINTER 2002/2003

VOLUME 33, NUMBER 3

# FOCAL SPOT

MALLINCKRODT INSTITUTE OF RADIOLOGY



*Imaging Miracles*



RADIATION ONCOLOGY

## *Teacher of the Year*



**I**mran Zoberi, MD, was selected as the 2002 Radiation Oncology Teacher of the Year. This annual award recognizes a faculty member, selected by the residents, who has made outstanding contributions to radiation oncology resident education.

According to Robert Malyapa, MD, PhD, radiation oncology chief resident, "Doctor Zoberi has demonstrated exceptional clinical acumen, an outstanding bedside manner, and a genuine willingness to teach. He embodies all the ideals and standards of excellence set forth during the past several decades in our department."

After completing a radiation oncology residency (chief resident, 2000-2001) at Mallinckrodt Institute, Zoberi joined the faculty of the newly formed Department of Radiation Oncology in 2001 as an instructor. He specializes in breast and gynecologic malignancies.



# CONTENTS

FOCAL SPOT  
FALL/WINTER 2002/2003  
VOLUME 33, NUMBER 3

## ANOTHER GOLD MEDAL FOR PURDY

2

The American College of Radiology honored James Purdy, PhD, for his outstanding clinical, academic, and research contributions to the field of radiation oncology physics.



## TEACHING THE TEACHERS

4

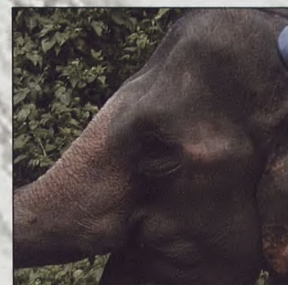
Mallinckrodt Institute and the Universidad Catolica in Santiago, Chile, are partners in the Radiological Society of North America's International Radiology Education Program aimed at improving radiology teaching practices in developing countries.



## RADIOLOGY IN PRATHET THAI

9

Led by a Mallinckrodt Institute radiologist, Washington University physicians are using a multidisciplinary approach to educate Thai physicians about clinical specialties and the latest technology.



## IMAGING MIRACLES

13



Washington University researchers use functional magnetic resonance imaging to study actor/director Christopher Reeve's unprecedented recovery of partial movement following a spinal cord injury.



## RSNA

19

The Institute's faculty and staff participate in the Radiological Society of North America's annual meeting—the largest medical meeting and radiological tradeshow in the world.



24.....FYI

**ON THE COVER** Magnetic resonance imaging can provide important information that may help researchers Maurizio Corbetta (left), Thomas Conturo, and Harold Burton to understand the scope of spinal cord injury in patients and their prospects for recovery. Photograph by Tim Parker.





*Another  
gold medal  
for Purdy*

***T**hroughout his  
30-year career in  
radiation oncology, James  
Purdy, PhD, has earned  
a long list of honors.*

*In October, 2002, at the  
American College of  
Radiology's (ACR's) 79<sup>th</sup>  
Annual Meeting in Miami,  
Florida, Purdy received*

*the ACR's highest  
honor: the Gold  
Medal Award.*

orary  
have  
the s  
is no  
30,00  
ogist  
ACR  
on th  
the d  
radio  
socie  
voice  
relati

I  
comp  
ning,  
conf  
CRT  
radia  
to ha  
pract  
has a  
radio  
nolog  
magn  
emis  
ment

I  
quali  
appo  
Natio  
3-D C  
over  
is ba  
Depa  
As p  
rece  
gran  
of H  
"Adv  
Coin  
gran  
rese  
John  
assis  
Stra  
prof  
asso

Left: M

FOCA



Founded in 1923 as an honorary society of 100 members "who have distinguished themselves in the science of radiology," the ACR is now comprised of more than 30,000 radiologists, radiation oncologists, and medical physicists. The ACR supports programs that focus on the practice of radiology and the delivery of comprehensive radiological health services. The society also serves as radiology's voice in the areas of government relations and socioeconomics.

Purdy's research efforts in computer-aided treatment planning, particularly three-dimensional conformal radiation therapy (3-D CRT) and intensity-modulated radiation therapy (IMRT) continue to have a profound effect on the practice of radiation therapy. He has actively promoted image-based radiotherapy, integrating the technology of computed tomography, magnetic resonance, and positron emission tomography into treatment planning and evaluation.

His early advocacy of 3-D CRT quality assurance resulted in his appointment as director of the National Cancer Institute-funded 3-D QA Center. This national center oversees 3-D CRT clinical trials and is based in Washington University's Department of Radiation Oncology. As principal investigator, Purdy recently received an \$8.1 million grant from the National Institutes of Health for research on "Advanced Technology QA Center." Coinvestigators for the five-year grant are Walter Bosch, DSc, research assistant professor; John Matthews, DSc, research assistant professor; William Straube, MS, research assistant professor; and Jeff Michalski, MD, associate professor.

Left: Marilyn and James Purdy

*Purdy's research  
efforts continue  
to have a  
profound effect  
on the practice of  
radiation therapy.*

Prior to joining the MIR faculty in 1973, Purdy trained in his home state of Texas at the prestigious University of Texas M. D. Anderson Cancer Center. He was named chief of radiation physics at MIR in 1976 and was appointed professor of radiology in 1983. With the formation of the Department of Radiation Oncology in 2001, Purdy is now a professor of radiation oncology and director of the department's Division of Radiation Physics.

He also directs the radiation physics residency program, the first to be approved by the Commission of Accreditation of Medical Physics Education Programs. Purdy is lauded by colleagues as "one of the most influential practitioners and teachers of radiation oncology physics." Many of Purdy's medical physics trainees hold prominent positions in national and international health care facilities.

Purdy has authored and co-authored more than 250 scientific articles and book chapters, has edited seven textbooks, and serves as senior physics editor for radiation oncology's premier journal, *The International Journal of Radiation Oncology, Biology, and Physics*. He is a former president and board chairman of the American Association of Physicists in Medicine (AAPM) and a past chairman of the Board of Chancellors of the American College of Medical Physics (ACMP). Among his many honors are ACR, ACMP, and AAPM fellowships, the American Society for Therapeutic Radiology and Oncology's Gold Medal Award, and the two highest honors bestowed by United States medical physics societies—the AAPM's William D. Coolidge Award and the ACMP's Marvin M. D. William Professional Achievement Award.

In honor of Purdy's clinical, academic, and teaching accomplishments, the Department of Radiation Oncology has established the James A. Purdy Medical Physics Lecture. The first (of what will be an annual) lecture is scheduled for May 16, 2003, at 8:00 a.m., in Steinberg Auditorium, Barnes-Jewish Hospital north campus. Guest lecturer is John Wong, PhD, a former MIR faculty member who is professor of radiation oncology and director of clinical physics, Department of Radiation Oncology, at William Beaumont Hospital in Royal Oak, Michigan. **MIR**



# TEACHING<sub>THE</sub> TEACHERS

BY ANNE KESSEN LOWELL



A unique partnership is spreading Mallinckrodt Institute of Radiology (MIR) talent and technique across five thousand miles to Chile. Sharlene Teefey, MD, associate professor of radiology, is concluding the first year of a three-year grant from the Radiological Society of North America's (RSNA's) "Teach the Teachers" program, and the program is already showing impressive results.

An in  
T  
In  
ti  
te  
T  
g  
k  
te

devel  
ted h  
selec  
pool

T  
progr  
comm  
beca  
and c  
leagu  
were  
youn  
Huet  
neur  
ship  
train  
also  
and p  
woul  
tiona

I  
joine  
Cato  
Chile  
of th  
dad  
boas  
prest  
Huet  
nosti  
buil  
subs  
task  
fello

Left: Fl  
system  
extend  
includi



## An international partnership

The RSNA, in 2000, established the International Radiology Education Program Grant to "teach the teachers from emerging nations." The RSNA sought to fund programs that would increase the knowledge base and improve teaching practices in radiology in developing countries. Teefey submitted her proposal in 2001 and was selected from a highly competitive pool of applicants.

The MIR Teach the Teachers program began with an international connection and flourishes in part because of the worldly experience and outlook of Teefey and her colleagues. The seeds of the program were sown 25 years ago, when a young Chilean doctor named Isidro Huete completed a fellowship in neuroradiology at MIR. His fellowship not only provided the renowned training of the MIR program, but also opened the door to friendships and professional connections that would eventually result in an international partnership.

Huete returned to Chile and joined the staff of the Universidad Catolica in Santiago, the capital of Chile and home to about 40 percent of the country's population. Universidad Catolica is a private hospital and boasts one of the country's most prestigious medical schools. When Huete was named chairman of diagnostic radiology in 1983, he set out to build a department with strong subspecialty expertise—a difficult task in a country with no radiology fellowship programs. So he began

**Left: Flying over the Andes, the world's largest system of high mountain ranges. The Andes extend into seven South American countries, including Chile.**

to work with his former colleagues at MIR. Fernando Gutierrez, MD, associate professor of radiology at the Institute, visited Universidad Catolica to lecture and teach, and Universidad Catolica sent residents to MIR for training.

When the Teach the Teachers opportunity arose, Teefey, Huete, and Gutierrez jumped at the chance to expand the impact of their to-date informal program and to solidify the relationship between the two universities. There were many reasons to select Chile and Universidad Catolica for the program: The university has high-quality facilities and equipment that accommodate a good teaching program and brings doctors from other South and Central American countries for training. Teefey also recognized the tremendous need in Chile for training in radiology expertise—there are only 500 radiologists in all of Chile to serve 15 million people.

The program set ambitious goals:

- Send four MIR faculty per year to Universidad Catolica to teach two-week blocks in a subspecialty
- Bring a total of eight Chilean second-year and third-year residents to MIR for three-month rotations
- Attract radiologists from other Central and South American countries to come to Universidad Catolica during the MIR visiting faculty program.

Sanjeev Bhalla, MD, assistant professor of radiology, made the inaugural visit to Santiago as the first MIR visiting faculty in March 2002. Leaving behind the signs of early spring in St. Louis, Bhalla encountered the cool fall climate of the southern hemisphere. His reception at Universidad Catolica could not have been warmer, however. Bhalla,



**Left: Sharlene Teefey, MD**



**Below: Fernando Gutierrez, MD (foreground, left) presents a noon conference in a reading room that was temporarily converted to a lecture hall.**



**Gutierrez prepares for morning rounds with Universidad Catolica residents and faculty.**



whose specialty is chest radiology, found himself immersed in twelve-hour days of nonstop teaching. "I didn't really know what to expect," says Bhalla. "But Doctor Huete just threw me in; he introduced me to the faculty on a Monday morning and said, 'Let's get going.'"

Even with somewhat limited second-language skills on both sides of the lectern, Bhalla was able to communicate effectively. "The scientific language was the same. The same search patterns and the same diseases show up on the CT [computed tomography]." Aside from increased incidence of tuberculosis in Chile and a higher rate of

Chilean residents Alvaro Burdiles and Luis Muse during their rotation at MIR

gastric disease caused by dietary and smoking habits, United States and Chilean radiologic health issues are fairly similar. However, Bhalla discovered that the Dominican Spanish he picked up in New York City would not always serve him well, as when he learned that the word *guagua* does not mean *bus*, as he thought, but means *baby* in Chilean Spanish.

The highlight of Bhalla's experience was the chance to practice the craft of teaching for hours every day. "The trip really cemented my desire to teach," he says. "And much to my surprise, the teaching went both ways." Bhalla found the Chilean residents to be outspoken participants in the conferences, responding to each case with an experience of their own and offering new perspectives.

## The program's impact

Teefey hopes the MIR Teach the Teachers program will have a broad and lasting impact on the Universidad Catolica training program and on radiology training throughout Chile. With an overwhelming clinical workload, faculty members at Universidad Catolica are eager to learn how to manage teaching and clinical duties more effectively. Chilean residents, future teachers themselves, have the most to gain from early exposure to the MIR faculty.

Just how does the Universidad Catolica radiology department compare to MIR? Mallinckrodt Institute's 165 clinical staff (including faculty,



resid  
mate  
case  
Cato  
near  
almo  
case  
syste  
from  
high  
rece  
of tr  
typic  
tech  
Non  
facu  
devo  
Unit

focus  
with  
ing t  
from  
an e  
nize  
beyo  
mate  
we a  
com  
over  
dous  
facu  
for p  
perh  
gists  
Univ

State  
equa  
Insti  
part  
thir  
sper  
far. A  
com  
raph  
diles  
a fel  
he w  
man



residents and fellows) see approximately 600,000 diagnostic radiology cases per year; Universidad Catolica's 18 faculty members see nearly 200,000 cases, equating to almost three times the average MIR caseload per clinician. The Chilean system takes some of this burden from the physicians by relying on highly-trained technologists, who receive five years to six years of training as compared to a typical two-year training period for technologists in the United States. Nonetheless, Universidad Catolica faculty have much less time to devote to teaching than do their United States counterparts.

Teefey and her colleagues are focused on a long-term relationship with Universidad Catolica. According to Huete, "what the faculty bring from MIR, they leave with us, such as an excellent background in organized teaching and conferences. But beyond the teaching methods, the materials are very helpful. With that we are building a teaching library, complete with case summaries and overheads," which can be a tremendous resource for an overtaxed faculty. Teefey is already planning for postgrant exchanges of faculty, perhaps recruiting retired radiologists to serve as visiting faculty at Universidad Catolica.

The other half of the United States-Chile exchange has been equally rewarding for Mallinckrodt Institute and Universidad Catolica participants. Four second-year and third-year Chilean residents have spent three months each at MIR so far. Alvaro Burdiles, MD, recently completed two months in mammography and one month in CT. If Burdiles reaches his goal of obtaining a fellowship in breast imaging, he will be the first fellowship-trained mammographer at the Universidad

Catolica. In his short time at MIR, Burdiles was impressed not only by the amount of information conveyed in the teaching program but also by the combination of efficiency and friendliness in faculty-resident interactions.

Burdiles says that his training at MIR "will make me a better radiologist, a better professional, and a better person. I've learned to make a good differential diagnosis, my accuracy is higher, and I am more confident. It has been a dream come true to study here."

## Rewarding results

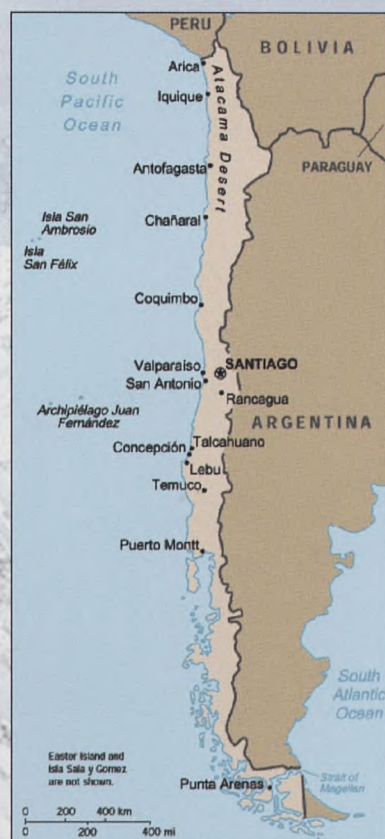Teefey agrees that the program has already proven successful. "The one-on-one interactions have been so significant—it is a give-and-take on both sides." But does the program measure up to the more objective evaluation criteria imposed by the RSNA?

Early indications suggest a resounding yes. Participants at Universidad Catolica were given tests before and after the MIR program, requiring them to evaluate 20 radiology cases. The Chilean faculty's scores increased from 75 percent of cases correctly evaluated before the two-week program to 86.7 percent following. Second-year and third-year resident scores improved from below 50 percent on the pre-test to 80 percent on the post-test.

Similar results were achieved by the Universidad Catolica residents completing rotations at MIR. The first two residents to report results improved their accuracy from 55 percent or less to a range of 70 percent to 80 percent. Huete plans to continue assessment of the MIR-trained

## FACTS AND FIGURES

- **Location:** Southern South America, between Argentina and Peru; borders the South Atlantic Ocean and the South Pacific Ocean.
- **Capital City:** Santiago
- **Population:** 15.5 million
- **Area:** 292,135 square miles, including Easter Island (Isla de Pascua) and Isla Sala y Gomez
- **Official language:** Spanish
- **Government:** Republic





faculty and residents at Universidad Catolica to measure the impact of the program over the long term.

Two other objectives of the program will take longer to evaluate but are of great importance to Teefey and her team. With so few radiologists in Chile, many areas of the country—which stretches 2,650 miles and encompasses a range of climates from arid desert to high mountain range—are underserved. Universidad Catolica trains several residents every year for the National Health Service. Those residents will be assigned to a more remote hospital and will be completely on their own with little opportunity to con-

sult other radiologists. To date, six of the National Health Service residents have been taught by MIR faculty. Radiologists from other Central and South American countries are also being trained at Universidad Catolica, and Teefey hopes the program can strengthen the extremely limited resources of poorer countries such as Bolivia, Colombia, and Honduras.

Seeking an opportunity to make a difference in health care in less developed countries is second nature to MIR's dedicated Teach the Teachers team. Individually, they have worked in Micronesia, Zimbabwe, Ghana, and rural Puerto Rico. Building bridges to developing countries is especially important in today's volatile international environment,

says Teefey—a sentiment echoed by Washington University in St. Louis Chancellor Mark Wrighton. "Washington University is committed to creating new knowledge that benefits the entire world," he says. "Programs like Doctor Teefey's 'Teach the Teachers' program in Chile stem from our exceptional faculty and the exciting research that is being carried on both here in St. Louis and in locations throughout the world where our researchers work hand-in-hand with international colleagues. With our distinguished history and strong support from graduates and friends around the world, Washington University is poised to further increase our impact on our rapidly changing world." **MIR**

**Main campus of Universidad Catolica in Santiago—the hospital is located behind the university.**

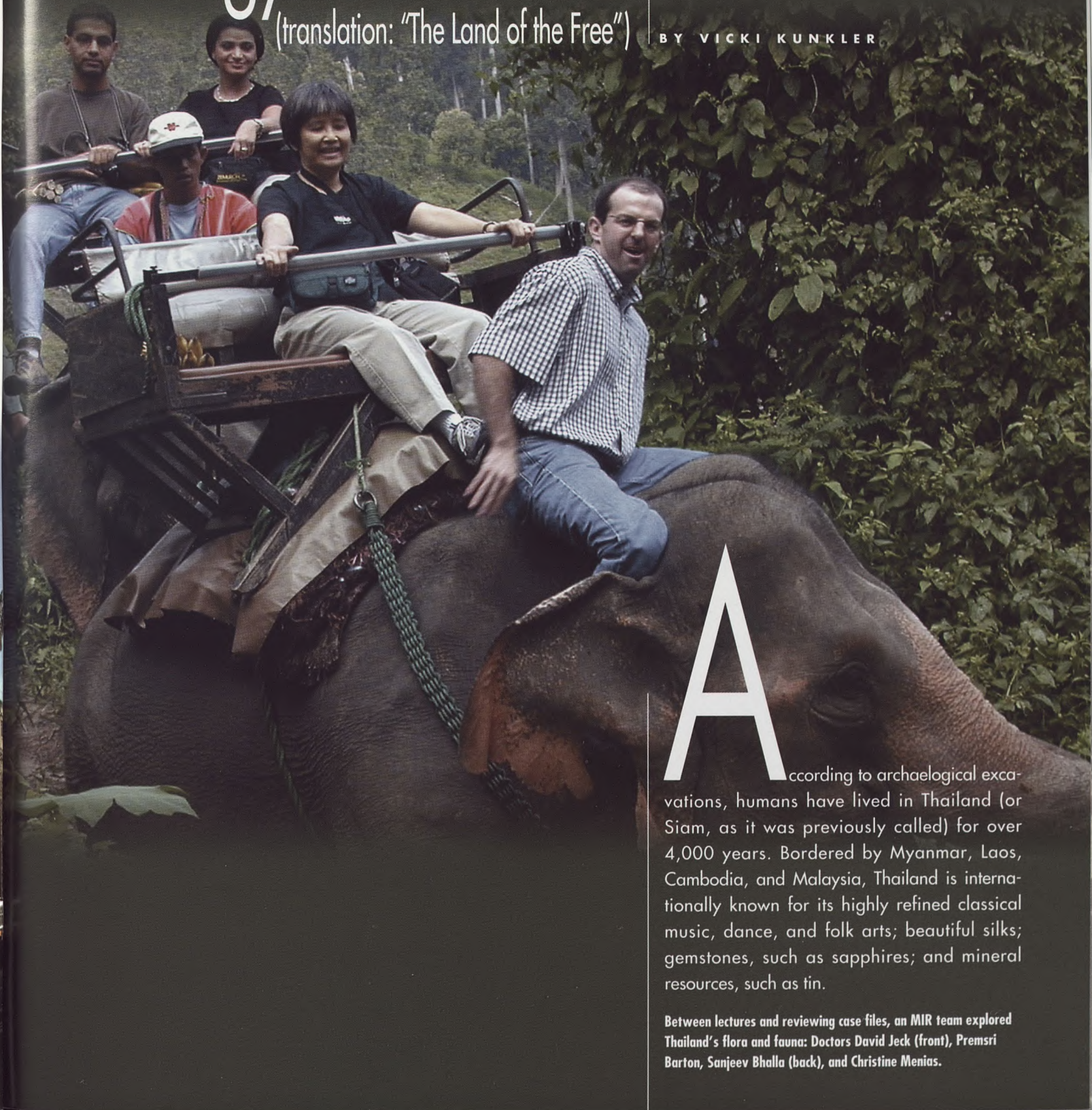



# Radiology in Prathet Thai

(translation: "The Land of the Free")

BY VICKI KUNKLER



A ccording to archaeological excavations, humans have lived in Thailand (or Siam, as it was previously called) for over 4,000 years. Bordered by Myanmar, Laos, Cambodia, and Malaysia, Thailand is internationally known for its highly refined classical music, dance, and folk arts; beautiful silks; gemstones, such as sapphires; and mineral resources, such as tin.

Between lectures and reviewing case files, an MIR team explored Thailand's flora and fauna: Doctors David Jeck (front), Premsri Barton, Sanjeev Bhalla (back), and Christine Menias.





Above: Sanjeev Bhalla, MD, (center) discusses cases with Thai physicians.

Below: Doctors Bhalla and Bradley Freeman at Wat Mahathat in the Sukhothai Historical Park. Sukhothai was the ancient capital city of Thailand.

For Mallinckrodt Institute of Radiology's (MIR's) Prem Sri Barton, MD, Thailand has a special meaning: It is her homeland. And for six years, Barton, an associate professor in the Institute's breast imaging section, has introduced MIR faculty to her native land by coordinating community-outreach trips to Thai medical schools and teaching hospitals. The medical teams have provided educational lectures and clinical evaluations for health-care facilities in northeast and southern Thailand and in the capital city of Bangkok.

Barton, who joined the MIR faculty in 1993, has been quite

resourceful in attaining funding for these trips and is appreciative for the sponsorship provided by the Thai Physicians Association of America (TPAA). In fact, TPPA was the impetus for the first trip in 1996. The society was hosting a large, general scientific meeting in Thailand that encompassed all aspects of medicine. They asked Barton for recommendations





for musculoskeletal radiology lecturers, so she quickly recruited doctors Louis Gilula and Anthony Wilson. Barton added a breast imaging segment to the scientific program and asked Barbara Monsees to join her on the trip.

In Thailand, approximately three percent of the country's physicians are radiologists, so the medical community was eager to learn about the latest in radiologic

technology. "Our radiology talks were the most well attended of any lectures at that 1996 meeting," says Barton. "So that set the stage for our subsequent trips."

Barton is a successful recruiter for the trips that now include teaching residents and medical students in several of Thailand's medical schools, such as Khon Kaen, Chiang Mai, and Prince of Songkhla universities. Thailand has a good health-care system, with about 90 provincial hospitals (at least one hospital in each of the 76 provinces) and more than 700 community hospitals throughout the country.

"Although the Thai hospitals can provide good basic medical care, they do not have the higher levels of care available in the United States," says Barton. "Mallinckrodt Institute can play an important role by sharing the expertise gained from seventy-plus years of radiology experience."

For the past two years, one or two Thai residents, sponsored by their government, have come to the Institute as visiting fellows to receive training in chest and abdominal radiology. "Doctor Monsees accepted the first visiting fellow from Thailand—she has been my strongest supporter—

## Participants in MIR's Thai Outreach Program

Prem Sri Barton, MD, coordinator for all Thai outreach trips

1996

Louis Gilula, MD (Radiology); Anthony Wilson, MD (Radiology); Barbara Monsees, MD (Radiology)

1997

Andrew Fisher, MD (Radiology)

1998

Andrew Fisher, MD (Radiology)

2000

Joanne Mortimer, MD (Internal Medicine); Marie Taylor, MD (Radiation Oncology); Barbara Monsees, MD (Radiology); Gerard Doherty, MD (General Surgery)

2001

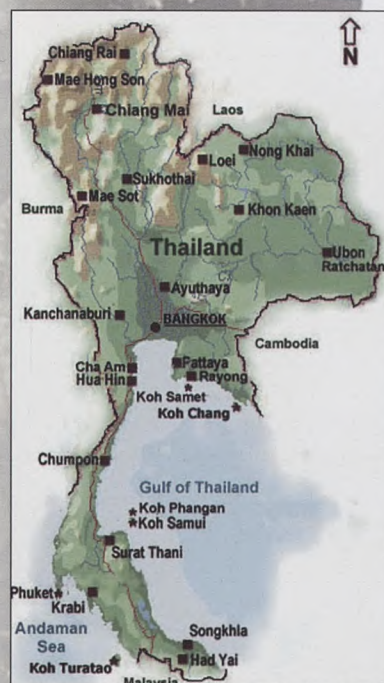Sanjeev Bhalla, MD (Radiology); Christine Menias, MD (Radiology); David Jeck, MD (Radiology)

2002


Sanjeev Bhalla, MD (Radiology); Christine Menias, MD (Radiology); Daniel Riew, MD (Orthopaedic Surgery); Robert Swarm, MD (Anesthesiology); Bradley Freeman, MD (General Surgery); Beverly Field, PhD (Psychiatry)

## FACTS AND FIGURES

- *Capital city:* Bangkok
- *Population:* 60+ million
- *Area:* approximately 198,000 square miles
- *Languages:* Thai, English, ethnic and regional dialects
- *Official name:* The Kingdom of Thailand
- *Government:* Democratic, led by a prime minister
- Estimated 99% of Thailand's population is literate
- Only Southeast Asian country never governed by a foreign power







Above: Doctors Barton (right) and Rosakorn, a mammographer at The Breast Health Center (Thunyaruk), Siriraj Hospital in Bangkok

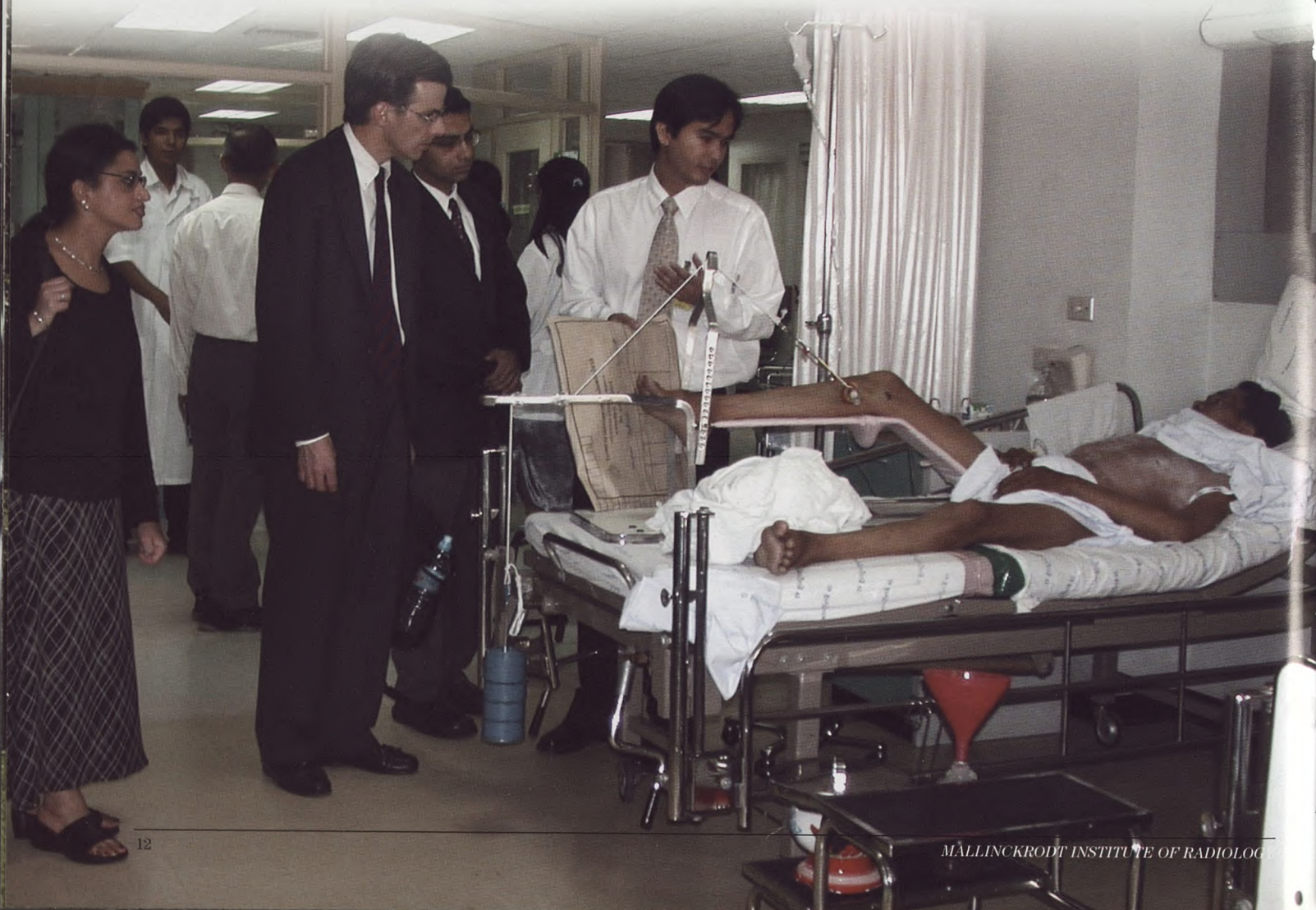Below: Doctors Menias, Freeman, and Bhalla during rounds of the Trauma Unit at Thammasart University Medical School in Bangkok

and I am most grateful to her and others, such as doctors Jay Heiken and Stuart Sagel, for their efforts with this program," says Barton. "And the program at MIR is expanding to include nuclear medicine and interventional radiology."

The incidence of breast cancer in Thailand is low, as is true in most Asian countries, but "it is on the rise, with a five percent increase in the past few years," says Barton. In 2000, TPPA sponsored a multidisciplinary Breast Cancer Symposium, and several Washington University Medical Center physicians were guest lecturers.

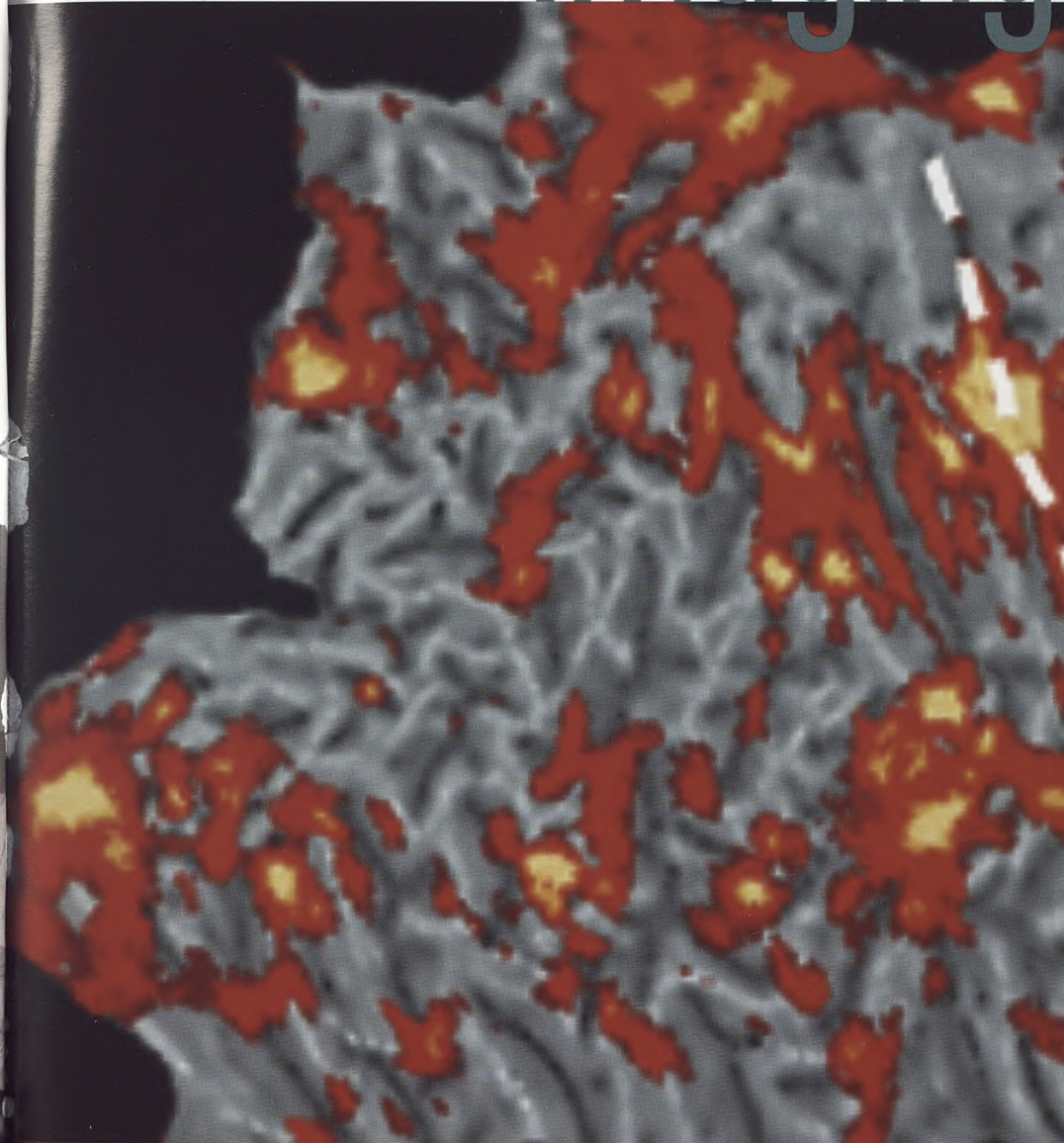
On the most recent trip, the focus was emergency and trauma medicine—an appropriate topic in a country where one of the greatest health threats is from injuries caused by vehicular crashes.

Barton plans to continue the teaching program, taking a multidisciplinary approach and including lectures on all aspects of specific clinical areas. She will also serve as a mammography consultant for a new Thai program that trains nurses to go into the rural communities to educate women about breast cancer and the benefits of mammography. **MIR**





# Imaging Miracles




Actor/director Christopher Reeve, a quadriplegic since 1995, celebrated his fiftieth birthday in September 2002 with the announcement of an even more important milestone: a slow, steady recovery of function that began more than five years after his accident—an unprecedented occurrence among patients with spinal cord injury. At the first hint of this improvement, signaled by the voluntary movement of his left index finger, Reeve started an intensive rehabilitation regimen, prescribed by a team of Washington University School of Medicine (WUSM) researchers headed by John McDonald, MD, PhD, assistant professor of neurology. By the time of his birthday, Reeve could feel pinpricks and the touch of a cotton swab over 65 percent of his body and could move some joints without help.

by Candace O'Connor





# Imaging Miracles



Maurizio Corbetta, MD

*A paper written by the WUSM team in the September 2002 Journal of Neurosurgery: Spine documents Reeve's extraordinary progress. And an addendum in the October issue chronicles an important piece of the story: the involvement of Mallinckrodt Institute of Radiology specialists, headed by Thomas Conturo, MD, PhD, in performing the magnetic resonance imaging (MRI) portion of this study. In four successful sessions, some for anatomical imaging and some for brain function imaging, the researchers collected high-quality MRI scans, while maintaining safety and comfort for Reeve. Reeve's recent book, Nothing is Impossible, contrasts these sessions with his 1995 MRI experience at another institution, where he needed sedation to carry him through the procedure.*

"Physicians are often reluctant to order MRI studies for patients who are ventilator dependent," says Conturo, associate professor of radiology, of physics, and of biomedical engineering. "Christopher Reeve has one of the most devastating spinal cord injuries that can occur. If we can scan him safely, then MRI should be doable in most patients with chronic spinal cord injury. We hope our experience at Mallinckrodt Institute can be a road map for other MRI facilities in managing these patients."

While performing these scans was an achievement in itself, what researchers discovered in the course of these studies was also striking and potentially significant. Some scans of Reeve's spinal cord anatomy, Conturo says, revealed changes that may be important in understanding the scope of spinal cord injury in these patients and their prospects for recovery.

Other brain activation scans aimed at determining the extent and degree of function that still exists within Reeve's cerebral cortex after those five dormant years are part of a functional MRI study led by Maurizio Corbetta, MD, associate professor of neurology, of radiology, and of anatomy and neurobiology, and head of WUSM's stroke and brain injury rehabilitation, and Harold Burton, PhD, professor of anatomy and neurobiology and of radiology. Their findings, published in the December 23 issue of the *Proceedings of the National Academy of Sciences*, showed an intriguing mix of stability and reorganization. While Reeve's cortical topography for the motor system looked like that of a healthy subject, his sensory system had undergone some change.

Several possible explanations exist for this result, say the researchers, but the overall message is clear and hopeful. "In this patient with a clinically incomplete spinal cord injury for five years, some of the surviving fibers are actually functioning—enough to maintain a normal map of the body in the cortex," says Corbetta.

"So the nervous system, despite its horrendous sensory and motor loss, seems to retain most of its normal organization," adds Burton. "If there is any way of getting some information across the level of the injury, the brain itself is still there to receive this information."

## Pathways to Motor Function

The spinal cord carries impulses from the brain throughout the body, telling its parts how, when, and where to move. No other pathway exists from the brain to the body; if the spinal cord is severed, all movement ceases below that point. In Reeve's case, his spinal cord was seriously damaged—though not severed—high up, at the C2 or second vertebral level. Typically, patients with this type of injury do not survive the initial trauma. Most specialists believe that if any recovery from such an accident occurs at all, it will happen within the first two years. But Reeve never gave up and maintained an aggressive exercise program. Then in 2000, when Reeve moved his finger, experts were galvanized by how this movement was happening.



"The impulses that tell him to move his finger have to be coming from his brain and traveling down his spinal cord," says Conturo. "But how can there be a pathway in this case? We don't know whether the spinal cord has changed over time to regrow some of the pathways. Or maybe there are some remaining fibers that were not damaged, and what was left is involved in moving the finger."

The regrowth question in humans is difficult to answer by using MRI scanning, since such subtle changes would be difficult to detect even with high-quality anatomical imaging. Detection is easier in animal models, when it is possible to remove the damaged spinal cord and check for cell division and growth. But in Reeve's case, researchers could establish baseline values in four other critical areas: the high-resolution anatomy of his damaged spinal cord, the anatomy of his brain after five years without motor movement and nearly absent sensations, his brain activity during his new motor movement, and his brain's response to sensation.

And all this could proceed because Reeve is a willing and cooperative subject, happy to have the details of his case publicized to advance scientific understanding. "Christopher Reeve has really been a hero to researchers in this field," says Conturo, "because he is the biggest cheerleader of all for this work. His dedication to spinal cord research is symbolized by his establishing the Christopher Reeve Paralysis Foundation."

### "Do No Harm"

When McDonald, Corbetta, Burton, and Conturo first discussed Reeve's case, they were not sure extended imaging sessions were possible because of the problems inherent in imaging patients who are ventilator dependent. At planning sessions held months in advance of the MR imaging, the team—which also included Linda Schultz, PhD, an instructor in neurology who took charge of all the logistics for each of Reeve's visits to St. Louis—discussed various contingencies. They also consulted other Mallinckrodt Institute staff as needed, including neuroradiologists Jay Wippold, MD, and Joshua Shimony, MD, PhD, to interpret Reeve's diagnostic images taken at other institutions.

Reeve's safety was the first consideration; the second was to obtain the best images possible. There were some temporary roadblocks: for example, in the aftermath of Reeve's 1995 horseback-riding accident, surgeons had implanted a curved, 18-inch metal rod in Reeve's spine to stabilize his neck and lower skull. There was a chance this metal could heat up, and Reeve, who had no sensation in that area, would not know it. Erbil Akbudak, PhD, a Mallinckrodt Insti-


tute physicist, also raised another concern: Could the metal affect the quality of the images by distorting the magnetic field? And could the metal itself be pulled out of alignment by the force of the magnet and cause an injury to Reeve?

To address the heat question, Conturo and others simulated the entire scenario in advance. From surgical records, they learned the type of metal used for the bar.

Then Schultz asked James Lu, MD, a neurosurgery resident, to produce a replica of Reeve's stabilizing bar, using special bending tools. The bar and other wires were attached to a fluid-filled anatomical phantom, and a series of scans were performed to test for warmth. Fortunately, none developed, and there was no attraction strong enough to pull the bar out of place.



Harold Burton, PhD, and Thomas Conturo, MD, PhD (right)







# Imaging Miracles

There also was the question of artifacts in the images, due to the presence of metal. "The researchers collected the images in several different ways to see if there was an optimal way to collect the data. "As luck would have it, the standard way was the best approach," says Conturo. "We *could* see the entire brain, including the cerebellum, and it looked like any functional MRI scan. That encouraged us to try advanced research studies to look at brain function."

## Other Challenges

The team decided to use a scanner at Mallinckrodt Institute's East Building, where visitors could be more carefully monitored. Also, the imaging equipment in the East Building could be scheduled

for four-hour periods, which would allow time for proper setup plus the two-hour scans.

Doorways were measured to ensure they were wide enough for Reeve's specially equipped wheelchair. But once inside the building, the wheelchair, with its metal parts, could not be rolled directly to the magnetic scanner. To solve this problem, an MRI-compatible, aluminum gurney was used.

Reeve's ventilator, necessary for much of his breathing, was also an obstacle, since it might emit radiofrequency (RF) noise that could interfere with the imaging. "The ventilator is like a radio station transmitting in there, and the scanner might just pick up those signals because the scanner acts like an antenna," says Conturo.

Placing the ventilator outside the MRI room and connecting it to Reeve by a length of tubing might be one solution, but ventilators don't work as effectively at that distance. Fortunately, Conturo had acquired a large copper RF-enclosure box, which could act as a barrier for the noise. The ventilator was placed inside the box and set next to the scanner, where Reeve's attendants could carefully monitor it. The Mallinckrodt Institute team went over every detail of these scanning

sessions carefully with Reeve's team to ensure everyone was comfortable with each step.

At the East Building, emergency personnel were just a phone call away, but the team wanted help closer at hand. So they enlisted Ellen Diebert, MD, a neuro-intensivist, to watch Reeve's vital signs. From the nearby control room, she monitored his heart rate and blood oxygenation. At one point, Reeve's oxygen saturation dropped to around 92 percent—a normal reading is 97 percent or 98 percent. With the help of MRI technologist Glenn Foster, an oxygen line was set up to add extra oxygen to Reeve's breathing mix, and the problem was quickly solved.

A key part of the scanning effort was the monitoring equipment itself, including a leading-edge computer used to process the data. Invivo Research, the company that supplied much of this MRI-compatible equipment, customized the equipment with cables running to the control room where Reeve's physiologic signs were displayed on monitors. It was the first time this equipment was used with a human patient for respiratory monitoring, and everyone was pleased with the results.



Erbil Akbudak, PhD



## Scanning and results

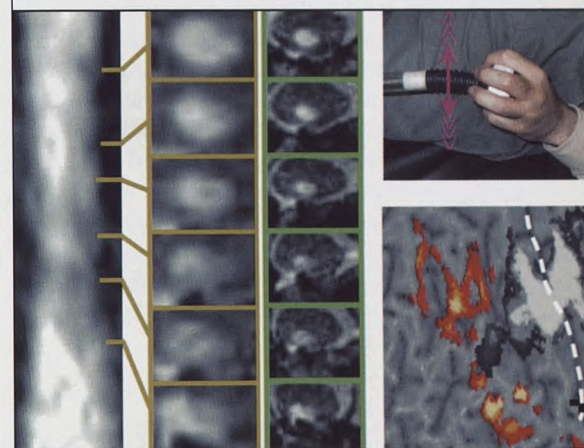
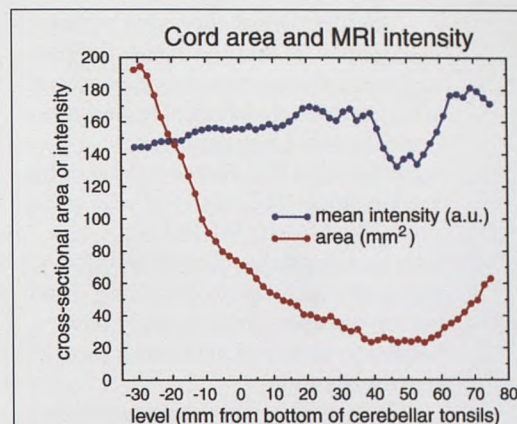
The scanning sessions began with the brain activation studies. Some research has shown that animals and even people with upper-extremity amputations show a great deal of reorganization of the functional areas of the cerebral cortex. To see whether this had happened in Reeve's case, Corbetta and Burton decided to examine the extent of Reeve's sensory system, based on his sense of touch. They also examined the organization of his motor systems, which—as his new finger motion demonstrated—he was only beginning to control.

To test Reeve's motor responses, they chose a body part (his tongue) above his spinal lesion, and another (his finger) below it, and asked him to move each one while watching a bobbing tennis ball on a computer screen. During these movements and rest periods in between, they performed functional MR imaging, watching with interest the Blood Oxygen Level-Dependent (BOLD) signal that relates to neural activity in the brain. They also mapped areas of Reeve's brain that were active during this task to see whether parts of the brain that are normally active during facial or foot movement were also active in his case. And quite unexpectedly, says Corbetta, "We found that for the motor task he had a near-normal topographical arrangement of his responses."

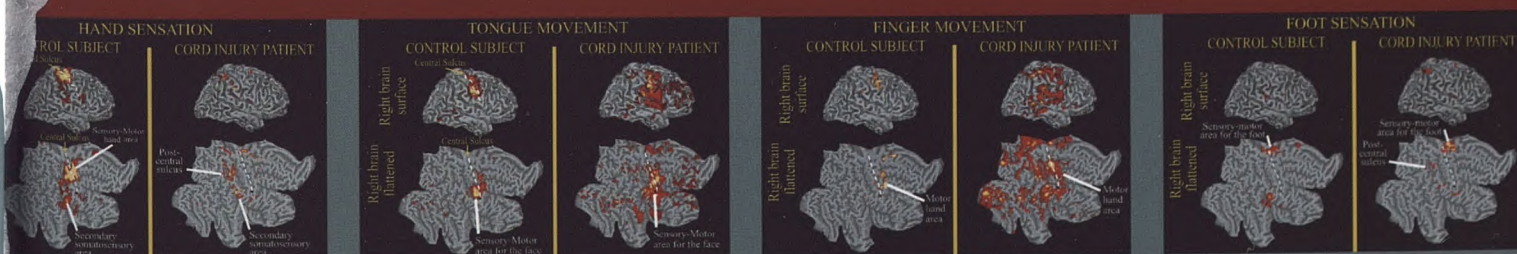
When the tongue moves to the left or right, that motion also sends sensory feedback to the somatosensory cortex, located next to the motor cortex. In looking at this, the researchers found another surprise. There was not only neural activity in the facial part of the cortex but also a spread of this activity into the hand representation portion of the brain—a finding that suggests cortical reorganization.

Next a sensory experiment was conducted: A massage vibrator, designed by Burton and Robert Sinclair, PhD, research assistant professor of neurobiology, was applied to Reeve's left palm and to the sole of his left foot. Again, the researchers performed cortical mapping and found largely normal sensory responses to the foot stimulation. "But when we stimulated his hand, although he was able to feel some input, the normal hand representation was mostly devoid of activation," says Burton. "The empty place was, effectively, invaded by the face representation."

The difference between foot and hand responses is not clear. Perhaps it has to do with the proximity of the lower-face region of the cortex (above the point of injury and still receiving normal activation) to the hand region (below the injury and not receiving activation). So the face representation invaded its neighbor but could not invade the foot representation, which is too far away.



Somatosensory-motor cortical responses following delayed recovery from high cervical spinal cord injury. Cord damage is shown as dark areas in T1-weighted MRI (coronal section far left, bordered in yellow). Spinal canal (dark oval area in green boxes) surrounds an atrophic cord. Left-hand vibration (upper right) causes cortical blood oxygenation responses in functional MRI (dark gray and white areas in lower right) but only in nonprimary sensory regions (red-to-yellow areas). Functional MRI is superimposed on flattened rendering of sensory cortex with central sulcus shown by white dashes.







# ImagingMiracles

Another possibility, also highly speculative, is that the rehabilitation regimen (intensive exercise combined with functional electrical stimulation, bone density treatments, and aquatherapy) that Reeve has been following since 1995, some of which was prescribed by the WUSM team, has also had an effect. The biking Reeve has done, with electrodes firing down his leg muscles, may possibly have helped to preserve his brain's foot representation.

In any case, say the researchers, the good news is that, in many patients with spinal cord injury, there may be surviving fibers that convey some information to the brain—enough to maintain a normal representation in the cortex. And if it becomes possible to use new therapies to reconnect even more fibers, researchers may potentially find cortical maps in the brain that are still normal, suggesting that some function might return.

## Spinal Cord Anatomy Scanning

Clearly the anatomy of the spinal cord—its intact or damaged fibers—plays a large part in this process. So the team decided to look at spinal cord anatomy, taking cross-sectional studies at different levels. Imaging was additionally challenging because the surgical metal was adjacent to the spinal cord lesion. First there was the lesion itself: a severely narrowed part of the spinal cord with a central oval

region of tissue damage. Conservatively, says Conturo, that area showed 75 percent loss in the cross-sectional area, but it may be up to 90 percent, since some of the remaining tissue was also damaged. Just above and below the lesion was an interesting finding: areas of shrinkage, probably from the die-back of damaged white-matter fibers. Similar findings had emerged from animal studies but, as far as Conturo knows, there have been few previous quantitative measurements of such loss in humans with chronic spinal cord injury.

It is still not clear why Reeve's improvement in function is occurring. Is his body using existing undamaged spinal cord pathways to re-establish new, more convoluted spinal cord pathways, or is it actually growing new cells? But the data from the spinal cord scans is potentially important for physicians in a number of ways.

"We can look at how far up and down the spinal cord that decreased area persists, determine the level of the primary spinal cord injury as the level with the smallest area, and get a sense for what parts inside the spinal cord might be damaged or dysfunctional," says Conturo. "The more information about which anatomical parts of the spinal cord remain, the better clinicians can prescribe rehabilitation and take advantage of the parts that are still there."

In recent studies, scientists have found naturally occurring stem cells in the central nervous system. This finding has raised the possibility that, if some way can be found to activate those dormant stem cells or even implant new ones, researchers could re-establish some of the lost pathways and improve a patient's function. The type of spinal cord MRI study performed on Christopher Reeve could some day help to determine the best location for those new stem cells or even guide the use of more speculative restorative techniques such as neuro-prostheses or implantable chips to help stimulate function.

But for now, researchers are encouraged by the discovery that even a pattern of damage within the spinal cord does not necessarily mean a patient cannot recover any function, given the right stimulation.

"Caution must be used when interpreting a study of one patient, and a larger study of more patients would be valuable. But this study suggests that, if there is some tissue left at the point of damage and in each adjacent slice of the spinal cord, there could be some pathways remaining and some rehabilitation might be possible," says Conturo. "And any improvement given to these patients is likely to have a major impact on their lives." **MIR**

*Editor's note: This article is being published with the approval of Mr. Reeve and the Christopher Reeve Paralysis Foundation.*



# RSNA


## *Leading Medicine's Digital Transformation*

DECEMBER 1 MARKED THE KICKOFF OF THE 88TH SCIENTIFIC ASSEMBLY AND ANNUAL MEETING OF THE RADIOLOGICAL SOCIETY OF NORTH AMERICA (RSNA) IN CHICAGO, ILLINOIS. NOT EVEN THE COLD WINDS BLOWING IN FROM LAKE MICHIGAN OR THE SHOWERS OF SNOW COULD DAMPEN THE MOOD OF THE ATTENDEES AT THE LARGEST MEDICAL MEETING AND RADIOLOGICAL TRADESHOW IN THE WORLD.


RSNA'S ANNUAL MEETING IS AN IMPORTANT VENUE FOR RADIOLOGY PROFESSIONALS, WITH PRESENTATIONS OF THE LATEST NATIONAL AND INTERNATIONAL RESULTS IN TECHNOLOGY, RESEARCH, AND CLINICAL APPLICATIONS. AS SHOWN ON THESE PAGES, MALLINCKRODT INSTITUTE WAS WELL REPRESENTED THROUGH PARTICIPATION IN SCIENTIFIC PRESENTATIONS, REFRESHER COURSES, AND EXHIBITS.



Pamela Woodard, MD



William Middleton, MD



Stephen Moore, MS



# RSNA

## MIR PRESENTATIONS AT RSNA 2002

**David Rubin, MD**, presiding officer, Musculoskeletal (Muscle); coordinator, Ankle MR imaging: techniques, normal anatomy, and common pathology—an interactive session.

**Barry Siegel, MD**, moderator, Optimizing PET interpretation.

**Marilyn Siegel, MD**, director, Screening for cancer minicourses: Basic tenets of screening; Lessons from mammography; CT colonography and total body imaging; Lung cancer screening.

### SPECIAL FOCUS SESSIONS

**Michael Darcy, MD**, "Call me SIR: highlights from the 2002 SCVIR scientific program: New name, new day—Where we are going and why."

**David Hovsepian, MD**, "Endovascular grafts: the role of the radiologist."

**Marilyn Siegel, MD; Vamsidhar Narra, MD**, "CT angiography and MR angiography in pediatrics—current applications."

### IMAGING SYMPOSIUM

**Barry Siegel, MD**, moderator, PET Imaging.

### infoRAD PRESENTATION

**Stephen Moore, MS; Jerold Wallis, MD**, "A MIRC storage service implementation using Java servlets."

### REFRESHER COURSES

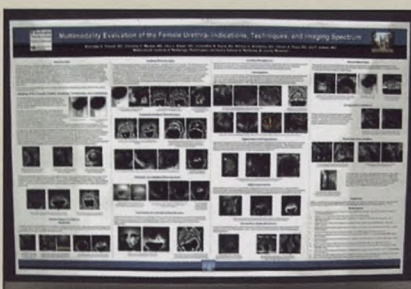
**Sanjeev Bhalla, MD**, "Pediatric thoracic CT. Airway disease: three-dimensional and dynamic imaging."

**Louis Gilula, MD**, "Vertebroplasty: indications, techniques, problems, and complications."

**Fernando Gutierrez, MD**, "Pediatric cardiovascular imaging. Mediastinal vascular anomalies."

**Jay Heiken, MD; Vamsidhar Narra, MD**, "Imaging of focal liver lesions with CT and MR."

**David Hovsepian, MD**, "Hysterosalpingography and selective salpingography ('how-to' workshop.)"



Certificate of Merit and an Excellence in Design Award-winning exhibit

**Elizabeth McFarland, MD**, "Screening for cancer minicourse: CT colonography and total body imaging. CT colonography: techniques and interpretation."

**William Middleton, MD**, "Categorical course in diagnostic radiology: findings at ultrasound—What do they mean?: liver. There are nonhyperechoic lesions in the liver: What does that mean?"

**Barbara Monsees, MD**, "Screening for cancer minicourse: lessons from mammography. Breast cancer screening: the track record"; "Problem-solving breast imaging. Supplementary mammographic views."

**Marilyn Siegel, MD**, "Pediatric CT body imaging: new developments. Multislice CT: applications and techniques."

**Sharlene Teefey, MD**, "Categorical course in diagnostic radiology: findings at ultrasound—What do they mean?: musculoskeletal. This rotator cuff looks abnormal: What does that mean?"; "Musculoskeletal US ('hands-on' workshop)."

**Pamela Woodard, MD**, "Update course: pulmonary and cardiovascular imaging—noninvasive coronary imaging. Coronary MR imaging techniques"; "Cardiovascular MR: cardiac."

### SCIENTIFIC SESSIONS

**Ty Bae, MD, PhD**, "Peak contrast enhancement in CTA and MRA: When does it occur and why?"; "MR imaging to assess the progression of polycystic kidney disease: baseline and ongoing follow-up."

**Ty Bae, MD, PhD; Jin Seung Kim; Jin-Hwan Kim, MD; Yonghum Na**, "Automatic detection of pulmonary nodules in multislice CT: performance of 3D morphologic matching algorithm."

**Ty Bae, MD; Pornpim Fuangthamthit, MD; Srinivasa Prasad, MD; Bonnie Joe, MD, PhD; Jay Heiken, MD**, "Characterization of adrenal masses using histogram analysis method in contrast enhanced CT."

**Sanjeev Bhalla, MD; Fernando Gutierrez, MD; Marilyn Siegel, MD**, "Multidetector computerized tomography (CT) evaluation of vascular shunts: abnormal contrast gradient and positive and negative jet signs."



David Rubin, MD

## RSNA GRANTS/ AWARDS

**Siemens Medical Solutions, Inc./RSNA Research Fellow Bonnie Joe, MD, PhD**, "Evaluation of MR contrast enhancement and MRS in breast cancer: effect of contrast injection rate and effect of contrast on MRS profile."

### RSNA Research Trainee Prize

**Bonnie Joe, MD, PhD**, "Improved reliability of stereology compared with ellipsoid-based uterine and leiomyoma volume measurements."

**Roentgen Resident/Fellow Research Award Bonnie Joe, MD, PhD Edward Pinkus, MD**



Bonnie Joe, MD, PhD

## RSNA 2002 EXHIBIT AWARD WINNERS

### Excellence in Design

**Howard Harvin, MD; Christine Menias, MD; Sanjeev Bhalla, MD; Sharlene Teefey, MD; Srinivasa Prasad, MD; Vamsidhar Narra, MD**, "Imaging of renal transplants: multimodality approach."

**Srinivasa Prasad, MD; Christine Menias, MD; Vikram Patel, MD; Sanjeev Bhalla, MD; Cary Siegel, MD; Jay Heiken, MD**, "Multimodality evaluation of the female urethra—indications, techniques, and imaging spectrum."

### CUM LAUDE

**Christine Menias, MD; Howard Harvin, MD; Sanjeev Bhalla, MD; Christine Peterson, MD; Srinivasa Prasad, MD; Edward Lee, MD, MPH**, "CT evaluation of acute gynecologic conditions: a pictorial review."

### CERTIFICATE OF MERIT

**Sanjeev Bhalla, MD; Fernando Gutierrez, MD**, "CT of the pericardium: normal anatomy and spectrum of disease."

**Howard Harvin, MD; Christine Menias, MD; Sanjeev Bhalla, MD; Sharlene Teefey, MD; Srinivasa Prasad, MD; Vamsidhar Narra, MD**, "Imaging of renal transplants: multimodality approach."

**Christine Menias, MD; Srinivasa Prasad, MD; Howard Harvin, MD; Dennis Balfe, MD; Jay Heiken, MD**, "Cystic pancreatic neoplasms—radiologic-pathologic correlation study."

**Srinivasa Prasad, MD; Christine Menias, MD; Vikram Patel, MD; Sanjeev Bhalla, MD; Cary Siegel, MD; Jay Heiken, MD**, "Multimodality evaluation of the female urethra—indications, techniques, and imaging spectrum."



**Daniel Brown, MD; Louis Gilula, MD; Joshua Shimony, MD, PhD,** "Treatment of chronic symptomatic compression fractures with percutaneous vertebroplasty."

**Dione Farria, MD, MPH; Barbara Monsees, MD; Charles Hildebolt, DDS, PhD; Kimberly Wiele, MD; Maria Schmidt, MD; Prem Sri Barton, MD,** "Digital and screen-film diagnostic mammography: a time-motion study."

**Cheng Hong, MD, PhD; Ty Bae, MD, PhD; Thomas Pilgram, PhD; Jong Dae Suh, MD; David Bradley, PhD,** "In vitro assessment of the effect of radiation dose on coronary artery calcium measurement using multidetector row CT."

**Bonnie Joe, MD, PhD; Jong Dae Suh, MD, PhD; Charles Hildebolt, DDS, PhD; David Hovsepian, MD; Ty Bae, MD, PhD,** "Improved reliability of stereology compared with ellipsoid-based uterine and leiomyoma volume measurements."

**Robert Kadner, MD; Ty Bae, MD, PhD; Jay Heiken, MD; Christine Menias, MD; Dennis Balfe, MD,** "Presence and clinical implication of appendicolith in pelvic CT."

**Edward Lee, MD, MPH; Vamsidhar Narra, MD; Jeffrey Brown, MD; Jay Heiken, MD; Mehdi Poustchi-Amin, MD,** "Detection, staging and assessment of surgical resectability of pancreatic ductal adenocarcinoma: a comparison of dynamic contrast-enhanced spiral CT, dynamic gadolinium-enhanced MRI and Mn-DPDP enhanced MRI."

**Edward Lee, MD, MPH; Christine Menias, MD; Amy Hara, MD; Dennis Balfe, MD; Srinivasa Prasad, MD; Jay Heiken, MD,** "A comparison of multiplanar CT and axial CT in diagnosis of small bowel obstruction."

**William Middleton, MD; Sharlene Teefey, MD,** "Ultrasonographic characteristics of full-thickness tendon tears."

**Vikram Patel, MD; Sharlene Teefey, MD; William Middleton, MD,** "The role of high resolution US for evaluating focal lesions of the hand and wrist."

**Grace Phillips, MD; Marilyn Siegel, MD; Sanjeev Bhalla, MD; Fernando Gutierrez, MD; Charles Hildebolt, DDS, PhD,** "Surveillance CT scanning of children after lung transplantation for detection of post-transplant lymphoproliferative disorder (PTLD)."

## RSNA 2002 FACTS AND FIGURES

- 298 refresher courses were presented.
- More than 120 educational and commercial exhibits were included in infoRAD.
- There were an estimated 59,200 attendees (an 11% increase as compared with the 2001 meeting).
- 29,323 exhibitors attended this year's meeting.
- 2002 was the fourth year for the IHE Vendor Demonstrations.
- 2002 was the first year for a select number of scientific presentations presented via an intranet system.
- The Philips Medical of North America exhibit booth encompassed 24,000 square feet.
- A visitor spends an average of 30 minutes in an exhibit booth.

**Yonglin Pu, MD, PhD; Mark Mintun, MD; Stephen Moerlein, PhD,** "[<sup>11</sup>C]flumazenil PET in the localization of the focus of epileptogenicity and surgical decision-making in intractable extra-limbic epilepsies."

**Joshua Shimony, MD, PhD; Louis Gilula, MD; Daniel Brown, MD,** "Vertebroplasty in patients with epidural extension of tumor."

**Sharlene Teefey, MD; Charles Hildebolt, DDS, PhD; William Middleton, MD,** "The demographics and morphology of rotator cuff disease: a comparison of asymptomatic and symptomatic shoulders."

## SCIENTIFIC EXHIBITS

**Sanjeev Bhalla, MD; Fernando Gutierrez, MD,** "CT of the pericardium: normal anatomy and spectrum of disease."

**Dionne Faria, MD, MPH; Edward Lee, MD, MPH; Susannah Thurman, MD; Prem Sri Barton, MD,** "Characterizing mural abnormalities in breast cysts."

**Howard Harvin, MD; Christine Menias, MD; Sanjeev Bhalla, MD; Sharlene Teefey, MD; Srinivasa Prasad, MD; Vamsidhar Narra, MD,** "Imaging of renal transplants: multimodality approach."

**Anil Khosla, MD,** "Cavernous angioma of brain and spinal cord."

**Jin Kim, MD, PhD; Anil Ambekar; Ty Bae, MD,** "World wide web-based interactive training for the detection of pulmonary nodules on chest radiographs."

**Edward Lee, MD, MPH; Marilyn Siegel, MD; Fernando Gutierrez, MD; Sanjeev Bhalla, MD; Mehdi Poustchi-Amin, MD,** "Mediastinal and pulmonary vascular anomalies: a pictorial review with emphasis on multi-row detector CT and fast MR technique, and on the multiplanar and three-dimensional appearance of vascular anomalies."

**Edward Lee, MD, MPH; Christine Menias, MD; Jay Heiken, MD; Dennis Balfe, MD; Srinivasa Prasad, MD,** "Multiplanar CT evaluation of small bowel obstruction: techniques and clinical applications."

**Christine Menias, MD; Howard Harvin, MD; Sanjeev Bhalla, MD; Christine Peterson, MD; Srinivasa Prasad, MD; Edward Lee, MD, MPH,** "CT evaluation of acute gynecologic conditions: a pictorial review."

**Christine Menias, MD; Srinivasa Prasad, MD; Howard Harvin, MD; Dennis Balfe, MD; Jay Heiken, MD,** "Cystic pancreatic neoplasms—radiologic-pathologic correlation study."

**Mehdi Poustchi-Amin, MD; Edward Lee, MD, MPH; Markus Lammle, MD; Kianoush Rezaei, MD; Vamsidhar Narra, MD; Jeffrey Brown, MD,** "Practical MRI of the liver: principles and applications—a review for the general radiologist."

**Srinivasa Prasad, MD; Jay Heiken, MD; Christine Menias, MD; Aamer Farooki, MD; Ty Bae, MD, PhD,** "Malignant neoplasms of the renal medulla—radiologic-pathologic correlation study."

**Srinivasa Prasad, MD; Christine Menias, MD; Humberto Rosas, MD; Sanjeev Bhalla, MD; Jay Heiken, MD,** "Fat-containing liver lesions: radiologic-pathologic correlation."

**Srinivasa Prasad, MD; Christine Menias, MD; Vikram Patel, MD; Sanjeev Bhalla, MD; Cary Siegel, MD; Jay Heiken, MD,** "Multimodality evaluation of the female urethra—indications, techniques, and imaging spectrum."

**Matthew Wiggins, MD; Christine Menias, MD; Srinivasa Prasad, MD; Ty Bae, MD, PhD,** "Imaging findings of primary hepatic lymphoma."

## CASE OF THE DAY

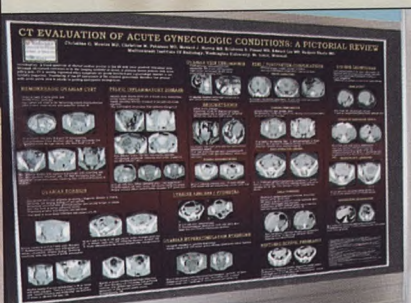
**Sanjeev Bhalla, MD; Jason Bronfman, MD; Andrew Bierhals, MD—Chest.**

**Sanjeev Bhalla, MD—GI.**

**Juliet Fallah, MD; Sanjeev Bhalla, MD; Pamela Woodard, MD—Cardiac.**



Cases of the Day



Cum Laude Award-winning exhibit



# *The Annual* **MIR/RSNA** *Reception*

ON DECEMBER 2,  
MALLINCKRODT INSTITUTE  
AND SIEMENS MEDICAL  
SOLUTIONS COSPONSORED  
A RECEPTION FOR FACULTY,  
ALUMNI, AND FRIENDS OF  
THE INSTITUTE THAT WAS  
HELD IN THE HYATT  
REGENCY CHICAGO'S ELEGANT  
CRYSTAL BALLROOM.



Joseph Lee, MD (former chief of MIR's magnetic resonance imaging), and Christina Lee



Gilbert Jost, MD, director of the Institute, welcomes everyone to the annual reception.



Clark West, MD, (left) and William Murphy, MD—former faculty in the Institute's musculoskeletal radiology section




Ty Bae, MD, PhD; Santiago Medina, MD (former MIR resident); Klaus Hambuechen, Siemens Medical Solutions; Shawn Quillin, MD (former MIR resident)



Anthony Wilson, MD (former MIR faculty)



Perry Pickhardt, MD; Sandy Ruhs, MD; Harold Bennett, MD—MIR alumni



Tom McCausland, Siemens Medical Solutions





Peggy Jost; Robert Stanley, MD (former chief of MIR's abdominal radiology); Sally Stanley



(Left to right) Gilbert Cheung, WUSM student; Scott Bolton, MD, MIR resident; Dennis Balfe, MD, director of the Institute's Diagnostic Radiology Residency Program; Judy Liu, MD, MIR resident; and Kevin Lee, MD, MIR resident



James Blaine, DSc; David Melson; and Bruce McClennan, MD (former chief of MIR's abdominal radiology)



Vamsidhar Narra, MD, (left) and Russell Madonia, Siemens Medical Solutions



(Left to right) Steve Shihadeh, Vern Davenport, Johannes Naerger, and Richard Brockman of Siemens



*In this section, the names of employees who are full-time faculty or staff or who have an appointment in the Department of Radiology or Department of Radiation Oncology are highlighted in boldface type.*

## PROMOTIONS

**Keith Kronemer, MD**, instructor in radiology, was promoted to assistant professor of radiology, Division of Diagnostic Radiology, Department of Radiology.

**Milos Vicic, PhD**, research associate, was promoted to instructor in radiation oncology, Department of Radiation Oncology.

## NEW FACULTY

**Richard Dorshow, PhD**, visiting research instructor, Division of Radiological Sciences, Department of Radiology.

## GRANTS

**David Gierada, MD**, assistant professor of radiology, as principal investigator, received a \$1.5 million grant from the National Institutes of Health/National Heart, Lung, and Blood Institute for research on "He-3 MR diffusion and low dose CT quantitation of emphysema." Coinvestigators for the four-year grant are **Dmitriy Yablonskiy, PhD**, assistant professor of radiology and professor of physics, and **Mark Conradi, PhD**, professor of physics and of radiology.

**Tej Pandita, PhD**, assistant professor of radiation oncology, as principal investigator, received a \$300,000 grant from the United States Department of Defense for research on "Chromatin structure and breast cancer radiosensitivity." Coinvestigators for the three-year grant are **Arun Gupta, PhD**, research associate; **Girdhar Sharma, PhD**, research associate; and **Sonu Dhar, MSc**, senior research technician. Pandita also received a National Institutes of Health grant for \$371,172 to study "Chromatin-telomere structure and AT genomic sensitivity." Coinvestigators for the one-year grant are Gupta and Sharma.

**Bradley Schlaggar, MD, PhD**, instructor in neurology and in radiology, received The Charles A. Dana Foundation Award in Clinical Hypotheses in Imaging for research on "The development of cognitive function in

Tourette Syndrome; fMRI studies." **Steven Petersen, PhD**, professor of neurology, of anatomy and neurobiology, and of radiology, is coinvestigator for the three-year, \$100,000 grant. Schlaggar received a four-year grant of \$300,000 from The John Merck Scholars Fund in the Neurobiology of Developmental Disabilities for research on "Normal and abnormal development of cognitive control; fMRI studies." He received The Burroughs-Wellcome Fund Career Award in Biomedical Sciences, a five-year, \$500,000 grant to fund his study of "Development of cognitive function; fMRI studies." Schlaggar received a two-year grant of \$80,000 from the McDonnell Center for Higher Brain Function for research on "The development of reading-related skills in developmental dyslexia; a pilot fMRI study to inform directed clinical interventions."

**Pamela Woodard, MD**, assistant professor of radiology, is principal investigator for the Mallinckrodt Institute/Washington University arm of a multicenter study to assess the accuracy and usefulness of multidetector spiral CT in the detection of pulmonary embolism. The study, Prospective Investigation in Pulmonary Embolism DX-II, is funded by a \$13.5 million grant from the National Institutes of Health.

## APPOINTMENTS/ELECTIONS

**Jeffrey Brown, MD**, associate professor of radiology, was appointed to an indefinite term as chairman of the American College of Radiology MR Standards Committee.

**Colin Derdeyn, MD**, associate professor of radiology, was appointed to a two-year term as chairman of the Membership Committee of the American Heart Association Stroke Council.

**Gilbert Jost, MD**, professor of radiology and director of the Institute, was appointed as an alternate councilor of the American College of Radiology, representing the Radiological Society of North America.



**Daniel Low, PhD**, associate professor of radiation oncology, was elected to the Board of Directors of the Hillel Center at Washington University.

**Tej Pandita, PhD**, assistant professor of radiation oncology, was appointed to one-year terms on the Radiation Oncology Department Steering Committee and the Radiation Oncology Department Research Committee.

**Bradley Schlaggar, MD, PhD**, instructor in neurology and in radiology, was appointed to the Medical Advisory Board of the Missouri Branch of the Tourette Syndrome Association.

**Marilyn Siegel, MD**, professor of radiology and of pediatrics, was appointed courses director for the Twelfth Summer Practicum of the Society of Computed Body Tomography and Magnetic Resonance Imaging held August 18-21 in Napa, California.

## HONORS/ AWARDS

**Louis Gilula, MD**, professor of radiology and of surgery, was named chairman of the Organizing Committee of the Wrist Investigators' Workshop held in Phoenix, Arizona, in October. He received the Favorite Son Award at the November 7th meeting of the Illinois Medical Society held in Belleville, Illinois.

**Anil Khosla, MD**, instructor in radiology, served as a Radiological Society of North America international visiting professor at the XXI Interamerican Congress of Radiology, XVII Colombian Congress of Radiology, and VI Latin American Congress of Pediatric Radiology in Cartagena, Colombia, October 12-16.

**Elizabeth McFarland, MD**, associate professor of radiology, was named a grant reviewer for the National Institute of Biomedical Imaging and Bioengineering institutional predoctoral/MSTP training grants.

**Pamela Woodard, MD**, assistant professor of radiology, served as moderator of "Basic Cardiac Imaging" at the 30<sup>th</sup> Annual Meeting and Scientific Sessions of the North American Society of Cardiac Imaging (NASCI), Dallas, Texas, September 21. She also is a member of the NASCI Board of Directors. Woodard served as moderator of "Molecular Basis for Cardiac Imaging" at the 2002 Scientific Sessions of the American Heart Association, Chicago, Illinois, November 17.

## Melson Lecture

On September 9, Stephanie Wilson, MD, head of ultrasound, Toronto General Hospital, and professor of medical imaging, University of Toronto, presented the Tenth Annual G. Leland Melson Visiting Professorship and Lecture—"Microbubble contrast agents for ultrasound: their role in the imaging of liver and renal masses." Shown with Wilson (second from left) are William Middleton, MD, professor of radiology; Sharlene Teefey, MD, head of ultrasonography; and Jay Heiken, MD, chief of abdominal radiology.





## LECTURES/ PRESENTATIONS

**Carolyn Anderson, PhD**, associate professor of radiology and of molecular biology and pharmacology, presented "<sup>64</sup>Cu-DOTA-CTTH-WGFTLC, a radiolabeled gelatinase inhibitor for PET imaging of metastatic breast cancer" at Era of Hope 2002, the Department of Defense Breast Cancer Research Program Meeting, Orlando, Florida, September 27.

**Ty Bae, MD, PhD**, assistant professor of radiology, presented "Contrast injection techniques and CT scan timing" at the 6th International Somatom CT Scientific User Conference, Tubingen, Germany, September 27 and 28.

**Jeffrey Bradley, MD**, assistant professor of radiation oncology, spoke on "Introduction to radiation oncology" at The Practice of Medicine II Course, Washington University School of Medicine, St. Louis, Missouri, September 4.

**Farrokh Dehdashti, MD**, associate professor of radiology, presented "Breast imaging with PET" at the Missouri Valley Chapter Society of Nuclear Medicine meeting, Kansas City, Missouri, October 12.

**Colin Derdeyn, MD**, associate professor of radiology, presented "The carotid occlusion surgery study" at Neurology Grand Rounds, St. Louis University School of Medicine, St. Louis, Missouri, September 19. He spoke on "Rationale for the new EC/IC bypass trial" at Neurosurgery Grand Rounds, University of Virginia School of Medicine, Charlottesville, Virginia, October 5. Derdeyn spoke on "Treatment of carotid atherosclerotic disease: medicine, surgery, or stent" at the Advances in Stroke Care Symposium, sponsored by the Washington University Stroke Center, St. Louis, Missouri, November 9.


**David Gierada, MD**, assistant professor of radiology, spoke on "Radiologic screening for early lung cancer" at Lung Cancer in 2002, the 7th Annual Missouri Baptist Medical Center Cancer Conference, St. Louis, Missouri, October 4.

**Louis Gilula, MD**, professor of radiology and of surgery, spoke on "Postoperative wrist" at the International Skeletal Society, Geneva, Switzerland, September 25. He presented "Non-surgical treatment of lumbar disc disease: selective nerve blocks" at Emerging Technologies in Spinal Surgery, Washington, DC, October 18. Gilula spoke on "Vertebroplasty" at the Illinois Medical Society Meeting, Belleville, Illinois, November 7.

**Perry Grigsby, MD**, professor of radiation oncology and of radiology, presented "Combined modality therapy and FDG-PET for cervical carcinoma" at Oncology Perspectives 2002, sponsored by the Oklahoma Society of Clinical Oncology, Oklahoma City, Oklahoma, September 21.

## Probstein Lecture

As invited speaker for the Norman K. Probstein Oncology Lecture on September 27, Anthony D'Amico, MD, PhD, chief of genitourinary radiation oncology, Dana Farber Cancer Institute, Harvard University, presented "Determinants of prostate cancer: specific and overall survival following external beam radiation therapy for localized prostate cancer." Shown with D'Amico (center) are Jeff Michalski, MD, chief of clinical service, and Carlos Perez, MD, chairman, Department of Radiation Oncology.





**Thomas Herman, MD**, associate professor of radiology, spoke on "Urological imaging in pediatric radiology" and "Radiology of benign bone lesions of childhood" at Current Medical Imaging, sponsored by the Ukrainian Radiological Association, Lviv, Ukraine, September 1-7.

**Pilar Herrero, MS**, research scientist of radiology, presented "Impact of increased lipid delivery on myocardial fatty acid oxidation in type I diabetics" at the American Medical Association Scientific Sessions, Chicago, Illinois, November 17-20.

**Jay Heiken, MD**, professor of radiology, chief of abdominal imaging, and codirector of body computed tomography, presented "CT of small bowel obstruction"; "CT of the abdominal aorta: aneurysm rupture and post-operative complications;" and "Incidental liver lesions: making the diagnosis with CT and MRI" at the Twelfth Summer Practicum of the Society of Computed Body Tomography and Magnetic Resonance, Napa, California, August 18-22. He spoke on "Volumetric CT imaging of the liver," "Volumetric CT imaging of the pancreas,"

and "Volumetric CT imaging of the small bowel and colon" at "Gourmet" Body Imaging: Volumetric CT and MR Applications, sponsored by the Ospedale Maggiore, Policlinico, Milan, and Yale University, Milan, Italy, September 27-28. Heiken spoke on "Detection and staging of pancreatic cancer" and "CT colonography" at the International Cancer Imaging Society, Third Annual Teaching Course, Paris, France, October 7-9.

**Elizabeth McFarland, MD**, associate professor of radiology, spoke on "CT colonography—2D and 3D image displays to detect colon cancer" at the American College of Gastroenterology Postgraduate Course, Seattle, Washington, October 19. She spoke on "CT colonography" and "Techniques and applications of 3D" at Clinical Essentials of CT and MRI, Chicago, Illinois, October 24. As the Seymour Ochsner Lecturer, McFarland presented "CT colonography" at the Ochsner Clinic Foundation, New Orleans, Louisiana, November 2.

**Franklin Marden, MD**, diagnostic radiology resident, as invited lecturer, presented "Imaging of Duchenne muscular dystrophy" to the Cooperative International Neuromuscle Research Group, Washington, DC, November 2 and 3.

## MR Training Course

The Institute sponsored a cardiac MR training course, "Cardiovascular MR: Hands-on Experience," on September 9 through the 11th in the Scott Avenue East Building. Under the direction of **Pamela Woodard, MD**, course participants learned how to perform cardiovascular MR on a dedicated whole-body cardiac MR system. Course faculty: MIR's **Fernando Gutierrez, MD**, associate professor of radiology; **Vamsidhar Narra, MD**, assistant professor of radiology; **Robert Gropler, MD**, associate professor of radiology, of medicine, and of biomedical engineering; and **Jie Zheng, PhD**, research assistant professor of radiology. Course staff: MIR's **Glenn Foster, RT**, research patient coordinator; **Deborah Delano, RN**, clinical lab manager; and **Richard Nagel, RT**, research patient coordinator.

**Jeff Michalski, MD**, associate professor of radiation oncology and director of the Clinical Division, presented "Advances in radiotherapy: brachytherapy and external beam" at the International Center for Post Graduate Medical Education Meeting, Nashville, Tennessee, August 2. He presented "Novel therapeutic modalities: innovations in radiation therapy" at the Societe Internationale d'Oncologie Pediatrique,

Porto, Portugal, September 20. Michalski spoke on "Current trends in prostate cancer: advances in radiotherapy: brachytherapy and external beam" at the Physicians' Education Resource, New Orleans, Louisiana, November 16. He spoke on "Brachytherapy for prostate cancer" at the Greater St. Louis Society of Radiologists meeting, St. Louis, Missouri, November 19.



## LECTURES/PRESENTATIONS

*Continued from page 27*

**Vamsidhar Narra, MD**, assistant professor of radiology and codirector of body magnetic resonance imaging, presented "Basic principles of 3D contrast enhanced MR angiography" and "MR angiography of the abdomen—clinical applications" at the Non-Invasive Vascular Imaging Symposium, Dallas, Texas, August 3; Phoenix, Arizona, August 10; and Newport Beach, California, September 23. He presented "MR imaging of the abdomen—an update" at Galaxy of Gastroenterology II, sponsored by the Division of Gastroenterology, Washington University, St. Louis, Missouri, November 9. Narra spoke on "Peripheral MR angiography" at the Greater St. Louis Radiological Society meeting, St. Louis, Missouri, November 19.

**Tej Pandita, PhD**, assistant professor of radiation oncology, presented "hTERT associates with human telomeres and enhances genomic stability and DNA repair" at Tumor Suppressor and Cancer Genetics, sponsored by the Cold Spring Harbor Laboratory, Cold Spring Harbor, New York, August 14-18.

**William Powers, MD**, professor of radiology, of neurology, and of neurological surgery, spoke on "Carotid occlusion surgery study" at Stroke Treatments 2002: Clinical Trials Planned and Completed, Columbia University, New York City, New York, October 12.

**David Reichert, PhD**, research instructor in radiology, presented "QSAR studies for estrogen receptor PET tracers" at the 224<sup>th</sup> National Meeting of the American Chemical Society, Boston, Massachusetts, August 20.

## Scott Lecture

On October 14, Robert Stanley, MD, former chief of MIR's abdominal radiology, returned to the Institute as invited speaker for the Thirty-first Annual Wendell G. Scott Memorial Lecture. Stanley, professor and chairman, Department of Radiology, University of Alabama, Birmingham, spoke on "Inherent dangers in radiologic screening." Gilbert Jost, MD, director of the Institute, presented Stanley (right) with a commemorative plaque

**Joseph Roti Roti, PhD**, professor of radiation oncology and chief of the Division of Radiation and Cancer Biology, presented "Can RF radiation from cellular telephones cause cancer? An overview of the results from the Washington University program" at the Ninth Annual Michaelson Research Conference, Portland, Maine, August 9-12, and at Old Dominion University, Norfolk, Virginia, November 15.

**Stuart Sagel, MD**, professor of radiology, chief of chest radiology, and codirector of body computed tomography, presented "CT pulmonary angiography for pulmonary embolism: alternative/additional diagnoses"; "Chest CT case discussions"; and "CT of the pleura" at the Twelfth Summer Practicum of the Society of Computed Body Tomography and Magnetic Resonance, Napa, California, August 18-22. As a Radiological Society of North America visiting professor, Sagel presented "CT





pulmonary angiography for pulmonary embolism: technique, interpretation, role"; "CT pulmonary angiography for pulmonary embolism: alternative/additional diagnoses"; "CT of the thoracic aorta"; "Role of CT in bronchogenic carcinoma"; "CT of the pleura"; "CT of the pericardium"; "CT of the thorax: problematic cases"; and "CT of non-vascular mediastinal masses" to the Department of Radiology, Universidad Catolica, Santiago, Chile, September 30 - October 11.

**Bradley Schlaggar, MD, PhD**, instructor in neurology and in radiology, spoke on "Postnatal brain development: experience and plasticity" at the Human Development Seminar Series, sponsored by the University of California, San Diego, California, October 18. He presented "Functional MRI and cognitive development" at the Department of Anatomy and Neurobiology Seminar Series, University of Kentucky, Lexington, Kentucky, October 21.

**Maria Schmidt, MD**, assistant professor of radiology, as a Radiological Society of North America visiting professor, presented "Overview of breast imaging," "Cases," and "Supplementary mammographic views" at the Colonial War Memorial Hospital, Suva, Fiji, August 5-9. As RSNA visiting professor, she spoke on "The WHO classification of breast lesions," "Breast imaging cases," "Breast interventions," and "Multidisciplinary care of breast patients" at

the Royal Australasian and New Zealand College of Radiologists New Zealand Branch Annual Scientific Meeting, Wellington, New Zealand, August 9-11.

**Marilyn Siegel, MD**, professor of radiology and of pediatrics, spoke on "CT/MRI of pediatric renal and adrenal tumors" at the 12<sup>th</sup> Summer Practicum of the Society of Computed Body Tomography and Magnetic Resonance Imaging, Napa, California, August 18-21. She spoke on "Ultrasound of neonatal congenital brain anomalies" and "Neonatal renal ultrasound" at the 23<sup>rd</sup> Annual Sonic Symposium, Biloxi, Michigan, August 24. As invited guest lecturer, Siegel presented "Multislice CT in children," "MRI of pediatric hepatic masses," "MRI of pediatric abdominal masses," and "CT of congenital lung lesions" at the Harvard Medical School Course on Pediatric CT and MRI: Present and Future, Boston, Massachusetts, September 13 and 14. She presented "Multislice CT: techniques and applications in children" at the 6<sup>th</sup> International Somatom CT Scientific User Conference, Tubingen, Germany, September 27 and 28. Siegel, as keynote speaker, presented "Multislice CT: cardiovascular and airway applications in children" and spoke on "Sonography of congenital brain lesions"; "CT of lung trans-

plantation: a decade of experience"; "Pediatric gynecologic ultrasonography"; and "CT of dynamic CT imaging of the airway" at the XXI Interamerican Congress of Radiology, XVII Colombian Congress of Radiology, and VI Latinamerica Congress Pediatric of Radiology, Cartagena, Colombia, October 13-16.

**Barry Siegel, MD**, professor of radiology and of medicine, and director of the Division of Nuclear Medicine, presented "Interpreting F-18 FDG images" and "PET in oncology: breast and gynecological CA" at the American College of Radiology Annual Meeting Categorical Course: PET Imaging for the Radiologist, Miami Beach, Florida, September 28. He spoke on "The role of positron emission tomography in the diagnosis and management of lung cancer" at Lung Cancer in 2002, the 7<sup>th</sup> Annual Missouri Baptist Medical Center Cancer Conference, St. Louis, Missouri, October 4. He presented "PET imaging in esophageal cancer" and "PET imaging in lung cancer" at the New England and Greater New York Chapters of the Society of Nuclear Medicine Sixteenth Annual Northeast Regional Scientific Meeting,

Newport, Rhode Island, November 1-3. As the Sheldon H. Miller, MD '55 and Edward I. Miller, MD '60 Visiting Clinical Scholar in Radiology, Siegel presented "Clinical applications of PET in oncology" at the University of Illinois at Chicago College of Medicine Cancer Center, Chicago, Illinois, November 7.

**Joseph Simpson, MD, PhD**, professor of radiation oncology, as the William E. Allen, Jr. Memorial Lecturer, presented "Challenges ahead for radiation oncology" at the 100<sup>th</sup> Annual Convention and Scientific Assembly of the National Medical Association, Honolulu, Hawaii, August 3-8.

**Franz Wippold, MD**, associate professor of radiology and chief of neuroradiology, presented "Interpretation of emergent brain scans" at Evidence-based Stroke Management and Prevention, sponsored by Washington University, St. Louis, Missouri, November 9.



## SYMPOSIA

*In this section of FYI, only those faculty and staff who have Department of Radiology or Department of Radiation Oncology appointments are listed.*

### AMERICAN SOCIETY FOR THERAPEUTIC RADIOLOGY AND ONCOLOGY

*44th Annual Meeting  
New Orleans, Louisiana  
October 6-10, 2002*

#### REFRESHER COURSES

**Perry Grigsby, MD**, "Well differentiated thyroid cancer."

**Jeff Michalski, MD; Carlos Perez, MD; James Purdy, PhD**, "Toxicity following 3D radiation therapy for prostate cancer on RTOG 9406 dose level IV."

**Sasa Mutic, MS**, "CT simulation process and techniques."

#### SCIENTIFIC SESSIONS

**Walter Bosch, DSc; Robert Malyapa, MD, PhD; Jason Lewis, PhD; Farrokh Dehdashti, MD; Michael Welch, PhD**, "Evolution of tumor hypoxia during radiotherapy predicts treatment response: implication of hypoxic imaging-guided IMRT."

**Jeffrey Bradley, MD; Joseph Deasy, PhD; Walter Bosch, DSc; James Purdy, PhD**, "Irradiated esophageal surface area predicts for esophagitis in patients treated for non-small cell carcinoma of the lung."

**Daniel Low, PhD; Randy Buckner, PhD; Joseph Deasy, PhD; Joseph Simpson, MD, PhD**, "Can functional imaging support brain dose escalation using IMRT?"

**Robert Malyapa, MD, PhD; Nobuo Horikoshi, PhD; Farrokh Dehdashti, MD; Mark Mintun, MD; Barry Siegel, MD; Perry Grigsby, MD**, "Molecular markers associated with poor prognosis in hypoxic tumors of uterine cervix."

**Anurag Singh, MD; Perry Grigsby, MD; Farrokh Dehdashti, MD; Barry Siegel, MD**, "FDG-PET lymph node staging and survival of patients with FIGO stage IIIB cervical carcinoma."

**Jason Sohn, PhD; Daniel Low, PhD; David Mansur, MD**, "Quantification of intra- and interfraction uncertainty during breast radiotherapy using an electronic portal imaging device for the implementation of IMRT."

**Binh Tran, MD; Perry Grigsby, MD; Farrokh Dehdashti, MD; Barry Siegel, MD**, "Frequency and prognostic significance of clinically occult supraclavicular lymph node metastases in cervical cancer patients identified by FDG-PET."

#### POSTER PRESENTATIONS

**Angel Blanco, MD; Joseph Deasy, PhD; Daniel Low, PhD**, "Recovery kinetics of salivary function in patients with head and neck cancers receiving radiation therapy."

**Daniel Low, PhD; Jeffrey Bradley, MD; David Politte, DSc; Sasa Mutic, MS; Joseph Deasy, PhD; Konstantin Zakaryan, PhD**, "A method for the four-dimensional measurement of normal and cancerous lung during free breathing."

**David Mansur, MD; Jeff Michalski, MD; Perry Grigsby, MD; Mary Ann Lockett, MBA; Joseph Simpson, MD, PhD**, "Long term results of surgery and postoperative radiation therapy in the curative management of intracranial ependymoma."

**Jeff Michalski, MD**, "Prostate localization."

## Perez Lecture

The Second Annual Carlos A. Perez Endowed Lectureship in Oncology was presented on November 1 by James Cox, MD, professor and chairman, Department of Radiation Oncology, M. D. Anderson Cancer Center, University of Texas, Houston. Cox (center), shown with Todd Wasserman, MD, professor of radiology, and (right) Carlos Perez, MD, chairman, Department of Radiation Oncology, spoke on "Improved outcomes in the treatment of lung cancer."





**Robert Myerson, MD, PhD; Wade Thorstad, MD,** "Alternating cycles of full dose split course radiation therapy and gemcitabine chemotherapy for unresectable pancreatic carcinoma."

**Marie Taylor, MD; David Mansur, MD; Jeffrey Bradley, MD; Robert Myerson, MD, PhD; Carlos Perez, MD; Imran Zoberi, MD; Mary Ann Lockett, MBA,** "The effect of regional nodal irradiation on local control, disease-free survival and overall survival in 1-3 node positive breast cancer patients treated with breast conservation therapy."

## ACADEMY OF MOLECULAR IMAGING

*Annual Conference  
San Diego, California  
October 23-27, 2002*

**Barry Siegel, MD,** program committee, Institute for Clinical PET.

## CLINICAL APPLICATIONS OF ONCOLOGIC PET: REVIEW WITH THE EXPERTS

**Farrokh Dehdashti, MD,** "PET in gynecologic cancers."

**Barry Siegel, MD,** "Artifacts."

## TREATMENT ASSESSMENT WITH PET

**Jeffrey Bradley, MD,** "Radiotherapy treatment planning. The use of positron emission tomography in imaging-guided radiation therapy."

## BRAIN PET

**Joel Perlmutter, MD,** "Movement disorders (and other receptor imaging)."

**William Powers, MD,** "O-15 imaging in cerebrovascular disease."

## SCIENTIFIC SESSIONS

**Joonyoung Kim, PhD; Terry Sharp; Pilar Herrero, MS; John Engelbach; Nicole Mercer; Lynne Jones; Michael Welch, PhD,** "Quantification of 18 FDG myocardial glucose utilization in mice with microPET."

**Richard Laforest, PhD,** "CMS microPET-R4: a performance evaluation."

**Jason Lewis, PhD; Joonyoung Kim, PhD; Michael Welch, PhD,** "MicroPET imaging to monitor distribution of chemotherapeutic 2DG and physiological effects of therapy."

**Wen Ping Li, PhD; Jason Lewis, PhD; Martin Eiblmaier; Shawn Lan; Carolyn Anderson, PhD,** "In vitro and in vivo evaluation of a radiolabeled gelatinase inhibitor for micro PET imaging of metastatic breast cancer."

**Nobuyuki Oyama, MD, PhD; Datta Ponde, PhD; Carmen Dence, MS; Joonyoung Kim, PhD; Terry Sharp; Lynne Jones; John Engelbach; Nicole Mercer; Jerrel Rutlin; Barry Siegel, MD; Michael Welch, PhD,** "In vivo evaluation of 18F-fluoroacetate: a potential acetate analog for tumor imaging."

## Tolmach Lecture

On November 8, Gloria Li, PhD, Department of Medical Physics, Memorial Sloan-Kettering Cancer Center, New York, presented the Eleventh Annual Leonard J. Tolmach Memorial Lecture. Li spoke on "Role of DNA-PK in radiation response: potential for cancer gene therapy."

**Douglas Rowland, PhD; Joonyoung Kim, PhD; Richard Laforest, PhD; Yuan-Chuan Tai, PhD; Michael Welch, PhD,** "Dependence of microPET resolution on the energy window and normalization for BR-76."

**Terry Sharp; Joonyoung Kim, PhD; Carmen Dence, MS; Lynne Jones; Nicole Mercer; John Engelbach; Pilar Herrero, MS; Michael Welch, PhD,** "Quantification of cardiovascular metabolism in mice."

**Yuan-Chuan Tai, PhD,** "MicroPET II: first results from an ultra-high resolution small animal PET system."

**Zheng Wang, PhD; David Reichert, PhD; Joonyoung Kim, PhD,** "Dynamic microPET studies of the initiation and mechanism of an antibody-mediated joint-specific murine model of rheumatoid arthritis."

## RADIATION AND BIOLOGICAL SCIENCES SYMPOSIUM

*18th Annual Meeting  
St. Louis, Missouri  
November 8-9, 2002*

**Joseph Roti Roti, PhD,** chair, program committee.

**Kathy Bles,** chair, local arrangements committee.

## SYMPOSIUM I: STRESS RESPONSES AND THERAPEUTIC APPROACHES

**Clayton Hunt, PhD,** "Characterization of the HSC110 member of the HSP110 gene family."

**Andrei Laszlo, PhD,** "Potential mechanisms of heat-resistance in oxidative stress resistant cells."

**Jacob Locke, MD,** "Celecoxib may enhance the cytotoxicity of heat shock using alternate pathways than nonspecific cox inhibitor NSAIDs."



## SYMPOSIA

Continued from page 31

**Buck Rogers, PhD**, "Non-invasive imaging and therapy in mice bearing human non-small cell lung tumor xenografts induced to express human somatostatin receptor subtype 2 with an adenoviral vector."

**SYMPOSIUM II: CELLULAR INTERACTIONS AND INTRACTIONS WITH THE EXTRACELLULAR MATRIX**

**Buck Rogers, PhD**, chair.

**Timothy Whitehead, DSc**, "Possible uses of quasi-steady-state, 3-dimensional cell culture techniques in cancer research."

**WORKSHOP I: BIOLOGICAL EFFECTS AND THERAPEUTIC APPLICATIONS OF ELECTROMAGNETIC ENERGY**

**Eduardo Moros, PhD; Bibiana Cha, BS; William Straube, MS**, "Thermal controls for achieving time-average cell-layer SARs of 10 W/kg in the RTL irradiator."

**Graham Hook, MD; Eduardo Moros, PhD; William Straube, MS; Joseph Roti Roti, PhD**, "Measurements of alkali labile DNA damage and protein-DNA crosslinks following 2450 MHz microwave and low-dose  $\gamma$ -irradiation *in vitro*."

**Eduardo Moros, PhD; William Straube, MS; Joseph Roti Roti, PhD**, "The effect of chronic exposure to 835.62 MHz FDMA or 847.74 MHz CDMA on the incidence of spontaneous tumors in rats."

**Joseph Roti Roti, PhD**, "Past, present, and future of RF work at Washington University."

**Timothy Whitehead, DSc; Joseph Roti Roti, PhD; Graham Hook, MD; Eduardo Moros, PhD**, "Use of gene chip technology to investigate change gene expression caused by exposure to CDMA and FDMA RF."

**SYMPOSIUM III: HEAT-INDUCED CHANGES IN PROTEIN-PROTEIN AND PROTEIN-DNA INTERACTIONS AND RADIOSENSITIVITY**

**Tej Pandita, PhD**, chair.

**Andrei Laszlo, PhD; Amanda Harvey; Jason Mueller, BA**, "Alterations in heat-induced radiosensitization in permanently resistant cell lines."

**Robert VanderWaal, PhD; Joseph Roti Roti, PhD**, "Heat-induced 'masking' of redox sensitive component(s) of the DNA-nuclear matrix anchoring complex."

**Robert VanderWaal, PhD; Beth Pierburg, BS; Joseph Roti Roti, PhD**, "Protein disulfide isomerase, a redox sensitive protein involved with anchoring DNA to the nuclear matrix appears to be altered in radiosensitive XR-1 cells."

**Mai Xu, MD, PhD; Robert Myerson, MD, PhD; Shashi Kumar; Raj Pandita; Eduardo Moros, PhD; Clayton Hunt, PhD; William Straube, MS; Joseph Roti Roti, PhD**, "The DNA-double-strand-break repair protein Mre11 is a target for radiosensitization by moderate hyperthermia."

**WORKSHOP II: TARGETING CELLULAR FUNCTIONS THAT ARE UNIQUE TO TUMOR CELLS**

**Andrei Laszlo, PhD**, chair.

**Girdhar Sharma, PhD; Arun Gupta, PhD; Tej Pandita, PhD**, "hTERT associates with human telomeres and enhances genomic stability and DNA repair."

**Shinichiro Kobayashi, MD, PhD; Regan Nantz, PhD; Nobuo Horikoshi, PhD**, "Inhibition of stress-inducible kinase pathways by tumorigenic mutant p53."

**Shinichiro Kobayashi, MD, PhD; Regan Nantz, PhD; Ryuji Higashikubo, PhD; Nobuo Horikoshi, PhD**, "A novel p53-inducible apoptogenic gene PRG3, encodes for a homologue of the apoptosis-inducing factor (AIF)."


**Tej Pandita, PhD**, "Inactivation of 14-3-3<sub>z</sub> influences telomere stability and radiation response"; "Tumor cell specific therapy/targeting?"

**WORKSHOP III: OXIDATIVE STRESS AND ENDOGENOUS DNA DAMAGE**

**Tej Pandita, PhD**, "ATM and oxidative stress."

**Joseph Roti Roti, PhD**, "Radiation-induced versus endogenous DNA damage and assays that measure parameters reflecting DNA damage on cell by cell basis."





 **Washington**  
University in St. Louis  
SCHOOL OF MEDICINE

**MIR** Mallinckrodt Institute  
of Radiology

## *...heavy smoker?*

- *Do you have a history of long-term or heavy cigarette smoking?*
- *Are you between the ages of 55 and 74?*
- *Are you concerned about the high risk of lung cancer due to smoking?*

**L**ung cancer is the leading form of cancer in the United States—and cigarette smoking is the leading cause of this disease. An estimated 169,000 new cases are expected this year.

Now you can help in the fight against lung cancer. Mallinckrodt Institute of Radiology at Washington University in St. Louis is participating in the National Lung Screening Trial. This study is part of a nationwide National Cancer Institute effort to determine whether lung cancer deaths can be reduced by early detection with standard chest X rays or spiral computed tomography (CT) before symptoms appear. Eligible participants will receive a free lung cancer screening test.

**For more information or to volunteer for this study, call  
Volunteer for Health at (314) 362-1000  
or toll free at 1-866-362-5656.**



# FOCAL SPOT

MALLINCKRODT INSTITUTE OF RADIOLOGY

## Address Service Requested

Send distribution changes or  
address corrections to  
*Focal Spot* editor  
Mallinckrodt Institute  
of Radiology at  
Washington University  
Campus Box 8131  
510 South Kingshighway Blvd.  
St. Louis, MO 63110  
(314) 362-2866 or e-mail to  
kunklerv@mir.wustl.edu

---

*Editor and Writer*  
Vicki Kunkler

---

*Contributing Writers*  
Anne Kessen Lowell  
Candace O'Connor

---

*Photographers*  
Prem Sri Barton, MD  
Fernando Gutierrez, MD  
Tom Murry  
Tim Parker  
Michelle Wynn

---

*Design*  
Purviance & Company  
Marketing Communications

---

*Printing*  
Swift Print Communications  
LLC


---


*Focal Spot* magazine is  
distributed three times annually.

---

© Mallinckrodt Institute of  
Radiology, 2003

Non-Profit Organization  
U.S. Postage  
St. Louis, Missouri  
Permit No. 2535

 **Washington**  
University in St. Louis  
SCHOOL OF MEDICINE

 **MIR** Mallinckrodt Institute  
of Radiology