

Fall 2001

Focal Spot, Fall/Winter 2001

Follow this and additional works at: http://digitalcommons.wustl.edu/focal_spot_archives

Recommended Citation

Focal Spot, Fall/Winter 2001, October 2001. Bernard Becker Medical Library Archives. Washington University School of Medicine.

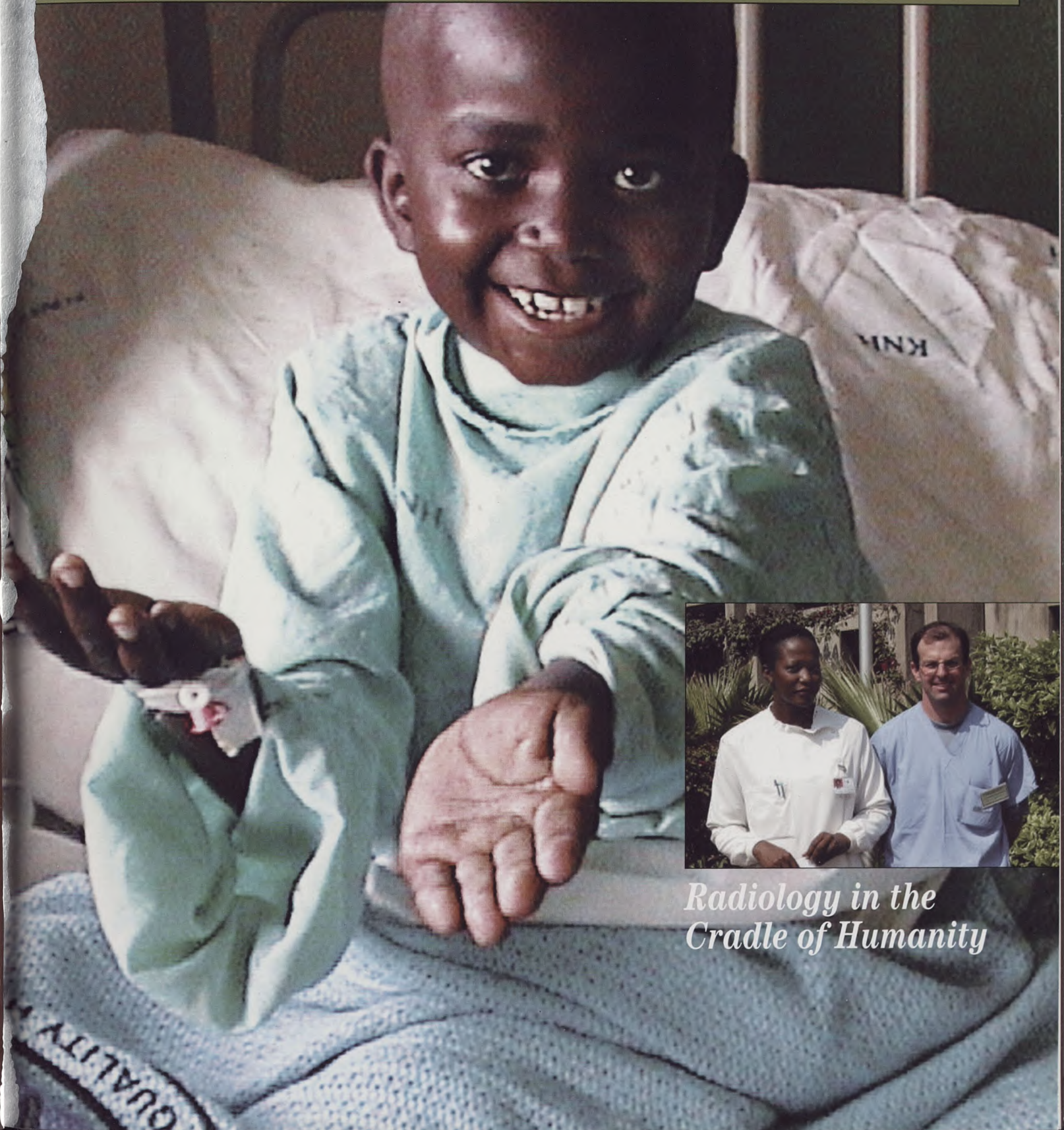This Book is brought to you for free and open access by the Focal Spot at Digital Commons@Becker. It has been accepted for inclusion in Focal Spot Archives by an authorized administrator of Digital Commons@Becker. For more information, please contact engeszer@wustl.edu.

FALL/WINTER 2001

VOLUME 32, NUMBER 3

FOCAL SPOT

MALLINCKRODT INSTITUTE OF RADIOLOGY



*Radiology in the
Cradle of Humanity*



Just the mention of Kenya conjures up romantic images of this beautiful land — the heart of African safari country, the cradle of humanity, the home of proud warrior tribes, and the survivor of colonial oppression. Few of us actually have traveled to Kenya, most of us have been there only in our dreams or through the magic of cinema.

For a group of St. Louis healthcare professionals, going to Kenya became a reality as they journeyed to Nairobi to provide medical and educational assistance to the patients and staff of Kenyatta National Hospital. For more on this story, turn to page 13.

CONTENTS


FOCAL SPOT
FALL/WINTER 2001
VOLUME 32, NUMBER 3



OUTPATIENT CARE IN ONE CONVENIENT LOCATION

5

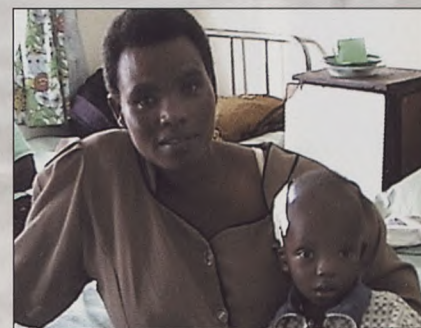Radiation oncology has moved clinical and physics staff into the new Center for Advanced Medicine, a collaborative effort between Washington University School of Medicine and Barnes-Jewish Hospital to provide ambulatory patients with convenient, multi-disciplinary care.



SIFTING THROUGH THE CONFUSION OF ALZHEIMER'S DISEASE

9


As part of one of the largest National Institutes of Health studies on Alzheimer's disease, the collaborative efforts of radiologists, neurologists, and psychiatrists at Washington University Medical Center may help to identify people at risk for developing the progressive, degenerative brain disorder.




RADIOLOGY IN THE CRADLE OF HUMANITY

13

Working side-by-side with surgeons at Kenya's largest public hospital, a multi-institutional team of St. Louis healthcare providers, including a Mallinckrodt Institute neuroradiologist, treated patients with brain and spinal cord problems and gained a new perspective on the practice of medicine.



2.....SPOT NEWS



24.....FYI


TRACING THE ROOTS OF DEPRESSION

18

Results of a Mallinckrodt Institute researcher's decade-long study of clinical depression show that anomalies in the brain's serotonin system play an important role in setting the stage for depression, discoveries that can impact the treatment not only of this disease but others such as Parkinson disease and epilepsy.

ON THE COVER A face you can never forget. Jim Kelly was one of the patients treated at Kenyatta National Hospital (KNH) in Nairobi, Kenya, by the St. Louis Neurosurgical Mission team. Inset photo shows David Jeck, MD, an MIR clinical fellow in neuroradiology, and Jessica Wabani, MD, chair of radiology at KNH.

SPOT NEWS



Joseph Simpson, MD, PhD

Simpson is Teacher of the Year

The radiation oncology residents annually select a faculty member who has made a significant contribution to radiation oncology resident education during the academic year. Joseph Simpson, MD, PhD, was named the 2001 Radiation Oncology Teacher of the Year.

After completing a radiation oncology residency at the University of Wisconsin Hospital in Madison, where he was chief resident and an American Cancer Society Clinical Fellow, Simpson joined the Mallinckrodt Institute faculty in 1978 as an assistant professor. He serves as clinical chief of the Department of Radiation Oncology's CNS service.

A fellow of the American College of Radiology, Simpson is a member of several medical organizations, including the American Association for Cancer Research, the American Society for Therapeutic Radiology and Oncology, and the American Society for Clinical Oncology. He is a member of the United States Department of Defense Dedicated Breast Cancer Tumor Board.

At Washington University Medical Center, Simpson coordinates the Radiation Oncology Summer Oncology Program, is coursemaster for the Radiation Oncology Senior Elective and Radiology Elective, and cochairs the Neuro-Oncology Focus Group. He has authored and coauthored approximately 100 scientific articles and book chapters and serves as a peer reviewer for several scientific journals, including *The International Journal of Radiation Oncology, Biology, and Physics* and *Radiology*.

Farria elected SBI fellow


In recognition of her contributions to the field of breast imaging, Dione Farria, MD, MPH, was elected a fellow of the Society of Breast Imaging (SBI) in November.

The SBI was organized in 1985 to improve and disseminate the scientific, professional, and educational aspects of breast imaging. The Society now has 1,520 members and

79 fellows. Barbara Monsees, MD, professor of radiology and chief of MIR's breast imaging, serves as the 2001-2003 SBI president.

Farria earned a medical degree from Harvard University and a Masters of Public Health degree from University of California, Los Angeles School of Public Health. While at UCLA, she completed residencies in diagnostic radiology and preventive medicine as well as a breast imaging clinical fellowship and a Robert Wood Johnson Clinical Scholars Program fellowship in health services research methodology. Prior to joining the MIR faculty in 1999, Farria was an American Roentgen Ray Scholar and an assistant professor of radiology at Thomas Jefferson University Hospital in Philadelphia, Pennsylvania.

She is a member of Delta Omega National Honor Society for public health as well as several medical organizations, including RSNA, the American Association of Women Radiologists, and the American Roentgen Ray Society. Farria currently serves on the Continuing Education Committee of American College of Practive Medicine, the American College of Radiology's Committee on Mammography Interpretive Skills Assessment, and the SBI's Economic and Practice Issues Committee. She is a productive author and coauthor of scientific and health education publications.



Kudos for Siegel's pediatric sonography text

The highly acclaimed first edition of *Pediatric Sonography*, authored by Marilyn Siegel, MD, was a comprehensive, standard-setting reference on the indications, advantages, and limitations of pediatric sonography. Now in its third edition, the text provides clinicians with a complete working knowledge of the latest scanning technologies and the expanding clinical applications of ultrasound in pediatric patients.

Siegel, professor of radiology and of pediatrics, organized the book's third edition into site-specific chapters, including scanning techniques, normal sonographic anatomy, pathologic conditions, and sonographic findings. William Middleton, MD, professor of radiology at Mallinckrodt Institute, is one of the contributing authors.

Published by Lippincott Williams & Wilkins of Philadelphia, the 768-page volume contains more than 1,700 images as well as "key concept" tables to highlight essential information. The text has been hailed as "well organized, very readable, and a comprehensive textbook" by *The Journal of Perinatology* and was recommended by *Chicago Medicine* as a book that "will be used as a reference many times."

Radioisotope alliance formed

Mallinckrodt, a business unit of Tyco Healthcare, and Mallinckrodt Institute of Radiology (MIR) are partners in a five-year product agreement involving the manufacturing and distribution of F-18 fluorodeoxyglucose (FDG), a radiopharmaceutical used in positron emission tomography (PET) studies of the brain, cancer, and heart disease.

As a leader in the production of contrast agents and radiopharmaceuticals, Mallinckrodt will provide expertise and assistance to the Institute in obtaining regulatory approvals and licensing of the MIR PET Center as a manufacturer and distributor of FDG. Initially, the MIR-produced FDG will be marketed to hospitals within a defined territory.

This agreement is a continuation of a long-standing relationship between Washington University, MIR, and Mallinckrodt. In 1923, Washington University researchers and Mallinckrodt Company chemists developed a contrast media that, used with an X ray, produced the first visualization of a human gallbladder, a cholecystogram. Recognizing that radiology would become an important medical specialty, Washington University administrators were determined that the University would establish one of the world's highest quality radiology departments. Edward Mallinckrodt, Sr. generously provided the funds for the building that would house the radiology department. On October 2, 1930, the cornerstone was laid for the Edward Mallinckrodt Institute of Radiology at Washington University.

PET, which was developed in the 1970s by an MIR research team led by Michel Ter-Pogossian, PhD, uses positron emitting isotopes to assess chemical processes in the human body, producing images of function rather than of form. In PET studies, short-lived, cyclotron-produced radioactive nuclides of carbon, nitrogen, and oxygen are used to produce radio-labeled compounds normally found in the body. These compounds, which are either inhaled by or injected into the patient, progress through the bloodstream and serve as indicators (or tracers) of normal physiological activity. While PET was initially used for basic research, the imaging device is increasingly being used for clinical, diagnostic purposes.

Best physicians survey published

The September 2001 issue of *St. Louis Magazine* included a listing of 148 of St. Louis' best physicians in 53 specialties. The list was compiled by Castle Connolly Medical Ltd, a research and information company that profiles nearly 4,000 top referral specialists throughout the United States. Castle Connolly surveys area physicians, via mail and telephone surveys and electronic ballots, for their nominations. Emphasis is placed on patient care rather than academic excellence or research. The following doctors from the departments of Radiology and Radiation Oncology were listed:

- DeWitte Cross, MD, associate professor of radiology
- William McAlister, MD, professor of radiology
- Robert Myerson, MD, PhD, professor of radiation oncology
- Carlos Perez, MD, professor of radiation oncology
- Stuart Sagel, MD, professor of radiology
- Barry Siegel, MD, professor of radiology
- Marie Taylor, MD, instructor in radiation oncology.

SPOT NEWS

Molecular Imaging Center receives additional funding

In the summer of 2000, David Piwnica-Worms, MD, PhD, professor of radiology and of molecular biology and pharmacology, received a \$1.2 million National Cancer Institute (NCI) planning grant to establish a molecular imaging center at Washington University. As principal investigator, Piwnica-Worms has now been awarded a five-year, \$10.5 million NCI grant to move the Molecular Imaging Center (MIC) from the planning stage into a centralized resource for three molecular imaging cores, four multidisciplinary research projects, four developmental research projects, an education program, and a training/career development program.

By combining Washington University Medical Center scientists' expertise in molecular oncology, immunology, molecular genetics, and signal transduction with Mallinckrodt Institute's state-of-the-art imaging technology, the MIC collaborators hope to transfer the information obtained from molecular and genomic research into the development of novel imaging techniques beneficial to the diagnosis of cancer and the assessment of treatment effectiveness. More than 50 investigators will study molecular targets in cancer cell biology, the validation of reporter constructs and reporter probes, the chemistry of image-enhancing agents, drug pharmacokinetics, and a variety of imaging strategies.

All areas of molecular imaging, including applications of positron emission tomography (PET), single photon emission computed tomography (SPECT), magnetic resonance (MR), optical, near infrared fluorescence, and bioluminescence, will be used in these studies. These MIC multidisciplinary

projects are designed to better understand cellular changes relevant to cancer:

- *in vivo* imaging of gene expression in prostate cancer
- noninvasive monitoring of T cell-mediated tumor ablation
- imaging cancer viruses with Tat transducible peptides
- imaging MDR1 P-glycoprotein transport activity *in vivo* with Tc-94m-sestamibi PET to predict response to chemotherapy in extensive stage small cell lung cancer.

The MIC's major laboratories will be housed on the ground floor of the Mallinckrodt Institute of Radiology at Washington University Imaging Center, adjacent to the Institute's East Building at 4525 Scott. Space on the Imaging Center's third floor will serve as offices for the MIC researchers and staff, and cell and molecular biologists, molecular imaging scientists, chemists, and physician-scientists can communicate daily through the Virtual Center.

Journal honors reviewers

Since 1985, the Editorial Board of *Radiology*, a leading scientific journal published by the Radiological Society of North America, annually has honored its most prolific manuscript reviewers. Of approximately 800 reviewers this year, only 109 were selected to receive the 2001 *Radiology* Editor's Recognition Award for reviewing with "Distinction." The following MIR physicians were among those honored.

- Kyongtae Bae, MD, PhD, assistant professor of radiology
- Louis Gilula, MD, professor of radiology and of surgery
- Christopher Moran, MD, associate professor of radiology
- Franz Wippold, MD, associate professor of radiology.

Research Project Principal Investigators

Paul Allen, PhD,
professor of pathology and of immunology
Jeffrey Milbrandt, MD, PhD,
professor of pathology and of immunology
David Piwnica-Worms, MD, PhD,
professor of radiology and of molecular biology and pharmacology
Lee Ratner, MD, PhD,
professor of medicine and of molecular microbiology

Development Project Principal Investigators

Samuel Achilefu, PhD,
associate professor of radiology

Carolyn Anderson, PhD,
associate professor of radiology
Jacob Locke, MD,
instructor in radiation oncology
Gary Luker, MD,
instructor in radiology
John Schotland, MD, PhD,
associate professor of electrical engineering and of radiology

Core Managers

Richard Laforest, PhD,
assistant professor of radiology
Kathryn Luker, PhD,
research instructor in radiology
Vijay Sharma, PhD,
assistant professor of radiology

Resource Directors/Senior Scientific Advisors

Joseph Ackerman, PhD,
professor of chemistry and of radiology
Marcus Raichle, MD,
professor of radiology and of neurology and neurobiology
Barry Siegel, MD,
professor of radiology and of medicine
Michael Welch, PhD,
professor of radiology and of chemistry

torial
lead-
b-
cal
ca,
s
ot
ately
only
ceive
tor's

tion."
si-
e

D,

essor
rgery

D,

OLU G

**Radiation oncology is
one of the first occupants
of a multidisciplinary facility**

The Center for Advanced Medicine (CAM) — the magnificent, 14-story, glass-fronted building at the corner of Forest Park Boulevard and Euclid Avenue — will be home to the clinical practices of more than 750 Washington University physicians and is the first of the Washington University Medical Center's five-year campus integration projects to open. The Alvin J. Siteman Cancer Center at Washington University School of Medicine (WUSM) and Barnes-Jewish Hospital will be the largest of the CAM building's multidisciplinary clinical centers, occupying the lower level and seventh floor for a total of more than 107,000 square feet.

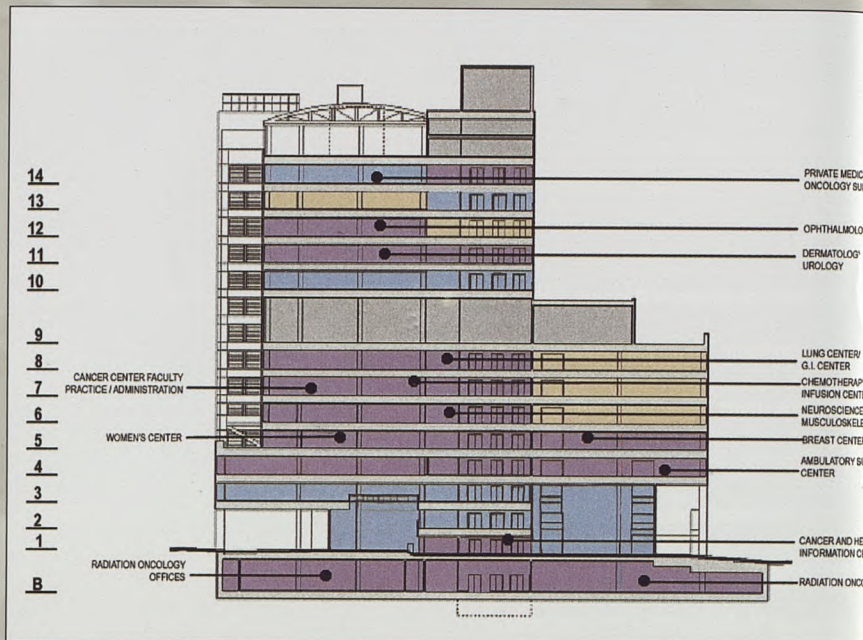
Outpatient Care
*in one convenient
location*




Outpatient Care

In August 2001, the Siteman Cancer Center became the only cancer facility in Missouri to earn national recognition as a National Cancer Institute-designated Cancer Center. As part of the NCI recognition, WUSM received a \$4 million federal grant for basic and clinical cancer research and cancer prevention programs.

Clinical facilities for the departments of Radiology and Radiation Oncology at Mallinckrodt Institute will be among those housed in the CAM building. Currently, the Division of Diagnostic Radiology's musculoskeletal service has moved into level 6 and the Clinical and Physics divisions of the Department of Radiation Oncology are in place in the lower level. Photos of radiation oncology's new home appear on the following pages. Watch for coverage of diagnostic radiology's new facilities in the spring 2002 issue of *Focal Spot* magazine.




Center for Advanced Medicine/Siteman Cancer Center



Jeff Michalski, MD, assistant professor of radiation oncology, completes a patient file in one of the new exam rooms.



The expanded and centralized radiation oncology medical records.



First-floor lobby of the Center for Advanced Medicine.

James Purdy, PhD, professor of radiation oncology and director of the Physics Division, Department of Radiation Oncology, in his new office in the lower level of the CAM building. Physics was the first group to move into the new radiation oncology facility.



Offices for hospital and medical school administrators include a roomy, open area for administrative assistants Karen Coleman, assistant to Todd Wasserman, MD, clinical chief; Bobbie Browning, assistant to Kathleen Brunsden, Barnes-Jewish Hospital director of radiation oncology; and Sonjia Stinger, assistant to Carlos Perez, MD, chairman of the Department of Radiation Oncology.

Christine Schmitz, RN, (left) and Monica Miller, BJH radiation oncology staff, check patient records in one of the patient waiting areas.

Outpatient Care



This top-of-the-line Elekta linear accelerator is one of seven linear accelerators that will be installed in the radiation oncology facility.



Genita Riley, clinical office assistant, has a smile on her face and in her voice when she talks to patients, visitors, and staff in the Radiation Oncology Center.




Under construction. Clinical staff will use computers in this area to monitor patients who are undergoing radiotherapy in one of the linear accelerator rooms.



The Physician Workroom is large enough to accommodate clinical staff. A workroom for radiation oncology nursing staff adjoins this area.



The Resident Workroom contains computer space for the 12 radiation oncology residents and four physics residents.



SIFTING THROUGH THE CONFUSION OF

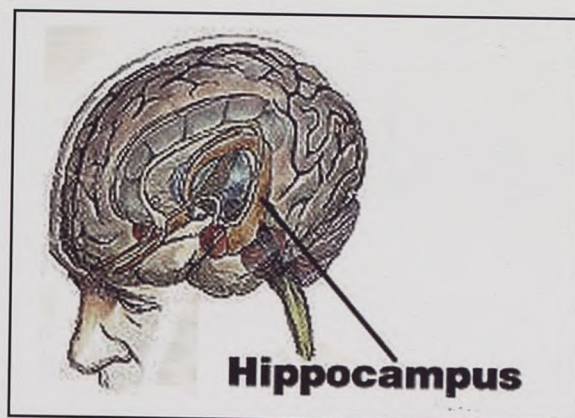

Alzheimer's Disease

by Barbra Rodriguez

An investment banker asks someone else to prepare his tax return for the first time in decades. A retired nurse forgets to show up to volunteer at a hospital. A minister who once proudly named congregation members now has trouble connecting a name with a face and cannot recall the food served at a wedding he presided over the day before.

Things like this can happen when someone is mentally fatigued, has a harried schedule, or is distracted. But when forgetfulness and confused thoughts become constant companions rather than occasional annoyances, it could signal an early stage of Alzheimer's disease. About 4 million Americans have this progressive, degenerative brain disorder for which there is no known cure.

For the past two years, a brain-imaging specialist at Mallinckrodt Institute of Radiology has been looking for telltale signs that may provide an early warning of Alzheimer's disease. If the magnetic resonance spectroscopy (MRS) work of Benjamin Lee, MD, associate professor of radiology, pans out as a diagnostic tool, it could greatly impact patient care.



About 4 million Americans have this progressive, degenerative brain disorder for which there is no known cure.

IDENTIFYING PEOPLE AT RISK

John Morris, MD, professor of neurology and director of the Healthy Aging and Senile Dementia (HASD) project at Washington University School of Medicine, says such a diagnostic test is sorely needed. "It would be great to identify people at risk for the disease before nerve cell damage occurs and then use disease-modifying interventions at that point," he says. Lee, who is studying 60 HASD volunteers using MRS, concurs. "We're hoping that imaging studies may provide the means whereby these cases can be picked up before clinical onset," he says.

This study is part of one of the largest National Institutes of Health program projects on Alzheimer's disease, which have tracked a large number of volunteers for two decades. Many of the prospective studies from this program project indicate that the disease produces pathologic brain changes long before tests of mental status raise

suspicious of its presence. In fact, the disease may begin to alter brain structures years — perhaps decades — before mental functions start faltering.

Before this decline, dense deposits called neuritic plaques are thought to form outside neurons. Inside the nerve cells, twisted strands of fiber, or neurofibrillary tangles, also develop. These tangles disrupt the transport machinery that is essential in transferring signals between neurons, effectively cutting off the supply route needed to bring energy into the cells and remove toxic wastes.

"When the brain cells begin to die, the memory and other thinking processes fail, and patients develop the symptoms of Alzheimer's disease," says Lee.

A class of drugs called cholinesterase inhibitors has already received United States Food and Drug Administration approval to treat the thought- and memory-robbing disease, and additional drugs are under development. The cholinesterase inhibitors do not cure but appear to prevent progression of

Left: The gray matter of the brain is most affected in Alzheimer's disease. This chemical shift proton spectral technique evaluates the entire brain, including the cerebral cortex.

Right: The hippocampus, a curved or scroll-like, complex portion of the temporal lobe of the brain, is often called the "memory center."

Forgetfulness

Alzheimer's disease for up to several years. The later the drugs are given in the course of the disease, the less impact they have.

MRS STUDY

Lee is analyzing changes in key brain regions of 30 healthy volunteers and of 30 volunteers believed to have mild dementia, attempting to capture the point, referred to as the flexion point, where the toxic effects of the plaques and tangles suddenly begin to cause nerve cell death. The volunteers are 65 years or older, which is when most cases of Alzheimer's disease begin to be diagnosed.

If the MRS images successfully identify brain changes before some of the volunteers develop Alzheimer's symptoms, it would add to the list of diseases for which MRS has proven diagnostic value. Lee and others currently use the noninvasive imaging tool as a litmus test to help differentiate primary brain tumors from metastatic brain tumors, for example, and for distinguishing brain tumors from radiation-induced necrosis.

Lee's study focuses on three brain regions that are damaged in Alzheimer's disease: the cerebral cortex, the hippocampus, and the cingulate gyrus. These regions were selected for study because autopsies of volunteers who died while participating in the HASD project showed that the neuritic plaques and neurofibrillary tangles of Alzheimer's disease appear in the regions first. The cerebral cortex forms the outer shell of the cerebrum, which provides most of the brain's volume. The MRS imaging will be of the frontal

The MRS assessments may do more than just catch an early snapshot of Alzheimer's disease in the brain; they may help redefine what aging is.

and parietal lobes constituting the front and apical portions, respectively, of the cortex.

The frontal lobe, which makes up half the brain volume by itself, transmits and processes information about multiple activities, including thought processes and memory. It organizes memories in sequence, controls a person's behavior, and is where problem solving occurs. The parietal lobe handles certain thought and certain sensations and is involved in reasoning and memory. The hippocampus, located below the cerebrum, plays an important role in memory processing. The cingulate gyrus, situated deep in the brain, also is essential for memory and is an additional focus of part of Lee's spectroscopic imaging.

Lee will hunt for early signs of nerve cell damage in the hippocampus and cerebral cortex by detecting the spectroscopic signal of four biochemical markers. The first, n-acetyl aspartate, is found within neurons. The second, choline, occurs in the fatty, myelin sheaths that coat axons extending from nerve cells. A marker of general cellular metabolism, phosphocreatine, also will be analyzed in both regions. In addition, Lee will evaluate the presence of a marker for the cingulate gyrus: myo-inositol. "That's a rather unusual metabolite, which is in some way connected with neuronal function," Lee says.

The level of myo-inositol is markedly changed in the brain of people who have come close to drowning or have suffered from hepatic encephalopathy, a form of brain dysfunction brought on by liver damage. "There's preliminary evidence that the level of myo-inositol is increased in Alzheimer's disease," he says.

With the assistance of Marcia Hendrix, research patient coordinator, Lee began performing MRS scans on the 60 HASD volunteers two years ago. All but about 10 have had an initial scan done so far, during sessions that last just over an hour per volunteer.

Follow-up scans on some of the same volunteers began recently. When more of these scans have been done, Lee will begin comparing the spectroscopic graphs from the first and second rounds of imaging.

If, as suspected, some of the neurons in volunteers with mild dementia have begun dying by the second round of imaging, this will show up as smaller peaks of the biochemical markers on the second spectroscopic graphs. "If we can detect the difference in this group, then we will gain some handle on what's happening in the brain during Alzheimer's disease," Lee says.

ALZHEIMER'S DISEASE (AD) FACTS AND FIGURES

- AD is the most common cause of dementia among people 65 and older.
- Scientists estimate that approximately 4 million people in the United States have AD.
- The prevalence of AD doubles every 5 years beyond age 65.
- An estimated 360,000 new cases of AD will occur each year.
- One study shows that nearly half of all people 85 and older have some form of dementia.
- African Americans and Hispanic Americans may have a higher overall risk of AD than do Caucasians.
- One study estimated that the annual cost of caring for one patient with mild AD is \$18,408; \$30,096 for a patient with moderate AD; and \$36,132 for a patient with severe AD.

Excerpted from The Impact of Alzheimer's Disease. Available at www.alzheimers.org, the web site of Alzheimer's Disease Education and Referral Center, a service of the National Institute on Aging, National Institutes of Health, U.S. Department of Health and Human Services.

He is particularly excited to review data of the cerebral cortex, which no one has previously analyzed with spectroscopy. The outer surface of the cerebrum had been difficult to image because neuronal signals become contaminated by those of fat cells located on the surface of the skull and within the skull bones. Lee and his colleagues at Mallinckrodt Institute developed a two-dimensional, multi-voxel imaging technique known as outer-volume suppression to overcome this difficulty. "It suppresses the fat signal on the skull, so we can accumulate data right out to the surface of the brain, and therefore look at the cortex," Lee says.

The MRS work also will be compared to high-resolution magnetic resonance imaging (MRI) that Lee is doing of the same volunteers. In particular, he is studying whether a part of the hippocampus decreases in size among imaging study volunteers. This part, known as CA1, extends the entire length of the hippocampus. The CA1 is a relay station for the processing of memories and develops the most neuritic plaques and neurofibrillary tangles in the hippocampus. "We have developed a method to separate out that portion of the hippocampus from the rest of the hippocampus," Lee says, referring to an analysis program developed by a Mallinckrodt Institute research group in the 1990s.

MAPPING THE HIPPOCAMPUS

Lee's MRI work will complement that of John Csernansky, MD, professor of psychiatry. Csernansky, who is studying the entire hippocampus of the same volunteers Lee is using in his MRS study, is creating three-dimensional reconstructions of MRI images to detect changes in the shape of specific hippocampal regions. These shape changes likely signal a loss of volume resulting from the neuronal loss in Alzheimer's disease.

The subjects studied by Lee, Csernansky, and other imaging specialists were carefully classified as "healthy" or "early dementia" by the HASD medical staff. The staff used an involved series of medical and mental function tests developed by investigators in the program project to make these decisions. A battery of mental function, or psychometric, tests had to be used because the early Alzheimer's symptoms are often too subtle to be detected with standard clinical methods. Their assessments, which allow accurate identification of the disease 93 percent of the time, will be compared to the imaging results of the volunteers once the blinded imaging studies are completed.

The MRS assessments may do more than just catch an early snapshot of Alzheimer's disease in the brain; they may help redefine what aging is. In the early 1990s, under the leadership of former HASD director Leonard Berg, MD, professor emeritus of neurology, Morris and others provided evidence that the disease is a distinct process from normal aging. In support of this theory, some of the HASD volunteers have been found to maintain the same, healthy mental status for as long as 15 years. ■



Radiology in the Cradle of Humanity

Considered by many anthropologists as the "cradle of humanity," the oldest human remains found in Kenya date to the Early Stone Age. Over the following centuries, this wild and beautiful land of pristine beaches, magnificent mountains, exquisite flora, and diverse fauna became home to 70 African tribal groups as well as thousands of Europeans. Kenya was under British colonial rule from the late 1800s until independence was won in 1963. In 1964, Kenya became the Republic of Kenya. Jomo Kenyatta, Kenya's founding father, was named the country's first president.

On September 1, 2001, five neurosurgeons, two anesthesiologists, four nurses, a physical therapist, and a neuroradiologist comprised a collaborative team from St. Louis that traveled to Kenyatta National Hospital (KNH) in Nairobi, Kenya, to provide free medical care to KNH patients. This was the second, of what is to be an annual, trip of the Saint Louis (STL) Neurosurgical Mission, a volunteer group started by two local neurosurgeons, Paul Young, MD, and Ken Smith, MD. The STL team worked side-by-side with medical staff in Kenya to provide educational lectures and clinical evaluations, train medical personnel, and perform surgeries on selected patients.

KENYA

BY THOMAS PETERS



FACTS AND FIGURES

- Capital city: Nairobi
- Population: 30 million+
- Area: 224,961 square miles
- Official Languages: English and Swahili
- Ethnic languages: Bantu (Luhya, Kikuyu, Kamba, Mijikenda); Cushitic (Oromo, Somali); Nilotic (Luo, Kalenjin, Masai)
- Government: Multiparty, since 1991

Michael Chicoine, MD, and Carl Laurysen, MB ChB, Washington University neurosurgeons, were returning team members, and accompanying the group for the first time was David Jeck, MD, a Mallinckrodt Institute of Radiology (MIR) clinical fellow in interventional neuroradiology. The following is a recounting of Jeck's medical and personal experiences in Kenya.

Adjusting to Kenya's healthcare system

The airplane flight from St. Louis to Kenya took 24 hours, but once the STL Neurosurgical Mission team arrived in Nairobi they were anxious to begin their two weeks of humanitarian work. Initially, the team was given a half-day tour of KNH (a public hospital) and of Aga Khan Hospital (a local private hospital). The disparity of medical facilities and patient care was immediately evident to the team. Kenyatta National Hospital serves as the only public hospital for a city of more than 2 million people, not including large numbers of patients from outside the city. Considered the best public hospital in sub-Saharan Africa, KNH also receives referrals from the entire region.

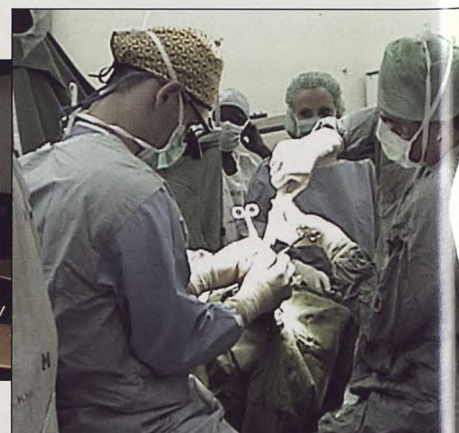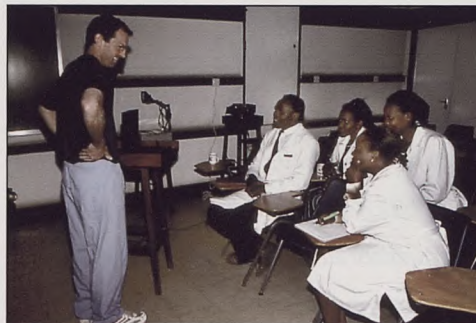
"The number of people who come to KNH far exceed the hospital's treatment capabilities," says Jeck. "Once the patients arrive at KNH they often are left unattended in hospital beds for long periods of time, waiting for surgery when they should have received emergency care."

Added to the overwhelming number of patients is the hospital's lack of funding. Patients often must purchase their own medical supplies, such as ventricular shunts or aneurysm clips, on the black market. The patient sometimes buys inappropriate equipment, and the doctors must try to "make do." Fortunately, the STL team brought a large number of donated equipment with them, allowing the team to perform surgery without most of the impediments faced by the KNH physicians and providing the hospital with supplies to last the balance of the year.

During the second half of the day the STL team met patients, reviewed cases, and determined which patients were good candidates for surgery. Some of the patients had been seen during the first STL Neurosurgical Mission trip to Kenya in 2000; others were new referrals. As Jeck indicates, "The task of selection was over-

Right: Dr. Jeck and University of Nairobi radiology residents during a teaching session.

Far Right: (right to left) Dr. Moody Qureshi, Kenyatta Hospital surgeon; Dr. Dennis Rivet, Washington University neurosurgeon; Janet Jones, RN; and Kenyan surgical registrars.





whelming when you, as a physician, see more than one hundred patients sitting in a room, holding their own medical records and CT and MRI scans – all of them hoping they will meet the criteria for surgery. Selection is based on the more difficult cases and on those patients who have the best chance of recovery.”

For the balance of the first week, the STL team performed surgery on the patients seen on the first clinic day. During the second week the team saw a new group of patients, reviewed new cases, and selected patients who met surgical criteria. “Some of the patients who were not selected for treatment this year are good candidates for treatment on the next trip,” says Jeck.

Below Left: Child with lumbar myelomeningocele during surgery.

Below Right: CT image of large hydatid cyst.

Specific cases at KNH

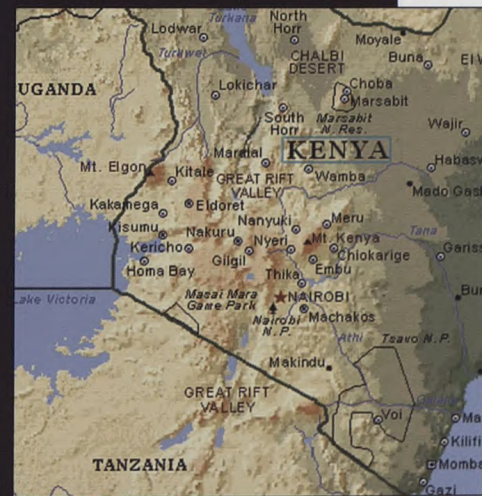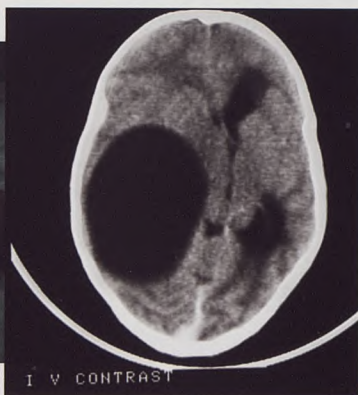
Jeck found that the clinic patients could be divided into two categories: those with diseases similar to or commonly found in the United States but with more advanced symptoms, and those with diseases that are less prevalent in the United States. In the first group were patients with advanced, benign meningiomas, extreme hydrocephalus, and spina bifida.

“Kenyan patients tend to be more stoic about their medical problems than are patients in the United States,” says Jeck. “Kenya has poorly funded medical care, and there are inadequate health insurance systems in place. Kenyan patients delay seeing a doctor until the disease has advanced because the cost of medical care that must be paid for out of the patient’s pocket is more than most patients can afford.”

The problem with this wait-and-see approach is that advanced, potentially curable diseases can lead to life-threatening debilitations and/or death. Several patients

DOWNTIME

Between clinics and lectures, the neurosurgery team traveled to Ngorongoro Crater in northern Tanzania. The trip began with a flight from Nairobi, Kenya, to Tanzania’s Kilimanjaro International Airport. From the airport to the crater required a six-hour van ride over extremely bumpy roads. Over the next two days the group was collectively driven down into the crater where a tremendous number of animals, including lions, zebras, and hippopotamuses, would venture close to the vans. And they also were able to catch a glimpse of the local Masai tribe’s way of life. This safari allowed Jeck and his teammates to experience African wildlife up close and provided a brief respite before another week of long clinic days and lectures.





seen during the trip had untreated advanced meningiomas (brain tumors) that led to incredibly large tumor masses, causing blindness and other irreversible brain damage. Alternatively, spina bifida (a congenital cleft of the spine, causing a hernia in the membrane covering the spine) is more prevalent in malnourished Third World countries such as Kenya. Infections develop if spina bifida is not treated early. Advanced untreated hydrocephalus (enlarged ventricles in the brain) in children is also relatively common.

A large percentage of KNH inhouse patients tested positive for the human immunodeficiency virus (HIV), which leads to acquired immune deficiency syndrome (AIDS). And the team saw patients with diseases rarely found in the United States such as different types of brain infections, including intracranial tuberculoma and hydatid.

According to Jeck, some of the landmark cases on this trip included a child with failed muscular coordination (ataxia) who had a posterior fossa tuberculoma; an infant with an extremely large brain hernia (occipital encephalocele); a man with enlarged bones and extremities (acromegaly) – he was over seven feet tall – who had a pituitary tumor; and a boy with a large neck mass and a large nerve cell tumor (jugular schwannoma) that caused the deterioration of part of his tongue.

Crash course in neuroradiology

“There are few neuroradiologists and no neurointerventional radiologists in Kenya,” says Jeck. So, in addition to clinical work, Jeck presented a series of lectures and grand rounds and conducted training workshops for a broad audience of Kenyan physicians: “Endovascular treatment of aneurysms” to the Kenyan Radiological Society; “An overview of neuroradiology” at the Aga Khan Neuroscience Symposium; grand rounds at Kenyatta National Hospital; “Cerebral vascular malformations” to Kenyatta Hospital radiologists. And he led multiple teaching sessions with small groups of University of Nairobi radiology residents, who were eager to learn and quickly comprehended new information and techniques.

Reflections

“The Saint Louis Neurosurgical Mission was limited in time and manpower to make any more than a dent in the multitude of cases at KNH,” says Jeck. But he says that his volunteer mission in Kenya was extremely rewarding, “I gained at least as much as I could provide. I saw an incredible variety of pathology in patients that is only seen in textbooks in the United States.”

Jeck found that the exemplary support and training he received at MIR was a tremendous asset and also put into perspective the situation dealt with in American healthcare. “In Kenya, physicians have to practice medicine with what is available despite not having enough materials or resources,” he says.

Jeck plans to travel with the 2002 Kenyan STL Neurosurgical Mission, adding that “there were a number of patients identified with aneurysms and other vascular malformations who were not treated on the 2001 trip; they would be potential candidates for endovascular treatment next year.” And he hopes that next year a group of MIR radiologists and support staff can join him on this enriching multi-institutional humanitarian effort to help the people of Kenya.

Moody Qureshi, MD (right) and H.W. Waweru, director, Kenyatta National Hospital.





RAMBEE

(Swahili: "Let's all pull together.")

On September 11, five days before the team was scheduled to return to the United States, terrorist attacks occurred in Washington DC, New York City, and Pennsylvania. For Kenyans and the American team in Kenya, September 11 was a vivid and painful reminder of the terrorist bombing of two United States embassies in East Africa on August 7, 1998, resulting in 213 (including 12 Americans) deaths in Nairobi, Kenya, and 11 deaths in nearby Dar es Salaam, Tanzania. According to CNN news reports, more than 4,500 people were injured in these two attacks.

Below: Kenyan mother with her young son who has hydrocephalus.

Below Right: CT images of a patient with tuberculoma.

Below Far Right: Dawn Schuessler, RN, and her friend in a corridor at KNH.

David Jeck remembers that when he heard the news he was at a lecture for Kenyan doctors and his immediate reaction was "to be with other Americans." Jeck says the Kenyans were extremely supportive, sympathetic, and pro-American. In fact, Jeck recalls that teenage boys came up to him on the street to say that America was in their prayers.

The ensuing lockdown of American airports led to several team members staying an additional four days in Kenya. During that time the team continued their daily routines, monitored the developments on CNN and BBC America, and felt fortunate they were not stranded in an airport. "Members of the STL Neurosurgical Mission bonded because there were not many Americans in Kenya," says Jeck. He says that keeping busy, interacting with the neurosurgery team, and being surrounded by hospitable Africans helped ease the stress until his return to the United States. **MIR**

THE 2001 SAINT LOUIS NEUROSURGICAL MISSION TO KENYA
BJC HealthCare

Dawn Besancenez, scrub tech (OR)
Dawn Schuessler, RN (ICU)

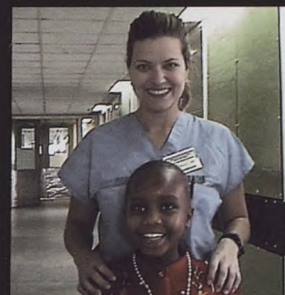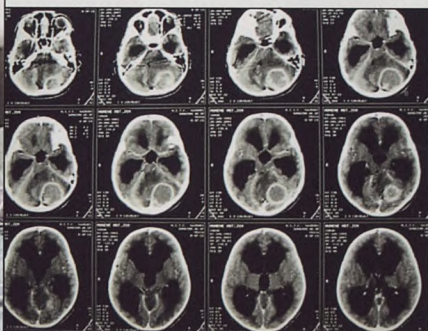
Microsurgery and Brain
Research Institute
Paul H. Young, MD


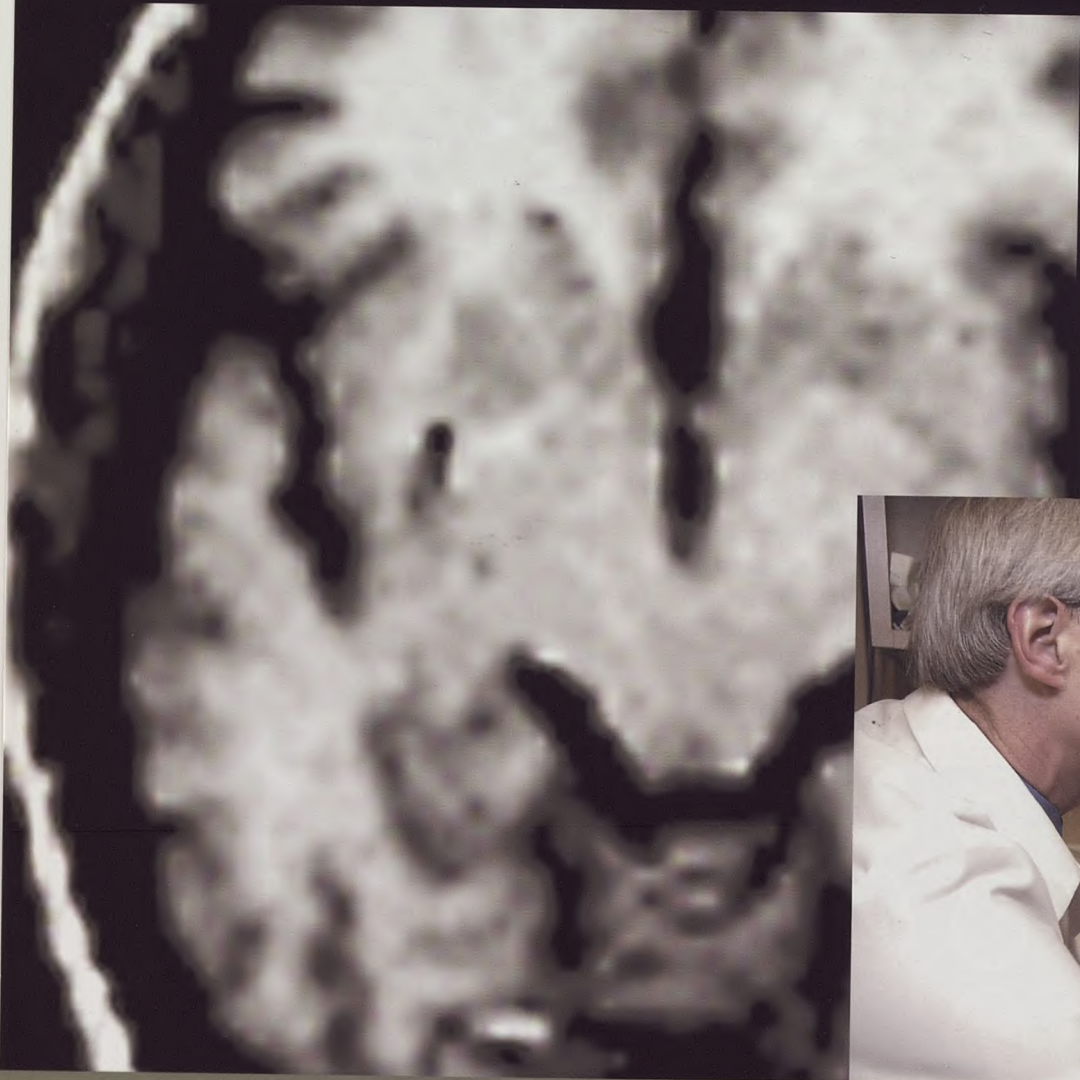
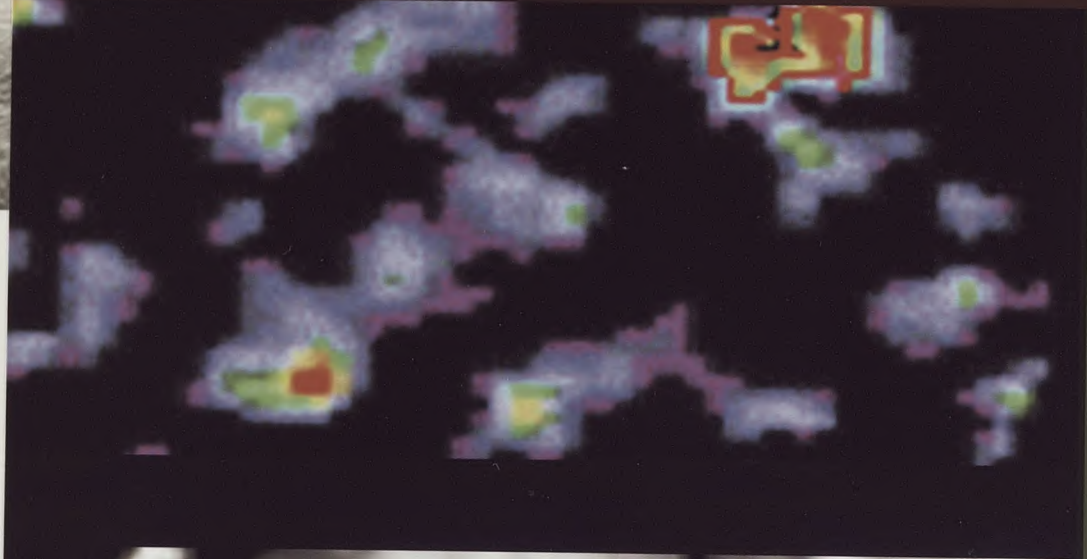
Saint Louis University Hospital
Pam Bruns, CRNA
Janet Jones, RN (OR)
Connie Pickering, RN
Ken Smith, MD

Town and Country Physical Therapy
Russell Eaves, PT

Washington University School of
Medicine in St. Louis
Jeffrey Carter, MD (Anesthesiology)
Michael Chicoine, MD
(Neurological Surgery)
David Jeck, MD (Radiology)
Carl Laurysen, MB, ChB
(Neurological Surgery)
Dennis Rivet, MD
(Neurological Surgery)

ADDITIONAL SPONSORS
B & H Orthotics Laboratory
Eagle's Wing Ministries
HealthSouth
Kenyan Neurosurgical Society





T R A C I N G . T H E R O O T S O F depression

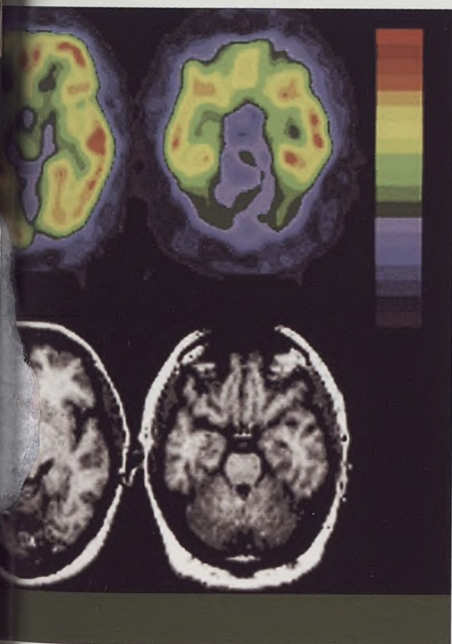
In the frustrating world of clinical depression, there are a few generally agreed-upon facts. We recognize the symptoms of the disease: the sleeplessness, the inability to concentrate, the lack of joy in life. We understand its devastating impact on people's lives, from the nearly 19 million people who suffer from it to the more than 30,000 suicides in the United States each year, many of them depression-related. Thanks to the success of some anti-depressant drugs in ameliorating the effects of depression, particularly the class of drugs known as selective serotonin reuptake inhibitors (SSRIs), we also feel confident that depression is biologically based.

But all the rest — the roots of the disease, the best treatments — is still shrouded in mystery. “We have theories, but no firm idea at all, about what precipitates depression. There is an incredibly small amount of data on what is biologically different in the brains of people who are depressed,” says Mark Mintun, MD, professor of radiology and of psychiatry.

Beginning at the University of Pittsburgh seven years ago, and then at Mallinckrodt Institute of Radiology (MIR) for the past four and a half years, Mintun has carried out a series of research projects aimed at unraveling this mystery with the help of positron-emission tomography (PET). The question he has asked is a basic one: Is there a biological change in the brain that may point to the cause of depression? If so, is it just one piece in a whole cascade of changes that medicine needs to understand? In depression, most of the brain still works well, so any imbalance is likely quite subtle.

Mintun's findings offer new evidence that anomalies in the brain's serotonin system play an important role in setting the stage for depression. And his most recent research takes that understanding one step further: demonstrating that the brain's hippocampus shows a striking serotonin abnormality in people with depression. While more work remains to be done, these discoveries may have important implications for treating not only depression but also a host of other diseases, including Parkinson disease and epilepsy.

Two PET images (top) showing the distribution of [F18]altanserin in the brain of a study volunteer who has depression. The binding of [F18]altanserin in the brain shows the location and number of serotonin-2A receptors. The MRI images on the bottom are coregistered to the PET images to allow accurate correlation to the brain's anatomy.



by Candace O'Connor

TRACING THE ROOTS OF depression

Research background

In the 1980s, Mintun completed a residency in nuclear medicine at MIR and then, as a young faculty member, worked with Marcus Raichle, MD, professor of radiology and of neurology and neurobiology, and Steven Petersen, PhD, professor of neurology (neuropsychology) and of radiology, on mapping complex language pictures in the brain using PET. But a decade ago, he decided on a new focus for his research.

"I felt that the biggest impact of new advances in brain imaging would be in mental health," he says. "This was an area that had been held back for a long time because we couldn't get good information about what was going on. So I directed my efforts at developing new techniques toward that goal."

He chose to focus on the brain's serotonin system, which clearly plays some role in depression. After all, the SSRIs, which alter the amount of serotonin in the brain, have had an enormous effect on the treatment of the disease. But scientists are still divided as to whether serotonin is itself the cause or part of a cascade effect. In treating depression, some drugs that don't affect serotonin directly, as well as treatments such as electroconvulsive therapy (ECT), have also proven helpful.

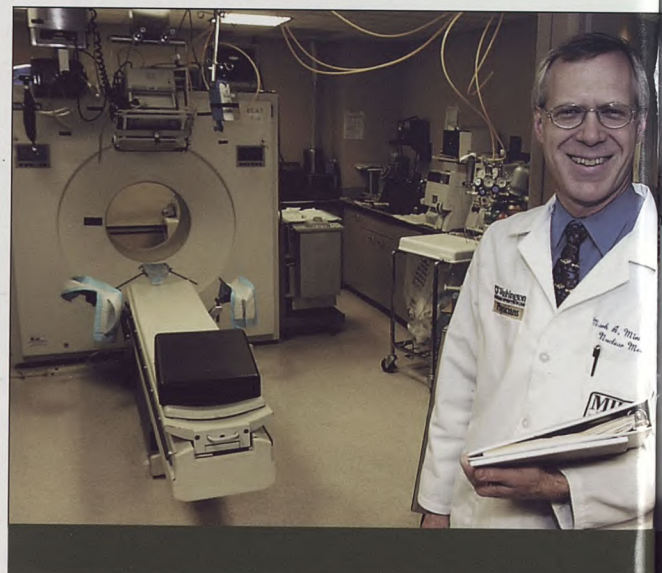
At Pittsburgh, Mintun began by studying the result of giving normal and depressed people a drug that rapidly stimulates the serotonin system. Next he measured the effect of this drug, using the subjects' glucose metabolism as a benchmark. While the brains of the healthy patients had changed, the brains of depressed patients showed a very muted response; their serotonin systems seemed to be malfunctioning. This finding supported the study hypothesis that depression is associated with reduced serotonin activity.

So Mintun decided to target the small number of serotonin receptors scattered throughout the brain. The receptors are critical elements in cellular communication, "listening" to neurotransmitter signals sent by the brain's synapses. Among these serotonin receptors, the most common is the 5-HT_{2A} receptor. Do depressed people have fewer-than-normal 5-HT_{2A} receptors in their brain? he wondered. Perhaps that would account for their impaired serotonin function.

"I also wanted to ask a second question: If the number of 5-HT_{2A} receptors is altered, does treatment with anti-depressants fix the problem? People with depression do get better; maybe their receptor change goes back to being normal," he says.

New findings

In his next study, Mintun wanted to develop a way of imaging these 5-HT_{2A} receptors to see whether they were, in fact, abnormal. In work that began at Pittsburgh and continued at Mallinckrodt Institute, he planned to inject subjects with a compound, tagged with a small amount of radioactivity, that would circulate throughout the body, move into the brain, and bind to the 5-HT_{2A} receptors. Using PET imaging,



Dr. Mark Mintun was recently appointed to the NIH's Integrative, Functional and Cognitive Neuroscience Study Section of the Center for Scientific Review.

"I FELT THAT THE BIGGEST IMPACT OF NEW ADVANCES IN BRAIN IMAGING WOULD BE IN MENTAL HEALTH. THIS WAS AN AREA THAT HAD BEEN HELD BACK FOR A LONG TIME BECAUSE WE COULDN'T GET GOOD INFORMATION ABOUT WHAT WAS GOING ON. SO I DIRECTED MY EFFORTS AT DEVELOPING NEW TECHNIQUES TOWARD THAT GOAL."

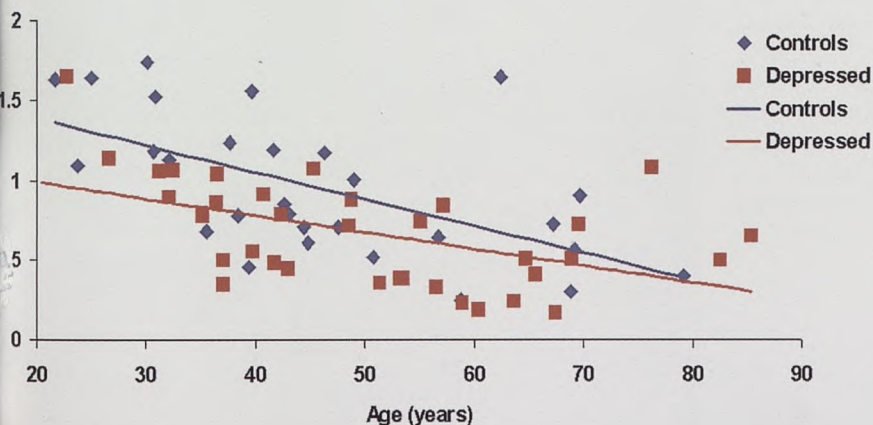
he would then visualize these receptors and assess changes in them that might provide insight into the nature of the dysfunction in these serotonin pathways.

Synthesizing the compound they needed to do this research –¹⁸F altanserin – was difficult. This ligand had to be able to bind tightly enough to the 5-HT_{2A} receptors so they could be seen during the imaging process, yet not bind to other receptors and confuse the picture. Mintun credits Stephen Moerlein, PhD, associate professor of radiology, and Mallinckrodt Institute's entire radiochemistry group, under the leadership of Michael Welch, PhD, professor of radiology and of chemistry, with providing the extraordinary assistance that made this study possible. Feiyu Xue, MD,

diagnostic radiology resident, and Andrei Vlassenko, MD, PhD, research associate, contributed their expertise in the processing of the data.

Three years ago, this ligand development work was complete and the study was ready to begin. Mintun and Yvette Sheline, MD, assistant professor of psychiatry and of radiology, along with Abraham Snyder, MD, radiology research scientist, recruited a group of healthy control subjects and 39 patients diagnosed with depression (men and women, ages 20 to 70) and used ¹⁸F altanserin and PET to evaluate their 5-HT_{2A} receptors. The results were barely significant for most of the brain; there was only a modest decrease in the number of 5-HT_{2A} receptors. But when the researchers looked at the region of the brain called the hippocampus (an area known to control aspects of memory, mood, and behavior), the results were much more striking.

"The hippocampus had a much larger decrease, approximately thirty percent," says Mintun. "That leads to a possible hypothesis: Perhaps this vital area of the brain is not able to function properly in depression because there are not the proper number of 5-HT_{2A} receptors. So it



Serotonin receptor binding in controls and subjects with depression at baseline over the lifespan: hippocampus region.

TRACING THE ROOTS OF
depression

may be that a person with depression does not recover as much from stress or bounce back as fast. We just don't have those answers yet."

This experiment led to another startling finding, which will soon be published in the *American Journal of Psychiatry*. While collecting the data on these subjects, the researchers noticed that the older people had lost an overwhelming number of these 5-HT_{2A} receptors. In fact, more than half were gone by the time people reached age 50.

"Is that the unfortunate consequence of stress? This loss seems to occur at different rates in different people," Mintun says. "Or is this a planned loss? After all, we are not all depressed at age fifty. On the other hand, what if these receptors help us recover from stress and losing them makes it harder to bounce back? We don't yet have the answers."

Future work

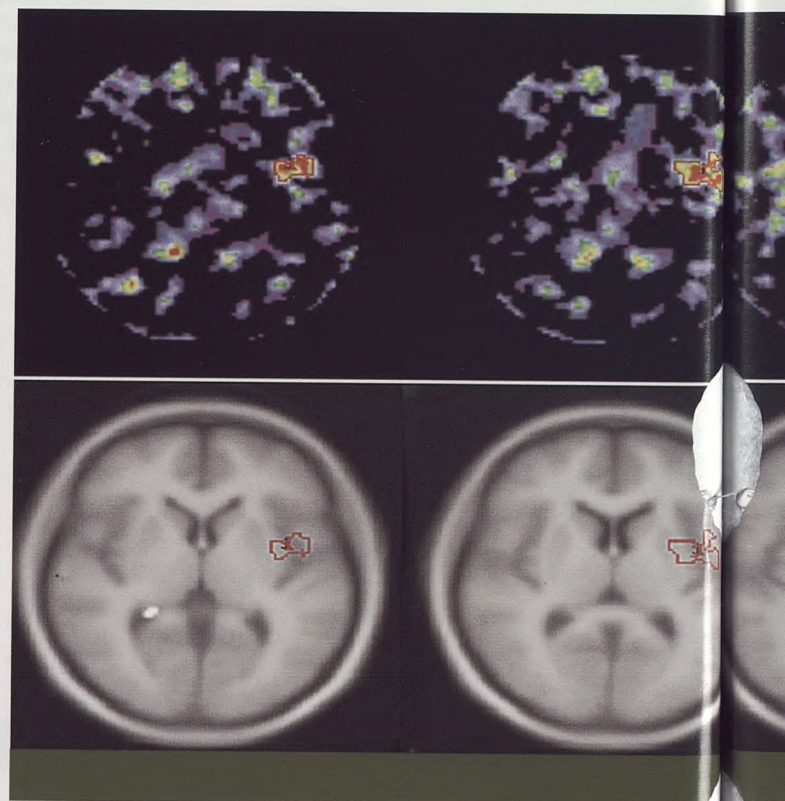
For Mintun and his colleagues, much more research is still to be done. They feel confident that, within the hippocampus, there is a depression-related abnormality in the serotonin system. But the hippocampus is tightly interconnected with other areas of the brain. Perhaps a serotonin abnormality here has a broader effect — for example, on the regulation of dopamine in the brain. Scientists already know that

dopamine is involved in helping people feel well, and there is evidence that people with Parkinson disease, which is related to dopamine problems, have an unusually high rate of depression.

In the future, Sheline will also pursue another, closely associated question: How do the hippocampus and related structures respond to things that generate an emotional response, such as a picture of a face that is unhappy or afraid? She will give subjects this kind of picture to look at, then map their brain response using functional magnetic resonance imaging.

And Mintun will also move ahead in several exciting new directions. One may involve looking at the biological anomalies that exist when people are depressed. Are these anomalies, such as a reduced number of serotonin

"THESE ARE VERY COMPLICATED THINGS, AND IN MANY OF THESE AREAS WE DON'T HAVE A HANDLE ON WHAT THE NORMAL FUNCTION IS, MUCH LESS HOW THEY ARE ALTERED IN DEPRESSION."



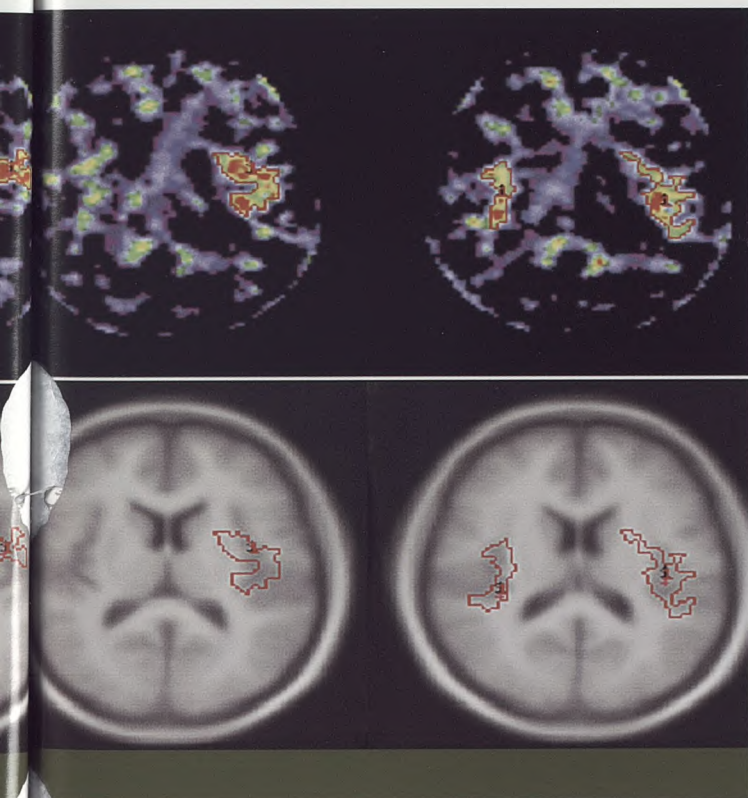
"THERE IS NO MAGIC BULLET HERE. WE ARE NOT GOING TO FIND THE ONE ABNORMALITY WITH DEPRESSION, FIX THAT ONE THING, AND EVERYBODY IS GOING TO BE HAPPY. THIS IS A VERY COMPLICATED PROBLEM, BUT WE ARE NOW BEGINNING TO UNDERSTAND IT."

receptors, present from birth, meaning that some people are genetically susceptible to depression? Or are they caused by something that regulates the serotonin system? He may also look at the effects of these anomalies on the symptoms generated by the disease. "These are very complicated things, and in many of these areas we don't have a handle on what the normal function is, much less how they are altered in depression," says Mintun.

Finally, he says, he would like to know more about where this understanding of causes and effects leads in terms of designing new treatments for depression. Scientists know that neurogenesis occurs within the hippocampus; it can grow new neurons as part of normal learning and adaptation. Existing brain cells can also grow whole new parts and connections.

But what if this ability is somehow blocked, and this inability shows up as decreased 5-HT_{2A} receptors? Sheline, Mintun, and Welch have recently been awarded a grant by Fidelity to develop ways to image these neurons as they are born in the human brain. Eventually, they hope to be able to determine whether people deficient in 5-HT_{2A} receptors are also failing to grow new neurons at a normal rate — whether they have hippocampuses that are unable to "reinvent" themselves, adapting to the environment. If that is true, perhaps it is also possible to develop a drug to act upon the chemicals that signal cells within the neurons to grow.

So far, Mintun says, one thing has become clear. "There is no magic bullet here," he says. "We are not going to find the one abnormality with depression, fix that one thing, and everybody is going to be happy. This is a very complicated problem, but we are now beginning to understand it." ■■■



Images of the statistical T-test and MRI showing regions of significant decrease in [18F]altanserin binding between the subjects with depression and the control groups. In patients with depression, there is decreased [18F]altanserin binding in the parahippocampal regions bilaterally ($p < 0.01$) and in the insular cortices bilaterally ($P < 0.01$).

In this section, the names of employees who are full-time faculty or staff or who have an appointment in the Department of Radiology or Department of Radiation Oncology are highlighted in boldface type.

PROMOTIONS

Colin Derdeyn, MD, assistant professor of radiology, was promoted to associate professor of radiology, Division of Diagnostic Radiology.

Debra Gusnard, MD, instructor in radiology, was promoted to assistant professor of radiology, Division of Radiological Sciences.

Richard Laforest, PhD, instructor in radiology, was promoted to assistant professor of radiology, Division of Radiological Sciences.

Vadim Markel, PhD, assistant professor of radiology, Division of Radiological Sciences.

Yuan-Chuan Tai, PhD, assistant professor of radiology, Division of Radiological Sciences.

Zheng Wang, PhD, research instructor in radiology, Division of Radiological Sciences.

Imran Zoheri, MD, instructor in radiation oncology, Department of Radiation Oncology.

GRANTS

Samuel Achilefu, PhD, associate professor of radiology, as principal investigator, received a National Science Foundation Award in the amount of \$620,000 to study "Novel RGD peptide dendrimeric optical contrast agents for imaging tumor angiogenesis." Coinvestigators for the three-year award are **John Schotland, MD, PhD**, associate professor of electrical engineering and of radiology, and **Carolyn Anderson, PhD**, associate professor of radiology and of molecular biology and pharmacology.


Carolyn Anderson, PhD, associate professor of radiology and of molecular biology and pharmacology, as principal investigator, received a one-year grant from the United States Department of Defense to study "Radiolabeled matrix metalloproteinase inhibitors for breast cancer therapy." As principal investigator, Anderson also received a \$236,970 grant from the United States Department of Energy to fund "Graduate research in nuclear medicine at Washington University."

NEW FACULTY

Lisa Connor, PhD, research instructor in radiology, Division of Radiological Sciences.

Jose Garcia-Ramirez, MS, instructor in radiation oncology, Department of Radiation Oncology.

Kathryn Luker, PhD, research instructor in radiology, Division of Radiological Sciences.



Melson Lecture

On September 10, Alec Megibow, MD, professor of radiology and vice chairman for education, Department of Radiology, New York University Medical Center, presented the Ninth Annual G. Leland Melson Visiting Professorship and Lecture, "CT/MR of pancreatic neoplasms." Shown with Megibow (second from left) are doctors Jay Heiken, chief of abdominal radiology; William Middleton, professor of radiology; and Sharlene Teehey, head of ultrasonography.

Steven Don, MD, assistant professor of radiology, as principal investigator, received a \$100,000 National Institutes of Health (NIH) grant for "Neonatal chest phantom for computed radiography testing." The one-year grant was awarded in conjunction with NIH's Small Business Technology Transfer Program with Gamma RMI, a Wisconsin-based corporation that is an innovator of quality control devices for radiology. Coinvestigators are **Bruce Whiting, PhD**, and **Charles Hildebolt, DDS, PhD**.

William Powers, MD, professor of neurology and of radiology, as principal investigator, received a \$900,000 grant from the National Institutes of Health/National Institute of Neurological Disorders and Stroke (NINDS) for "Cerebral mitochondrial metabolism in neurodegeneration." Coinvestigators for the four-year project are **Joel Perlmutter, MD**, professor of neurology and of radiology, and **Tom Videen, PhD**, research assistant professor of neurology and of radiology. As principal investigator, Powers also received a \$14 million-plus NINDS grant for a Carotid Occlusion Surgery Study. **Robert Grubb, MD**,

professor of radiology and of neurology is co-principal investigator. Videen and **Colin Derdeyn, MD**, associate professor of radiology, are coinvestigators.

Joseph Roti Roti, PhD, professor of radiation oncology and director of Division of Radiation and Cancer Biology, and **Eduardo Moros, PhD**, associate professor of radiation oncology, were awarded a one-year research/testing agreement in the amount of \$85,974 with Integrated laboratory Systems, Inc. for the project "RTL development and control for high SAR exposures."

Jie Zheng, PhD, research assistant professor in radiology, received the Whitaker Foundation's Biomedical Engineering Research Program grant for \$210,300. The two-year grant will support his research on "In vivo assessment of myocardial oxygen extraction ratio with magnetic resonance BOLD effects." Coinvestigators are **Dmitriy Yablonskiy, PhD**, assistant professor of radiology; **Robert Gropler, MD**, associate professor of radiology; and **Nikolaos Tsekos, PhD**, assistant professor of radiology. Consultant is Debiao Li, PhD, Northwestern University.

Jacob Locke, MD, instructor in radiation oncology, has been appointed to the Washington University Human Subjects Committee.

Eduardo Moros, PhD, associate professor of radiation oncology, was appointed a member of the North American Hyperthermia Society (NAHS) 2001-2002 Finance Committee, the Membership Committee, and the Web Site Committee, and as the American Association of Physicists in medicine liaison for the NAHS. He was appointed a member of the Program Committee for the 2002 meetings of the Radiation Research Society and the North American Hyperthermia Society. Moros was appointed chair of the scientific session "Visualization and imaging in biotransport" at the International Mechanical Engineering Conference and Exhibition, New York City, New York, November 16.

Mark Oswald, MD, PhD, clinical fellow in neuroradiology, was appointed to a three-year term on the American College of Radiology Committee on Residency Training in Diagnostic Radiology.

Joseph Roti Roti, PhD, professor of radiation oncology and director of Division of Radiation and Cancer Biology, was elected to a three-year term as president of the 9th International Congress of Hyperthermic Oncology and to a three-year term as councilor of the Bioelectromagnetics Society. He was appointed to the Awards and Honors Committee and the Program Committee of the Radiation Research Society.

HONORS/ AWARDS

Fengming Kong, MD, PhD, assistant in radiation oncology, received the American Association for Women Radiologists' Research and Education Foundation Member-in-Training Award in Radiation Oncology. The award was presented for Kong's paper on "3D analysis of lung & heart dose to decipher central lung/heart distances and radiation techniques for intact breast irradiation: adding a medial breast port decreases volume of lung and heart to high dose," which was presented at the Radiological Society of North America Annual Meeting, November 25-30, in Chicago, Illinois.

Eduardo Moros, PhD, associate professor of radiation oncology, was invited to serve as an ad hoc grant reviewer for the Radiation Study Section of the Oncological Sciences Integrated Review Group at the National Institutes of Health's Center for Scientific Review, San Francisco, California, November 2-4.

Barry Siegel, MD, professor of radiology and of medicine, and director of the Division of Nuclear Medicine, received a Certificate of Outstanding Contribution from the American College of Radiology Imaging Network (ACRIN) in recognition of his "contribution towards ACRIN achieving its goal of conducting high quality clinical trials of imaging technology and thereby improving the quality and length of lives of cancer patients."

APPOINTMENTS/ELECTIONS

Samuel Achilefu, PhD, associate professor of radiology, was appointed to the editorial board of the *Journal of Biomedical Optics*, which is published by the International Society for Optical Engineering.

Louis Gilula, MD, professor of radiology and of surgery, was appointed organizer of the International Wrist Investigators' Workshop held on October 3 in Baltimore, Maryland

HONORS/ AWARDS

Continued from page 25

Sharlene Teefey, MD, associate professor of radiology, received a \$300,000 award from the Radiological Society of North America's Research and Education Foundation International Radiology Program for "Teach the Teachers." The three-year award is designed to provide opportunities to use or develop educational programs for individuals in emerging countries around the world.

LECTURES/ PRESENTATIONS

Samuel Achilefu, PhD, associate professor of radiology, presented "The few, the proud, the challenged" at The Optical Imaging of Brain Function Summer Program Graduation, University of Pennsylvania, Philadelphia, August 17. He spoke on "Targeting exogenous optical agents for tumor diagnosis and therapy" at the Optical Society of America Annual Meeting, Long Beach, California, October 15.

Carolyn Anderson, PhD, associate professor of radiology and of molecular biology and pharmacology, presented "Copper complexes as radiopharmaceuticals: from inorganic chemistry to *in vivo* studies" at the University of Missouri, St. Louis, October 15, and at the University of New Hampshire, Durham, October 23.

Jeffrey Bradley, MD, instructor in radiation oncology, as invited speaker, presented "It's time to focus on lung cancer" at a symposium sponsored by The Wellness Community of Greater St. Louis, Missouri, November 10.

Clifford Chao, MD, assistant professor of radiation oncology, spoke on "IMRT for head and neck cancer" at the Southeast Missouri Regional Cancer Center, Cape Girardeau, Missouri, October 27.

Thomas Conturo, MD, PhD, associate professor of radiology and adjunct professor of physics and of biomedical engineering, presented "Diffusion tensor fiber tracking: methods, experimental results, and error simulations" at the Workshop on Diffusion NMR and MRI: From the Single Molecule to the Entire Human Brain, Tel Aviv University, Tel Aviv, Israel, August 26-30. He spoke on "Tracing white matter fiber connections with MRI and clinically practical whole-brain bolus perfusion imaging" at the Instituto Neurologica Carla Besta, Milan, Italy, August 31.

Louis Gilula, MD, professor of radiology and of surgery, spoke on "Unusual problems with vertebraloplasty and how to handle them" at the International Skeletal Society meeting, Montreal, Quebec, September 5. He presented "Analysis of complex carpal trauma," "Ligamentous instability of the wrist," "Wrist arthrography," and "Musculoskeletal CT" at the Nicer Course on Musculoskeletal Imaging, Buenos Aires, Argentina, October 26-28. As visiting professor, Gilula presented "Ligamentous instabilities of the wrist" and "Wrist trauma cases - unknowns" at Oregon Health Sciences University, Portland, November 16.

Anil Khosla, MD, instructor in radiology, spoke on "Spine intervention procedures" at the Ninth Annual Radiology Update for the Clinician, Memorial Hospital, Carbondale, Illinois, November 3.

Eric Klein, MS, associate professor of radiology, presented "Intensity modulated radiation therapy," "Multileaf collimation: utility, dosimetry, and cost analysis," and "Dynamic wedging: utility, dosimetry, and cost analysis" at the Brazilian Radiotherapy Oncology Society Annual Meeting, Blumeneau, Brazil, August 20-23.

Jason Lewis, PhD, research instructor in radiology, presented "MRI and microPET imaging of tumor progression in hamster abdomens following laparoscopic surgery and radiotherapy" at the High Resolution Imaging in Small Animals: Instrumentation, Application and Animal Handling meeting, Rockville, Maryland, September 9-11.

Jacob Locke, MD, instructor in radiation oncology, spoke on "Enhancement of hyperthermic radiosensitization and inhibition of NF- κ B with indomethacin."

Elizabeth McFarland, MD, associate professor of radiology, presented "Tracheal resection and primary anastomosis: 3D imaging of trachea" at ENT Grand Round Washington University in St. Louis, Missouri, October 24. She spoke on "Colonography: current issues" at the Turnbull Lecture Series, Department of Colorectal Surgery, Washington University in St. Louis, Missouri, November 2.

Robert McKinstry, MD, PhD, assistant professor of radiology, spoke on "Cerebral blood flow: MR diffusion/perfusion" at The 2nd Annual International Symposium and Hands-on Course on Cerebral Revascularization, Saint Louis University, St. Louis, Missouri, November 30.

Jeff Michalski, MD, assistant professor of radiation oncology, presented "RTOG trials in the management of prostate cancer with 3D CRT" at the University of Chicago, Illinois, August 2. He presented "3D radiation therapy and hormone therapy in the management of prostate cancer - The RTOG trials" at Ball Memorial Hospital, Muncie, Indiana, September 18. He spoke on "3-D CRT" at The Prostate Cancer Lecture Series Program, sponsored by IntraMed Education Group, New Orleans, Louisiana, September 19. Michalski spoke on "Grade 2 toxicity on RTOG 9406: robbing Peter to pay Paul" at the

6th International Conference on Dose, Time & Fractionation in Radiation Oncology, Madison, Wisconsin, September 23. He presented "3D-CRT/IMRT prostate" at Kyoto University, Kyoto, Japan, December 5, and participated in The 39th Forum of Radiation Oncology, Chugoku-Shikoku, Japan, December 6. Michalski presented "3D conformal therapy for prostate cancer" at Hiroshima University, Hiroshima, Japan, December 7. He spoke on "An update on conformal RT trial conducted by the RTOG" and cochaired the symposium on "How clinical outcomes can be improved by 3D-CRT/IMRT in terms of local control rate and incidence of sequelae," sponsored by the Association of 3-Dimensional Conformal Radiotherapy, Nagoya University School of Medicine Nagoya, Japan, December 8-11.

Barbara Monsees, MD, professor of radiology and chief of breast imaging, presented "Imaging in breast cancer" at New Imaging Techniques for Cancer Management, sponsored by St. Luke's Hospital, St. Louis, Missouri, October 16.

Pratik Mukherjee, MD, PhD, clinical fellow in neuroradiology, spoke on "Diffusion tensor MR imaging of normal human brain maturation" at the University of California, San Francisco Medical Center, San Francisco, September 18, and at Stanford University Hospital, Stanford, California, September 20.

Carlos Perez, MD, professor of radiation oncology and chair of the Department of Radiation Oncology, presented "Tumor physiology and distant spread" and "Functional imaging in treatment planning in radiation therapy" at Modern Radiotherapy, Tumor Physiology, and Functional Imaging, sponsored by the Instituto di Radiologia, Universita Cattolica del Sacro Cuore, Rome, Italy, November 12-16.

William Powers, MD, professor of neurology and of radiology, spoke on "Imaging of haemodynamics and metabolism in cerebrovascular diseases" at the 11th Nordic Meeting on Cerebrovascular Diseases, Kuopio, Finland, August 12.

William Reinus, MD, associate professor of radiology, presented "Rheumatology radiology rounds" at Grand Rounds, Department of Rheumatology, Washington University in St. Louis, Missouri, October 18.

Henry Royal, MD, professor of radiology, presented "Treatment of hyperthyroidism with I-131 – consensus and controversies" at 2001 – A Functional Imaging Odyssey, sponsored by The Missouri Valley Chapter of The Society of Nuclear Medicine, Columbia, Missouri, October 6.

Stuart Sagel, MD, professor of radiology, chief of chest radiology, and codirector of body computed tomography, spoke on "CT of the thorax: anatomic variants and pitfalls," "Interactive problematic cases,"



Perez Lecture

The First Carlos A. Perez Endowed Lectureship in Oncology, in honor of Carlos Perez, MD, professor of radiation oncology and chairman of the Department of Radiation Oncology, was held on December 7. Norman Coleman, MD, director of the radiation oncology sciences program, associate director of the radiation research program, and deputy director of the Division of Clinical Sciences at the National Cancer Institute, National Institutes of Health, presented "Radiation oncology and the NCI's extraordinary opportunities: molecular imaging, signatures, and therapeutics." William Peck, MD, executive vice chancellor for medical affairs and dean of the School of Medicine, is shown with the commemorative plaque presented to Coleman (second from left). Also shown are Perez (far right) and Todd Wasserman, MD, chief, Clinical Division, Department of Radiation Oncology.

LECTURES/PRESENTATIONS

Continued from page 27

"Role of CT in bronchogenic carcinoma," "CT of the pericardium," and "CT of non-vascular mediastinal masses" at the 11th Summer Practicum of the Society of Computed Body Tomography and Magnetic Resonance, Keystone, Colorado, August 20-24.

Vijay Sharma, PhD, assistant professor of radiology, as invited speaker, presented "Targeting chloroquine-resistant *Plasmodium Falciparum* with novel antimalarial metal(III) complexes: structure-activity relationships" at the Medicinal Chemistry Symposium of the 222nd National Meeting of the American Chemical Society, Chicago, Illinois, August 26-30.

Barry Siegel, MD, professor of radiology and of medicine, and director of the Division of Nuclear Medicine, as the Eighth Annual Ralph G. Robinson, MD Memorial Lecturer, spoke on "Oncologic FDG-PET – artifacts, variants, and benign lesions simulating cancer" at 2001 – A Functional Imaging Odyssey, sponsored by The Missouri Valley Chapter of The Society of Nuclear Medicine, Columbia, Missouri, October 6. He presented "FDG-PET in oncology" at the Annual Meeting and Scientific Session of the Oklahoma Society of Clinical Oncology, Tulsa, Oklahoma, October 12 and 13. He spoke on "Clinical applications of PET in oncology" at New Imaging Techniques for

Cancer Management, sponsored by St. Luke's Hospital, St. Louis, Missouri, October 16. Siegel presented "Evaluating tumor response to treatment with FDG PET" and "PET: techniques, artifacts, and interpretations" at the Fifteenth Annual Northeast Regional Scientific Meeting of the Society of Nuclear Medicine, Greater New York and New England Chapters, Stamford, Connecticut, October 26-28. As guest lecturer, he presented "PET Imaging" at The Second Annual John H. Walker, MD Lecture in Radiology, Virginia Mason Medical Center, Seattle, Washington, November 2. He spoke on "Assessing tumor biology with PET" and "Clinical applications of PET scanning in oncology" at Modern Radiotherapy, Tumor Physiology, and Functional Imaging, sponsored by the Instituto di Radiologia, Università Cattolica del Sacro Cuore, Rome, Italy, November 12-16.

at the Children's Oncology Group meeting, San Antonio, Texas, October 18. She presented "MRI imaging of bone marrow" and "Imaging of common abdominal tumors in children" at Modern Radiotherapy, Tumor Physiology, and Functional Imaging, sponsored by the Instituto di Radiologia, Università Cattolica del Sacro Cuore, Rome, Italy, November 12-16.

Sheng-Kwei Song, PhD, instructor in radiology, spoke on "Detection of white matter tracts in mouse brain and spinal cord" at the High Resolution Imaging in Small Animals: Instrumentation, Application and Animal Handling meeting, Rockville, Maryland, September 9-11.

Todd Wasserman, MD, professor of radiation oncology, presented "The role of radiation in the treatment of lymphomas" at the Annual Meeting and Scientific Session of the Oklahoma Society of Clinical Oncology, Tulsa, Oklahoma, October 12 and 13.

Dmitriy Yablonskiy, PhD, assistant professor of radiology, spoke on "Human brain temperature regulation and oxidative metabolism during functional visual stimulation" at the International Thermal Physiology Symposium, Wollongong, Australia, September 4. As invited lecturer, he presented "The role of tissue-specific magnetic susceptibility effects in MR signal formation: theoretical concepts and experimental applications" to the Department of Radiology, Evanston Northwestern Healthcare, Chicago, Illinois, November 30.

Scott Lecture

At the Thirtieth Annual Wendell G. Scott Memorial Lecture on October 8, MIR's David Piwnica-Worms, MD, PhD, professor of radiology and of molecular biology and pharmacology, spoke on "Radiology in the post-genome era: new frontiers in molecular imaging."



Marilyn Siegel, MD, professor of radiology and of pediatrics, presented "Pediatric mediastinal masses," "Pediatric renal masses: multimodality imaging strategies," "Adrenal and retroperitoneal masses in children," and "Pediatric liver masses: CT/MRI" at the 14th Jornada Gaucha de Radiologia meeting, Gramado, Brazil, August 17-19. As an invited guest speaker, she presented "CT and MRI of pediatric renal masses" at the Pediatric Update 2001, Toronto, Ontario, September 8. Siegel spoke on "Fast MR imaging of small cell tumors"

SYMPOSIA

In this section of FYI, only those faculty and staff who have Department of Radiology or Department of Radiation Oncology appointments are listed.

AMERICAN SOCIETY FOR THERAPEUTIC RADIOLOGY AND ONCOLOGY

*43rd Annual Meeting
San Francisco, California
November 4 - 8, 2001*

Jeffrey Bradley, MD, recipient of a 2001 European Society for Therapeutic Radiology and Oncology Travel Grant.

WORKSHOP ON PHYSICS TEACHING TO RADIATION ONCOLOGY RESIDENTS

Eric Klein, MS, "The variation of physics teaching material and intensity among programs."

REFRESHER COURSE

Sasa Mutic, MS, "CT simulation process and techniques."

SCIENTIFIC SESSIONS

Angel Blanco, MD; James Dempsey, PhD; Clifford Chao, MD, "A scoring function for target coverage in intensity modulated radiation therapy (IMRT) planning based on the probability of microscopic tumor extension and lymph node metastasis."

Clifford Chao, MD; Walter Bosch, DSc; Sasa Mutic, MS; Jason Lewis, PhD; Farrokh Dehdashti, MD; Mark Mintun, MD; James Dempsey, PhD; Carlos Perez, MD; James Purdy, PhD; Michael Welch, PhD, "A prospective study on tumor hypoxia kinetics to implement hypoxic imaging-guided IMRT."

James Dempsey, PhD; Joseph Deasy, PhD; Walter Bosch, DSc; Daniel Low, PhD, "Treatment plan review tools incorporating spatial dose-volume information."

Perry Grigsby, MD, "Long-term follow-up of RTOG 88-05: twice daily external irradiation with brachytherapy for carcinoma of the cervix."

Jeff Michalski, MD; Fengming Kong, MD; David Mansur, MD; Carlos Perez, MD, "Quality of life following 3D conformal radiation therapy or permanent interstitial brachytherapy for localized prostate cancer."

Binh Tran, MD; Clifford Chao, MD; James Dempsey, PhD, "Patterns of local regional failure in head and neck cancer treated with IMRT."

POSTER PRESENTATIONS

Joseph Deasy, PhD; Joseph Roti Roti, PhD; Daniel Low, PhD, "Dose-rate effects in intensity modulated radiation therapy."

Perry Grigsby, MD; Farrokh Dehdashti, MD; Tom Miller, MD, PhD; Barry Siegel, MD, "FDG-PET evaluation of tumor control after radiotherapy for carcinoma of the uterine cervix."

Clifford Chao, MD; Chih-Jen Huang, MD; Joseph Simpson, PhD, MD; Carlos Perez, MD, "Intensity-modulated radiation therapy yields satisfactory tumor control and spares salivary function in patients with oropharyngeal carcinoma: a nonrandomized comparison with conventional techniques."

Shervin Karimpour, MD, "Active site cysteine residues in thioredoxin reductase regulate cell cycle progression and NF- κ B activity."

Clifford Chao, MD, "Lymphangiogram-assisted lymph node target delineation for patients with gynecological malignancies receiving IMRT treatment."

Xiao Lin, MD, PhD, "2-deoxy-d-glucose is a cytotoxic and radiosensitizing agent in tumor cells."

Daniel Low, PhD; Jeffrey Bradley, MD; Joseph Deasy, PhD; Richard Laforest, PhD; Jason Sohn, PhD; Farrokh Dehdashti, MD; Sasa Mutic, MS; Walter Bosch, DSc, "Lung trajectory mapping."

Robert Malyapa, MD, PhD; Clifford Chao, MD; Jeffrey Williamson, PhD; Perry Grigsby, MD, "Pelvic organ motion and displacement during radiation therapy in patients with gynecological malignancies - a prospective study using serial CT imaging during external-beam radiotherapy."

David Mansur, MD; Fengming Kong, MD; Eric Klein, MS; Jeffrey Bradley, MD; Marie Taylor, MD; Carlos Perez, MD; Harvey Glazer, MD; Imran Zoberi, MD; Robert Myerson, PhD, MD, "Three dimensional localization of internal mammary and axillary lymphatic regions and the significance on optimized breast cancer treatment planning."

Tom Miller, MD, PhD; Perry Grigsby, MD, "Measurement of tumor volume by PET to evaluate prognosis in patients with cervical cancer."

Anurag Singh, MD; Mary Ann Lockett, MBA; Jeffrey Bradley, MD, "Analysis of clinical and dosimetric predictors of radiation-induced esophageal toxicity in patients with non-small cell lung cancer treated with three dimensional conformal radiation therapy."

Jason Sohn, PhD; Daniel Low, PhD; Joseph Deasy, PhD, "Motion-induced dose distribution artifacts in lung cancer IMRT."

Jeffrey Williamson, PhD; Fritz Lerma, PhD; Clifford Chao, MD; Kyongtae Bae, MD, PhD; Kim Nguyen, dosimetry QA specialist; Perry Grigsby, MD; John Matthews, DSc, "3D image-based dose planning of intracavitary brachytherapy and teletherapy of gynecological tumors: registration of cumulative dose via deformable anatomic templates."

SYMPOSIA

Continued from page 29

SOCIETY FOR NEUROSCIENCE

*31st Annual Meeting
San Diego, California
November 10 - 15, 2001*

ORAL PRESENTATIONS

Kevin Black, MD; Joel Perlmutter, MD, "Parkinson's disease patients with levodopa-related mood fluctuations have increased posterior cingulate response to acute levodopa."

Harold Burton, PhD; Abraham Snyder, MD, PhD; Thomas Conturo, MD, PhD; Erbil Akbudak, PhD; John Ollinger, DSc; Marcus Raichle, MD, "A fMRI study of verb generation to heard nouns in early and late blind."

Marcus Raichle, MD; Harold Burton, PhD; Abraham Snyder, MD, PhD; Erbil Akbudak, PhD; Thomas Conturo, MD, PhD, "Negative BOLD responses in early and late blind."

POSTER PRESENTATIONS

Erbil Akbudak, PhD; Joshua Shimony, MD, PhD; Abraham Snyder, MD, PhD; Marcus Raichle, MD; Harold Burton, PhD; Thomas Conturo, MD, PhD, "Diffusion MRI tracking of amygdalo-calcarine pathways: replication and detailed error study."

Melanie Leitner, PhD; Abraham Snyder, MD, PhD; Aaron Tansy; Steven Petersen, PhD; Maurizio Corbetta, MD, "Brain reorganization in frontal aphasia: a longitudinal study."

Stephen Moerlein, PhD; Michael Welch, PhD; Joel Perlmutter, MD, "PET imaging of the serotonin S3 antagonist [C-11] ondansetron in living baboon brain."

Joel Perlmutter, MD; Stephen Moerlein, PhD; Michael Welch, PhD, "Imaging studies of [C-11] (N-methyl) benperidol (NMB) as a D2 receptor-binding PET tracer."

Abraham Snyder, MD, PhD; Kevin Black, MD; Mokhtar Gado, MD; Joel Perlmutter, MD, "MRI and PET template images for neuroimaging in baboon and macaque."

RADIOLOGICAL SOCIETY OF NORTH AMERICA

*87th Scientific Assembly and Annual Meeting
Chicago, Illinois
November 25 - 30, 2001*

Kyongtae Bae, MD, PhD, presiding officer, Gastrointestinal (CT liver, contrast techniques).

Dennis Balfe, MD, presiding officer, Gastrointestinal (intervention, upper gastrointestinal tract); presiding officer, Gastrointestinal (CT: pancreatitis).

Fengming Kong, MD, PhD, recipient of RSNA Resident Research Trainee Prize - 2001.

Louis Gilula, MD, presiding officer, Musculoskeletal (infection).

Jay Heiken, MD, member Program Committee: gastrointestinal radiology; presiding officer, Gastrointestinal (pancreatic cancer: CT and MR); Gastrointestinal keynote speaker.

Gilbert Jost, MD, moderator, IHE Symposium: Integrating the Healthcare Enterprise: clinical goals and technical challenges.

Jeff Michalski, MD, member, Program Committee: radiation oncology and radiobiology; presiding officer, Radiation Oncology (prostate: brachytherapy).

Barbara Monsees, MD, guest lecturer, "Update on breast imaging."

Srinivasa Prasad, MD, recipient of RSNA Research Trainee Prize - 2001.

Marilyn Siegel, MD, moderator, Friday Imaging Symposium, "Screening for cancer"; member, Refresher Course Committee.

Sharlene Teefey, MD, presiding officer, Ultrasound (musculoskeletal).

REFRESHER COURSES

Dennis Balfe, MD, "Imaging the invisible: mesenteries and peritoneum of the upper abdomen."

Sanjeev Bhalla, MD, "Airways: virtual and dynamic imaging."

Louis Gilula, MD, coordinator, "Vertebroplasty: indications, technique, problems, and complications."

Tolmach Lecture

The Tenth Annual Leonard J. Tolmach Memorial Lecture was presented on November 9. Martin Brown, PhD, director of the program in cancer biology at Stanford University, spoke on "Identification of mechanisms of action of anticancer agents using yeast genomics."



Fernando Gutierrez, MD, "Vascular anomalies: mediastinum and lung."

Ray Heiken, MD, "Imaging of focal liver lesions with CT and MR."

David Hovsepian, MD, "Hysterosalpingography and selective salpingography ('how-to' workshop)."

Daniel Low, PhD, "Physics of three-dimensional conformal radiation therapy and intensity-modulated radiation therapy."

Elizabeth McFarland, MD, "CT of the small bowel and colon: principles, techniques, and applications."

Jeff Michalski, MD, "Dose escalation with three-dimensional conformal radiation therapy."

Barbara Monsees, MD, "Problem-solving breast imaging: supplementary mammographic views."

David Rubin, MD, "Ankle MR imaging: techniques, normal anatomy, and common pathology—an interactive session."

Barry Siegel, MD, moderator, "Optimizing PET interpretation"; "Pediatric MR imaging—an interactive session: abdomen."

Marilyn Siegel, MD, "Focal hepatic masses."

Sharlene Teefey, MD, "Practical tips in US: musculoskeletal—hand and wrist"; "Musculoskeletal US ('hands-on workshop')."

SCIENTIFIC EXHIBITS

Sanjeev Bhalla, MD; Christine Menias, MD, "Radiologic-pathologic correlation of abdominal masses that may present as life-threatening hemorrhage."

Sanjeev Bhalla, MD; Prensri Barton, MD; Dennis Balfe, MD, "Fat-containing lesions in the breast, chest, and abdomen: friends or foe?"

Carol Hwang, MD; Prensri Barton, MD; Barbara Monsees, MD; Dione Faria, MD, MPH; Thomas Pilgram, PhD, "Breast cancer T1 tumor size: correlation of mammography, ultrasound, and pathologic measurements."

Christine Menias, MD, "Volvulus above and below the diaphragm."

Pratik Mukherjee, MD; Joseph Philip, MD; Benjamin Lee, MD; Jeffrey Neil, MD, PhD; Robert McKinstry, MD, PhD, "Diffusion-tensor MR imaging of normal human brain maturation: a pictorial essay."

Mehdi Poustchi-Amin, MD; Jeffrey Brown, MD; Kezaei Kianoush, MD; Thelma Lopes, MD; Edward Lee, MD, "Practical MRI of the body: principles, applications, and protocols—a review for the general radiologist."

SCIENTIFIC SESSIONS

Douglas Adkisson, BS; Erbil Akbudal, PhD; Joshua Shimony, MD, PhD; Thomas Conturo, MD, PhD, "Finite-element analysis of the magnetic field effects of compartmentalized paramagnetic agents."


Erbil Akbudak, PhD; Melanie Kotys, MS; Glenn Foster, RT; Joanne Markham, MS; Thomas Conturo, MD, PhD, "Whole-brain bolus perfusion imaging in humans with a head-only 3 Tesla MRI system."

Kyongtae Bae, MD, PhD, "MR imaging to assess the progression of polycystic kidney disease: work in progress."

Kyongtae Bae, MD, PhD; Paul Commean, BEE; Jeong Rim Lee, PhD; Jongdae Suh, MD; Barry Brunsden, "Development of image analysis method for volumetric measurement of renal cysts and parenchyma using MRI."

Probstein Lecture

Eric Klein, MD, associate professor of surgery, Ohio State University, and head of urologic oncology, The Cleveland Clinic, presented the Norman K. Probstein Oncology Lecture on October 23. The lecture topic was "Localized prostate cancer surgery or radiation therapy: the debate continues."



SYMPOSIA

Continued from page 31

Kyongtae Bae, MD, PhD; Jay Heiken, MD; Huy Tran, MD; Sheila Agan, research patient coordinator, "Uniform vascular contrast-enhancement and reduced contrast volume achieved by multiphasic injection method: clinical validation."

Kyongtae Bae, MD, PhD; Jongdae Suh, MD; Bruce Whiting, PhD, "3D visualization of cochlea using high-resolution CT for cochlear implant surgery planning."

Kyongtae Bae, MD, PhD, "Coronary scoring using multi-slice CT: evaluation of interscan variability and optimal scan tube current."

Jeffrey Bradley, MD; Wade Thorstad, MD; Sasa Mutic, MS; Jennifer Britt, dosimetry QA specialist; **Walter Bosch, DSc,** "Image-guided radiotherapy using PET/CT fusion improves delineation of target volumes and alters the three-dimensional radiotherapy plan in non-small cell lung carcinomas."

Louis Gilula, MD, "Different types of polymethylmethacrylate (PMMA) leakage as short- and mid-term predictors for patient symptoms in 363 vertebroplasties."

Fengming Kong, MD; Eric Klein, MS; Jeffrey Bradley, MD; David Mansur, MD; Marie Taylor, MD; Carlos Perez, MD, "Analysis of lung and heart dose to decipher central lung/maximal heart distances and radiation techniques for intact breast irradiation."

Jason Leawoods, MS; Dmitriy Yablonskiy, PhD; David Gierada, MD; Mark Conradi, PhD, "Comparison of ³He MR images of gas diffusion and ventilation in the lungs of candidates for lung volume reduction surgery (LVRS)."

Margaret Lee, MD; Barbara Monsees, MD; Kimberly Wiele, MD; Preme Sri Barton, MD, "Ultrasound breast biopsy: number of cores obtained in routine practice."

Jacob Locke, MD, Risk factors for acute urinary retention requiring temporary intermittent catheterization after prostate brachytherapy: a prospective study."

Thelma Lopes, MD; William Reinus, MD, "Acetabular labral tear: MRI arthrography findings and arthroscopic correlation."

Ronan McDermott, MBBCh; Elizabeth McFarland, MD; Christine Menias, MD, "Prospective comparison of air and CO₂ insufflation techniques at CT colonography: evaluation of image quality and patient reactions."

Barbara Monsees, MD; Dione Farria, MD, MPH, "Training and attitudes of residents regarding breast imaging."

Christopher Moran, MD; Colin Derdeyn, MD; DeWitte Cross, MD, "Magnetic-tipped guidewire-catheter manipulation in patients with intracranial aneurysms."

Robert Myerson, PhD, MD; Mary Ann Lockett, MBA, "The addition of continuous infusion 5-FU to pre-operative radiotherapy increases sphincter in locally-advanced low-rectal cancer."

Vikram Patel, MD; William Middleton, MD; Sharlene Teefey, MD, "Giant cell tumors of the tendon sheath: analysis of sonographic features."

Srinivasa Prasad, MD, "CT tumor measurement and assessment of tumor response: unidimensional, bidimensional, and volumetric techniques – Is there an optimal technique?"; "Comparison between standard dose and 50%-reduced dose abdominal CT: effect on image quality."

Joshua Shimony, MD, PhD; Erbil Akbudak, PhD; Thomas Conturo, MD, PhD, "Diffusion and perfusion imaging of the cervical spinal cord."

Bruce Whiting, PhD; Kyongtae Bae, MD, PhD, "Three-dimensional localization of cochlear implants by co-registration of CT and radiograph images."

Dmitriy Yablonskiy, PhD; Joseph Ackerman, PhD, "Liver-fat content quantification by MR spectroscopy in patients with apoB truncation-containing lipoproteins."

Dmitriy Yablonskiy, PhD; Michelle Lee, BS; Jason Leawoods, MS; David Gierada, MD; Mark Conradi, PhD, "³He diffusional MRI provides quantitative information on lung tissue structure in patients with emphysema."

Jie Zheng, PhD; Jason Leawoods, MS; Mark Nolte, special procedures technologist; Dmitriy Yablonskiy, PhD; Mark Conradi, PhD, "MR volumetric pulmonary artery perfusion, angiography, and ³He lung ventilation imaging: initial experience."

THE SYMPOSIUM

Gilbert Jost, MD, "Clinical goals and technical challenges."

FOR THE RECORD

In the summer 2001 issue of *Focal Spot* magazine, Maria Schmidt, MD, assistant professor of radiology, was incorrectly listed as the recipient of a \$25,000 grant from the Alvin J. Siteman Cancer Center. Dione Farria, MD, assistant professor of radiology, should have been listed as principal investigator for the Siteman-funded study on "Evaluating the effect of informed consent and procedure scheduling on breast biopsy patient outcomes." Schmidt, along with Mark Walker, PhD, Department of Medicine, is a co-investigator. Consultant is Jill Bokern, RN, Barnes-Jewish Hospital.

To Our Physician Colleagues


When you're trying to schedule a patient for a CT or an MRI exam, it pays to know your options. Barnes-Jewish West County Hospital (BJWCH) now has on line a second CT and a second MRI—both state-of-the-art technology. This assures that your patients receive the studies they need as soon as possible.

Head, spine, musculoskeletal, and abdomen CT and MRI as well as general X rays are offered through the Barnes-Jewish West County Hospital Imaging Center. You can be assured your patients will receive professional care from our expert staff of board-certified radiologists, each a member of the renowned Mallinckrodt Institute of Radiology at Washington University. Additionally, the images can be electronically transmitted to Barnes-Jewish Hospital for review on the Picture Archiving System (PACS).


The facility is easily accessible with plenty of free parking.

Call (314) 996-8080 to schedule an appointment.

Barnes-Jewish
West County Hospital

 BJC HealthCare™

 Washington
University in St. Louis
SCHOOL OF MEDICINE

 MIR Mallinckrodt Institute
of Radiology

FOCAL SPOT

MALLINCKRODT INSTITUTE OF RADIOLOGY

Address Service Requested

Send distribution changes or
address corrections to
Focal Spot editor
Mallinckrodt Institute
of Radiology at
Washington University
Campus Box 8131
510 South Kingshighway Blvd.
St. Louis, MO 63110
(314) 362-2866

Editor and Writer
Vicki Kunkler

Contributing Writers
Candace O'Connor
Thomas Peters
Barbra Rodriguez

Photographers
Marian Brickner
David Jeck, MD
Tom Murry
Tim Parker
Michelle Wynn

Design
Purviance & Company
Marketing Communications

Printing
Scholin Brothers
Printing Company


Focal Spot magazine is
distributed three times annually.

© Mallinckrodt Institute of
Radiology, 2001

Non-Profit Organization
U.S. Postage
St. Louis, Missouri
Permit No. 2535

ARCHIVES
SERIALS DEPT., MEDICAL LIBRARY
WASH. U. SCHOOL OF MEDICINE
CAMPUS BOX 8132

 Washington
University in St. Louis
SCHOOL OF MEDICINE

 Mallinckrodt Institute
of Radiology