

Fall 1998

Focal Spot, Fall/Winter 1998

Follow this and additional works at: http://digitalcommons.wustl.edu/focal_spot_archives

Recommended Citation

Focal Spot, Fall/Winter 1998, October 1998. Bernard Becker Medical Library Archives. Washington University School of Medicine.

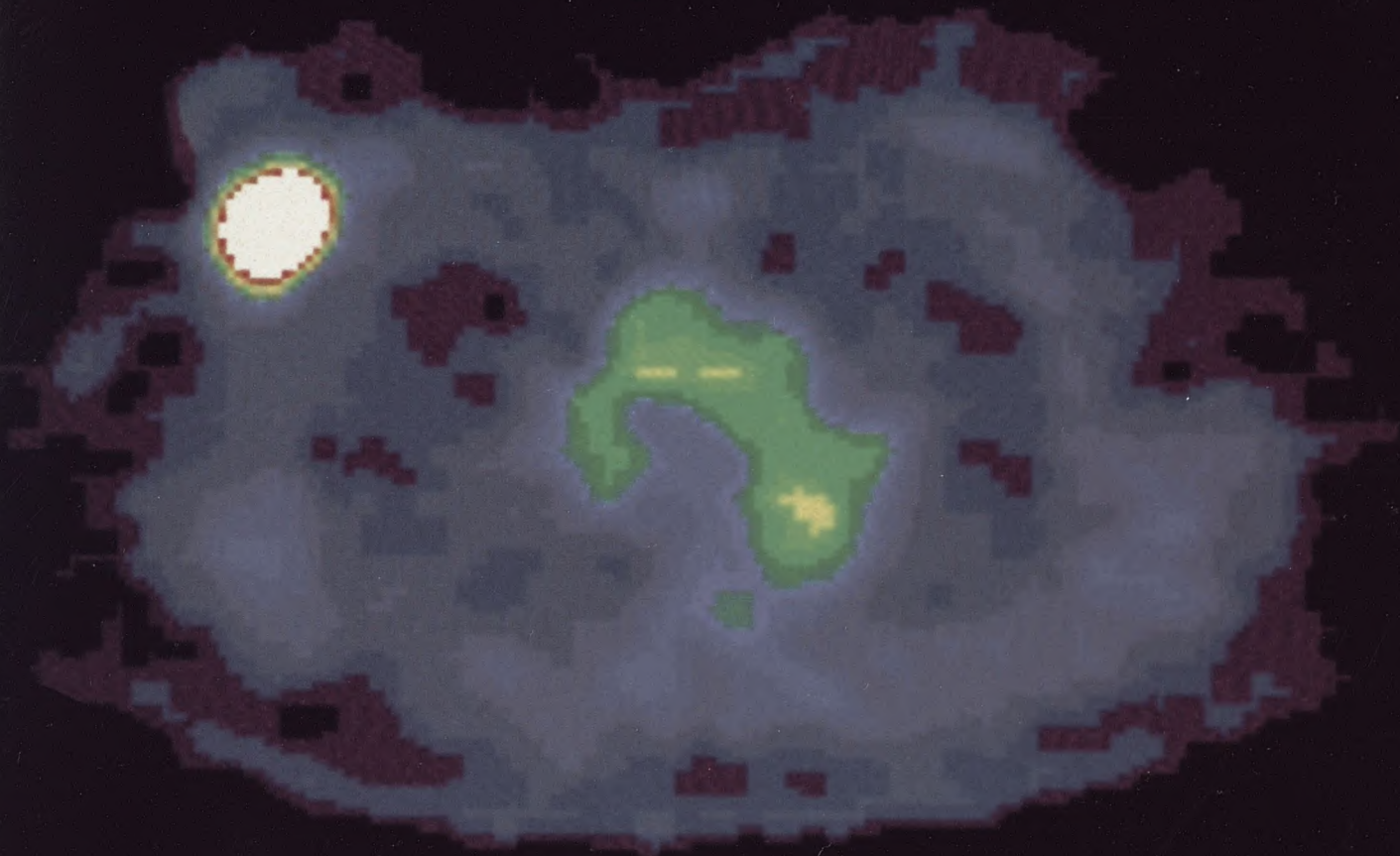
This Book is brought to you for free and open access by the Focal Spot at Digital Commons@Becker. It has been accepted for inclusion in Focal Spot Archives by an authorized administrator of Digital Commons@Becker. For more information, please contact engeszer@wustl.edu.

FALL/WINTER, 1998

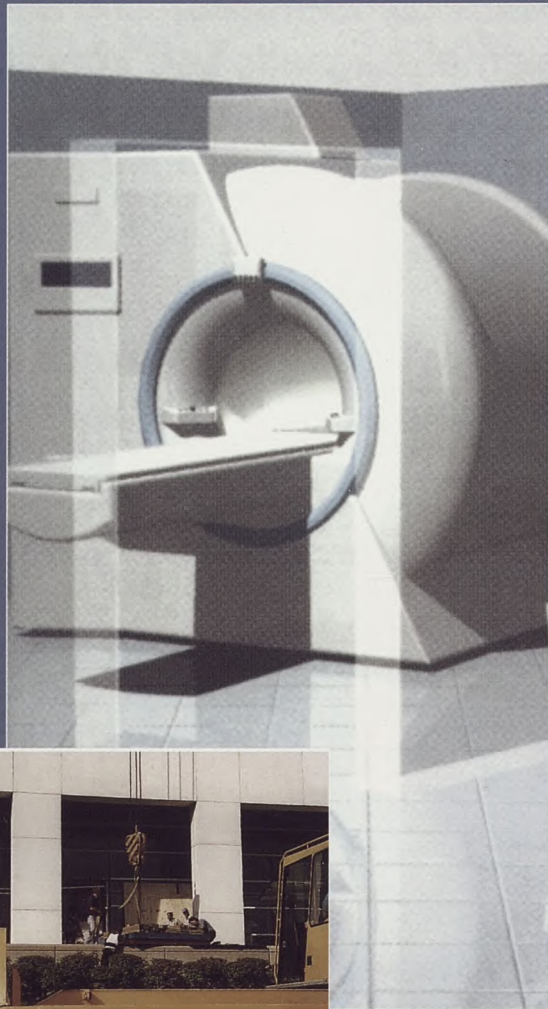VOLUME 29, NUMBER 3

FOCAL SPOT

MALLINCKRODT INSTITUTE OF RADIOLOGY



**A BREAKTHROUGH IN
TAMOXIFEN THERAPY**



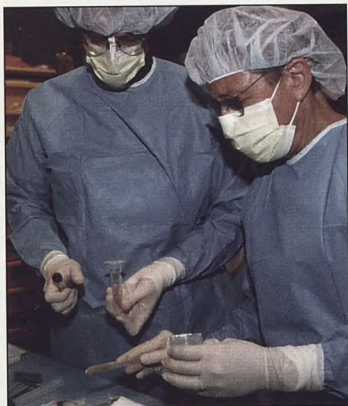"The Symphony," the newest MRI platform for cardiovascular imaging, was recently installed in the Institute's research facilities in the East Building on Scott Avenue. The scanner is manufactured by Siemens Medical Systems, Inc. and will play an important role in the Institute's Cardiovascular Magnetic Resonance Imaging Program.

FALL/WINTER, 1998

FOCAL SPOT


VOLUME 29, NUMBER 3

MALLINCKRODT INSTITUTE OF RADIOLOGY




4 VERTEBROPLASTY: MIR MAKES PROGRESS IN TREATING BONE PAIN

Musculoskeletal radiologists at Mallinckrodt Institute are perfecting a procedure that has the potential to provide pain relief and mobility for patients who suffer from the debilitating effects of spinal bone loss and vertebral compression fractures.



8 BREAKTHROUGH IN TAMOXIFEN THERAPY

Using the anticancer agent tamoxifen and a non-invasive radiology technology called positron emission tomography, researchers can predict—within two weeks of initiation of treatment—the effectiveness of tamoxifen therapy in patients with metastatic breast cancer.



12 PROTON BEAMS, A NEW APPROACH TO CANCER THERAPY

An MIR radiation oncology resident discusses a special, proton-based form of cancer treatment and shares his experiences during a two-month fellowship at the only clinical proton therapy facility in the United States.

16 SOLVERS AND PLANNERS

In the mid-1970s Mallinckrodt Institute was among the first radiology departments worldwide to develop and to install information systems. Now some 20 years later, the MIR Computer Facilities group is efficiently supporting more than 1,000 MIR and BJC users while planning for the challenges of the radiology department of the future.



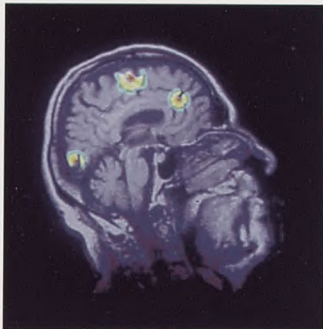
2 SPOT NEWS

19 FYI

ON THE COVER:

Breast cancer cells response to estrogen can determine the type of treatment used to combat breast cancer. In this positron emission tomography image, the increased uptake of an imaging agent called fluoroestradiol indicates that this breast cancer (shown in upper left quadrant of image) is estrogen receptor positive. Turn to page 8 for more information. Image courtesy of Farrokh Dehdashti, MD.

SPOT NEWS



Raichle shares top honor

Marcus Raichle, MD, codirector of the Division of Radiological Sciences, and Michael Posner, PhD, a former Washington University School of Medicine faculty member, received the American Philosophical Society's 1998 Karl Spencer Lashley Award in recognition of their contributions to brain imaging. The award was presented in November in Philadelphia and honors Karl Spencer Lashley, an American psychologist who studied the relation between brain mass and learning ability.

Raichle and Posner began their successful collaborative research at Washington University in 1985. In 1996, their study of neuroimaging and understanding the cognitive process in the human brain earned the 11th Annual Charles A. Dana Award for Pioneering

Achievements in Health and Education. Posner, a psychology professor, is now on faculty at the University of Oregon; Raichle is a professor of radiology and of neurology and neurobiology.

Founded in 1743 by Benjamin Franklin, the American Philosophical Society (APS) is the oldest learned society in the United States. Its original members were the "most ingenious and curious men who would promote useful knowledge in the colonies." The APS has evolved into an international institution of more than 700 distinguished scientists and scholars from the fields of mathematical and physical sciences, biological sciences, social sciences, humanities, and arts and public affairs.



Visit Web site

www.imaging.wustl.edu/meetings/ for more information about the three international radiopharmaceutical symposia scheduled this summer at the Washington University Medical Center. Information also is available by e-mailing ISRC13@mirlink.wustl.edu or by calling the office of Dr. Michael Welch, symposia coordinator, at 314-362-8436.

Gilula receives silver medal

In September, the International Skeletal Society (ISS) presented its silver medal to Louis Gilula, MD, chief of MIR's musculoskeletal radiology, in recognition of his active support of the society's interdisciplinary study of the pathogenesis, diagnosis, and treatment of skeletal disease. Since the society's inception in 1983, Gilula has been a leader of key ISS committees, including the Refresher Course Program, the Ad Hoc Committee on Refresher Course Planning, the Ad Hoc Liaison-Future Planning Committee, and the Committee for Fellowship Accreditation of Musculoskeletal Radiology.

An important segment of Gilula's research is diagnosing and treating the myriad causes of chronic wrist pain, a challenge for radiologists and surgeons due to the wrist's complex structure. Under Gilula's leadership a clinical center for patients with wrist pain has been developed at the Institute, with referrals from hand surgeons throughout the metropolitan St. Louis area and the bistate region.

Gilula is a fellow of the American College of Radiology and an honorary member of the American Society for Surgery of the Hand. He is on the review board and editorial staff of several leading scientific journals, including *Radiology*, the *American Journal of Roentgenology*, *Skeletal Radiology*, and the *American Journal of Orthopedics*. He is a founding member of the American Society for Musculoskeletal Radiology and a co-organizer since 1987 of the International Wrist Investigator's Workshop.

After receiving a medical degree from the University of Illinois School of Medicine, Gilula completed a one-year internship at San Francisco General Hospital. He completed a two-year radiology training program at DeWitt Army Hospital and three years of radiology residency at St. Louis City Hospital. Gilula joined the faculty of Mallinckrodt Institute in 1973 as an instructor in radiology and was appointed professor of radiology in 1982. He also holds joint appointments as professor of plastic and reconstructive surgery and of orthopaedic surgery.

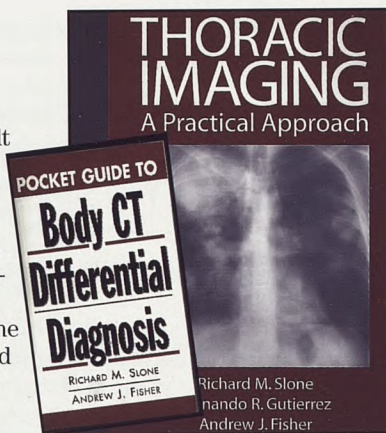
Evens heads ACR

Director of Mallinckrodt Institute Ronald Evens was installed in September as president of the American College of Radiology (ACR). With more than 31,000 members, the ACR is the major radiological association in the nation. Prior to being named president, Evens was chairman of the ACR's Board of Chancellors, the governing body responsible for determining policy standards.

During Evens' 27 years of leadership, Mallinckrodt Institute underwent a major expansion program and is now one of the largest academic radiology departments nationwide, with responsibility for more than 500,000 radiologic examinations per year.

A diagnostic radiologist, Evens is the Elizabeth Mallinckrodt professor of radiology and head of the Department of Radiology. He has served as past president and chief executive officer of St. Louis Children's Hospital, past vice-chancellor of financial affairs at Washington University, past vice president of the Washington University Medical Center Board of Directors, and past president of the Association of University Radiologists (AUR) and of the American Roentgen Ray Society (ARRS).

In 1990, he was appointed to the editorial board of the *Journal of the American Medical Association*, considered one of the premier medical and scientific journals worldwide. Evens received the prestigious Gold Medal awards of the AUR and the ARRS in 1996 and 1997, respectively, for his outstanding contributions to the specialty of radiology.



Radiology references published

Richard Slone, MD, assistant professor of radiology; Fernando Gutierrez, MD, associate professor of radiology; and Andrew Fisher, MD, assistant professor of radiology, are editors of *Thoracic Imaging: A Practical Approach*. Published by McGraw-Hill, this concise review provides vital information for diagnosing and managing patients with chest disease. Chapters devoted to a single topic or disease, along with hundreds of detailed images and drawings, provide an invaluable guide for physicians. Slone, Gutierrez, and Fisher authored several chapters as did Washington University School of Medicine doctors Bryan Meyers and Roger Yusen and former MIR fellows Matthew Fleishman and Robert Kanterman.

Slone and Fisher also edited *Pocket Guide to Body CT Differential Diagnosis*. Organized by body region, the *Pocket Guide* provides quick access to clinical findings, diagnostic considerations, and aids for the accurate interpretation of CT scans. Contributing authors are doctors Dennis Balfe, professor of radiology; Fleishman; David Gierada, assistant professor of radiology; Louis Gilula, professor of radiology, of plastic and reconstructive surgery, and of orthopaedic surgery; Christopher Gordon, instructor in radiology; Gutierrez; Cary Siegel, assistant professor of radiology; and Franz Wippold, associate professor of radiology.

RSNA funds MIR research

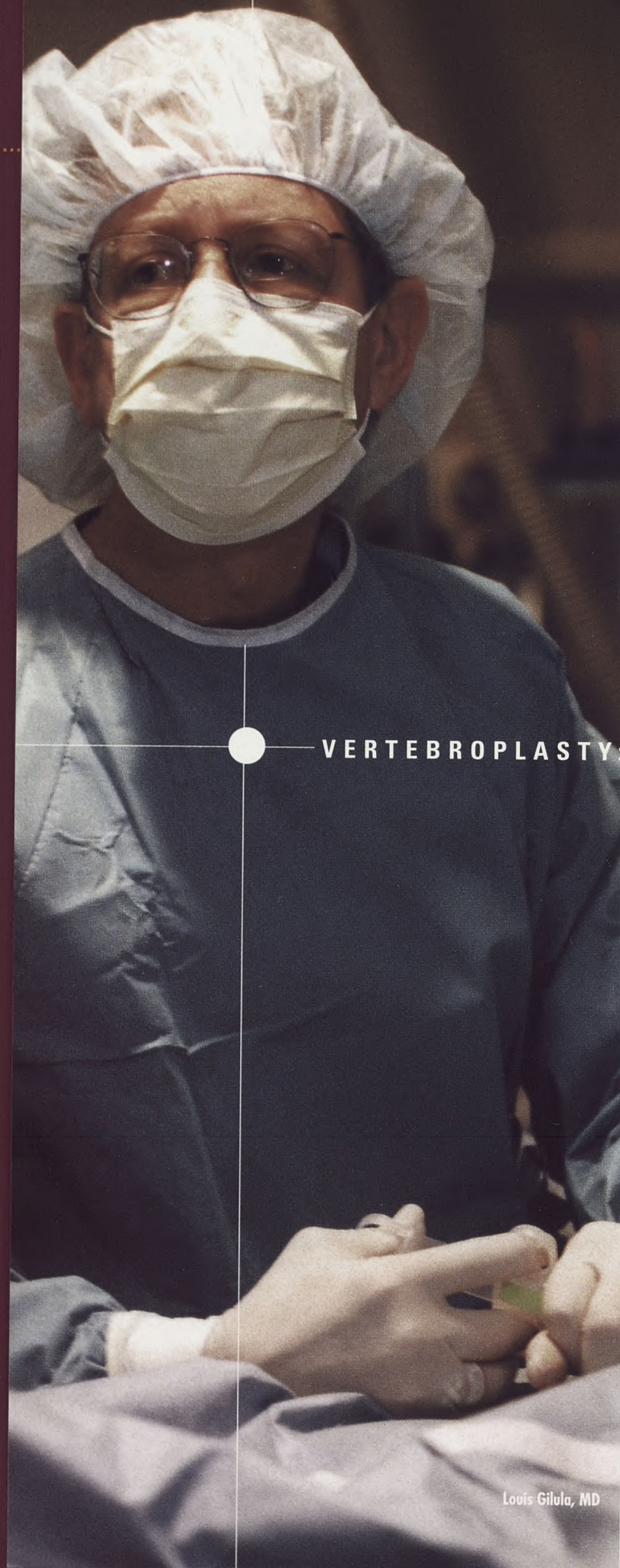Since 1986 the Radiological Society of North America (RSNA) has awarded Research and Education Fund Grants to young investigators as they begin careers in radiology research and education and in related scientific disciplines.

David Feinberg, MD, PhD, instructor in radiology, received an RSNA Scholar Award of \$60,000 annually for two years for his study of "Fast MRI scanning: development and clinical evaluation." Faculty members of North American institutions who are in the first five years of their academic careers are eligible for the Scholar Award.

David Hillier, MD, PhD, assistant in radiology, is the recipient of a Roentgen Resident/Fellow Research Award, which is presented annually to individuals who have distinguished themselves with their early accomplishments in radiological investigation. The award was presented to Hillier, in collaboration with Jerold Wallis, MD, associate professor of radiology, for his assessment of the effects of liver uptake on myocardial perfusion imaging using Tc-99m sestamibi.

Joshua Shimony, PhD, MD, assistant in radiology, received a Roentgen Resident/Fellow Research Award for his investigations of diffusion-weighted magnetic resonance (MR) imaging, which included the development of novel mathematical and numerical procedures for extracting information and analyzing data on diffusion anisotropy in the normal human brain. Thomas Conturo, MD, PhD, assistant professor of radiology and adjunct assistant professor of physics, served as scientific advisor.

Katy Vo, MD, clinical neuroradiology fellow, was named a Mallinckrodt Medical/RSNA Fellow. The award is presented to a qualified young scientist nearing the completion of training and carries a \$35,000 full-time stipend for one year, which will support Vo's research on "High resolution MR venography of occult venous malformations."



VERTEBROPLASTY:

MALLINCKRODT INSTITUTE OF RADIOLOGY (MIR) IS OFFERING A NEW PROCEDURE THAT HAS THE POTENTIAL TO OFFER PAIN RELIEF AND MOBILITY TO THOSE WHO SUFFER FROM THE DEBILITATION CAUSED BY SPINAL BONE LOSS AND VERTEBRAL COMPRESSION FRACTURES. ■ LOUIS GILULA, MD, PROFESSOR OF RADIOLOGY AND OF ORTHOPAEDIC, PLASTIC, AND RECONSTRUCTIVE SURGERY, HAS EXPERIENCED A HIGH MEASURE OF SUCCESS IN TREATING SUCH PATIENTS WITH THE TECHNIQUE KNOWN AS PERCUTANEOUS

MIR MAKES PROGRESS IN TREATING BONE PAIN

VERTEBROPLASTY (PVP), WHICH INVOLVES THE INJECTION OF A BIOCOMPATIBLE MATERIAL INTO SEGMENTS OF THE SPINE. THE INJECTION OF POLYMETHYLMETHACRYLATE (PMMA), A CEMENT-LIKE SUBSTANCE THAT HARDENS UPON DELIVERY, WORKS TO SUPPORT WEAKENED OR DETERIORATING BONES AND FRACTURED OR COMPRESSED VERTEBRAE AND TO BLOCK THE PAIN CAUSED BY THE ABNORMAL VERTEBRA. IN 70 TO 90 PERCENT OF PATIENTS, PAIN IS RELIEVED OR COMPLETELY ALLEVIATED.

Louis Gilula, MD

BY BRIDGET McDONALD

A GROWING NEED

Given the aging of the American population and the increasing number of elderly persons being diagnosed with osteoporosis, as well as patients with metastasis to the vertebra, vertebroplasty is a procedure that could offer an improved quality of life for many patients who are immobilized by pain. A preferred alternative to surgery, vertebroplasty is virtually painless, less invasive than surgery, and, therefore, has a shorter recovery period. A variation of vertebroplasty—a procedure known as cementoplasty—may have potential in the treatment of a wide range of individuals with bone deterioration and pain (typically from metastases) in areas other than the spine. "Cementoplasty has been useful in treating areas of the anatomy where surgery is not desirable, such as the pelvic area in patients with metastases," says Gilula, who also is chief of musculoskeletal radiology at MIR.

"The prime candidate for vertebroplasty is someone who has experienced a painful fracture that cannot be managed with pain medication or a fracture that does not resolve itself with time," says Gilula. "It is also a consideration for the patient who becomes unable to function because of pain or the use of pain medication."

Vertebroplasty, like cementoplasty, has been effective when used in conjunction with radiation to treat tumors and cancer of the bone. PVP may also benefit heart- and lung-transplant patients who have experienced compression fractures following the use of oral steroids as part of an immunosuppressive regimen or chronic condition.

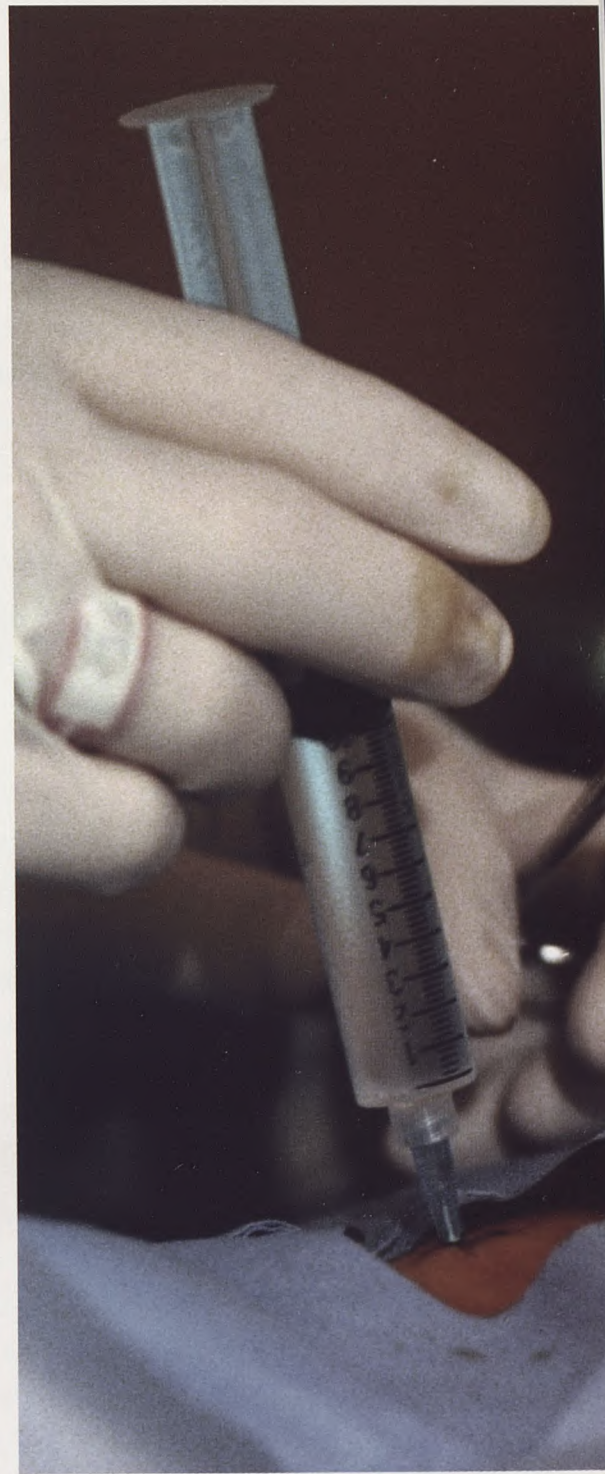MOBILIZING THE IMMOBILE

Vertebroplasty was introduced in the United States at the 1988 annual meeting of the Radiological Society of North America. Although the procedure has been used widely and successfully for many years in Europe, vertebroplasty has only recently been performed at a few medical centers in this country. Clinical results recorded by radiologists in France and in the United States show that the fundamental advantage of vertebroplasty is pain relief. Improvement in walking following PVP was also noted, especially in those who were previously bedridden. Researchers believe that pain relief plays a major role in restoring the patient's ability to walk, which in turn improves the patient's general quality of life.

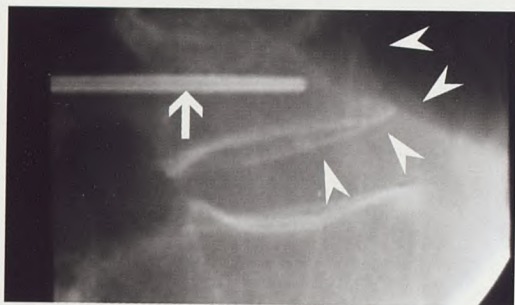
IMPROVING DELIVERY

Gilula says the use of PMMA to strengthen or replace lost bone is not a totally new development, even in the United States. The acrylic-based PMMA has been used as a bone filler in orthopaedics and dentistry for as many as 30 years. But the method of delivery used in vertebroplasty is fairly new in the U.S., and Gilula has worked to fine-tune the delivery system, using radiological viewing technologies for detailed precision during the procedure.

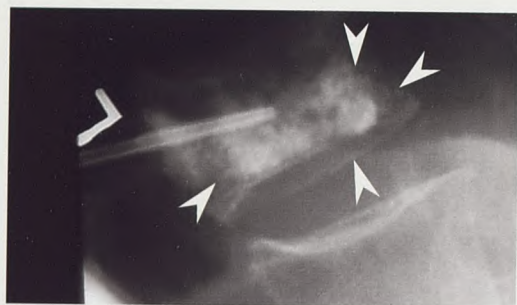A special type of PMMA must be used to allow placement of the substance through a needle. Using a 10- to 15-gauge needle to inject the acrylic cement through a small incision in the skin and into the problem area, radiologists at MIR are able to direct the flow of the injection as it occurs. With the visual aid provided by fluoroscopic



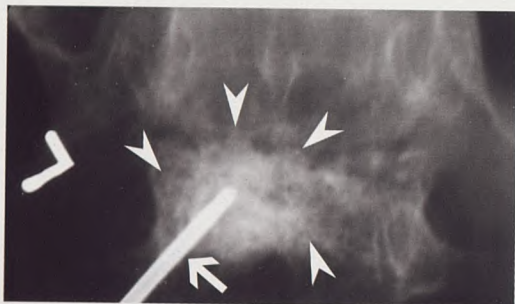
VERTEBROPLASTY



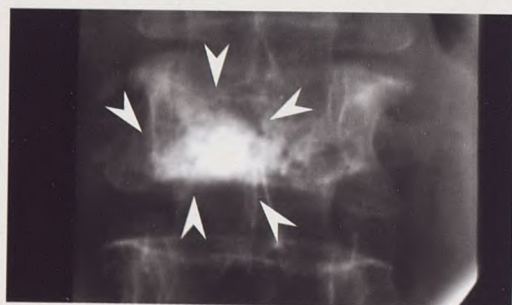On a side view, a needle (arrow) is in place within a fractured vertebral body (arrowheads).



On a side view of the vertebra, the white material (between arrowheads) is the methyl methacrylate which has been injected through the needle.



On a frontal view of the vertebra, the needle (arrow) is within the vertebral body surrounded by the dense, white methyl methacrylate (between arrowheads).



On the frontal view of the vertebra after removal of the needle, dense white methyl methacrylate (between arrowheads) is evident within the vertebral body.

guidance—with or without computed tomography (CT), doctors can see not only where the injection will work best but can actually watch the PMMA as it flows into the problem area, allowing for accurate placement and application of the substance. “The success of the procedure requires a marked attention to detail,” says Gilula, “and every technique available is used to make the desired precision possible.” In preparation for the procedure, patients undergo X-ray exams and various combinations of other imaging studies, including CT, magnetic resonance imaging, and isotope exams.

Before injecting the PMMA, doctors first inject a contrast material or dye into the bone site to judge the accuracy of the desired location and to get a visual sense of the density of the bone area. It is important that the PMMA substance does not seep into the blood system, so the ability to view the directional flow of the contrast injection prior to the actual cement injection is another safety feature.

“If there is too much destruction of the vertebra or if there is no structure for the PMMA to mold into, then the patient may not be a good candidate for the procedure,” says Gilula. He stresses the need to evaluate each patient’s situation individually. For instance, sometimes a patient will feel pain in the back that is associated with nerve pain going into an extremity. According to Gilula, vertebroplasty may help the back pain but usually would not reduce pain in the hips, thighs, or legs of those particular patients.

Vertebroplasty is performed under mild anesthesia that allows the patient to be awake while feeling either mild discomfort or no pain. “The patient’s ability to tell the radiologist what he or she is feeling is one of the safety features of the procedure,” says Gilula. The

patient lies facedown during the procedure, which usually takes approximately two hours, and feels only enough sensation to let the doctor know if a nerve is touched or if more anesthesia is needed.

Patients who undergo vertebroplasty can expect to go home usually the same day of the procedure, with no stitches and a simple Band-Aid® over their incision. Some patients experience immediate relief from pain, while for others it may take two to three days before there is a noticeable decrease in pain.

WEIGHING THE SIDE EFFECTS

Any procedure that involves the spine has certain risk factors and vertebroplasty is no exception. But radiologists at Mallinckrodt Institute use every precaution to assure the procedure is delivered in the safest manner. The most common complication for vertebroplasty, especially for those patients with thoracic spine fractures, is rib fracture caused by the pressure needed to insert the needle into the spine. Nothing can be done to prevent the rib fracture since most patients having this procedure usually have weakened bones, but the fractures can be treated with pain medication and will eventually heal. More serious complications can involve bleeding and spinal cord injury, cement particles entering the blood stream, or increased pain or further fracture of the bone being treated. But these more serious complications are exceedingly rare, says Gilula. The monitoring process during the procedure combined with the patient pre-evaluation make this a relatively safe and effective procedure.

KILLING THE PAIN

Although the success of vertebroplasty is usually attributed to the support and reinforcement of the bone provided by the hardened cement-like substance, Gilula says it is also likely that the heat created by the substance immediately after it is administered could play a part in the pain relief. "We know that the cement supports and holds the bone fragments apart so that they cannot rub together, and that alone can stop the pain. But it may also be that the heat generated by the hardening process kills the nerve ends that are causing the pain," he says, "and this is especially possible since pain relief can be evident immediately after the procedure."

"This procedure is a valuable new tool that will be more commonly used in the future to treat bone pain," adds Gilula, "and radiologists at Mallinckrodt Institute are paving the way for these developments." ■■■

Editor's note: Bridget McDonald is a Miami-based free-lance writer.

FINDING PAIN RELIEF

When Helen McCoy became incapacitated last winter following a fall on the ice while walking her dog, she became acutely aware of how pain can alter your life. "There were days when I couldn't make the bed," recalls the active 75-year-old great-grandmother. "And there were days I couldn't even get out of bed."


After a visit to her family physician, a referral to an orthopaedic surgeon and three sessions of physical therapy that she found too painful to pursue, Helen was referred to Dr. Louis Gilula, chief of musculoskeletal radiology at Mallinckrodt Institute of Radiology at Washington University Medical Center. By that time, seven months after the fall that caused a vertebra to fracture, Helen was a prime candidate for vertebroplasty. Her fracture had healed on its own, but she was having constant pain. She found it difficult to do simple things like climb in and out of the bathtub. "It was painful to bend over at all," she says, "and nearly impossible unless I held onto something."

Now, following vertebroplasty, Helen has returned to the healthy and active lifestyle she previously enjoyed. The procedure, says Helen, took only a few hours of recovery time and she felt no pain or discomfort during the injections.

"I could see what Doctor Gilula was doing while he was doing it," says Helen, who watched the procedure on a monitor via fluoroscopy. "I was not totally sedated, but just given something to numb the pain. The staff told me step-by-step what they were doing."

It took a little over an hour for Helen to recover from the treatment; she was allowed to sit up and shortly afterward went home. "It took a day or two for the pain [of the procedure] to completely disappear," she says. "But I didn't even need the pain medication Doctor Gilula prescribed."

She experienced no side effects or complications from the treatment and today has resumed her life as it was prior to the fall. "I can bend and I can sit up straight with no pain," Helen says. "It's great. I feel no pain in that area at all." ■■■



*A breakthrough
in treatment
outcome*

T A M O X I F E N

Imagine making an investment and knowing in advance what your return will be or planting a crop and determining the yield before the first seed germinates. Researchers at Mallinckrodt Institute of Radiology (MIR) and Washington University School of Medicine (WUSM) are doing just that in the treatment of advanced breast cancer. Using **tamoxifen**, the most commonly prescribed anti-cancer agent, and a noninvasive radiology technique called positron emission tomography (PET) that provides vivid functional images of various organ systems, researchers can predict within two weeks of initiation of treatment whether or not the therapy will work. This breakthrough enables patients who do not respond to tamoxifen therapy to pursue other avenues of treatment without wasting precious months or even weeks.

TAMOXIFEN'S EFFECTIVENESS

In a recent scientific paper, "PET Assessment of 'metabolic flare' to predict response of metastatic breast cancer to antiestrogen therapy," Mallinckrodt Institute's Farokh Dehdashti, MD, associate professor of radiology, describes the use of PET in determining the effectiveness of tamoxifen therapy by a response called "metabolic flare" in the patient. Metabolic flare is indicated on the PET image by an increased uptake of fluorodeoxyglucose (FDG), a radioactive form of sugar that is absorbed faster by malignant tissues than by normal tissues. It is from this flare reaction that a positive response to the treatment can be expected. The paper was coauthored by MIR's Barry Siegel, MD, and Michael Welch, PhD; Fidelma Flanagan, MRCPI, FRCR, University Hospital, Dublin, Ireland; Joanne Mortimer, MD, WUSM Department of Internal Medicine; and John Katzenellenbogen, PhD, University of Illinois, Champaign-Urbana.

Using PET and fluoroestradiol (FES), a radioactive form of estrogen developed as a PET imaging agent by Welch and Katzenellenbogen, researchers also are able to determine if a breast tumor is estrogen receptor (ER) positive—an important discovery because estrogen, a naturally occurring hormone, is believed to promote the growth of breast cancer cells.

Tamoxifen acts like both estrogen and antiestrogen. Like FES and estrogen, tamoxifen binds to the estrogen receptors on the tumor, but the drug's antiestrogen characteristics block the receptor, acting as an antagonist in the tumor to slow or prevent tumor growth.

According to Dehdashti, whose research is funded by the National Institutes of Health, 30 to 40 percent of patients with breast cancer are ER positive and are likely to respond to tamoxifen therapy. PET images using FES and FDG were taken of each woman in the study before initiation of her tamoxifen therapy. The images were repeated seven to ten days after therapy began, at which point metabolic flare could be determined. Those women with positive metabolic flare reactions continued tamoxifen treatment; those who had negative reactions were changed to a different type of therapy, thus saving valuable time.

Another important finding is the identification of "clinical flare," which is similar to metabolic flare but signals the possible onset of disease remission. Clinical flare is characterized by pain in the tumor site and in areas surrounding the tumor, making it difficult to differentiate clinical flare from disease progression. Since clinical flare occurs in less than 20 percent of patients, the discovery of the reaction of metabolic flare is important in saving time and unnecessary treatment.

REDUCING RISK


In women who have an increased risk of developing breast cancer, tamoxifen's antiestrogen characteristics are helpful in reducing their chance of developing the disease. In women who have been diagnosed with breast cancer, tamoxifen therapy can prevent a

recurrence of the original breast cancer as well as prevent metastasis in the opposite breast. If you consider that approximately 110 women out of every 100,000 will be diagnosed with breast cancer this year, then Dehdashti's and Welch's findings become paramount in fighting this disease. Even though tamoxifen has been in use for the treatment of breast cancer since 1978, it was not until October, 1998, that the U.S. Food and Drug Administration approved its use for prevention in high-risk patients. According to a recent study performed at the National Cancer Institute, tamoxifen has shown the ability to reduce the risk of breast cancer by 44 percent.

WEIGHING THE BENEFITS

The danger in the widespread use of tamoxifen as a prevention for breast cancer is that for healthy low-risk women, the possible side effects may outweigh the benefits. Although for women at high risk for breast cancer, prevention with tamoxifen might be considered based on the drug's record as a treatment as well as the new statistics on its preventive abilities.

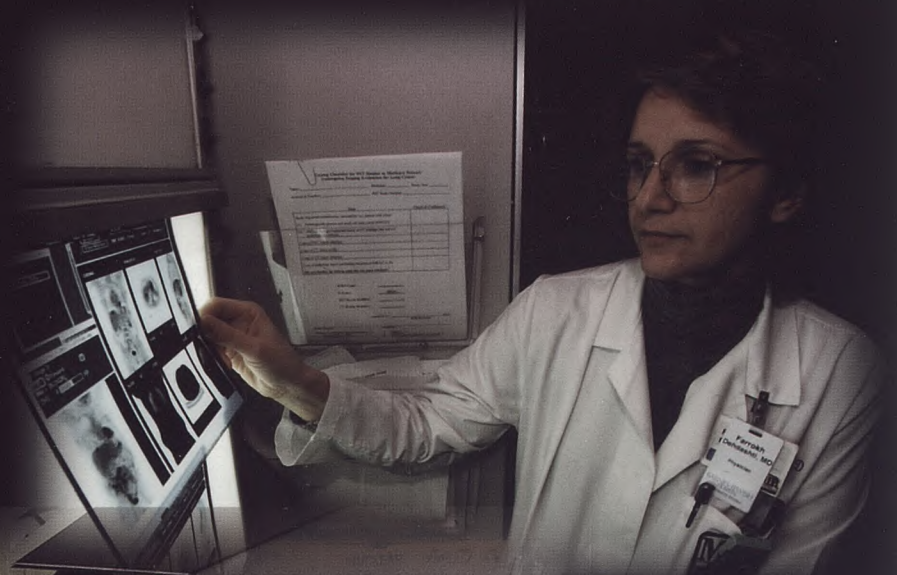
For 20 years and counting, MIR and WUSM researchers have been pioneers in the study of the treatment and prevention of breast cancer using tamoxifen. "Pharmacologically speaking, tamoxifen is very complicated," says Welch. "For this reason, the world can expect research to continue for at least another two decades."



TAMOXIFEN

Farrokh Dehdashti, MD

Michael Welch, PhD




Joanne Mortimer, MD

FDG-PET

FES-PET

Breast Cancer



Patient has primary breast cancer in her right breast. The above images are transaxial images at the level of the cancer. FDG image (left) shows markedly increased glucose metabolism in the breast lesion, consistent with breast cancer. FES image (right) shows markedly increased activity in the tumor consistent with high levels of estrogen receptors in the tumor. The green color on the right image is normal blood pool activity.

CONCURRENT TAMOXIFEN RESEARCH

Not only does menopause increase a woman's risk of breast cancer, it also puts her at risk of developing other common diseases such as osteoporosis and senile dementia of the Alzheimer's type (SDAT). And a possible antiestrogen side effect of tamoxifen is memory loss. Because estrogen is important to memory and brain function, women receiving estrogen hormone replacement therapy have shown a reduced incidence of developing SDAT. According to Mortimer, who is clinical director of WUSM's Division of Medical Oncology, there is some concern when 60 to 70 percent of women taking tamoxifen experience memory loss. In collaboration with Welch, professor of radiology, of chemistry, and of molecular biology and pharmacology, and with Marcus Raichle, MD, professor of radiology and of neurology and neurobiology, and Mark Minutn, MD, associate professor of radiology, Mortimer recently received a research grant from the Dana Foundation to assess the effects of tamoxifen on cognitive functioning.

Welch's research team, whose study is funded by the U.S. Department of Energy, used PET and FES to highlight estrogen receptors in the hypothalamus area of a baboon's brain. When using these same tools to image a woman's brain, Mortimer expects to see estrogen receptors concentrated in the region known as the hippocampus, which is responsible for memory.

The researchers also will use PET and FDG to image a woman's brain after initiation of tamoxifen treatment in order to capture a metabolic flare response similar to that found in breast cancer. After initiation of treatment, FES uptake will decrease as tamoxifen binding to the ERs will increase. At the same time, FDG uptake (glucose metabolism) increases. The results of Mortimer's study will help in understanding how glucose metabolism and brain function are closely related.

The images will allow researchers to see which parts of the brain contain ERs or where tamoxifen is binding in the brain. If tamoxifen is acting as an antiestrogen in the brain and is binding to sites that regulate memory, its use as a preventive agent may need to be reviewed and reconsidered. Tamoxifen's antiestrogen properties might have the same effect on short-term memory in menopausal women as that caused by lowered concentrations of estrogen. "Menopausal women often complain about not remembering people's names, being slower at working crossword puzzles, not having immediate recall, or having difficulty in finding their car in the parking garage," says Mortimer. "Since American women are living longer and will spend one-third of their lives postmenopause, our research findings are significant." **MIR**

Editor's note: Kirstin Blase is currently working as a medical research technician in MIR's Radiological Chemistry Laboratory.

POSSIBLE *side effects* OF TAMOXIFEN

As in premenopausal women whose bodies are still producing estrogen, tamoxifen's estrogen side effects may include the following:

- Lowered blood cholesterol.
- Increased bone density.
- Prevention of the recurrence of original breast cancer as well as new cancers in the opposite breast.
- Reduced number of cases of invasive breast cancer.
- Possible increased fertility in premenopausal women.
- Increased risk of developing uterine cancer.

As is the case with menopause, not all women who take tamoxifen have these symptoms:

- Hot flashes and vaginal discharge.
- Irregular menstrual periods.
- Dizziness, headaches.
- Fatigue and loss of appetite.
- Vaginal dryness or bleeding.
- Possible blood clots.
(Research studies suggest a small increase in number of blood clots in women taking tamoxifen, particularly in women who are receiving chemotherapy drugs along with tamoxifen.)
- Depression. (Reported in one percent of postmenopausal women using tamoxifen.)
- Slight increase for developing cataracts. (As women age, they are more likely to develop cataracts whether or not they take tamoxifen.)

This information was extracted from the National Cancer Institute's Cancer Facts.

PROTON BEAMS, A NEW APPROACH TO CANCER THERAPY

Samuel Au, MD, PhD, a resident in MIR's Radiation Oncology Center, received the 1998 American College of Radiation Oncology Fellowship, which sponsored a rotation in proton therapy at Loma Linda University Medical Center in California. Proton therapy is a form of cancer treatment that uses protons created by a special acclerator to deliver high doses of radiation to a tightly confined tumor site, thus reducing the side effects of the treatment while destroying diseased cells. In the following article, Au shares his thoughts about this exciting technology and his experiences at the only clinical proton therapy facility in the United States.



I have read about protons and charged particle beams in cancer treatments and was fascinated by their physical properties. They are especially important in the treatment of surgically inaccessible cancers. There are centers in Europe, the United States, and South Africa with such therapeutic modality. I chose to spend my two-month elective at Loma Linda University Medical Center (LLUMC) in California to learn firsthand about their proton facility. Currently, LLUMC houses the only clinical proton facility in the United States; however, Massachusetts General Hospital (MGH) has a lower energy level proton facility that is currently used for radiation treatment. MGH plans to open a modern clinical facility soon.

I have seen an artist's depiction of MGH's proposed proton facility, which highlights the center's structural complexity. I am still in awe every time I see the gigantic cyclotron and gantry structures of LLUMC's proton treatment facility. The cyclotron, as expected, is sizable. The gantry mechanisms and supporting structures above the treatment rooms are three to four stories high. Besides the advanced technology and science involved, the proton treatment facility is an engineering monument in itself. Since the medical center is within a few miles of the San Andreas Fault Line, the proton facility is designed structurally to withstand the worst foreseeable earthquake.

A proton beam, by virtue of its Bragg peak (a term used to describe the energy deposit pattern of the beam), offers the unique capability of delivering high dose radiation to a target volume deep inside a patient's body while keeping the dose to the adjacent organs relatively low. The entrance dose, compared to that of a photon beam, is substantially lower. In addition, the beam terminates abruptly with zero-exit dose after depositing all of its energy in the target. By modulating the beam with a rotating disc, the width of its Bragg peak is matched spatially to cover the target volume. In three-dimensional conformal therapy, proton beams are truly 3-D conformal beams. As photon beams, they conform to the cross-sections of the targets. In addition, the depths of their penetration and the lengths of energy deposition are matched to the longitudinal dimension of the target volume. This is implemented with a custom bolus shaped to compensate for the irregular thickness of the target volume.

The proton beams also possess the desirable feature of extremely sharp beam edges. Unlike photon beams that have penumbra and angular divergence, proton beams are made up of parallel aligned particles—with essentially no divergence or penumbra. In particular, the portion of the beam before the Bragg peak is especially

LLUMC has developed its own 3-D treatment planning system for proton and photon therapy, fully accounting for the difference in each therapy's dosimetry and physical attributes.

sharp-edged and practically a "parallel pencil beam." This portion of the beam is frequently used in the highly precise stereotactic radiotherapy used to treat critical targets. The Bragg peak, by design, is placed outside of the patient's body after the beam has exited the patient. The importance of the beam's sharp edges cannot be understated in treatment of tumors around critical structures such as the spinal cord, the optic nerves, the chiasm and essential tissues in the central nervous system. While covering the tumor volume in its entirety, the beams have to necessarily avoid the neighboring critical organs and structures. The beam's sharp edge geometrically offers the highest therapeutic ratios in these

PROTON BEAMS

cases. Very often, this spatial advantage presents the only feasible treatment plan adequate for the target, without causing unacceptable collateral injury to surrounding critical structures.

To achieve the full spatial benefits of proton beams, the treatment planning is necessarily done and optimized in a computerized 3-D system. The placement of beams, their orientations, and distributions are limited only by the physical limitations and degrees of freedom of the gantry, collimator, and treatment table. The coverage of target and dose homogeneity can be optimized in the process of virtual simulation using the stored images of the patients. This shortens the uncomfortable time patients spend lying on a simulation table while clinicians determine the best treatment geometry. This virtual procedure also alleviates the heavy demand on support personnel and allows more efficient use of simulation resources. With the advancement of image processing techniques, delineation of targets and critical organs to a high degree of precision and accuracy is feasible with the fusion of various imaging modalities, including ultrasound, computed tomography, and magnetic resonance imaging.

LLUMC has developed its own 3-D treatment planning system for proton and photon therapy, fully accounting for the difference in each therapy's dosimetry and physical attributes. As do other commercially available photon planning systems, LLUMC's system offers the full spectrum of computational and 3-D display features. One can readily appreciate that its design stems from years of three-dimensional treatment planning experience. In my opinion, it has achieved the user-friendly criterion of "bringing together and connecting man and machine in continuum."

The striking aspect of this system is that it is a PC window-based system. All the PCs in the department are connected in a local network, exploiting to the maximum the current computer-network technology. An authorized user can access the full capacity of any PC in the network from his or her terminal. Using a home PC, a physician can outline a gross tumor in the comfort of his or her own home, plan the treatment, and still enjoy a family dinner. With the availability of high-data-rate communication technology and the Internet, the idea of transcontinental telemedicine in radiation therapy is not a farfetched idea.

One of the challenging issues in high-dose conformal radiotherapy is dealing with internal target-organ movements or target-position changes between treatments, such as occurs in high-dose conformal prostate therapy. Currently, ultrasonic imaging of the prostate prior to every treatment in order to facilitate better targeting is being studied in some treatment centers. Other centers approach this problem by increasing the (beam) portal margins to account for the prostate's change of position. The sensitive rectum, which is immediately posterior to the prostate, is mobile and tends to move freely with the prostate. The increase of margin around the target prostate will result in an increase of exposure to the rectum. A proactive technique is used at LLUMC, whereby a rectal balloon is applied onto the prostate. The balloon places the target prostate in a more consistent reproducible position relative to the bony landmarks. It also displaces a major portion of the rectal wall away from the target prostate and seminal vesicles, thereby minimizing the unnecessary exposure to the rectum. LLUMC's therapeutic results in terms of tumor control, complications, and patient satisfaction have been excellent and comparable with some of the best published results

in scientific literature. It will be interesting to see the comparative results of various approaches in the future. If LLUMC's rectal balloon technique proves beneficial, it can readily be deployed with the transrectal ultrasound approach.

The supporting technology and methodology that make the best and most optimal use of proton therapy as a standard treatment modality for cancers are advancing rapidly. It would not be surprising to have multileaf collimators, reverse planning, beam intensity modulation, and similar technology for proton therapy available within the next few years. At LLUMC, a real-time portal imaging system has already become a standard portion of the daily treatment operation. Staff physicians routinely verify and fine-tune the isocentric setup so that daily setup variations are minimized. At first glance the procedure is labor-intensive, but operational practice experience suggests that it can be very efficient with a fully trained team.

Another technology deployed at LLUMC for efficient treatment delivery is a bar-code system for each patient's chart, treatment blocks, custom bolus, and immobilization cradle. As a daily quality assurance control


measure, therapists scan the bar codes on every medical-related article of the patient's information before treatment begins. The bar-code system improves efficiency and daily patient setups and is a simple safeguard for any day-to-day human errors.

During the two months I spent at LLUMC, I was very impressed with the weekly treatment planning review. For every case, the tumor and isodose volumes with surface rendering were selectively projected onto a room-size screen, and the clinical staff participated in a lively discussion and exchange of ideas for planning the beams and treatment geometry. This

The supporting technology and methodology that make the best and most optimal use of proton therapy as a standard treatment modality for cancers are advancing rapidly.

took experience and insight into the planning of each case since there was never a textbook case.

Proton as a modality in radiation therapy has not been an option in the less developed countries, and its unavailability in the Third World countries is largely due to economics as well as the lack of properly trained physicians and support personnel. Asia, with its large population, has one of the highest incidence rates of head and neck cancers in the world. Physicians trained in proton therapy will be essential in establishing and making available such treatment options to the public. Currently in Taiwan, Japan, and soon in China and other Third World countries, concrete plans to implement this technology are being generated.

My goal is to use my scientific knowledge to bring medical technology and newly available medicine to Asia, where I was born and raised. I am thankful for the opportunity to have observed LLUMC's world-class proton facility and the application of various advanced technologies for efficient treatment delivery. I am grateful to LLUMC's staffs and residents for making my rotation such a profound learning experience and to the American College of Radiation Oncology Committee for sponsoring my rotation. 

A man with a mustache, wearing a dark shirt and khaki pants, is sitting on the floor in a server room. He is looking down at a large sheet of paper he is holding. Behind him are several server racks filled with equipment, and a dense, chaotic network of white cables hangs from the racks. The lighting is dim, creating a focused and technical atmosphere.

SOLVERS & PLANNERS

MIR Computer
Facilities plans
for the radiology
department
of the future.

by Candace O'Connor

Phil Seper, a system support technician



Laura Ruhrwien

From the moment a BJC Health SystemSM patient makes an appointment for a radiologic exam, Mallinckrodt Institute of Radiology (MIR) computers are at the very heart of the process. The computers record the scheduling data, the patient's arrival, and the written test results. They supply background on the patient's medical history to the physician, and they even provide a link to billing once the exam is complete.

"All of this information used to be handled with pieces of paper," says Gilbert Jost, MD, professor of radiology and chief of MIR's Division of Diagnostic Radiology. "Not only is this computer record more efficient, but it also gives us an opportunity to access patient data electronically from any point in the system."


This radiology system relies upon the work of a behind-the-scenes group: MIR Computer Facilities. This busy service provides information systems (IS) support for 400 MIR users located at Barnes-Jewish, Barnes-Jewish St. Peter's, and St. Louis Children's hospitals as well as 600 users in BJC's central region.

And as if this were not enough, the computer group itself has recently undertaken a major reorganization, a planned move to the Institute's East Building, and a major shift in focus to new activities and a broader mission. "We are growing—and not just growing and doing the same thing. We're adding a number of services, which we're delivering in a cost-effective manner," says Laura Ruhrwien, director of information systems at MIR who has expertise in managing IS systems and creating business plans that contain strong cost-benefit analysis.

"The revitalized emphasis on computer facilities comes at a time when some institutions are backing away from leading-edge involvement in computer technology. MIR historically has been an information systems leader and, in the mid-1970s, was among the first radiology departments worldwide to develop and install information systems, says Jost. "We intend to maintain its reputation as a leader in this area."

"It is most unusual for a radiology department to have a computer group as large and as vigorous as this one," Jost adds. "But we feel that this technology is going to be at the heart of our specialty for years to come, and that having a strong IS group will enable us to deal with a host of challenges down the road."

There were eight computer staff when Ruhrwien arrived at MIR in November of 1997, but she plans to increase that number to 19 by the end of 1999. Under Ruhrwien's leadership, the group has reorganized into a three-tier structure: One group now handles the "Help Desk" function, answering 50 to 100 calls each day. They log all calls, respond as quickly as possi-

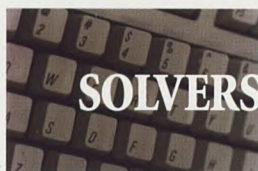

Tracy Duckett, a user support technician

ble, and work with users to spot potential trouble and to eliminate routine problems. Eighty percent of the problems can be solved in a single business day; the other 20 percent are referred to a second-tier group who tackle large projects that may take from one day to three weeks to resolve.

The third group covers major projects that are part of a new four-year plan developed by Ruhrwien, Jost, and James Blaine, DSc, professor of radiology and director of MIR's Electronic Radiology Laboratory (ERL). This third group just completed a year-long project to convert Children's Hospital from the MIR radiology information system that had been developed in-house to a newer, easier-to-maintain system called IDXrad, which is offered by an outside vendor. This group was no stranger to large, complicated projects since they had previously completed a system conversion at Barnes-Jewish Hospital (BJH) in June, 1996, and another at BJH West County in May, 1997. Next up is the conversion of the information system for the BJH-sponsored Breast Health Center as well as the system for the mammography van.

"The Children's conversion was our third project," says Steve



SOLVERS & PLANNERS



Steve Rodewald

Rodewald, a systems analyst who has been with the computer group since 1980. "Our experience pays off each time we handle a more complicated conversion."

One key to success of the Children's Hospital project was taking data from the old system—affectionately known as "REXrad" for Rex Hill, the system's developer and former head of the computer group—and loading it on IDXrad so that users had easy access. A second key was the staging of a full-scale simulation of the system a few weeks prior to "going live." This afforded the group a sense of how IDXrad would operate.

Another large, complicated project just now beginning involves working with the ERL on Project Spectrum, a collaborative partnership among BJC, MIR, and Washington University School of Medicine. Project Spectrum will ultimately provide integrated patient information and images to physicians in the BJC system. The ERL is charged with the electronic imaging aspect of this project: to facilitate a major shift from film-based to digital images.


BJC's Information Technology group has been storing standard BJC patient data, laboratory tests, demographics, and vital statistics in a clinical information repository. At

the same time, the ERL group is creating an image repository, so that the primary care physician can have desktop access, through a simple click of an icon, to radiologic images cited on a patient's chart. At the moment, some 450 clinical workstations, located in physicians' offices and homes, provide access to these written and visual records.

Within the next year, this project will be taken a step further: The ERL will provide its developmental support to the Computer Facilities staff, and the two groups will work together closely to develop and support a filmless environment at MIR. To make this collaboration easier, the computer group will move in early 1999 from their cramped quarters in the Clinical Sciences Research Building to a larger space in the East Building on Scott Avenue, placing them adjacent to the ERL.

"One of the goals for Computer Facilities is to accomplish the transition from the research and development area into production," says Blaine. "I believe that Laura is taking a very professional approach to defining requirements and activating plans that will achieve this goal."

The computer group also will be undertaking several other big projects, including Satellite Radiology Services that is slated to begin in summer of 2000 and is aimed at developing new procedures so that MIR can add client groups, such as health care facilities, for whom MIR will provide fast and inexpensive radiologic services. Another project, still in the planning stage, is a complete changeover of MIR desktop services, in an effort to make the workplace more efficient by standardizing software and hardware. As part of this project, all MIR employees will receive a new computer, along with a uniform version of software and a brand-new electronic-mail system.



Prapapun "Pun" Wilson, a programmer

Ruhrwien also believes that another opportunity for improvement is in the area of management reporting. The computer staff will soon begin work on a new system that will make it easier to evaluate performance, to provide managed-care and outcomes analysis, and to merge clinical and financial data. "The more information we can provide to BJC management and to the radiologists, the more efficiently they can do their work," says Ruhrwien.

With all of these changes already in progress, and with those that are anticipated, it is appropriate that the Computer Facilities group may adopt a new name—Radiology Information and Imaging Services—that is indicative of the wide range of services the group provides. It has been a hectic, sometimes frustrating, first year, Ruhrwien admits. But on days when she can pause to reflect upon it, she also realizes that all this work and planning for the future has actually been enjoyable.

"Now that we have our vision in mind and many people are on board with our ideas, it is exciting to create this new organization and to think about the strategic importance and value we can provide both to BJC and MIR," she says. 

In this section, the names of personnel who are full-time faculty or staff or who have an appointment in the Department of Radiology are highlighted in boldface type.

THE DIRECTOR'S OFFICE REPORT

APPOINTMENTS

Robert Thompson, MD, associate professor of surgery (general surgery) and of cell biology and physiology, was appointed as associate professor of radiology, Division of Diagnostic Radiology.

CHANGE IN STATUS

Harold Bennett, MD, PhD, assistant professor of radiology (investigator), was appointed assistant professor of radiology (clinical), Division of Diagnostic Radiology.

DeWitte Cross, MD, assistant professor of radiology (investigator), was appointed assistant professor of radiology (clinical), Division of Diagnostic Radiology.

David Hovsepian, MD, assistant professor of radiology (investigator), was appointed assistant professor of radiology (clinical), Division of Diagnostic Radiology.

Clayton Hunt, PhD, assistant professor of radiology (investigator), was appointed assistant professor of radiology (research), Radiation Oncology Center.

Janice Semenkovich, MD, assistant professor of radiology (investigator), was appointed assistant professor of radiology (clinical), Division of Diagnostic Radiology.

NEW FACULTY

David Feinberg, MD, assistant professor of radiology, Division of Diagnostic Radiology.

Pilar Herrero, MS, research scientist, Division of Radiological Sciences.

Suresh Vedantham, MD, assistant professor of radiology, Division of Diagnostic Radiology.

OFF STAFF

Mary Graham, MD, assistant professor of radiology, Radiation Oncology Center.

Celette Sugg Skinner, PhD, assistant professor of radiology, Division of Radiological Sciences.

Rao Vallabhaneni, PhD, instructor in radiology, Division of Radiological Sciences.

APPOINTMENTS/ELECTIONS

Thomas Conturo, MD, PhD, assistant professor of radiology and adjunct assistant professor of physics, was appointed director of the MIR Summer Research Program. Now in its fifth year, the program offers medical students and science undergraduates an introduction to different aspects of radiological sciences research.

Jay Heiken, MD, professor of radiology, chief of abdominal radiology, and codirector of body computed tomography, was elected vice president-elect designate of the Society of Computed Body Tomography and Magnetic Resonance at the society's annual meeting in Rancho Mirage, California. He was appointed by the Board of Governors of the Radiological Society of North America (RSNA) to serve on the Gastrointestinal Subcommittee of the RSNA Program Committee.

Gilbert Jost, MD, professor of radiology and chief of the Division of Diagnostic Radiology, was appointed chairman of the Radiological Society of North America's (RSNA) Electronic Communications Committee. The committee is responsible for the InfoRAD exhibit at RSNA's annual meeting as well as a variety of computer- and electronic communication-related projects throughout the year.

Eric Klein, MS, assistant professor of radiology, was appointed to a three-year term as a member of the

American Board of Medical Physics. He also was appointed as a member of the Continuing Education Committee and of the Program Committee of the American Association of Physicists in Medicine (AAPM) and as scientific codirector for the 1999 AAPM Annual Meeting.

Robert McKinstry, MD, PhD, instructor in radiology, was appointed to the National Institutes of Health/National Institute of Mental Health Technical Evaluation Panel.

Eduardo Moros, PhD, assistant professor of radiology, was appointed chairman of the Symposium on Modeling of Mass Transfer in Biological Systems and of the Symposium on Modeling of Heat Transfer in Biological Systems for the International Mechanical Engineering Congress and Exposition held November 15 - 20 in Anaheim, California.

David Piwnica-Worms, MD, PhD, professor of radiology and of molecular biology and pharmacology, and director of the molecular pharmacology laboratory, was appointed as a member of the Washington University Cancer Center Executive Committee and of the Washington University School of Medicine Medical Scientist Training Program's Admissions Committee. He was reappointed as a member of the Radiological Society of North America's Research Development Committee.

APPOINTMENTS/ ELECTIONS

Continued from page 19

William Reinus, MD, associate professor of radiology, was appointed comoderator of the "GI pathology and radiology in the next millennium" course at the American College of Gastroenterology Annual Meeting held October 9.

Joseph Roti Roti, PhD, professor of radiology, associate director of the Radiation Oncology Center, and chief of cancer biology, was appointed as a panel member of the FDA Inneragency Working Group on the

Progress of Wireless Technology Research, which convened in Washington, DC, on November 12 and 13.

Marilyn Siegel, MD, professor of radiology and of pediatrics, was appointed to a two-year term as treasurer of the International Cancer Imaging Society.

Pamela Woodard, MD, assistant professor of radiology, was appointed to the Society for Cardiovascular Magnetic Resonance Membership Committee.

FELLOWSHIPS/ GRANTS

Joshua Shimony, PhD, MD, assistant in radiology, received a \$90,724 grant from the Spinal Cord Research Foundation, which is sponsored by the Paralyzed Veterans of America, for research on "Diffusion imaging of the cervical spinal cord." Coinvestigators for the two-year grant are **Erbil Akbudak, PhD**, research instructor in radiology; **Abraham Snyder, PhD, MD**, research scientist of radiology; and **Thomas Conturo, MD, PhD**, assistant professor of radiology and adjunct assistant professor of physics.

David Piwnica-Worms, MD, PhD, professor of radiology and of molecular biology and pharmacology, and director of the molecular pharmacology laboratory, as principal investigator, received a \$254,000 renewal grant from the U.S. Department of Energy Molecular Nuclear Medicine Program. Coinvestigators for the research on "Targeting multidrug resistance with metal complexes" are **Vijay Sharma, PhD**, research assistant professor of radiology; **Valery Polyakov, PhD**, research associate; **Kathryn Luker, PhD**, research associate; and **Julie Dahlheimer**, senior medical research technician.

Douglas Spitz, PhD, assistant professor of radiology, as principal investigator, received a \$1.3 million grant from the National Institutes of Health for research on "Nitric oxide-induced cell injury: molecular mechanisms." Coinvestigators for the grant are **Prabhat Goswami, PhD**, assistant professor of radiology, and **Clayton Hunt, PhD**, assistant professor of radiology.

Sharlene Teefey, MD, associate professor of radiology, as principal investigator, received a grant from the Society of Radiologists in Ultrasound for research on "Detection of rotator cuff and biceps tendon pathology in patients with a painful shoulder: a comparison of US, MRI, and arthroscopic surgery in 100 consecutive cases." Coinvestigators for the \$40,000 grant are **William Middleton, MD**, professor of radiology; **Scott Mirowitz, MD**, associate professor of radiology; **William Totty, MD**, professor of radiology; **Vamsidhar Narra, MD**, instructor in radiology; and **Ken Yamaguchi, MD**, assistant professor of orthopaedic surgery, Washington University.

Jeffrey Williamson, PhD, professor of radiology, received a \$1 million grant from the National Cancer Institute for research on "Integration of imaging techniques into treatment of locally advanced cervical cancer." Coinvestigators for the four-year grant are **Harold Bennett, MD, PhD**, assistant professor of radiology; **Clifford Chao, MD**, assistant professor of radiology; **Joseph O'Sullivan, PhD**, associate professor of

electrical engineering and of radiology; **James Dempsey, PhD**, research associate; **Carlos Perez, MD**, professor of radiology; **Perry Grigsby, MD**, professor of radiology; **Donald Snyder, PhD**, professor of electrical engineering and of radiology; **Michael Vannier, MD**, University of Iowa; **Ge Wang, PhD**, University of Iowa; **Gary Christensen, DSc**, University of Iowa; and **Kenneth Weeks, PhD**, Duke University.

HONORS/ AWARDS

Sharlene Teefey, MD, associate professor of radiology, was named a fellow of the Society of Radiologists in Ultrasound.

LECTURES/ PRESENTATIONS

Heather Curry, MD, assistant in radiology and assistant chief resident, radiation oncology, presented "Heat shock inhibits radiation-induced activation of DNA-binding and nuclear localization of NF-KB" at The Oxygen Society meeting, Washington, DC, November 20.

Colin Derdeyn, MD, assistant professor of radiology, spoke on "Imaging of stroke: evaluation of carotid artery disease" at the 6th Annual Update for the Clinician, Carbondale, Illinois, November 7.

David Gierada, MD, assistant professor of radiology, presented "Quantitative CT assessment of emphysema in patients evaluated for lung volume reduction surgery" at Chest 1998, American College of Chest Physicians, Toronto, Ontario, Canada, November 8 - 12.

Louis Gilula, MD, professor of radiology, of orthopaedic and plastic and reconstructive surgery, and chief of musculoskeletal radiology, spoke on "Cervical nerve root spine blocks," "Introduction for interventional spine procedures," and "Radiofrequency facet denervation of lumbar spine" at the International Skeletal Society Annual Meeting, Dublin, Ireland, September 5 - 12. He presented "MRI of wrist and hand," "MRI of foot and ankle," "Plain film approach to bone tumors," "Radiography of hand and wrist trauma," and "Known condi-

tions of wrist and hand that should be recognized by radiologists" at A Meeting of Sociedade Brasileira de Radiologia, Rio de Janeiro, Brazil, October 24.

David Gius, MD, instructor in radiology, presented "Redox regulation of AP-1 DNA binding in HeLa and NIH3T3 cells in response to heat" at The Oxygen Society meeting, Washington, DC, November 20.

Robert Gropler, MD, associate professor of radiology and director of the cardiovascular imaging laboratory, presented "Effective reporting of myocardial perfusion imaging to clinicians" at the Strategies for Effective Myocardial Perfusion Imaging in Managing Patients with Coronary Artery Disease Symposium, sponsored by Mallinckrodt Institute and Washington University, St. Louis, Missouri, September 19. He spoke on "Noninvasive measurement of regional myocardial efficiency in the normal human heart" at the 71st Scientific Sessions of the American Heart Association, Dallas, Texas, November 8 - 11.

Speaking for **Pamela Woodard, MD**, assistant professor of radiology, Gropler presented "New developments in 3D coronary MR angiography using the MS325 MR blood pool agent" at the 25th Annual Meeting of the North American Society for Cardiac Imaging, Dallas, Texas, November 7.

Mark Haacke, PhD, professor of radiology and of electrical engineering and



Melson Lecture

Philip Ralls, MD, head of the Division of Diagnostic Radiology at the University of Southern California-Los Angeles Medical Center, presented the Sixth Annual G. Leland Melson Visiting Professorship and Lecture on September 14 in MIR's Scarpellino Auditorium. Dr. Ralls, who spoke on "Pancreatic sonography: What's New," was presented with a commemorative lecture plaque and is shown with Mrs. Lee Melson (Brenda) and Dr. Jay Heiken, chief of abdominal radiology and coordinator of the Melson Lecture.

director of the magnetic resonance imaging research laboratory, spoke on "Applications of 3D gradient echo imaging in observing lesion vascularity" at the Xth International Workshop on MRA, Park City, Utah, September 30 - October 3. He presented "Understanding fMRI: its origins and its implications" at Baylor College of Medicine, Houston, Texas, November 17.

Jay Heiken, MD, professor of radiology, chief of abdominal radiology, and codirector of body computed tomography, presented "3D imaging: Why should we do it?" and "Hepatic masses: characterization with CT and MRI" at Digital Imaging Update, sponsored by Yale University, Brescia, Italy, September 28. He presented "CT evaluation of nontraumatic gastrointestinal emergencies" to the South Central

Kansas Radiological Society, Wichita, November 3. As visiting professor, Heiken spoke on "A practical approach to spiral CT of the abdomen" at the Wesley Medical Center, Wichita, Kansas, November 3. He presented "CT evaluation of nontraumatic abdominal emergencies" at Radiology Update for the Clinician, sponsored by Memorial Hospital of Carbondale, Carbondale, Illinois, November 7.

Pilar Herrero, MS, research assistant professor of radiology, presented "Evaluation of myocardial kinetics of the hypoxic agent Cu-60-Diacetyl-Bis-(N-Methylthiosemicarbazone) (Cu-ATSM)" at the 71st Scientific Sessions of the American Heart Association, Dallas, Texas, November 8 - 11.

LECTURES/
PRESENTATIONS*Continued from page 21*

Fiorenza Ianzini, PhD, assistant professor of radiology, spoke on "Radiation-induced mitotic catastrophe occurs to a reduced extent in cells with functional p53: implications for genomic instability" at the Workshop on Dose Response Relationships Involved in the Development of Radiation-induced Genomic Instability and the Implications for Radiation Protections, Capri, Italy, October 2 - 4. She presented "Kinetics and magnitude of mitotic catastrophe produced by exposure of V79 Chinese hamster cells to high LET radiation" at the 29th Meeting of the European Society for Radiation Biology and 9th Meeting of the Italian Society for Radiation Research, Capri, Italy, October 3 - 7.

Eric Klein, MS, assistant professor of radiology, presented "New technologies in radiation oncology" at the United International Cancer Congress, Rio de Janeiro, Brazil, August 23.

Weili Lin, PhD, assistant professor of radiology, spoke on "Cerebral oxygen saturation measurement using MRI" at the Xth International Workshop on MRA, Park City, Utah, September 30 - October 3.

Jacob Locke, MD, assistant in radiology, presented "Risk factors for urinary retention in prostate brachytherapy patients" at the Western American Urological Association Annual Meeting, Hawaii, October 25.

Daniel Low, PhD, assistant professor of radiology, presented "Serial tomotherapy" at Stanford University and at the University of California, San Francisco, October 8 and 9.

Robert McKinstry, MD, PhD, instructor in radiology, as an invited speaker for a series of workshops sponsored by the American Medical Association, presented "Physicians accessing the Internet" to the California Medical Association Leadership Council, Palm Springs, September 11; to the Alameda Contra Costa Medical Association, Oakland, California, October 17; to the 1st Marine Expeditionary Force, Camp Pendleton, San Diego, California, November 13; and at the American Medical Association House of Delegates meeting, Waikaloa, Hawaii, December 10 - 13.

Jeff Michalski, MD, assistant professor of radiology, spoke on "Quality assurance in 3D RTP radiation therapy planning clinical trials" at the University of North Carolina, Chapel Hill, September 1. He presented "The challenge of delivering and verifying quality conformal radiotherapy" at EPI, Phoenix, Arizona, October 29. Michalski spoke on "3D RT planning for CNS/pediatric tumors," "Quality assurance for 3D conformal radiation therapy trials," and "Treatment of prostate cancer: 3D conformal RT & BT," Haifa, Israel, November 17 and 18.

Eduardo Moros, PhD, assistant professor of radiology, presented "Model for ultrasonic heating of chest-wall recurrences" at the Symposium on Modeling of Heat Transfer in Biological Systems, International Mechanical Engineering Congress and Exposition, Anaheim, California, November 15 - 20.

Vamsidhar Narra, MD, instructor in radiology, spoke on "MR imaging of the liver" at the Nizam's Institute of Medical Sciences, Hyderabad, India, August 24. He presented "MR imaging of the pelvis" to the Indian Radiological and Imaging Association, Hyderabad, India, August 26.

Carlos Perez, MD, professor of radiology and director of the Radiation Oncology Center, spoke on "Cervix: management of stage I through IIIB" and "Hypoxic cell sensitizers/protectors" at the 17th UICC International Cancer Congress, Rio de Janeiro, Brazil, August 24 - 28. He presented "Radiotherapy in the management of carcinoma of the prostate" and "Role of postoperative irradiation in T3 tumors and in patients with extensive axillary involvement" to the Third Turkish National Oncology Congress, Istanbul, Turkey, October 11 - 17. He spoke on "When is it appropriate to treat breast cancer with irradiation alone: When is axillary nodal dissection not needed?" at the St. Louis Medical Society meeting, St. Louis, Missouri, November 10. Perez presented "3-D conformal radiation therapy in carcinoma of the prostate" at the 3-D Conformal External Radiation Therapy Conference, Barcelona, Spain, November 24 - 26. Perez presented "Conventional radiation therapy and neoadjuvant

hormone therapy in localized carcinoma of the prostate" and "Three-dimensional conformal radiation therapy and potential for intensity modulated radiation therapy" to the Italian Association of Radiation Oncology, Milan, Italy, November 27. He spoke on "Primary treatment of nasopharyngeal cancer," "Radiotherapy in the multidisciplinary treatment of locally advanced head and neck carcinomas," "Treatment of recurrent nasopharyngeal cancer," "Advances in radiotherapy," "Radiation alone or combined with chemotherapy in carcinomas of the nasopharynx," and "Cancer of the salivary glands" at the 1st World Congress on Head and Neck Oncology meeting, Madrid, Spain, December 1 - 3. He presented "From conventional to conformal radiotherapy" and "LDR-HDR brachytherapy: USA experience" to the World Board Congress of Brachytherapy, Guayaquil, Ecuador, December 14 - 16.

Marcus Raichle, MD, professor of radiology and of neurology and neurobiology, and codirector of the Division of Radiological Sciences, spoke on "Conservation of consciousness: notes towards an imaging-based theory" at the Neuroscience Colloquium, sponsored by the Medical University of South Carolina, Charleston, September 17, and at the Cognitive Neuroscience Talk, Washington University School of Medicine, St. Louis, Missouri, November 18. He presented "Images of mind" at the St. Louis Science Center, St. Louis, Missouri, September 22. Raichle spoke on "Emerging images of mind" at the Whitehead Institute Symposium, Cambridge,

Massachusetts, October 25 - 27. He spoke on "Searching for images of the mind" at the Princeton University Public Lecture, Princeton, New Jersey, December 2. As a panel member, he spoke on "The neurobiological bases of functional neuroimaging" at the American College of Neuropsychopharmacology, Las Croabas, Puerto Rico, December 14 - 18.

Joseph Roti Roti, PhD, professor of radiology, associate director of the Radiation Oncology Center, and chief of cancer biology, spoke on "Effects of 835.62MHz FMCW and 847.74 MHz CDMA microwaves on mammalian cell proliferation in vitro" at the 5th Michaelson Research Conference, Essex, Montana, August 14 - 17. As invited speaker, he presented "Interactions of RF fields with molecular processes that relate to stress and genotoxic processes" to the U.S. Army Medical Research Detachment, Walter Reed Army Institute of Research, Brooks Air Force Base, Texas, October 1 and 2. As invited speaker, he presented "Thermal effects and oncogenesis" to the UAL Safety and Effects Panel, St. Louis, Missouri, November 21.

Henry Royal, MD, professor of radiology and associate director of the Division of Nuclear Medicine, spoke on "Myocardial perfusion imaging protocols: Which one when?" at the Strategies for Effective Myocardial Perfusion Imaging in Managing Patients with Coronary Artery Disease Symposium, sponsored by Mallinckrodt Institute and Washington University, St. Louis, Missouri, September 19. He pre-

sented "Effects of low level radiation" and "Practical radiation accident management" at the Bethesda Naval Medical Center, Bethesda, Maryland, October 20.

Stuart Sagel, MD, professor of radiology, chief of chest radiology, and codirector of body computed tomography, spoke on "CT of the thorax: anatomic variants and pitfalls" and "CT of the mediastinum" at the 8th Summer Practicum of the Society of Computed Body Tomography and Magnetic Resonance, Olympic Valley, California, August 2 - 6. He presented "CT of the pericardium," "Anatomic variants and pitfalls in thoracic CT," "Helical CT in the thorax," "CT of focal lung lesions," "CT of the mediastinum," and "CT angiography for pulmonary embolism" to the 20th International Congress of Radiology, New Delhi, India, September 19 - 23.

Maria Schmidt, MD, instructor in radiology, presented "Breast care and you" at a community lecture sponsored by Boone Hospital Center in recognition of Breast Cancer Awareness Month, Columbia, Missouri, October 29.

Vijay Sharma, PhD, research assistant professor of radiology, presented "Targeting plasmodium falciparum candidate chloroquine-resistance protein (CG2) with novel metal (III) complexes" at the American Chemical Society Annual Meeting, Boston, Massachusetts, August 23-27.



Probstein lecture

On September 18, Dr. Dattatreya Nori, chairman of the Department of Radiation Oncology at New York Hospital-Cornell Medical Center, presented the Norman K. Probstein Oncology Lecture. Dr. Nori (left) shown with Carlos Perez, MD, director of the MIR Radiation Oncology Center, spoke on "Brachytherapy in localized carcinoma of the prostate." Now in its 12th year, the Probstein Lecture is given annually in recognition of meritorious contributions to oncology.

Barry Siegel, MD, professor of radiology and of medicine and director of the Division of Nuclear Medicine, as symposium moderator, spoke on "Introduction and description of overall program objectives" at the Strategies for Effective Myocardial Perfusion Imaging in Managing Patients with Coronary Artery Disease Symposium, sponsored by Mallinckrodt Institute and Washington University, St. Louis, Missouri, September 19. As invited lecturer, he presented "The emerging role of PET in the management of patients with cancer" at The Fifty-fifth Annual Carman Lecture, sponsored by the Greater St. Louis Society of Radiologists and the St. Louis Metropolitan Medical Society, St. Louis, Missouri, October 20. As invited lecturer, he presented "Applications of PET in management of patients

with cancer" at The 23rd Annual Memorial Lecture, sponsored by the medical and dental staffs of St. Anthony's Medical Center, St. Louis, Missouri, November 10.

Marilyn Siegel, MD, professor of radiology and of pediatrics, presented "Spiral CT of the pediatric chest and abdomen," "Imaging the pediatric kidney," and "CT/MR of the pediatric pelvis" to the Society of Computed Tomography and Magnetic Resonance Imaging, Squaw Creek, California, August 2 - 4. She spoke on "Pediatric spiral CT and techniques," "Spiral CT of the pediatric liver," "Spiral CT of the pediatric retroperitoneum," and "Spiral CT of the pediatric chest" at the Spiral/Helical CT 1998: National Symposium, New York City, New York, September 18 - 20. As visiting

LECTURES/ PRESENTATIONS

Continued from page 23

lecturer, Siegel presented "Ultrasonography/CT of the acute pediatric abdomen" at St. Bartholomew Hospital, London, England, October 1. As visiting professor, she spoke on "Gray-scale and Doppler imaging of the acute pediatric abdomen" at the Oregon Radiologic Society Meeting, Portland, October 28. As visiting professor, Siegel presented "MR imaging of bone marrow," "MR imaging of soft tissue masses," "Spiral CT of the pediatric airway and great vessels," and "Sonography of intracranial hemorrhage and ischemia" at the Oregon Health Sciences University, Portland, October 29 and 30.

Douglas Spitz, PhD, assistant professor of radiology, spoke on "Genomic instability and catalase gene amplification induced by chronic exposure to metabolic oxidative stress" at the William Beaumont Research Institute Radiation Oncology Retreat, Royal Oak, Michigan, September 18 and 19. He presented "Glucose deprivation-induced oxidative stress" at the Oxygen Society Meeting, Washington, DC, November 20. He spoke on "Glucose deprivation-induced oxidative stress in human tumor cells" at the Cleveland Clinic Department of Cell Biology Fall Seminar Series, Cleveland, Ohio, December 11.

Todd Wasserman, MD, professor of radiology, presented "Protectors" at the Combined Radiation/Medical Oncology Conference, New York University Medical Center, New York City, New York, September 9. He presented "Ethyol: a new approach to reducing radiation-induced xerostomia" to the Society of Otorhinolaryngology and Head-Neck Nurses, 22nd Annual Congress, San Antonio, Texas, September 14. He spoke on "Radioprotectors," "The contribution of radiotherapy in the management of Hodgkin's disease," and "The contribution of radiotherapy in the management of non-Hodgkin's lymphomas" at the Third National Radiation Oncology Congress, Turkish Radiation Oncology Society, Istanbul, Turkey, October 11 - 14. Wasserman presented "Radioprotectors" at the New Strategies on Radiation Oncology Symposium, Madrid, Spain, October 16. He presented "Head and neck cancer health services" and the "Symposium Wrap-up Session" at the Cancer Care Quality of Life and Outcomes Symposium, Chicago, Illinois, November 13 and 14.

SYMPOSIA

In this section of FYI, only the names of those faculty and staff who have radiology appointments are listed.

AMERICAN ASSOCIATION OF PHYSICISTS IN MEDICINE

*The 40th Annual Meeting
San Antonio, Texas
August 9 - 13, 1998*

Daniel Low, PhD, cochair, scientific session, "Intensity modulated radiation therapy II."

POSTER PRESENTATIONS

James Dempsey, PhD; Daniel Low, PhD; Assen Kirov, PhD; Jeffrey Williamson, PhD, "Quantitative film dosimetry with scanning laser film digitizers."

Robert Drzymala, PhD; Sasa Mutic, PhD; Eric Klein, MS, "A comparison of imaging techniques for stereotactic localization."

William Harms, BS; Eric Klein, MS; James Purdy, PhD, "Initial angular divergence of electron beams from Varian Clinac C/D machines."

Eric Klein, MS, "Technology assessment of multileaf collimation: a North American users survey."

Eric Klein, MS; William Harms, BS; Sasa Mutic, PhD; James Purdy, PhD, "Dynamic and physical wedge calculations with FOCUS using the Clarkson and FFT convolution algorithms."

John Matthews, DSc; James Purdy, PhD, "Progress in real-time 3D dose planning."

Eduardo Moros, PhD; Xiaobing Fan, research associate; **William Straube, MS; Robert Myerson, PhD, MD**, "Towards three dimensional power deposition control in superficial thermoradiotherapy."

Eric Klein, MS, "Side table transmission for ETR and exact treatment couches."

Jeffrey Williamson, PhD; James Dempsey, PhD; Assen Kirov, PhD, "Plastic scintillator response to low-energy photons."

PROFESSIONAL COUNCIL SYMPOSIUM

Jeffrey Williamson, PhD, "U.S. NRC regulatory change from an ACMUI member's perspective."

REFRESHER COURSES

Eric Klein, MS, "Multileaf collimation: general description, systems and technology assessment."

Jeffrey Williamson, PhD, "Introduction to AAPM Task Group 59 report: high dose-rate brachytherapy treatment delivery."

SCIENTIFIC SESSIONS

Jeffrey Williamson, PhD, "Dosimetric modeling of the microselection high dose rate Ir-192 source by the multigroup discrete ordinates method."

Assen Kirov, PhD; James Dempsey, PhD; Jeffrey Williamson, PhD, "New highly effective water equivalent plastic scintillator materials for radiation dosimetry."

Daniel Low, PhD; Ramesh Venkatesan, research associate; **Sasa Mutic, MS; Mark Haacke, PhD; James Purdy, PhD**, "Evaluation of BANG (TM) gel for intensity modulated dose distribution measurements."

Sasa Mutic, MS; Daniel Low, PhD, "Superficial doses from serial tomotherapy delivery."

James Purdy, PhD; William Harms, BS; Walter Bosch, DSc; Jeff Michalski, MD, "Update on quality assurance of multi-institutional 3D radiotherapy clinical trials."

PRACTICAL ISSUES IN LEADING-EDGE RADIOLOGY III

*Clayton, Missouri
October 23 - 25, 1998*

William Reinus, MD, symposium course director.

SCIENTIFIC SESSIONS

Prem Sri Barton, MD, "Missed breast cancer."

Kyongtae Bae, MD, PhD, "Basic principles of spiral CT and volumetric data display techniques."

Harold Bennett, MD, PhD, "Imaging of RLQ pain," "MR of the pancreas," "CT of abdominal trauma."

DeWitte Cross, MD, "Cerebral atherosclerosis: angiographic assessment and comparison to MRA," "Cerebral aneurysms: angiographic assessment."

Colin Derdeyn, MD, "Carotid imaging."

Robert Feiwell, MD, "Imaging of white matter diseases in adults."

Andrew Fisher, MD, "Imaging of urolithiasis," "Thoracic trauma," "Fractures and their implications."

Mokhtar Gado, MD, "Imaging epilepsy."

Harvey Glazer, MD, "Pitfalls in the radiologic diagnosis of bronchogenic carcinoma."

Robert Gropler, MD, "Risk assessment in patients with CAD," "Added value of myocardial imaging in patients with CAD."

Fernando Gutierrez, MD, "Imaging the trachea," "Vascular abnormalities of the mediastinum."

Jay Heiken, MD, "CT evaluation of the acute nontraumatized abdomen," "Imaging evaluation of small bowel obstruction."

William Middleton, MD, "Ultrasound of advanced gallbladder disease," "Ultrasound of the bile ducts."

William Reinus, MD, "MRI of elbow and ankle."

Douglas Robertson, MD, PhD, "CT of the foot and ankle."

Stuart Sagel, MD, "Nonvascular abnormalities of the mediastinum," "CT of the pleura."

Farid Shafaie, MD, "Spinal MRI," "Imaging of the postoperative spine."

Cary Siegel, MD, "CT/MRI of focal renal masses."

Sharlene Teefey, MD, "Duplex color sonography of the liver."

William Totty, MD, "MRI of marrow."

Pamela Woodard, MD, "Spiral CT for the detection of PE."

THE AMERICAN SOCIETY FOR THERAPEUTIC RADIOLOGY AND ONCOLOGY

*Phoenix, Arizona
October 25 - 29, 1998*

Jeffrey Bradley, MD, ASTRO Research Fellow.

David Diamond, MD, Resident Clinical/Basic Science Award Winner.

James Purdy, PhD, abstract reviewer.

GENERAL SESSION OF SOCIETY FOR RADIATION ONCOLOGY ADMINISTRATORS

Eric Klein, MS, "Multileaf collimation: results from the first AAPM assessment of technology subgroup."

PANELS

Eric Klein, MD, "Outcomes assessment of technology."

James Purdy, PhD, "Conformal radiation approaches to the treatment of early prostate cancer: techniques, outcomes and pitfalls."

POSTER SESSIONS

Walter Bosch, PhD, "An integrated image/clinical database for outcome studies in 3D conformal radiation therapy."

Sasa Mutic, MS, "A reduction in the AAPM TG-36 reported peripheral dose distributions with tertiary multileaf collimation."

Robert Myerson, PhD, MD, "Five fractions of preoperative radiotherapy for selected cases of rectal carcinoma: long term tumor control and tolerance."

Marie Taylor, MD, "The impact of regional lymphatic irradiation on treatment outcomes for T1 and T2 node positive breast cancer patients treated with conservation therapy."

SCIENTIFIC SESSIONS

Jeffrey Bradley, MD, "The use of concomitant radiotherapy and an attenuated herpes simplex-1 virus improves survival in mice with intracranial glioblastoma multiforme tumors."

David Diamond, MD, "Redox factor-1 (ReF-1) mediates the activation of AP-1 in HeLa NIH 3T3 cells in response to heat."

Mary Graham, MD, "Survival and prognostic factors of non-small cell lung cancer (NSCLC) patients treated with definitive three-dimensional (3D) radiation therapy."

Perry Grigsby, MD, "Radiotherapy with or without misoprostol for patients with stages IIIB and IVA carcinoma of the cervix: final results of RTOG 80-05."

Daniel Low, PhD, "Abutment-region dose distribution heterogeneities in serial tomotherapy."

Jeff Michalski, MD, "Preliminary report of toxicity following 3D radiation therapy for prostate cancer on 3DOG/RTOG 9406."

SYMPOSIA

Continued from page 25

MIR-ROC RADIATION AND BIOLOGICAL SCIENCES SYMPOSIUM

The 14th Annual Meeting
St. Louis, Missouri
November 6 - 8, 1998

Andrei Laszlo, PhD; Douglas Spitz, PhD; Joseph Roti Roti, PhD, program committee.

Kathy Bles, Carolyn Crowell, Carla Thurman, local arrangements committee.

SYMPOSIUM I: STRUCTURE AND CONSEQUENCES OF DNA DAMAGE

Yi Wang, graduate research assistant, "Differentiation of isometric photomodified oligodeoxynucleotides by mass spectroscopic methods."

Peng Zhang, MD; William Wright, BS; Joseph Roti Roti, PhD, "Post-irradiation DNA supercoiling and radiosensitivity in XRCC4 transfected XR-1-CHO variant cells."

WORKSHOP I: POST-RADIATION RESPONSES AND CELL DEATH

Fiorenza Ianzini, PhD; Michael Mackey, PhD, "Mitotic catastrophe induced by light ions: kinetics and magnitude. "Reduced induction of mitotic catastrophe in cells with functional p53 exposed to ionizing radiations: implications for genomic instability."

SYMPOSIUM II: MODIFICATIONS OF TISSUE RESPONSES TO RADIATION INJURY

Fiorenza Ianzini, PhD, chairperson.

WORKSHOP II: REDOX-MEDIATED SIGNAL TRANSDUCTION

Douglas Spitz, PhD, chairperson.

Lee Albee, medical research technician; **Prabhat Goswami, PhD**, "Characterization of a redox sensitive 3' untranslated region ribonucleoprotein complex associated with cell-cycle coupled topoisomerase II (mRNA) turnover."

Douglas Spitz, PhD, "Metabolic oxidative stress-induced signal transduction."

David Gius, MD; David Diamond, MD; Heather Curry, MD; Regina Clemens, lab assistant; **Ana Botero, MD; Douglas Spitz, PhD**, "Redox regulation of AP-1 DNA-binding in HeLa and NIH 3T3 cells in response to heat."

SYMPOSIUM III: THE BIOLOGICAL EFFECTS OF RADIO-FREQUENCY RADIATION

Isabelle Lagroye, PhD; Barbara Wettring, medical research technician; **Eduardo Moros, PhD; William Straube, MS; Cheryl Hoff**, surgical assistant; **Joseph Roti Roti, PhD**, "Investigation of DNA damage after *in vitro* and *in vivo* exposure to 2450 MHz microwaves."

Robert Malyapa, MD, PhD; Eric Ahern, medical research technician; **Eduardo Moros, PhD; William Straube, MS; Joseph Roti Roti, PhD**, "Lack of neoplastic transformation in C3H 10T1/2 cells following exposure to cellular phone communication frequencies."

Ryuji Higashikubo, PhD; Victoria Culbreth, scientific coordinator; **Douglas Spitz, PhD; William Straube, MS; Eduardo Moros, PhD; Joseph Roti Roti, PhD**, "Radiofrequency electromagnetic fields have no effect on the *in vivo* proliferation of 9L brain tumor."

Michael Niehoff, research assistant; **Joseph Roti Roti, PhD; Douglas Spitz, PhD; Ryuji Higashikubo, PhD; Eduardo Moros, PhD; Dorrine Cushman**, surgical assistant; **Cheryl Hoff**, surgical assistant, "The effect of chronic exposure to 835.62 MHz FMCW or 847.74 MHz CDMA on the incidence of spontaneous brain and central nervous system tumors."

William Wright, BS; Joseph Roti Roti, PhD, "Computer-assisted analysis of 2D gels."

SYMPOSIUM IV: CELLULAR RESPONSES TO THERMAL STRESS

Ming-Shun Chen, PhD; Andrei Laszlo, PhD; Joseph Roti Roti, PhD, "Identification and characterization of a new member of the Hsp40 family, the Hsc40, in human and mouse cells."

Andrei Laszlo, PhD; Teri Davidson, medical research technician; **Silvia Laszlo**, lab assistant, "Effect of proteasome inhibitors on the localization of Hsp/Hsc70 during recovery from heat shock."

Robert VanderWaal, PhD; Joseph Roti Roti, PhD, "Effects of hyperthermia on the abundance of specific proteins at the nuclear matrix during S-phase and the morphology of DNA replication."

Mai Xu, MD, PhD; Prabhat Goswami, PhD; Joseph Roti Roti, PhD, "Increased expression of certain cell surface proteins in chronic heat-resistant cells."

Heather Curry, MD; Regina Clemens, lab assistant; **Ana Botero, MD; David Gius, MD**, "Heating of HeLa cells prior to radiation inhibits radiation-induced activation of the NF-(B) DNA-binding complex."

WORKSHOP III: UNIFIED (INTEGRATED?) STRESS RESPONSE(S)

Andrei Laszlo, PhD, chairperson.

Hsiu-san Lin, MD, PhD; Theodore D'Rosario, research lab technician, "Adaptation of tumor cells to a high normoxic environment decreases their sensitivity to adriamycin."

Ming-Shun Chen, PhD; William Wright, BS; Andrei Laszlo, PhD; Joseph Roti Roti, PhD, "A multi-stress inducible gene (MSI) encodes multiple proteins (via alternative splicing) which share significant sequence similarity with a yeast cell-cycle checkpoint protein, Rad24."

Douglas Spitz, PhD; Lori Worley, medical research technician; **Julia Sim**, senior medical research technician; **Lisa Ridnour, PhD**, "Glucose deprivation-induced oxidative stress."

RADIOLOGICAL SOCIETY OF NORTH AMERICA

*The 84th Scientific Assembly and Annual Meeting
Chicago, Illinois
November 29 - December 4,
1998*

KEYNOTE ADDRESS

William McAlister, MD, "New horizons in pediatric radiology."

INFORAD PRESENTATIONS

James Blaine, DSc, "An approach to enterprise imaging."

Richard Slone, MD, "JPEG and JPEG 2000: compression for medical images."

INFORAD EXHIBITS

Gregory Reiker, MS; Richard Slone, MD; Pamela Woodard, MD; David Gierada, MD; Stuart Sagel, MD; Gilbert Jost, MD; James Blaine, DSc, "Image processing strategies in picture archiving and communication systems."

Winner of the 1998 RSNA Certificate of Merit Award
Richard Slone, MD; Bruce Whiting, PhD; Edward Muka, MSE, "Demonstration of JPEG and JPEG 2000 compression for medical images."

SCIENTIFIC EXHIBITS

Pamela Woodard, MD; Fernando Gutierrez, MD, "Metastatic involvement of the heart and pericardium."

Anil Khosla, MD, "Craniofacial and appendicular osteomas."

Peter Shile, MD; Thomas Pilgram, PhD, "BI-RADS feature assessments in mammography and their relationship to diagnostic accuracy."

Dmitriy Yablonskiy, PhD; David Gierada, MD, "High-speed dynamic MRI of lung ventilation with hyperpolarized ³He and EPI."

REFRESHER COURSES

Jeffrey Brown, MD, "Practical abdominal MR imaging."

Michael Darcy, MD, "Embolization techniques: a 'how-not-to' workshop."

Louis Gilula, MD, "Imaging of ligaments, capsules, and tendons of wrist and hand;" "Imaging upper-extremity trauma with plain films, CT, and MR."

Jay Heiken, MD, "The acute abdomen: CT evaluation."

David Hovsepian, MD, "Hysterosalpingography and selective salpingography (a 'how-to' workshop)."

William Middleton, MD, "Musculoskeletal US ('hands-on' workshop)," "Practical tips in US—small parts: other musculoskeletal US."

Scott Mirowitz, MD, "Shoulder MR imaging: techniques and interpretation."

David Rubin, MD, "Shoulder injuries."



Scott Lecture

Michael Welch, PhD, professor of radiology and codirector of MIR's Division of Radiological Sciences, was invited lecturer for the Twenty-seventh Annual Wendell G. Scott Memorial Lecture on October 12. Dr. Welch spoke on "Contrast agents in imaging: current status and future prospects."

Stuart Sagel, MD, "Digital chest radiography: techniques and clinical applications."

Cary Siegel, MD, "Advances and controversies in CT and MR of the genitourinary tract."

Marilyn Siegel, MD, "Pediatric spinal CT: challenges of childhood."

William Totty, MD, "Wrist and hand injuries."

Jeffrey Williamson, PhD, "Update course in brachytherapy physics—quality delivery accuracy: quality assurance of brachytherapy treatment delivery and planning devices."

SCIENTIFIC SESSIONS

David Hovsepian, MD; Gregorio Sicard, MD; Brent Allen, MD; Daniel Picus, MD; Eric Malden, MD, "Adjunctive use of metallic stents during placement of bifurcated endoprostheses for abdominal aortic aneurysm repair."

Leo Lawler, MD; Marilyn Siegel, MD, "Characterizing inspiratory and expiratory CT appearance of lung parenchyma in asymptomatic pediatric lung transplant recipients."

Marilyn Siegel, MD, "MR diagnosis of anterior cruciate ligament tears in children."

SYMPOSIA

Continued from page 27

William Middleton, MD; Sharlene Teefey, MD; Christine Menias, MD; John Leahy, MD, "Follow-up of patients at low risk for hepatic malignancy and a characteristic hemangioma on ultrasound."

Louis Gilula, MD; Sean Pierce, MD, "Characteristics of scapholunate ligament communicating defects in symptomatic and asymptomatic wrists."

Elizabeth McFarland, MD; Vamsidhar Narra, MD; Dan Hirselj, BS; Glenn Foster, RT, "Evaluation of the dynamic velopharynx during speech production with magnetic resonance imaging."

Elizabeth McFarland, MD; Bruce Whiting, PhD; Barry Brunsten; Casey Dellabarca, BS, "Spiral CT colography rippling artifact: influence of acquisition parameters on 3D virtual endoscopy images using *in vitro* colon phantom."

Demetri Papadatos, MD, "Pancreas divisum revisited: prevalence in acute and chronic pancreatitis on MR cholangiopancreatography (MRCp)."

Douglas Robertson, MD, PhD; Jie Yuan, PhD, "Providing radiographic outcome data to the surgeons."

Douglas Robertson, MD, PhD; Paul Commean, BEE; Kirk Smith, BEng; Andrew Fisher, MD, "Bone density changes within lumbar interbody fusion cages: Can CT assess interbody fusions?"

David Rubin, MD, "MR imaging of subscapularis tendon tears: prospective accuracy and identification of associated findings to reduce diagnostic errors."

Joshua Shimony, MD, PhD; Erbil Akbudak, PhD; Robert McKinstry, MD; Thomas Cull, PhD; Thomas Conturo, MD, PhD, "Quantitative diffusion anisotropy imaging: normal values, anatomical findings, and results in relapsing remitting multiple sclerosis."

Joshua Shimony, MD, PhD; Erbil Akbudak, PhD; Abraham Snyder, MD, PhD; Thomas Conturo, MD, PhD, "Diffusion imaging of the cervical spinal cord."

Richard Slone, MD; Dan Hendrickson, BS; Sanjeev Bhalla, MD; Andrew Fisher, MD; Scott Kaltman, MD; Pamela Woodard, MD; David Gierada, MD; Thomas Pilgram, PhD; Edward Muka, MSE, "Visually lossless compression of digital chest radiographs."

Sharlene Teefey, MD; William Middleton, MD, "Accuracy of sonography for determining individual tendon movement in patients with full thickness rotator cuff tears."

Sharlene Teefey, MD; William Middleton, MD, "Can sonography differentiate acute from chronic rotator cuff tears?"

Elizabeth McFarland, MD, "GI tract unraveling with curved cross-sections."

Pamela Woodard, MD; Jie Zheng, PhD; Vamsidhar Narra, MD; Mark Haacke, PhD, "Coronary MR angiography with MS-345, an intravascular contrast agent."

Pamela Woodard, MD; Fernando Gutierrez, MD; Marilyn Siegel, MD; Philip Ludbrook, MBBS, "Comparison of HASTE and conventional spin echo MRI techniques for assessment of congenital heart disease."


Dmitriy Yablonskiy, PhD; David Gierada, MD, "High-speed dynamic MRI of lung ventilation with hyperpolarized ³He and EPI."

Yuming Yin, MD; Louis Gilula, MD, "An arthrographic method to determine the precise size and site of scapholunate and lunotriquetral ligament communicating defects."

FOR THE RECORD

On page 17 of the Summer 1998 issue of *Focal Spot* magazine, the listing for Dr. Antoinette Cortese should have read: She completed a one-year internship at the University of Nevada Affiliated Hospitals and a four-year diagnostic radiology residency at the University of Washington.

er
Dr.
ld
ed a
e
ili-
r-
y
ty



A state-of-the-art positron emission tomography (PET) system is up and running in the Institute's seventh-floor PET facility. The \$1.8 million system, known as EXACT HR⁺, will be heavily utilized for clinical brain and whole body PET studies. Duffy Cutler, PhD, assistant professor of radiology, views some of the EXACT-produced images that have higher resolution and extended axial fields.

FOCAL SPOT

MALLINCKRODT INSTITUTE OF RADIOLOGY

Address Service Requested

Send distribution changes or address corrections to
Focal Spot Editor
Mallinckrodt Institute of Radiology
510 South Kingshighway Blvd.
Campus Box 8131
St. Louis, MO 63110
(314) 362-2866

Editor and Writer
Vicki Kunkler

Contributing Writers
Samuel Au, MD, PhD
Kirstin Blase
Bridget McDonald
Candace O'Connor

Photographers
Bob Boston
Thomas Murry
Tim Parker
Pamela Woodard, MD
Michelle Wynn

Design
Purviance & Company
Marketing Communications

Printing
Scholin Brothers
Printing Company

Focal Spot magazine is distributed three times annually. Magazine articles may be reproduced if credit is given to *Focal Spot* magazine of the Mallinckrodt Institute of Radiology at Washington University.

© Mallinckrodt Institute of Radiology, 1998

Non-Profit Organization
U.S. Postage
PAID
St. Louis, Missouri
Permit No. 3309



ARCHIVES
SERIALS DEPT., MEDICAL LIBRARY
WASH. U. SCHOOL OF MEDICINE
CAMPUS BOX 8132