

Fall 1992

Focal Spot, Fall/Winter 1992

Follow this and additional works at: http://digitalcommons.wustl.edu/focal_spot_archives

Recommended Citation

Focal Spot, Fall/Winter 1992, October 1992. Bernard Becker Medical Library Archives. Washington University School of Medicine.

This Book is brought to you for free and open access by the Focal Spot at Digital Commons@Becker. It has been accepted for inclusion in Focal Spot Archives by an authorized administrator of Digital Commons@Becker. For more information, please contact engeszer@wustl.edu.

FALL/WINTER, 1992

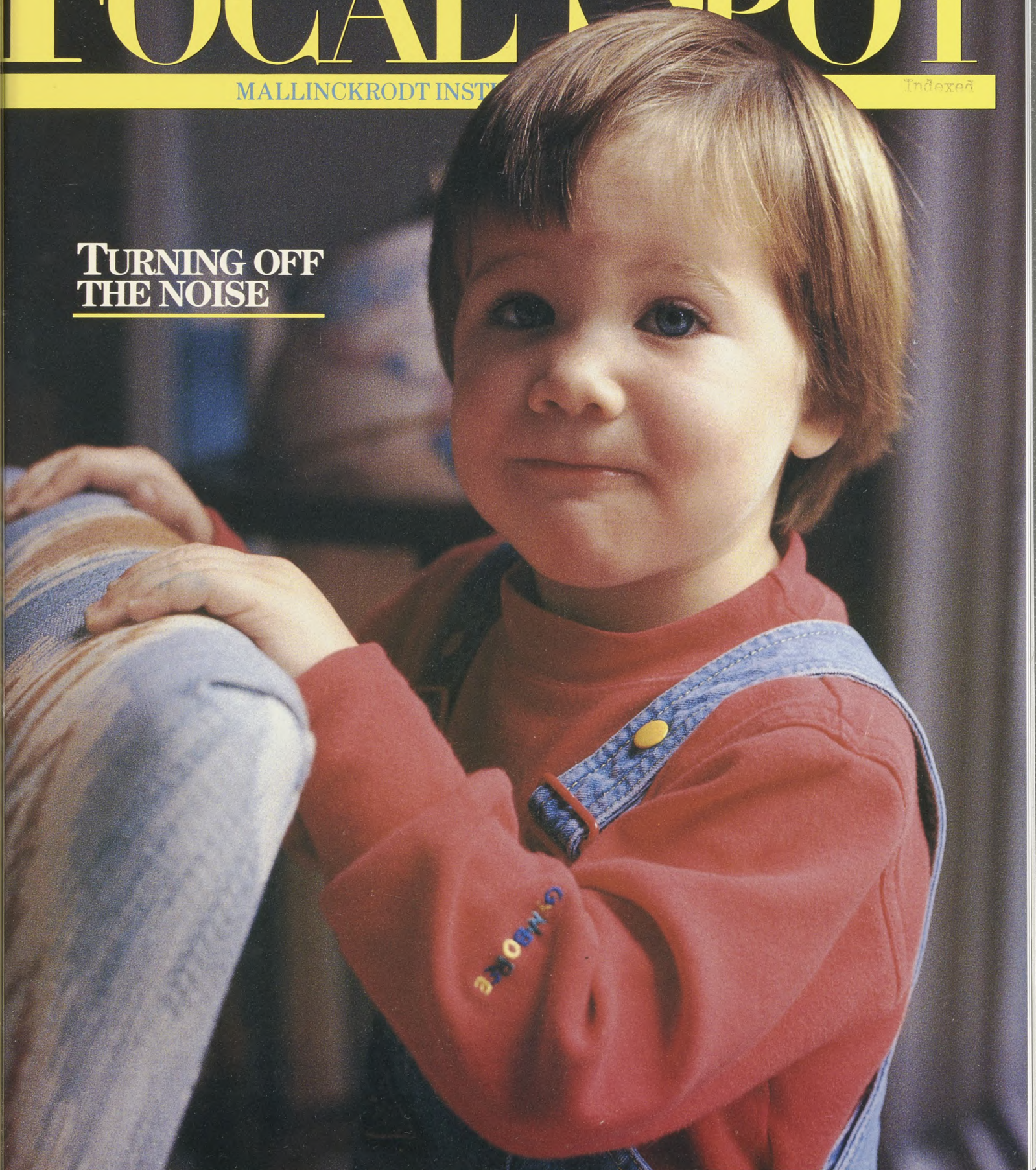
VOLUME 23, NUMBER 3

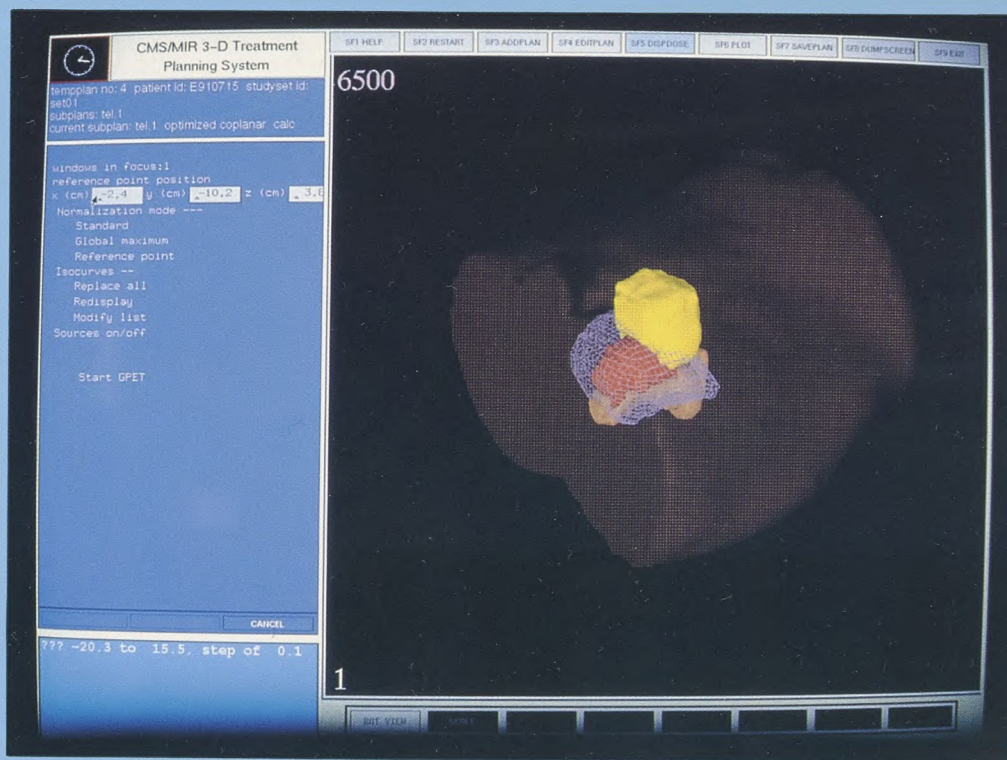
FOCAL SPOT

MALLINCKRODT INSTITUTE

Indexed

TURNING OFF THE NOISE






A revolutionary three-dimensional treatment planning system is providing positive results for prostate cancer patients. As shown by this color-enhanced, computer-generated image, maximum dose delivery (magenta) was directed to the tumor site (red) while the bladder (yellow) and rectum (brown) were spared. The story begins on page 6.

FOCAL SPOT

MALLINCKRODT INSTITUTE OF RADIOLOGY




6 TREATING CANCER

Three-dimensional radiation therapy may soon become the cancer treatment of choice. As part of a collaborative effort funded by the National Cancer Institute, investigators at MIR were instrumental in the development of a treatment planning program with the potential for improved survival rates and a better quality of life for cancer patients.




12 TURNING OFF THE NOISE

As an infant, Kevin Crocker was diagnosed with a neurological problem. A rapid flow of blood in the occipital artery had created a loud noise in the child's head. At Mallinckrodt Institute, neurointerventional radiologists embolized the artery and eliminated the noise.



18 CHECKS AND BALANCES

Effective cancer treatment depends upon accurate delivery of the radiation therapy dose to the tumor. That accuracy can be affected by something as simple, and as uncontrollable, as the patient's normal breathing pattern during treatment. Using on-line imaging technology, researchers at Mallinckrodt Institute are investigating better methods for estimating variations in dose delivery.



2 SPOT NEWS

23 FYI

32 SPOTLIGHT

MIR

MALLINCKRODT

INSTITUTE OF RADIOLOGY

WASHINGTON UNIVERSITY

MEDICAL CENTER

ON THE COVER:

Two-year-old Kevin Crocker is one of the many patients benefitting from the expertise of the region's only trained neurointerventional radiology team.

SPOT NEWS

Winning the Gold

On November 10, the American Society for Therapeutic Radiology and Oncology (ASTRO) presented the prestigious Gold Medal award to Carlos A. Perez, M.D., professor of radiology and director of the Radiation Oncology Center, for his outstanding contributions to the specialty of radiation oncology. Perez, one of two recipients, received the award at the Society's 34th Annual Meeting in San Diego.

ASTRO, established in 1958, is the largest society of radiation oncologists in the world. The first Gold Medal was presented in 1977 to highlight the achievements made by ASTRO members in the field of radiation oncology.


In a medical career that spans three decades, Perez has made valuable contributions to the field of radiotherapy through clinical research, analysis and publication of that research, lectures, and involvement in radiotherapy-related organizations. A past president of ASTRO (1981-1982), Perez now serves as a trustee of the American Board of Radiology and as a member of the National Board of the American Cancer Society. He is a prolific author, with more than 270 papers and book chapters to his credit. Now in its second edition, *Principles and Practice of Radiation Oncology*, which Perez co-edited with Luther W. Brady, M.D., the

1987 ASTRO Gold Medal recipient who is professor and chairman of the Department of Radiation Oncology at Hahnemann University in Philadelphia, is considered the definitive work on radiation therapy.

In 1960, when Perez was entering into his first year of residency at Mallinckrodt Institute of Radiology, there were only 25 residents in the U.S. who were training exclusively in radiotherapy. By 1972, aided by programs funded by the American Cancer Society and the National Cancer Institute and expanded by the National Advisory Cancer Council, that number had grown to more than 250 radiotherapy trainees.

Perez earned his undergraduate and medical degrees in his native Colombia, South America, where he also completed a one-year residency in radiology. Following a three-year residency in radiology at the Institute, Perez began a fellowship in radiotherapy at M.D. Anderson Hospital and Tumor Institute in Houston. He returned to Mallinckrodt Institute in 1964 as an instructor in radiology. In 1966, Perez initiated a program for the specific training of radiation therapy technologists — a program that is recognized nationally for its standard of excellence.

Perez was named a professor of radiology in 1972 and, in 1976, assumed the directorship of the Radiation Oncology Center. Under his leadership, the Center has evolved into one of the leading radiation therapy centers worldwide. The St. Louis area's first three-dimensional treatment planning center for cancer opened in July of this year, and the hyperthermia research and treatment center is considered one of the



most innovative in the country. The Center's division into four sections (clinical, physics, cancer biology, and information systems) promotes a solid interaction among all areas of the radiation therapy program.

Under Perez's organization, the Radiation Oncology Center has a strong research core, a result of the combined efforts of scientists in the cancer biology and physics sections interacting with the clinical staff. This research has resulted in significant contributions to cancer treatment, amplifying the effects of radiation with chemotherapy and hyperthermia.

One of Perez's more visible accomplishments is the Cancer Information Center (CIC), which was founded in 1977 because he firmly believed that patients would respond better to treatment if they were well informed. The CIC was the first of its kind in the United States,

offering medical information and resources as well as emotional support to its more than 10,000 visitors annually, and has served as a model for similar centers both in the United States and abroad. Now in its 15th year, the CIC is cosponsored by Barnes and Barnard hospitals and supported by the MIR Radiation Oncology Center.

Perez's strong advocacy of the human aspect of medicine, of providing the Center's patients with a genuine sense of caring and understanding of their psychological and emotional needs, has been at the forefront of his efforts: "I frequently say to our residents that meaningful communication with our patients (an exchange of thoughts and feelings, but especially listening) and touching them as if we were transferring our energy to promote their healing will go a long way toward helping the patients feel better and alleviating their anxieties."

SPOT NEWS

Two MIR Researchers Named ACR Fellows

Selected for their outstanding contributions to the field of radiology, Daniel K. Kido, M.D., professor of radiology and chief of neuroradiology, and Mokhtar H. Gado, professor of radiology, were named as fellows of the American College of Radiology (ACR) at the annual meeting September 12 - 16 in Phoenix.

The ACR is the principal radiological organization serving some 28,000 radiologists, radiation oncologists, and radiological physicists nationwide. ACR fellowships are based on the following criteria: significant scientific or clinical research in the field of radiology, or significant radiological literary contributions; performance of outstanding service as a teacher of radiology; service to organized medicine; and an outstanding reputation among colleagues and the local community.

Gado, a renowned neuroradiologist, is recognized for his extensive research in the radiological manifestations of Alzheimer's disease and brain changes in the elderly, and in the correlation of physical principles of magnetic resonance to the pathologic changes in the disease processes of the central nervous system. Gado joined the MIR faculty in 1970 and was appointed chief of the neuroradiology section in 1972. He relin-

quished his administrative duties in 1991 to devote his full time to research and teaching and to the enhancement of the Institute's neuro-radiology training program.

Kido, a former director of neuroradiology at the University of Rochester Medical Center and of the New York State Magnetic Resonance Imaging Demonstration Project, joined the MIR faculty in March of 1991. He has focused his research on two main areas: the clinical value of magnetic resonance imaging as an alternative to invasive angiographic procedures in the diagnosis of carotid stenosis, and the role of imaging in the diagnosis of dementia and depression in the elderly, of multiple sclerosis, and of low-back pain.

Siemens Funds Nuclear Medicine Research

As co-principal investigators, Tom R. Miller, M.D., Ph.D., professor of radiology, and Jerold W. Wallis, M.D., assistant professor of radiology, received a three-year grant of \$50,000 per year from Siemens Gamma-sonics to further their study of attenuation correction in tomographic cardiac perfusion imaging.

According to Miller, in nuclear medicine, thallium cardiac imaging is an important tool for diagnosing coronary artery disease. However, these scans may contain artifacts that can

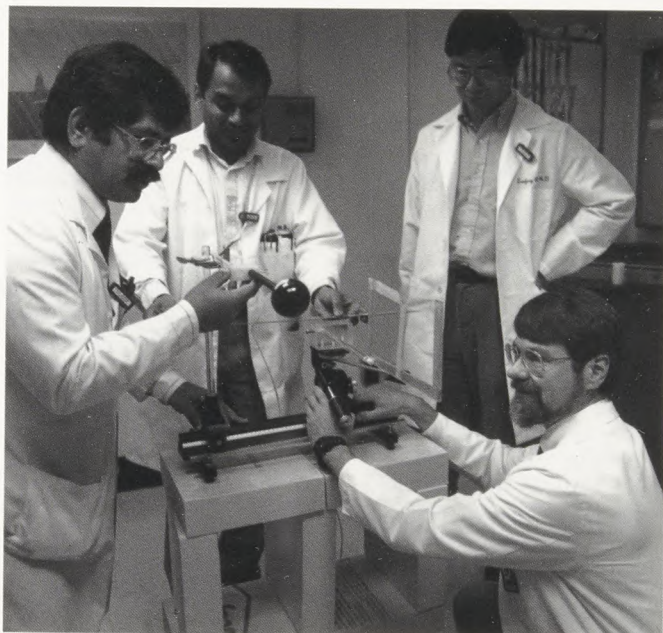
make a normal study appear abnormal. This is a common problem in cardiac perfusion imaging because of the attenuation in the chest as radiation comes from the heart. The deeper walls of the heart may appear to have reduced blood flow although flow actually is normal.

Wallis compared this attenuation problem to the distorted image received when looking at an object deep into the water: the deeper the object is into the water, the fainter it appears because of the decreased availability of light. By investigating computer methods that modify data received from the scans, Miller and Wallis hope to correct or to reduce the attenuation problem.



Residents, fellows, and trainees for 1991-1992 were (front row, left to right) Doctors Robert M. Smith, II; Jonathan C. White; O. Clark West; R. Gilbert Jost, chief, Division of Diagnostic Radiology; Dixie J. Anderson, residency program coordinator; Scott M. Baker; Edith H. Kang, chief resident; Ronald G. Evens, director of the Institute; William G. Horstman, cochief resident; Allen B. Oser; Dennis M. Balfe, residency program coordinator; Mark D. Mayhle; Clinton M. Anderson; Andrew B. Landes; Jeffrey L. Borders; (middle row, left to right) Rosalie J. Hagge; James R. Duncan; Tracy L. Roberts; Colin P. Derdeyn; Rachel Fineberg Oser; Valerie C. Reichert; Kavita K. Erickson; Kevin W. McEnery; Michael C. Roarke; Cynthia K. Rigsby; L. Santiago Medina; John A. Freeby; William B. Mehard; Jamie T. Surratt; M. Gena Frederick; Daniel F. Broderick; Howard P. Forman; (back row, left to right) Francis J. Schlueter; Kurt R. Simpson; John A. Stahl; Robert Y. Kanterman; Paul S. Hsieh; Nitin K. Tanna; Thomas H. R. Farmer; Warren S. Lun; Constance M. Stone Courtois; Spencer M. Smith; Mitchell A. Miller; Gary D. Luker; Sean M. Muldowney; Maria E. Schmidt; Dale P. Harris; Marc G. Koenig.

SPOT NEWS



NCI Awards Grant for Brachytherapy Dosimetry Study

The National Cancer Institute (NCI) presented the James A. Shannon Director's Award of \$100,000 to Jeffrey F. Williamson, Ph.D., chief of the brachytherapy physics group in MIR's radiation physics section. The two-year research grant is earmarked for the study of dose distribution variations resulting from differences in density and composition of tissues treated with brachytherapy. This type of radiotherapy uses sealed, radioactive isotopes to treat the targeted tissue. According to Williamson, dosimetry (the methods used to determine radiation dose distribution, amount, and rate) has not progressed proportionately with the advances made in brachytherapy treatment.

Williamson and coinvestigators Ali Soleimani-Meigooni, Ph.D.; Perry W. Grigsby, M.D.; Zuofeng Li, D.Sc.; and Vivek Mishra, Ph.D., have set specific goals

Using devices, such as this free-air calibration instrument for measuring radiation dose intensity, Mallinckrodt Institute physicists (left to right) Ali Soleimani-Meigooni, Ph.D.; Vivek Mishra, Ph.D.; Zuofeng Li, D.Sc.; and Jeffrey Williamson, Ph.D., are investigating more precise methods for calculating brachytherapy dose distributions.

for the brachytherapy project: develop a complex numerical calculation, called Monte Carlo simulation, to predict dose distribution; investigate the effects of different tissue compositions (heterogeneity) on the dose delivery; develop better dose calculation algorithms; and, by late 1993, establish a clinical study involving 40 patients with breast, gynecological, head and neck, and brain cancers. As part of a collaborative effort for the clinical study, Siemens Medical Systems will provide a dual energy scanning package used with the radiation computed tomography simulator to identify the composition, density, and geometry of different tissues.

First Annual Tolmach Lecture Established

Leonard J. Tolmach, Ph.D., professor emeritus of radiation biology in radiology, who was renowned for his work in radiation research, died on November 26, 1991. Through the combined efforts of Carlos A. Perez, M.D., director of the Radiation Oncology Center, and Joseph L. Roti Roti, Ph.D., professor of radiology, associate director of the Radiation Oncology Center, and chief of the cancer biology section, the Leonard J. Tolmach Lecture was established in honor of the life and work of this revered colleague.

The English essayist William Hazlitt wrote, "No really great man ever thought himself so." And that was especially true of Professor Tolmach. Tolmach's statement made during a 1987 interview revealed the essence of the man, "I'm just an average, hardworking scientist; every university's full of them."

Leonard Tolmach was not an average scientist, a fact confirmed by his fellow researchers and friends. Tolmach earned not only the respect of his colleagues but some of the nation's highest honors in radiation research. His role in the development of the mitotic collection method for obtaining synchronous populations of mammalian cells provided the basis for future breakthroughs in studies on irradiated cell survival and cellular repair.

Hywel Madoc-Jones, M.D., former MIR faculty member and a long-time friend and colleague of Tolmach's, traveled to St. Louis as guest speaker for the First Annual Leonard J. Tolmach Lecture on November 20, presented in conjunction with the November 21 - 22 Annual Midwestern Regional Radiation Research Meeting. Madoc-Jones is radiotherapist-in-chief and professor and chairman of the Department of Radiation Oncology at Tufts-New England Medical Center.

Siegel Appointed to County Commission

As part of the U.S. Department of Energy's (DOE) environmental review of contaminated sites in the St. Louis area, Barry A. Siegel, M.D., director of the Division of Nuclear Medicine, was appointed to the St. Louis County Radioactive and Hazardous Waste Oversight Commission. Area technical and public health professionals are working with DOE representatives to assess issues concerning four St. Louis sites that were contaminated during the infant years of the nation's atomic energy program.

In the 1940s and '50s, a local commercial firm was

SPOT NEWS



(left to right) Ronald G. Evens, M.D.; Marcus E. Raichle, M.D.; and Mrs. Wendell G. Scott

employed to process and produce various forms of uranium compounds and pure uranium metal. Contamination from naturally occurring radioactive materials affected the plant's downtown site and residue storage areas north of the airport. Decontamination efforts carried out according to the standards of more than 30 years ago are unacceptable by today's more stringent federal guidelines.

Under the provisions of the Comprehensive Environmental Response, Compensation, and Liability Act and the National Environmental Policy Act, the DOE conducted a feasibility study of the area's contaminated sites, which will be used in recommendations for cleanup of the St. Louis properties. The Oversight Committee will be instrumental in the decisions affecting that cleanup.

Scott Lecture Provides A Glimpse into Mysteries of the Brain

Marcus E. Raichle, M.D., a pioneer in the field of cerebral blood flow and metabolism, presented "Decade of the Brain 1990-2000: Importance of Brain Imaging Techniques in Understanding the Relationship Between the Human Brain and Behavior" at the Twenty-first Annual Wendell G. Scott Memorial Lecture on October 5. Raichle, professor of radiology and neurology at Mallinckrodt Institute and a recently elected member of the prestigious Institute of Medicine of the National Academy of Sciences, was one of the first researchers to use positron-emitting cyclotron-produced radionuclides to study human and other primate brains.

According to Raichle, modern imaging techniques play a significant role in relating human behavior to

brain function: Computed tomography (CT), a provider of anatomical information, was a key in the development of modern brain imaging techniques. Magnetic resonance imaging (MRI) has already played a major role in the structural imaging of the nervous system, and positron emission tomography (PET), developed at the Institute in the 1970s, led the way for functional mapping of the areas of the brain used in daily tasks, such as seeing, hearing, and speaking.

In discussing the flexible, modular organization of the brain, Raichle pointed out that human behavior, including emotion, is realized in multiple, spatially distributed modules or ensembles of neurons. Although there are significant individual differences, there also are many similarities in the modular organization of all human brains. He compared this organization to a symphony orchestra that is made up of many separate parts that work harmoniously with each other.


An understanding of normal brain organization is essential to comprehending the behavioral effects of disease. Although PET provides valuable information, Raichle foresees that studies of the brain will increasingly involve MRI as a viable solution to problems associated with PET and the use of ionizing radiation.

Update on Breast Cancer

A positron emission tomography (PET) scan technique, developed by a team of scientists led by Michael J. Welch, Ph.D., director of the Division of Radiation Sciences, is capable of detecting whether breast cancer cells contain estrogen receptors. The research was highlighted in *Vogue* magazine's report in October on new discoveries in the prevention, diagnosis, and treatment of breast cancer.

Estrogen-receptive breast cancer tumors account for more than two-thirds of breast tumors in postmenopausal women; in premenopausal women, one-third to one-half. Using a radioactive substance (radiolabeled estradiol) that adheres to estrogen receptors, PET scans are able to detect concentrations of estrogen receptors and, in turn, produce an image of the cancer. In the treatment of breast cancer, Welch says that PET scans can identify those women who would respond to anti-estrogen drugs that retard the growth of breast cancer cells. PET images also could verify the treatment's success or failure.

BRITISH MUSEUM





TREATING CANCER

by Vicki Kunkler

THREE-DIMENSIONAL RADIATION THERAPY, ONCE THOUGHT OF AS CANCER TREATMENT OF THE FUTURE, IS NOW BEING PERFECTED AT MIR.

Almost a decade ago, investigators at the National Cancer Institute (NCI) outlined a research program for delivering high-energy radiation safely and more precisely to the tumor site while sparing normal tissue nearby. The goal: create a system that could rapidly integrate into a three-dimensional image the 60 to 80 computed tomography (CT) scans used to plan target volume. The task: develop the software and hardware for planning and delivering the radiation therapy.

Mallinckrodt Institute of Radiology was one of six institutions nationwide involved in the NCI-funded research contracts for the evaluation of 3-D radiation treatment planning. Under the direction of James A. Purdy, Ph.D., MIR's principal investigator, information gained from previous MIR research is now in the formulation stage and will be tailored for use at the community-hospital level.

Bahman Emami, M.D., clinical director of MIR's 3-D program, is enthusiastic about the positive results of clinical trials on 3-D conformal radiotherapy. If the program is successful, thousands of cancer patients may profit from a higher cure rate with a better quality of life.



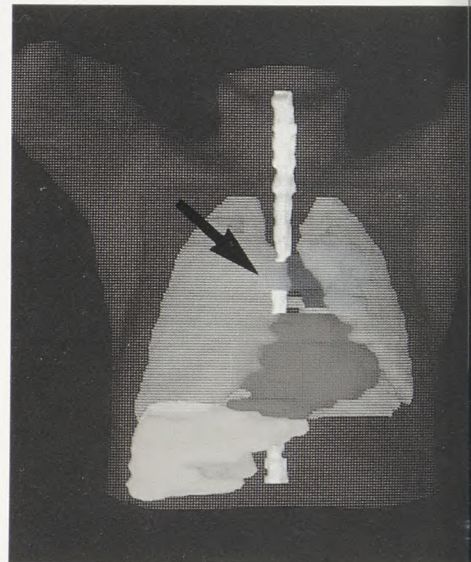
TREATING CANCER

In July of 1991, MIR's Radiation Oncology Center opened the St. Louis area's first three-dimensional treatment planning center for cancer. Using an existing CT scanner equipped with a special laser marking system and connected to a 3-D treatment planning computer, Emami and a team of clinicians and physicists targeted a select group of hard-to-treat cancer sites for evaluating the treatment program. Initial studies involved head and neck, lung, prostate, and pediatric cancers.

"In reality, the implementation of this technology will be in three phases," says Emami. "First, maintain the dose to the tumor but lower it to normal tissue; second, keep the complication rate at routine levels but increase dose to the tumor; and, third, increase the dose to the tumor and lower it to normal tissue, thus lowering the complication rate."

"So far, we have successfully accomplished phases one and two and, in limited cases, phase three," adds Emami. "We have the technology to perform the task, but we need more studies to establish large-scale clinical results."

*For the first time,
radiation oncologists
can objectively
determine the target
volume to the
specific tumor site.*



Above: Using the 3-D treatment planning tools, therapy was specifically tailored for this lung cancer patient. Shown is a front-to-back image of the tumor (arrow) and the surrounding structures (lung, heart, liver, and spinal cord).

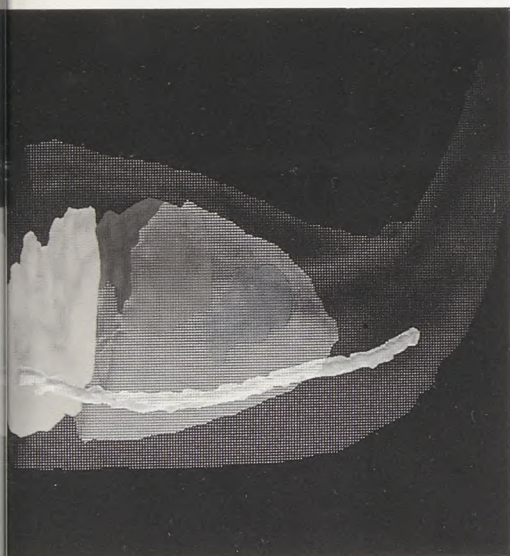
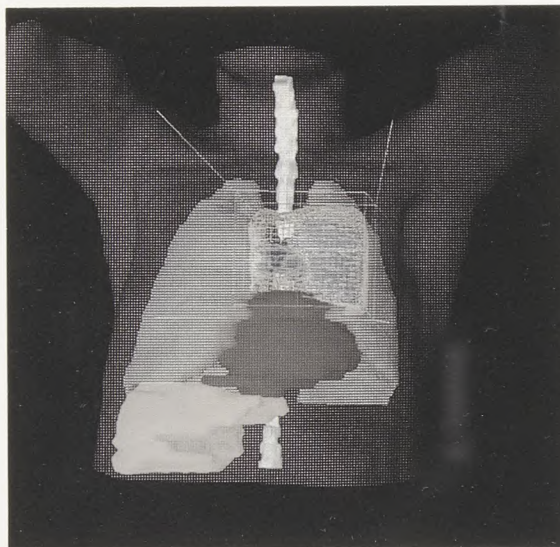
For the first time, radiation oncologists will have the capability to objectively determine the target volume or dose of radiation to the specific tumor site. An added plus is improved dose delivery, closely conforming the dose of radiation to the area of the tumor — an impossibility with conventional two-dimensional treatment.

"Routinely, we had to irradiate a boxed-in field, including any volume that fell into that space," explains Emami. "We could target only from front-to-back or side-to-side, irradiating the entire area. With three-dimensional therapy, we can target from different angles, specifically tailoring the radiation beam to the individual tumor site but missing the surrounding structures."

Emami cites a particular case of a male patient who had a tumor in the head-and-neck area. With conventional radiotherapy, the

Right: Novel (non-coplanar) beam arrangements deliver higher doses to the tumor while sparing the surrounding organs.

Below: A lateral view of the same area provides additional information for determining the volume of the tumor to be treated.



glands that produce saliva are in the irradiation field and receive the same or nearly the same dose as does the tumor site. Nearly 90 percent of patients consequently develop severe, and sometimes troubling, xerostomia or dry mouth, which can cause medical problems with teeth, gums, jaws, swallowing, and speech. In severe cases, patients may have to carry a water bottle to produce moisture in the mouth, chew a special saliva-producing gum, or use an artificial saliva.

Using 3-D therapy, close to 70 percent of the patient's saliva-producing glands can be spared the high dose of radiation....

Using 3-D therapy, close to 70 percent of the patient's saliva-producing glands can be spared the high dose of radiation, by identifying normal tissue with CT scans and then conforming the target site to the tumor. "The results were especially gratifying in this case," says Emami. "The patient is a professional musician. He plays the trumpet, and without a normal flow of saliva, he would have been out of a job."

The results have been equally promising in prostate cancer patients. A study involving 10 patients showed consistent improvement by lowering radiation doses to the bladder and the rectum while maintaining excellent target volume coverage.

Pediatric patients also have responded well to the new technology. For example, a young child with a sarcoma on the side of his face and neck could not have been treated safely with conventional radiotherapy. The possibility of irradiating the child's eye or brain or of missing the tumor site while trying to avoid hitting the other areas would have been too risky. However, the treatment was a success with the conformal capabilities of the 3-D program.

But, Emami explains, the technology is not perfect; there are some disadvantages. The process is time-consuming and labor intensive. Conventional radiotherapy techniques require around two to three hours to implement therapy for a new patient. Three-dimensional treatment planning involves more than simply punching in a formula on a computer. A little more than a year ago, the process involved approximately four days, from the patient's first-day consultation to the start of the first treatment. Now the refinement process has reduced the time to roughly five or six hours, with the goal of even further time reduction.



TREATING CANCER

“Of course, the more experience we have with the process, the less time it should take to implement,” says Emami. “One of the tools to be developed by Doctor Purdy and his team is the delineation of the volume, irradiating a little faster with better concentration. We’re working on it.”

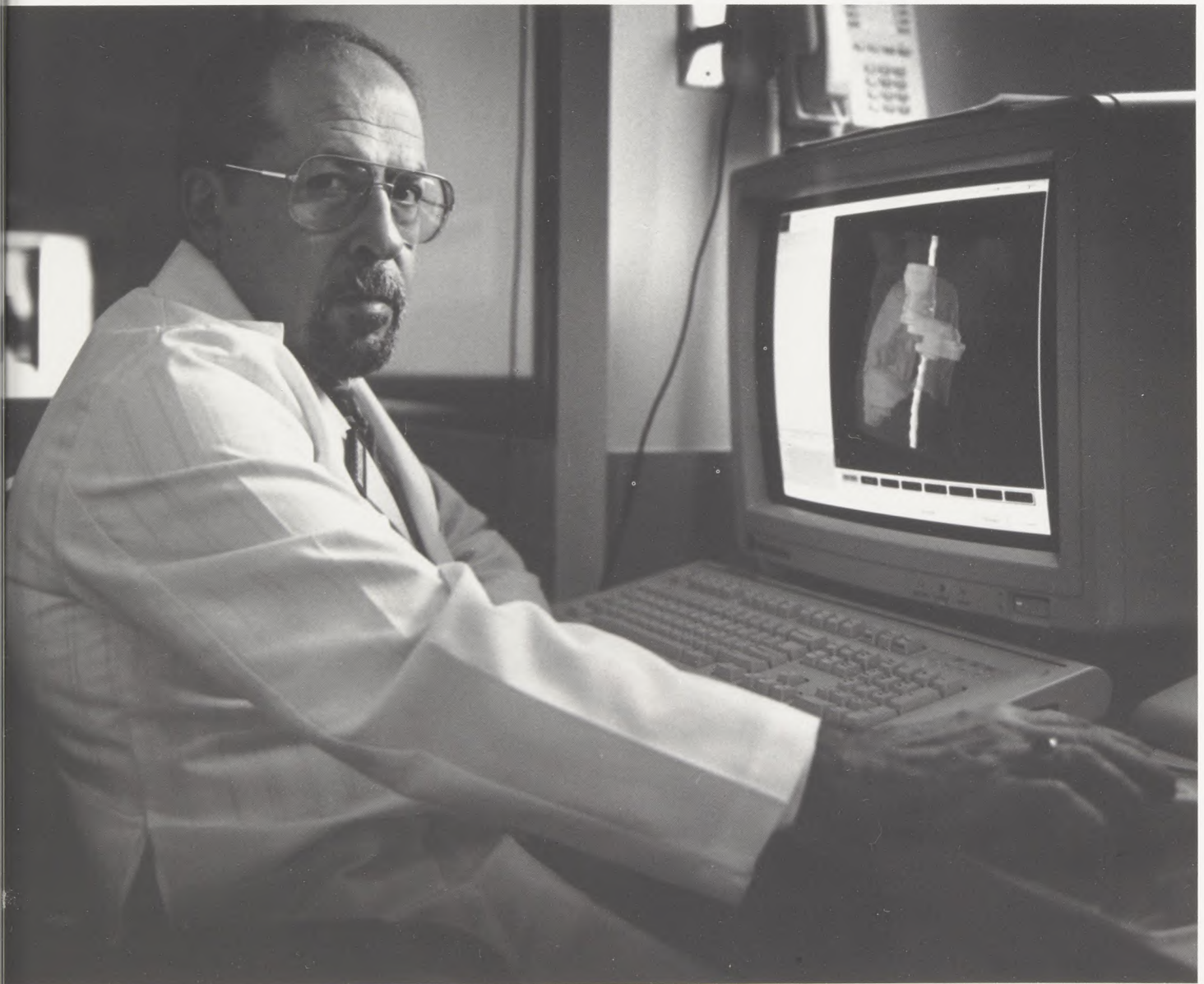
The technology is costly and, with the additional hours and manpower involved, the expense can be a drawback. But, according to Carlos A. Perez, M.D., director of the Radiation Oncology Center, “The upfront investment is well worth the cost when compared with the potential for improved survival and quality of life for our

patients, not to mention the improved quality of life for the patients’ families. With conventional treatment techniques, the cost of treating a patient who fails is three times that of a patient who is cured.”

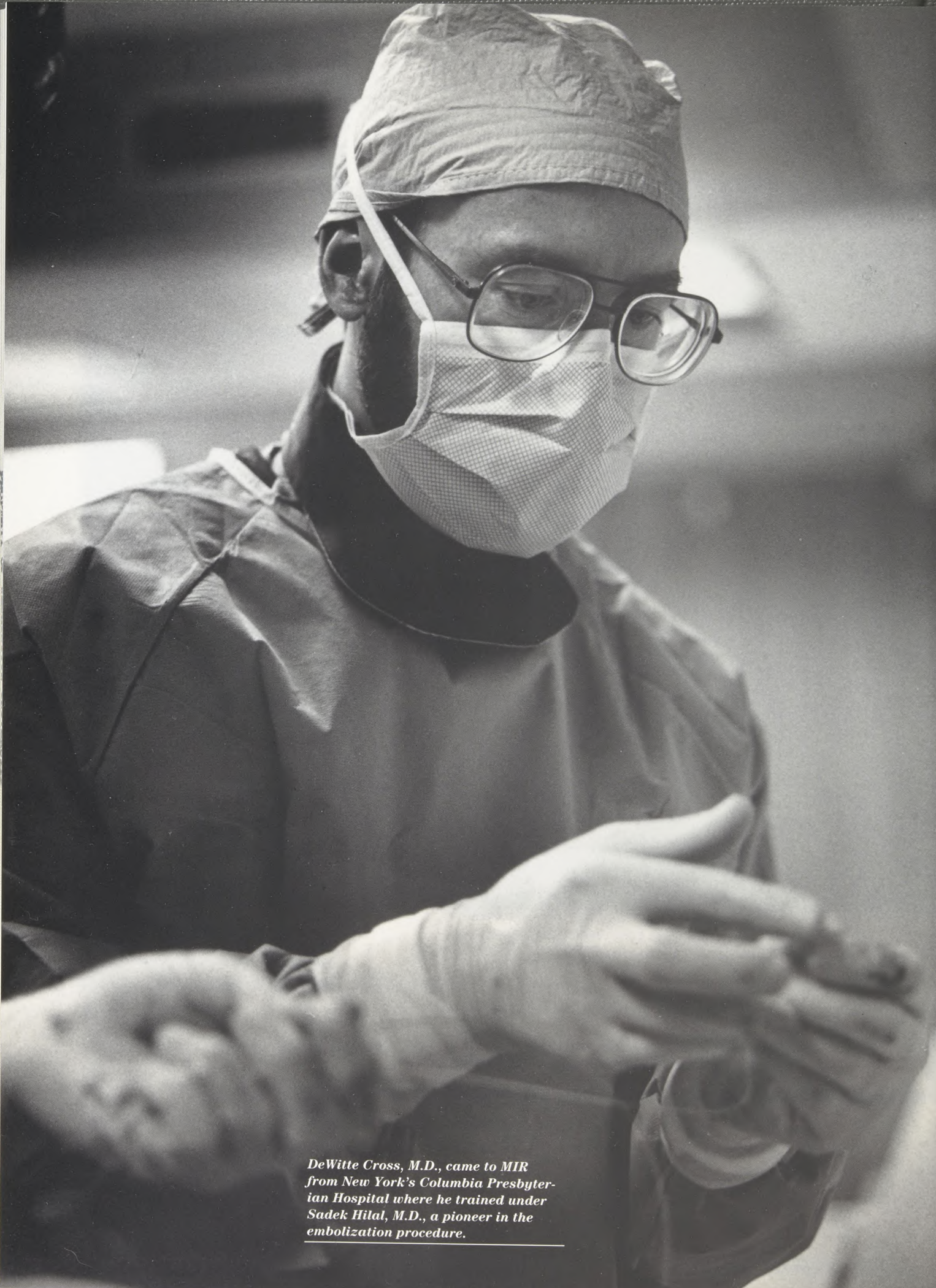The next step for 3-D treatment planning: additional refinement of the techniques used for pediatric, lung, head and neck, and prostate cancer patients. Using those proven techniques, more patients can then be treated, establishing better clinical results for use in streamlining the process. In the meantime, Emami and his colleagues will develop techniques for four additional cancer groups — breast, brain, bowel, and liver. □

PROCEDURES FOR THREE-DIMENSIONAL TREATMENT PLANNING AND DELIVERY

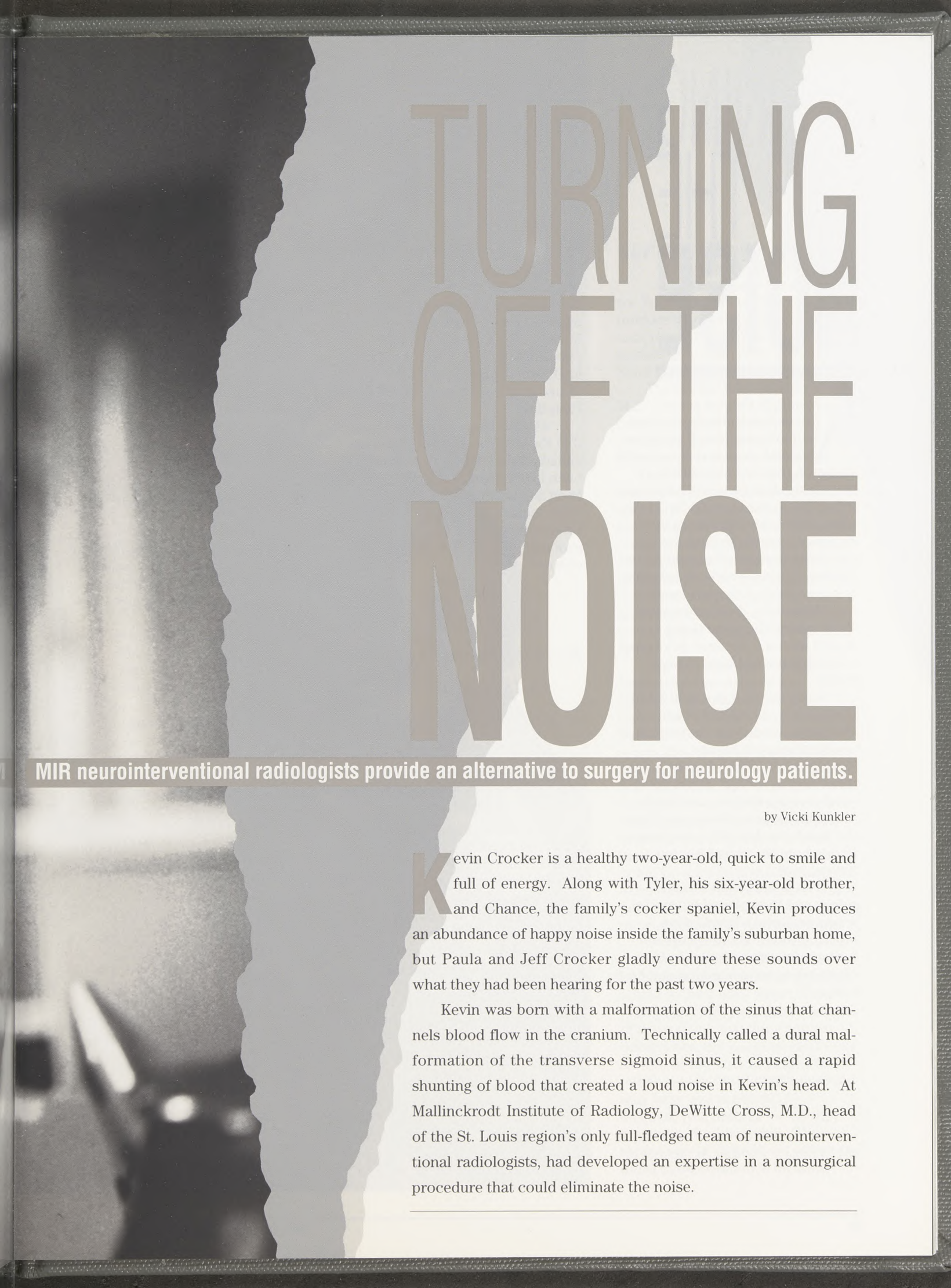
Preplanning and Localization	Position patient in proposed treatment position Fabricate immobilization devices Fiducial marks on patient’s skin Obtain localization radiographs
CT Imaging Study	Volumetric CT scan series of patient in treatment position
Delineate Planning Volumes	Load CT images in Radiation Therapy Program system Define tumor and target volumes as well as critical structures
Treatment Planning	Generate plans; optimization and evaluation Design of the beam arrangement, using the beam’s eye view display (the observer’s viewing point at the source of radiation, looking out along the axis of the radiation beam)
Plan Verification on Simulator	Verify patient position Obtain films of treatment fields
Treatment Verification	Initial verification of plan on treatment machine Periodic verification checks during treatment



Bahman Emami, M.D.: "The bottom-line for three-dimensional treatment planning is to control the tumor and lower the complication rate."



DeWitte Cross, M.D., came to MIR from New York's Columbia Presbyterian Hospital where he trained under Sadek Hilal, M.D., a pioneer in the embolization procedure.



TURNING OFF THE NOISE

MIR neurointerventional radiologists provide an alternative to surgery for neurology patients.

by Vicki Kunkler

Kevin Crocker is a healthy two-year-old, quick to smile and full of energy. Along with Tyler, his six-year-old brother, and Chance, the family's cocker spaniel, Kevin produces an abundance of happy noise inside the family's suburban home, but Paula and Jeff Crocker gladly endure these sounds over what they had been hearing for the past two years.

Kevin was born with a malformation of the sinus that channels blood flow in the cranium. Technically called a dural malformation of the transverse sigmoid sinus, it caused a rapid shunting of blood that created a loud noise in Kevin's head. At Mallinckrodt Institute of Radiology, DeWitte Cross, M.D., head of the St. Louis region's only full-fledged team of neurointerventional radiologists, had developed an expertise in a nonsurgical procedure that could eliminate the noise.

TURNING OFF THE NOISE

According to Paula, she had an uncomplicated pregnancy and an easy delivery with Kevin. As she held her newborn son for the first time, with his head in her hand, Paula could feel a rippling of the skin, similar to the ridges of a comb, behind Kevin's ear. With her thumb placed on the ripples, Paula also felt an extremely heavy pulse in Kevin's head.

"Although I didn't remember Tyler having the same thing, I wasn't alarmed because Kevin was a healthy, normal baby," says Paula.

Given the thumbs-up at all of his regular scheduled newborn checkups, Kevin was developing at a normal rate for his age. In November of 1990, when he was three months of age, Kevin developed an ear infection and Paula took him to the pediatrician. During that Saturday office visit, she pointed out the ridges behind Kevin's ear.

"The pediatrician felt the ridges and then placed his stethoscope on Kevin's head," says Paula. "And that's when the doctor heard a noise, similar to the churning sound a washing machine makes."

Paula discovered that, without a stethoscope, she could hear the noise as she cuddled her son, placing his head against hers. On the following Monday, the Crockers had an appointment with Ruthmary Deuel, M.D., a neurologist and professor of pediatrics at St. Louis Children's Hospital.

"Doctor Deuel explained to us that the noise in Kevin's head was called a bruit. If the noise had been in his heart, it would have been a heart murmur," adds Jeff. "She decided to perform a series of tests to help diagnose Kevin's problem; nothing was left to chance."

*... heard a noise in
Kevin's head, similar
to the churning
sound a washing
machine makes.*

Over the next month, Kevin underwent radiological procedures to determine the cause of his problem: an angiogram, an X ray of the blood vessels; a computed tomography (CT) scan, which can differentiate a few soft tissues, such as tendon, muscle, and fluid; and a magnetic resonance imaging (MRI) scan, which distinguishes types of soft tissue even further — muscle, tendon, ligament, articular and fibroid cartilage, fluid, fat, blood, and flowing blood, in addition to bone.

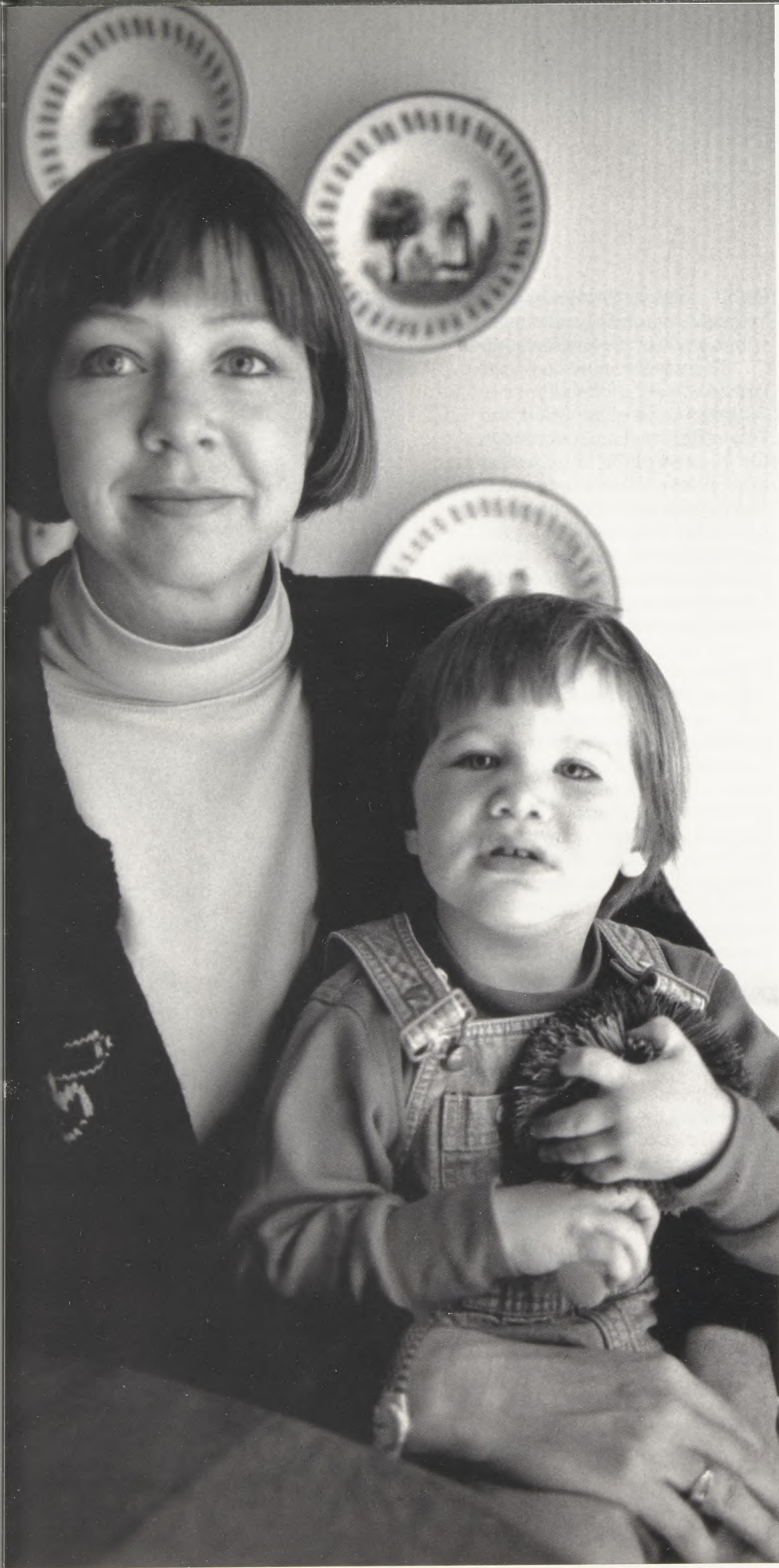Deuel then brought in Bruce Kaufman, M.D., a pediatric neurosurgeon and assistant professor of neurological surgery at Children's Hospital. The risk of surgery was great because of Kevin's age and physical size, and there was no guarantee of success. Kaufman decided against immediate surgery, opting to closely monitor Kevin and to look for other alternatives.

"Doctor Kaufman didn't make any snap judgments about Kevin; I liked that. He told us that Kevin's problem was very serious, that correcting it might take a long time. He said to take our son home and treat him like a normal baby," says Jeff.

"Doctor Kaufman said the best case scenario was with each month that Kevin got bigger, he had a better chance of surviving surgery or whatever other option was available," adds Paula. "Then he told us there was a nonsurgical procedure that could alleviate Kevin's problem but, again, his small size caused the same risks as those involved with surgery. So we waited."

By September of 1992, Kevin had grown enough that he could undergo surgery with reduced risks. In addition, there was still the possibility of the nonsurgical procedure, an embolization, in which a material is injected into the arterial feeders to close off the blood flow for the malformation. The procedure was being performed successfully by medical teams in New York and in California. The Crockers decided that if taking Kevin to either coast for treatment was best for him, that is what they would do.

Paula Crocker: "Doctor Cross' work is amazing. It's medicine of the future that's available today."



“Then, everything just seemed to fall into place,” says Paula. “Doctor Kaufman told us that one of the doctors who had developed an expertise in embolizations was transferring from New York to Saint Louis.”

The doctor was DeWitte Cross, M.D., who is head of Mallinckrodt Institute’s neurointerventional suite and the St. Louis area’s only trained neurointerventional radiologist.

According to Cross, dural malformation of the transverse sigmoid sinus is a common occurrence. The malformation can be congenital, or it can be caused by trauma or by a clot within a venous sinus. Basically, the malformation is an abnormal communication between arteries and veins, resulting in a concentration of blood vessels in a particular area.

The site of Kevin’s dural malformation was unusual in a child of his age. Although the ridges behind his ear and the externally audible noise are not common symptoms, they were more noticeable in Kevin because of the rapid and excessive flow of blood through the occipital artery, running along the back of the head, near the ear. Luckily, his dural malformation was so large that it could be seen with the human eye; otherwise, it may have been years before Kevin had visible symptoms or could describe the symptoms.

“Older patients who can relay definite symptoms often have headaches and noises or a ringing sound in their ear,” says Cross. “They can’t sleep at night because of the pulsing, swishing sound. Sometimes, the patients can’t hear as well in the affected ear. Other patients with dural malformations may have eye problems — swollen, red, painful — or they may have double vision. The symptoms all depend on where the dural malformation is located.”

TURNING OFF THE NOISE

Before arriving at Mallinckrodt Institute, Kevin had undergone two routine angiograms. Cross studied the results of the first test, to define the problem, and compared it to the second angiogram, taken about 12 months later, to determine whether there were any changes. Case studies show that a portion of these malformations spontaneously dissolve, others remain stable, and some worsen.

In Kevin's case, the problem had worsened. The venous drainage pattern had changed, suggesting that the pressure in the vein had increased. This complication could lead to neurological problems: the possibility of intracranial hemorrhage, delayed development, a stroke, or hydrocephalus (an enlargement of fluid-filled ventricles in the brain). Cross felt there were three ways to approach Kevin's problem: observation over a period of time to see if further symptoms develop, surgery, or embolization.

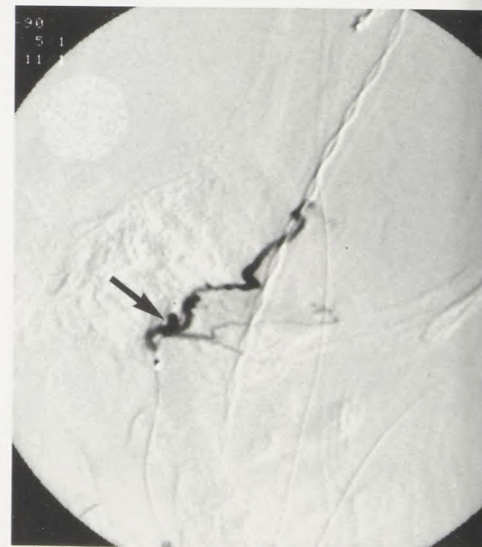
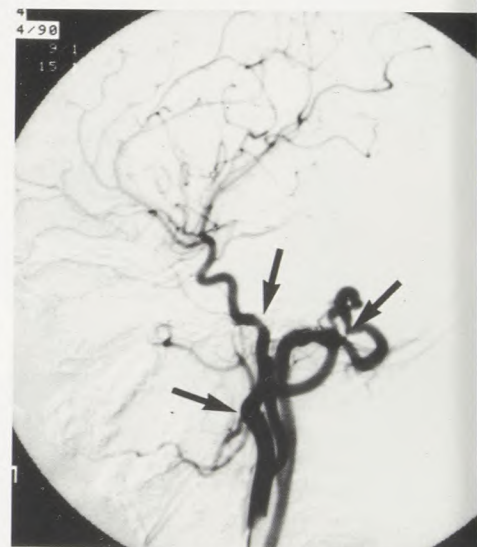
Based on the medical team's diagnosis and recommendation, the Crockers decided to go ahead with the embolization. There are two methods of embolization of dural malformations – transarterial and transvenous. In the transarterial method, the neurointerventional radiologist corrects the problem by injecting a sealing material into the arteries supplying the blood flow to the malformation. Transvenously, the procedure is directed via the jugular vein and the transverse and sigmoid sinuses, deposit-

ing the sealing material into the venous sinus cavity and closing the venous side of the malformation.

There were some factors to consider. One of the major drainage veins of the brain was emptying into the venous sinus, the location of the dural malformation. If Cross chose to transvenously embolize, there was a possibility of increased venous pressure within the temporal lobe, causing swelling or a blood clot. Cross decided transarterial embolization was safer for Kevin.

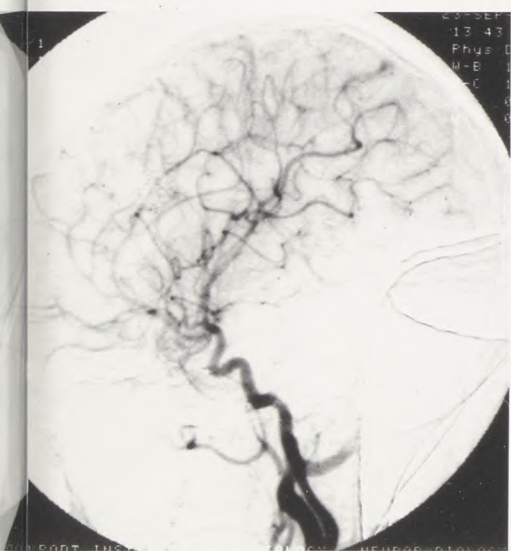
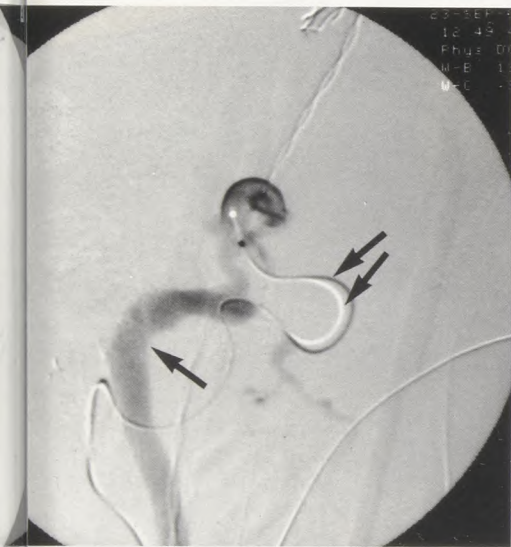
The procedure was scheduled for September 23 in the recently renovated angiographic suite, a room large enough to accommodate a full medical team — in this case, Drs. Cross and Christopher Moran, a neuroradiologist; a nursing team to monitor the patient and assist with the equipment and with administering drugs; technologists to operate the angiographic imaging equipment; and members of the pediatric anesthesia service. Kevin was anesthetized, not so much for the discomfort from the embolization but because he had to remain motionless during the process, a near impossibility for a toddler.

During the procedure, Cross found that two different arterial branches supplied blood flow to the malformation. A small external carotid branch was enlarged as was the occipital artery branch. "Kevin's occipital was larger than his internal carotid artery, larger than the artery that supplies blood to his entire cerebral hemisphere," says Cross.



Top: Pre-embolization – An angiogram revealed an enlarged external carotid artery (middle arrow) and occipital artery (left arrow) with a fistula to the jugular vein (right arrow).

Bottom: The embolization, part 1 – Catheters were advanced through the carotid artery into the enlarged branches of the ascending pharyngeal artery (arrow), which provided a blood supply to the malformation.



Top: The embolization, part 2 – Catheters (right arrows) were inserted into the occipital artery (left arrow), the second arterial branch supplying blood flow to the malformation.

Bottom: Post-embolization – The embolization using Avacryl was a success — the angiogram shows no filling of the fistula.

Using a small guidewire, Cross directed an angiographic catheter into the external carotid artery, advancing a microcatheter of about a millimeter in diameter into the ascending pharyngeal artery of the ear. Then Avacryl, a glue material that is liquid in the catheter but hardens upon contact with blood, was injected into the area supplying the blood flow. Glue has been used in Europe for over a decade but, in the U.S., is classified as an investigational agent by the Food and Drug Administration (FDA). The glue has been approved for use in research centers, such as Mallinckrodt Institute, and should obtain FDA approval for widespread use within the next three to six months.

Cross found that two different arterial branches supplied blood flow to the malformation.

Next, Cross tackled the second portion of the task. Initially, he attempted to insert a guidewire-directed microcatheter into the occipital artery branch, but, because of the artery's twisting and turning path, the catheter could not be advanced far enough. He then switched to a flow-guided catheter, which is advanced by blood flow. The procedure was a success; the catheter maneuvered the artery's curves, allowing Cross to embolize the occipital branch with Avacryl.

The procedure took about two hours, and then Kevin was transported to Children's Hospital. "Kevin was a little groggy Wednesday afternoon, but by Thursday morning he was ready to play," says Paula. "And on Friday morning, we were on our way home."

Kevin's embolization appears to have been a success. Angiographic cure rates are difficult to establish due to the different types of malformations, ranging from a low of 50 percent to a high of 100 percent. Unfortunately, there are patients who have many different arteries feeding the malformation, occasionally making it impossible to insert the catheters and to provide a route for the embolization. Kevin had only two arteries involved, and Cross located and embolized both.

"We don't have any perfect embolization materials at present," says Cross. "Glue is the closest thing we have to something that is permanent, but there is nothing available that doesn't carry the potential for recanalization of a malformation. So, while we hope this is a permanent cure, we will continue to monitor how Kevin is doing clinically and to see if there's evidence of symptomatic or asymptomatic recurrence of his malformation."

For now, Kevin is a body in motion, an active toddler whose main goal is charming someone into taking him to the park. But Paula and Jeff still marvel at the sequence of events, how "everything fell into place and the noise in Kevin's head was turned off - just like flipping a switch." □


CHECKS & BALANCES

by Vicki Kunkler

The Radiation Oncology Center's clinicians and physicists continue the search for a device to improve the accuracy of radiation therapy.

In the last six decades, the five-year survival rate after a diagnosis of cancer has increased from fewer than one in five patients to four out of 10. Based on normal life expectancy, a "relative" five-year survival rate of 51 percent is now predicted for all cancer patients. The key to that survival is early detection and advanced, carefully tailored treatments.

Jeff Michalski, M.D., of MIR's Radiation Oncology Center, iterates the longstanding goal of all radiation oncologists: direct the maximum radiation therapy dose to the tumor while sparing healthy tissue nearby. However, determining that the tumor is receiving the most accurate and most effective dose is not an easy task, and current verification methods are often impeded by the mechanics of the process. Using the technology of On-Line Image Verification (OLIV), Michalski and a team of researchers are investigating the most efficient way of estimating variations in radiation therapy dose delivery.



*Jeff Michalski, M.D.,
is shown with the
original prototype of
the on-line imager
developed at MIR.*

CHECKS & BALANCES

Across the U.S., radiation therapy verification includes weekly progress reports on each patient. While the patient is at the treatment unit, called a linear accelerator, an X ray is made of the body portion being treated. The X ray, or portal film, is compared to the simulation film — the initial X ray used to establish the patient's treatment plan. If all specifications match on both films, then treatment can proceed; if not, adjustments must be made.

"The process has many disadvantages," says Michalski. "First, the use of weekly portal films makes the assumption that previous treatments were identical to the treatment when the portal film was done. If we detect an error on the portal film, we might assume that correcting the error will solve the problem. What we find frequently on closer examination is that an error on one day may not be the same as an error the next day. There are naturally some day-to-day variations."

The variations in targeting the dose delivery can range from a few millimeters up to 10 millimeters, a result of the patient's normal breathing motion, swallowing, movement during treatment, or from altered positioning of the patient before treatment began. In some instances, the variation is caused by the skin's mobility.

Taking more frequent portal films would increase accuracy, but the films are expensive and cumbersome because of the development process and storage problems. A typical 30-day course of treatment, with two fields per day, equals 60 films per patient. Multiply that figure by the large number of patients treated in the Center, and the outcome would be tens of thousands of films annually.

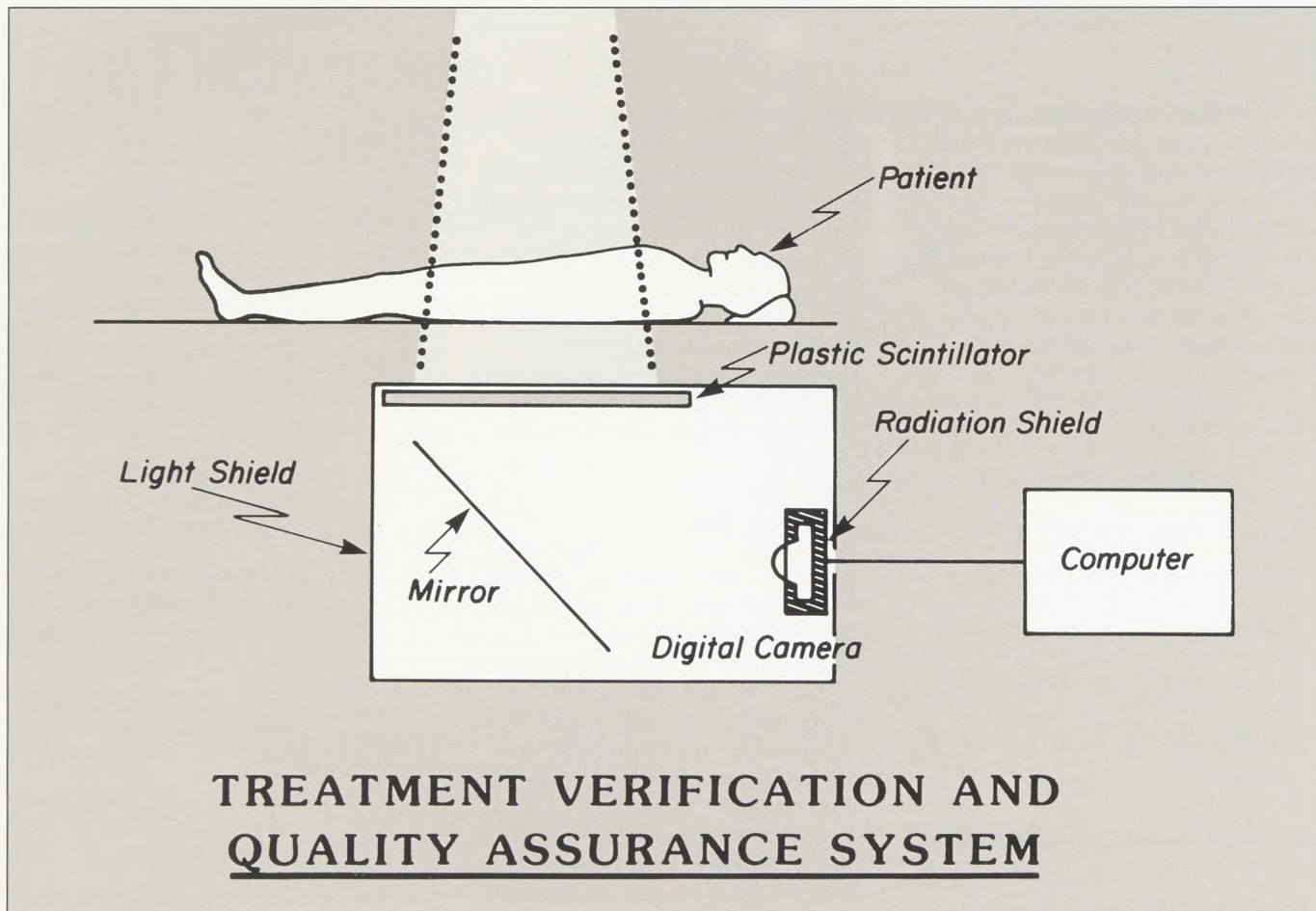
*The variations
in targeting the dose
delivery can range
from a few
millimeters up to 10
millimeters.*

"We are investigating the development of devices to electronically acquire all the information we need to give our patients the best treatment possible," says Michalski.

The devices are known by different names, such as on-line imagers or real-time portal imagers, but the concept is basic: an imager is installed at the back of the treatment unit and plots the target of the radiation beam as treatment occurs. According to Michalski, "Not only do we see variations in setup on a day-to-day basis, but in some instances, we can see them from second-to-second."

The imager used in the Radiation Oncology Center is a home-grown model, developed about four years ago by Mallinckrodt Institute radiation physicists working with Washington University scientists. The concept was the brainchild of John Wong, Ph.D., a former MIR researcher who is now director of clinical physics at William Beaumont Hospital in Michigan. He believed the plastic fibers the University scientists were using to measure cosmic rays could be adapted to improve the aim of the radiation beam in cancer treatment.

The plastic fibers were stretched, becoming thin in the middle and remaining thick on each end. Then, the fibers were packed together, bent into a 90-degree angle, and placed into a container, similar to a large cutting board, with a fluorescent covering on one end. When the device was placed beneath the patient during treatment, the radiation beam was absorbed as energy and transmitted to a television camera connected to the imager. From the resulting image, physicians could detect deviations from the area targeted for treatment.



TREATMENT VERIFICATION AND QUALITY ASSURANCE SYSTEM

Based on the same principle as that of the Institute's imager, this mirror-based OLIV system uses a mirror instead of a fiberoptic reducer to project an image to the camera.

Over the past three years, Michalski and the investigation team have been studying information collected from the imaging results. In one of the first clinical papers on OLIV, Mary Vogelsang Graham, M.D., reported on the motion that occurs during treatment. Taking those results one step further, Karen Halverson, M.D., quantified that motion by studying the number of times a patient moved as well as the degree, in millimeters, of movement.

Next, the team ran a series of checks on the accuracy of dose delivery, taking an image based on a few seconds of radiation exposure and then deciding whether the patient's position should be adjusted. An adjustment was made if there was a centimeter or more difference between simulated and actual dose delivery. The results: less than a three-percent error rate overall.

"Now the question is, can we go even better?" ponders Michalski. "As radiation therapy moves into the next century, we're going to be pushing the doses of radiation treatments. One way to accomplish that is by using three-dimensional treatment planning, and if we're going to be pushing doses, we need to limit the amount of normal tissue that we have to treat."

CHECKS & BALANCES

A standard treatment plan includes an area of normal tissue around the tumor, a margin that accounts for patient movement during treatment and assures the delivery of the prescribed radiation dose. According to Michalski, an effective way to limit the dose to normal tissue is to reduce the margin.

"If we're going to be pushing the doses of radiation treatments, we need to limit the amount of normal tissue we have to treat."

"So, our next step is to detect errors of five millimeters or more and to be able to correct those errors. If we're successful, when we begin using three-dimensional treatment on a regular basis, treatment plans need only allow a five-millimeter margin of normal tissue in the target area."

OLIV does have some disadvantages:

- Additional staff may be required to implement the technology.
- The installation of an imager will place new constraints on the linear accelerator, possibly causing interference with certain types of treatments.
- Additional costs may be incurred with training of staff and installation of equipment.

However, several centers in the U.S. and abroad are using OLIV, and Michalski believes the disadvantages of OLIV are more than balanced by the advantages. In October, the Center acquired a second on-line imager, installed in the radiation oncology facility at Jewish Hospital. This type of imager uses scintillation crystals to receive and convert radiation into an electronic signal that, in turn, is converted into an image on a computer screen.

OLIV's speed and accuracy will be a major asset to 3-D treatment planning, where up to eight portal films per patient per day may be necessary for treatment verification. "We're working out the kinks right now," says Michalski. "We need to document first that the goals can be accomplished and then integrate those results with three-dimensional treatment planning. It's one thing to have the technology available; it's another to use that technology to its best advantage." □

FYI

THE DIRECTOR'S OFFICE REPORT

NEW STAFF

Jorge G. Castillo-Perez, M.D., instructor in radiology, Division of Radiation Oncology.

P. Duffy Cutler, Ph.D., assistant professor of radiology, Division of Nuclear Medicine.

Terry C. Der, M.S., research associate in radiology, Division of Radiation Sciences.

Edward A. Deutsch, Ph.D., adjunct professor of radiology, Division of Radiation Sciences.

Paul Koppel, Ph.D., research instructor, Division of Nuclear Medicine.

Kevin W. McEnery, M.D., instructor in radiology, Division of Diagnostic Radiology.

Mary A. Middleton, M.D., instructor in radiology, Division of Diagnostic Radiology.

Tracy L. Roberts, M.D., instructor in radiology, Division of Diagnostic Radiology.

David J. Scherer, M.S., instructor in radiology, Division of Radiation Oncology.

Sharlene A. Teehey, M.D., assistant professor of radiology, Division of Diagnostic Radiology.

O. Clark West, M.D., instructor in radiology, Division of Diagnostic Radiology.

Yin Yuming, M.D., research fellow in radiology, Division of Diagnostic Radiology.

OFF STAFF

Jeffrey L. Borders, M.D., Ph.D., completed four years of training in diagnostic radiology and has accepted a position in the Department of Radiology, Children's Mercy Hospital, Kansas City, Missouri.

Daniel F. Broderick, M.D., instructor in radiology, completed a two-year fellowship in neuroradiology and has entered private practice with the Mayo Clinic, Jacksonville, Florida.

M. Alan Burns, M.D., instructor in radiology, completed a four-year residency in diagnostic radiology and a one-year fellowship in vascular and interventional radiology, and has accepted a position with Presbyterian Hospital, Charlotte, North Carolina.

Kevin E. Burton, M.D., instructor in radiology, completed a one-year fellowship in vascular and interventional radiology and has joined the faculty of the Department of Radiology, Indiana University, Indianapolis.

Paul L. Chesis, M.D., completed one year of residency in nuclear medicine and has been accepted into a four-year residency program in diagnostic radiology at the University of California at Los Angeles.

Judy M. Destouet, M.D., associate professor of radiology and head of mammography, Division of Diagnostic Radiology, has entered private practice in Baltimore.

Gino DiIorio, M.D., Ph.D., instructor in radiology, completed a one-year fellowship in magnetic resonance imaging.

Avraham Eisbruch, M.D., instructor in radiology, completed three years of residency and a one-year fellowship in radiation oncology, and has accepted an academic position in the Department of Radiation Oncology, University of Michigan Hospitals, Ann Arbor.

Kavita K. Erickson, M.D., instructor in radiology, completed a two-year fellowship in neuroradiology and has entered private practice with the Ernst Radiology Clinic, Inc., Bridgeton, Missouri.

Delia M. Garcia, M.D., assistant professor of radiology, Division of Radiation Oncology, has accepted the position of medical director, Department of Radiation Oncology, Missouri Baptist Hospital, St Louis.

Michaele R. Gold, director of public relations, has accepted the position of director of public relations for the Health Sciences Center, State University of New York at Stony Brook.

Jeffrey W. Hanna, M.D., instructor in radiology, completed a one-year fellowship in chest radiology and has entered private practice in Greenville, South Carolina.

William G. Horstman, M.D., cochief resident, Division of Diagnostic Radiology, 1991-1992, completed a four-year residency in diagnostic radiology and has accepted a residency in GU radiology and abdominal imaging in the Department of Radiology, Naval Hospital, San Diego.

Martin Keisch, M.D., instructor in radiology, completed three years of residency and a one-year fellowship in radiation oncology, and has entered private practice in La Mesa, California.

Harold E. Kim, M.D., instructor in radiology, completed a one-year fellowship in radiation oncology and has entered private practice with the Oncology Care Center, Belleville, Illinois.

Andrew B. Landes, M.D., completed four years of training in diagnostic radiology and has accepted a position in the Department of Radiology, The Hospital for Sick Children, Toronto.

Warren S. Lun, M.B., B.S., completed one year of residency in nuclear medicine and has received a computed tomography/ultrasound/magnetic resonance imaging fellowship at The New York Hospital, Cornell Medical Center, New York.

Gary E. Meyerrose, M.D., completed two years of residency in nuclear medicine and has received a positron emission tomography fellowship at Johns Hopkins Hospital, Baltimore.

P. Kim Nelson, M.D., instructor in radiology, completed four years of training in diagnostic radiology and a two-year fellowship in neuroradiology, and has accepted a position in the Department of Radiology, New York University Medical Center, New York.

William H. Perman, Ph.D., assistant professor of radiology, Division of Radiation Sciences.

FYI

THE DIRECTOR'S OFFICE REPORT

Continued from page 23

Mark Perry, M.D., instructor in radiology and cochief resident, Division of Diagnostic Radiology, 1990-1991, completed four years of training in diagnostic radiology and a one-year fellowship in abdominal radiology, and has accepted a position with Radiology Associates Chartered, Shawnee Mission, Kansas.

Hui Hua Shu, M.D., instructor in radiology, completed four years of training in diagnostic radiology and a one-year fellowship in magnetic resonance imaging, and has entered private practice with the Ernst Radiology Clinic, Inc., Bridgeton, Missouri.

Robert M. Smith II, M.D., completed four years of training in diagnostic radiology and has accepted a position with Radiology Associates of Pensacola, Baptist Hospital, Pensacola, Florida.

Scott D. Stevens, M.D., instructor in radiology, completed a four-year residency and a one-year fellowship in vascular and interventional radiology, and has entered private practice with Central Baptist Hospital, Lexington, Kentucky.

Neal R. Stewart, M.B., Ch.B., instructor in radiology, Division of Diagnostic Radiology, has accepted a position with the Radiology Department, Auckland Hospital, New Zealand.

Harri V. Suoniemi, M.D., instructor in radiology, completed a one-year fellowship in neuroradiology and has entered private practice in Tampere, Finland.

Jamie T. Surratt, M.D., completed a four-year residency in diagnostic radiology and has entered private practice with Drs. Mori, Bean, and Brooks, PA., Jacksonville, Florida.

R. Stephen Surratt, M.D., instructor in radiology, completed a four-year residency in diagnostic radiology and a one-year fellowship in abdominal radiology, and has entered private practice with Drs. Mori, Bean, and Brooks, PA., Jacksonville, Florida.

Di Yan, D.Sc., research associate in radiology, Division of Radiation Oncology, has accepted a position with the Department of Radiology, William Beaumont Hospital, Royal Oak, Michigan.

FIRST-YEAR POST-GRADUATES

Mary G. Alderman, M.D., received her Bachelor of Science degree in biology from the University of North Carolina at Chapel Hill and her medical degree from the University of Florida College of Medicine. She is a member of AOA.

Kyongtae Tyler Bae, M.D., received his undergraduate degree in chemical engineering from Seoul University, Korea; a master's degree in chemical engineering from the University of Iowa; and a master's degree as well as his Ph.D. degree in chemical engineering from the University of Pennsylvania. He received his medical degree from the University of Chicago-Pritzker.

Andrew J. Fisher, M.D., received his Bachelor of Arts degree in economics from Yale University and his medical degree from Duke University School of Medicine. He is a member of AOA.

Anthony M. Foti, M.D., received his Bachelor of Science degree in biology and his medical degree from the University of Michigan. He is a member of AOA.

Eric S. Malden, M.D., received his Bachelor of Arts degree in biology from the University of Rochester, New York, and his medical degree from Washington University. He is a member of AOA.

Michele D. Semin, M.D., received her Bachelor of Science degree and her medical degree from Washington University. She is a member of AOA.

Farrel K. VanWagenen, M.D., received his Bachelor of Science degree in biology and his medical degree from the University of Utah. He is a member of AOA.

NEW FELLOWS

Carlos F. Aquino-Aponte, M.D., instructor in radiology, is a fellow in magnetic resonance imaging. He received his medical degree from the University of Puerto Rico School of Medicine. Aquino-Aponte completed his internship at San Juan City Hospital, Rio Piedros, Puerto Rico; a two-year residency in radiology at the University of Puerto Rico School of Medicine; and a two-year residency in radiology at the University of California at San Diego Medical Center. He has received American Board of Radiology certification.

Clinton M. Anderson, M.D., instructor in radiology, is a fellow in magnetic resonance imaging. He completed a four-year residency at Mallinckrodt Institute of Radiology.

Meredith W. Bell, M.D., instructor in radiology, is a fellow in abdominal radiology. She received her Bachelor of Science degree in chemistry and biology from Mississippi University for Women and her medical degree from the University of Mississippi School of Medicine. She completed a residency in diagnostic radiology at the University of North Carolina Hospitals, Chapel Hill. Bell is a member of AOA and has received American Board of Radiology certification.

Lane A. Deyoe, M.D., instructor in radiology, is a fellow in abdominal radiology. He received his medical degree from the University of Connecticut. Deyoe completed his internship at John Dempsey Hospital, Farmington, Connecticut, and a four-year residency in radiology at Rhode Island Hospital, Providence. He has received American Board of Radiology certification.

Leeanna Dick, M.D., instructor in radiology, is a fellow in vascular and interventional radiology. She received her medical degree from the University of Louisville. Dick completed her internship and a residency in radiology at the University of North Carolina Hospitals, Chapel Hill. She has received American Board of Radiology certification.

FYI

Humberto M. Fagundes, M.D., instructor in radiology, is a fellow in radiation oncology. He completed a three-year residency in radiation oncology at Mallinckrodt Institute of Radiology and is chief resident, Division of Radiation Oncology, 1992-1993.

Jeffrey E. Fischbein, M.D., instructor in radiology, is a fellow in neuroradiology. He received his Bachelor of Arts in economics from Tufts University and his medical degree from State University of New York at Stony Brook. Fischbein completed his internship at Winthrop University Hospital, Mineola, New York, and his residency in radiology at Long Island Jewish Hospital. He is a member of AOA and has received American Board of Radiology certification.

Robin Frank-Gerszberg, M.D., instructor in radiology, is a fellow in pediatric radiology. She received her Bachelor of Arts degree in economics from Bryn Mawr College and her medical degree from Albert Einstein College of Medicine, New York. Frank-Gerszberg completed her internship at St. John's Mercy Medical Center, St. Louis, and a residency in diagnostic radiology at The Jewish Hospital of St. Louis. She has received American Board of Radiology certification.

Anastasios Georgiou, M.D., instructor in radiology, is a fellow in radiation oncology. He completed a three-year residency in radiation oncology at Mallinckrodt Institute of Radiology.

Patrick O. Gordon, M.D., instructor in radiology, is a fellow in neuroradiology. He received his Bachelor of Science degree from Pennsylvania State University and his medical degree from the University of Pittsburgh School of Medicine. Gordon completed a four-year residency in radiology at the Cleveland Clinic Foundation. He has received American Board of Radiology certification.

Edith H. Kang, M.D., instructor in radiology, is a fellow in magnetic resonance imaging. She completed four years of training at Mallinckrodt Institute of Radiology and was chief resident, Division of Diagnostic Radiology, 1991-1992.

Karl W. King, M.D., instructor in radiology, is a fellow in radiation oncology. He completed a three-year residency in radiation oncology at Mallinckrodt Institute of Radiology.

Myles B. Koby, D.D.S., M.D., instructor in radiology, is a fellow in neuroradiology. He received his Doctor of Dental Surgery degree from the University of Detroit and his medical degree from Wayne State University, Detroit. Koby completed internships at Wayne State University Medical Center and at Albert Einstein Medical Center, Philadelphia. He completed a four-year residency in diagnostic radiology at LAC/USC Medical Center, Los Angeles. Koby has received American Board of Radiology certification.

Mark D. Mayhle, M.D., instructor in radiology, is a fellow in vascular and interventional radiology. He completed four years of training in diagnostic radiology at Mallinckrodt Institute of Radiology.

Kurt L. Openshaw, M.D., instructor in radiology, is a fellow in vascular and interventional radiology. He received his Bachelor of Science in biomedical engineering and his medical degree from the University of Southern California. Openshaw completed his internship at the University of California Medical Center, Irvine, and his residency in radiology at the University of California Medical Center, San Francisco. He is a member of AOA and has received American Board of Radiology certification.

Nhan P. Truong, M.D., instructor in radiology, is a fellow in musculoskeletal radiology. He received his Bachelor of Arts degree in biochemistry from Rice University and his medical degree from the University of Texas Southwestern Medical School, Dallas. Truong completed his residency in radiology at Parkland Memorial Hospital, Dallas. He has received American Board of Radiology certification.

John F. Walsh, M.D., instructor in radiology, is a fellow in nuclear medicine. He received his Bachelor of Arts degree in medical sciences and classical civilizations and his medical degree from Boston University. He completed his internship and a residency in internal medicine at the United States Air Force Medical Center, Keesler, Mississippi. Walsh is a member of AOA.

Robert C. Wood, M.D., instructor in radiology, is a fellow in neuroradiology. He received his Bachelor of Science degree in biology from Baylor University and his medical degree from the University of Texas Medical Branch at Galveston. Wood completed a four-year resi-

dency in diagnostic radiology at Vanderbilt University Medical Center. He is a member of AOA and has received American Board of Radiology certification.

DIAGNOSTIC RADIOLOGY RESIDENTS

Gerard M. Eagar, M.D., received his medical degree from the University of Otago, Dunedin, New Zealand, and the Fellow degree in radiology from the Royal Australasian College of Radiologists. He completed a five-year residency in radiology at Christchurch Hospital, New Zealand, and a one-year fellowship in radiology at Dalhousie University, Halifax, Nova Scotia.

Richard N. Edelstein, M.D., received his Bachelor of Science degree in chemistry and his medical degree from the University of Miami. He completed his internship and his residency in medicine at the Yale-New Haven Hospital. Edelstein is a member of AOA.

Matthew J. Fleishman, M.D., received both his Bachelor of Arts degree in biology and his medical degree from Columbia University. He completed his internship and a two-year residency in nuclear medicine at Presbyterian Hospital, New York City. Fleishman is a member of AOA.

Jeffrey A. Friedland, M.D., received his Bachelor of Science degree in interdisciplinary basic medical science and his medical degree from the University of Florida. He completed his internship at The Jewish Hospital of St. Louis. Friedland is a member of AOA.

FYI

THE DIRECTOR'S OFFICE REPORT

Continued from page 25

Rory A. Satterfield, M.D., received his Bachelor of Arts degree in biochemistry and his medical degree from the University of California, San Diego. He completed his internship at Deaconess Hospital, St. Louis.

Eric R. Weidman, M.D., received his Bachelor of Arts degree in biochemistry from Dartmouth College and his medical degree from Duke University. He completed his internship at St. Mary's Health Center, St. Louis. Weidman is a member of AOA.

Neda Yagan, M.D., received her Bachelor of Arts degree in anthropology and her medical degree from Case Western Reserve University. She completed her internship at Lennox Hill Hospital, New York City.

NUCLEAR MEDICINE RESIDENTS

Richard L. Butler, M.D., received his medical degree from St. Louis University and completed his internship and his residency in internal medicine at St. Louis University Hospitals. He completed a one-year fellowship in cardiology at St. Louis University Hospitals as well as a one-year fellowship in cardiology at The Jewish Hospital of St. Louis.

Chi-lai Ho, M.D., received his Bachelor of Science degree in chemical engineering from Brigham Young University, his Master of Science degree in biomedical engineering from Stanford University, and his medical degree from the University of Hong Kong. He completed his internship at Queen Mary and Kwong-Woh hospitals, Hong Kong, and a residency in nuclear medicine at Queen Mary and Queen Elizabeth hospitals, Hong Kong.

RADIATION ONCOLOGY RESIDENTS

Astrid E. Morrison, M.D., received her Bachelor of Science degree in chemical engineering and her medical degree from the University of Oklahoma. She completed her internship at the University of Oklahoma Health Sciences Center.

Higinia Cardenes, M.D., received her premedical training at Instituto Nacional Aguines, Canary Islands, and her medical degree from Facultad de Medicina, Universidad de Laguna, Canary Islands. She completed her internship at Clinica Puerta de Hierro, Madrid.

Robert G. Swanson, M.D., received his Bachelor of Science degree in chemistry from Vanderbilt University and his medical degree from Washington University. He completed his internship at St. John's Mercy Medical Center, St. Louis.

PROMOTIONS

Dennis M. Balfe, M.D., professor of radiology, Division of Diagnostic Radiology.

Prabhat C. Goswami, Ph.D., instructor in radiology, Division of Radiation Oncology.

Albert M. Hammerman, M.D., assistant professor of clinical radiology, Division of Diagnostic Radiology.

Lawrence M. Kotner, Jr., M.D., assistant professor of clinical radiology, Division of Diagnostic Radiology.

Tom R. Miller, M.D., Ph.D., professor of radiology, Division of Nuclear Medicine.

Robert J. Myerson, M.D., Ph.D., associate professor of

radiology, Division of Radiation Oncology.

Thomas M. Vesely, M.D., assistant professor of radiology, Division of Diagnostic Radiology.

CHANGE OF STATUS

Robert E. Drzymala, Ph.D., assistant professor of radiology, Division of Radiation Oncology, received a joint appointment as assistant professor of neurosurgery, Department of Neurosurgery.

Anthony J. Wilson, M.B., Ch.B., assistant professor of radiology, was named director of emergency radiology at the Institute.

VISITING PROFESSORS & INVITED LECTURERS

James A. Brink, M.D., assistant professor of radiology, as visiting professor, spoke on "Spiral Computed Body Tomography" at the Baptist Medical Center of Oklahoma, Oklahoma City, October 23. He presented "Imaging of the Pancreaticobiliary System," "CT of the Peritoneal Ligaments," and "Imaging of the Urinary Tract" at the Annual Meeting of the Oklahoma State Radiological Society, Oklahoma City, October 24. Brink also spoke on "Spiral Computed Body Tomography" at the Imaging Techniques Seminar, Carle Clinic, Champaign, Illinois, October 31.

DeWitte T. Cross III, M.D., assistant professor of radiology, spoke on "Interventional Neuroradiology" at the Scientific Program session for the Washington University Medical School Alumni Reunion, St. Louis, May 7. He also spoke on "Interventional Neuroradiology" at the City-Wide Radiology Conference, St. Louis, September 14, and at the Neuroscience Seminar, Missouri Delta Medical Center, Sikeston, Missouri, November 21.

FYI

Bahman Emami, M.D., professor of radiology and associate director of the Radiation Oncology Center, presented "Role of 3D Radiotherapy in Evaluation of Irradiation Late Effects" at the Consensus Conference on Late Effects of Cancer Treatment, San Francisco, August 26 - 28. He participated in and chaired a session at the NCI Multi-Institutional Clinical Trials in Hyperthermia Workshop, Bethesda, September 24 - 25. Emami spoke on "Research of Target Volume in the Therapeutic Integration for Lung Cancer" and "Research of the Target Volume in the Therapeutic Integration for Prostatic Cancer" at the Residential Course on the Research of the Target Volume in Therapeutic Integrations, Rome, November 16 - 20.

Mokhtar H. Gado, M.D., professor of radiology, presented "Adult Intracranial Brain Tumors" and "MRI of the Sella" at the 1992 Harvard Postgraduate Course on Basic and Current Concepts in Neuroradiology, Head, and Neck Radiology and Neuro-MRI, Boston, September 21 - 25.

Delia M. Garcia, M.D., assistant professor of radiology, presented "Brachytherapy and Hyperthermia for Brain Tumors" at the Seventh International Brachytherapy Working Conference, Nucletron Corporation, Baltimore, September 6 - 8.

Louis A. Gilula, M.D., professor of radiology and codirector of the musculoskeletal section, spoke on "Tailored Approach to Wrist CT" at the International Skeletal Society, Stockholm, August 24 - 29. He organized the International Wrist Investigator's Workshop and presented a lecture on "Imaging of the Distal Radioulnar Joint" at a course on "The Distal Radioulnar Joint" held by the American Society for Surgery of the Hand, Asheville, North Carolina, September 10 - 12. Gilula lectured on "Imaging Approach to Wrist Pain" at the Problems in the Wrist Meeting, St. Louis, October 1. He conducted sessions on "Current Uses of Arthrography," "Hand and Wrist Trauma," and "Leg Venography" as part of the Musculoskeletal Imaging Refresher Course, New Delhi, October 28 - November 1. Gilula and **Neal R. Stewart, M.B., Ch.B.**, displayed an exhibit on "Tailored Approach to Wrist CT," and Gilula presented a refresher course on "Imaging of the Painful Wrist" at the Annual Meeting of the American Society for Surgery of the Hand, Phoenix, November 11 - 14. As keynote speaker, Gilula presented "Wrist Imaging, an Update" at the Swedish Radiological Society, Stockholm, November 25.

Jay P. Heiken, M.D., associate professor of radiology and codirector of computed body tomography, lectured on "CT and MRI Evaluation of Gynecologic Neoplasms" and conducted workshops on "Spiral CT" and "Retroperitoneal Fluid Collections" at the Second Summer Practicum - Society of Computed Body Tomography and Magnetic Resonance, Keystone, Colorado, August

16 - 20. He spoke on "Intravenous Contrast Enhancement and Spiral CT: Effect in the Chest and Abdomen" at the Spiral CT Workshop, sponsored by Siemens Medical Systems, Baltimore, August 29. Heiken also presented "Detection of Liver Metastases" and "CT and MRI of Renal Masses" at Advances in Body CT/MRI, University of Michigan Medical School, Ann Arbor, September 15 - 17.

William H. McAlister, M.D., professor of radiology and radiologist-in-chief at St. Louis Children's Hospital, conducted "Fellowship Accreditation and CAQ's in Pediatric Radiology" at the SCORCH meeting, Chicago, October 3. He spoke on "Imaging Child Abuse" to the American Academy of Pediatrics, San Francisco, October 11.

Bruce L. McClennan, M.D., professor of radiology and head of abdominal imaging, as visiting professor, spoke on "CT of Renal Infections" and "CT Staging of Renal Cell and Adrenal Carcinoma" at Wilford Hall United States Air Force Hospital, Brooke Army Hospital, and the University of Texas, San Antonio, October 7 - 9. He presented "Contrast Media Reactions: Recognition and Response" at Radiology Grand Rounds, University of California, San Francisco, October 29.

Scott A. Mirowitz, M.D., assistant professor of clinical radiology, as invited speaker, presented "Techniques for Rapid MR Imaging" at the 11th Annual Scientific Meeting of the Society of Magnetic Resonance in Medicine, Berlin, August 12.

Stephen, M. Moerlein, Ph.D., associate professor of radiation chemistry, presented "In Vivo Specificity of N-(2' - [F-18] Fluoroethyl) benperidol for PET Investigation of Dopaminergic D-2 Receptor Binding," coauthored by **Moerlein; Joel S. Perlmutter, M.D.**; and **David Parkinson, Ph.D.**, at the 22nd Annual Meeting of the Society for Neuroscience, Anaheim, October 27.

Christopher Moran, M.D., assistant professor of radiology, presented "Magnetic Resonance Angiography" at the Neuroscience Seminar, Missouri Delta Medical Center, Sikeston, Missouri, November 21.

Eduardo G. Moros, Ph.D., assistant professor of radiology, presented "Ultrasonic heating of Superficial Tumors and Peripheral Normal Tissues: The Effect of Thermally Significant Vessel Pair" at the 1992 Winter Annual Meeting of the American Society of Mechanical Engineers, Bioheat and Biomass Transfer Division, Anaheim, November 9 - 13.

William A. Murphy, Jr., M.D., professor of radiology and codirector of the musculoskeletal section, as a member of the investigative team, participated in the interpretation of radiographs and CT images used in the evaluation of a 5,000 year-old frozen mummy that was discovered in the Tyrolean Alps over a year ago. During his participation in the investigation, as invited lecturer, Murphy spoke on bone marrow magnetic resonance imaging, temporomandibular joint imaging, and forensic radiology to the staff and residents at der Leopold-Franzens-Universität and the Universitätsklinik für

FYI

VISITING PROFESSORS & INVITED LECTURERS

Continued from page 27

Innere Medizin, Innsbruck, Austria, September 14 - 17. As visiting professor, he presented talks on bone marrow imaging, forensic radiology, and the pathophysiology of inflammatory arthropathies to the Pennsylvania State University Department of Radiology, Milton S. Hershey Medical Center, Hershey, Pennsylvania, November 5-6.

Carlos A. Perez, M.D., professor of radiology and director of the Radiation Oncology Center, spoke on "Conservation Treatment of Breast Cancer: Radiation Therapy" and "Radiation Therapy Treatment of Post-mastectomy Chest Wall or Regional Lymph Node Recurrence," and participated in a panel discussion on "Radiation Therapy and Breast Cancer: Current Indications" and a roundtable on "In Situ Ductal Carcinoma: Role of Radiation Therapy" at the IX Brazilian Congress of Mastology, Belo Horizonte, August 2 - 6. He lectured on "Place of Radiotherapy in Treatment of Carcinoma of Lung," "Multidisciplinary Management of Breast Cancer," and "Biological Bases of Multidisciplinary Therapy" at the Society of Oncology of Cordoba, Argentina, August 13 - 15. Perez presented "Indications and Techniques of Radiotherapy in Treatment of Carcinoma of the Breast" and "Irradiation and Conservation Surgery in Stages I and II Carcinoma of the Breast" at *Advances 92 en*

Gineco-Obstetricia y Reproduccion Humana, Barcelona, October 13 - 17. He also spoke on "Integration of Radiation Therapy and Chemotherapy in Early Breast Cancer," "Radiation Therapy in Management of Locoregional Recurrence of Cancer of the Breast," and "Conservation Therapy in Breast Cancer" at the VIII Congreso Latino-Americano de Mastologia, I Simposio Euro-Latino-Americano de Mastologia, I Congreso Uruguayo de Mastologia, Montevideo, Uruguay, November 22 - 27.

Marcus E. Raichle, M.D., professor of radiology and neurology, as invited lecturer, presented the Decade of the Brain Lecture, "The Human Brain and Behavior: Insights from Modern Imaging Techniques," at the opening session of the 22nd Annual Meeting of The Society for Neurosciences, Anaheim, October 25 - 30.

William J. Powers, M.D., associate professor of neurology and radiology, and neurologist-in-chief, The Jewish Hospital of St. Louis, presented "Positron Emission Tomography in Neurologic Disease" at the Neuroscience Seminar, Missouri Delta Medical Center, Sikeston, Missouri, November 21.

Henry D. Royal, M.D., associate professor of radiology and associate director of the Division of Nuclear Medicine, as visiting professor, lectured on "Ventilation and Perfusion Lung Scans," "Scientific, Social, and Political Views of the Effects of Low Level Radiation," "Cardiac Nuclear Medicine," "Health Effects of the Chernobyl Accident," and "IAEA International Chernobyl Project" at Dalhousie University, Halifax, Nova Scotia, September 25 - 26. He spoke on "Cancer and Genetic Radiation Effects" at the Management of Radiation Accidents course, sponsored by the University of New Mexico School of Medicine Department of Radiology in cooperation with Los Alamos National Laboratories and Sandia National Laboratories, Albuquerque, October 15. As invited speaker, Royal presented "Diagnostic Radiology: Risks and Benefits" and "Health Effects of the Chernobyl Accident: Perceptions and Realities" at the Conference on Radiation Effects Academia Sinica, Taipei, October 21 - 23.

Stuart S. Sagel, M.D., professor of radiology, director of chest radiology, and codirector of computed body tomography, lectured on "CT of Vascular Mediastinal Lesions," "CT of the Mediastinum: Anatomic Variants and Pitfalls," and "CT of the Thymus" at the Second Summer Practicum - Society of Computed Body Tomography and Magnetic Resonance, Keystone, Colorado, August 16 - 20. He spoke on "CT of the Thorax: Technique," "CT of the Thorax: Anatomic Variants and Pitfalls," "CT of Non-vascular Mediastinal Masses," "CT of the Pericardium," and "High

Resolution CT of Focal Pulmonary Lesions" at the 2nd Annual Nycomed Course on Chest and Cardiac Radiology, Bahia, Brazil, September 30 - October 3.

Barry A. Siegel, M.D., professor of radiology and medicine, and director of the Division of Nuclear Medicine, presented "Nuclear Medicine and the FDA" to the Missouri Valley/Central Chapters, Society of Nuclear Medicine, St. Louis, October 18. He spoke on "Scintigraphic Diagnosis of Pulmonary Embolism" at the Hong Kong Society of Nuclear Medicine, Hong Kong, November 10.

Marilyn J. Siegel, M.D., professor of radiology, presented "CT of the Pediatric Mediastinum" at the Second Summer Practicum - Society of Computed Body Tomography and Magnetic Resonance, Keystone, Colorado, August 16 - 20. She lectured on "Ultrasonography of Neonatal Intracranial Hemorrhage and Leukomalacia," "Congenital Brain Anomalies," "Pediatric Gynecologic Ultrasonography," and "Ultrasonography of Acute Abdominal Pain in Children" at the 5th International Imaging Course of the Chinese University, Hong Kong, November 8 - 14.

FYI

Ali Soleimani-Meigooni, Ph.D., assistant professor of radiology, lectured on "Selection of Radioactive Material for Brachytherapy Treatments," Imam Khomeini Hospital, Tehran, July 31. He spoke on "Choice of the Intracavitary and Interstitial Brachytherapy Sources Based on Source Dosimetry Data," St. Jude Children's Research Hospital, Memphis, October 16.

Michel M. Ter-Pogossian, Ph.D., professor of radiation sciences, as a member of the panel on "Functional Neuroimaging: An Art of the 20th Century?", spoke on "The Genesis of Positron Emission Tomography" and, as a member of the panel on "New and Established Clinical Applications," spoke on "The Future: Instrumentation" at the Symposium on Recent Developments in PET, Cologne, September 27 - 29. He presented "In the Early Days of PET - A Retrospective" at the Positron Emission Tomography Workshop, sponsored by the National Institutes of Health, Bethesda, November 9 - 10.

Michael W. Vannier, M.D., professor of radiology, director of the Division of Radiology Research, and head of the image processing lab, as vice chairman of the Technical Program Committee, spoke on "Electronic Imaging of the Human Body" and chaired a session on "Surgery Treatment Planning" at the Visualization in

Biomedical Computing 1992 Conference, hosted by the Department of Computer Science, University of North Carolina at Chapel Hill, October 13 - 16. He presented "Neuroimaging Research" at the Neuroscience Seminar, Missouri Delta Medical Center, Sikeston, Missouri, November 21.

Jerold W. Wallis, M.D., assistant professor of radiology, participated in a panel discussion on "Functional Magnetic Resonance Imaging and Spectroscopy versus PET and SPECT: The Potential and Limitations of Each Modality" at the IEEE Medical Imaging Conference, Orlando, October 31.

Jeffrey F. Williamson, Ph.D., associate professor of radiology and chief of brachytherapy physics services, presented a paper, "Calculated and Measured Heterogeneity Correction Factors for ^{125}I , ^{137}Cs and ^{192}Ir Brachytherapy Sources" and a poster, "Dose Measurements, Monte Carlo Calculations and Absolute Calibration of a New Interstitial Yb-169 Source," coauthored with **Harold Perera, Ph.D.**, and **Zuofeng Li, Sc.D.**, at the 1992 Annual American Association of Physicists in Medicine, Calgary, Alberta, August 22 - 27. He spoke on "Physical Aspects of Pulsed Dose-Rate Brachytherapy" at the 7th International Brachytherapy Working Conference, Baltimore, September 5. As invited lecturer, Williamson presented the Varian Keynote Address, "Recent Developments in Basic Brachytherapy Physics," and spoke on "Quality Assurance in Brachytherapy: Principles and a Practical Implementation," "Heterogeneity Corrections in Brachytherapy

Dosimetry," and "Monte Carlo Photon Transport Calculations: A Powerful Dosimetry Tool for Brachytherapy" at the Australasian College of Physical Scientists and Engineers in Medicine, and the Institution of Biomedical Engineering (ACPSEM/BECON) 92 Meeting, Gold Coast, Australia, September 14 - 18.

He lectured on "Overview of a General Purpose Geometry Package for Use by Monte Carlo Code with Special Reference to Its Use with EGS," "Physical Aspects of Historical Dose Specification Systems in Intracavitary Brachytherapy," and "HDR Brachytherapy including QA Aspects" at the Royal Brisbane Hospital, Division of Oncology, Queensland Radium Institute, Queensland, Australia, September 21. Williamson spoke on "Recent Developments in Basic Brachytherapy Physics," "Quality Assurance in Brachytherapy: Principles and a Practical Application," and "Heterogeneity Corrections in Brachytherapy Dosimetry" at the Waikato Hospital, Radiation Oncology Department, Hamilton, New Zealand, September 25. He presented "Recent Developments in Brachytherapy Physics" at Christchurch Hospital, Christchurch, New Zealand, September 28; at Peter MacCallum Cancer Institute, Melbourne, September 29; and at the Brachytherapy Seminar, NSW/ACT Branch of ACPSEM, Royal North Shore Hospital, Sydney, October 1. Williamson also presented

"Quality Assurance in Brachytherapy: Principles and a Practical Application" at Christchurch Hospital, Christchurch, September 28; at Repatriation General Hospital Heidelberg, Melbourne, September 29; and at the Brachytherapy Seminar, NSW/ACT Branch of ACPSEM, Royal North Shore Hospital, Sydney, October 1.

Anthony J. Wilson, M.B., Ch.B., assistant professor of radiology and director of emergency radiology, spoke on "Musculoskeletal Digital Imaging" at the International Skeletal Society Annual Refresher Course, Stockholm, August 26.

SYMPOSIA

AMERICAN COLLEGE OF RADIOLOGY

The following Mallinckrodt Institute staff members participated in the 69th Annual Meeting of the American College of Radiology, Phoenix, September 12 - 16.

Ronald G. Evens, M.D., FACR, as ACR secretary-treasurer, presented "Report of the ACR."

Todd H. Wasserman, M.D., FACR, was chairman of the American College of Radiology/Radiation Therapy Oncology Group Symposia on Clinical Trials - "A Predictor of Future Trends in Radiation Oncology."

FYI

SYMPOSIA

Continued from page 29

CATEGORICAL COURSE

"Imaging of Cancers: Diagnosis, Staging and Follow-up Challenges"

Bruce L. McClennan, M.D., FACR, "Renal-Adrenal Cancer-Diagnosis, Staging and Follow-up Requirements."

Jeffrey J. Brown, M.D., "Prostate Cancer: Imaging Roles in Detection, Staging, and Follow-up."

Jay P. Heiken, M.D., "Testicular Cancer-Imaging Role in Detection, Staging and Follow-up."

Marilyn J. Siegel, M.D., FACR, "Lymphomas in Children."

ACR/RTOG SYMPOSIA ON CLINICAL TRIALS
"A Predictor of Future Trends in Radiation Oncology"

James A. Purdy, Ph.D.; Bahman Emami, M.D., FACR, "Three-Dimensional Radiation Therapy."

Todd H. Wasserman, M.D., FACR, "Chemical Modifiers" and "Quality of Life."

AMERICAN SOCIETY FOR THERAPEUTIC RADIOLOGY AND ONCOLOGY

The following Mallinckrodt Institute staff members participated in the 34th Annual Scientific Meeting of the American Society for Therapeutic Radiology and Oncology, San Diego, November 9 - 13.

Carlos A. Perez, M.D., presented his Gold Medal Award acceptance speech, "Quest for Excellence: The Ultimate Goal of the Radiation Oncologist."

SCIENTIFIC SESSIONS

Venkata R. Devineni, M.D., "Early Glottic Carcinoma Treated with Radiotherapy: Impact of Treatment Energy on Success Rate."

Humberto Fagundes, M.D., "Breast-Conserving Surgery and Definitive Irradiation: A Comparison Between Quadrantectomy and Local Excision with Special Focus on Cosmesis and Local Control" and "Predictive Assays in Medulloblastoma."

Eric E. Klein, M.S., "Breast Tangential and Nodal Therapy Using One Isocenter and Dual Asymmetric Jaws."

Jeff M. Michalski, M.D., "Comparison of Two Portal Image Alignment Methods for Treatment Verification Analysis."

Robert J. Myerson, M.D., "Preoperative Radiation Therapy for Transrectal Ultrasound T3 or T4 Rectal Adenocarcinoma."

James A. Purdy, Ph.D., "3D Treatment Planning Tools."

Joseph R. Simpson, M.D., "Influence of Location and Extent of Surgical Resection on Survival of Patients with Glioblastoma Multiforme: Results of Three Consecutive RTOG Clinical Trials."

Eric D. Slessinger, M.S., "Early Breast Cancer: Duplication of 6 MV Dose Buildup with 18 MV X-rays in Patients with Large Bridge Separations."

Richard Valicenti, M.D.; Todd H. Wasserman, M.D., "Analysis of Prognostic Factors in Localized Gastric Lymphoma and the Importance of Bulk of Disease."

Mary L. Vogelsang Graham, M.D., "3-D Radiation Treatment Planning Study for Patients with Carcinoma of the Lung."

Jeffrey F. Williamson, Ph.D., "Dosimetric Characteristics of a New Ytterbium-169 Interstitial Seed: An Experimentally Validated Monte Carlo Investigation."

REFRESHER COURSES

Perry W. Grigsby, M.D., "Carcinoma of the Endometrium — Prognostic Factors and Management."

POSTER PRESENTATIONS

Gopal R. Desai, M.D., "Early Glottic Carcinoma: Underdosage in the Vocal Cords from Megavoltage Irradiation."

Karl King, M.D., "Prognostic Significance of Anterior Commissure Involvement in Early Glottic Cancer Treated with Radiation Therapy."

HONORS/ AWARDS

G. James Blaine, D.Sc., associate professor of radiology and codirector of the Electronic Radiology Laboratory, was a medical communications guest editor for the IEEE Communications Society's *Journal on Selected Areas in Communications*, September, 1992. "Considerations in Moving Electronic Radiography into Routine Use," co-authored by **Jerome R. Cox, Jr., D.Sc.; Edward Muka, M.S.; Blaine; Stephen M. Moore, M.S.;** and **R. Gilbert Jost, M.D.**, was published in the "Architectures" section of the journal.

Bruce L. McClennan, M.D., professor of radiology and head of abdominal imaging, was a guest examiner in genitourinary radiology for the American Board of Radiology exams held in Louisville, November 7 - 9.

William A. Murphy, Jr., M.D., professor of radiology and codirector of the musculoskeletal section, was appointed to the editorial boards of *Radiographics* and *Skeletal Radiology*. He also was an examiner in diagnostic radiology for the American Board of Radiology oral boards held in Louisville, November 8 and 9.

Carlos A. Perez, M.D., professor of radiology and director of the Radiation Oncology Center, and **Bahman Emami, M.D.**, professor of radiology and associate director of the Radiation Oncology Center, were named in the October

FYI

APPOINTMENTS/ ELECTIONS

1992 issue of *Good Housekeeping's* listing of the top cancer experts in the U.S. The magazine's medical editors polled more than 350 department chairmen and section chiefs at 110 major hospitals and comprehensive cancer centers nationwide. Of the final compilation of 419 medical and radiation oncologists and surgeons, Perez was cited for his expertise in the treatment of breast cancer, gynecologic cancer, lung cancer, and prostate cancer; Emami, for lung cancer.

James A. Purdy, Ph.D., professor of radiology and associate director of the Radiation Oncology Center, edited *Advances in Radiation Oncology Physics - Dosimetry, Treatment Planning, and Brachytherapy*, published by the American Institute of Physics.

Ali Soleimani-Meigooni, Ph.D., assistant professor of radiology, as invited lecturer at the Imam Khomeini Hospital in Tehran, was interviewed on July 31 by *Keyham*, one of Tehran's major newspapers. The interview focused on the application of physics in medicine and is part of Iran's national effort to increase students' awareness of the various aspects of the medical profession.

Michael W. Vannier, M.D., professor of radiology, director of the Division of Radiology Research, and head of the image processing lab, was named an associate editor for *IEEE Transactions on Medical Imaging*.

Ronald G. Evens, M.D., Elizabeth Mallinckrodt professor of radiology and director of the Institute, was elected to a second term as secretary-treasurer of the Board of Chancellors for the American College of Radiology for 1992-1993.

Louis A. Gilula, M.D., professor of radiology and codirector of the musculoskeletal section, was appointed chairman, 1992-1993, of the Convention Planning Committee for the International Skeletal Society.

Bruce L. McClennan, M.D., professor of radiology and head of abdominal imaging, was appointed chairman of the American College of

Radiology's Committee on Drugs and Contrast Media. One of the committee's projects was the compilation of a manual on iodinated contrast media. McClennan was appointed to the Contrast Registry Steering Committee of the Cardiovascular and Interventional Radiology Research and Education Foundation (CIRREF). He also was appointed to the Food and Drug Administration's Medical Advisory Committee.

Barry A. Siegel, M.D., professor of radiology and medicine, and director of the Division of Nuclear Medicine, was reappointed to a second two-year term as chairman of the Advisory

Committee for the Medical Uses of Isotopes of the U.S. Nuclear Regulatory Commission.

Marilyn J. Siegel, M.D., professor of radiology, was appointed to a three-year term as a member of the Food and Drug Administration's Medical Imaging Drug Advisory Committee.

Michel M. Ter-Pogossian, Ph.D., professor of radiation sciences, was reappointed to a four-year term as a presidential nominee to the Corporation Visiting Committee for the Department of Nuclear Engineering at Massachusetts Institute of Technology. He also was appointed to the Washington University Medical School Admissions Committee for 1992-1993.

IN MEMORIAM

It is with profound sadness that we report the death of our friend and colleague G. Leland Melson, M.D., on November 10, 1992. A recognized authority in the area of ultrasonography, he was professor of radiology and chief of clinical ultrasound at Mallinckrodt Institute.

Dr. Melson was an accomplished teacher, a popular lecturer, and the author of more than 60 scientific journal and textbook articles. He served on numerous boards and committees and was an active member of professional societies, including the Missouri Radiological Society, the Greater St. Louis Society of Radiologists, the American Institute of Ultrasound in Medicine, the American College of Radiology, and the American Registry of Diagnostic Medical Sonographers.

He received his Bachelor of Arts degree with honors in chemistry from Ottawa University, Kansas and his medical degree from Washington University School of Medicine. Dr. Melson completed his residency at the Institute where he was co-chief resident, 1971-1972.




SPOTLIGHT

PROFILES OF THE CHIEFS

SCOTT M. BAKER, M.D.

Coming out of medical school at the University of North Carolina at Chapel Hill, Scott Baker, Diagnostic Radiology's chief resident, set his sights on a common goal of most physicians — a top-notch residency program. But Baker's decision was guided by an additional requirement; his wife Kristin also was searching for a residency program.



"We looked at about seventeen or eighteen programs, all in larger cities with more than one hospital, figuring that a larger city would offer more opportunities for medical positions than smaller cities," says Baker.

The search obviously was a success; Kristin is a fellow in the Barnes Hospital child psychiatry program, and Baker is pleased to have been accepted into "one of the premier radiology programs in the United States as well as one of the most sought after residencies."

Baker, a native North Carolinian, earned his Bachelor of Science degree in zoology from the University of North Carolina at Chapel Hill. Although he is the son of a pediatrician, Baker, flashing a broad smile, says his switch to medicine probably was a result of his not liking the botany portion of his zoological studies. Then, he admits that his interest in radiology stemmed from a high-school physics project on ultrasound.

After his residency is completed, Baker will enter a one-year fellowship in the Institute's abdominal imaging section.

ALLEN B. OSER, M.D.

During his early years in medical school at Harvard, Diagnostic Radiology's Cochief Resident Allen Oser thought that clinical medicine was the right field for him. He went on to complete a medicine/surgery clinical internship at Newton-Wellesley Hospital in Newton, Massachusetts. But, Oser says he chose radiology because he finds the combination of anatomy and the technology of radiology fascinating.


According to Oser, "To me, the most interesting part of medicine is the diagnostic process. In radiology, which is a refinement of that process, I can be at the diagnostic point on a higher percentage of patients."

An Easterner, Oser grew up in Long Island, New York, and earned his Bachelor of Arts degree in biology from Brown University. He

has lived in Indiana and in Kentucky and admits to having a soft spot in his heart for the Midwest — part of which may be because he met his wife, Rachel


Fineberg Oser, M.D., during his residency here at the Institute. She is a third-year resident in diagnostic radiology.

After his residency, Oser will remain at the Institute for a two-year neuroradiology fellowship. He plans to pursue a career in academics, trying his hand at teaching and writing papers, but says he will have to test the waters to see how well he adapts to an academic environment.



JAMES V. PIEPHOFF, M.D.

James Piephoff, M.D., the Radiation Oncology Center's

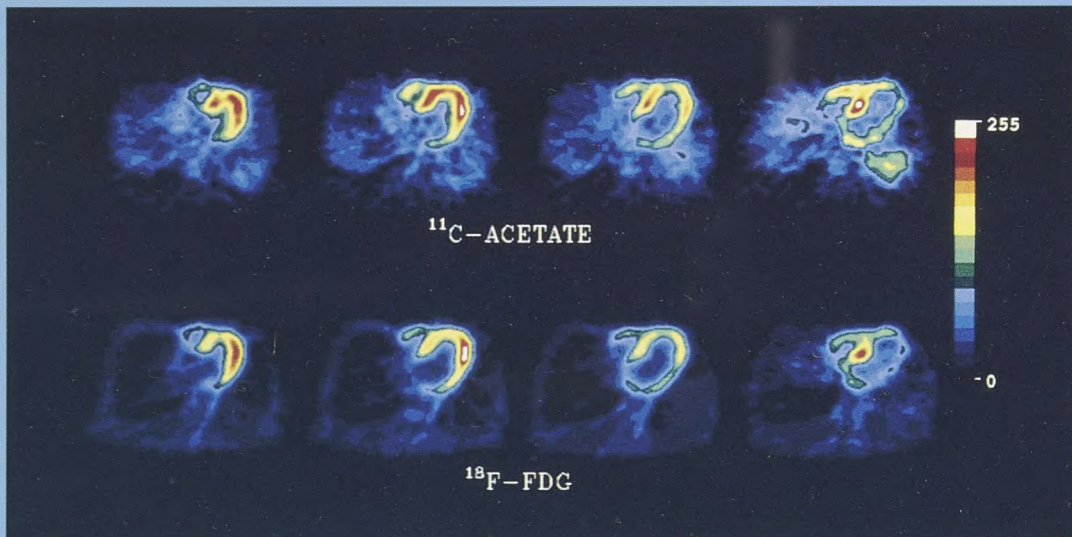


assistant chief resident, has always had an interest in oncology and was drawn to the field of radiation oncology because of the patient care aspect. He hails from South Carolina and received his Bachelor of Science degree in biology from The Citadel in Charleston and his medical degree from the University of South Carolina in Columbia.

Piephoff arrived in the Midwest to complete an internship at St. John's Mercy Medical Center in St. Louis, but coming here also provided an unexpected benefit. He and his wife Cindy, a native St. Louisan and a registered nurse on staff at St. John's, met during that internship and have been married for two years.

Piephoff says he was interested in a residency at Mallinckrodt Institute because of the nationally recognized excellence of MIR's radiation oncology program. After his residency is completed, Piephoff will remain in the Radiation Oncology Center for a one-year fellowship. At the end of the fellowship, the Piephoffs will be heading either to Tacoma, Washington, or somewhere in Hawaii to finish up a three-year obligation to the U.S. Army.

After his military stint, Piephoff's plans are not finalized. "But I would like to get back to the ocean and to the beach, where it's warm," he says. □



Doctor Robert Gropler's research involving positron emission tomography and the tracer F-18 fluorodeoxyglucose (FDG) is an important factor in determining the viability of heart muscle in patients who have had heart attacks. The images on the bottom represent glucose metabolism; on the top, oxygen consumption. Scans on the far right (top and bottom) indicate a reduced correlation between glucose metabolism and oxydated metabolism that is consistent with dead heart muscle.

FOCAL SPOT

MALLINCKRODT INSTITUTE OF RADIOLOGY

MIR
MALLINCKRODT
INSTITUTE OF RADIOLOGY
WASHINGTON UNIVERSITY
MEDICAL CENTER

Administrator
Planning, Marketing and Public Relations
Virginia Trent

Editor
Vicki Kunkler

Design
Purviance & Company
Marketing Communications

Photographers
T. Mike Fletcher
Thomas Murry
Michelle Wynn

Circulation
Ramona "Lisa" Simmons

Focal Spot magazine is published three times a year by the Mallinckrodt Institute of Radiology at the Washington University Medical Center at 510 South Kingshighway, St. Louis, MO 63110.

Permission is granted to reproduce articles contained herein, provided **Focal Spot** magazine of the Mallinckrodt Institute of Radiology at the Washington University Medical Center is credited.

Public Relations Department
Mallinckrodt Institute of Radiology
510 South Kingshighway
St. Louis, MO 63110
(314) 362-2866

© Mallinckrodt Institute of Radiology, 1992

Address Correction Requested

Non-Profit Organization
U.S. Postage
PAID
St. Louis, Missouri
Permit No. 1032

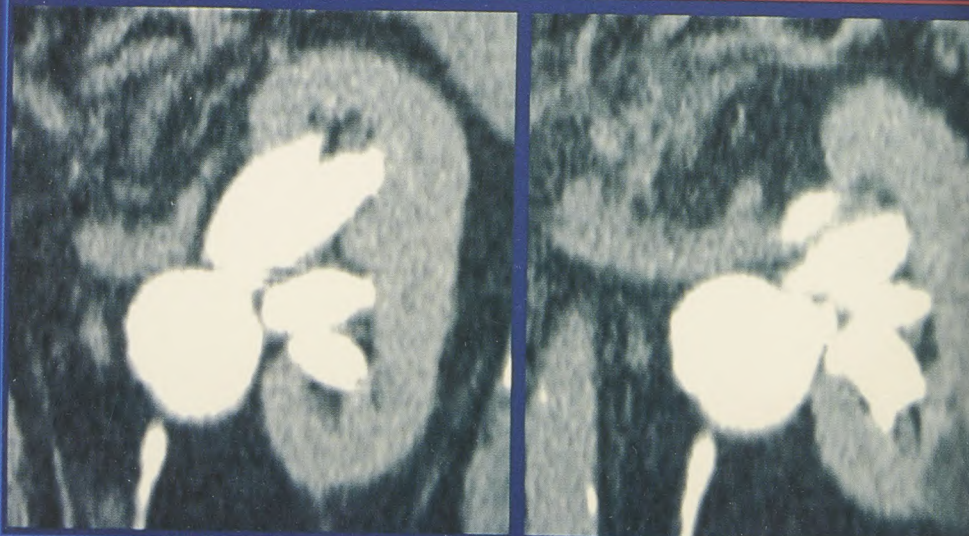
Non-Profit Org
U.S. Postage
PAID
St. Louis, MO
Permit No. 1032

Archives

Serials Dept, Medical Library
Wash U School of Medicine
Campus Box 8132
St. Louis, MO 63110

3958B

MIR UPJ Obst.-- 5mm Spiral



By using multiplanar reconstructions of spiral computed tomography (CT), Drs. Jay Heiken and James Brink and colleagues are able to increase diagnostic confidence in assessing urinary tract abnormalities depicted on conventional CT scans. The image above is a coronal reconstruction showing an obstruction of the left kidney at the ureteropelvic junction.