

Spring 1991

Focal Spot, Spring 1991

Follow this and additional works at: http://digitalcommons.wustl.edu/focal_spot_archives

Recommended Citation

Focal Spot, Spring 1991, April 1991. Bernard Becker Medical Library Archives. Washington University School of Medicine.

This Book is brought to you for free and open access by the Focal Spot at Digital Commons@Becker. It has been accepted for inclusion in Focal Spot Archives by an authorized administrator of Digital Commons@Becker. For more information, please contact engeszer@wustl.edu.

SPRING, 1991

VOLUME 22, NUMBER 1

FOCAL SPOT

MALLINCKRODT INSTITUTE OF RADIOLOGY




**CHARTING
THE FACE**

more than 10
is for special
was "in the
moon during
I sponsored
no's story

MIR
Celebration
...
September 12-14, 1991

•
*Sponsored by
The Mallinckrodt Institute
of Radiology
Washington University School
of Medicine*

•
*at The Hyatt Regency Hotel
at Union Station
Saint Louis, Missouri*




FOCAL SPOT

SPRING, 1991

VOLUME 22, NUMBER 1

MALLINCKRODT INSTITUTE OF RADIOLOGY



6

AGAINST THE ODDS

David Cantrall works where millions of dollars are wagered each year. After Cantrall's heart attack, his doctors did not have to gamble on bypass surgery. A positron emission tomography (PET) scan put the odds in Cantrall's favor.



12

CHARTING THE FACE

Lory Halbrook did not want to look younger. She just wanted to look rested and relaxed. A 3-D imaging process eliminated any guesswork during the cosmetic surgery and gave Halbrook a peek at her new profile.



18

THE HUMAN TOUCH

Vicki Grober is a teacher, friend, advocate, and comforter to patients during their visits to the vascular and interventional radiology department. Spend some time on the job with Grober — a radiology nurse.



2

SPOT NEWS

24

FYI

31

REFLECTIONS

32

CELEBRATION

MIR

MALLINCKRODT

INSTITUTE OF RADIOLOGY


WASHINGTON UNIVERSITY

MEDICAL CENTER

ON THE COVER:

Research into a new three-dimensional facial scanning technology holds great promise for the study of the changes the facial structure undergoes before, during and after cosmetic surgery. Photograph by T. Mike Fletcher.

SPOT NEWS



Norman Hente

Joel S. Perlmutter, M.D.

Perlmutter Receives First Koster Award

Joel S. Perlmutter, M.D., associate professor of neurology and research associate professor of radiology, has been designated as the Mattie Lou Koster Endowment Scholar, sponsored by the Mattie Lou Koster Endowment Fund of the Benign Essential Blepharospasm Research Foundation (BEBRF). He is the recipient of a one-year, \$30,000 research grant for the study of benign essential blepharospasm (BEB).

A relatively new organization as far as research foundations are concerned, the BEBRF was established in July of 1981 to undertake, promote, develop, and carry

on the search for a cure for Benign Essential Blepharospasm and other related diseases and infirmities of the facial musculature. Blepharospasm, the involuntary, forceful contraction of the eyelid muscles, affects adults and is two to three times more prevalent among women than among men. Extreme light sensitivity along with prolonged, frequent eyelid spasms may eventually lead to functional blindness in BEB patients.

According to Perlmutter, "Presently, all treatments for blepharospasm are symptomatic. Some form of relief can be attained with oral medication, by selectively destroying nerves in the muscles around the eyes, by surgically removing the muscles surrounding the eyes, or most effectively with injections of botulinum toxin into the muscles around the eyes."

Although the actual cause of the disease is unknown, the symptoms suggest a neurological dysfunction involving a chemical imbalance in the motor centers of the brain. Utilizing positron emission tomography (PET), Perlmutter and his team of researchers will study responses to sensory motor stimuli and will measure the brain's blood flow during different processes in a group of 30 patients, half of whom have blepharospasm.

Low Risks, High Benefits

At the Fifth Annual Daniel R. Biello Memorial Lecture on February 11, S. James Adelstein, M.D., Ph.D., shared some reassuring data on the risks of ionizing radiation. Adelstein, who is the Paul C. Cabot professor of medical biophysics at the Harvard Medical School, spoke on "Ionizing Radiation and Health: What Do BEIR V, UNSCEAR 1988, and ICRP 1990 Mean to the Practicing Radiologist?"

According to Adelstein, reports issued by the National Council Committee on the Biological Effects of Ionizing Radiation (BEIR), the United States Scientific Committee on Effects of Atomic Radiation (UNSCEAR), and the International Commission on Radiologic Protection (ICRP) make estimations of radiation effects.

Adelstein pointed out that estimations of risks have been based on the principal data available from the effects of the atomic bomb in Japan following World War II. Initial projections for cancer risks due to radiation were set on unrealistic rationale. Now, 40 to 45 years after Hiroshima and Nagasaki, that data has been reviewed and lower risk levels have been released.


"The good news," says Adelstein, "is that background or naturally occurring radiation offers higher levels of radiation than do conventional X rays. The high benefits provided by diagnostic X rays far outweigh the low risks involved."

SPOT NEWS

McClennan Appointed to AHCPR Panel

Prompted by his nationally recognized research in diagnosing urinary tract diseases and with the recommendation of the American College of Radiology, Bruce L. McClennan, M.D., professor of radiology and head of abdominal imaging, was appointed to the Agency For Health Care Policy and Research (AHCPR) panel, which was convened to establish guidelines for diagnosis and treatment of benign prostatic hypertrophy. As the only radiologist on this panel and the only radiologist involved with any of the first seven panels, McClennan will play a key role in generating policy statements concerning the appropriateness of urinary tract imaging in the diagnosis and follow-up of this disease.

The AHCPR, one of eight agencies of the Public Health Service within the Department of Health and Human Resources, absorbed the health services research and technology assessment functions of the now defunct National Center for Health Services Research. AHCPR also is responsible for the dissemination of research results, the development of databases, and the development of practice guidelines.



Herb Weitman

Evens Elected to Office

Ronald G. Evens, M.D., director of the Institute, was elected secretary-treasurer of the Board of Chancellors for the American College of Radiology (ACR). Evens, widely recognized as an authority in the field of socioeconomics, is serving his second term on the Board. His initial appointment was in 1988.

The Board of Chancellors is the governing body of the ACR, which has more than 20,000 members and

Ronald G. Evens, M.D.

fellows in diagnostic and therapeutic radiology, radiologic physics, and related disciplines. The ACR, founded in 1924 as the principal organization serving radiologists, promotes the advancement of the science of radiology, improves radiologic service to the patient, studies the economic aspects of the practice of radiology, and encourages improved and continuing education for radiologists and allied professional fields.

Vannier Appointed to Editorial Board

Michael W. Vannier, M.D., director of the Division of Radiology Research and head of the image processing lab, has been appointed to the editorial board of *Radiology*, a leading radiologic scientific journal that is devoted to clinical radiology and allied sciences.

According to Stanley S. Siegelman, M.D., professor of radiology at Johns Hopkins University School of Medicine and editor of *Radiology*, "Doctor Vannier's appointment to the editorial board is in recognition of his superb performance as a reviewer. In addition to reviewing manuscripts, board members regularly input their opinions and suggestions for appropriate material to be solicited. Doctor Vannier will be a valuable asset to our publication."

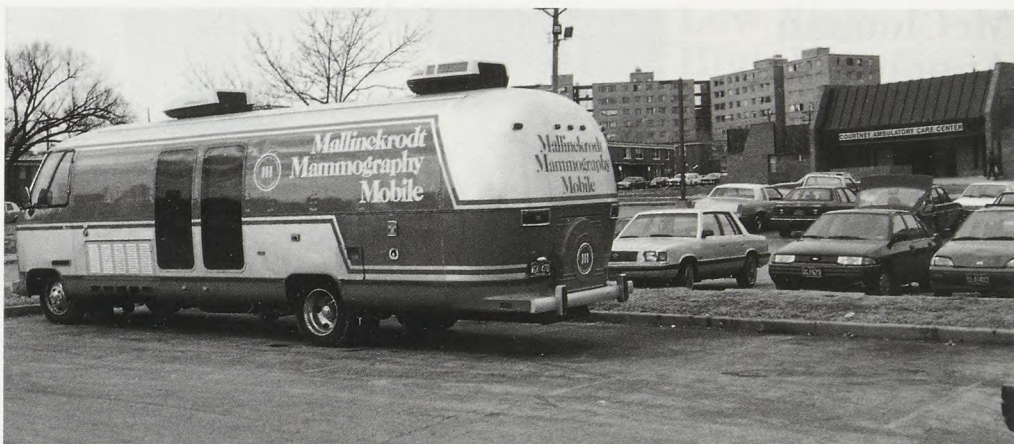SPOT NEWS

Melson Member of NIH Consensus

G. Leland Melson, M.D., professor of radiology and chief of diagnostic ultrasound, was one of 14 practicing physicians and biomedical investigators who served as panel members for the National Institutes of Health (NIH) Consensus Development Conference on Diagnosis and Management of Asymptomatic Primary Hyperparathyroidism. The Conference was sponsored by the NIH Office of Medical Applications of Research and the National Institute of Diabetes and Digestive and Kidney Diseases.

Approximately 100,000 new cases of hyperparathyroidism (HPT) occur each year in the United States, with diagnosis twice as prevalent among women than men. The disease, an abnormally increased activity of the parathyroid glands that secrete the hormone regulating metabolism of calcium and phosphorous, produces bone mass loss and changes in the skeletal system. HPT may cause or accelerate hypertension, renal deterioration, peptic ulcer disease, and depression. The risk of HPT increases with age and occurs most often in postmenopausal women.

Considering presentations by experts in this field and a review of the literature, the panel concluded that surgery is the only currently effective treatment for HPT. However, patients whose calcium levels are only mildly elevated and whose renal and bone status are close to normal may be



On February 15, the Mallinckrodt Mammography Mobile received patients at St. Louis Regional Medical Center's Lillian E. Courtney Ambulatory Care Center during a press conference announcing expansion of MIR's free mammography screening for the economically disadvantaged.

safely followed medically. These patients should be monitored semiannually for significant increases in calcium levels, for deterioration of kidney function and development of kidney stones as well as for bone mass changes, which mandate surgery. According to the panel, using imaging techniques to locate benign tumors prior to initial surgery is not cost effective nor is the success of surgical therapy improved by these tests. However, the tests may be useful if previous surgery was not successful.

The panel also called for a randomized, multicenter clinical trial to compare surgical versus medical management of HPT.

Five-year Accreditation Earned by School of Radiography

The Washington University School of Radiologic Technology at Mallinckrodt Institute of Radiology has been awarded a five-year accreditation, the maximum duration recommended by the Joint Review Committee on Education in Radiologic Technology (JRCERT) in collaboration with the American College of Radiology and the American Society of Radiologic Technologists. The accreditation also is recognized by the Committee on Allied Health Education and Accreditation of the American Medical Association.

In order to be accredited, documentation must be submitted to the Joint Review Committee showing that the program adheres to the operating guidelines, known as Essentials. These guidelines cover six specific areas: sponsorship, resources, curriculum, stu-

dents, operational policies, and continuing program evaluation.

According to Director of Technical Education and Chief Technologist for Quality Assurance Michael D. Ward, R.T., M.Ed., FASRT, who is a 1976 graduate of the program, "The School, now in its forty-first year, not only adheres to the Essentials but goes far beyond its requirements. We teach not only the required curriculum but other courses as well, such as Introduction to MRI, Digital Imaging Processing, and introductions into some of the other specialty modalities like ultrasound. Our graduates are prepared to assume leadership roles and staff positions in any size medical center or imaging facility in the country."

SPOT NEWS

Brink Named Acting Technical Administrator

The responsibility for diagnostic technical operations and facilities at the Institute has been placed in the capable hands of Chief Technologist Gary Brink, R.T., B.S., FASRT. As acting technical administrator, he will coordinate all construction and equipment development programs for clinical services.

According to Ronald G. Evens, M.D., director of the Institute, "Gary brings to this position many years of experience and knowledge about the Institute. His personal expertise and abilities will greatly enhance his administration of the important tasks he will be undertaking."


Brink received his bachelor's degree from Washington University and is a 1967 graduate of The Washington University School of Radiologic Technology at Mallinckrodt Institute of Radiology. He joined the MIR staff in 1967 and was appointed chief technologist as well as assistant director of education in 1970.

Improved CT Scanners Prompt Collaboration on Research Project

Contrast-enhanced computed tomography (CT) of the liver is presently the result of many methods of administering intravenous (IV) contrast material. These methods were developed when most CT scanners took four to six minutes of imaging time. Newer, state-of-the-art CT scanners are capable of performing the same examination in less than half that time, usually in one to two minutes.

Reduced imaging time has prompted an MIR research project to determine the volume and speed of injection for optimal enhancement. This determination has the potential to lower the quantity of contrast media used, a benefit that can be passed on to the patient in reduced costs. Funded by a \$15,000 grant from Mallinckrodt Pharmaceuticals, a major supplier of IV contrast media, the study involves 210 in- and outpatients — males and females who are 18 years of age or older and all of whom require contrast-enhanced CT scanning of the abdomen.

Researchers Jay P. Heiken, M.D., codirector of computed body tomography and principal investigator for the study; Bruce L. McClenan, M.D., head of abdominal



Norman Hente

Jay P. Heiken, M.D.

imaging; Stuart S. Sagel, M.D., codirector of computed body tomography; James A. Brink, M.D.; Howard P. Forman, M.D.; and Joseph DiCroce, B.S., B.A., R.T., will conduct the study in two phases: the comparison of contrast material injection rates and the comparison of contrast material volumes. A quantitative and qualitative analysis of all studies will be performed; each study will be reviewed without knowledge of the IV contrast material administration protocol used in that particular patient.



David Cantrall's degree of fitness, which is a benefit of his physically demanding job, plus his age were two important factors in his rapid recovery from coronary artery bypass surgery.



AGAINST THE ODDS

by Vicki Kunkler

David Cantrall, a resident of Collinsville, Illinois, is not a gambling man even though he works as a carpenter at Fairmount Park, a nearby racetrack where trotters and Thoroughbreds run year-round. But if you had asked him a year ago what he thought his odds were for having a heart attack and coronary bypass surgery, he would have said, "A million to one."

In January of 1990, that bet became odds-on-even for the 30-year-old Cantrall after a medical team determined that he had survived a heart attack. The next gamble for Cantrall: Was the heart muscle alive? Would bypass surgery or a procedure called coronary angioplasty, which opens up the blocked artery with a balloon-like device, be of benefit or an unnecessary procedure?

This time the odds were on Cantrall's side. Researchers at Washington University's Mallinckrodt Institute of Radiology and the Department of Internal Medicine are collaborating on a study using positron emission tomography (PET) to measure metabolic activity in relation to blood flow in the heart. What does this mean to a patient who has coronary artery disease? Simply put, if the blood flow is restored to the heart muscle, will that muscle begin functioning again?

AGAINST THE ODDS

Coronary bypass is the most common major surgical procedure in the United States, with more than 200,000 operations annually. There are more than 350,000 patients annually who undergo coronary angioplasty.

According to Robert J. Gropler, M.D., instructor in radiology at the Institute and principal investigator of the research team, "The most commonly used procedures clinically are suboptimal in predicting when abnormally functioning myocardium will benefit from surgery or angioplasty. PET is a unique imaging tool. It allows us to look at the biochemistry and the physiology of heart muscle."

The first PET machine to be used in human studies was developed at Mallinckrodt Institute in the early 1970s by a team of researchers led by Michel M. Ter-Pogossian, Ph.D. With PET, the researchers were able to produce images of physiology rather than of anatomy as with conventional X rays, computed tomography (CT), ultrasound, or magnetic resonance imaging (MRI). Short-lived, radioactive nuclides of carbon, nitrogen, and oxygen are used to prepare radiolabeled compounds normally found in the body. These tracers then measure the body's specific biochemical or physiological pathways. There are four major radionuclides used (oxygen-15, carbon-11, nitrogen-13, and fluorine-18) to synthesize radiopharmaceuticals for monitoring specific biologic processes in the body in PET studies.

Gropler, working with Barry Siegel, M.D., director of the Division of Nuclear Medicine at MIR, and Edward M. Geltman, M.D., associate professor of internal medicine at Washington University School of Medicine, uses ^{18}F -fluorodeoxyglucose (FDG) to measure how much sugar the heart metabolizes and ^{11}C -acetate to measure how much oxygen is directly used by the heart. The correlation between blood flow, glucose utilization, and, particularly, overall

"...PET is a unique imaging tool. It allows us to look at the biochemistry and the physiology of heart muscle."

oxygen consumption in the heart are key factors in the study. If the myocardium is metabolically active, (i.e., it is still using glucose and oxygen even though blood flow is decreased), bypass surgery or angioplasty probably will benefit the patient. But, if the myocardium is metabolically silent and, thus, not using glucose and oxygen, it is less likely that bypass surgery or balloon angioplasty will be of benefit to the patient.

"The main goal of our study," says Gropler, "is to measure metabolic activity in relation to blood flow in damaged heart muscle. If the muscle is metabolically active, it may well respond to restoring blood flow by angioplasty or surgery."

Coronary artery disease annually affects more than 6 million people in the United States. With

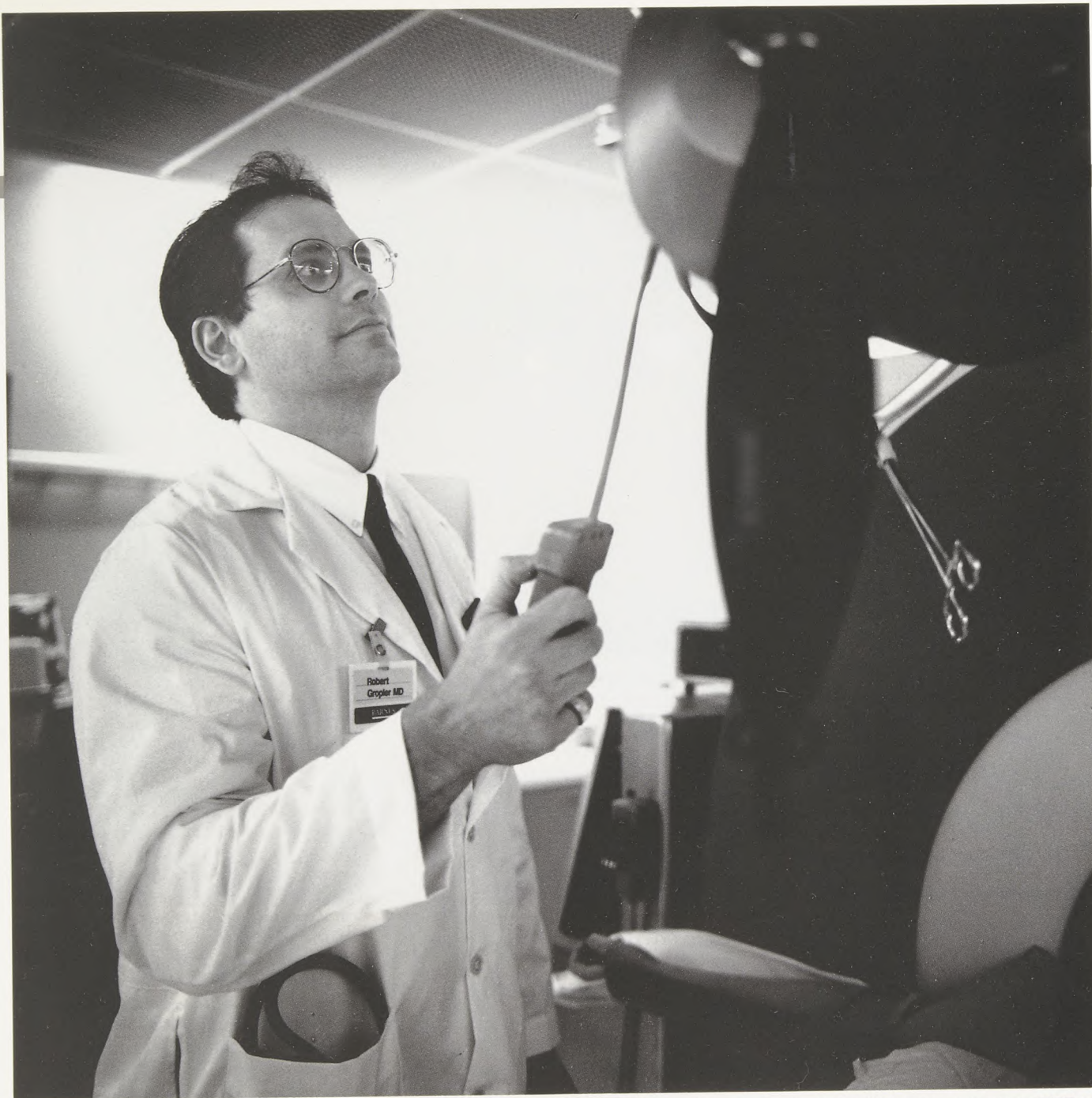
this disease, the arteries that supply blood to the heart muscle are lined with fatty deposits that harden and obstruct the arteries. The resulting reduction in blood flow can lead to chest pain or a heart attack, which kills part of the heart muscle. According to the American Heart Association, major risk factors that promote such fatty accumulations in blood vessels are heredity, high blood pressure, smoking, increased levels of cholesterol in the blood, and the presence of diabetes mellitus.

Based on these risk factors, David Cantrall had more than a 50 percent chance of developing coronary artery disease. Although the lean, wiry Cantrall did not have diabetes and had no family history of heart disease, he did fit into the other categories.

"I started smoking cigarettes when I was about sixteen years old," says Cantrall. "Plus, I was diagnosed with high blood pressure when I was a teenager."

"And he loves all the high-cholesterol foods, like eggs and red meat," adds Cantrall's wife, Sue.

Cantrall had not been feeling well, he recalls. Nothing major, just not up to par. Then one evening, a little over a year ago, he experienced some numbness in his left arm. It was worrisome enough to prompt a trip to a nearby hospital. His physician suggested that Cantrall be admitted to Barnes Hospital for more extensive tests and sent him to Craig K. Reiss, M.D., assistant professor of medicine and director of Barnes Comprehensive Cardiology Group.



T. Mike Fletcher

If the myocardium is metabolically active, bypass surgery or angioplasty probably will benefit the patient.

It was to be an 18-day stay where, as Cantrall says, "I had every test imaginable. The doctors certainly were thorough." An electrocardiogram (EKG) showed an "old" heart attack with damage to the heart muscle.

There are three major blood vessels that feed the heart: one on the right, one in the middle, and one on the left. These vessels are about five inches long and no larger in diameter than a soda straw. A cardiac catheterization, in which a long, fine catheter is fed by X-ray guidance into the artery to determine the location of the obstruc-

In support of his research using PET to study coronary artery disease, Robert Gropler, M.D., received the American Heart Association's prestigious Clinician-Scientist Award.

tion, showed the left anterior descending artery was virtually 100 percent blocked.

Cantrall then underwent angioplasty in an attempt to open the blocked artery. When the procedure proved to be unsuccessful,

AGAINST THE ODDS

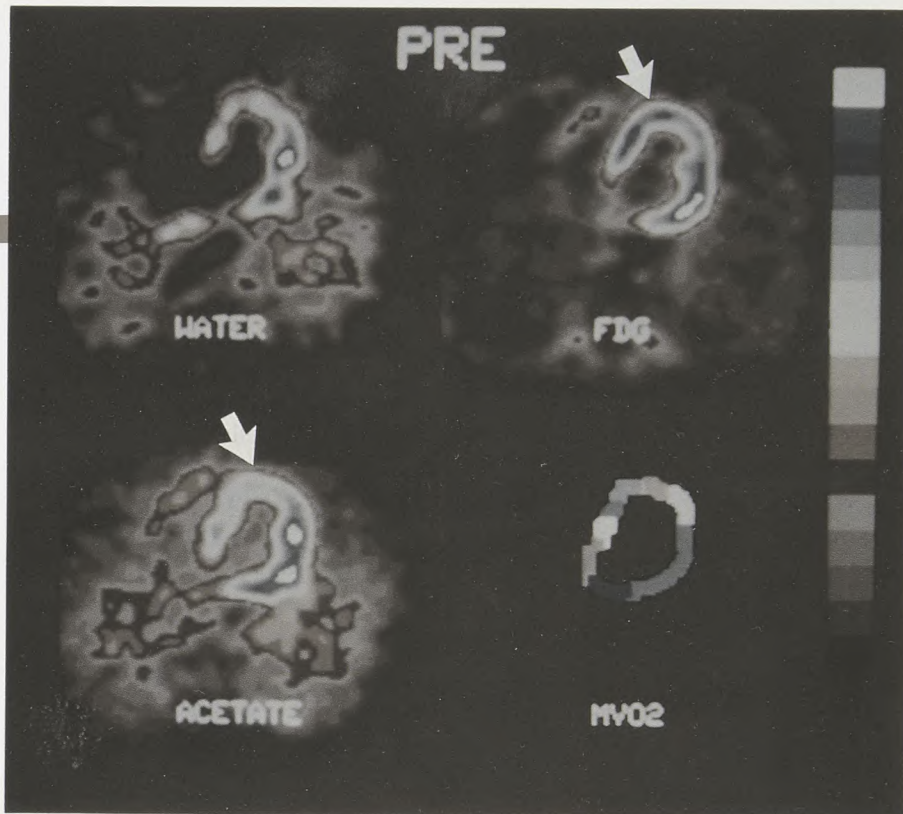
coronary bypass surgery became another option. But the heart muscle's viability was a major question.

In order to determine if the muscle was alive, Cantrall underwent a thallium treadmill test, where an intravenous injection of the radioactive isotope thallium is used to map blood flow to the heart and to determine if the myocardium is alive or dead. These results were equivocal. A radionuclide ventriculogram, which measures the pumping capability of the heart, provided some good but not decisive news. The

“David Cantrall exemplifies the potential of what this technology can do.”

pumping range of Cantrall's damaged heart muscle had been decreased by 20 percent — a moderate reduction that suggested the heart muscle was alive.

A PET scan was included in the protocol. This time there was definitive information. According to Gropler, blood flow was reduced to the area of the myocardium fed by the diseased artery, but glucose and oxygen were being used consistently. This suggested the muscle was damaged but still alive. Single artery bypass surgery was a promising option for David Cantrall.



On Thursday, February 8, 1990, Cantrall was in the operating room where surgeons made an incision the length of the breast bone to open the chest cavity. A section of the mammary blood vessel was removed and attached to the coronary artery, bypassing the blockage. This procedure detours the blood around the blocked or damaged arteries, improving the flow of blood to the heart.

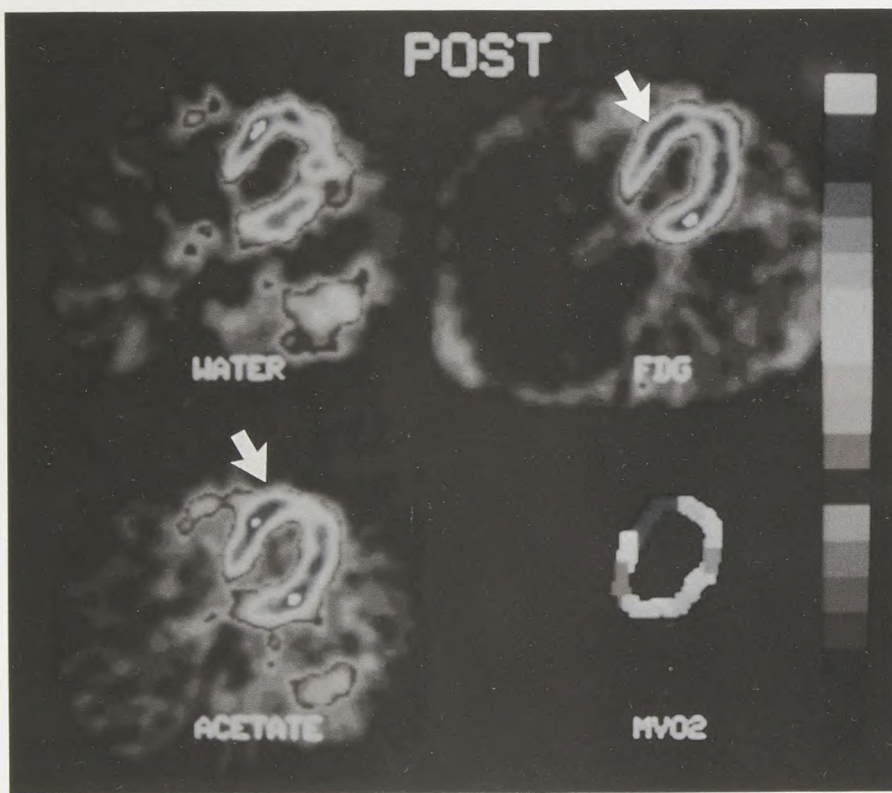
“Everything went very well,” says Cantrall. “I was up, walking around on Sunday following the surgery.”

Cantrall went home to Sue and their three daughters on St. Valentine's Day, February 14, 1990. “That was the best Valentine's gift I could have received,” says Sue.

He was told to “take it easy for awhile.” “That was the hardest part of the whole thing,” says Cantrall. “I have a hard time just sitting.”

At his six-week checkup, the results of the EKG and blood tests were good. A PET reevaluation taken twelve weeks after the coronary bypass bore the best news of

On each PET image, (shown above and on opposite page), blood flow (left), glucose metabolism (center), and oxydated metabolism (right) can be seen in David Cantrall's heart before and after bypass surgery. The slight decrease in blood flow in the front, or anterior portion, of the heart (shown at the top of each image) with preservation of glucose and oxydated metabolism (arrow) indicated heart muscle that was still metabolically active and, thus, viable. After successful bypass surgery, blood flow to the anterior portion of the heart returned to normal, and glucose and oxydated metabolism continued to be preserved.



all. Both the heart's pumping ability and metabolism rate were back to normal. The bypass surgery was a success.

"David Cantrall exemplifies the potential of what this technology can do," says Gropler.

Within three months after surgery, Cantrall was back at work. He takes a medication for hypertension and also a blood thinner. He has no limitations as to activity but finds that he does tire more easily. Presently, he has no restrictions on his diet until he regains some of the weight lost during his illness. However, he is cautioned to monitor his intake levels of salt, cholesterol, and saturated fats to lower the risk of recurrence of coronary disease.

"That won't be a problem," says Sue. "I do the cooking and I can control most of what he eats."

However, Cantrall readily admits there is one restriction that is causing a major problem for him. Despite his physician's warning, Cantrall still smokes "more than a pack of cigarettes a day."

To date, the PET study includes 30 patients, half of whom underwent coronary bypass surgery; the other half, angioplasty.

Gropler is excited about the preliminary data. "Our hypothesis is holding true, we are seeing that the heart's ability to metabolize oxygen is an important factor in determining if the heart muscle will remain viable," he says.

"Our next step is to offer this approach to patients on a routine clinical basis rather than on a research basis," adds Gropler. "Every aspect of this research, which is incredibly complex, has been developed at the Institute. Doctor Michel Ter-Pogossian, of course, developed PET; Doctor Michael Welch, who is director of our Division of Radiation Sciences, developed the syntheses for the tracers; and Doctor Steven Bergman, who is a cardiologist at the School of Medicine, validated the tracers used in the study. Mallinckrodt Institute is the premier place to do this type of research." ■



Lory Halbrook is one of approximately 50,000 people annually in the United States who undergo facelifts. Of the total number of facelifts, 88 percent are performed on women; 12 percent, on men.



CHARTING THE FACE

by Michaele Gold

The

creases in Lory Halbrook's forehead bothered her. They made her

look tired, she thought, as did the furrows between her

eyebrows. But at 41 Halbrook is anything but tired. In fact, her

family describes her as having two speeds: fast and faster.

Although her husband Roger thought she was still beautiful, she

wanted to look as energetic as she felt. For Lory Halbrook it was


time to do something about it.

CHARTING THE FACE

Halbrook of Festus, Missouri, made an appointment with her doctor to try collagen injections to plump up the skin where the lines were. He suggested that she investigate all her options and referred her to Leroy Young, M.D., professor of plastic and reconstructive surgery at Washington University School of Medicine. Little did she know she would become the first facelift surgery candidate to participate in research into three-dimensional craniofacial imaging at the Mallinckrodt Institute of Radiology (MIR). "I fell into a rose bucket when I came to Doctor Young," she says.

Halbrook had always said that when the time came to have a facelift, she would know it. "I really care about being fit and feeling good," she says, "and to me, part of feeling good is looking good." Despite her demanding job as director of human resources at Jefferson Memorial Hospital in Crystal City, or perhaps because of it, Halbrook is committed to regular fitness workouts. Halbrook, her husband, and their 13-year-old son Nick work out at the South County YMCA four nights a week.

In her consultation with Young, Halbrook discussed the changes she wanted to see. "Basically, I wanted to look refreshed, as though I'd come back from a long vacation," she says. Young emphasizes that a frank discussion of reasonable expectations prior to surgery is crucial and that emotional stability is one of the most important factors to be established before any aesthetic surgery should be undertaken. Fortunately, Halbrook was not expecting perfection. A facelift can enhance



T. Mike Fletcher

Leroy Young, M.D.

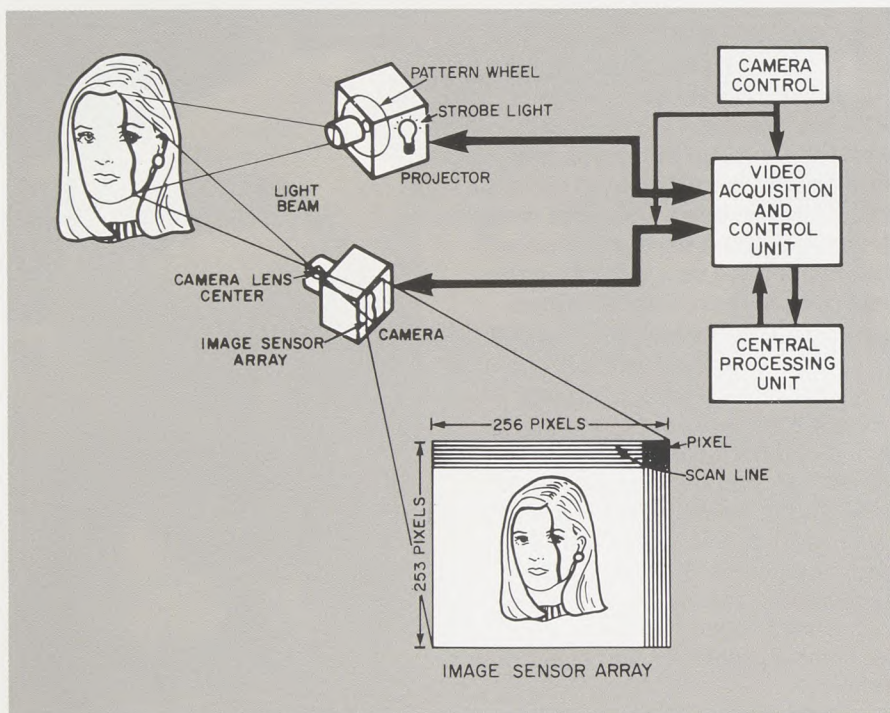
"Basically, I wanted to look as though I'd come back from a long vacation."

appearance and renew self-confidence, but the rest is up to the patient.

After learning about all of her options, she decided to have them all: a forehead lift for the creases across her brow, eyelid surgery to remove the hood of skin on her upper eyelids, removal of the excess cartilage from the tip of her nose, a tiny chin implant to strengthen her jawline, and, finally, a facelift.

Because Halbrook decided to have extensive cosmetic surgery, Young concluded that her participation in the 3-D facial-scanning research would yield important information for the project.

Led by Young and Michael W. Vannier, M.D., professor of radiology and director of radiology research at MIR, the project represents an important phase in ongoing research into identifying medical applications for three-dimensional imaging. Vannier is widely recognized for his work in craniofacial and cardiac three-dimensional reconstructions to enhance diagnostic procedures and presurgical treatment planning. In particular, it was Vannier's expertise in 3-D imaging of



congenital facial deformities that brought a small St. Louis company called Cencit, Inc. to his 3-D image-processing laboratory door.

Originally formed in 1983, Cencit, Inc. developed a 3-D shape-sensing technology that could replicate the human head and facial features. The intention was to create a new market for portrait sculptures, which, for a time, were sold at several shopping malls around the country. Under Vannier's guidance, software and techniques were developed to convert the existing sensing device into a medical facial-surface scanner.

Vannier and Young hope to offer plastic surgeons an objective way of planning the best surgical technique for each patient, and of accurately predicting the long-term affects of cosmetic surgery on the patient's appearance. "By studying the skin's surface in 3-D, we expect to measure the size and shape of the face, to compute differences due to surgical interventions, and to assist in planning treatment before and in helping characterize swelling after surgery," says Vannier.

"Until now achieving what is considered attractive—in other words predicting beauty—was based on looking just at a surface profile and dividing the face into thirds. Now, with this technology we can obtain an entire 3-D data set, and with that, a much more thorough description of a particular face," explains Vannier.

Ultimately, Vannier sees great potential uses for this new technology including assessing scoliosis, radiation therapy treatment planning, and assessing weight loss.

Three-dimensional facial surface data is a four-step process:

1. First, the projector fires a strobe light, creating a profile of the subject's face.
2. The profile is then captured by the digital camera.
3. The camera, the pattern wheel containing the profile, and the strobe light are controlled and synchronized by the video acquisition and control unit.
4. After all the images are collected, a central processing unit creates 3-D surface data.

Having decided to participate in the facial-scanning research project, Halbrook agreed to the project protocol. She would have three scans: one just before her surgery, one immediately after, and a final scan two weeks after her surgery.

Accordingly, Halbrook arrived three days before her surgery to have her facial features mapped. The scanner is a free-standing, geodesic-shaped structure that looks like a photo booth. Inside, arrayed around the electronically controlled chair, are six cameras and six strobe light projectors. Ordinary white light is used to produce structured patterns, appearing as a grid projected onto the face. The patterns are identified and processed into 3-D data with

CHARTING THE FACE

special computer algorithms adapted for medical applications in Vannier's laboratory.

As Halbrook sat on the chair for her first scan, someone asked if she would miss her dimples. Not one to mince words, she said, "At sixteen they were dimples; now they're lines."

When Halbrook was settled into the chair, the scanner's operator, Gulab Bhatia, M.S., research

"... with this technology we can obtain an entire 3-D data set, and a much more thorough description of a particular face."

engineer, pressed a button activating the strobe lights and cameras. Bhatia, the system's original software designer, knew the importance of this first baseline scan. It would produce data to compare with changes measured one day after surgery and with those measured two weeks after surgery. The information would ultimately show how much swelling did or did not occur and would test, in addition, the effectiveness of the antismoothing drugs prescribed for Halbrook.


After processing the data, 250,000 points on Halbrook's face were recorded and digitized.

Three days later, Halbrook was admitted to Barnes West County Hospital as a 23-hour outpatient. Her surgery began, after she was fully anesthetized, with the forehead lift and an incision right at the hairline across the top of the forehead. The skin was gently separated from the muscle and then pulled upward, lifting the eyebrows and eyelids and softening horizontal creases at the top of the nose and in the forehead.

Next on Halbrook's surgical agenda was the eyelid surgery, called blepharoplasty, to remove the excess skin hooding her upper lids. Young made incisions in the upper eyelids following natural lines and creases, extending the incision into the crow's feet at the eyes' outer edges. He then removed exposed fat and excess skin.

Following eyelid surgery, Young performed Halbrook's nasal surgery, making incisions inside the nostrils and trimming some cartilage from the sides and tip of her nose. Then Young began Halbrook's facelift, first on one side of the face, then on the other. Incisions are sometimes individualized, but in most cases, like Halbrook's, the incision starts inside the hairline at the temples, continues downward in a natural line around and close to the earlobe and extends into the back of the scalp or nape of the neck. A small incision frequently is necessary under the chin to provide access to excess skin. In Halbrook's case, the chin incision also served as an opening through which Young inserted the tiny chin implant.

The surgery normally takes four to six hours and there usually is some pain afterward. For Halbrook, the pain was minor and easily controlled with Tylenol III.





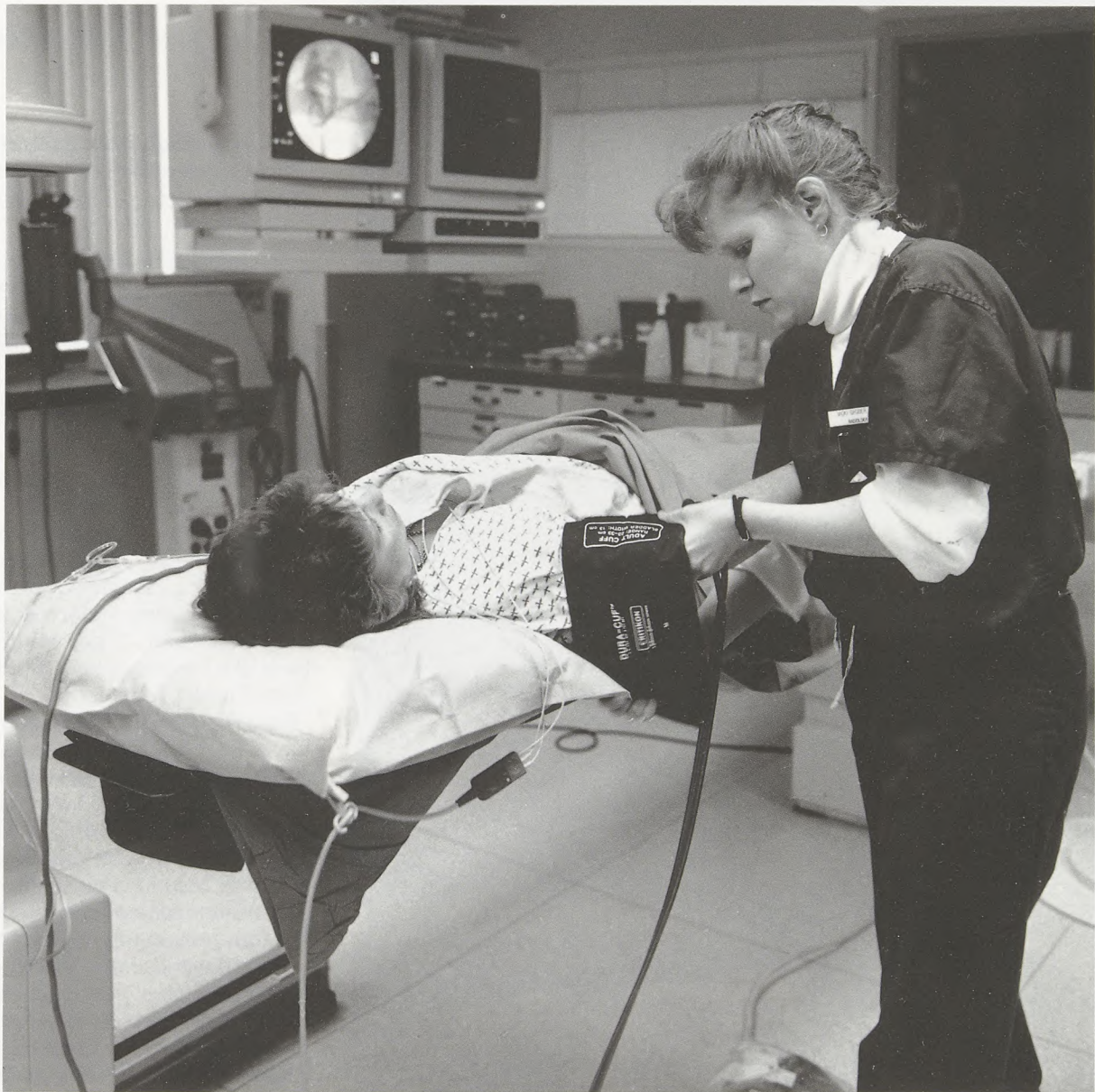Michael Vannier, M.D., is internationally known for his work in 3-D image processing.

The next morning, Halbrook was released from the hospital, and she and her husband arrived bright and early at MIR's 3-D imaging laboratory for her second facial scan. This scan would measure Halbrook's altered face and allow doctors to study the various changes, including swelling, that her facial tissues would undergo immediately after surgery.

With the second scan completed, and her image displayed on the computer screen, Halbrook was duly impressed. "They said I'd look like I was in a fight and lost. I think I look pretty good." "Even though I'd always said I'd have a facelift when the time came," she adds, "I was a bit nervous when I realized how much I was having done. But then I felt privileged to be part of research that may help kids born with facial deformities or scoliosis and to be the first person to participate."

Two weeks later, Halbrook returned for her third scan, wearing her full complement of makeup. All her sutures had been removed and the swelling had gone down. But best of all, her dimples looked like real dimples again. ■

T. Mike Fletcher



T. Mike Fletcher

■

The Human Touch


By Joe Mueller

Vicki Grober, R.N., moves from cabinet to cabinet gathering instruments for the day's first procedure, a renal arteriogram. She arranges tubes and wires on sterile trays and, after reinspecting the instruments, strides to the waiting area to greet patients arriving at Mallinckrodt Institute of Radiology's vascular and interventional radiology department.

■

As a radiology nurse, Grober has few idle moments. Her undivided attention is focused on serving the patient. During procedures, Grober checks vital signs by watching monitors that track heart beat, oxygen saturation, and blood pressure. She also watches for any changes in the patient's appearance or ability to speak. A few beads of sweat or a slightly slurred word could indicate anything from oncoming nausea to cardiac arrest. Before the procedure, throughout the examination, and during the recovery period, Grober is a teacher, friend, advocate, and comforter.

The Human Touch



T. Mike Fletcher

....teacher, friend,
advocate, and
comforter.



T. Mike Fletcher

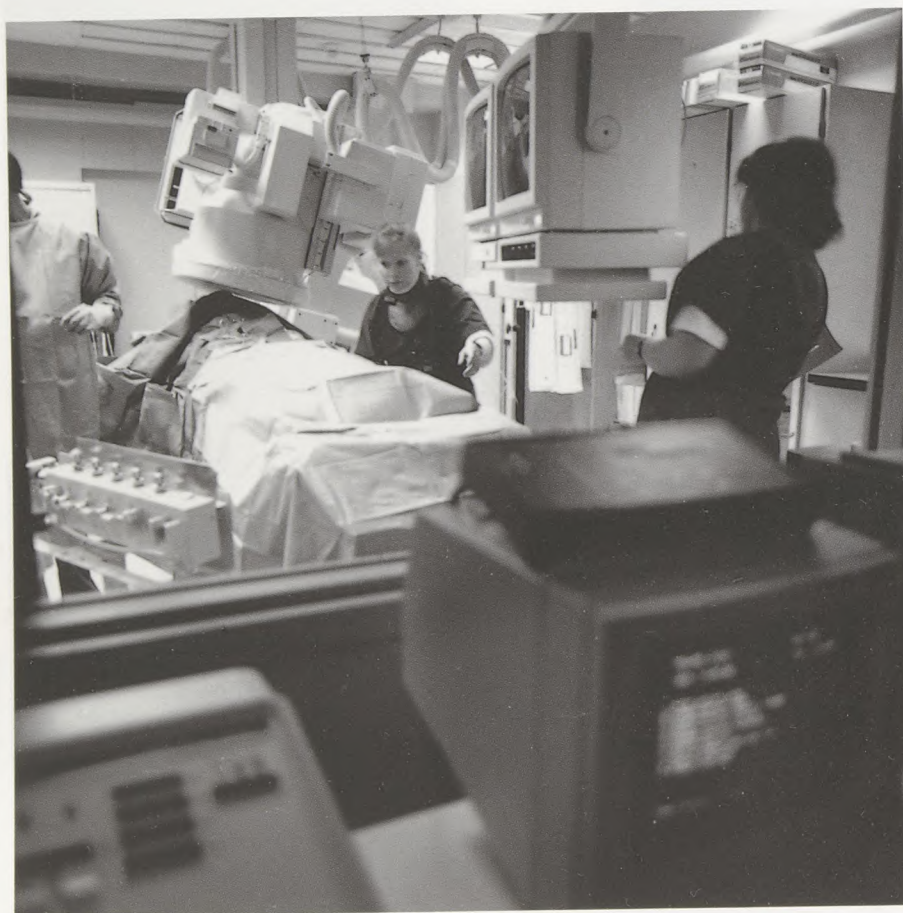
On the move again, Grober checks the chart of her first patient, John Fatchett, and then hurries around a corner, grabbing for the telephone. The 20-second conversation sends her on a brisk walk to the pharmacy, some eight floors away. Returning to the waiting area, Grober goes directly to the patient to start an intravenous line.

Grober then rechecks Fatchett's vital signs and makes sure his consent forms have been signed. Fatchett, an outpatient, lost a kidney to cancer eight years ago. His renal arteriogram will check the blood flow to his remaining kidney. Grober carefully explains the procedure to Fatchett before he is transported into an examination room. He is lifted onto an examining table where a C-shaped piece of X-ray equipment, called a C-arm, surrounds Fatchett's chest

and abdominal area. A cylinder, the size of a barrel, intensifies the images. In an adjacent control room, technologists and radiologists make the necessary preparations for the scans.

Alone in the examining room, the only sound the patient hears is the hum of computers and monitors. But in the midst of the high-tech equipment and medical environment, Grober adds the human touch by softly humming a Nat King Cole tune when she comes into the room to adjust Fatchett's sterile drapes.

"I really like to sing very softly to my patients," she says. "None of them have told me to quit ... yet."



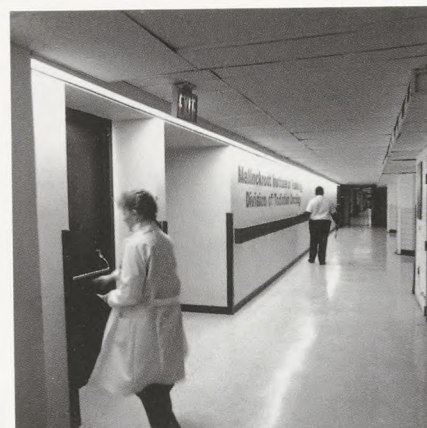
T. Mike Fletcher

Grober calls her patient Mr. Fatchett, until he asks to be called John. "I always address patients by mister, miss or missus, unless they allow me to be on a first-name basis," she says. While waiting for the procedure to begin, Grober and Fatchett discuss entertainment spots around St. Louis.

Fatchett's renal arteriogram allows blood vessels to be seen on film after the vessels have been filled with a contrast medium — a substance that shows up on X rays. Grober monitors the patient's condition throughout the exam.

First, a needle is inserted through the skin and into the artery. Then, a wire with a soft tip is inserted through the needle, and a catheter is threaded over the wire and into the blood vessel. By watching an X-ray image on a black-and-white television monitor above and to the side of the patient, the radiologist guides the catheter toward the kidney. Contrast medium is injected. Since reactions to the contrast can develop rapidly, Grober closely watches the patient and the monitors.

As the first series of X rays are taken, Grober moves into the control room where she watches images of Fatchett's remaining kidney on four black-and-white video



T. Mike Fletcher

screens. On another monitor his lungs can be seen, expanding and contracting. A rapid sequence of X-ray images is taken so the blood flow along the vessels can be studied.


Grober explains to Fatchett that movement will blur the X ray. "We need to make sure the images are clear," she explains. "We should be finished real soon."

True to her promise, the procedure is completed after the next series of images, and Grober and her coworkers lift Fatchett from the examining table to a stretcher. After Fatchett arrives in the recovery area, the catheter is removed and the artery is compressed to stop any bleeding. Grober continues to monitor Fatchett during the following four-hour recovery period.

In good spirits, Fatchett teases the staff, "Does this mean I can't go dancing tonight?"

"Yes, it means you can't go dancing tonight," shoots back Tom Vesely, M.D., a radiologist from the Mayo Clinic who is serving a fellowship at Mallinckrodt Institute. Vesely returns to the control room and Grober prepares the examination room for the next procedure.

The Human Touch



T. Mike Fletcher

"I really like to sing very softly to my patients."



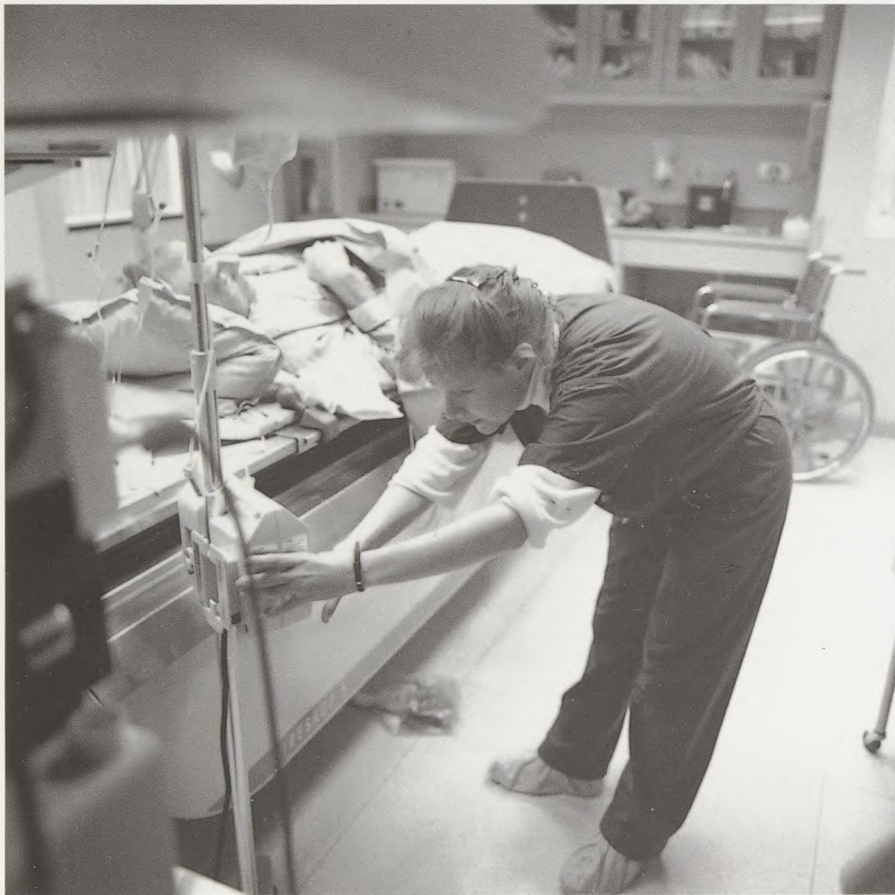T. Mike Fletcher

The next patient is Jamie Campbell, an outpatient who is scheduled for removal of bile duct stones that were left behind after gallbladder surgery. After Campbell changes into surgical garments, Grober starts an intravenous line. While recording Campbell's medical history, Grober confirms that, during the gallbladder surgery, a tube for the removal of the stones had been inserted into Campbell's side.

Campbell is moved into the examining room, and the existing

tube is replaced with a larger sheath so an endoscope can be inserted. The endoscope, a flexible tube slightly thinner than a garden hose, has a lens and a light attached to the end, allowing the radiologist to visually locate the stones. A basket is inserted into the endoscope and the stones are removed. When Campbell experiences some abdominal pain, Grober quickly squeezes her shoulder and tries to comfort her, while explaining the necessity of lying still.

The procedure ends, and Grober prepares Campbell for her recovery period. As Grober passes through the waiting area on her way to her next patient, she tells Fatchett good-bye as he is getting ready to leave the floor.

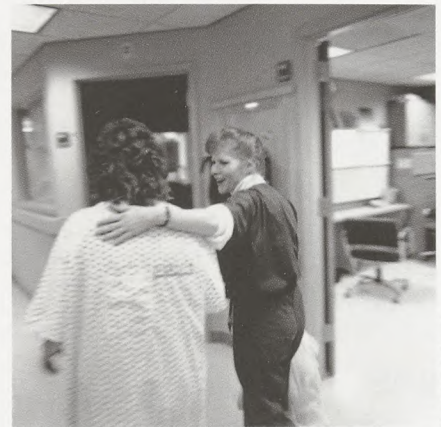


T. Mike Fletcher

Grober's next patient is scheduled for a gastrostomy. He has a history of drug use and has been unable to feed himself after a recent overdose. A surgically produced opening must be made in his stomach and a feeding tube inserted. Grober monitors a nasogastric

tube, which sends oxygen through the nose and into the stomach. Some oxygen must be present in the stomach for the radiologist to see the image on the black-and-white monitor and, subsequently, to insert the tube.

When the patient burps, Grober senses something is wrong and instinctively grabs a suction hose just as the patient begins to vomit. She tries to clear his airway so he will not aspirate or inhale fluid into his lungs. The patient's



T. Mike Fletcher

"I always address them by mister, miss, or missus, unless the patient allows me to be on a first-name basis."

teeth are clenched and Grober struggles to open his mouth. "I'm trying to help you," she says.

As the airway is cleared and the patient catches his breath, a sense of calm returns to the examining room. The procedure continues, and Grober monitors the patient's breathing pattern as she wipes his forehead and mouth.

"I think a patient can be relaxed just by touching them," she says. "Most patients, especially those in acute distress, seem to feel better if I put my arm around them and communicate to them that somebody cares." ■

FYI

THE DIRECTOR'S OFFICE REPORT

NEW STAFF

Mingshun Chen, Ph.D., research associate in radiology, Division of Radiation Oncology

Maureen J. Fusselman, M.S., B.S.N., research associate in radiology, Division of Nuclear Medicine

Daniel K. Kido, M.D., professor of radiology, Division of Diagnostic Radiology

Henry K. Lee, M.D., instructor in radiology, Division of Radiation Oncology

Daniel A. Low, Ph.D., instructor in radiology, Division of Radiation Oncology

Ali S. Meigooni, Ph.D., assistant professor of radiology, Division of Radiation Oncology

Christopher J. Moran, M.D., assistant professor of radiology, Division of Diagnostic Radiology

Thomas K. Pilgrim, Ph.D., research associate in radiology, Division of Diagnostic Radiology

Christopher G. Ullrich, M.D., adjunct assistant professor of clinical radiology, Division of Diagnostic Radiology

NUCLEAR MEDICINE RESIDENTS

Gary E. Meyerrose, M.D., received his undergraduate degree in chemistry from the University of Tennessee, Chattanooga, and his medical degree from the Universi-

ty of Tennessee, Memphis. He completed his internship at Baptist Memorial Hospital, Memphis.

PROMOTIONS

Joel S. Perlmutter, M.D., was promoted to research associate professor of radiology.

Steven S. Solomon, M.D., was promoted to assistant professor of radiology.

CHANGE OF STATUS

Armand Diaz, R.N., R.T., FASRT, was named assistant professor emeritus of radiology.

OFF STAFF

William R. Banks, Ph.D., research associate in radiology, Division of Radiation Sciences, has accepted a position in the department of nuclear medicine at Kettering Medical Center, Kettering, Ohio.

Leonid B. Leybovich, M.S., instructor in radiology, Division of Radiation Oncology, has accepted a position at Loyola University Medical Center, Naperville, Illinois.

Jonas Singer, M.D., assistant professor of radiology, Division of Diagnostic Radiology, has entered private practice in Alton, Illinois.

Patrick R. M. Thomas, M.D., professor of radiology, Division of Radiation Oncology, has accepted a position at The Temple University Comprehensive Cancer Center, Philadelphia.

VISITING PROFESSORS & INVITED LECTURERS

Jerome G. Cox, Jr., D.Sc., Welge Professor and chairman, Department of Computer Science at Washington University, organized and chaired the invited session on "New Developments in High-Speed Communications" and presented the paper "Rapid Display of Radiological Images," coauthored with **Stephen M. Moore, M.S.**, research associate in radiology; **Robert A. Whitman, M.S.**, research engineer; **G. James Blaine, D.Sc.**, associate professor of computer sciences in radiology; and **R. Gilbert Jost, M.D.**, professor of radiology and chief of the Division of Diagnostic Radiology, at the Medical Imaging V PACS Design and Evaluation Conference, sponsored by the Society of Photo-Optical Instrumentation Engineers, San Jose, California, February 26-28.

Harvey S. Glazer, M.D., associate professor of radiology, spoke on "CT of Pulmonary Collapse," "CT of Thorax-Pitfalls in Diagnosis," "CT of Cystic Neck Masses," "CT/Plain Film Radiography of Postoperative Chest," and "Plain Chest Radiography-Differential Diagnosis" at the Society of Mexican Radiology, Mexico City, February 4-6.

Fernando R. Gutierrez, M.D., associate professor of radiology, lectured on "Cardiovascular MRI" and "Imaging of Peripheral Aneurysms" at the 20th Latin American Congress of the International Society for Cardiovascular Surgery, Buenos Aires, Argentina, September 2-6.

Louis A. Gilula, M.D., professor of radiology and codirector of the musculoskeletal section, as visiting professor, spoke on "Analytic Approach to Complex Wrist Trauma," "Ligament Instabilities of the Wrist," "Radiologic Aspects of Surgical Procedures," and "Imaging Approach to the Painful Wrist," Oita, Nagasaki, Kyoto, and Nara, Japan, February 27 - March 11. He presented "Imaging Approach to the Painful Wrist" and served as moderator of the sessions on "Roentgenographic Studies of the Wrist" and "Examination of the Wrist" at The International Symposium on Wrist, Nagoya, Japan, March 6-8.

Jay P. Heiken, M.D., associate professor of radiology and codirector of computed body tomography, lectured on "MRI of the Female Pelvis," "CT and MRI Evaluation of Abdominal Vascular Disease," "CT of the Peritoneal Spaces" and conducted a workshop on "Rapid MR Imaging of the Abdomen" at the CT and

FYI

MRI Head to Toe Conference, New York, December 20-21. As visiting professor, he spoke on "Detection of Hepatic Metastases" and "CT of the Peritoneal Spaces" at the University of Iowa, Iowa City, January 14-15. Heiken presented "Rapid MR Imaging of the Abdomen," "MR Imaging of the Retroperitoneum," "MRI of the Liver," "MRI of the Female Pelvis," "MRI of the Male Pelvis," and "MRI of the Kidney, Adrenal, Pancreas and Spleen" at Seminars in MRI, Vail, January 19-26. He lectured on "CT of the Peritoneal Spaces" at Practical Radiology-1991, Whistler, British Columbia, February 3-8. He spoke on "Imaging Hepatic Metastases: Rationale" and "Detection of Hepatic Metastases: Techniques and Accuracy" at the Twentieth Annual Meeting and Postgraduate Course of The Society of Gastrointestinal Radiologists, Carlsbad, California, February 17-21.

R. Gilbert Jost, M.D., professor of radiology and chief of the Division of Diagnostic Radiology, presented the paper "Telerradiology Applications Within the Hospital," coauthored with **G. James Blaine, D.Sc.**, associate professor of computer sciences in radiology, and **Edward Muka, Ph.D.**, Eastman Kodak visiting scientist; and served as conference chairman of "PACS Design and Evaluation" as well as symposium chairman of Medical Imaging V, sponsored by the Society of Photo-Optical Instrumentation Engineers, San Jose, California, February 23-March 1.

Joseph K. T. Lee, M.D., professor of radiology and director of magnetic resonance imaging, as invited lecturer, presented "Basic MRI Physics for Radiologists," "MRI of the Cardiovascular System," "MRI of the Retroperitoneum," "MRI of the Kidney," "MRI of the Liver," "CT/MRI of the Non-Functioning Adrenal Mass," "MRI of the Female Pelvis," and "MRI of the Male Pelvis" at the Brazilian Conference of Radiology, San Paolo, December 5-8, and at the Argentinian Conference of Radiology, Mar del Plata, December 10-12. He spoke on "Upper Abdomen," "Kidneys and Retroperitoneum," and "Chest and Mediastinum" at the MRI Symposium, University of California-San Diego, March 5-8. As guest faculty, Lee presented "Clinical Applications of Fast MR Imaging," "MR of the Cardiovascular System," "CT of the Liver," "CT of the Biliary Tree," "MR of the Liver," and "CT/MR of the Adrenal Gland" at the Loyola Postgraduate Course, Maui, Hawaii, March 17-24.

Bruce L. McClellan, M.D., professor of radiology and head of abdominal imaging, spoke on "Contrast Media-1991," "Biliary Lithotripsy - a Future," "Contrast Media Reaction - Dx & Tx," and "CT of Renal Cell Carcinoma" at the Sun Valley Imaging Conference, Sun Valley, Idaho, February 23-March 1.

Tom R. Miller, M.D., Ph.D., associate professor of radiology, spoke on "Three-Dimensional Display in Nuclear Medicine" at the University of Massachusetts, Worcester, December 19.

Stephen M. Moerlein, Ph.D., associate professor of radiation chemistry in radiology and associate professor of biochemistry, presented "Assessment of Myocardial Perfusion with Positron Emission Tomography" and served as a panel member at a workshop on "On-Site Cyclotron Produced PET Radiopharmaceuticals: Regulatory and Quality Assurance Considerations" at the 138th Annual Meeting of the American Pharmaceutical Association, New Orleans, March 9-13.

Paul L. Molina, M.D., assistant professor of radiology, presented "Pitfalls in CT of the Thorax," "CT and MRI of Mediastinal Masses—Differential Diagnosis," "CT and MRI of the Pericardium," "CT of the Pleura," "CT of Peridiaphragmatic Processes," and "CT of the Thymus" at the 12th Annual Intermountain Imaging Conference, Steamboat Springs, Colorado, February 9-16.

William A. Murphy, Jr., M.D., professor of radiology and codirector of the musculoskeletal section, conducted a workshop on forensic radiology at the 43rd Annual Meeting of the American Academy of Forensic Sciences, Anaheim, California, February 19.

Carlos A. Perez, M.D., professor of radiology and director of the Radiation Oncology Center, presented the paper "External Irradiation of Epithelial Skin Cancer" at the American Society of Therapeutic Radiology and Oncology Conference, San Francisco, October 1-6. He lectured on "Optimization of Dose with Irradiation Alone in Carcinoma of the Uterine Cervix" at the American Society for Therapeutic Radiology and Oncology, Miami Beach, October 15-19. As an invited lecturer, Perez spoke on "Uterine Cervix," "Carcinoma of the Endometrium," "Carcinoma of the Lung," and "Hyperthermia in Head and Neck" at the Franze Buschke Lecture, San Francisco, March 7.

Joseph L. Roti Roti, Ph.D., professor of cancer biology in radiology and chief of the cancer biology section, presented "Effects of Hyperthermia on Cell Cycle Progression" at the Role of Cell Kinetics in Hyperthermic Oncology Symposium, Cell Kinetics Society meeting, Kiawah Island, South Carolina, March 22-24.

William J. Powers, M.D., associate professor of radiology, spoke on "Role of PET in Clinical Evaluation of Cerebrovascular Disease" at the 24th Annual Recent Advances in Neurology Conference, San Francisco, February 15-17.

Stuart S. Sagel, M.D., professor of radiology, director of chest radiology, and codirector of computed body tomography, as visiting professor, lectured on "CT of Asbestos-Related Pleural Disease" and "Role of CT and MRI in Bronchogenic

FYI

SYMPOSIA

Carcinoma," Stanford University, Stanford, November 9. He spoke on "CT and MRI of the Mediastinum: Anatomy, Technique and Masses," "CT of the Thymus," "CT of the Pericardium," "CT and MRI in Bronchogenic Carcinoma," "CT of the Larynx," "CT and MRI in Functional Adrenal Masses," and "Digital Chest Roentgenography" at the 8th Annual Course in Diagnostic Imaging, San Paolo, Brazil, December 6-8, and at the 11th Annual Course in Diagnostic Imaging, Mar del Plata, Argentina, December 9-11. Sagel, as visiting speaker, presented "CT of the Mediastinum" and "High Resolution CT of the Lungs" at Emory University, Atlanta, January 17-18. He spoke on "CT in Bronchogenic Carcinoma," "CT and MRI of the Mediastinum," and "CT of the Pleura" at the University of California-Los Angeles, March 11-12.

Marilyn J. Siegel, M.D., professor of radiology, presented "Abdominal Masses in the Newborn" and "Midline Central Nervous System Anomalies" at the Central Florida Ultrasound Society meeting, Orlando, October 18-20. As visiting professor, she lectured on "Imaging of Pediatric Ovarian Masses," "Pediatric Oncologic Imaging," and "CT and MRI of the Pediatric Thymus" at the Department of Radiology, Cincinnati Children's Hospital, Cincinnati, January 28-29.

Jerold W. Wallis, M.D., assistant professor of radiology, spoke on "Principles and Applications of Three Dimensional Displays" at the "New Horizons in SPECT, PET, and Computers" symposium, sponsored by the Society of Nuclear Medicine, Tampa, February 5. He presented "Three Dimensional Display: Techniques and Applications in Nuclear Medicine" at the 2nd International Symposium on Computer Applications in Nuclear Medicine and Cardiac Magnetic Resonance Imaging, Rotterdam, The Netherlands, March 20-22.

Michael W. Vannier, M.D., professor of radiology, director of the Division of Radiology Research, and head of the image processing lab, presented "Quantitative Analysis of Brain Cortical Surface Sulcal Lengths by 3-D MR" at the American Association for Advancement of Science (AAAS) Annual Meeting, Washington, D.C., February 14-19.

Todd H. Wasserman, M.D., professor of radiation oncology, as guest speaker, presented "Current Status of Radiosensitizers" at the Chicago Radiological Society, Chicago, November 14.

MIDWEST REGIONAL RADIATION RESEARCH

The following Mallinckrodt Institute staff members participated in the Sixth Annual Meeting of Midwest Regional Radiation Research, St. Louis, November 9-10.

Andrei Laszlo, Ph.D.,
Joseph L. Roti Roti, Ph.D.,
Program Committee members.

SESSION I

Ryuji Higashikubo, Ph.D.,
Joseph L. Roti Roti, Ph.D.,
"BrdU-Chase Study of the Heat-Induced Alterations in Cell-Cycle Progression."

Kenzo Ohtsuka, Ph.D.*;
Balakrishna Lokeshawar, Ph.D.;**
Andrei Laszlo, Ph.D., "Initial Characterization of a Monoclonal Antibody Against the Constitutive Form of HSP 70." *Aichi Cancer Institute, Nagoya, Japan; **University of Miami.

WORKSHOP I

Andrei Laszlo, Ph.D.;
Kenzo Ohtsuka, Ph.D.*;
Teri Frechmann, B.A., M.A.;
An Hu, M.S.;
Robert Quackenbush, M.D.;
Yvonne C. Taylor Ph.D., "Further Evidence for the Two States of Thermotolerance Model." *Aichi Cancer Institute, Nagoya, Japan.

Michael A. Mackey, Ph.D.,
Joseph L. Roti Roti, Ph.D.,
"Effects of Blockage of HeLa S3 Cells in G1 Upon Chronic Thermotolerance Expression."

Nazan Turkel, M.S.,
Joseph L. Roti Roti, Ph.D.,
"The Correlation Between Heat-Induced Excess Nuclear Protein and Cell Killing."

SYMPOSIUM

Joseph L. Roti Roti, Ph.D., introduced the symposium speaker, Nancy L. Oleinick, M.D., Case Western Reserve University School of Medicine, who lectured on "Chromatin Structure Modifies the Response of DNA to Ionizing Radiation: Examining the Sensitive Regions of Chromatin."

WORKSHOP II

An Hu, M.S.;
Teri Frechmann, B.A., M.A.;
Andrei Laszlo, Ph.D., "Heat-Induced Alterations in the Solubility of HSP 70 in Chinese Hamster Cells."

Michael A. Mackey, Ph.D., chairperson for Workshop II: "Mechanisms of the Stress Response."

WORKSHOP III

Andrei Laszlo, Ph.D., chairperson for Workshop III: "The Role of DNA Damage in the Response of Cells to Radiation."

Yvonne C. Taylor, Ph.D.;
Pamela G. Duncan;
Azam J. Parsian, B.S.;
Catherine M. Koziol, B.A., "Nuclear Effects of Caffeine in Normal and SV40-Transformed Human Fibroblasts."

FYI

William D. Wright, B.S.;
Ryuji Higashikubo, Ph.D.;
Joseph L. Roti Roti, Ph.D.,
"Radiation-Induced Changes
in the Synthesis of NP170:
Evidence That It Is DNA
Topoisomerase II."

SESSION III

Jeffrey J. Kovalic, M.D.,
Gilbert H. Nussbaum,
Ph.D., "Excessive Heating at
Soft Tissue-Bone Interfaces
with Parallel-Beam
Ultrasound."

Robert J. Myerson, M.D.,
Ph.D., "Probabilistic Relation
Between SAR and Time to
Achieve Temperature
Elevation."

RADIOLOGICAL SOCIETY OF NORTH AMERICA

*The following Mallinckrodt
Institute staff members par-
ticipated in the 76th Annual
Scientific Assembly and
Annual Meeting of the Radi-
ological Society of North
America, Chicago, Novem-
ber 25-30.*

PLENARY SESSIONS

Louis A. Gilula, M.D.,
panel member for the session
on "The X-Ray Bowl: A Chal-
lenge Film Interpretation
Panel."

Bruce L. McClennan, M.D.,
panel member for the session
on "Lithotripsy" and modera-
tor of "Imaging Symposium:
Low-Osmolality Contrast
Media - Issues and Answers."

Marilyn J. Siegel, M.D.,
panel member of the RSNA
Film Interpretation session
and for the session on "MR
Imaging of the Pediatric Mus-
culoskeletal System: Strate-
gies for the Nineties."

REFRESHER COURSES

Harvey S. Glazer, M.D.,
"CT of the Lung, Medi-
astinum, and Diaphragm"

Barbara B. Hasse, R.N.,
"AIDS Issues, Risk Manage-
ment, and Infection Control"

Jay P. Heiken, M.D., "CT of
the Retroperitoneum"

Bruce L. McClennan, M.D.,
"CT of Indeterminate Renal
Masses"

Barbara S. Monsees, M.D.;
Ronald G. Evens, M.D.,
"Patient-Initiated Mammog-
raphy: The Potential and the
Problems"

William A. Murphy, Jr.,
M.D., "Forensic Radiology:
Techniques for Death Inves-
tigation"; comoderator of
"Special Course in MR for
the 90's" on the topics of
technical overview; cere-
brovascular disease; white
matter disease; spine, chest
and abdomen; genitourinary
system; and musculoskeletal.

Daniel Picus, M.D.,
"Advances in Interventional
Biliary Radiology"

Robert E. Dryzmala,
Ph.D.; **James A. Purdy,**
Ph.D., "Practical Implemen-
tation of Three-Dimensional
Treatment Planning"

Stuart S. Sagel, M.D.,
"How to Prepare and Deliver
an Effective Audiovisual
Presentation"

Marilyn J. Siegel, M.D.,
"Pediatric Oncologic
Imaging"

Michael W. Vannier, M.D.;
Louis A. Gilula, M.D.,
"Three-Dimensional Imaging
of the Musculoskeletal
System"

Todd H. Wasserman, M.D.,
"Lymphomas"

SCIENTIFIC SESSIONS

James A. Brink, M.D.;
Michael de Correia-
Kamat, M.D.*; **Peter R.**
Mueller, M.D.*; **Joseph F.**
Simeone, M.D.*; **Sanjay**
Saini, M.D.*; **Nathan O.**
Spell, M.D.*; **Joseph T.**
Ferrucci, M.D.*, "Quantita-
tive Assessment of Gallstone
Burden for Monitoring Non-
surgical Gallstone Therapies:
In Vitro Studies." *Depart-
ment of Radiology, Mas-
sachusetts General Hospital,
Boston.

James A. Brink, M.D.;
Michael de Correia-
Kamat, M.D.*; **Joseph F.**
Simeone, M.D.*; **Peter R.**
Mueller, M.D.*; **Sanjay**
Saini, M.D.*; **Joseph T.**
Ferrucci, M.D.*, "Effect of
Echogenic Bile on the Per-
formance and Accuracy of
Gallbladder Sonography
after ESWL: In Vitro Model."
*Department of Radiology,
Massachusetts General Hos-
pital, Boston.

Holly J. Burge, M.D.;
William D. Middleton,
M.D.; **Bruce L. McClen-**
nan, M.D., "Color Doppler
US Investigation of Ureteral
Jet Phenomena in Patients
with Urinary Tract
Obstruction."

James R. Duncan, M.D.,
Ph.D.; **Jeffrey J. Brown,**
M.D.; **Steven S. Eilenberg,**
M.D.; **Scott A. Mirowitz,**
M.D.; **Joseph K. T. Lee,**
M.D.; **Jay P. Heiken, M.D.,**
"Effects of Perfluorocetylbro-
mide and Glucagon on the
Appearance of Bowel and
Bowel-related Artifacts on
MR Images."

Steven S. Eilenberg, M.D.;
Joseph K. T. Lee, M.D.;
Jeffrey J. Brown, M.D.;
Jay P. Heiken, M.D.; **Scott**
A. Mirowitz, M.D., "Diag-
nostic Accuracy of Dynamic
Contrast-Enhanced MR
Imaging of Renal Masses
with Rapid-Acquisition Spin-
Echo Technique."

Mark S. Frank, M.D.*; **R.**
Gilbert Jost, M.D.; **Dixie**
J. Anderson, M.D.; **Paul J.**
Molina, M.D.; **Stuart S.**
Sagel, M.D.; **Steven L.**
Solomon, M.D.; **Robert A.**
Whitman, M.S.; **Stephen**
M. Moore, M.S.; **G. James**
Blaine, D.Sc., "Interpreta-
tion of Storage Phosphor
Chest Radiographs: High-
Resolution Cathode Ray
Tube versus Film." *Seattle,
Washington.

Edith H. Kang, M.D.;
William D. Middleton,
M.D.; **Dennis M. Balfe,**
M.D.; **Nathaniel J. Soper,**
M.D.*, "Laparoscopic Chole-
cystectomy: Sonographic
Evaluation." *Department of
Surgery, Washington Univer-
sity, St. Louis.

FYI

Jeffrey J. Kovalic, M.D.;
Perry W. Grigsby, M.D.;
Barbara B Fineberg, B.A.,
"Radiation Therapy as Salvage for Recurrent Pituitary Adenomas after Surgical Resection."

Andrew B. Landes, M.D.;
Jay P. Heiken, M.D.; **Marilyn J. Siegel, M.D.,** "CT Scanning in Children: Evaluation of a New Continuously Rotating CT Scanner."

Joseph K. T. Lee, M.D., president, Genitourinary (Pelvis).

Frederick A. Mann, M.D.;
Anthony J. Wilson, M.B., Ch.B.; **Louis A. Gilula, M.D.;** **William G. Totty, M.D.;** **Margaret R. Linn, M.D.;** **Barbara S. Monsees, M.D.,** "Is Three-Joint Wrist Arthrography Really Necessary?"

Bruce L. McClennan, M.D., president, Genitourinary (Contrast).

William D. Middleton, M.D.; **Barry A. Siegel, M.D.;** **G. Leland Melson, M.D.;** **Carol K. Yates, M.D.*;** **Gerald Andriole, M.D.**,** "Prospective Comparison of Color Doppler Ultrasonography and Testicular Scintigraphy in the Evaluation of Acute Scrotal Disorders." * Baptist Medical Center, Oklahoma City. **Department of Surgery, Washington University, St. Louis.

Tom R. Miller, M.D., Ph.D., president, Nuclear Medicine (Tumor).

Scott A. Mirowitz, M.D.;
Jeffrey J. Brown, M.D.;
Joseph K. T. Lee, M.D.;
Jay P. Heiken, M.D.;

Steven S. Eilenberg, M.D., "Dynamic Gd-DTPA-Enhanced Rapid Acquisition Spin-Echo MR Imaging of Normal and Abnormal Spleen."

Scott A. Mirowitz, M.D.;
Elsa Guterrez, M.D.;
Joseph K. T. Lee, M.D.;
Jeffrey J. Brown, M.D., "Enhancement Patterns of Normal Abdominal Organs in Dynamic Gd-DTPA-Enhanced RASE MR Images."

Scott A. Mirowitz, M.D.;
Joseph K. T. Lee, M.D.;
Jeffrey L. Brown, M.D.;
Elsa Guterrez M.D.; **Jay P. Heiken, M.D.,** "Dynamic Gd-DTPA Enhanced Rapid Acquisition Spin Echo (RASE) MR Imaging of Focal Hepatic Lesions."

Scott A. Mirowitz, M.D.;
William G. Totty, M.D.;
Joseph K. T. Lee M.D., "Evaluation of Musculoskeletal Masses with Dynamic Gd-DTPA-Enhanced Rapid-Acquisition Spin-Echo Imaging."

Marilyn J. Siegel, M.D., president, GI Doppler Ultrasound.

Steven L. Solomon, M.D.;
Jeffrey J. Brown, M.D.;
Harvey S. Glazer, M.D.;
Scott A. Mirowitz, M.D.;
Joseph K. T. Lee, M.D., "MR Imaging of Thoracic Aortic Dissection: Pitfalls and Artifacts."

Scott D. Stevens, M.D.*;
Jay P. Heiken, M.D.; **Douglas W. Hanto, M.D.*;**
Elizabeth M. Brunt, M.D.;** **M. Wayne Flye, M.D.*,** "Periportal Collar on CT Scan After Liver Trans-

plantation Reliability as a Sign of Allograft Rejection." *Department of Surgery, Washington University, St. Louis; **Department of Pathology, Washington University, St. Louis.

R. Stephen Surratt, M.D.;
Daniel Picus, M.D.; **Marshall E. Hicks, M.D.;**
Michael D. Darcy, M.D.;
Michael A. Kleinhoffer, R.T.; **Martin D. Jendrisak, M.D.*,** "Role of Upper Extremity Venography in Dialysis Vascular Access Planning." *Department of Surgery, Washington University, St. Louis.

Anthony J. Wilson, M.B., Ch.B., president, Bone (Shoulder MR Imaging).

Anthony J. Wilson, M.B., Ch.B.; **Michael Kyriakos, M.D.*;** **Lauren V. Ackerman, M.D.**,** "Chondromyxoid Fibroma: Analysis of the Radiography Finding." *Department of Pathology, Washington University, St. Louis. **Department of Pathology, SUNY at Stony Brook, New York.

Thomas W. Zusag, M.D.;
Sarah McDonald, M.B., Ch.B.*; **Aimee Mitchell, M.S.*;** **Martin Weinhaus, Ph.D.;** **James Purdy, Ph.D.;** **Philip Rubin, M.D.*,** "Radiation Oncology Residents' Workstation." *University of Rochester Medical Center, Rochester, New York

WORKS IN PROGRESS
Judy M. Destouet, M.D., president, General Current Concepts (Breast Imaging).

Frederick A. Mann, M.D.;
Neal R. Stewart, M.B., Ch.B.; **Calvin B. Terrell, M.D.*,** "Performance of Internal Medicine Residents

in the Primary Interpretation of Musculoskeletal Radiographs in an Ambulatory Care Setting." *Department of Surgery, Washington University, St. Louis.

SCIENTIFIC EXHIBITS

James A. Brink, M.D.; **Birgit Kammer, M.D.*;** **Peter R. Mueller, M.D.*;** **Joseph F. Simeon, M.D.*;** **Sanjay Saini, M.D.*;** **Joseph T. Ferrucci, M.D.*,** "Prediction of Gallstone Composition: Synthesis of Growth Patterns and Radiographic Features." *Department of Radiology, Massachusetts General Hospital, Boston.

William G. Horstman, M.D.; **William D. Middleton, M.D.;** **G. Leland Melson, M.D.,** *magna cum laude* award for "Color Doppler US of the Scrotum."

Marilyn J. Siegel, M.D.;
Paul L. Molina, M.D., "Instructive Radiology Cases"

Jamie T. Surratt, M.D.;
Marilyn J. Siegel, M.D., *cum laude* award for "Imaging of Ovarian Lesions in Childhood."

Michael W. Vannier, M.D.;
Barry S. Brunsten, research engineer;
Charles F. Hildebolt, D.D.S., Ph.D.; **James M. Cheverud, Ph.D.;** **Gary S. Figiel, M.D.;** **William H. Perman, Ph.D.;** **Luci A. Kohn, Ph.D.;** **Richard A. Robb, Ph.D.;** **Roberta L. Yoffie, R.T.;** **Stephen J. Bresina, M.S.;** **Robert H. Knapp, R.T.;** **Gulab H. Bhatia, M.S.,** "Cartographic Mapping of the Skull and Brain from CT and MR Imaging"

FYI

APPOINTMENTS/ ELECTIONS

Louis A. Gilula, M.D., professor of radiology and codirector of the musculoskeletal section, was reappointed chairperson of the convention planning committee of the International Skeletal Society. He also will serve on the awards committee, the liaison future planning committee, and the committee for fellowship accreditation of musculoskeletal radiology.

Bruce L. McClennan, M.D., professor of radiology and head of abdominal imaging, was appointed program subcommittee chairman of the Genitourinary Committee for 1991 by the Radiological Society of North America.

Daniel Picus, M.D., assistant professor of radiology and head of vascular/interventional radiology, was appointed to the 1991 Editorial Board of *Radiology* as associate editor of the Interventional Division and was appointed deputy editor of the *Journal of Vascular and Interventional Radiology*.

HONORS/ AWARDS

Jay P. Heiken, M.D., associate professor of radiology and codirector of computed body tomography, received the 1990 Editor's Recognition Award with Special Distinction from *Radiology*.

Michael W. Vannier, M.D., professor of radiology, director of the Division of Radiology Research, and head of the image processing lab, was appointed to the 1991 Editorial Board of *Radiology* as associate editor for Computer Applications.

Todd H. Wasserman, M.D., professor of radiation oncology, was chairman of and editor for the 7th International Conference on Chemical Modifiers of Cancer Treatment, Clearwater, Florida, February 2-5. He served on the Executive Committee of the Radiation Therapy Oncology Group meeting, Philadelphia, Pennsylvania, March 21-22.

CIC NEWS

The Cancer Information Center (CIC) is cosponsored by the Mallinckrodt Institute of Radiology, the Barnard Free Skin and Cancer Hospital, and Barnes Hospital at the Washington University Medical Center.

CONTRIBUTIONS

Mr. and Mrs. Paul Kaufmann in memory of Neal Wallace

Employees of A & E Brake Company in memory of Bonnie Lambert

Mr. and Mrs. James Fleming in memory of Ronald Beachum

Saxton A. Angevine

Mr. and Mrs. Joseph Santangelo

Mr. and Mrs. Frederick Hermann in memory of Richard Houser

Mr. and Mrs. Frederick Hermann in memory of Edward Weakley

Jacquelyn B. Campbell in memory of Doris Berry Williams

Mr. and Mrs. Clifford N. Huskey in memory of Donald Faerber

General Dynamics Corporation Finance Department in memory of Cletus Behr

Mrs. Marion Winkler in memory of Rita Simms

Mr. and Mrs. Mike Wood in memory of Mrs. Jane Kohr

Mr. and Mrs. Don Vitt in memory of Mrs. Jane Kohr

Catherine Tretler in memory of Mrs. Jane Kohr

Elizabeth Otto in memory of Mr. Charles Loring

CSC Credit Services in memory of William Faust

Decor Interiors, Inc. in memory of the father of Elliot Kalmes

Mr. and Mrs. Frederick Hermann in memory of Mrs. Margaret Mudd

Dave, Linda, Erica and Bryan Morotz in memory of Henry Hennenhoefler

James Sweney in memory of Deloris Sweney

Bill Matson in memory of William J. Simon

E. Max Huber

Mary L. Merten in memory of I. W. Kurtz

Anne, Jim, and Jane Miller in memory of Lawrence Claudio

Chrysler First Commercial Corporation in memory of Alvin C. Bryce

Sandy Siehl in memory of Betty, Carol, and Beckner Siehl

Mr. and Mrs. Hugo Heine- mann in memory of I. W. Kurtz

Hermann Oak Leather Company

Mr. and Mrs. Wilson P. Jean- nelle in memory of Lee Hartwell

CALENDAR

April 5-7, 1991

In Vivo MR Spectroscopy Workshop
St. Louis

April 7-12, 1991

Diagnostic Imaging: 1991
Kona, Hawaii

April 8, 1991

City-Wide Radiology Conference
Leroy Sante Lecture
"Imaging of Adrenal Disease"
Peter Armstrong, M.D.
St. Louis University

April 13-17, 1991

Society for Magnetic Resonance Imaging
Chicago

April 15-19, 1991

14th Annual Course of the Society of Computed Body Tomography
Washington, D.C.

May 4-8, 1991

American Radium Society
Paris

May 5-10, 1991

American Roentgen Ray Society
Boston

May 5-10, 1991

American Association of Women Radiologists
Boston

FYI

CALENDAR

Continued from page 29.

May 12-16, 1991

Radiology Business Management Association
San Francisco

May 13, 1991

City-Wide Radiology Conference
"Intravascular Stents"
Gary Becker, M.D.
Scarpellino Auditorium
St. Louis

May 27-31, 1991

Society for Pediatric Radiology
Stockholm

June 7-13, 1991

Canadian Association of Radiologists
Hamilton, Ontario

June 7-14, 1991

American Society of Neuroradiology
Washington, D.C.

June 11-14, 1991

Society of Nuclear Medicine
Cincinnati

June 17-19, 1991

Breast Cancer Diagnosis: Interventional Procedures Conference presented by Mallinckrodt Institute of Radiology and Siemens, Inc.
Hilton Head Island

June 23-27, 1991

American Medical Association
Chicago

July 21-25, 1991

American Association of Physicists in Medicine
San Francisco

The Mallinckrodt Mammography Mobile brings the latest technology in breast cancer screening plus low-dose, state-of-the-art equipment to women at the St. Louis-area Schnucks stores

for a cost of \$60. Call 362-7111 to schedule an appointment for the following dates:

April 1 -

Butler Hill Store, 4333 Butler Hill Road 63128

April 2 -

Crestwood Store, 9719 Watson Road 63126

April 8 -

Telegraph Store, 5519 Oakville Shopping Center 63129

April 9 -

Hazelwood Store, 8780 Per-shall 63042

April 15 - Breckenridge Store, 9685 St. Charles Rock Road 63114

April 16 -

Cross Keys Store, 115 Cross Keys Shopping Center 63033

April 22 -

Belleville Store, 5720 North Belt West 62220

April 23 -

Collinsville Store, 501 Belt Line Road 62234

April 29 - Fairview Store, 625 Lincoln Highway 62208

April 30 -

Swansea Store, 2665 North Illinois Street 62221

The MIR Alumni Reception at the 76th Annual Meeting of RSNA, November 25-30, Chicago.



Mike Simone

Ronald Evens, M.D., director of the Institute, and Anica Jovanovic, M.D., who was the first female resident at the Institute.



Mike Simone

(Left to right) Dixie Anderson, M.D.; Thomas Getz, M.D., and Bill Spies, M.D.



Mike Simone

(Left to right) Douglas Smith, M.D., chief resident, Diagnostic Radiology; Andrew Landes, M.D. (background); Stephen Surratt, M.D.; Jamie Surratt, M.D.; and Mark Perry, M.D., cochief resident, Diagnostic Radiology.

REFLECTIONS

H E N R Y D. R O Y A L, M. D.

The world's most serious radiation accident occurred on April 26, 1986. The fifth anniversary of the Chernobyl disaster will be observed with reviews of the causes and consequences.

The social and economic consequences have been profound. Millions of Soviets have been relocated due to concern about the environmental contamination from the accident. It has been estimated that the cost will exceed \$500 billion.

The immediate health effects of the accident have been extensively documented. Two workers died due to traumatic injuries resulting from the explosion. Approximately 250 workers and rescue personnel who were at the accident site were hospitalized for the acute effects of radiation. Twenty-nine of the hospitalized patients eventually died in the weeks following the accident.

The greatest public concern has been the long-term effects on the health of the Soviet citizens living in the more contaminated regions. The Soviet government has struggled to develop an evacuation policy based on an acceptable level of contamination. Understandably, the concept of an acceptable level of contamination strikes many as an oxymoron. Who among us would want to live anywhere that was contaminated with anything? However, if the resources that are available to promote public health and to protect the environment are finite, quantitative risk analysis is essential.

In the case of Chernobyl, the contaminants are radioactive elements. The citizens currently living in the more contaminated areas of the Soviet Union are exposed to radiation that is two to three times (900 millirems per year) the average amount of exposure from natural sources (300 millirems per year). Since the effects

of radiation have been studied more extensively than the effects of any other toxin, the risks from this additional exposure can be estimated with some confidence. For example, there are many areas in the world where the radiation from natural sources is several times the average amount. Epidemiologic studies of these populations fail to demonstrate adverse health effects that can be attributed to chronic increased radiation exposure. Additional studies of workers in the nuclear industry exposed to similar levels of radiation also fail to demonstrate adverse health effects. Therefore, a quantitative estimate of the risk of living in a contaminated area leads to the conclusion that the risk is too small to measure and that it is very small when compared to other everyday risks (e.g., driving) which are deemed acceptable.

The fact that the risk from radiation exposure can be small may be surprising to some. In order to deal effectively with the complexities of life, we are often forced to simplify complex issues. With radiation, quantitative risk analysis is simplified to the binary concepts of safe and dangerous. Any amount of radiation is considered to be dangerous.

Given this mind-set, it is easy to understand why most people believe that the incidence of leukemia, thyroid disease, anemia, cancers and immune suppression have increased in the population living in areas contaminated by the Chernobyl accident. However, quantitative estimates of the expected increase in the incidence of disease due to radiation exposure for many of the populations of concern are very small and unlikely to be detectable. Contrary to frequent, widely circulated anecdotal reports, there are no published, peer-reviewed scientific papers

that have indicated an increased incidence of leukemia, thyroid disease, anemia, cancers or immune suppression in persons currently living in contaminated areas.

If the risks from the radioactive contamination due to Chernobyl are small, why are they so unacceptable? We need only to look in our own backyard to understand that many factors other than the size of the risk determine its acceptability. In St. Louis, quantitative risk analysis would suggest that the health risk from nuclear waste in Weldon Springs, Latty Avenue, the airport and other locations is extremely small. The *maximum* credible dose from this waste to any single member of the public is approximately 10 millirems per year, yet cost estimates for remedial actions approach \$1 billion.

Additional factors which can make a very small risk unacceptable include whether (1) it is voluntary or involuntary; (2) it is shared equitably; and, (3) the benefits are less than the risk. Involuntary risks are especially unacceptable when they are imposed by a powerful "other" such as the government or industry. Finally, the risk to the individual may be very small, but if that individual receives no benefit from accepting this risk, the risk becomes unacceptable.

Ultimately, the Soviet society must decide how best to spend its finite resources to protect the public health and the environment. The more money that is spent protecting the public from the small but unacceptable risks of the Chernobyl accident, the less money that is available to protect the public from much larger but acceptable risks (e.g., smoking, alcohol abuse, inadequate perinatal care, malnutrition, etc.). We all have a great deal to learn from the accident at Chernobyl.

MIR

Celebration

...

September 12-14, 1991

N*ineteen ninety-one*


*is a very special time in the history of Mallinckrodt Institute —
a time for looking back at the accomplishments of the last 60 years,
and a time for looking forward to the goals
and tasks of the next 60 years.*

*As part of the three-day radiology program
to commemorate the anniversary of the Institute, a special
rededication ceremony is scheduled for the morning of Saturday,
September 14, 1991.*


*Current and former members of the Institute,
each a recognized leader in the field of radiology, will address
the Institute's mission as well as pertinent central issues,
such as clinical care, education, research, industrial
relationships, technological progress, government regulations,
and ethical issues.*

*A reception and an open house with tours
of the Institute will follow the rededication.*


*Please join us for the rededication
as we reflect on our accomplishments and reaffirm our mission
for the future.*



Above: From the humble beginnings of the actinographic laboratory housed in Barnes Hospital, Mallinckrodt Institute of Radiology has evolved into one of the five largest and most modern radiologic centers worldwide. Photograph, circa 1920s, courtesy of the Visual Collection of the Archives, Washington University School of Medicine.



Right: The first cyclotron dedicated to medical use was built in 1940 by Mallinckrodt Institute scientists. A team of researchers led by Michel Ter-Pogossian, Ph.D., used this same cyclotron in the developmental stages of positron emission tomography (PET). Photograph courtesy of the MIR Photography Lab.



Left: In the early 1970s, Sir Godfrey Hounsfield, Nobel Prize winner and inventor of computed tomography (CT), perfected the scanner's prototype here at the Institute. Shown with Hounsfield are (left to right) Drs. Ronald Evens, Gilbert Jost (background), Stuart Sagel, and Robert Stanley. Photograph courtesy of the MIR Photography Lab.

FOCAL SPOT

MALLINCKRODT INSTITUTE OF RADIOLOGY

MI
MALLINCKRODT
INSTITUTE OF RADIOLOGY
WASHINGTON UNIVERSITY
MEDICAL CENTER

Director, Public Relations
Executive Editor
Michaele Gold

Managing Editor
Vicki Kunkler

Associate Editor
Joe Mueller

Administrative Assistant
Laura Waugh

Design
Purviance & Company
Marketing Communications

Contributing Writers
Laura Waugh

Photographers
T. Mike Fletcher
Norman Hente
Thomas Murry
Mike Simane
Herb Weitman

Focal Spot magazine is published three times a year by the Mallinckrodt Institute of Radiology at the Washington University Medical Center at 510 South Kingshighway, St. Louis, MO 63110.

Permission is granted to reproduce articles contained herein, provided **Focal Spot** magazine of the Mallinckrodt Institute of Radiology at the Washington University Medical Center is credited.

Public Relations Department
Mallinckrodt Institute of Radiology
510 South Kingshighway
St. Louis, MO 63110
(314) 362-2866.

© Mallinckrodt Institute of Radiology, 1990

Address Correction Requested

Non-Profit Organization
U.S. Postage
PAID
St. Louis, Missouri
Permit No. 1030



T. Mike Fletcher

These computer-generated, three-dimensional images show Lory Halbrook before cosmetic surgery (left) and one day after surgery. Her story begins on page 12.