

Fall 1990

Focal Spot, Fall/Winter 1990

Follow this and additional works at: http://digitalcommons.wustl.edu/focal_spot_archives

Recommended Citation

Focal Spot, Fall/Winter 1990, October 1990. Bernard Becker Medical Library Archives. Washington University School of Medicine.

This Book is brought to you for free and open access by the Focal Spot at Digital Commons@Becker. It has been accepted for inclusion in Focal Spot Archives by an authorized administrator of Digital Commons@Becker. For more information, please contact engeszer@wustl.edu.

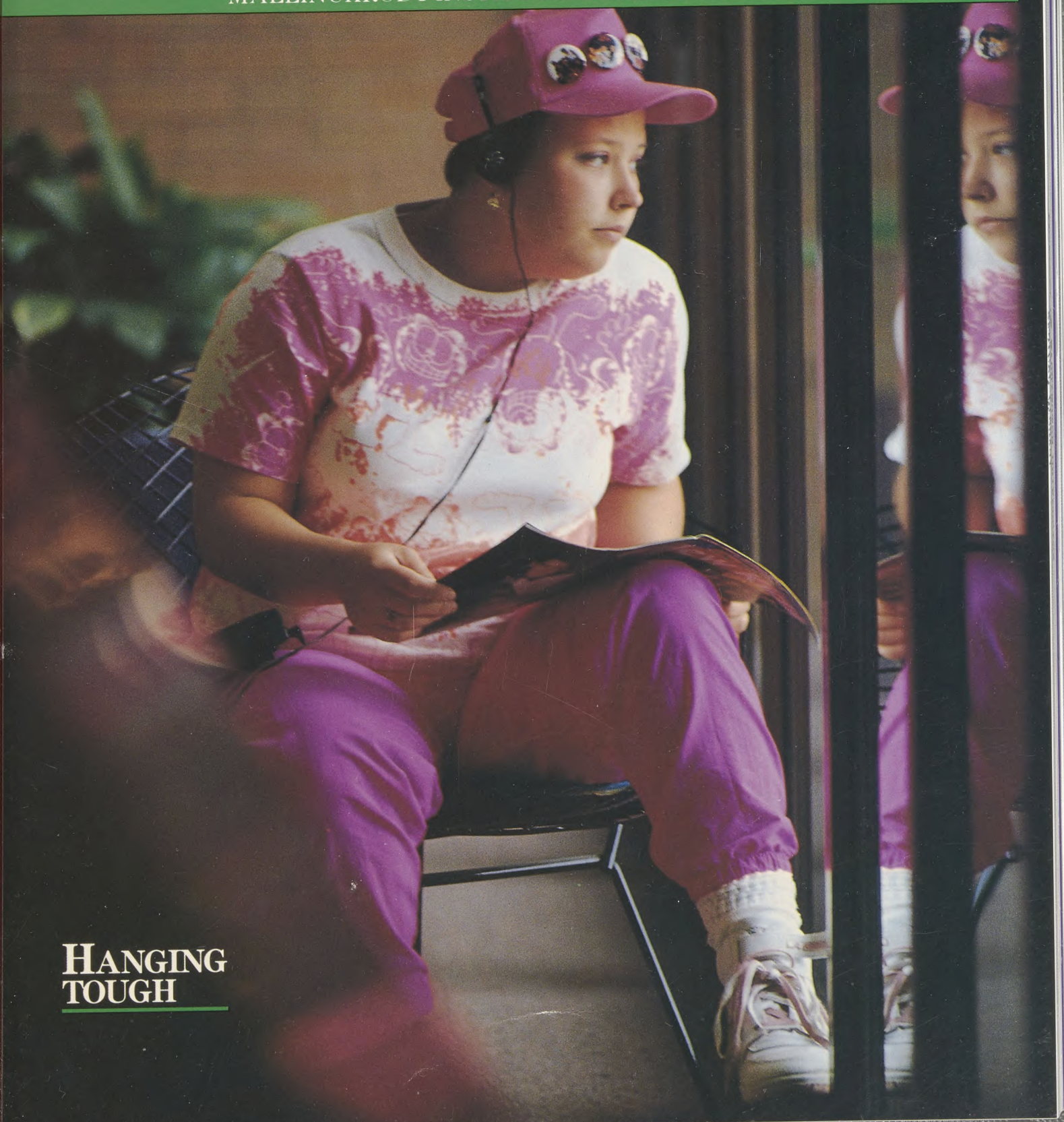FALL/WINTER, 1990

VOLUME 21, NUMBER 3

FOCAL SPOT

MALLINCKRODT INSTITUTE OF RADIOLOGY

Indexed



**HANGING
TOUGH**

MIR

Celebration

...

100th
ANNIVERSARY OF
WASHINGTON UNIVERSITY MEDICAL SCHOOL

•

60th
ANNIVERSARY OF
MALLINCKRODT INSTITUTE OF RADIOLOGY

...

SAVE THESE DATES...

September 12-14, 1991—St. Louis, Missouri

•

Scientific Program (CME)

•

20th Annual Wendell G. Scott Memorial Lecture

•

Special Events • Social Events • MIR Alumni Reunion

...


MORE LATER....

FALL/WINTER, 1990

VOLUME 21, NUMBER 3

FOCAL SPOT

MALLINCKRODT INSTITUTE OF RADIOLOGY



6 HANGING TOUGH

Being told she had a rare form of cancer and learning to walk again were difficult for 16-year-old Chrissy Dunn. Even harder was winning her battle with the emotional side of her disease.




12 THE RIGHT CHOICE

In a study of 417 women with breast cancer, researchers at MIR reported a significantly low recurrence rate in patients treated with brachytherapy in combination with surgery and external irradiation. The results are very encouraging.



16 LOOKING FORWARD

The hard-won order in Audrey Davis' life was threatened when she was diagnosed with cervical cancer. But thanks to a sophisticated combination of both intracavitary and external radiation therapies, Davis looks forward to a long and happy life.



2 SPOT NEWS

21 FYI

30 SPOTLIGHT

32 REFLECTIONS

MIR
MALLINCKRODT
INSTITUTE OF RADIOLOGY
WASHINGTON UNIVERSITY
MEDICAL CENTER

ON THE COVER:

In her fight against spinal cancer, Christina Dunn relied on her family's support, her own inner strength, and a song by New Kids on the Block called "Hanging Tough."
Photograph by T. Mike Fletcher.

SPOT NEWS



T. Mike Fletcher

MIR Adds Research Division

Mallinckrodt Institute has long had a reputation as a world leader in clinical investigations. The establishment of the Division of Clinical Research indicates a major commitment to the expansion of clinical research projects. The Division will serve as a focus and resource for studies in technology assessment, clinical protocols, electronic imaging, and radiologic procedures.

The director of the Division is Michael W. Vannier, M.D., professor of radiology and head of the MIR 3-D imaging laboratory. Through Vannier's pioneering research, MIR has maintained its leadership in the development and clinical application of 3-D image processing. Vannier, a former consulting engineer for NASA, is recognized for

Director of the Division of Clinical Research Michael Vannier, M.D., will oversee research at the Institute and coordinate resources for resolving research issues.

his application of aerospace technology to improve the quality of human life, his highly acclaimed research into the reconstruction of craniofacial deformities, and for his work in computed tomography scanning of ancient fossil skulls.

Vannier will develop a committee of key researchers from the MIR divisions of Nuclear Medicine, Radiation Sciences, Radiation Oncology, and Diagnostic Radiology. The committee will aid principal investigators in their efforts to design projects and attract extramural funding.

"The Division will provide an environment in which radiologists, other physicians, basic scientists, and engineers can collaborate and address important research questions," says Vannier.

Going for the Silver

Cited for its "high level of professionalism and of innovation, content, form, and message," *Focal Spot* magazine has been selected as the 1990 Silver Quill Award of Merit recipient. The spring, summer, and fall/winter 1989 issues of the publication were chosen from over 300 entries in the four-color external magazine category from the District IV-Midwest region. District IV includes Illinois, Iowa, Minnesota, Nebraska, North Dakota, Wisconsin, and Missouri.

The Silver Quill Award is sponsored by the International Association of Business Communicators (IABC), an organization of more than 11,000 public relations and marketing professionals and marketing professionals. Established in 1970, IABC has more than 125 chapters and affiliates worldwide. Throughout the calendar year, IABC awards recognition for public relations and marketing programs on three levels: the Bronze Quill for local chapters, the Silver Quill for regional, and the Gold Quill for international. *Focal Spot* also was a 1988 Silver Quill Award recipient. In 1987 MIR Public Relations received the Bronze Quill Award of Excellence for its Total Communications Program in Mammography Outreach.

SPOT NEWS



Thomas Murry

Manual of Clinical MRI in Second Edition

Jay P. Heiken, M.D., and Jeffrey J. Brown, M.D., are authors and coeditors of the second edition of the *Manual of Clinical Magnetic Resonance Imaging*, published in November, 1990, by the Raven Press in New York. First published in 1986, the manual has become a guidebook for performing diagnostically effective and efficient MRI examinations and is used worldwide by teaching hospitals as well as private practitioners.

As Ronald G. Evens, M.D., director of Mallinckrodt Institute stated in the Foreword of the publication, "Magnetic resonance imaging is a recent example of a technological advance that has progressed rapidly from a research program with considerable clinical potential to an imaging procedure of importance to most radiologists. As the number of MRI installations increases, a working knowledge of MRI procedures is a requirement for most radiologists and an increasing number of technologists."

MIR contributors to the manual are Mokhtar Gado, M.D., professor of radiology and director of neuroradiology; Joseph K. T. Lee, M.D., professor of radiology and director of magnetic resonance imaging; Paul L. Molina, M.D., assistant professor of radiology; and William G. Totty, M.D., associate professor of radiology.

High Utilization/ High Unit Cost

As chairman of the Board of Chancellors of the American College of Radiology (ACR), James M. Moorefield, M.D., has a special interest in the affordability of health care and cost restraints on radiological practices. Speaking at the Nineteenth Annual Wendell G. Scott Memorial Lecture on September 10, Moorefield discussed how radiological services should be examined in overall health-care costs, emphasizing particularly the targeting of those services with high utilization and high unit cost.

Basing his talk on the Medicare radiology fee schedule developed by the ACR, a project headed by Moore, he stressed the importance that Relative Value Scales (RVS), the guidelines previously used for determining radiology and other medical costs, played in the transition to fee schedules. The two more commonly used RVSS were

developed by the Harvard School of Public Health and by the ACR.

In April, 1989, radiology was placed on a fee schedule, and in 1992, the national Medicare fee schedule will go into effect. However, as Moorefield pointed out, "There are limitations, no matter which method or scale is chosen. Some of these limitations have implications for the current and future practice of radiology."

The 1989 fee schedule for radiology is different for each of the 257 carrier localities in the United States, reflecting a range of 2.6 to 1 from the highest to the lowest conversion factor.

According to Moorefield, "If radiology practices are to do well in the future economically, they must learn the lesson that management of operating expenses is essential to good business practices.

James M. Moorefield, M.D. (left); Mrs. Wendell G. Scott; and Ronald G. Evens, M.D.

Ironically, radiology is often labeled as an expensive technology to be controlled heavily by utilization guidelines. Yet there are no policy steps taken to insure that radiology is the modality of choice when cost is lower and efficacy is equal or higher."

"In conclusion, if we recognize the value of radiology in the RVS, we will be able to make RVS work positively for radiology in the future," Moorefield added.

SPOT NEWS

Ter-Pogossian Steps Aside; Welch Named Director of Radiation Sciences

There was no interruption in the flow of research conducted in the Division of Radiation Sciences as Michel M. Ter-Pogossian, Ph.D., passed his leadership of the Division to Michael J. Welch, Ph.D. Effective September 1, 1990, Ter-Pogossian, a renowned physicist and nuclear scientist, relinquished administrative responsibilities to devote his time to research and teaching.

Ter-Pogossian, known as the "Father of PET," and his team of researchers developed positron emission tomography (PET) at the Institute in the early 1970s. A pioneer in developing the use of cyclotron-produced radionuclides in biomedical research, he has played a distinctive role in developing the instrumentation applied to the practice of nuclear medicine. During the past 10 years of experimenting with PET, Ter-Pogossian and his colleagues have developed multiple techniques for measuring blood flow, blood volume, oxygen metabolism, and glucose metabolism. He was one of the first scientists to use radioisotopes to detect brain tumors and was the first scientist in the world to report the biomedical application of the sodium iodide detector for the diagnosis of these tumors.

According to Ronald G. Evens, M.D., head of the Institute, "Under the leadership of Doctor Ter-Pogossian, the Division of Radiation Sciences has become famous throughout the world for its innovative research. Washington University is fortunate to have such a distinguished scientist as Michael Welch to continue the groundbreaking work and to lead the Division in the future."

Welch is highly regarded for his work on rapid synthesis of positron labeled organic chemicals and has been involved in the development of the PET imaging of estrogen receptors in the treatment of breast cancer. His work also has been instrumental in the blood-cell labeling process that has revolutionized the use of radiolabeled cells for measurement of cell function and for detection of abnormalities. Welch's research on the labeling of chemical compounds with short-lived radionuclides is used worldwide in biology and medicine.

Welch sees "the expansion and diversification of research efforts in radiolabeled monoclonal antibodies and imaging enhancement agents used in magnetic resonance imaging as the future challenge for the Division of Radiation Sciences."

NIH Awards Research Grant to Miller

The National Institutes of Health (NIH) has awarded a three-year research grant in the amount of \$450,000 to Tom R. Miller, M.D., Ph.D., associate professor of radiology, for enhancing the capabilities of positron emission tomography (PET) imaging of the heart. Miller and coinvestigators Jerold W. Wallis, M.D.; Kondapuram S. Sampathkumaran, M.S.; Steven R. Bergman, M.D., Ph.D.; and Edward M. Geltman, M.D., have set specific goals for the project: to use computer hardware to develop new three-dimensional methods of interactive viewing of the heart, to study the effects of slice-spacing in the PET scanners, and to generate images that directly portray myocardial blood flow and myocardial oxygen utilization.

The research team will study 20 patients with heart disease along with an equal number of healthy volunteers to evaluate the new display techniques. Theirs will be the first systematic analysis of slice-spacing in PET scanners. Through the study results, improved ways to view heart images will be developed, and a determination of how closely the slices need to be placed in order to produce better images will be achieved.

"Investigators here have devoted many years to the development of PET instrumentation and PET studies of the heart. As a result, PET imaging of the heart is now a highly developed tool at the Medical Center as well as at a number of centers nationwide," says Miller. "We hope this study will lead to improvement in diagnosis of heart disease."

MIR Paper Earns President's Award

The collaborative work of Holly J. Burge, M.D.; William D. Middleton, M.D.; and Bruce L. McClennan, M.D., resulted in a winner at the September meeting in Vancouver, British Columbia, of The Society of Uroradiology. The paper, entitled "Color Doppler Ultrasound Investigation of the Ureteral Jet Phenomenon," was selected from 34 papers as a cowinner of the prestigious President's Award of The Society of Uroradiology. Chartered in 1974, the Society's membership includes international urologists who are devoted to the study and advancement of urologic imaging and intervention.

The paper focused on the diagnostic accuracy of using color Doppler ultrasound (CDU) to determine urine jet density, resulting from the ureter emptying into the bladder, and the degree of ureteral obstruction, if any. Based on a

SPOT NEWS



Thomas Murry

Residents, fellows, and trainees for 1989-1990 were (front row, left to right) Doctors David Burtner; Johnson Liou; Marie Tartar; Allen Oser; Gilbert Jost, chief, Division of Diagnostic Radiology; Larry Schertz; Ronald Evens, director of the Institute; Michael Evert; Dixie Anderson, residency program coordinator; James Duncan; Neal Frenkel; Andrew Landes; (second row, left to right) Paul Hsieh; Mark Mayhle; Thong Nguyen; Daniel Winder; Paul Kountz; Margaret Linn; Michael Postma; Douglas Smith; Clark West; Scott Stevens;


Michael Schiering; Sonke Harms; Mark Frank; (third row, left to right) Scott Baker; Mark Zobel; Benjamin Bartnicke; Henry Lee; Dale Harris; Dale Fletcher; Charles James; Thomas Hirsh; James Matthews; Allen Burns; William Horstman; Clinton Anderson; (back row, left to right) Christopher Rowe; Edith Kang; Thomas Winter; Gena Frederick; Ted Cardoso; Jamie Surratt; Steve Surratt; Holly Burge; John Clemett; Robert Smith; William Way.

study of 26 patients, who were diagnosed as having ureteral obstructions detected by intravenous urography, and 17 volunteers with no ureteral problems, the results proved that color Doppler techniques are more sensitive to fluid (urine) flow than common gray-scale imaging.

According to Bruce McClennan, M.D., director of abdominal radiology and the 1989-1990 president of The Society of Uroradiology, who also presented the

paper at the Society's 10th Postgraduate Course, "This award is a tribute to the work of Doctors Burge and Middleton and a testimony to the fact that often the most basic applications of a new technique, such as CDU, are the best."

HANG



ING

WIZARD

by Vicki Kunkler

Christina Dunn, age 16, is a special young lady—her parents, Gordon and Linda, and her brothers, Andy and Jason, tell her so every day. And her pediatrician, her surgeon, and her radiation oncologist concur. Chrissy, as she likes to be called, was diagnosed in January of this year with a rare form of cancer, so rare that there may be only eight documented cases in the United States. Myxopapillary ependymoma normally is a slow growing tumor, confined to the lower portion of the spine and involving the sacral nerve roots, that rarely metastasizes to other parts of the body. But in Chrissy's case, the tumor had grown quite large and had spread to other parts of her spinal canal.

Linda Dunn: "Chrissy has experienced more at age sixteen than most adults can ever imagine. But through it all, she's kept her sense of humor and her sweet nature."

HANGING *tough*

“The tumor had invaded the covering of the spinal cord and had spread along the spinal fluid pathway.”

Primary spinal cord tumors are unusual in someone of Chrissy’s age or younger, occurring more often in adults in their twenties or older. Early warning signs may show up in progressive weakness and abnormal sensations, such as burning or prickling, of the lower extremities.

According to Linda Dunn, “I never suspected there was a problem, and I probably would never have known anything was wrong until one of Chrissy’s friends spilled the beans on her. Her friend told me that Chrissy had fallen down the stairs at school about fifteen times.” When questioned about the falls, Chrissy admitted that her legs “just gave out.” Linda wasted no time in taking her daughter to Naresh Solanki, M.D., the family’s pediatrician. An earlier fall about 18 months previous at the local skating rink had resulted in three hairline cracks in Chrissy’s tailbone and was first thought to be the culprit. Further examinations ruled out that possibility.

Chrissy further disclosed that she experienced numbness in the backs of her legs, low backaches, intermittent headaches, and no movement in the toes of her right foot. Solanki promptly scheduled an appointment for Chrissy to see



Garrett C. Burris, M.D., neurologist and assistant professor of clinical pediatrics at St. Louis Children's Hospital

Garrett C. Burris, M.D., a neurologist who is assistant professor of clinical pediatrics at St. Louis Children's Hospital in the Washington University Medical Center.

According to Burris, “Chrissy’s symptoms could have indicated any number of problems—tumor, cyst, blood clot. My job was to find where the symptoms were coming from, what was causing the symptoms, and then put a name on it.”

Working with the Mallinckrodt Institute of Radiology pediatrics staff, Burris scheduled a series of tests to determine the cause of Chrissy's ailments. Routine X rays, which visualize air, soft tissue, and bone, showed no conclusive evidence.

Burris then decided to schedule Chrissy for magnetic resonance imaging (MRI). MRI is an excellent noninvasive modality for differentiating the soft tissues, cerebrospinal fluid, fat, and nervous tissues of the spine. The MRI scan clearly showed the tumor occupying the entire spinal canal within the tailbone and extending much higher up the canal. As the view was scanned, it quickly became apparent that this tumor was intimately involved with Chrissy's spinal cord.

"Spinal cord tumors are difficult to diagnose because they present with the same symptoms," says Burris. "It's doubly difficult to diagnose children because they're very cautious; they won't tell you all their symptoms."

The medical team working with Chrissy now was expanded to include Bruce Kaufman, M.D., a pediatric neurosurgeon on staff at Children's Hospital. Kaufman felt surgery was needed immediately. He prescribed Decadron, a steroid

medication, to reduce spinal cord edema caused by compression. On January 29, Chrissy was in the operating room for over 12 hours, from "prep time" to recovery room. The incision, extending from mid-shoulder blade to the base of the tailbone, took over 300 stitches to close.

Under microscopic scrutiny, the tumor was identified as a myxopapillary ependymoma, which has a distinctive appearance. Cube-shaped cells are arranged around a central core of the hyaline material, which contains one or several blood vessels.

"The tumor had invaded the covering of the spinal cord and had spread higher in the spine by way of the spinal fluid," says Kaufman. "No tumor was found outside of the central nervous system since neurological tumors rarely spread to other organs."

Chrissy remained in the hospital from January 29 to February 16. "Recuperating from the surgery was tough," says Chrissy. "But even tougher were the fifty hours of physical therapy and learning to walk again."

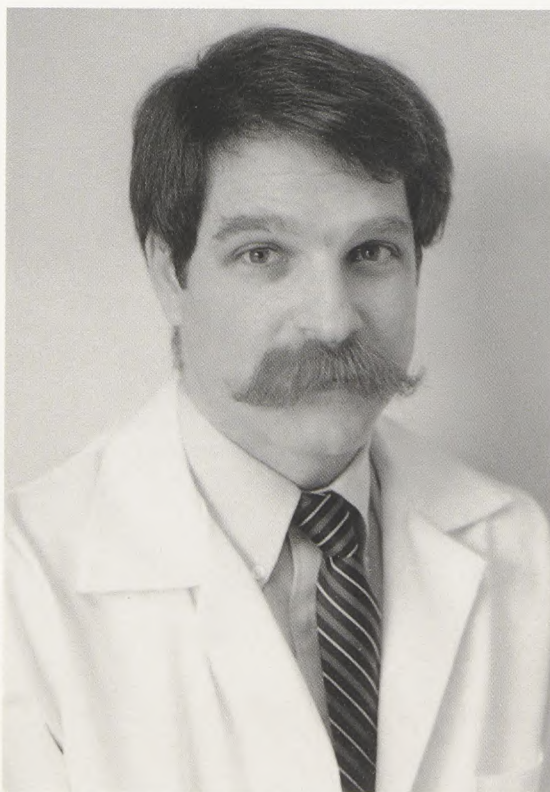
"That was hard for Chrissy," agrees Linda. "But I think the hardest part for her was learning to cope with her disease. Chrissy wouldn't talk to her dad and me about her feelings, but Nan Winters, the social worker at Children's Hospital, really got her to open up. And then when Chrissy was in radiation therapy at Mallinckrodt Institute, Lynn Nichols, the social worker there, was a godsend."

On February 16, Chrissy went home to Winfield, a small rural town about 60 miles outside of St. Louis. She had a few days reprieve before her radiation therapy began on February 19 at Mallinckrodt Institute's Radiation Oncology Center. Chrissy's first day at the Radiation Oncology Center focused on planning her treatment, or simulation.

According to Patrick Thomas, M.D., Chrissy's radiation oncologist at the Institute, "Surgery alone is often effective at eradicating local myxopapillary ependymoma, but, if the tumor is left behind, as in Chrissy's case, radiotherapy must be given."

From February 21 to April 12, Chrissy underwent more than 60 one-hour cranial-spinal radiotherapy treatments, positioned facedown on an examination

Bruce Kaufman, M.D., pediatric neurosurgeon



Photograph courtesy of St. Louis Children's Hospital

HANGING *tough*

“Recuperating from the surgery was tough, but even tougher was learning to walk again.”

table while the radiation beams were directed on each side of her hips toward the tumor site to avoid hitting her reproductive organs. Lying perfectly still for one hour, to avoid misdirecting the radiation beam, was an impossible task for the teenager; consequently, she was outfitted with a face mask that had a brace on the back of her head to prevent movement.

“The mask was worse than the nausea I had from the radiation therapy,” Chrissy says. “I took my Walkman in to treatment and listened to my favorite song, ‘Hanging Tough,’ by New Kids on the Block. It helped me get through that hour.”

In the early weeks of Chrissy’s therapy, her family made the two-hour round-trip drive five days a week. Later when the drive became too tiresome, the Dunns moved into a Holiday Inn near the medical center.

After weeks of treatment in which Chrissy suffered through some side effects of the radiation therapy (drowsiness, hair loss, nausea, and weight loss), “graduation day” came. The family had a pizza party around the pool of the Holiday Inn, their home away from home. “The party was a celebration for Chrissy, plus it was our way of saying thank you to the Radiation Oncology staff for helping us get through everything,” says Linda.



Michelle Wynn

Patrick Thomas, M.D., radiation oncologist for the Radiation Oncology Center at MIR

The family once again headed home. As they tried to settle down into a normal routine, Chrissy’s parents sensed that she was having difficulty dealing with her emotions. The reality of her disease hit home as some friends and acquaintances started to drift away, whether from an inability to understand the disease or from fear of the disease itself.

The "why me" syndrome, so common in life-threatening-disease patients, emerged. Linda credits a class assignment at Chrissy's high school with helping the teenager cope with her disease.

"Chrissy had missed a lot of school because of surgery, therapy, and treatments. Her teacher offered two options: drop the subject or prepare a video-taped speech in order to earn credit. The hard part was Chrissy's speech topic—her disease," says Linda.

In her speech, Chrissy poignantly asked her friends "to see that I am still the same person, even though I have cancer." Chrissy and her mother agree that the speech was a turning point. Her disease was brought into perspective, and the family's lives resettled into a more normal pattern.

Three weeks after her speech, Chrissy attended Camp Rainbow, a camp specifically for younger cancer patients. Seeing others her age with various forms of the disease helped alleviate the isolation she felt. Other activities followed that made Chrissy feel normal again—a family vacation to Disney World, arranged through the philanthropic organization called Dream Factory; an outing at Six Flags over Mid-America with CURE, an organization for helping younger patients deal with life-threatening diseases; the installation of a swimming pool so Chrissy could strengthen her legs; and best of all, attending a live concert of New Kids on the Block.

Chrissy's progress is carefully monitored by each member of her medical team. And that progress has been steady and good enough for her to attend

full-time classes at her high school, where she is part of the crowd—the high-top athletic shoes (to give added support to her weakened ankles) and the short hair echo the universal fashion statements of teenagers.

"Chrissy's success is the result of the medical expertise and care she received at Children's Hospital and at Mallinckrodt Institute and of her strong will to lead a normal life," says Linda Dunn. "At her visit on July 17 with Doctor Kaufman, he told her, 'I never thought I'd ever see you walk again.'"

What lies ahead for 16-year-old Christina? She is doing well presently; she does experience periods of fatigue and some vision problems. She's scheduled for a checkup this month at the Institute's Radiation Oncology Center where Thomas will evaluate the effectiveness of the radiation therapy and check for any local recurrence of the cancer—the nemesis of successful cancer treatment. The family is optimistic and will continue to take life one day at a time. □

*"...I am still the same person, even though I have cancer."
—Christina Dunn*

The Right Choice

by Vicki Kunkler

Combining Brachytherapy and External Radiation
with Lumpectomy Offers Breast Cancer Patients a
Second Chance

They were a diverse group, those 417 women who may never know the role they played in measuring the effectiveness of a medical treatment plan that could mean the difference between life and death for thousands of women. Coming from different cities, different socioeconomic levels, different heritages, and different educational backgrounds, they had one common bond. All 417 women had breast cancer, and all 417 women were included in a collaborative study between Washington University and University of Cincinnati. The study compared the success rates in treating breast cancer with lumpectomy, external radiation therapy and brachytherapy with the success rates of lumpectomy and external therapy alone.

The study, spearheaded by Robert Kuske, M.D., chief of the breast service at the Mallinckrodt Institute Radiation Oncology Center, mapped the progress of this group of patients who had undergone conservative breast cancer treatment from 1969 to 1984, a range of from five to 20 years previous to the study. One half of these women had been treated by lumpectomy (removing only the tumor plus a small margin of surrounding tissue) followed by external radiation treatments. The other half of the group had undergone lumpectomy plus brachytherapy (radiation implant therapy) in addition to external radiation.



Maxine Tawney: "All I knew was that I had to choose between keeping my breast or losing it."

The results of the five-to-eight-year follow-up were eye-opening. The women who had received brachytherapy in addition to external radiation had a 4.6 percent breast cancer recurrence rate—the lowest result ever recorded in medical literature—as opposed to a 10 to 15 percent rate with other forms of conservative treatment. The overall survival rate for women undergoing brachytherapy is similar to the survival rate of those women who have had a mastectomy. The 3,200 women who will be diagnosed with breast cancer in 1990, as estimated by the United States Department of Health, are the beneficiaries of these study results.

So, how does this life-saving, appearance-saving treatment work, and who is a good candidate for it? According to Kuske, a good candidate for brachytherapy fits into the following categories: her tumor is two inches or smaller in diameter; she has one lump, not several; the surgeon can remove all of the visible tumor; the disease has not spread to the skin or muscle surrounding her breast; and the tumor is small in relation to the size of her breast.

If the patient meets these criteria, then she and her doctor must decide if brachytherapy after a lumpectomy is the most beneficial treatment plan for her.

The Right Choice

After the tumor is surgically removed and while the patient is in the operating room, the surgeon inserts a small, hollow plastic tube called a catheter into the remaining breast tissue. The catheters are similar in size to the tube in a plastic ink pen. The catheters are similar in size to the tube in a plastic ink pen. The patient is taken to her hospital room, where thin, spaghetti-like wires containing iridium, a radioactive substance, are fed through the catheters. The wires remain in her breast from 24 to 48 hours, depending on the extent of the tumor. Then the iridium and the catheters are removed, and the patient goes home. External radiation treatments are administered on an out-patient basis. In one to two days, brachytherapy provides the same dosage of radiation that is received in one to two weeks with external radiation. This higher dosage of radiation, concentrated on the area of the breast at higher risk, can target large tumors located deep in the breast tissue.

“Brachytherapy has been offered at Mallinckrodt Institute for the last seven years, and I firmly believe the technique is a logical choice for those women who are good candidates. But there are pros and cons to every procedure, and brachytherapy is no exception,” says Kuske. “With brachytherapy, first and foremost, the breast is saved. An added plus is that there is little discomfort, and the technique has proven to be as medically effective as a mastectomy.”

“The downside of brachytherapy is that it is an invasive procedure with eleven or twelve catheters placed into the breast,” he adds. “While the patient is in the hospital, her visitors are restricted to thirty

Results of the five-to-eight-year follow-up study showed the lowest recurrence rate reported to date.

minutes a day because of the concentrated doses of radiation. And some physicians believe the cosmetic results aren't as good as with external treatments alone.”

The cosmetic quality of brachytherapy is a point of contention for Kuske. In a follow-up to the study, patients who had been treated at least three years previous and their surgeons were surveyed concerning the overall appearance of the brachytherapy-treated breast as compared with the normal breast. Of those surveyed, 96 percent were in favor of brachytherapy.

Maxine Tawney is one breast cancer survivor who applauds brachytherapy and wants other women to know about this treatment choice that can save their breasts and their lives. Maxine is no stranger to mammography, having had mammograms as far back as the early 1960s when the procedure was first gaining prominence in the United States. She had some suspicious findings about 30 years ago, all benign and attributed to problems in the milk glands that may have



T. Mike Fletcher

Robert Kuske, M.D.

resulted from several miscarriages. So, four years ago in early October, at age 63, Maxine was unprepared for the urgency in her doctor's voice when he told her “there was something on your mammogram that needs to be checked out.”

After a needle localization to determine the location of the tumor, followed by surgical biopsy, Maxine was given the bad news in the form of a choice—she had to decide between lumpectomy or mastectomy.

“My brain just froze at the idea of breast cancer. Lumpectomy followed by brachytherapy wasn't fully explained to me. All I knew was that I had to choose between keeping my breast or losing it,” explains Maxine.

She opted for lumpectomy, using the logic that "just because your toe is sore, you don't cut off your leg." She hasn't regretted the choice. The tumor was very small, found in its earliest stages,

*"With
brachytherapy, first
and foremost, the
breast is saved."*

but very deep into the breast—almost at the chest wall. And, the best news, of the 20 lymph nodes removed, all were benign. It was these statistics that made Maxine an excellent candidate

for brachytherapy, as was suggested by her oncologist at a subsequent follow-up to her surgery.

On October 22, Maxine underwent brachytherapy treatment. In mid-November, she went to Mallinckrodt Institute's Radiation Oncology Center to begin five weeks of external radiation treatments. Kuske was her radiation oncologist, and Maxine agreed to participate in his study.

According to Kuske's study results, women who have a recurrence in a breast previously treated with lumpectomy and brachytherapy will have a second chance of again saving the breast. The breast may be retreated successfully with brachytherapy. Since there

is an equal cure rate with brachytherapy and mastectomy, most recurrences will not require mastectomy.

Four years later, Maxine still feels good about her treatment choice. "Mastectomy gives up your second chance if you have a recurrence of the cancer, and to me, no one should ever want to give up a second chance at anything. I'm glad I had a choice in picking a procedure that kept me whole," she says.

Kuske agrees, "This is an exciting time for the treatment of breast cancer. We have the opportunity to give women a chance to save their breasts and their lives. I want to inform as many surgeons and patients as possible about lumpectomy and brachytherapy." □

When Biopsy Is Needed

To date, open biopsy is the only method to confirm malignancy. But often times, the tumor is benign, and physicians feel that the threat of unnecessary surgical biopsy may be discouraging women from having regularly scheduled mammograms. A special study being conducted at the Mallinckrodt Institute Breast Diagnostic Center is testing the accuracy of stereotaxic needle biopsy, a non-surgical biopsy procedure for diagnosis of breast cancer that may allay those fears.

In this one-year study, led by Judy Destouet, M.D., head of mammography, 100 women will undergo both stereotaxic needle biopsy and surgical biopsy to establish the Institute's stereotaxic accuracy rate for equipment as well as for technique.

Developed in Europe, the stereotaxic instrument operates on the same principle as a sewing machine. The breast to be biopsied is positioned between a compression plate and X-ray film, with two views taken approximately 15 degrees apart. After the lesion is pinpointed, a local anesthetic is applied to the precise area of the tumor. A needle is inserted into the breast by the radiologist, and a syringe, which creates a vacuum, is attached to a connecting tube and the hub of the needle. The vacuum from the syringe helps pull the tissue into the needle. Cells from the suspicious lesion are retained in the needle and removed from the breast. The material is then sent to the cytopathology lab for analysis to determine if the lesion is benign or malignant. For the purposes of this study, the patient also goes to the operating room for a surgical biopsy of the lesion.

Other studies show that stereotaxic needle biopsy is 50

percent less expensive than open biopsy. The procedure takes less than 60 minutes and carries a 95.5 percent accuracy rate in detecting malignant lesions.

According to Destouet, the greatest benefit for the patient is the elimination of a surgical procedure that often results in the detection of a benign tumor. Consequently, the scar tissue that develops after open biopsy and that may interfere with subsequent mammography is eliminated.

"By affording high diagnostic accuracy without the fear of unnecessary surgical biopsy, we hope this procedure will encourage more women to see their doctors and to have regularly scheduled mammograms," says Destouet. "The surgeons we work with are anxious to participate in our study because stereotaxic needle biopsy will give the surgical team additional information in planning definitive surgery." □

Audrey Davis' triumph over cervical cancer has allowed her to resume her normal activities, including her goal of handpainting a set of 39 ceramic Santas.




B Y B R I D G E T M C D O N A L D

LOOKING FORWARD

Cervical cancer wasn't supposed to happen in Audrey Davis' happy, orderly life. She and Sam Davis have lived in the same tidy South St. Louis home for 31 of the 36 years of their marriage. They reared their daughter here in this same solid brick house where they now welcome visits from their two grandsons. Audrey's 84-year-old mother lives upstairs and shares the Davises' passion for Cardinal baseball; they attend nearly 30 games a year. Looking forward to Sam's retirement in 1992, the Davises were planning many years of a healthy life together. But last year, when she first began to experience abdominal cramping, Audrey knew instinctively that the order she had worked so hard to maintain was at risk.

T. Mike Fletcher





T. Mike Fletcher

Carlos A. Perez, M.D., (left) and Perry W. Grigsby, M.D.

“**E**ven before the cramps, I just wasn’t feeling well,” she recalls, “but I couldn’t pinpoint the problem. Then I started cramping and I knew something was wrong.”

Like many women who reach menopause, Audrey had become lax in her gynecological checkups. “You read about it all the time, you hear it on television: ‘Get a checkup at least once a year’—and yet you don’t think it means you,” she says, shaking her head. “It sounds monotonous, but believe me it’s worth listening to,” she adds.

The most common symptom of cervical cancer is abnormal vaginal bleeding, such as intermittent bleeding between menstrual periods or following intercourse. Bleeding that occurs following a gynecological exam and an increased vaginal discharge also are possible warning signs. But often there are no symptoms for cancer of the cervix, and the best way to identify it in its early stage is through regular pelvic examinations and Pap smears.

On May 24, 1989, Andrew Galakatos, M.D., a gynecological oncologist on staff at Barnes

Hospital, informed Audrey that she had stage IIB cervical cancer. The diagnosis was confirmed following a complete exam; a Pap smear that showed “suspicious results;” dilation of the cervix and curettage of the uterus (a D and C), which involves scraping of the uterine lining; and a biopsy. It had been nearly six years since Audrey’s last pelvic examination.

“You hear it on TV all the time, ‘Get a check-up once a year’—and yet you don’t think it means you.”

“I told Sam, ‘If it’s my time to go, that’s fine,’ but what really upset me was thinking that I would miss seeing my grandsons grow up,” she recalls.

Audrey’s fears were soon put to rest. “Doctor Galakatos laid everything out on the table. He said my condition was serious, but he believed we could beat it.”

There is no specific age group for women who are vulnerable to cervical cancer; it is detected in its various stages in women ranging from ages 20 to

70, and although incidents of cervical cancer are on the rise, early detection and new forms of treatment are increasing chances of survival. According to Carlos A. Perez, M.D., professor of radiology and director of the Radiation Oncology Center at Mallinckrodt Institute of Radiology (MIR), “We are seeing a rise in the number of women between the ages of 30 and 40 with very early cancer that has not yet spread below the lining of the cervix and a decline in the number of women between the ages of 40 and 50 with advanced cases, or those with invasive lesions.” He attributes those factors to an increased awareness in women of the need for regular pelvic exams.

“**R**adiation therapy has been used in treating cervical cancer since the beginning of this century,” explains Perez. “But over the past thirty years, the development of new equipment, safer radioisotopes, and improved treatment planning, in addition to our understanding better the natural history, biology and pathologic features of the disease, have contributed to improved treatment results in these patients.” There also is, he says, a closer working relationship now between the gynecological oncologist and the radiation oncologist, which leads to a favorable multidisciplinary approach.

The choice of treatment for cervical cancer depends on the patient’s general health and the stage of the disease. In its early stages, cervical cancer may be treated with surgery or radiation or a combination of the two. An advantage of treating premenopausal women with sur-

gery is the preservation of the hormone-producing function of the ovaries while removing the uterus and the cervix. In sexually active women, surgery may be preferred because it may leave the vagina more pliable than radiation therapy. Both treatments are equally effective, with cure rates of 85 to 90 percent at 10 years.

Radiation is considered the preferred treatment in advanced cervical carcinoma, with a cure rate at 10 years of 67 percent (stage IIB) and 40 percent (stage III). In older women, radiation is more easily tolerated than surgery, particularly if there are other medical problems.

Both external irradiation (an important part of the treatment) and intracavitary irradiation are used in treating cervical cancer. At MIR, external irradiation is delivered by a high energy X-ray linear accelerator, which directs a beam of radiation to the treatment area. According to Perez, within the last 30 years external techniques have made significant advances through the use of higher energy megavoltage external beams, which allow larger doses of irradiation to be delivered to the pelvic tissues and lymph nodes.

The intracavitary treatment, an implant procedure called brachytherapy, is critical to the treatment program and has a good success rate. At MIR all stages of cervical cancer are treated by brachytherapy in addition to surgery or external irradiation, although very early stage cervical cancer may be treated solely by brachytherapy.

“**B**arnes Hospital and Mallinckrodt Institute are noted internationally for their gynecological oncology treatment and research,” says Perry Grigsby, M.D., associate professor of radiology, clinical chief of the radiation therapy team, and an authority on brachytherapy.

According to Grigsby, the use of radium in the treatment of cervical cancer has been around for over 60 years. During the 1930s and '40s, the radioactive source (iridium) was inserted into the catheters while the patient was in the operating room, thus exposing the medical team to the radioactive material. Each time the nurses entered the patients' rooms, they also were needlessly exposed to irradiation.

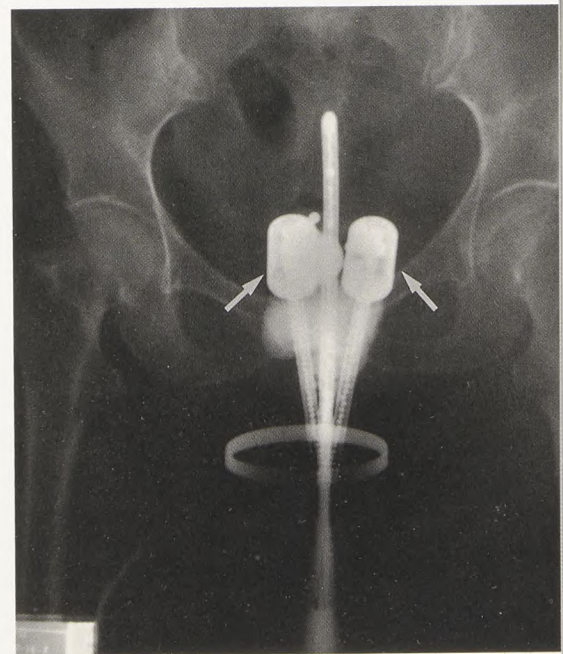
From the 1960s through the 1980s, afterloading of the iridium became prevalent. The catheters were inserted into the patient in the operating room, but the iridium was not placed until the patient was taken to her hospital room. In this method, the length of exposure to the iridium was lessened for the medical team. Remote afterloading, adopted at MIR in 1987, has now become the procedure of choice. Again, the catheters are placed into the patient in the operating room, and after the patient is taken to her hospital room, the iridium is inserted into the catheters by a remote-controlled unit outside of the patient's room. “Today's afterloading is not only more intense and focused,” says Grigsby, “the remote control reduces radiation exposure to everyone involved.”

Jeffrey F. Williamson, Ph.D., associate professor of radiology and chief of the brachytherapy

physics group in MIR's department of radiation physics, adds that remote afterloading brachytherapy allows more flexibility in tailoring a treatment plan. “With this system we are able to aim in beams to cover the targeted tissue and miss the critical anatomical structures,” he notes. “It also provides a more uniform dose distribution so that hot and cold spots can be avoided.”

Williamson explains that dose distribution can be optimized to limit the dose received by the bladder and rectum by altering the source positions within the catheter. “Afterloading presents the physician with alternatives, such as the dose per unit of time, and provides quality assurance,” says Williamson. “The system monitors its own

At MIR, all stages of cervical cancer are treated with brachytherapy implants (arrows).




LOOKING FORWARD

activity, insuring that treatment remains constant."

The treatment can be interrupted at any time when patient care is required or during visiting hours. The radiation sources, which are transferred pneumatically, are withdrawn inside the shielding of the afterloading system. A printer automatically records all interruptions and monitors the position of the radioactive sources, ensuring that they are within one millimeter accurate.

Audrey's treatment plan first was prescribed by Perez. Then through the use of computed tomography (CT) and fluoroscopy, a team of dosimetrists computed the doses delivered to the treatment area. In the simulation lab, X rays of the implants were made and used to complete the computer treatment-planning process. The films allowed the technologists to double-check the position of the implants, ensuring greater accuracy before brachytherapy actually began. By entering into the computer the dimensions of the treatment area, the dose prescribed, and other factors including the dosage effect on other critical organs, a plan was tailored to Audrey's particular treatment needs.

Because Davis lives only a few miles from the Washington University Medical Center, her treatment began with two doses of external radiation per day, delivered in the morning and afternoon, five days per week for three weeks. The doses, at two per day, were smaller and therefore easier on Audrey's system than a higher one-dose-per-day treatment. Thus, the only side effects she experienced from the treatment were mild diarrhea and fatigue.



T. Mike Fletcher

Audrey was admitted to Barnes Hospital to begin preparations for intracavitary therapy on a Monday, and after treatment, was released the following Friday morning. During her treatment, Audrey slept a great deal, and although there was no real discomfort, she says it was difficult for her to remain in the same position so as not to disturb the placement of the implants.

The intracavitary treatment was followed by a continuation of the external irradiation for an additional three weeks. After the series of external treatments was completed, Audrey entered the hospital again on July 10, 1989, as an inpatient to receive a second and final intracavitary treatment that involved 70 hours of irradiation. On July 19, following four additional doses of external irradiation, her treatment was completed.

"Then it was crying time in the Radiation Oncology Center," she recalls. "The radiation therapists who cared for me were glad to see the treatments completed; we had developed friendships and I knew I would miss them. They gave me the best care possible."

As chief of brachytherapy physics, Jeffrey Williamson, Ph.D., ensures that the dose distribution for each patient's treatment plan is carefully monitored.

Nearly 18 months later, through the expertise of her doctors and with the constant support of her family, Audrey Davis has returned to the active social and family life that has been so important to her well-being. Following a series of promising follow-up examinations with Galakatos and Perez, she feels confident that she has overcome her disease and will continue to schedule examinations every six months.

For now, when not spending time with her grandsons or volunteering at church, she keeps busy sanding and painting her growing collection of ceramic Santas. And you can expect to find Audrey Davis dressed in red at Busch Stadium for many seasons to come. □

FYI

THE DIRECTOR'S OFFICE REPORT

NEW STAFF

Maryellen E. Amato, M.D., instructor in clinical radiology, Division of Diagnostic Radiology.

Carolyn J. Anderson, Ph.D., research associate in radiology, Division of Radiation Sciences.

Ranajit K. Bera, Ph.D., research instructor in radiology, Division of Radiation Sciences.

James A. Brink, M.D., assistant professor of radiology, Division of Diagnostic Radiology.

Farrokh Dehdashti, M.D., instructor in radiology, Division of Nuclear Medicine.

Barbara A. Garner, M.D., instructor in radiology, Division of Nuclear Medicine.

Charles F. Garvin, M.D., instructor in clinical radiology, Division of Diagnostic Radiology.

Clayton R. Hunt, Ph.D., assistant professor of radiology, Division of Radiation Oncology.

Scott A. Mirowitz, M.D., assistant professor of clinical radiology, Division of Diagnostic Radiology.

John H. Niemeyer, M.D., instructor in clinical radiology, Division of Diagnostic Radiology.

William R. Reinus, M.D., assistant professor of clinical radiology, Division of Diagnostic Radiology.

Janice R. Semenkovich, M.D., instructor in clinical radiology, Division of Diagnostic Radiology.

Sally J. Schwarz, M.S., research instructor in radiology, Division of Nuclear Medicine.

OFF STAFF

Bruce L. Bower, M.D., cochief resident, Diagnostic Radiology, 1988-1989, completed a four-year residency in Diagnostic Radiology, a one-year fellowship in interventional radiology, and has entered private practice with San Diego Diagnostic Radiology.

James W. Brodack, Ph.D., research assistant professor of radiology, Division of Radiation Sciences, has accepted a position as senior research specialist in the Nuclear Medicine Research, Science and Technology Division of Mallinckrodt Medical, Inc.

Holly J. Burge, M.D., instructor in radiology, completed a one-year fellowship in abdominal radiology and has entered private practice with Wake Radiology Consultants, Raleigh, North Carolina.

Ted J. Cardoso, M.D., instructor in radiology, completed a four-year residency in Diagnostic Radiology, a one-year fellowship in abdominal radiology, and has entered private practice with Sheer, Aharn and Associates, Tampa, Florida.

Steven S. Eilenberg, M.D., instructor in radiology, completed a four-year residency in Diagnostic Radiology, a one-year fellowship in magnetic resonance imaging, and has entered private practice in Oceanside, California.

Michael B. Evert, M.D., cochief resident, Diagnostic Radiology, 1989-1990, completed four years of training in Diagnostic Radiology and has entered private practice with Greenville Radiology, Greenville, South Carolina.

Mark S. Frank, M.D., instructor in radiology, completed a one-year fellowship in chest radiology and has accepted a position in the Division of Thoracic Radiology and Cross Sectional Imaging, University of Washington, Seattle.

Donald E. Gayou, Ph.D., research associate in radiology, Division of Diagnostic Radiology, has accepted a position in the Department of Orthopedic Surgery, Washington University School of Medicine.

Sonke Harms, M.D., completed three years of training in Diagnostic Radiology and has accepted a position in academic radiology in Switzerland.

Thomas F. Hirsh, M.D., completed a four-year residency in Diagnostic Radiology and has entered private practice with The Radiology Group, P.C., Portland, Oregon.

Dah-Ren Hwang, Ph.D., research instructor in radiology, Division of Radiation Sciences, has accepted a position at Kettering Hospital, Dayton, Ohio.

Charles A. James, M.D., completed four years of training in Diagnostic Radiology and has received a pediatric radiology fellowship at Arkansas Children's Hospital, Little Rock.

Corbin R. Johnson, M.D., instructor in radiology, completed three years of residency and a one-year fellowship in Radiation Oncology, and has accepted a position at Little Company of Mary Hospital, Evergreen Park, Illinois.

Paul D. Kountz, Jr., M.D., completed four years of training in Diagnostic Radiology and has entered private practice in Rome, Georgia.

Robert R. Kuske, M.D., assistant professor of radiology and chief of the breast service in the Radiation Oncology Center, has accepted the position of chairman of Radiation Oncology, Ochsner Clinic, New Orleans.

Margaret R. Linn, M.D., instructor in radiology, completed a one-year fellowship in musculoskeletal radiology and has entered private practice in Seattle, Washington.

Richard D. Lovett, M.D., cochief resident, Radiation Oncology, 1988-1989, completed three years of residency in Radiation Oncology and a one-year American Cancer Society Clinical Fellowship in Radiation Oncology. He has joined the staff of the Department of Radiation Oncology, Medical Center Hospital of Vermont, Burlington.

Victor A. Marcial-Vega, M.D., instructor in radiology, Division of Radiation Oncology, has joined the staff of the Cancer Treatment Center, Baptist Hospital of Miami, and has accepted an academic position at the University of Miami.

Carla J. Mathias, B.A., research associate in radiology, Division of Radiation Sciences.

FYI

THE DIRECTOR'S OFFICE REPORT

Continued from page 21.

Andrea H. McGuire, M.D., instructor in radiology, Division of Nuclear Medicine, has entered private practice at Mercy Hospital, Des Moines, Iowa.

Thong H. Nguyen, M.D., instructor in radiology, completed a one-year fellowship in neuroradiology and has received a neuro-radiology fellowship at the University of California Medical Center, Los Angeles.

Edward S. Rollins, M.D., instructor in radiology, completed a one-year fellowship in interventional radiology and has entered private practice in Johnson City, Tennessee.

Larry D. Schertz, M.D., chief resident, Diagnostic Radiology, 1989-1990, completed a four-year residency in Diagnostic Radiology and has received a neuro-radiology fellowship at Johns Hopkins Hospital, Baltimore, Maryland.

Susan J. Shapiro, M.D., instructor in radiology, has entered private practice in Belleville, Illinois.

James N. Suojanen, M.D., instructor in radiology, Division of Diagnostic Radiology, has joined the staff of New England Deaconess Hospital, Boston.

V. Marie Tartar, M.D., completed four years of training in Diagnostic Radiology and has received a magnetic resonance imaging fellowship at the University of California, San Diego.

Thomas C. Winter, III, M.D., completed four years of training in Diagnostic Radiology and has received a magnetic resonance imaging fellowship at the University of Washington, Seattle.

James H. Wynstra, M.D., instructor in radiology, completed three years of residency and a one-year fellowship in Radiation Oncology, and has joined the staff at St. Johns Hospital, Springfield, Illinois.

John B. Zimmerman, Ph.D., assistant professor of computer applications in radiology, Division of Diagnostic Radiology, has accepted a position with Sun Microsystems, Research Triangle Park, North Carolina.

Martin S. Weinhaus, Ph.D., assistant professor of radiology, Division of Radiation Oncology, has joined the staff of the Department of Radiation Oncology at Hahnemann University, Philadelphia.

FIRST-YEAR POSTGRADUATES

Thomas H. R. Farmer, M.D., received his Bachelor of Arts degree in religion and his medical degree from Duke University.

Rachel J. Fineberg, M.D., graduated from Dartmouth College with a Bachelor of Arts degree in comparative literature. She received her medical degree from Indiana University School of Medicine. Fineberg is a member of AOA.

Hamid R. Latifi, M.D., graduated from the University of California at Los Angeles with a Bachelor of Science degree and a Master of Arts degree in biology. He received his medical degree from Washington University School of Medicine. Latifi is a member of AOA.

William B. Mehard, M.D., received his Bachelor of Arts degree in biology from Washington University and his medical degree from the Medical University of South Carolina. He is a member of AOA.

Shawn P. Quillin, M.D., graduated from the University of Wisconsin with a Bachelor of Science degree in chemical engineering and received his medical degree from Washington University School of Medicine.

Spencer M. Smith, M.D., received his Bachelor of Science degree in zoology from Brigham Young University and his medical degree from Duke University. He is a member of AOA.

Nitin K. Tanna, M.D., graduated from the University of Rochester with a Bachelor of Arts degree in biology. Tanna received his medical degree from the University of Pennsylvania.

NEW FELLOWS

Steven L. Anolik, M.D., instructor in radiology, is a fellow in Radiation Oncology. He completed three years of residency in Radiation Oncology at Mallinckrodt Institute of Radiology.

Kenneth T. Bing, M.D., instructor in radiology, is a fellow in interventional radiology. He received his medical degree from the University of Virginia, Charlottesville. Bing completed his internship at the University of Kentucky, Lexington, and his residency in radiology at the University of Colorado, Denver. He has received American Board of Radiology certification.

Joseph A. Borrello, M.D., instructor in radiology, is a fellow in magnetic resonance imaging. He received his Bachelor of Science degree in biochemistry from the University of Michigan, Dearborn, and his medical degree from the University of Michigan, Ann Arbor. Borrello completed his internship at Stanford University and his residency in radiology at the University of Michigan, Ann Arbor. He has received American Board of Radiology certification.

Daniel F. Broderick, M.D., instructor in radiology, is a fellow in neuroradiology. He received his Bachelor of Science degree in biology from Saint Ambrose College, Davenport, Iowa, and his medical degree from the University of Illinois. He completed his residency in diagnostic radiology at Mayo Clinic, Rochester, Minnesota. Broderick is a member of AOA.

Lawrence D. Dalan, M.D., instructor in radiology, is a fellow in interventional radiology. He received his Bachelor of Science degree in microbiology and his medical degree from the University of Washington. He completed his internship at the University of Washington, Seattle. Dalan

FYI

completed one year of residency in internal medicine at the University of Washington and three years of residency in radiology at the University of Minnesota, Minneapolis/St. Paul. He has received American Board of Radiology certification.

Kavita K. Erickson, M.D., instructor in radiology, is a fellow in neuroradiology. She received her Bachelor of Science degree in zoology from Louisiana Tech University, Ruston, and her medical degree from Louisiana State University School of Medicine, New Orleans.

Dale M. Fletcher, M.D., instructor in radiology, is a fellow in abdominal radiology. He completed four years of training in diagnostic radiology at Mallinckrodt Institute of Radiology.

Karen J. Halverson, M.D., instructor in radiology, is a fellow in Radiation Oncology. She completed three years of residency in Radiation Oncology at Mallinckrodt Institute of Radiology.

Bernadette V. Jakomin, M.D., instructor in radiology, is a fellow in abdominal radiology. She received her Bachelor of Science degree in biology from Cleveland State University and her medical degree from Case Western Reserve University, Cleveland. Jakomin completed her residency in diagnostic radiology at Cleveland Clinic Foundation. She has received American Board of Radiology certification.

Jeffrey J. Kovalic, M.D., instructor in radiology, is a fellow in Radiation Oncology. He completed three years of residency in Radiation Oncology at Mallinckrodt Institute of Radiology.

Johnson Liou, M.D., instructor in radiology, is a fellow in magnetic resonance imaging. He completed a four-year residency at Mallinckrodt Institute of Radiology.

Jeff M. Michalski, M.D., instructor in radiology, is a fellow in Radiation Oncology. He completed two years of residency in Radiation Oncology at Mallinckrodt Institute of Radiology.

P. Kim Nelson, M.D., instructor in radiology, is a fellow in neuroradiology. He completed four years of training at Mallinckrodt Institute of Radiology.

Jonathan D. Root, M.D., instructor in radiology, is a fellow in chest radiology. He completed three years of training in diagnostic radiology at The Jewish Hospital, St. Louis.

Thomas M. Vesely, M.D., instructor in radiology, is a fellow in interventional radiology. He received a Bachelor of Arts degree in theatre arts, a Bachelor of Science degree in microbiology, and a Bachelor of Science degree in medical technology from the University of Minnesota. He received his medical degree from Mayo Medical School, Rochester. Vesely completed his residency in diagnostic radiology at Mayo Clinic.

Mary Vogelsang Graham, M.D., instructor in radiology, is a fellow in Radiation Oncology. She completed three years of residency in Radiation Oncology at Mallinckrodt Institute of Radiology.

Thomas W. Zusag, M.D., instructor in radiology, is a fellow in Radiation Oncology. He completed three years of residency in Radiation Oncology at Mallinckrodt Institute of Radiology.

FIRST-YEAR RESIDENTS

Colin P. Derdeyn, M.D., as an Echols Scholar, received his Bachelor of Arts degree and his medical degree from the University of Virginia, Charlottesville. He completed his internship at the University of North Carolina Hospital, Chapel Hill.

Howard P. Forman, M.D., received his Bachelor of Science degree in biomedical science from the City College of New York, New York City, and received his medical degree from State University of New York, Stony Brook. Forman completed his internship at Winthrop University Hospital, Mineola, New York. He is a member of AOA.

Linda R. King, M.D., received her Bachelor of Arts degree in chemistry at the University of Pennsylvania, Philadelphia, and her medical degree at the University of Pennsylvania School of Medicine. She completed her internship at Pennsylvania Hospital, Philadelphia.

L. Santiago Medina, M.D., received his medical degree from the Instituto de Ciencias de la Salud-Ces, Colombia, South America. He completed his internship at Medellin General Hospital, Colombia, South America.

Maria E. Schmidt, M.D., received her Bachelor of Science degree in biology from Stanford University and her medical degree from Yale University. Schmidt

completed her internship at Naval Hospital in San Diego and one year of residency in radiology at Mercy Catholic Medical Center at Darby, Pennsylvania.

Neal R. Stewart, M.D., received his medical degree from the University of Otago, Dunedin, New Zealand, and the Fellow degree in radiology from the Royal Australasian College of Radiologists. He completed his internship at Canterbury Hospital, New Zealand, and a five-year residency in radiology at Christ Church Hospital, New Zealand.

Constance M. Stone, M.D., received her Bachelor of Science degree in biology from Wofford College, Spartanburg, South Carolina, and her medical degree from the Medical University of South Carolina. She completed her internship and a three-year residency in general surgery at Barnes Hospital. Stone is a member of AOA.

RADIATION ONCOLOGY RESIDENTS

Timothy R. O'Leary, M.D., received his Bachelor of Arts in physics from Northwestern University and his medical degree from Loyola University. He completed his internship at Deaconess Hospital, St. Louis.

James V. Piephoff, III, M.D., received his Bachelor of Science degree in biology from The Citadel, Charleston, South Carolina. He received his medical degree from the University of South Carolina, Columbia. Piephoff completed his internship at St. John's Mercy Medical Center, St. Louis.

FYI

THE DIRECTOR'S OFFICE REPORT

Continued from page 23.

NUCLEAR MEDICINE RESIDENTS

Henry H. L. Shih, M.D., received his Associate Bachelor degree and Associate Master degree in chemistry from Harvard University. He received his medical degree from Jefferson Medical College at Thomas Jefferson University, Philadelphia. He completed his internship at Santa Clara Valley Medical Center, San Jose, California.

Andre S. Strezembosz, M.D., received his Bachelor of Science degree in biology from Purdue University and his medical degree from Washington

University School of Medicine. He completed his internship and two years of residency in internal medicine at Indiana University Medical Center, Indianapolis. He also completed three years of training in diagnostic radiology at The Jewish Hospital, St. Louis. Strezembosz has received board certification in internal medicine.

PROMOTIONS

Perry W. Grigsby, M.D., was promoted to associate professor of radiology.

Barbara S. Monsees, M.D., was promoted to associate professor of radiology.

Jonas Singer, M.D., was promoted to assistant professor of radiology.

Pain" at the University of Birmingham Course on Neuroradiology Update with Emphasis on MRI, Birmingham, Alabama, October 19-21. Gado lectured on "CT and MR of Hemorrhage, Aneurysm and Arteriovenous Malformation;" "Demyelinating Diseases;" and "Cervical Spine Imaging Techniques: Protocols and Anatomy" at the 17th Annual Course on CT and MRI of the Brain, Head and Spine, Chicago, November 1-2.

Barbara B. Hasse, R.N., B.S.N., M.A.Ed., nursing supervisor of Radiation Oncology, spoke on "Lung Cancer—Nursing Implications in Radiation Therapy" at the Lung Cancer Workshop, sponsored by Barnes Hospital, St. Louis, August 3. She lectured on "Skin Care Needs in Radiation Therapy" and "Breast Cancer—Alternative to Mastectomy" at the American Society of Radiologic Technologists Specialty Conference, Chicago, August 23-26. Hasse presented "Radiation Therapy: Nursing Implications" at the St. Louis Chapter of the Oncology Nursing Society, September 17.

Jay P. Heiken, M.D., associate professor of radiology and codirector of computed body tomography, lectured on "MRI of the Liver" at the Greater Kansas City Radiological Society, and on "CT of the Peritoneal Spaces" at the Kansas University Medical Center and at St. Luke's Medical Center, Kansas City, October 10. He spoke on "MRI Evaluation of Cervical Carcinoma," "Hysterosalpingographic Evaluation of Female Infertility,"

"MRI Evaluation of Bladder Carcinoma," "MRI of Prostate Carcinoma," and "Testicular Tumors: Radiologic Evaluation" at the Third International Imaging Course, sponsored by the Chinese University of Hong Kong and the Medical College of Wisconsin, held in Hong Kong, October 29-November 4.

Joseph K.T. Lee, M.D., professor of radiology and director of magnetic resonance imaging, was invited plenary session speaker at the Society of Magnetic Resonance in Medicine, New York, August 20-24. He lectured on "Current Status of Abdominal MRI" and presented the paper "Evaluation of Renal Masses with RASE," coauthored with **Steven Eilenberg, M.D.**, instructor in radiology; **Jeffrey Brown, M.D.**, assistant professor of radiology; **Jay Heiken, M.D.**, associate professor of radiology and codirector of computed body tomography; and **Scott Mirowitz, M.D.**, instructor in radiology. As an invited speaker he presented "Clinical Applications of MRI" and delivered seven additional lectures on MRI/CT of various chest and abdominal organs at the 6th ASEAN Congress of Radiology, Kuala Lumpur, Malaysia, August 31-September 2. Lee spoke on "Update in CT Staging of Gynecologic Neoplasms" at The Society of Uroradiology 10th Postgraduate Course, Vancouver, British Columbia, September 10-14.

VISITING PROFESSORS & INVITED LECTURERS

Bahman N. Emami, M.D., professor of radiology, as invited lecturer, spoke on testes, clinical hyperthermia, esophagus, lungs, mediastinum, and heart in addition to citing a number of case reviews at the Radiation Oncology Review Course, sponsored by the Osler Institute, Chicago, September 19-25. He presented "Interstitial Hyperthermia and Radiation Therapy in the Treatment of Malignant Tumors" at the Hyperthermia Clinical Conference, Valhalla, New York, October 5-6.

Mokhtar Gado, M.D., professor of radiology and chief of neuroradiology, lectured on "MRI of the Brain: Basic Concepts," "Lesions of the Sella Region," and "Degenerative Diseases of the Lumbar Spine" at the Harvard Postgraduate Course on Current Concepts in Neuroradiology, Head and Neck Radiology and Neuro-MRI, Boston, October 1-3. As a visiting professor, he spoke on "Basic Concepts of Magnetic Resonance Imaging of the Brain," "MR Evaluation of Posterior Fossa Tumors," "MR of Cerebral Infarction," and "MR in the Evaluation of Sciatica and Low Back

FYI

Bruce L. McClennan, M.D., professor of radiology, spoke on "Contrast Media and Risk Management Issues" at the St. Louis Association of Healthcare Risk Managers Meeting, St. Louis, October 3. McClennan, as a member of the Society and as a board of directors representative, attended the Missouri Radiological Society Meeting, Lake Ozark, Missouri, October 27-28.

Stephen M. Moerlein, Ph.D., associate professor of radiation chemistry in radiology and associate professor of biochemistry, presented "Measurement of Benzodiazepine Receptor Binding In Vivo with N- ω -[F-18] Fluoroethyl-flumazenil and Positron Emission Tomography," coauthored with **Joel S. Perlmutter, M.D.**, assistant professor of neurology and research assistant professor of radiology, at the 20th Annual Meeting of the Society for Neuroscience, St. Louis, October 28-November 2.

Paul L. Molina, M.D., assistant professor of radiology, as invited speaker, presented "The Role of Computed Tomography in Bronchogenic Carcinoma" at the Third Annual Lung Cancer Seminar, Erie, Pennsylvania, October 5. As a visiting professor, he lectured on "CT and MRI of Thoracic Vascular Disease," "CT and MRI of Mediastinal Masses—Differential Diagnosis," "CT and MRI of the Pericardium," and "CT of Peridiaphragmatic Processes" at the Third International Imaging Course, sponsored by the Chinese University of Hong Kong, Shatin, October 29-November 4. He spoke on "CT and MRI of Thoracic

Vascular Disease" and "CT and MRI of Mediastinal Masses—Differential Diagnosis" at Greenlane Hospital, Auckland, New Zealand, November 5. Molina presented "CT of the Pleura" at Christchurch Hospital, Christchurch, New Zealand, November 7.

William A. Murphy, Jr., M.D., professor of radiology, lectured on "Bone Marrow MRI" and "MRI of Soft Tissue Tumors" at the Organ Imaging Review Course, University of Toronto, September 14.

Carlos A. Perez, M.D., professor of radiology and director of the Radiation Oncology Center, presented "Magnetic Resonance, Its Application in Radiotherapy," "Radiotherapy in Carcinoma of the Prostate," "Brachytherapy in Brain Tumors," and "Microelectron Afterloading Brachytherapy" at the Mexican Society of Radiotherapy, Monterrey, October 31-November 3. As an invited lecturer, Perez spoke on "Cancer of the Uterine Cervix" and "Impact of Treatment Planning and Quality Assurance on Cancer Therapy Outcome" at the All Union Society Congress of Radiologists and Radiotherapists, Leningrad, November 12-17.

Joel S. Perlmutter, M.D., assistant professor of neurology and research assistant professor of radiology, spoke on "PET Measured Brain Blood Flow Responses in Nonhuman Primates" at the Third International Conference on Peace Through Mind/Brain Science, Hamamatsu, Japan, August 5. He presented "Non-steady State Measurement of In

Vivo Receptor Binding with Positron Emission Tomography," coauthored with **Stephen M. Moerlein, Ph.D.**, associate professor of radiation chemistry in radiology; **Dah-Ren Hwang, Ph.D.**, research instructor in radiology; and **Richard D. Todd, M.D.**, assistant professor of psychiatry; and "Measurement of Benzodiazepine Receptor Binding with In Vivo N- ω -[F-18] Fluoroethyl-flumazenil and Positron Emission Tomography," and "Vibration-induced Cerebral Blood Flow Responses: Effects of Aging," coauthored with **Lee W. Tempel, M.D.**, research instructor in neurology, at the Society of Neuroscience Meeting, St. Louis, October 28-November 2. As invited lecturer, Perlmutter spoke on "PET Investigations of Dystonia" at the Dystonia Medical Research Foundation Meeting, Kansas City, October 13. He presented "Post-encephalitic Movement Disorder with Spontaneous Remission" at the Hyperkinetic Movement Disorders Symposium, Atlanta, October 14.

Michel M. Ter-Pogossian, Ph.D., professor of radiation sciences, presented "The Many Roles of Positron Emission Tomography in Oncology" at the 15th International Cancer Congress, Hamburg, Germany, August 16-22.

Michael W. Vannier, M.D., professor of radiology, director of the Division of Clinical Research, and head of the image processing lab, presented a short course on "Introduction to 3-D Imaging in Medicine" at SPIE-The International Society for

Optical Engineering-Midwest '90, Rosemont, Illinois, September 28. He was a panelist in a discussion group on "Blow-Out Fractures of the Orbital Floor" at the 84th Annual Scientific Assembly of the Southern Medical Association, Nashville, Tennessee, October 14-17. He lectured on "Introduction to 3-D Imaging" and "MRI Data Reconstruction" at the 3-D Neuroimaging: Theory and Clinical Applications Course, Johns Hopkins Medical Institution, Baltimore, October 30-31. As a session chairman, Vannier collaborated with researchers at Washington University and Johns Hopkins on "Automated Production of Custom Bone Replacements," "The Biological Implications of Varying Element Design in Finite-Element Scaling Analyses of Growth," "Three Dimensional Solid Modeling of the Canine Biventricular Unit," and "Microcomputer-Based Workstations for Radiographic Periodontal Disease Quantification" at the 12th Annual International Conference IEEE Engineering in Medicine and Biology Society, Philadelphia, November 1-4. As invited lecturer, Vannier presented "Brain Cortical Surface Quantitation by MRI" to the Medical Image Processing Group, Department of Radiology, University of Pennsylvania, November 5. He lectured on "3-D X-Ray Imaging" at the 1990 Fall Meeting of the Materials Research Society, Boston, November 26-December 1.

FYI

VISITING PROFESSORS & INVITED LECTURERS

Continued from page 25.

Anthony J. Wilson, M.D., assistant professor of radiology, as invited speaker, lectured on "MRI of Avascular Necrosis" and moderated a discussion on "MRI of Bone Marrow and Osteomyelitis" at the Symposium on Magnetic Resonance of the Musculoskeletal System, Bonn, Germany, September 28.

John W. Wong, Ph.D., assistant professor of radiation physics in radiology, presented "On-line Radiotherapy Verification Systems" to the Southwest Chapter of the American Association of Physicists in Medicine, Carson, California, September 20. He spoke on "Advances in Radiotherapy

Treatment Planning and Verification," "A Cascade Model to Calculate Photon-Electron Transport in Photon Beam Dose Calculation," "Two-Dimensional Areal Scintillators for Rapid Teletherapy and Brachytherapy Dosimetry," and "A Fiber-Optic Imaging System for On-line Radiotherapy Verification" at the 10th International Conference on the Use of Computers in Radiation Therapy, Lucknow, India, November 11-14. As an invited speaker, Wong presented "Rapid Areal Scintillation Dosimetry for External Beams and Brachy-Radiotherapy" and "Treatment Verification Using On-line Imaging Systems" at the Toyko PC User Group, Toyko, November 22-23.

Eric E. Klein, M.S., and **Robert R. Kuske, M.D.**, "Changes in Photon Dosimetry Due to Breast Prostheses."

Zuofeng Li, D.Sc., and **Jeffrey Williamson, Ph.D.**, "Volume-Based Geometric Modeling for Radiation Transport."

John W. Matthews, D.Sc.; **William Harms, B.S.**; **Robert Drzymala, Ph.D.**; and **James Purdy, Ph.D.**, "Advances in 3-D Radiation Treatment Planning System."

Eric D. Slessinger, M.S.; **Jeffrey F. Williamson, Ph.D.**; **Perry W. Grigsby, M.D.**; and **Carlos A. Perez, M.D.**, "Implementation of a New Remote Afterloading System for Gynecological Brachytherapy."

Martin S. Weinhaus, Ph.D., "Arbitrary-Plane Images Sampled From Within a 3-D CT-Image Dataset: Application to a Radiation Oncologist's Workstation."

Jeffrey F. Williamson, Ph.D., "Comparison of Measured and Calculated Dose Rates in Water Near I-125 and Ir-192 Seeds."

Jeffrey F. Williamson, Ph.D.; **John W. Wong, Ph.D.**; and **Martin S. Weinhaus, Ph.D.**, "Rapid 2-D Brachytherapy Dosimetry Using a Fluorescent Screen."

John W. Wong, Ph.D.; **T. C. Leung, M.S.**; and **Martin S. Weinhaus, Ph.D.**, "A Method to Evaluate Daily Treatment Portal Verification Images."

John W. Wong, Ph.D.; **William S. Ge, Ph.D.**; **Walter R. Binns, Ph.D.**; and **Joseph Klarmann, Ph.D.**, "Rapid 2-D External Photon and Electron Beam Dosimetry Using A Sheet of Plastic Scintillator."

Thomas W. Zusag, M.D., and **James A. Purdy, Ph.D.**, "Feasibility of a Macintosh-Based Clinical Dosimetry System."

AMERICAN SOCIETY FOR THERAPEUTIC RADIOLOGY AND ONCOLOGY

The following Mallinckrodt Institute staff members participated in the 32nd Annual Scientific Meeting of the American Society for Therapeutic Radiology and Oncology, Miami Beach, October 15-20.

SCIENTIFIC SESSIONS

Bahman N. Emami, M.D., presented "Combined Hyperthermia and Irradiation in Treatment of Superficial Tumors: Results of a Prospective Randomized Trial of Hyperthermia Fractionation (1/wk vs 2/wk)."

Karen J. Halverson, M.D., presented "Evaluation of Treatment Variation Observed in Head and Neck Irradiation Utilizing On-Line Portal Imaging Verification."

Jeffrey J. Kovalic, M.D., presented "Immunohistochemical Staining as a Prognostic Variable for Patients with Pituitary Adnomas Treated with Surgery and Radiation Therapy."

Robert R. Kuske, M.D., presented "Breast Reconstruction and Irradiation."

Peter P. Lai, M.D., presented "The Effect of Overall Treatment Time on the Outcome of Definitive Radiotherapy for Localized Prostate Carcinoma: The Radiation Therapy Oncology Group 75-06 and 77-06 Experience."

Carlos A. Perez, M.D., presented "Optimization of Dose Irradiation Alone in Carcinoma of the Uterine Cervix."

SYMPOSIA

AMERICAN ASSOCIATION OF PHYSICISTS IN MEDICINE

The following members of the Division of Radiation Oncology participated in the 32nd Annual Meeting of the American Association of Physicists in Medicine, St. Louis, July 22-26.

Robert E. Drzymala, Ph.D.; **John W. Matthews, D.Sc.**; **Michael D. Holman, B.S.**; **William B. Harms, B.S.**; and **James A. Purdy, Ph.D.**, "Computerized Three Dimensional Treatment Planning for Stereotactic External Beam Irradiation."

FYI

APPOINTMENTS/ ELECTIONS

Patrick R. Thomas, M.D., chaired the panel on Pediatric Brain Tumors.

Mary Vogelsang Graham, M.D., presented "Locally-Advanced (noninflammatory) Carcinoma of the Breast: Results and Comparison of Various Treatment Modalities."

Martin S. Weinhaus, Ph.D., presented "The Selection of Beam Orientation at Portal Aperture Using Interactively Displayed Arbitrary-Plane Sections Calculated From 3-D CT Data."

POSTER PRESENTATIONS

Venkata R. Devineni, M.D., "Impact of Radiation Therapy in Positive Margins After Surgery in Supraglottic Carcinoma" and "Tolerance of Gastric Mucosal Flap to Radiation Therapy."

Avraham Eisbruch, M.D., "Adjuvant Irradiation After Prostatectomy for Carcinoma of the Prostate with Positive Surgical Margins, or Treatment for Clinical Recurrence."

Perry W. Grigsby, M.D., "Relative Source Distributions from Fletcher Applicators."

Robert J. Myerson, M.D., "Pre-operative Radiotherapy for Rectal Carcinoma."

REFRESHER COURSES

Bahman N. Emami, M.D., "Applied Techniques and Clinical Practice of Local External and Interstitial Hyperthermia."

Perry W. Grigsby, M.D., "Carcinoma of the Endometrium—Diagnosis and Management."

Jeffrey F. Williamson, Ph.D., "Basic Brachytherapy Physics."

Jeffrey F. Williamson, Ph.D., associate professor of radiation physics in radiology, was appointed associate editor of *Medical Physics*.

William A. Murphy, Jr., M.D., professor of radiology, was appointed general chairman of the Program Committee for 1991 by the Radiological Society of North America. As general chairman, he will serve as a member of the Educational Council for 1991.

Michael W. Vannier, M.D., professor of radiology, director of the Division of

Clinical Research and head of the image processing lab, was appointed to the International Scientific Advisory Committee of the 1st International Conference on Computers in Biomedicine to be held September 24-27, 1991, in Southampton, United Kingdom. The conference, organized by the Wessex Institute of Technology, Computational Mechanics Institute in Southampton, will promote the exchange of information among scientists who work on the applications of computers in biomedical systems and engineering.

TECHNOLOGIST NEWS

Michael A. Kleinhoffer, R.T., interventional radiology research technologist, was elected vice president, fourth district, and was appointed state chairman of the Legislative Activities Committee for the Missouri Society of Radiologic Technologists (MSRT). Kleinhoffer was appointed to the Program Advisory Committee of the Washington University School of Radiologic Technology, Mallinckrodt Institute of Radiology.

Robert Knapp, B.M., R.T., supervisor of the 3-D imaging lab, presented "3-Dimensional Cardiac MRI" and "3-Dimensional Surface

Imaging" at the American Society of Radiological Technologists Educational Foundation Specialty Seminar, Chicago, August 25.

Michael D. Ward, R.T., M.Ed., FASRT, chief technologist and director of technical education, has been appointed to the Washington University School of Medicine Centennial Celebration Committee, which will plan events for employee participation in the Centennial.

HONORS/ AWARDS

G. Leland Melson, M.D., professor of radiology and chief of Diagnostic Ultrasound, was appointed to the consensus panel for the NIH Consensus Development Conference on the Diagnosis and Management of Asymptomatic Primary Hyperparathyroidism, Bethesda, Maryland, October 29-31.

Michael W. Vannier, M.D., professor of radiology, director of the Division of Clinical Research, and head of the image processing lab, was awarded the first Phillip V. Tobias International Essay Prize from the Institute for the Study of Man in Africa. The honor was based on Vannier's studies, in collaboration with **Glenn Conroy, Ph.D.**, professor of anatomy, Washington University, of the Taung skull, the Makapansgat cranium MLD 37/38 and other South African australopithecines, using high resolution computed tomography. Vannier and Conroy's essay "The Taung Skull Re-Visited: New Evidence from High Resolution Computed Tomography" was subsequently published in *Science*.

FYI

ALUMNI NEWS

William Moss, M.D., has recently been honored with the gold medal award from the American College of Radiology for his outstanding leadership in the discipline of radiation oncology. This award is reserved for individuals whose contributions have significantly advanced radiological science and practice.

Moss received his medical degree from Washington University in 1944 and completed an internship at Barnes Hospital, St. Louis. He completed his residency training at Ellis Fischel State Cancer Center and graduate studies in Manchester, England, and at the Curie Foundation in Paris. Receiving certification in therapeutic radiology by the American Board of Radiology in 1950, Moss was among the first native-born Americans trained exclusively in therapeutic radiology to hold such recognition. He was a staff member in the Radiation Oncology Division of Mallinckrodt Institute of Radiology prior to accepting the position of chief of radiation therapy at Chicago Veterans' Administration Research Hospital in 1953. In 1974 Moss joined the staff of the School of Medicine of the Oregon Health Sciences University as professor and chairman of radiation oncology, where he retired in mid-1989 but as, professor emeritus, continues to contribute regularly to the teaching of medical students, residents and others.

CIC NEWS

The Cancer Information Center (CIC) is cosponsored by the Mallinckrodt Institute of Radiology, the Barnard Free Skin and Cancer Hospital, and Barnes Hospital at the Washington University Medical Center.

CONTRIBUTIONS

Mr. and Mrs. Paul Ross in memory of Loraine Davis
Sylvia Schachter in memory of Frank Kopitsky
Mr. and Mrs. Warren Stout in memory of Agnes Hamill
Gayle Schollmeyer, Carol Kohl, and Marianne Short in memory of Marie Beckman
Mr. and Mrs. Arnold Weintrub in memory of Mae Belle Schneider
Homer H. Rustebert
Sylvia Schachter in honor of the Reverend and Mrs. William North
Helen F. Trojahn in memory of Minnie Wagener
Buffalo Tool Corporation in memory of Helen Eichstadt
Mr. and Mrs. Gustave Hoelscher in memory of Joseph Schnurbush
Mr. and Mrs. Bill Boyce in memory of Gale Stamm
Jennifer Manlet in memory of Irene Ann Hrenak
Adele Beins in memory of Wilhelm Heinz
Mildred Wulfers in memory of Wilhelm Heinz
Harriet Kusselman in memory of Wilhelm Heinz
Mr. and Mrs. Paul Ross in memory of David Crossen
Mr. and Mrs. Paul Ross in memory of Jerry R. McAllister

Mr. and Mrs. Richard S. Hawes in memory of Dr. E. Lawrence Keyes
Terri Burton in memory of George Simmons
Catherine Porter in memory of Don Smith
Alice A. Smith in memory of Roy M. Lake
Isabel Godair in memory of Roy M. Lake
Charles R. Triplett in memory of Morris Borcharding
Jean Tiefenauer in memory of George Mersinger
Mr. and Mrs. Marvin L. Meyers in memory of Leona Hoffman
Employees of CSC Credit Services in memory of Helen Warneke
Mr. and Mrs. Herbert Leisler and Mimi in memory of William H. Woods, Jr.
Mr. and Mrs. Robert Painter in memory of Barbara Givens
Gay Hagan
Mr. and Mrs. John Koch in memory of Harold P. McCoz
Mr. and Mrs. Donald Dunn in memory of Colette Theismann
Mr. and Mrs. James A. Layton in memory of William Richard
Leona Kilian
Elizabeth (Beau) Vallance

Mr. and Mrs. Sidney Bronfin in memory of Ely Fortus
Sylvia Schachter in memory of Mollie Kootman
Janice Thomas in memory of Mary Ann Brunt
Jeanette Wilson in memory of Harry H. Craig
Mrs. Mildred Brandy in memory of Rita Thenhaus Wilfert
Miss Dorothy Koetting in memory of Rita Thenhaus Wilfert
Missouri Eastern Correctional Center Personnel Club in memory of James Rickard Volmer
Friends from Storz Instrument Company in honor of Lou Franca
The Salerno Sisters in memory of Victor Mangullo
Dr. and Mrs. C. E. Anagnostopoulos in memory of Mildred Leucking
Mrs. and Mrs. Mike Bartoni and family in memory of Jeanne Brown

FYI

CALENDAR

The Mallinckrodt Mammography Mobile brings the latest technology in breast cancer screening plus low-dose, state-of-the-art equipment to women at the St. Louis-area Schnucks stores for a cost of \$50. Call 362-7111 to schedule an appointment for the following dates:

- **December 3**—Creve Coeur Store, 10650 Olive Street Road 63141
- **December 4**—Kirkwood Store, 10233 Manchester Road 63122
- **December 10**—Lindbergh Store, 10275 Clayton Road 63124
- **December 11**—Belleville Store, 5720 North Belt West 62220
- **December 17**—Fairview Heights Store, 625 Lincoln Highway 62208
- **December 18**—Swansea Store, 2665 North Illinois Street 62221


December 2-5, 1990
American Medical Association/Interim Meeting
Orlando

December 10, 1990
City-Wide Radiology Conference "Color Flow Doppler—Update 1990"
Christopher R. B. Merritt, M.D.
Scarpellino Auditorium
St. Louis

January 14, 1991
City-Wide Radiology Conference
St. Louis University
To Be Announced


January 19-26, 1991
Seminars in MRI
Vail

January 21-24, 1991
International Symposium on Peripheral Vascular Intervention
Miami Beach



Left: In 1963, the first cyclotron to be installed in a medical facility was brought to MIR. The 20-ton, Allis Chalmers steel unit produced short-lived radionuclides that were key to the development of positron emission tomography (PET) in the early 1970s. After 27 years, the cyclotron was retired in July. Michel M. Ter-Pogossian, Ph.D., who led the original team of PET researchers, directed the dismantling of the historic machine.


Below right: Lennis Lich, technical supervisor in the Division of Radiation Sciences, was part of the team that dismantled the cyclotron prior to its removal from the shielded vault in the basement of Barnard Hospital.



The new cyclotron, a smaller, more streamlined version of its predecessor, was manufactured by Japan Steel Works. Here, one of the major components of the cyclotron arrives at the loading dock.

February 3-8, 1991
The 9th Annual Practical Radiology 1991
Whistler, British Columbia

February 7-10, 1991
Computed Body Tomography 1991 The Cutting Edge
Orlando



February 11, 1991
City-Wide Radiology Conference
5th Annual Daniel R. Biello Memorial Lecture
"Ionizing Radiation and Health: What Do BEIR V, UNSCEAR 1988, and ICRP 1986 Mean To The Practicing Radiologist?"
S. James Adelstein, M.D., Ph.D.
Scarpellino Auditorium
St. Louis


February 17-21, 1991
The Society of Gastrointestinal Radiologists
The 20th Annual Meeting and Postgraduate Course
Carlsbad

February 18-21, 1991
Society of Cardiovascular and Interventional Radiology
San Francisco

March 11, 1991
City-Wide Radiology Conference "Some Fundamental Observations in Chest Radiology"
Anthony V. Proto, M.D.
Scarpellino Auditorium
St. Louis

SPOTLIGHT

PROFILES OF THE CHIEFS



Norman Hentze

CURTIS HAMMERMAN

Perhaps growing up in St. Louis, a city known for excellence in health care, influenced Curtis Hammerman, M.D., chief resident in Nuclear Medicine, in choosing a career in medicine. Whatever the influencing factor, Hammerman began his preparation back in high school by taking "a lot of science classes."

He received his undergraduate degree in biology from Washington University and his medical degree from Saint Louis University. Unlike the typical resident, Hammerman comes to the Institute out of a

(left to right) Doctors Curtis Hammerman, Douglas Smith, Mark Perry, and Jeffrey Kovalic

four-year private practice in Florida. Hammerman, his wife, and two-year-old son made the move back to St. Louis when he decided to sub-specialize in nuclear medicine.

"Nuclear Medicine is an efficient division at the Institute, devoted to the excellent care of our patients," says Hammerman. "Being at the Institute is worth coming out of private practice."

At the completion of his residency, Hammerman says he will go back into private practice. Back to Florida? "No, I'll stay here," he says. "I missed my family and the city of St. Louis when I was in Florida."

MARTIN KEISCH

Martin Keisch, M.D., assistant chief resident in Radiation Oncology, is a transplanted easterner who came to the Institute because "it's one of the top programs in the United States."

Keisch was born in Idaho but spent most of his early years in Pittsburgh, Pennsylvania. He earned a degree in biology from the State University of New York at Stony Brook and his medical degree from Tufts University. The foundation for becoming a radiation oncologist was laid while he was a student at Tufts.

"I liked radiology but didn't want to give up patient care," he says. "I took an elective in radiation oncology and knew this was the field for me."

What do busy residents do for relaxation? Keisch has become an avid scuba diver since coming to St. Louis, passing his certification requirements at the Bonne Terre Mines. He looks forward to diving in the Bahamas in February.

Keisch will remain at the Institute next year as chief resident and instructor in the Radiation Oncology fellowship program.

JEFFREY KOVALIC

As a native midwesterner, it seemed logical to Jeffrey Kovalic, M.D., who hails from Chicago, to remain in the area for his medical training. Kovalic, chief resident in Radiation Oncology, received his undergraduate degrees in mathematics and in computer science from Loyola University in Chicago. He received his medical degree from the Medical College of Wisconsin in Milwaukee.

When asked if he always wanted to be a physician, Kovalic said, "No, only since organogenesis." He decided to specialize in radiation oncology because he "likes working with cancer patients and was drawn to the new developments in the treatment of cancer."

And why Mallinckrodt Institute? "MIR is a leading center in the country. The Radiation Oncology Center is recognized worldwide for the advanced treatment techniques offered here," says Kovalic. "And, besides, it was the tallest radiology building I interviewed in."

MARK PERRY

Mark Perry, M.D., cochief resident in Diagnostic Radiology, remembers that as a child he enjoyed going to the doctor's office. No, he was not a glutton for punishment—his father was a doctor in Perry's hometown of Kansas City, Missouri.

He received his undergraduate degree in biology from the University of Missouri at Columbia and his medical degree from Washington University. Perry chose to specialize in radiology

because he "likes the problem solving, the diagnostic end of radiology, and the investigations involved in coming up with an answer."

After his residency is completed, Perry plans to go into private practice in either Kansas City or St. Louis. Does he have plans for his one-year-old son to enter the medical profession? "I want my son to do whatever he wants," says Perry. "But, of course, it would be a nice tradition."

DOUGLAS SMITH

Douglas Smith, M.D., chief resident in Diagnostic Radiology, went through some rigorous training on his way to becoming a physician—and not all of it was in medical school.

Smith, a graduate of Hendrix College in Conway, Arkansas, and of Bowman Gray Medical College in Winston-Salem, North Carolina, was an instructor for two years for Outward Bound, an organization that uses out-of-doors skills and the environment as a vehicle for group counseling and establishing self-confidence. He also worked as a helicopter firefighter in the Sierra Mountains in California.

Smith comes to the Institute after three years in orthopedic surgery at the Mayo Clinic. He decided to make the switch to radiology because he "likes the diagnostic end of medicine rather than the therapeutic end." He intends to stay in academic radiology.


REFLECTIONS

I N M E M O R I A M

Dr. Hyman R. Senturia received his A.B. and M.D. degrees from Washington University. He was a gifted student and was elected to Phi Beta Kappa and Alpha Omega Alpha. After graduation from medical school, he served an internship, a year of medical residency, and a two-year residency in radiology at the University of Cincinnati. Here, as the senior resident, he was a mentor of the late Dr. Benjamin Felson, a dear friend who became a giant in the world of academic radiology. Having been awarded a National Cancer Institute Fellowship as a trainee in cancer, Dr. Senturia spent the next two years on rotations at several cancer centers and a final year at the Chicago Tumor Institute under the direction of the renowned radiotherapists Drs. Henri Coutard and Max Cutler.

Starting in 1942, Dr. Senturia served a four-year stint during World War II as a major in the Army Air Force. After discharge, he came back to St. Louis and became a radiologist at The Jewish Hospital where he practiced radiology almost without missing a day, except for short vacations, until two weeks before his death. He was appointed director of radiology in 1953.

Dr. Senturia was a very disciplined radiologist, blessed with a keen intellect and a very discerning eye. His diagnostic talents were immediately recognized by his medical colleagues. His reading cubicle was one of the major diagnostic centers of the hospital—he was consulted on almost every puzzling diagnostic case. A significant portion of Dr. Senturia's training and career was spent in radiotherapy. His skill and compassion in treating malignant diseases were appreciated by his medical colleagues and his patients.



Dr. Senturia authored several scientific papers, yet his greatest fulfillment and contribution was in teaching house staff and medical students. Soon after his arrival at The Jewish Hospital, he began a residency program in radiology, which has since trained more than 50 radiologists.

When Washington University Medical students began rotating through The Jewish Hospital, Dr. Senturia organized a teaching elective in radiology for fourth-year students. Almost immediately, it became one of the most over-subscribed electives offered. He organized his entire weekly work schedule to optimize it as a teaching experience for the students who rarely left his side. The medical students elected him Teacher of the Year on at least four different occasions; Washington University named him professor of clinical radiol-

ogy; and, in 1988, he received the Washington University Medical School Alumni/Faculty Award in recognition of his teaching contributions.

He continued to practice radiology full-time and, to the best of his ability, almost until his death from cancer. Such controlled commitment brings majesty to mortal man. Having witnessed this *imitatio dei*, we are thankful that when it was time for him to be taken, it was without compromise of dignity and pride.

Noah Susman, M.D.
Ronald G. Evens, M.D.



In preparation for MIR's 60th anniversary celebration in September, 1991, Focal Spot will feature selected photographs of former residents, trainees, and fellows. The 1974-1975 staff shown here are (seated, left to right) Doctors James P. Blakely; David E. Bookin; John V. Forrest; R. Gilbert Jost, chief, Division of Diagnostic Radiology; Ronald G. Evens, director of the Institute; Robert F. Scheible; Edda Q. de Sevilla; Daniel R. Biello; Anthony L. Merlis. Middle row, left to right, are Doctors M. Reed Knight; Richard E. Chepey; J. Bruce Hauser; John L. Cieply; William A. Murphy, Jr; Robert G. Levitt; Kil Soo Lee; Thomas F. Craven; and Naris Rujanavech. Back row, left to right, are Doctors Willie Bob Davis, Michael A. Mikhael, Gene L. Davis, Christopher J. Moran, Dennis M. Welch, Lance J. Lembeck, Bharath Kumar, Matthew G. Powers, Stephen D. Burrows, and Isidro L. Heute.

FOCAL SPOT

MALLINCKRODT INSTITUTE OF RADIOLOGY

MIR
MALLINCKRODT
INSTITUTE OF RADIOLOGY DO
WASHINGTON UNIVERSITY
MEDICAL CENTER

Director, Public Relations
Executive Editor
Micheale Gold

Managing Editor
Vicki Kunkler

Administrative Assistant
Laura Waugh

Design
Purviance & Company
Marketing Communications

Contributing Writers
Bridget McDonald
Laura Waugh

Photographers
T. Mike Fletcher
Norman Hente
Thomas Murry
Michelle Wynn

Focal Spot magazine is published three times a year by the Mallinckrodt Institute of Radiology at the Washington University Medical Center at 510 South Kingshighway, St. Louis, MO 63110.

Permission is granted to reproduce articles contained herein, provided **Focal Spot** magazine of the Mallinckrodt Institute of Radiology at the Washington University Medical Center is credited.

Public Relations Department
Mallinckrodt Institute of Radiology
510 South Kingshighway
St. Louis, MO 63110
(314) 362-2866.

© Mallinckrodt Institute of Radiology, 1990

Address Correction Requested

ARCHIVES
SERIALS DEPT., MEDICAL LIBRARY
WASH. U. SCHOOL OF MEDICINE
CAMPUS BOX 8132
ST. LOUIS, MO 63130

Non-Profit Organization 13
U.S. Postage
PAID
St. Louis, Missouri
Permit No. 1032



After the completion of more than 60 radiotherapy treatments for spinal cancer, Christina Dunn was "in the clouds" in a hot-air balloon during her trip to Disney World, sponsored by Dream Factory. Christina's story begins on page 6.