

Unexpected Metastasis of High Grade Serous Ovarian Cancer to Breast: Case Report and Literature Review

Lavinia Domenici*, Marco Monti, Federica Tomao, Margherita Giorgini, Ilaria Sabatucci, Vanessa Colagiovanni, Agnese Maria Lourdes Gambaro, Ludovico Muzii and Pierluigi Benedetti Panici

Department of Gynecologic, Obstetrics and Urologic Sciences - "Sapienza" University of Rome, Italy

Abstract

Introduction: Metastasis of ovarian serous carcinoma to breast and/or axillary lymph nodes represents an unusual event. Nevertheless, their detection and distinction from mammary carcinoma are of huge clinical importance because the treatment and prognosis diverge significantly.

Case presentation: We report a case of a 47 year-old Caucasian female patient with unforeseen metastasis to the breast and to axillary lymph nodes due to ovarian serous carcinoma.

Conclusion: In patients with history of OSC who present with axillary or breast mass, an accurate histological diagnosis should be obtained since this has a great impact on treatment outcomes.

Keywords: Metastasis to breast; Ovarian cancer

Introduction

Ovarian serous carcinoma (OSC) usually compares at an advanced stage, but with disease limited to the peritoneal cavity in the majority of patients (roughly 85%) [1]. However, metastasis of ovarian cancer to retroperitoneal organs such as kidney or distant organ metastases involving brain have also been previously stated but very few reports describe extra-abdominal lymph node involvement in this kind of tumour. In particular, metastases to breast from OSC are almost exceptional. Clinical studies have revealed that the incidence of metastases to breast arrays from 0.5-1.2% [2,3]. We present a case of metastatic carcinoma to breast in a patient with a known history of OSC and a new breast lump. Importantly, this case had histopathologic features that can be confused with ductal carcinoma *in situ*.

Case Report

A 47-year-old Caucasian female patient with past medical history of stage IIA high grade serous OC 9 months after cytoreductive surgery and three lines of adjuvant chemotherapy (carboplatin AUC6 plus taxol 175 mg/mq every three weeks for 6 cycles) referred to the clinic for regular follow-up visit. CA-125 levels were normal and she had no evidence of disease. She had a very good primary response to OSC standard treatment. Her medical history was negative excluding OSC. On physical examination, a 2 cm diameter, non-tender, round, firm, and fixed breast mass was discovered in superior inner quadrant of the left breast of the patient. Patient was unaware of this mass. Left axilla examination was positive for two solid, fixed and nodes.

On mammography, a mass of 18 mm was detected (Figure 1a). Sonogram of bilateral breasts was performed which showed a 29 × 21 × 18 mm vascularized left breast mass (Figure 1b) and two suspicious left axillary lymph nodes of 12 and 15 mm respectively (Figure 1c). Whole body CT scan executed two months before was negative for other possible metastatic sites. A surgical excision of the mass and an elective axillary clearance were made after accurate counselling and discussion of the treatment possibilities with the patient. No minor or major complications were collected. To a first microscopical examination, the breast mass was identified as a ductal carcinoma *in situ*. Thirteen lymph-nodes were gained from the axillary fat. Of the 13 axillary lymph nodes got, five showed metastatic deposits that were identical to the ovarian primary. Immunohistochemical studies revealed that the tumour cells expressed estrogen receptor (80%) and progesterone receptor (20%). There was no expression of HER-2/neu

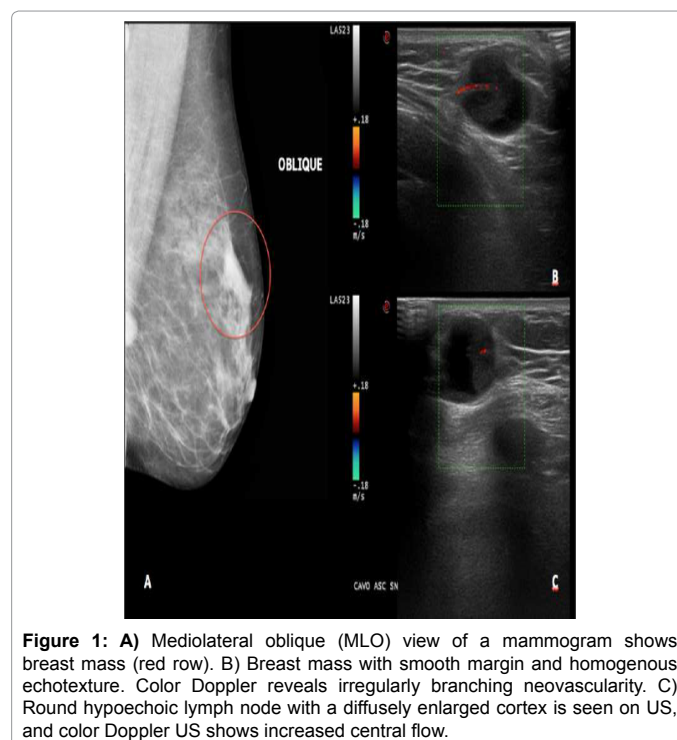


Figure 1: A) Mediolateral oblique (MLO) view of a mammogram shows breast mass (red row). B) Breast mass with smooth margin and homogenous echotexture. Color Doppler reveals irregularly branching neovascularity. C) Round hypoechoic lymph node with a diffusely enlarged cortex is seen on US, and color Doppler US shows increased central flow.

oncprotein. Immunohistochemical staining performed on the nodes was positive for WT-1, p16, and CA-125 while cytokeratin 20 (CK20) and gross cystic disease fluid protein-15 (GCDFP-15) were negative. According to microscopic and immunocytochemical findings, the

*Corresponding author: Lavinia Domenici, Department of Gynecologic, Obstetrics and Urologic Sciences-"Sapienza" University of Rome, Italy, Tel: +39-06-4940550; Fax: +39-06-49970355; E-mail: lavinia.domenici@uniroma1.it

Received february 11, 2016; Accepted April 13, 2016; Published April 18, 2016

Citation: Domenici L, Monti M, Tomao F, Giorgini M, Sabatucci I, et al. (2016) Unexpected Metastasis of High Grade Serous Ovarian Cancer to Breast: Case Report and Literature Review. J Clin Case Rep 6: 764. doi:10.4172/2165-7920.1000764

Copyright: © 2016 Domenici L, et al. This is an open-access article distributed under the terms of the Creative Commons Attribution License, which permits unrestricted use, distribution, and reproduction in any medium, provided the original author and source are credited.

The breast and/or ipsilateral lymph node metastases were discovered at an average of 30 months after presentation as in our case (36 months).

When tumours in the breast or axillary lymph nodes are discovered before or simultaneously with an OSC, diagnostic difficulties may arise. The use of immunohistochemical markers such as WT-1 and GCDFP-15 may aid in defining the origin of the tumour if an ovarian primary should be contemplated carefully, because the treatments of these two entities are completely different.

Furthermore, metastatic cancer to the breast from an OSC is associated with a poor prognosis, infact the majority of patients dying in one year [6,7]. Kayikcioglu et al. [8] described the case of a patient that was initially stage IIC epithelial ovarian cancer. After two years, she presented with bilateral metastatic breast disease originated from the primary ovarian cancer. Although she was heavily treated, she died 18 months after diagnosis. Breast metastases from ovarian cancer were found an average of 2 years after initial diagnosis [9] and were usually a clue of advanced disease. It is interesting that in our patients there was no evidence of disseminated disease at the beginning.

Immunohistochemical markers may benefit in determining the origin of breast or axillary lymph node metastases. Yamamoto et al. [10] analysed WT-1 immunoreactivity in 119 patients with OSC and disclosed that WT-1 positivity is positively linked with high grade, advanced stage and higher Ki-67 index, higher bcl-2 expression and poorer outcome in a study. Although WT-1 positivity can be seen in many solid tumours, it has been recognized as a possible marker mostly for ovarian cancer.

Conclusion

We suggest that, in patients with history of OSC who present

with axillary or breast mass, every effort should be made to obtain an accurate histological diagnosis since this has a great impact on treatment outcomes. It is critical to distinguish histologic pattern and recognize it from de novo ductal carcinoma *in situ*. Immunohistochemistry is crucial to confirm the diagnosis

References

1. Cormio G, Rossi C, Cazzolla A, Resta L, Loverro G, et al. (2003) Distant metastases in ovarian carcinoma. *Int J Gynecol Cancer* 13: 125-129.
2. Sandison AT (1959) Metastatic tumours in the breast. *Br J Surg* 47: 54-58.
3. Brown JB, O'Keefe CD (1928) Sarcoma of the ovary with unusual oral metastases. *Ann Surg* 87: 467-471.
4. Ben-Baruch G, Sivan E, Moran O, Rizel S, Menczer J, et al. (1996) Primary peritoneal serous papillary carcinoma: a study of 25 cases and comparison with stage III-IV ovarian papillary serous carcinoma. *Gynecol Oncol* 60: 393-396.
5. Recine MA, Deavers MT, Middleton LP, Silva EG, Malpica A (2004) Serous carcinoma of the ovary and peritoneum with metastases to the breast and axillary lymph nodes: a potential pitfall. *Am J Surg Pathol* 28: 1646-1651.
6. Moore DH, Wilson DK, Hurteau JA, Look KY, Stehman FB, et al. (1998) Gynecologic cancers metastatic to the breast. *J Am Coll Surg* 187: 178-181.
7. Martel J, Roux JJ, Treilleux I, Bouchet P, Froger X, et al. (2003) Breast metastases of an ovarian adenocarcinoma. *Ann Dermatol Venereol* 130: 623-625.
8. Kayikcioglu F, Boran N, Ayhan A, Güler N (2001) Inflammatory breast metastases of ovarian cancer: a case report. *Gynecol Oncol* 83: 613-616.
9. Laifer S, Buscema J, Parmley TH, Rosenshein NB (1986) Ovarian cancer metastatic to the breast. *Gynecol Oncol* 24: 97-102.
10. Yamamoto S, Tsuda H, Kita T, Maekawa K, Fujii K, et al. (2007) Clinicopathological significance of WT1 expression in ovarian cancer: a possible accelerator of tumor progression in serous adenocarcinoma. *Virchows Arch* 451: 27-35.

Citation: Domenici L, Monti M, Tomao F, Giorgini M, Sabatucci I, et al. (2016) Unexpected Metastasis of High Grade Serous Ovarian Cancer to Breast: Case Report and Literature Review. J Clin Case Rep 6: 764. doi:10.4172/2165-7920.1000764

OMICS International: Publication Benefits & Features

Unique features:

- Increased global visibility of articles through worldwide distribution and indexing
- Showcasing recent research output in a timely and updated manner
- Special issues on the current trends of scientific research

Special features:

- 700+ Open Access Journals
- 50,000+ editorial team
- Indexing at major indexing services
- Rapid review process
- Quality and quick editorial, review and publication processing
- Indexing at major indexing services
- Sharing Option: Social Networking Enabled
- Authors, Reviewers and Editors rewarded with online Scientific Credits
- Better discount for your subsequent articles

Submit your manuscript at: <http://www.omicsonline.org/submission/>