

## PUBLISHED VERSION

Christo, Jonathan Elias; Bennett, Sam; Wilkinson, Thomas Maynard; Townsend, Grant  
Clement

[Discal attachments of the human temporomandibular joint](#) Australian Dental Journal, 2005;  
50(3):152-160

### PERMISSIONS

This document has been archived with permission from the Australian Dental Association, received 18th January, 2007.

Australian Dental Association: <http://www.ada.org.au/>

<http://hdl.handle.net/2440/16785>

# Discal attachments of the human temporomandibular joint

JE Christo,\* S Bennett,\* TM Wilkinson,\* GC Townsend\*

## Abstract

**Background:** Despite its clinical significance, the anatomy of the human temporomandibular joint (TMJ) and its relationship to the lateral pterygoid muscle remains poorly described and often misrepresented in standard texts. The aim of this study was to describe how the anterior and posterior attachments of the TMJ disc vary between lateral, central and medial regions of the joint.

**Methods:** Ten left TMJs were removed *en bloc* from cadavers and serial sections were made at 3-4mm intervals. Observations were made to ascertain the anterior and posterior attachments of the disc and the joint structures were traced from standardized photographs.

**Results:** Laterally, the capsule and lateral discal ligament merged prior to their attachment at the condylar pole. Medially, muscle fibres, capsule and the disc converged on the medial pole of the condyle. There was no evidence that fibres of the upper head of the lateral pterygoid muscle inserted directly into the disc. The upper head inserted into the condyle either directly at the pterygoid fovea or via a central tendon or indirectly via the capsule. Posteriorly, the superior part of the posterior attachment of the disc attached to the cartilaginous meatus and tympanic part of the temporal bone. The inferior part of the posterior attachment of the disc attached to the posterior surface of the condyle. In four joints, this attachment was folded beneath the posterior band of the disc, creating a wedge-shaped flap that ran medio-laterally.

**Conclusion:** This study is in broad agreement with other anatomical TMJ studies but there are two main points of difference. Firstly, a true muscle insertion of the superior head of the lateral pterygoid muscle to the disc was not observed. Secondly, a wedge-shaped flap of retrodiscal tissue was identified between the condyle and the disc.

**Key words:** Temporomandibular joint, discal attachments, lateral pterygoid muscle.

**Abbreviations and acronyms:** ADD = anteriorly displaced disc; CPA = condylar part of the posterior attachment; IPA = intermediate part of the posterior attachment; MRI = magnetic resonance imaging; PA = posterior attachment; TMJ = temporomandibular joint; TPA = temporal part of the posterior attachment.

(Accepted for publication 1 November 2004.)

## INTRODUCTION

The human temporomandibular joint (TMJ) is a synovial joint that has several unique features.<sup>1</sup> It performs both gliding (arthrodial) and hinge (ginglymal) movements, there is bilateral articulation, the articular surfaces are covered by fibrous tissue not hyaline cartilage, and the teeth limit as well as guide certain movements.

The TMJ provides articulation between the mandible via the condyle and the cranium via the temporal bone, in particular, the mandibular fossa and the articular eminence. The TMJ disc is interposed between the condyle and the fossa, separating them from direct articulation. The articular disc is composed mainly of dense fibrous connective tissue and it divides the joint into an upper and lower compartment. The disc can be divided into three regions based on thickness when viewed from the lateral perspective; an anterior thick zone, an intermediate thin zone and a posterior thick zone.

The disc attaches to the medial and lateral poles of the condyle via discal ligaments. In centric occlusion the articular surface of the condyle faces the posterior slope of the articular eminence with pressure exerted through the intermediate thin zone of the disc. The posterior band typically envelops the most superior portion of the condyle.

As in any synovial joint, the capsule defines the anatomical and functional boundaries of the TMJ. Rees<sup>1</sup> described a posterior wall of the capsule connecting the temporal bone with the mandibular condyle and he considered the tissue posterior to the articular disc, the so-called bilaminar zone, to be the fourth component of the disc. It was described as being separated into upper and lower laminae consisting of dense collagen fibres. The upper lamina attached to the posterior wall of the glenoid fossa and the squamo-tympanic suture, whilst the lower lamina attached to the posterior aspect of the condyle. The space between the two laminae and the posterior wall was described as being filled with loose connective tissue. Zenker<sup>2</sup> described the retrodiscal tissues as a 'retroarticular plastic pad' and did not describe a posterior wall as mentioned by Rees.<sup>1</sup> Zenker<sup>2</sup> indicated that collagen fibres in the upper and lower stratum inserted into the

\*Dental School, The University of Adelaide.

temporal bone or condyle independently. Scapino<sup>3</sup> described the retrodiscal tissues as the posterior attachment, the upper laminae as the temporal part of the posterior attachment (TPA) and the lower laminae as the condylar part of the posterior attachment (CPA). A posterior joint capsule was not described, however it was demonstrated that collagen fibres, termed fibres of the intermediate part of the posterior attachment (IPA), arose from the postglenoid process, tympanic bone, and cartilaginous meatus and descended to become continuous with the CPA. It was suggested that most of the expansion of the posterior attachment (PA) that occurred during condylar movements took place within the IPA.

Rees<sup>1</sup> claimed that the capsule was absent anteriorly but mentioned an independent temporal and mandibular attachment for the articular disc. He also described tendinous fibres of the lateral pterygoid muscle that merged with the disc forming a true insertion. Schmolke<sup>4</sup> made similar findings concluding that a small number of muscle fibres attached into the 'anteromedial dip' of the articular disc. However, other researchers have described a different relationship between the disc and the lateral pterygoid muscle. Wilkinson and Chan<sup>5</sup> reported that the superior head of the lateral pterygoid muscle was attached to the medial half of the condyle at the pterygoid fovea via a central tendon or directly to the fovea, or indirectly by blending with fibres of the capsule below the attachment of the disc to the capsule. They did not observe a direct insertion of the superior head of the lateral pterygoid muscle to the disc.

The anatomy and function of the TMJ is complex, and our knowledge of the joint is incomplete. Except for the structure of the lateral wall of the joint capsule, connective tissue arrangements are by no means clear. The anterior and posterior attachments of the disc have been studied extensively but there has been relatively little research on how the attachments vary between lateral, central and medial regions of the joint. Therefore, the aim of this study was to describe the nature of the anatomical relationships of the anterior and posterior attachments of the TMJ disc at a macroscopic level by comparing parasagittal sections across the human TMJ.

## MATERIALS AND METHODS

Left TMJs were dissected from 10 cadavers used for teaching in the BDS course of the Adelaide Dental School. The cadavers' ages ranged from 60-90 years with an average of 79.3 years. Cadavers were partially dentate or edentulous. There were three females and six males, and the identity of one cadaver head was unknown.

Five of the joints (specimens 1-5) were utilized from a previous preliminary study. For these five cadavers, a block of tissue including the left TMJ was removed. This block was bounded anteriorly by the posterior wall of the maxilla, posteriorly by the external acoustic

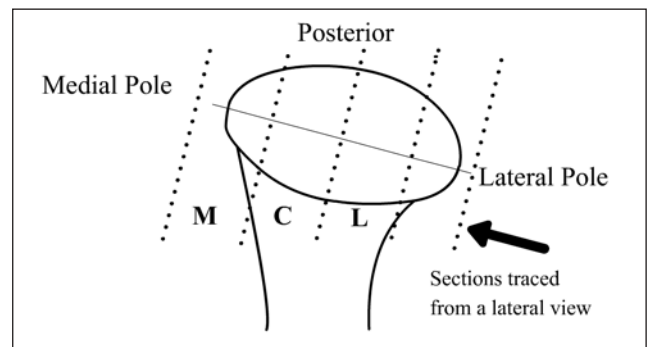


Fig 1. Superior view of the condylar head. The intercondylar axis is indicated by the solid line through the medial and lateral poles. Sectional cuts, shown by the dotted lines, were made 3-4mm apart, perpendicular to the intercondylar axis. L, C, M – represent the lateral, central and medial sections. All sections were traced from a lateral view.

meatus, superiorly by the floor of the middle cranial fossa, medially by the lateral pterygoid plate and inferiorly to include the angle of the mandible. The blocks were washed in running water for 48 hours to flush the preserving solution from the tissues and then frozen to  $-80^{\circ}\text{C}$  before sectioning.

A precision band saw with a new fine-toothed metal cutting blade was used to make serial sections of the deep frozen blocks. Cuts were made at 3-4mm intervals in a direction perpendicular to the intracondylar axis, the axis between the lateral and medial poles of the condyle, and parallel to the lateral pterygoid muscle. This produced five sections – three through the condyle, with one cut being medial and one cut lateral to the condyle as shown in Fig 1.

The remaining five left cadaver TMJs (specimens 6-10) were prepared using the method described above. However, an additional radiographic technique was utilized and the TMJ block was sectioned with the superior and inferior surfaces parallel to the Frankfort horizontal and the anterior and posterior cuts

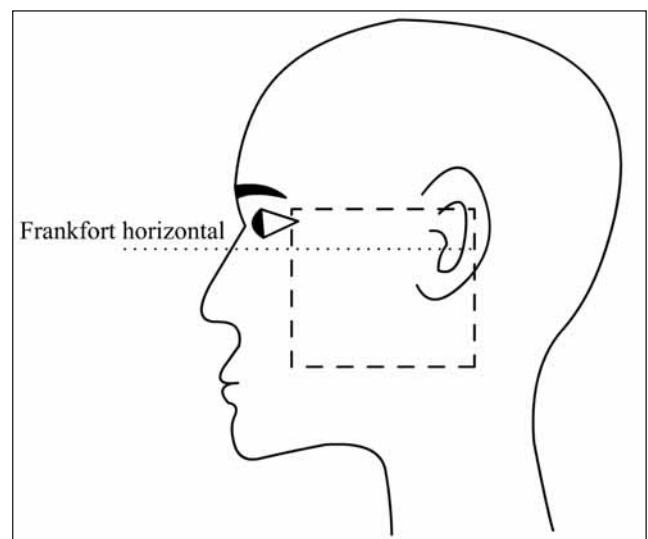


Fig 2. A block of tissue including the left TMJ, indicated by the dashed box, was sectioned from cadaver heads. The sectioned block was aligned to the Frankfort horizontal, represented by the dotted line.

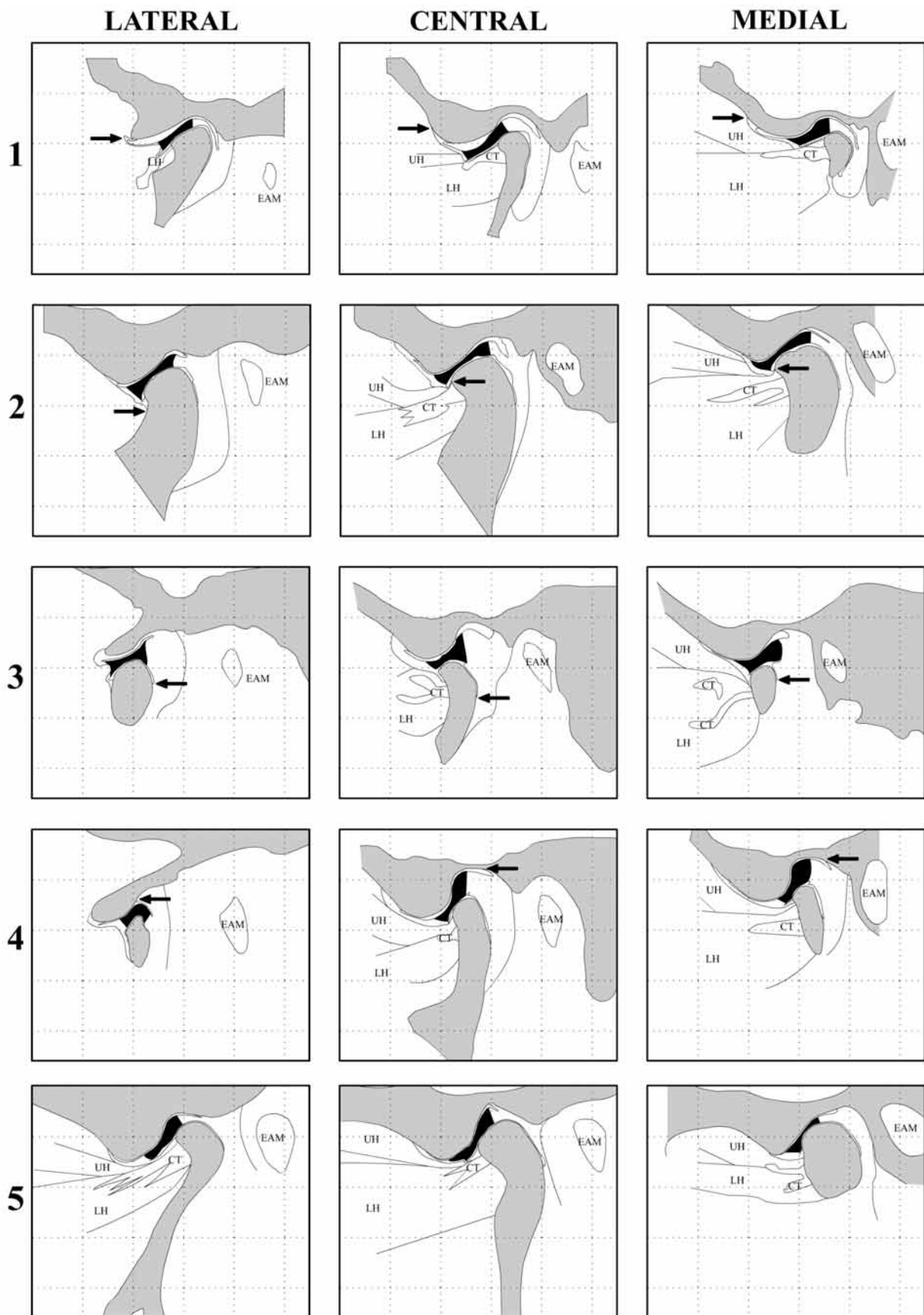


Fig 3. TMJ tracings of sections through the lateral, central and medial thirds of the condyle in specimens 1-5. Sections are viewed from the lateral aspect and are orientated so that comparisons can be made between the lateral, central and medial tracings within the same specimen. Arrows on specimen 1 indicate the capsules anterior and superior attachment to the articular eminence. Arrows on specimen 2 indicate the capsules anterior and inferior attachment to the condyle. Arrows on specimen 3 indicate the attachment of the condylar part of the posterior attachment. Arrows on specimen 4 indicate the attachment of the temporal part of the posterior attachment.

■ Bone UH – upper head of lateral pterygoid; LH – lower head of lateral pterygoid; CT – central tendon; EAM – external acoustic meatus;  
 ■ Disc Grid – 10mmx10mm; Scale – 1:1.

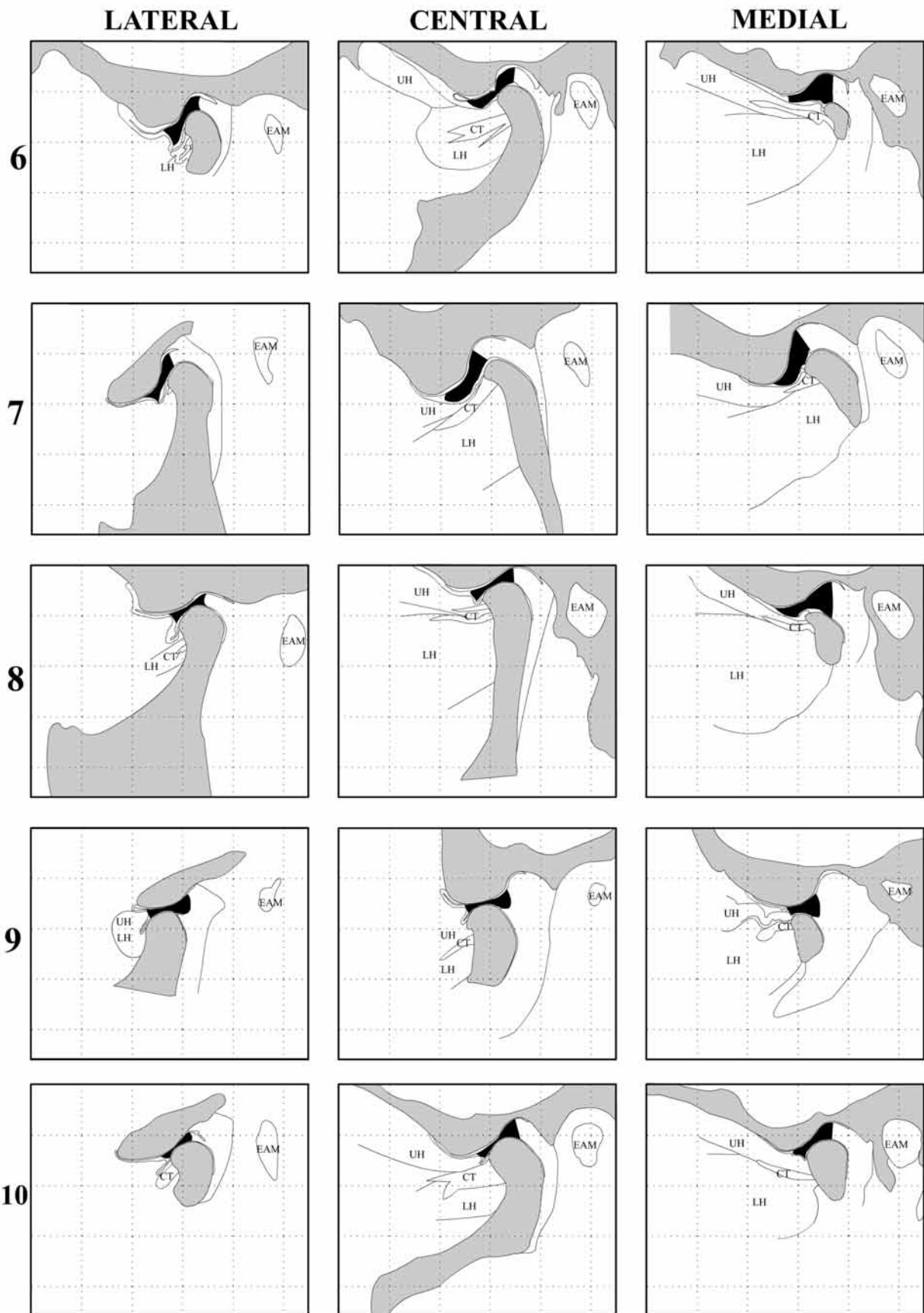


Fig 4. TMJ tracings of sections through the lateral, central and medial thirds of the condyle in specimens 6-10. Tracings are viewed from the lateral aspect. Sections are orientated to the Frankfort horizontal and have been aligned to allow comparison between lateral, central and medial sections within the same joint as well as between specimens.

■ Bone UH – upper head of lateral pterygoid; LH – lower head of lateral pterygoid; CT – central tendon; EAM – external acoustic meatus;  
 ■ Disc Grid – 10mmx10mm; Scale – 1:1.

perpendicular to this line as shown in Fig 2. The radiographic technique ensured that the sectional cuts were made perpendicular to the intracondylar axis. This involved placing a 1mm diameter wire across the superior surface of the block, estimating the intracondylar axis. The block was radiographed from a superior direction and the radiograph was assessed to determine whether the wire and intracondylar axis were parallel. If the wire was not parallel to the intracondylar axis, the wire was repositioned and another radiograph was taken. The blocks were frozen to -80°C with the wire in position and later sectioned perpendicular to this wire.

The newly-cut surfaces of the lateral, central and medial sections of all specimens were scanned at 400dpi using an Epson Perfection 2400 flatbed scanner and Photoshop 7 software. Contrast and brightness levels were adjusted to best display the images. Macromedia Flash MX was used to trace the joints utilizing 20 times magnification. Tracings of the joints were made and displayed in a standardized process to allow comparisons between a joint's lateral, central and medial sections.

All joints were sectioned in their post-mortem relationship. Eight of the 10 joints were sectioned with the condyle seated in the fossa and two joints with the condyle translated down the posterior slope of the eminence.

Observations were made to ascertain the anterior and posterior attachments of the disc and to clarify the association between the disc anteriorly and the superior head of the lateral pterygoid muscle. This involved application of tension to the uppermost fibres of the muscle and translation of the condyle forward on the articular eminence which also enabled observation of the extension of the retrodiscal tissue.

The position of the posterior band of the disc in relation to the condyle was noted. The presence of remodelling of the mandibular fossa and the condyle, and any associated alterations in the disc and the level of attachment and the degree of folding of the retrodiscal tissues, were also observed.

## RESULTS

The series of joint tracings for specimens one through five are shown in Fig 3. Specimens six through 10 were sectioned with the Frankfort horizontal as a reference plane and these tracings are displayed in Fig 4.

Laterally, the capsule arose from the outer rim of the mandibular fossa, in all specimens, and descended to a level directly inferior to the lateral condylar pole. The disc followed the contour of the condyle and merged with the capsule just prior to its insertion into the lateral pole.

The attachment of the anterior portion of the disc was observed to be, superiorly, via the capsule to the anterior slope of the articular eminence and, inferiorly, to the anterior rim of the condyle. In the central third,

the superior attachment via the capsule was positioned further anteriorly and superiorly along the anterior slope of the articular eminence compared with the lateral and medial thirds. The inferior attachment to the anterior rim of the condyle was located more superiorly in the central section compared with the lateral and medial thirds, although the levels of attachment for the central and medial sections were similar.

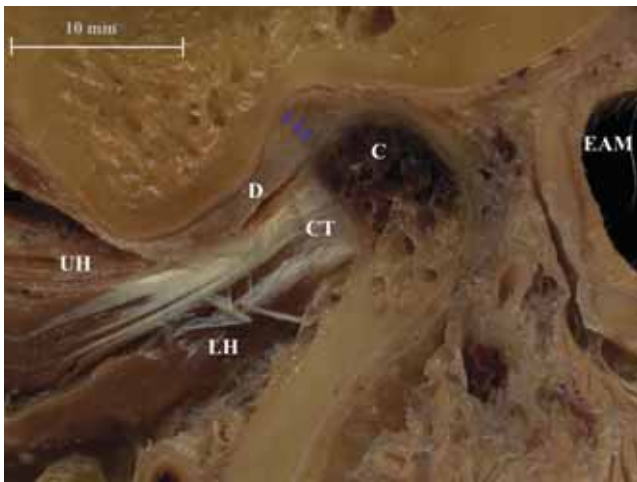
Medially, the capsule was more vascular, arising from the squamotympanic suture and descending toward the medial pole of the condyle. The disc merged with the capsule prior to its insertion into the medial pole of the condyle.

Generally fibres of both the upper and lower heads of the lateral pterygoid muscle were not found in the lateral third of the TMJ but all central and medial sections contained the muscle. The lower head appeared further laterally compared with the upper head but the majority of muscle fibres from both heads were found medially. In one specimen (specimen 9) muscle fibres were present in lateral and central sections but upper and lower heads could not be distinguished. At a point underneath the crest of the articular eminence in all joints, the two heads blended together around a central tendon and could not be separated.

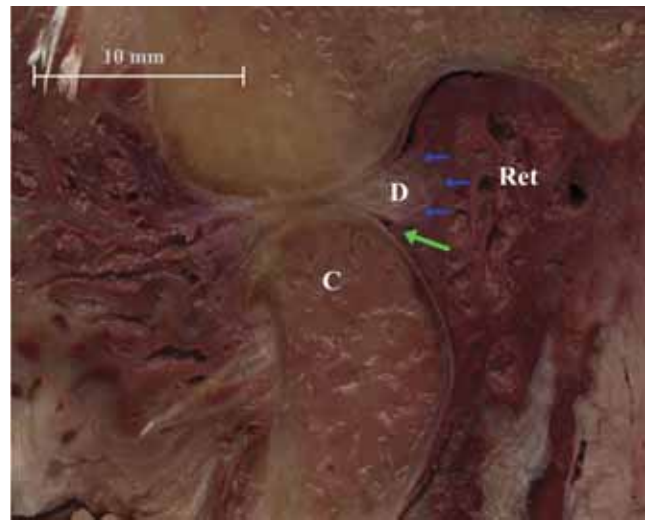
All of the TMJs studied showed that the superior head of the lateral pterygoid muscle was attached to the condyle, either directly at the pterygoid fovea or by a central tendon or indirectly via the capsule. When forward tension was applied to the superior lateral pterygoid muscle, the condyle was pulled forward and little or no movement of the disc was produced. Any movement of the disc was produced by either the muscle acting on the condyle or capsule, thus indirectly affecting the disc due to its attachment to both the capsule and condyle. It was not possible to produce movement of the disc independent of the condyle. Medially, muscle fibres, capsule and the disc converged on the medial pole. In several joints it appeared that muscle fibres inserted into the medial aspect of the disc. However, no muscle fibres were observed passing through the capsule and when tension was applied to these fibres movement of the condyle and not the disc occurred. It was deemed that these muscle fibres terminated within the capsule and beneath the disc.

No disc perforations were found but the disc was observed to be significantly thinner laterally in specimens 8 and 10. Specimen 6 contained two irregularities within the superior joint space. Immediately anterior to the crest of the articular eminence and on the posterior slope of the eminence there were two fibrous tissue extensions that had the appearance of adhesions.

In intercuspal position, the posterior band of the disc was typically located in the 12 o'clock position or over the condylar crest. Three joints (4, 5 and 7) were observed to have a steep articular eminence. In two of



**Fig 5.** A lateral view of the lateral section of specimen 5. The posterior band of the disc (arrowed) is positioned downward and forward of the anterior articular rim of the condyle (C) indicating an anteriorly displaced disc (D). UH, upper head of the lateral pterygoid muscle; LH, lower head of the lateral pterygoid muscle; CT, central tendon; EAM, external acoustic meatus.



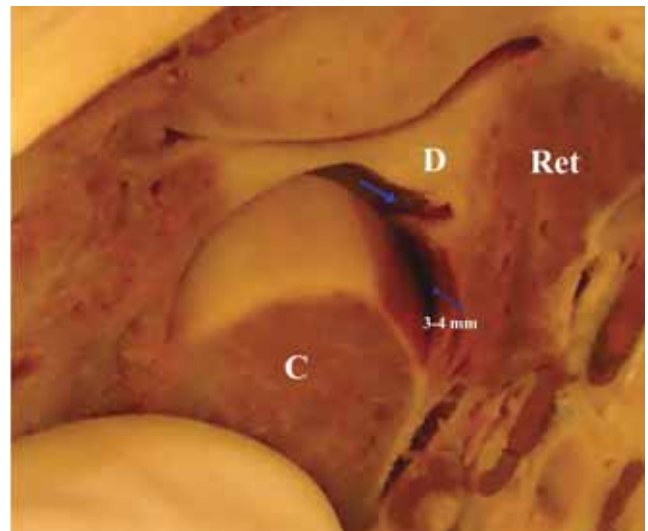
**Fig 6.** A lateral view of the central section of specimen 9 which was dissected with the condyle translated. Note the expansion of the retrodiscal tissues (Ret) to fill the space vacated by the translated condyle (C). A wedge-shaped flap of retrodiscal tissue (green arrow) filled the space between the posterior thick part of the disc (blue arrows) and the condyle.

these three joints, specimens 5 and 7, the posterior band was located anterior to the condylar crest. The most lateral section of specimen 5, viewed from the medial aspect, showed that the posterior band was positioned downward and forward of the anterior articular rim indicating an anteriorly displaced disc (Fig 5). In the central and medial thirds of specimen 7, the disc was thickened and did not display an intermediate thin zone.

Posteriorly, fibres of the posterior band of the disc were continuous with those of the retrodiscal tissues in all parasagittal sections. The venous plexus of the retrodiscal tissues formed a wedge shape, increasing in size medially.

Laterally, the temporal or superior retrodiscal attachment (TPA) attached to the cartilaginous meatus and tympanic part of the temporal bone. Medially, the TPA blended with the capsule, and both could be seen to originate from the squamotympanic fissure. Folding of the posterior part of the TPA was observed in all specimens where the condyles were seated in the fossae. The fold occurred in lateral, central and medial sections. Condylar translation, to the crest of the eminence, was required before this recess began to unfold. In the two sections where the condyle was translated, the fold either appeared to be unfolding (specimen 3) or was not observed (specimen 9).

The condylar or inferior retrodiscal attachment (CPA) was to the posterior aspect of the condyle. In the majority of joints (specimens 1-5, 7 and 9) the attachment of the CPA was most inferior in the central third. In the lateral and medial thirds, the level of attachment was elevated and at approximately the same height, as the retrodiscal tissues converged on the lateral and medial poles. The temporal attachment of the TPA was positioned most anteriorly and inferiorly in the lateral third and most posteriorly in the medial third (specimens 1, 2, 4, 6, 7, 9 and 10).



**Fig 7.** An antero-supero-lateral view of the lateral section of specimen 9. The condylar head (C) has been tilted laterally and distracted from the fossa to show the groove (arrowed) between the disc (D) and the retrodiscal tissues (Ret), running in a mediolateral direction. The 3-4mm marking displays the thickness of the section.

In specimen 9, sections were obtained with the condyle translated forward and the increase in size of the retrodiscal tissues to fill the vacated space was clearly evident (Fig 6). In this open position, the condyle was positioned further anteriorly and aligned with the thin intermediate part of the disc. A wedge-shaped flap of retrodiscal tissue filled the space between the posterior thick part of the disc and the condyle (Fig 6). This wedge-shaped flap contained parts of the CPA and IPA and was seen through all sections of this joint creating a groove between the disc and the CPA that ran in a mediolateral direction (Fig 7). This wedge-shaped flap was also observed in specimen 3 in which the condyle was translated onto the articular eminence

and in specimens 4 and 7 where the condyles were seated in their fossae. However, in specimens 4 and 7 where the condyles were seated in their fossae, the flap was only seen in central and medial sections and only involved a folding of CPA without inclusion of the IPA. The medial section of specimen 7 also displayed elongation of the anterior capsule which was folded between the inferior surface of the disc and the condyle.

The posterior capsule was not clearly identifiable. A visual boundary that represented the posterior extension of the retrodiscal tissues was observed and drawn on the joint tracings. This boundary arose from the post-glenoid process, tympanic bone and cartilaginous meatus and terminated at the posterior surface of the condyle or at the parotid gland tissue.

## DISCUSSION

Some authors view the anterior capsule conceptually as a peripheral fibrous and synovial extension of the disc.<sup>6</sup> Schmolke<sup>4</sup> and Rees<sup>1</sup> did not mention an anterior capsule but rather a temporal and mandibular attachment of the articular disc. Histological studies have shown a band of fibrous tissue is present from the condyle to the roof of the infratemporal fossa and that the foot of the anterior part of the disc sits on and blends with the superior surface of the capsule.<sup>7</sup> In this study, anteriorly, the capsule was mechanically distinguishable from the disc when probed with a blunt instrument. The anterior capsule attached superiorly to the anterior slope of the articular eminence and inferiorly to the anterior articular rim of the condyle. Laterally, the lateral discal ligament and capsule are not separate entities, but rather they both attach at the condylar pole level. Marguelles-Bonnet *et al.*<sup>6</sup> reported a similar finding.

Clinical opinion that a disturbance in the activity of the lateral pterygoid muscle plays an important role in the aetiology of TMD is still widely accepted.<sup>8</sup> The view that the upper head of the lateral pterygoid can cause an anteriorly displaced disc (ADD) is very simplistic. Some parts of the upper head do appear to be active during intercuspal clenching,<sup>9</sup> but the joint must be unloaded for this to have an affect on the disc. Nitzan<sup>10</sup> believes that changes in joint lubrication resulting from altered synovial fluid can generate high friction while the disc is translating against the fossa. Such friction is probably the prime mover in elongation of discal attachments to the condyle and subsequent disc displacement.

Recent work by Murray *et al.*<sup>11</sup> has proposed that any upper head fibres inserting into the disc could be activated independently of other upper head fibres and thus forces may be exerted on the disc that are not directed simultaneously to the condyle. The site of insertion of the upper head of the lateral pterygoid is important because it determines where the force of the muscle contraction will be applied. Early anatomical studies reported a direct insertion of the upper head of the lateral pterygoid muscle into the articular disc.<sup>1</sup>

More recent studies have found that a small number of muscle fibres may insert into the anteromedial aspect of the articular disc, with the majority of fibres attached to the condyle.<sup>4,6</sup> However, other studies have not observed a direct muscle insertion into the disc.<sup>5,7</sup> In this present study no muscle fibres were found to insert directly into the disc.

Schmolke<sup>4</sup> stated that if sections were made obliquely, the insertion of the muscle into the disc may not be seen. Our method ensured that sections were made perpendicular to the intercondylar axis which produced similar sections to those obtained by Schmolke, but we still found no muscle fibres inserting into the disc. It did seem that the muscle inserted into the disc in several joints but when tension was applied to these fibres, condylar movement was produced. It is our belief that fibres do not directly insert into the disc but some fibres terminate within the capsule under the disc.

Despite our finding that fibres did not insert into the disc, the theory described by Murray *et al.*<sup>11</sup> may still play a role in disc position. Activation of upper head muscle fibres inserting into the capsule under the foot of the disc may apply tension to the disc and not to the condyle. The effect of these muscle fibres would be greatly increased if the joint was unloaded.

For an anterior-medial disc displacement there must be a greater elongation of the lateral discal ligament compared with the medial discal ligament. Tanaka<sup>12</sup> reported that the retrodiscal tissues were tightly attached to the medial aspect of the posterior fossa but noted that this was not the case in the lateral aspect. He proposed that the lateral aspect of the disc may be more easily displaced, allowing the displacement to occur in a more anterior-medial direction. The present study did not support this theory as no difference was found between the lateral and medial retrodiscal attachments. Folding of the posterior part of the TPA was observed in lateral, central and medial sections in all specimens where the condyles were seated in the fossae. Condylar translation, to the crest of the eminence, was required before the TPA recess began to unfold. Therefore, the concept of an elastic upper stratum that has a recoil mechanism to control disc movement was also not supported by this study or others.<sup>13</sup>

Our observation of an association between a steep articular eminence and an anterior positioning of the posterior band of the disc has been reported previously.<sup>6</sup> This may be the normal development of the disc position in response to a steep eminence and does not indicate a displacement. This has clinical implications in the interpretation of normal versus pathological disc position from magnetic resonance imaging (MRI) images. In other cadaver studies, estimates of the frequency of anterior positioning of the posterior band of the disc have varied from 28<sup>14</sup> to 56 per cent.<sup>15</sup> In this current study three of the 10 specimens were found to have an anterior positioning of the disc which falls within the lower range of what has been reported previously.



It is possible that a steep eminence could predispose to an ADD. Okeson<sup>16</sup> proposed that as the slope of the eminence increases, more rotational movement is required between the disc and the condyle during translation of the condyle. Therefore, a steep eminence is more likely to demonstrate greater condylar-disc movement during function which increases the risk of ligament elongation leading to disc derangement disorders. Kerstens *et al.*<sup>17</sup> supports this view. Hall *et al.*<sup>18</sup> went further, proposing that the difference in slope of the eminence in the medial and lateral part of the fossa, makes an ADD at the lateral (steep) side more likely than on the medial side. Alsawaf *et al.*<sup>19</sup> did not find an association between the slope of the eminence and TMJ clicking. In the present study, the specimen that displayed an ADD had a steep articular eminence but, as this was only observed in one specimen, no conclusions can be drawn.

Muscle fibres of the upper head of the lateral pterygoid were generally only found in central and medial joint thirds. It is interesting that in this study the only joint with muscle fibres of the superior head of lateral pterygoid found in the lateral third of a joint was also the joint with an ADD. As this only occurred in one joint, again no firm conclusions can be drawn but this does warrant further investigation.

Scapino<sup>3</sup> observed that when the condyle translated forward, the CPA folded beneath the posterior band of the disc. We observed similar findings in joints where the condyle was translated forward but folding of the CPA was also noted in sections with the condyle seated in the fossa. Posterior rotation of the disc on the condyle during opening shortens the distance between the posterior band and the attachment of the CPA. This, combined with a vascular perfusion of the IPA accompanying condylar translation, leads to an increase in size of the wedge-shaped flap that fills the space created between the posterior aspect of the disc and the translated condyle.

We propose four possibilities for the folding of the CPA observed in sections with the condyle seated in the fossa. Firstly, it may have been a post mortem artefact. Secondly, the wedge-shaped flap may be a sign of an elongated CPA that then folds under the disc due to its excessive length. However, it is difficult to imagine what would cause an elongated CPA. One possibility is a decrease in occlusal vertical dimension. An example of this would be an edentulous person removing their dentures, resulting in an over rotation of the condyle and a stretching of the CPA which then folds when the person returns to using their dentures. Alternatively, it may appear as if the CPA is excessive in length but in effect the distance between the posterior band of the disc and the CPA's attachment could have shortened. As the condyle rotates under the disc on hinge opening, the distance between the posterior band and CPA's attachment at the posterior aspect of the condyle shortens, possibly creating a fold in the CPA. This would occur if joints were sectioned with the mouth

partly opened and the rotated condyle was still seated in the fossae. Thirdly, the wedge-shaped flap that fills the space between the translated condyle and the disc may become repeatedly pinched during closing or parafunction leading to fibrosis of the tissue. Given the average age of the cadavers' was 79.3 years, it is possible that both the second and third hypotheses are associated with age changes. Finally, the fold may be a synovial extension but it was not possible in this macro-anatomic study to carry out tissue differentiation.

## CONCLUSION

The anterior and posterior attachments of the TMJ disc and variability between these attachments in lateral, central and medial thirds of the condyle, has been described. Our results are in broad agreement with other anatomical TMJ studies. However, this study has two main points of difference. Firstly, a true muscle insertion of the superior head of the lateral pterygoid muscle to the disc was not observed. Secondly, a wedge-shaped flap of retrodiscal tissue was identified between the condyle and the disc.

## ACKNOWLEDGEMENTS

We wish to thank the Australian Dental Research Foundation for their financial support and Wesley Fisk and Stelios Michas from the Department of Anatomical Sciences at Adelaide University for their expertise and assistance.

## REFERENCES

1. Rees LA. The structure and function of the mandibular joint. *Br Dent J* 1954;96:125-133.
2. Zenker W. Das retroarticulare plastische Polster des Kiefergelenks und seine mechanische Bedeutung. *Z Ant Entwickl Gesch* 1956;119:375-388.
3. Scapino RP. The posterior attachment: its structure, function, and appearance in TM imaging studies. Part 1. *J Craniomandib Disord* 1991;5:83-95.
4. Schmolke C. The relationship between the temporomandibular joint capsule, articular disc and jaw muscles. *J Anat* 1994;184(Pt 2):335-345.
5. Wilkinson T, Chan EK. The anatomic relationship of the insertion of the superior lateral pterygoid muscle to the articular disc in the temporomandibular joint of human cadavers. *Aust Dent J* 1989;34:315-322.
6. Marguelles-Bonnet R, Yung JP, Carpentier P, Meunissier M. Temporomandibular joint serial sections made with mandible in intercuspul position. *Cranio* 1989;7:97-106.
7. Wilkinson TM. The relationship between the disk and the lateral pterygoid muscle in the human temporomandibular joint. *J Prosthet Dent* 1988;60:715-724.
8. Lund JP. Pain and movement. In: Lund JP, Lavigne G, Dubner R, Sessle BJ, eds. *Orofacial Pain: From Basic Science to Clinical Management*. Chicago: Quintessence, 2000:151-163.
9. Phanachet I, Whittle T, Wanigaratne K, Klineberg IJ, Sessle BJ, Murray GM. Functional heterogeneity in the superior head of the human lateral pterygoid. *J Dent Res* 2003;82:106-111.
10. Nitzan DW. The process of lubrication impairment and its involvement in temporomandibular joint disc displacement: a theoretical concept. *J Oral Maxillofac Surg* 2001;59:36-45.
11. Murray GM, Phanachet I, Uchida S, Whittle T. The human lateral pterygoid muscle: a review of some experimental aspects and possible clinical relevance. *Aust Dent J* 2004;49:2-8.

12. Tanaka TT. Head, neck and TMD management. In: Okeson JP. Bell's Orofacial Pain. 5<sup>th</sup> edn. Chicago: Quintessence, 1982:306.
13. Wilkinson TM, Crowley CM. A histologic study of retrodiscal tissues of human temporomandibular joint in the open and closed position. J Orofac Pain 1994;8:7-17.
14. Hellsing G, Holmlund A. Development of the anterior disk displacement in the temporomandibular joint: an autopsy study. J Prothet Dent 1985;53:397-401.
15. Westesson PL, Rohlin M. Internal derangement related to osteoarthritis in temporomandibular joint autopsy specimens. Oral Surg Oral Med Oral Pathol 1984;57:17-22.
16. Okeson JP. Management of temporomandibular disorders and occlusion. 5th edn. St Louis: Mosby, 2003.
17. Kerstens HC, Tuinzing DB, van der Kwast WA. Eminectomy and discoplasty for correction of the displaced temporomandibular joint disc. J Oral Maxillofac Surg 1989;47:150-154.
18. Hall MB, Brown RW, Sclar AG. Anatomy of the TMJ articular eminence and changes following surgical reduction in cadavers. J Craniomandib Pract 1984;2:135-140.
19. Alsawaf M, Garlapo DA, Gale EN, Carter MJ. The relationship between condylar guidance and temporomandibular joint clicking. J Prosthet Dent 1989;61:349-354.

*Address for correspondence/reprints:*

Professor Grant C Townsend  
Dental School  
The University of Adelaide  
Adelaide, South Australia 5005  
Email: grant.townsend@adelaide.edu.au