

Case Report

Histological Analysis of Failed Cartilage Repair after Marrow Stimulation for the Treatment of Large Cartilage Defect in Medial Compartmental Osteoarthritis of the Knee

Kenichiro Sakata^a, Takayuki Furumatsu^{a*}, Nobuhiro Abe^b, Shinichi Miyazawa^a,
Yoshimasa Sakoma^a, and Toshifumi Ozaki^a

Departments of ^aOrthopaedic Surgery, and ^bIntelligent Orthopaedic System, Okayama University Graduate School of Medicine, Dentistry and Pharmaceutical Sciences, Okayama 700-8558, Japan

Bone marrow-stimulating techniques such as microfracture and subchondral drilling are valuable treatments for full-thickness cartilage defects. However, marrow stimulation-derived reparative tissues are not histologically well-documented in human osteoarthritis. We retrospectively investigated cartilage repairs after marrow stimulation for the treatment of large cartilage defects in osteoarthritic knees. Tissues were obtained from patients who underwent total knee arthroplasty (TKA) after arthroscopic marrow stimulation in medial compartmental osteoarthritis. Clinical findings and cartilage repair were assessed. Sections of medial femoral condyles were histologically investigated by safranin O staining and anti-type II collagen antibody. Marrow stimulation decreased the knee pain in the short term. However, varus leg alignment gradually progressed, and TKA conversions were required. The grade of cartilage repair was not improved. Marrow stimulations resulted in insufficient cartilage regeneration on medial femoral condyles. Safranin O-stained proteoglycans and type II collagen were observed in the deep zone of marrow-stimulated holes. This study demonstrated that marrow stimulation resulted in failed cartilage repair for the treatment of large cartilage defects in osteoarthritic knees. Our results suggest that arthroscopic marrow stimulation might not improve clinical symptoms for the long term in patients suffering large osteoarthritic cartilage defects.

Key words: bone marrow stimulation, microfracture, subchondral drilling, osteoarthritis of the knee, cartilage repair

Bone marrow-stimulating techniques including microfracture, subchondral drilling, and abrasion arthroplasty are valuable for the treatment of osteoarthritis of the knee in appropriately selected patients who expect immediate pain relief and do not want more extensive surgeries [1]. Marrow stimulation is expected to recruit bone marrow-derived mes-

enchymal stem cells into the full-thickness cartilage defect by penetrating the subchondral bone plate [2]. In arthroscopic management of degenerative osteoarthritic knees, microfracture has been favorably performed. Microfracture can improve knee function at 1 year postoperatively and can increase the knee joint space on standing radiographs [3]. Microfracture for isolated degenerative cartilage defects of the knee was shown to improve knee function and reduce pain associated with walking and activities of daily living at an average 2.6-year follow-up [4]. However, 16% of

such treated patients needed repeat arthroscopy within 5 years after the initial microfracture, and 6% of the patients required repeated microfracture or total knee arthroplasty (TKA) at an average of 23 months postoperatively [4]. Subchondral drilling reduced the knee pain of osteoarthritis at 2 to 7 years postoperatively, and can be used in patients for whom more extensive surgery is not indicated [5]. Abrasion arthroplasty resulted in improvement of knee complaints in 56% of patients suffering medial compartmental osteoarthritis, while the knee was unchanged in 36% and worse in 8% at an average 1-year follow-up period [6]. On the other hand, 50% of patients who had osteoarthritis of the knee subsequently underwent TKA for salvage at a mean of 3 years following abrasion arthroplasty [7]. From these reports, arthroscopic marrow stimulation provides unpredictable results in the treatment of osteoarthritis of the knee, and controversy still exists about its use. Concerns regarding marrow-stimulating techniques for osteoarthritis of the knee include the durability of the repaired fibrocartilaginous tissue. The resurfaced fibrocartilage has diminished resilience, stiffness, and poor wear characteristics when compared with hyaline cartilage, resulting in a predilection for the re-development of osteoarthritis [8, 9]. Isolated fibrocartilage islands and/or newly generated fibrocartilaginous tissue on the femoral condyle were observed at second-look arthroscopy after marrow stimulation of degenerative knees [8, 10–12]. Several histological analyses have demonstrated that marrow stimulation results in failed cartilage repair for the treatment of small cartilage defects of the knee [13, 14]. In a rabbit large-cartilage-defect model, reparative chondral plugs in the drilled holes lost their hyaline appearance at 8 months after subchondral drilling [15]. However, the fibrocartilaginous tissue induced by microfracture and drilling is not histologically well-documented in human degenerative osteoarthritic knees. In this study, we investigated the effect of marrow stimulation in a large cartilage defect of medial compartmental osteoarthritic knee, and histologically analyzed the failed cartilage resurfacing at a mean of 21 months following arthroscopic marrow stimulation.

Patients, Tissues, and Histological Analyses

Degenerated medial femoral condyles were obtained at total knee arthroplasty (TKA) for revision surgery in patients who underwent primary arthroscopic marrow stimulation for the treatment of large cartilage defect in medial compartmental osteoarthritis of the knee ($n = 4$). This retrospective study received the approval of our Institutional Review Board and informed consent was obtained from each patient at TKA salvation. These patients underwent arthroscopic marrow stimulation such as microfracture and subchondral drilling for primary surgical procedures because they wished to avoid more extensive surgeries. Arthroscopic debridement was simultaneously performed at the primary arthroscopic surgery. Two additional patients (a 61-year-old male and a 70-year-old female) received marrow stimulations in the same situation. However, one could not be followed up and the other did not need additional surgery in the 1-year-follow-up period. The radiological stage of osteoarthritis was determined by the Kellgren-Lawrence grading scale [16]. The femorotibial angle (FTA) in the standing position and the body mass index (BMI) were measured at the time of arthroscopy and TKA. Cartilage defect was evaluated by the International Cartilage Repair Society (ICRS) cartilage injury classification (graded from 0 to 4), focusing on the lesion depth as follows: 0, normal; 1, superficial lesions; 2, lesions extending down to < 50% of cartilage depth; 3, cartilage defects extending down to > 50% of cartilage depth but not through the subchondral bone; and 4, cartilage defect extending to the subchondral bone [17]. ICRS cartilage injury classification was assessed by 4 surgeons at operative procedures on a consensus basis. Cartilage repair induced by marrow stimulation techniques was evaluated by the ICRS cartilage repair assessment system (grade I, total score of 12 points; II, 11–8 points; III, 7–4 points; and IV, 3–1 points) based on 3 criteria at TKA as follows: degree of defect repair (0–4 points), integration to border zone (0–4 points), and macroscopic appearance (0–4 points) [17]. ICRS cartilage repair assessment was macroscopically graded by the gross appearance of medial femoral condyles. Mean scores were calculated as points for individual criteria. An ICRS visual histological assessment scale composed of 6 features

(scores ranged from 0 to 18) [18] was used for microscopic evaluation of repaired cartilage after marrow stimulation. Medial femoral condyles were fixed with 4% paraformaldehyde solution. Paraffin-embedded tissue sections were stained with safranin O dye for investigating proteoglycan synthesis of fibrocartilaginous tissue [19, 20]. Type II collagen synthesis was assessed by immunohistological analysis using a mouse anti-human type II collagen antibody (clone II-4CII, 1:100 dilution, MP Biomedicals, Solon, OH, USA) as previously described [21, 22]. Scores on the ICRS visual histological assessment scale were calculated by mean scores derived from 6 sections per sample, taken from areas representing the entire repair tissue. Macroscopic and microscopic assessments of the cartilage repair were performed by 4 observers in a blinded manner.

Case Reports

Case 1. A 52-year-old male had swelling and pain in the left knee for 7 months prior to arthroscopy. He had neither a history of trauma nor clinical disorder in the knee joint. On arthroscopic examination of the medial femoral condyle, a large cartilage defect (approximately 8 cm²) classified as ICRS cartilage injury grade 4 was observed (Fig. 1A). Marrow stimulation was performed using an arthroscopic 40° awl (1.5-mm diameter and 5-mm depth) at distances of 3-4 mm after arthroscopic debridement of the osteoarthritic knee (Fig. 1B). Penetration of the subchondral plate and communication with the marrow were confirmed by the outflow of bone marrow blood (Fig. 1C). After the primary arthroscopic surgery, the knee was immobilized by bracing in extension for 2 weeks. Range of motion exercises were performed beginning

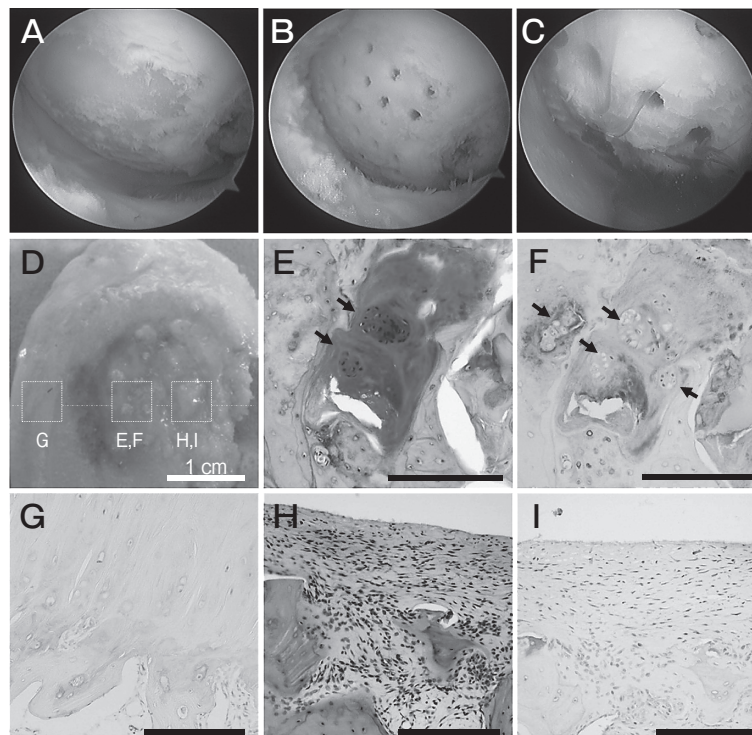


Fig. 1 A 52-year-old male (Case 1). An arthroscopic view of the medial femoral condyle (A). Microfracture was performed using an arthroscopic awl (B). The outflow of bone marrow blood indicated the penetration of the subchondral bone plate (C). Microfracture technique resulted in limited fibrocartilaginous tissue regeneration on the medial femoral condyle (D). Cartilage-like tissues were observed only in the deep zone of marrow-stimulating holes (E and F). A cluster of chondrocyte-like cells (arrows) was packaged in safranin O-stained ECMs (E). Type II collagen deposition was detected (F). Remaining articular cartilage showed no signal in the absence of an anti-type II collagen antibody (G). Subchondral bone was partially covered by fibrous tissues that did not contain safranin O-stained proteoglycans (H) and type II collagen (I). Black bars, 200 μm.

3 weeks postoperatively. Partial weight bearing was allowed to proceed at 4 weeks and full weight bearing was started at 6 weeks. The patient was then allowed to return to activities of daily living. He had no swelling in the left knee until 30 months after the surgery. However, the knee pain and swelling were gradually increased at 31 months postoperatively. The radiological stage was aggravated from grade 2 at arthroscopy to grade 3 at TKA (Table 1). FTA was also increased from 181° to 184° (Table 1). At the time of

TKA (34 months postoperatively), microfracture techniques had induced a limited cartilage-like tissue regeneration (ICRS cartilage repair assessment grade IV, ICRS visual histological assessment scale 5.0) on the medial femoral condyle (Table 1-3; Fig. 1D-F). Cartilage-like tissues were observed only in the deep zone of marrow-stimulating holes (Fig. 1E and F). A cluster of chondrocyte-like cells was packaged in cartilaginous extracellular matrix (ECM) (Fig. 1E and F). Subchondral bone was partially covered by fibrous

Table 1 Demographic data of marrow-stimulated MFC-OA patients underwent TKA salvation

Case	Sex	Side	Age at AS (years)	BMI (kg/m ²)	Defect size (cm ²)	Marrow stimulation	Duration until TKA (months)	Radiological stage ¹⁶ (Grade) (at AS→TKA)	FTA (°) (at AS→TKA)	ICRS cartilage injury classification ¹⁷ (Grade at AS→TKA)	*ICRS cartilage repair assessment ¹⁷ (Grade at TKA)	[†] ICRS visual histological assessment scale ¹⁸ (Score at TKA)
1	M	L	52	25	8	Mfx (1.5mm)	34	2→3	181→184	4→4	IV	5.0±0.8
2	F	R	52	26	8	Drill (1.2mm)	16	3→4	187→191	4→4	IV	6.0±2.3
3	F	R	65	31	6	Mfx (1.5mm)	21	3→3	180→182	3→3	IV	8.8±1.3
4	F	L	73	28	6	Mfx (1.5mm)	11	3→3	180→181	4→4	IV	7.3±1.5
Mean			60.5	27.5	7		20.5		180→181			6.8±2.0

Case 1, 2, 3, and 4 are presented in Fig. 1, 2, 3, and 4, respectively.

[‡]Details are presented in Table 2.

[†]Details are shown in Table 3.

AS, arthroscopy; BMI, body mass index; FTA, femorotibial angle; MFC, medial femoral condyle; Mfx, microfracture; OA, osteoarthritis; TKA, total knee arthroplasty.

Table 2 ICRS cartilage repair assessment¹⁷ (macroscopic) at TKA

Case	Degree of defect repair Protocol A (0-4 points)	Integration to border zone (0-4 points)	Macroscopic appearance (0-4 points)	Total score (0-12 points)	Overall repair assessment* (Grade I-IV)
1	0.8±0.5	0.5±0.6	0	1.3±0.5	IV
2	0.8±0.5	0	0.5±0.6	1.3±0.5	IV
3	0.8±0.5	0.5±0.6	0.5±0.6	1.8±0.5	IV
4	1.0	0.5±0.6	0.5±0.6	2.0±1.2	IV

Scores: means ± SD

*Grade I (12 points), normal; II (11-8 points), nearly normal; III (7-4 points), abnormal; IV (3-1 points), severely abnormal.

Table 3 ICRS visual histological assessment scale¹⁸ (microscopic) at TKA

Case	Surface (0, 3 points)	Matrix (0-3 points)	Cell distribution (0-3 points)	Cell population viability (0, 1, 3 points)	Subchondral bone (0-3 points)	Cartilage mineralization (0, 3 points)	Total score (0-18 points)
1	0.8±1.5	1.0±0.8	0.8±0.5	1.8±1.0	0.8±0.5	0	5.0±0.8
2	0.8±1.5	0.5±0.6	0.3±0.5	3.0	1.5±1.0	0	6.0±2.3
3	0	2.3±0.5	1.5±1.0	3.0	2.0	0	8.8±1.3
4	0.8±1.5	1.0	0.5±1.0	3.0	2.0	0	7.3±1.5

Scores: means ± SD

tissues that did not contain type II collagen or safranin O-stained proteoglycans (Fig. 1H and J).

Case 2. A 52-year-old female complained of right knee pain for 10 years. Conservative treatments did not result in relief of pain and swelling. Arthroscopic findings revealed that a full-thickness cartilage defect (approximately 8 cm²) was classified as ICRS grade 4 (Fig. 2A). Subchondral drilling was performed using a 1.2-mm Kirschner wire (5-mm depth) at distances of 3–4 mm after arthroscopic debridement (Fig. 2B). Postoperative treatment was performed as described above. She had no swelling in the right knee until 13 months after the arthroscopic treatment. However, the knee pain and swelling appeared at 14 months postoperatively. Radiological stage was aggravated from grade 3 to grade 4 at TKA (Table 1). FTA was also increased from 187° to 191°

(Table 1). Fibrocartilaginous tissue formation (ICRS cartilage repair assessment grade IV, ICRS visual histological assessment scale 6.0) was observed in drilled holes and the surface of the medial femoral condyle at 16 months postoperatively (Table 1–3; Fig. 2C–G). Cells packaged in regenerated tissues had round and chondrocytic morphologies (Fig. 2D–G). However, safranin O-stained proteoglycans and type II collagen were partially detected in the deep layer of fibrocartilaginous tissues (Fig. 2D–G).

Case 3. A 65-year-old female had pain and swelling in the right knee for 5 months. Conservative treatments did not result in relief of pain or swelling. A full-thickness cartilage defect (approximately 6 cm²), classified as ICRS grade 3, was observed at arthroscopic debridement (Fig. 3A and B). Microfracture was performed using a 1.5-mm arthroscopic awl (5-mm

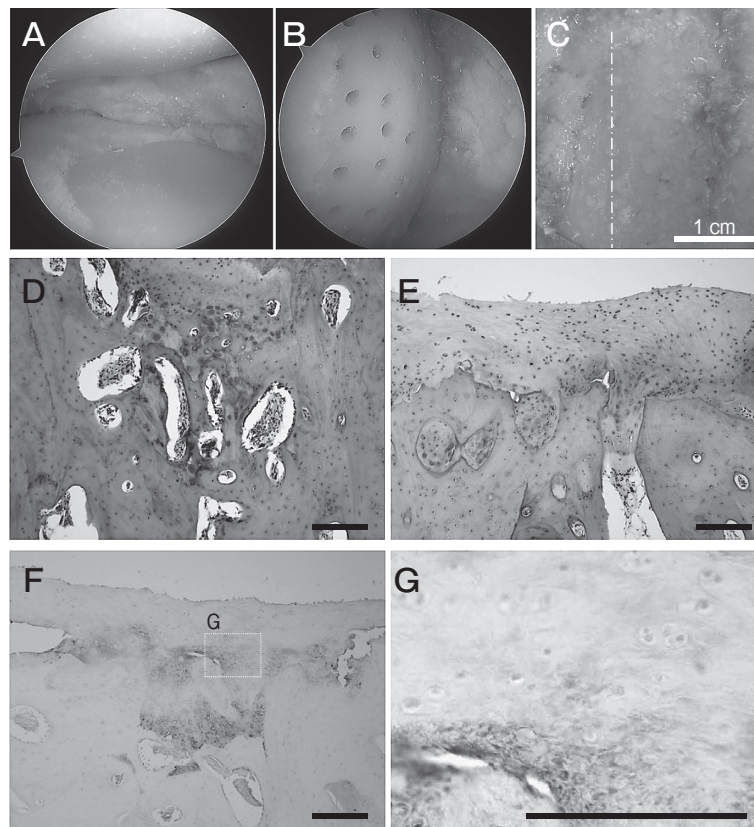


Fig. 2 A 52-year-old female (Case 2). A full-thickness cartilage defect (A). Subchondral drilling was performed using a 1.2-mm Kirschner wire (B). Fibrocartilaginous tissue formation was observed (C) in drilled holes (D) and the surface of the medial femoral condyle (E). Safranin O-stained proteoglycans were partially detected in the deep layer of fibrocartilaginous tissues (D and E). Type II collagen deposition was also observed in the deep zone (F and G). Empty osteocyte lacunae and osteonecrosis were not histologically observed (D–G). Black bars, 200 μm.

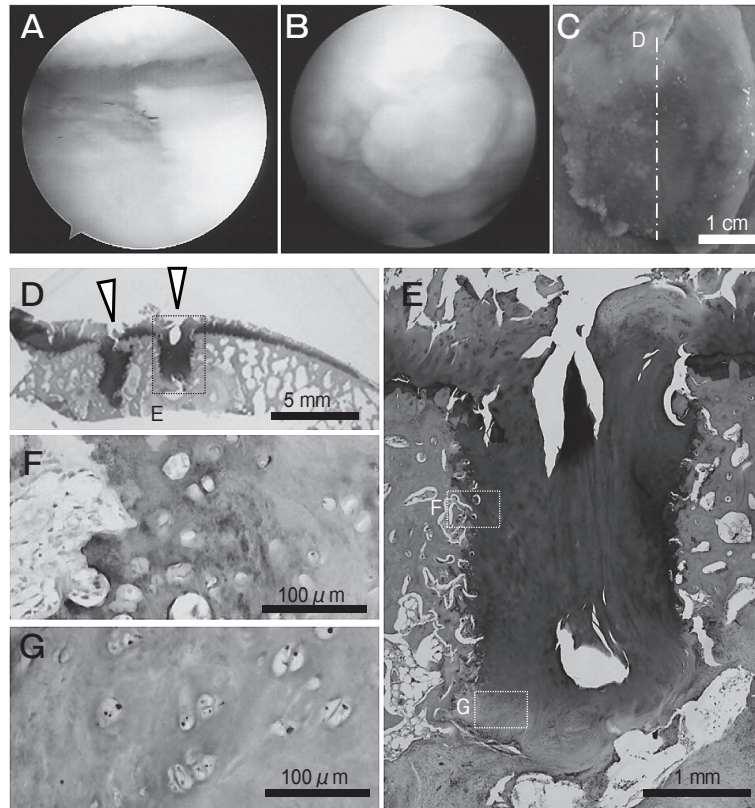


Fig. 3 A 65-year-old female (Case 3). An arthroscopic image of degenerated articular surface (A and B). The medial femoral condyle was obtained at TKA (C). Specimens were prepared along the dashed line (D). Triangles denote the direction of marrow-stimulating holes. Safranin O-stained proteoglycans were generally detected in the regenerated tissues (D and E). Chondrocytic cells were observed in the regenerated ECM that was positively stained by an anti-type II collagen antibody (F and G).

depth) at distances of 3–4mm. Postoperative treatment was performed the same as in case 1. She had no swelling in the right knee after the arthroscopic treatment. However, moderate knee pain appeared at 18 months postoperatively. Although aggravation of the radiological stage was not detected, FTA was increased from 180° to 182° at 21 months postoperatively (Table 1). The articular surface of the medial femoral condyle was degenerated (ICRS cartilage repair assessment grade IV, ICRS visual histological assessment scale 8.8). However, safranin O-stained proteoglycans and type II collagen were sufficiently observed in the penetrated holes (Fig. 3D–G). Cells packaged in regenerated tissues showed chondrocytic morphologies (Fig. 3F and G).

Case 4. A 73-year-old female had pain and swelling in the left knee for 6 months. Conservative treatments did not result in relief of pain and swelling.

A full-thickness cartilage defect (approximately 6cm²), classified as ICRS grade 4, was observed at an arthroscopic debridement (Fig. 4A). Microfracture was performed using a 1.5-mm arthroscopic awl (5-mm depth) at a distance of 3–4mm apart (Fig. 4B). Postoperative treatment was performed the same as in case 1. She had no swelling in the left knee after the arthroscopic treatment. However, moderate knee pain appeared at 7 months postoperatively. Although aggravation of radiological stage was not detected, the FTA was increased from 180° to 181° at 11 months postoperatively (Table 1). Fibrocartilaginous tissues were observed only in penetrated holes at the medial femoral condyle (Fig. 4C and D). A large area of subchondral bone was exposed (ICRS cartilage repair assessment grade IV, ICRS visual histological assessment scale 7.3) except for the penetrated holes (Fig. 4C and D). Cells packaged in regenerated tissues

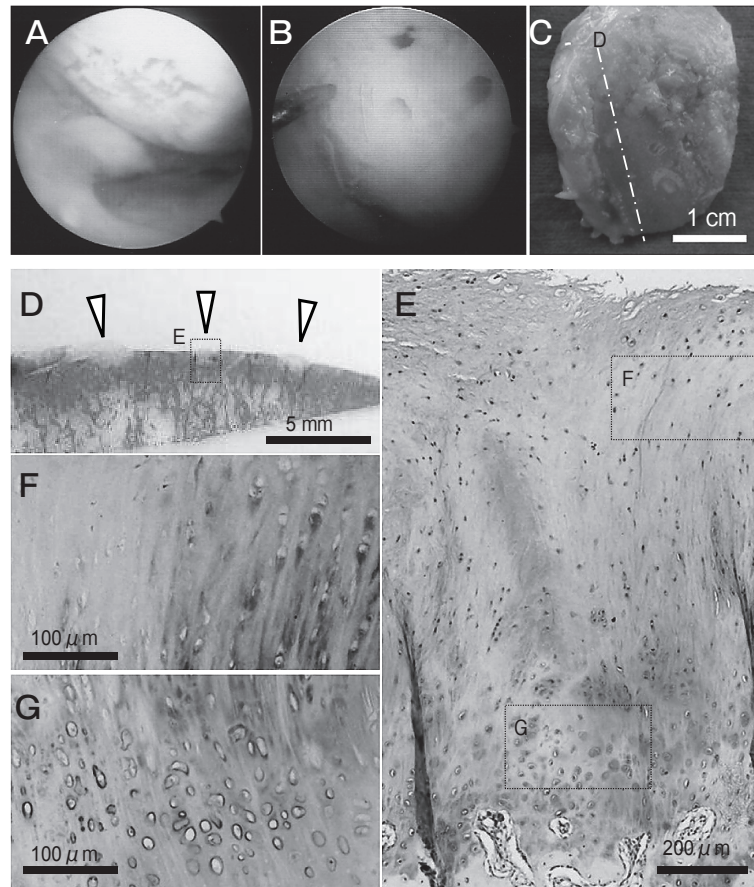


Fig. 4 A 73-year-old female (Case 4). An arthroscopic image of degenerated medial femoral condyle (A). Microfracture was performed using an awl (B). Fibrocartilaginous tissues were observed only in penetrated holes (C). The specimen was prepared along the dashed line (D). Triangles denote the direction of marrow-stimulating holes. HE staining (D). Safranin O-stained proteoglycans (E) and type II collagen (F and G) were limited in the middle to deep layer of the fibrocartilaginous tissues.

showed a fibrocartilaginous cell shape (Fig. 4E-G). However, safranin O-stained proteoglycans and type II collagen were limited to the middle to deep layer of the fibrocartilaginous tissues (Fig. 4E-G).

Discussion

Arthroscopic marrow stimulation induces bleeding from the subchondral bone followed by the formation of a fibrin clot, the migration of mesenchymal stem cells, and the formation of fibrocartilaginous tissue that covers full-thickness cartilage defects [12]. Microfracture and subchondral drilling were developed mainly for the treatment of focal chondral lesions, but are also used in degenerative arthritic knees [9, 12]. Microfracture is used more often than

subchondral drilling, which is considered to induce thermal necrosis of the subchondral bone. However, the adverse effect of drilling on cartilage repair has not been clinically tested. Crushing and compacting of bone by the microfracture technique have been shown to induce substantial osteocyte necrosis around penetrated holes at 1 day postoperatively in a rabbit cartilage defect model [23]. Compared to subchondral drilling at the same depth, microfracture produced similar amount and quality of cartilage repair at 3 months postoperatively in a rabbit model [24]. In our study, empty osteocyte lacunae and osteonecrosis were not histologically observed around penetrated holes at a mean of 21 months after arthroscopic surgery in patients treated by microfracture or subchondral drilling (Fig. 1-4). However, marrow stimulation

induced insufficient cartilage repair for the treatment of large cartilage defects in osteoarthritic knees (Table 2 and 3). Kaul *et al.* reported that microfracture and subchondral drilling resulted in failed cartilage repair for the treatment of early osteoarthritis of the knee (radiological grade 1 and 2); these marrow-stimulating techniques did not improve small cartilage defects (ranging from 2.6 to 4.0 cm²) in 5 patients aged 47 to 65 years old [14]. Several reports have demonstrated that clinical results after microfracture for the treatment of knee cartilage defect are age/size-dependent and that the best prognostic factor is a patient aged 40 or younger with defects on the femoral condyles [25–27]. In our study, marrow stimulation resulted in TKA salvation for the treatment of large cartilage defects (mean, 7 cm²). Furthermore, marrow stimulation did not reach hyaline-like cartilage regeneration in cartilage repair and histological assessments (Table 1–3, Fig. 1–4). On the other hand, marrow stimulation did not need TKA conversion in 6 patients (51, 59, 62, 65, 66, and 74 years old) suffering from small full-thickness cartilage defects (mean, 2.8 cm² ranged from 1 to 4 cm²) of osteoarthritic knees at a mean of 37 months after primary arthroscopic surgeries (Table 4). No difference between TKA salvation and TKA-free groups was observed in the mean age, BMI, and preoperative FTA, except for cartilage defect size (Table 1 and 4). These findings suggest that marrow-stimulating techniques may not suitable for the treatment of cartilage defects larger than 6 cm² in medial compartmental osteoarthritis of the knee. However, limitations still exist in our study. Histological and arthroscopic assessments of cartilage repair after marrow stimula-

tion are ethically prohibited in patients who obtain favorable clinical outcomes of their osteoarthritic knees.

The depth of subchondral drilling (2 mm versus 6 mm) was shown to influence the filling status of rabbit cartilage defects [24]. We consider that the thickness of the eburnated subchondral bone plate (penetrating depth) and the percentage of marrow-communicated area (hole diameter and interval between each hole) might have critical roles in fibrocartilaginous tissue formation after arthroscopic marrow stimulation. In a horse focal cartilage defect model, type II collagen was observed in the intermediate and deep zone of microfractured holes (3-mm depth and 2–3-mm interval) at 8 weeks postoperatively [28]. On the other hand, microfracture (0.028-mm diameter and 3-mm depth) induced poor status of safranin O staining in fibrocartilaginous tissues even at 12 weeks using a primate model [29]. Several authors have reported that safranin O-stained proteoglycans are detected only in the deep layer of marrow-stimulating holes at 1 year postoperatively (1-mm diameter in rabbits; 2–4-mm depth and 3–4-mm interval in humans) [8, 15, 30]. In our study, chondrocyte-like cells, safranin O-stained ECM, and type II collagen deposition localized mainly in the deep layer of penetrated holes (Fig. 1–4). From these findings, true cartilage-like tissue regeneration might be limited to the cavity of marrow-stimulating holes. Further examinations will be required to induce the optimum effect of marrow stimulation on cartilage repair in younger patients.

Marrow stimulation induces pain relief and knee function improvement at a short- to middle-term fol-

Table 4 Demographic data of marrow-stimulated MFC-OA patients underwent no revision surgery

Case	Sex	Side	Age at AS (years)	BMI (kg/m ²)	Defect size (cm ²)	Marrow stimulation	Duration until FFU (months)	Radiological stage ¹⁶ (Grade) (at AS→FFU)	FTA (°) (at AS→FFU)	ICRS cartilage injury classification ¹⁷ (Grade at AS)
5	M	R	51	32	4	Mfx (1.5 mm)	40	1→2	178→180	4
6	F	L	59	29	1	Drill (1.2 mm)	53	2→3	179→181	3
7	F	L	62	29	3	Mfx (1.5 mm)	50	2→3	180→182	3
8	F	R	65	25	4	Mfx (1.5 mm)	15	3→3	177→179	4
9	F	R	66	21	1	Mfx (1.5 mm)	6	2→2	177→177	4
10	F	R	74	24	4	Drill (1.2 mm)	58	3→4	177→181	4
Mean			62.8	26.6	2.8		37		178→180	

AS, arthroscopy; BMI, body mass index; FFU, final follow-up; FTA, femorotibial angle; MFC, medial femoral condyle; Mfx, microfracture; OA, osteoarthritis; TKA, total knee arthroplasty.

low-up period in full-thickness cartilage defects of the osteoarthritic knee [3-5]. Lesion size ($< 2.5 \text{ cm}^2$), patient age (< 30 years), and activity level (low) are the parameters that should be considered in selecting microfracture for the treatment of symptomatic cartilage lesions of the knee [31]. Lower BMI ($< 30 \text{ kg/m}^2$) and a shorter duration of preoperative symptoms (< 12 months) correlate with better postoperative results of microfracture in cartilage defects of the non-osteoarthritic knee [32]. On the other hand, microfracture does not show the anticipated clinical and radiological long-term outcomes in focal cartilage defects of the knee [33]. A leg malalignment $> 5^\circ$ in varus correlates with a worse clinical outcome after microfracture, but no difference was observed with regard to the age of patients (< 45 versus 45-55 years) [33]. In our small sample size study, patients who had a degenerative knee accompanied by large cartilage defect, varus leg alignment, and middle BMI resulted in TKA salvations at a minimum duration of 11 months after arthroscopic microfracture and drilling (Table 1). Cartilage repair on arthroscopic classification was better in osteoarthritic patients who underwent abrasion arthroplasty plus closing-wedge high tibial osteotomy (HTO) than in those who underwent microfracture plus HTO or HTO alone at 1 year postoperatively [11]. However, no difference between these groups was observed in the clinical outcomes at 1, 3, and 5 years postoperatively [11]. Postoperative rehabilitation in the literature is similar to the postoperative protocol in our study. Partial weight bearing is allowed from 4 to 6 weeks postoperatively. Excessive knee motion and early weight bearing may inhibit the maturation of bone marrow-derived clots. However, the optimum rehabilitation procedure to prevent the loss of marrow-derived reparative tissue is unclear. Taken together, arthroscopic marrow stimulation provides a limited short-term effect on the treatment of medial compartmental osteoarthritis of the knee, and might not be suitable for osteoarthritic knees having varus leg alignment.

In conclusion, our study demonstrated that microfracture and subchondral drilling resulted in failed cartilage repair for the treatment of large cartilage defects in the osteoarthritic knees. Regenerated cartilaginous tissues localized mainly at the deep layer of the holes penetrating the subchondral bone plate. Our results suggest that arthroscopic marrow stimulation

might not improve clinical symptoms for the long term in patients suffering large cartilage defects derived from osteoarthritic knees.

Acknowledgments. We are grateful to Ms. Aki Yoshida, Ms. Reina Tanaka, and Ms. Emi Matsumoto for their support. This work was supported by Grants from Japan Society for the Promotion of Science (No. 24791546), the Nakatomi Foundation, and the Japanese Foundation for Research and Promotion of Endoscopy.

References

- Hunt SA, Jazrawi LM and Sherman OH: Arthroscopic management of osteoarthritis of the knee. *J Am Acad Orthop Surg* (2002) 10: 356-363.
- Pape D, Filardo G, Kon E, van Dijk CN and Madry H: Disease-specific clinical problems associated with the subchondral bone. *Knee Surg Sports Traumatol Arthrosc* (2010) 18: 448-462.
- Bae DK, Yoon KH and Song SJ: Cartilage healing after microfracture in osteoarthritic knees. *Arthroscopy* (2006) 22: 367-374.
- Miller BS, Steadman JR, Briggs KK, Rodrigo JJ and Rodkey WG: Patient satisfaction and outcome after microfracture of the degenerative knee. *J Knee Surg* (2004) 17: 13-17.
- Pedersen MS, Moghaddam AZ, Bak K and Koch JS: The effect of bone drilling on pain in gonarthrosis. *Int Orthop* (1995) 19: 12-15.
- Friedman MJ, Berasi CC, Fox JM, Del Pizzo W, Snyder SJ and Ferkel RD: Preliminary results with abrasion arthroplasty in the osteoarthritic knee. *Clin Orthop Relat Res* (1984) 182: 200-205.
- Rand JA: Role of arthroscopy in osteoarthritis of the knee. *Arthroscopy* (1991) 7: 358-363.
- Johnson LL: Arthroscopic abrasion arthroplasty historical and pathologic perspective: present status. *Arthroscopy* (1986) 2: 54-69.
- Goldman RT, Scuderi GR and Kelly MA: Arthroscopic treatment of the degenerative knee in older athletes. *Clin Sports Med* (1997) 16: 51-68.
- Johnson LL: Arthroscopic abrasion arthroplasty: a review. *Clin Orthop Relat Res* (2001) 391: S306-317.
- Matsunaga D, Akizuki S, Takizawa T, Yamazaki I and Kuraishi J: Repair of articular cartilage and clinical outcome after osteotomy with microfracture or abrasion arthroplasty for medial gonarthrosis. *Knee* (2007) 14: 465-471.
- Lützner J, Kasten P, Günther KP and Kirschner S: Surgical options for patients with osteoarthritis of the knee. *Nat Rev Rheumatol* (2009) 5: 309-316.
- LaPrade RF, Bursch LS, Olson EJ, Havlas V and Carlson CS: Histologic and immunohistochemical characteristics of failed articular cartilage resurfacing procedures for osteochondritis of the knee: a case series. *Am J Sports Med* (2008) 36: 360-368.
- Kaul G, Cucchiari M, Remberger K, Kohn D and Madry H: Failed cartilage repair for early osteoarthritis defects: a biochemical, histological and immunohistochemical analysis of the repair tissue after treatment with marrow-stimulation techniques. *Knee Surg Sports Traumatol Arthrosc* (2012) 20: 2315-2324.
- Mitchell N and Shepard N: The resurfacing of adult rabbit articular cartilage by multiple perforations through the subchondral bone. *J Bone Joint Surg Am* (1976) 58: 230-233.
- Kellgren JH and Lawrence JS: Radiological assessment of osteoarthritis. *Ann Rheum Dis* (1957) 16: 494-502.

17. Brittberg M and Winalski CS: Evaluation of cartilage injuries and repair. *J Bone Joint Surg Am* (2003) 85 Suppl 2: 58–69.
18. Mainil-Varlet P, Aigner T, Brittberg M, Bullough P, Hollander A, Hunziker E, Kandel R, Nehrer S, Pritzker K, Roberts S and Stauffer E: Histological assessment of cartilage repair: a report by the Histology Endpoint Committee of the International Cartilage Repair Society (ICRS). *J Bone Joint Surg Am* (2003) 85A Suppl 2: 45–57.
19. Furumatsu T, Hachioji M, Saiga K, Takata N, Yokoyama Y and Ozaki T: Anterior cruciate ligament-derived cells have high chondrogenic potential. *Biochem Biophys Res Commun* (2010) 391: 1142–1147.
20. Takata N, Furumatsu T, Abe N, Naruse K and Ozaki T: Comparison between loose fragment chondrocytes and condyle fibrochondrocytes in cellular proliferation and redifferentiation. *J Orthop Sci* (2011) 16: 589–597.
21. Furumatsu T, Kanazawa T, Yokoyama Y, Abe N and Ozaki T: Inner meniscus cells maintain higher chondrogenic phenotype compared with outer meniscus cells. *Connect Tissue Res* (2011) 52: 459–465.
22. Matsumoto E, Furumatsu T, Kanazawa T, Tamura M and Ozaki T: ROCK inhibitor prevents the dedifferentiation of human articular chondrocytes. *Biochem Biophys Res Commun* (2012) 420: 124–129.
23. Chen H, Sun J, Hoemann CD, Lascau-Coman V, Ouyang W, McKee MD, Shive MS and Buschmann MD: Drilling and microfracture lead to different bone structure and necrosis during bone-marrow stimulation for cartilage repair. *J Orthop Res* (2009) 27: 1432–1438.
24. Chen H, Hoemann CD, Sun J, Chevrier A, McKee MD, Shive MS, Hurtig M and Buschmann MD: Depth of subchondral perforation influences the outcome of bone marrow stimulation cartilage repair. *J Orthop Res* (2011) 29: 1178–1184.
25. Kreuz PC, Erggelet C, Steinwachs MR, Krause SJ, Lahm A, Niemeyer P, Ghanem N, Uhl M and Südkamp N: Is microfracture of chondral defects in the knee associated with different results in patients aged 40 years or younger? *Arthroscopy* (2006) 22: 1180–1186.
26. Kreuz PC, Steinwachs MR, Erggelet C, Krause SJ, Konrad G, Uhl M and Südkamp N: Results after microfracture of full-thickness chondral defects in different compartments in the knee. *Osteoarthritis Cartilage* (2006) 14: 1119–1125.
27. Mithoefer K, McAdams T, Williams RJ, Kreuz PC and Mandelbaum BR: Clinical efficacy of the microfracture technique for articular cartilage repair in the knee: an evidence-based systematic analysis. *Am J Sports Med* (2009) 37: 2053–2063.
28. Frisbie DD, Oxford JT, Southwood L, Trotter GW, Rodkey WG, Steadman JR, Goodnight JL and Mcllwraith CW: Early events in cartilage repair after subchondral bone microfracture. *Clin Orthop Relat Res* (2003) 407: 215–227.
29. Gill TJ, McCulloch PC, Glasson SS, Blanchet T and Morris EA: Chondral defect repair after the microfracture procedure: a nonhuman primate model. *Am J Sports Med* (2005) 33: 680–685.
30. Saris DB, Vanlauwe J, Victor J, Haspl M, Bohnsack M, Fortems Y, Vandekerckhove B, Almqvist KF, Claes T, Handelberg F, Lagae K, van der Bauwhede J, Vandenuecker H, Yang KG, Jelic M, Verdonk R, Veulemans N, Bellemans J and Luyten FP: Characterized chondrocyte implantation results in better structural repair when treating symptomatic cartilage defects of the knee in a randomized controlled trial versus microfracture. *Am J Sports Med* (2008) 36: 235–246.
31. Bekkers JE, Inklaar M and Saris DB: Treatment selection in articular cartilage lesions of the knee: a systematic review. *Am J Sports Med* (2009) 37 Suppl 1: 148–155.
32. Mithoefer K, Williams RJ 3rd, Warren RF, Potter HG, Spock CR, Jones EC, Wickiewicz TL and Marx RG: The microfracture technique for the treatment of articular cartilage lesions in the knee. A prospective cohort study. *J Bone Joint Surg Am* (2005) 87: 1911–1920.
33. Von Keudell A, Atzwanger J, Forstner R, Resch H, Hoffelner T and Mayer M: Radiological evaluation of cartilage after microfracture treatment: A long-term follow-up study. *Eur J Radiol* (2011) 81: 1618–1624.