

Acta Medica Okayama

Volume 55, Issue 4

2001

Article 9

AUGUST 2001

Successful resection of rectal carcinoma in an Evans' syndrome patient followed by predonisolone and high-dose immunoglobulin: report of a case.

Atsunori Nakao* Hiromi Iwagaki† Kenji Notohara‡
Yushinori Morimoto** Norifumi Ariki†† Taiichiro Kanagawa‡‡
Hiroshi Isozaki§ Noriaki Tanaka¶

*Okayama University,

†Okayama University,

‡Okayama University,

**Okayama University,

††Okayama University,

‡‡Okayama University,

§Okayama University,

¶Okayama University,

Successful resection of rectal carcinoma in an Evans' syndrome patient followed by prednisolone and high-dose immunoglobulin: report of a case.*

Atsunori Nakao, Hiromi Iwagaki, Kenji Notohara, Yushinori Morimoto, Norifumi Arika, Taiichiro Kanagawa, Hiroshi Isozaki, and Noriaki Tanaka

Abstract

A 69-year-old woman was admitted to our hospital because of anal bleeding and fatigue. The patient was previously diagnosed as having Evans' syndrome on the basis of hematological examination and had been treated with prednisolone for 8 years. On admission, severe anemia and thrombocytopenia were noted. Colonoscopy and Barium enema studies demonstrated an irregular tumor with hemorrhagic ulceration in the rectum, which was histopathologically confirmed as an adenocarcinoma. After red blood cells and platelets were transfused, and the patient was treated with high-dose gammaglobulin, prednisolone, and camostat mesylate, the platelet count gradually increased and hemolysis was well controlled. The patient then underwent Hartmann's operation and splenectomy without any postoperative complications. Prednisolone and high-dose immunoglobulin therapy in a rectal cancer burdened patient with Evans' syndrome is considered useful in combination with surgical treatment. This is the first case report of rectal carcinoma resection in a patient with Evans' syndrome.

KEYWORDS: immune thrombocytopenia, autoimmune hemolytic anemia, surgical treatment

*PMID: 11512568 [PubMed - indexed for MEDLINE]

Case Report

Successful Resection of Rectal Carcinoma in an Evans' Syndrome Patient Followed by Prednisolone and High-dose Immunoglobulin: Report of a Case

Atsunori Nakao^a, Hiromi Iwagaki^a, Kenji Notohara^b, Yushinori Morimoto^a,
Norifumi Arikai^a, Taiichiro Kanagawa^a, Hiroshi Isozaki^a, and Noriaki Tanaka^a

^aDepartment of Surgery I, and ^bDepartment of Pathology,
Okayama University Medical School, Okayama 700-8558, Japan

A 69-year-old woman was admitted to our hospital because of anal bleeding and fatigue. The patient was previously diagnosed as having Evans' syndrome on the basis of hematological examination and had been treated with prednisolone for 8 years. On admission, severe anemia and thrombocytopenia were noted. Colonoscopy and Barium enema studies demonstrated an irregular tumor with hemorrhagic ulceration in the rectum, which was histopathologically confirmed as an adenocarcinoma. After red blood cells and platelets were transfused, and the patient was treated with high-dose gammaglobulin, prednisolone, and camostat mesylate, the platelet count gradually increased and hemolysis was well controlled. The patient then underwent Hartmann's operation and splenectomy without any postoperative complications. Prednisolone and high-dose immunoglobulin therapy in a rectal cancer burdened patient with Evans' syndrome is considered useful in combination with surgical treatment. This is the first case report of rectal carcinoma resection in a patient with Evans' syndrome.

Key words: immune thrombocytopenia, autoimmune hemolytic anemia, surgical treatment

Evans' syndrome is an uncommon disorder characterized by the association of immune thrombocytopenia (ITP) and autoimmune hemolytic anemia (AIHA)[1]. Both AIHA and ITP have been reported to be associated with malignancies [2, 3], but malignancies occurring with Evans' syndrome have never been reported. It is important for patients with this disorder who are in need of surgical treatment to control hemolysis and thrombocytopenia. We herein describe a successfully treated 69-year-old woman with Evans' syndrome with rectal cancer, whose hemolysis and thrombocytopenia responded well to a combination of prednisolone and

high-dose immunoglobulin administration. Although the patient presented with severe anemia due to rectal bleeding from the tumor and also due to the thrombocytopenia, we were able to successfully treat the patient during the pre- and post-operative periods. To our knowledge, this is the first report of a patient with Evans' syndrome associated with rectal cancer. The present report may help patients with Evans' syndrome and may provide useful information for risk management in cases necessitating surgical intervention.

Case report

The patient was a 69-year-old Japanese woman. In 1991, the patient's family doctor discovered that the patient was anemic and thrombocytopenic. The patient

Received August 24, 2000; accepted January 15, 2001.

*Corresponding author. Phone: +81-86-235-7257; Fax: +81-86-221-8775
E-mail: anakao@imap.pitt.edu (A. Nakao)


was then diagnosed as having Evans' syndrome on the basis of the results of hematological and chemical blood analyses. The patient was treated with 5 mg/day prednisolone p.o. In March 1999, the patient visited her family doctor with complaints of anal bleeding and fatigue. Colonoscopic studies showed a rectal adenocarcinoma; the patient was then referred to our hospital for surgery. The patient also had a history of cholecystectomy due to cholelithiasis in 1976 without complications. There was no significant family history.

On admission, the patient appeared pale and weak, and her body temperature was 38.0 °C. The patient's blood pressure and pulse rate was 104/60 mmHg and 102/min, respectively. The abdomen was soft and flat without tenderness. The spleen was not palpable below the left costal margin. No superficial lymphnodes were palpable. Digital examination revealed an irregular tumor with ulceration on the rectum.

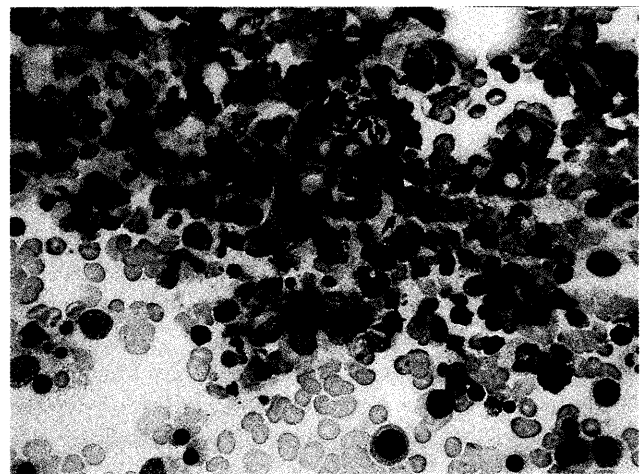
Laboratory studies on admission showed the following results: white blood cell count, 10,700/ μ l; red blood cell count, 204×10^4 / μ l; hemoglobin, 5.8 g/dl; thrombocyte count, 8×10^3 / μ l; total bilirubin 3.13 mg/dl; albumin, 3.0 mg/dl; lactic dehydrogenase, 785 U/ml; carcinoembryonic antigen 3.3 ng/ml; CH50 17 U/ml, serum haptoglobin level; 137 (40-270) mg/dl; fibrin degeneration factor, 16.1 μ g/ml; D-dimer, 4.3 μ g/ml; fibrinogen, 532 mg/dl; antithrombin III 66%; prothrombin time, 15.2 sec. The reticulocyte count was 2.7

% and the erythrocyte sedimentation rate was 121 mm/min. Results of both the direct and the indirect Coombs' tests were positive and were characterized by antiglobulin activity in response to IgG and a complement. Anti-nuclear antibody, anti-DNA antibody, anti-RNA antibody, and anti-platelet antibody tests were all negative. The rheumatoid factor test was also negative. Platelet-associated IgG was 21.0 fg per platelet. Examination of the bone marrow showed increased megakaryocytes and erythroid hyperplasia (Fig. 1A, B). The megakaryocyte count was 611/ μ l; the M/E ratio was 0.3:1.0.

Abdominal ultrasonography and computed tomography revealed no hepatic metastasis or ascites. Barium-enema examination showed an extrinsic filling defect in the rectum. Colonoscopy revealed an irregular tumor with hemorrhagic ulceration. Histopathologic examination of the biopsied specimen identified an adenocarcinoma. The normal haptoglobin level suggested that the severe anemia was most probably due to continuous bleeding from the rectal tumor. A transfusion with red blood cells and platelets was initiated and 0.4 g/kg/day gammaglobulin was administered for 5 days. Prednisolone (40 mg/kg for 3 days and 20 mg/kg for 6 days) and camostat mesylate (500 mg/day) were also administered. The patient's platelet count increased gradually and remained above 150×10^3 / μ l; the hemolysis was well controlled by 10 mg/day of prednisolone (Fig. 2). Although it was thought that the surgical resection might present an



A



B

Fig. 1 Examination of the bone marrow showed increased megakaryocytes (A, $\times 100$). Increased erythroblasts at various stages of maturation were observed (B, $\times 400$).

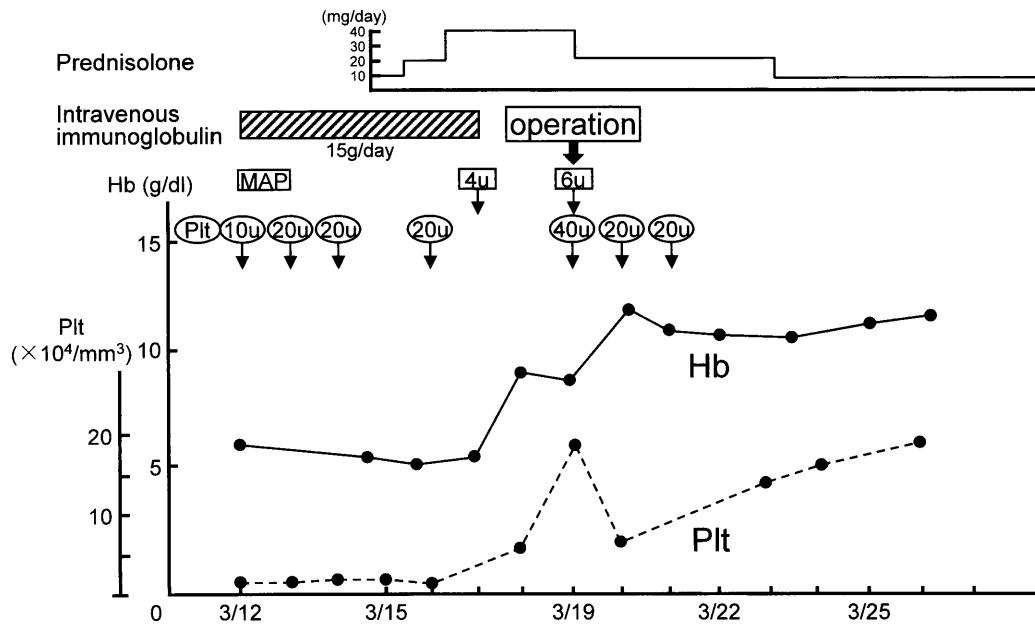


Fig. 2 Clinical course.

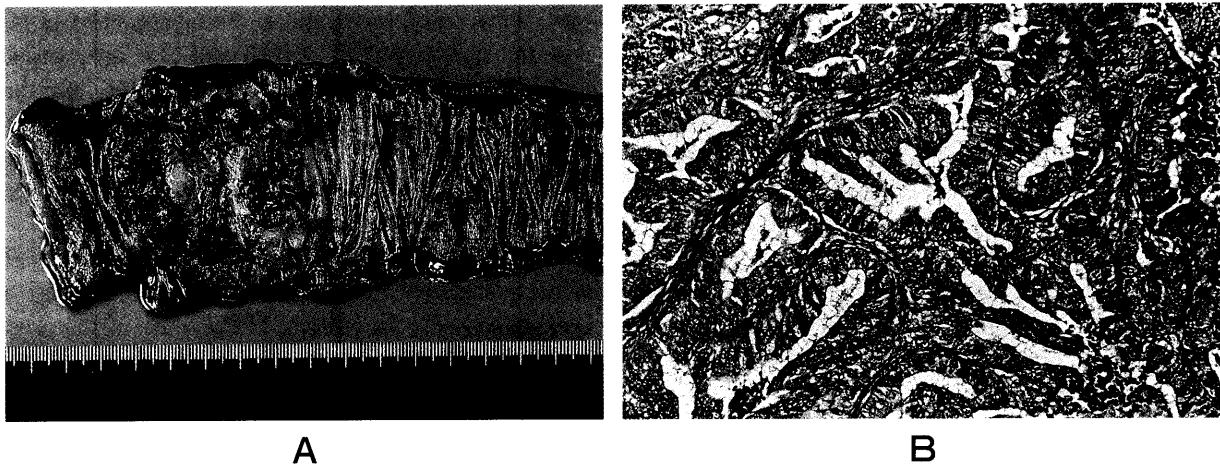


Fig. 3 A, resected specimen included an elevated tumor in the rectum measuring 5.0×4.5 cm. B, histopathological examination revealed a moderately differentiated adeno-carcinoma with subserosal invasion. (H&E $\times 100$)

increased risk because of thrombocytopenia and persistent hemolysis, we performed the operation after obtaining adequate informed consent. The patient underwent Hartmann's operation (D2 lymph node dissection) and splenectomy in order to avoid complications due to the

aforementioned surgical risk. Resected specimen included an elevated tumor measuring 5.0×4.5 cm (Fig. 3A) and a spleen weighing 260 g. Histopathological examination revealed a moderately differentiated adenocarcinoma with subserosal invasion (Fig. 3B). The patient is currently

free of recurrence 10 months after the surgery.

The clinical data from the 14 postoperative days showed extreme improvement: white blood cell count, 9100/ μ l; red blood cell count, $323 \times 10^4/\mu$ l; hemoglobin, 11.0 g/dl; thrombocyte count, $161 \times 10^3/\mu$ l; total bilirubin 1.15 mg/dl; albumin, 3.47 mg/dl; lactic dehydrogenase, 103 U/ml; serum haptoglobin level, 235 mg/dl. AIHA and ITP were well controlled by treatment with 5 mg prednisolone p.o. after the dose of prednisolone was gradually reduced.

Discussion

Evans *et al.* [1] described the first case of the association of idiopathic thrombocytopenic purpura (ITP) with autoimmune hemolytic anemia (AIHA). This clinically rare entity is generally referred to as Evans' syndrome. The pathogenesis of Evans' syndrome is still under debate. However, it has been said that both AIHA and ITP are autoimmune diseases. Although there are many reports of either AIHA [3-5] or ITP [2, 6] in association with a variety of neoplasms, to the best of our knowledge, this is the first report of Evans' syndrome associated with rectal carcinoma. The present report may therefore help overcome hematological risks of surgical intervention in patients with Evans' syndrome. Reporting useful pretreatments for surgery candidates with more than one disease is of increasing importance, because the number of aged patients is also increasing; such patients often have several different diseases at the same time.

The present case invites an investigation into the nature of a relationship between rectal cancer and Evans' syndrome. Remission of autoimmune hemolytic disease obtained by tumor excision has been described in many reports. For example, some cases of AIHA-associated ovarian or non-ovarian dermoid cysts have been reported to be consistently abated by removal of the tumor, whereas in similar cases, responses to corticosteroids have been either negligible or of brief duration [4, 5]. Moreover, ITP has also been recognized as a secondary entity associated with tumors. The cause of ITP in carcinoma patients is unknown, but severe thrombocytopenia has been resolved after the resection of a tumor [6]. Although the pathogenesis of Evans' syndrome observed in this case remains unclear, tumors have been reported to be a cause of Evans' syndrome [4]. Disordered immunoregulation in some patients with ITP or AIHA might predispose them to the development of

carcinoma [2].

In the present case, it had been 10 years after the patient was first diagnosed with Evans' syndrome, when rectal cancer was discovered. Moreover, even after the resection of the tumor, the patient's hematologic features have not resolved as might have been expected. Therefore, there may be a negative relationship between rectal cancer and Evans' syndrome.

For patients with Evans' syndrome who are in need of surgical treatment, it is crucial to control hemolysis and thrombocytopenia due to hematological abnormalities. If medication is an appropriate therapy in any patient with Evans' syndrome, then this therapy remains appropriate if the patient also develops a carcinoma. In the treatment of chronic AIHA, the use of corticosteroids, splenectomy, immune suppressive agents, plasma exchange, and a combination of these treatments have all been reported to induce partial or short remissions, even though they have various negative side effects.

Immunoglobulin fractionated from human plasma and specifically manufactured for intravenous use has been approved for various uses. High doses of immunoglobulin are currently used to treat various autoimmune diseases. Recently, high-dose intravenous immunoglobulin therapy was shown to be successful in the management of otherwise unresponsive ITP. AIHA and ITP are considered to have similar pathophysiologic mechanisms, and thus it is logical to assume that this therapy can be applied for the treatment of AIHA. Corticosteroids, splenectomy, high-dose intravenous immunoglobulin therapy for the treatment of ITP have also been reported [9-12].

Although the mechanism of the immunoglobulin effect is not completely understood, several possibilities have been discussed. As regards ITP, some of the possible mechanisms include: reticuloendothelial system Fc receptor blockade, decrease in autoantibody synthesis, protection of platelets and megakaryocytes from platelet antibody, and clearance of persistent viral infection by specific antibody [10, 13]. Similarly, in connection with AIHA, it can be speculated that the elimination of antibody-coated red cells was prevented by overloading and a blockade of the Fc receptors on macrophages; the subsequent reduction in red cell autoantibody production might be a long-term effect [8].

Furthermore, high-dose immunoglobulin therapy has relatively mild side effects with low frequency. Headache, backache, flushing, chills, fever, and nausea are the most common side effects reported with intravenous

August 2001

Rectal Carcinoma in Evans' Syndrome Patient 257

infusions of immunoglobulin. However, it is important for all clinicians to be aware of the potential for aseptic meningitis to develop after the use of intravenous immunoglobulin products, which may be a cause of continuous headache following the therapy [14]. The direct causes of these symptoms have not been determined. No deaths have been reported due to these side effects.

In conclusion, we successfully resected a rectal carcinoma in a patient with Evans' syndrome. Surgical treatment was followed by treatment with a combination of prednisolone and high-dose immunoglobulin in order to inhibit hematological abnormalities. The pathogenesis of a combined carcinoma and Evans' syndrome remains poorly understood. However, the reported therapy would be advised in the clinical course leading up to and following surgical intervention in such cases.

References

1. Evans RS, Takahashi K, Duane RT, Payne R and Lie CK: Primary thrombocytopenic purpura and acquired hemolytic anemia. *Arch Intern Med* (1951) **87**, 48-65.
2. Bellone JD, Kunicki TJ and Aster RH: Immune thrombocytopenia associated with carcinoma. *Ann Intern Med* (1983) **99**, 470-472.
3. Spira MA and Lynch EC: Autoimmune hemolytic anemia and carcinoma: An unusual association. *Am J Med* (1979) **67**, 753-758.
4. Payne D, Muss HB, Homesley HD, Jobson VW and Baird FG: Autoimmune hemolytic anemia and ovarian dermoid cysts: Case report and review of the literature. *Cancer* (1981) **48**, 721-724.
5. Buonanno G, Gonnella F, Pettinato G and Castaldo C: Autoimmune hemolytic anemia and dermoid cyst of the mesentery. A case report. *Cancer* (1984) **54**, 2533-2536.
6. Kim HD and Boggs DR: A syndrome resembling idiopathic thrombocytopenic purpura in 10 patients with diverse forms of cancer. *Am J Med* (1979) **67**, 371-377.
7. Doll DC, List AF and Yarbrow JW: Evans' syndrome associated with microcystic adenoma of the pancreas. *Cancer* (1987) **59**, 1366-1368.
8. Oda H, Honda A, Sugita K, Nakamura A and Nakajima H: High-dose intravenous intact IgG infusion in refractory autoimmune hemolytic anemia (Evans syndrome). *J Pediatr* (1985) **107**, 744-746.
9. Fehr J, Hoffman V and Kappeler U: Transient reversal of thrombocytopenic in idiopathic thrombocytopenic purpura by high-dose intravenous gamma globulin. *N Engl J Med* (1982) **306**, 1254-1258.
10. Imbach P, Barandun S, d'Apuzzo V, Baumgartner C, Hirt A, Morell A, Rossi E, Schoni M, Vest M and Wagner HP: High-dose intravenous gammaglobulin for idiopathic thrombocytopenic purpura in childhood. *Lancet* (1981) **1**, 1228-1231.
11. Mathew P, Chen G and Wang W: Evans syndrome: Results of a national survey. *J Pediatr Hematol Oncol* (1997) **19**, 433-437.
12. Scaradavou A and Bussel J: Evans syndrome. Results of a pilot study utilizing a multiagent treatment protocol. *J Pediatr Hematol Oncol* (1995) **17**, 290-295.
13. Bussel JB and Hilgartner MW: The use and mechanism of action of intravenous immunoglobulin in the treatment of immune haematologic disease. *Br J Haematol* (1984) **56**, 1-7.
14. Scribner CL, Kapit RM, Phillips ET and Rickles NM: Aseptic meningitis and intravenous immunoglobulin therapy. *Ann Intern Med* (1994) **121**, 305-306.