

Acta Medica Okayama

Volume 52, Issue 4

1998

Article 4

AUGUST 1998

Different expression of Tn and sialyl-Tn antigens between normal and diseased human gastric epithelial cells.

Atushi Yoshida*

Masaaki Sotozono†

Tatsuaki Nakatou‡

Yoshio Okada**

Takao Tsuji††

*Okayama University,

†Okayama University,

‡Okayama University,

**Okayama Prefectural University,

††Okayama Prefectural University,

Different expression of Tn and sialyl-Tn antigens between normal and diseased human gastric epithelial cells.*

Atushi Yoshida, Masaaki Sotozono, Tatsuaki Nakatou, Yoshio Okada, and Takao Tsuji

Abstract

Thomsen-Friedenreich antigen (T antigen) has been supposed to be a cancer-specific carbohydrate antigen. We have previously shown that one third of the Japanese population normally expressed T antigen in gastric surface epithelia and the other two thirds expressed fucosyl-T antigen. Their sialylation and blocked-synthesis were associated with diseased conditions. In the present study, we studied gastric surface epithelial expression of monosaccharide antigen Tn, i.e., a precursor of T antigen, and sialyl-Tn. Normal fundic and pyloric epithelia, respectively, expressed Tn supranucleally and cytoplasmically, but did not express sialyl-Tn. In the intestinal metaplasias and intestinal-type adenomas, goblet cells expressed sialyl-Tn in their vacuoles, and absorptive cells expressed Tn apically. In gastric-type adenomas, Tn, but not sialyl-Tn, was detected. Intestinal-type cancers expressed Tn and sialyl-Tn more often than the diffuse-type cancers. Five cancers did not express Tn, sialyl-Tn, or the T-related antigens. In these, four were diffuse-type cancers. We concluded that: a) normal gastric epithelial cells express Tn; b) metaplastic differentiation is associated with sialylation of Tn and c) expression of Tn and sialyl-Tn is depressed in the gastric cancers.

KEYWORDS: Tn, immunohistochemistr

*PMID: 9781270 [PubMed - indexed for MEDLINE]

Different Expression of Tn and Sialyl-Tn Antigens Between Normal and Diseased Human Gastric Epithelial Cells

Atsushi YOSHIDA^{a*}, Masa-aki SOTOZONO^a, Tatsuaki NAKATOU^a, Yoshio OKADA^b and Takao TSUJI^a

^aFirst Department of Internal Medicine, Okayama University Medical School, Okayama 700-8558 and ^bDepartment of Nutritional Science, Faculty of Health and Welfare Science, Okayama Prefectural University, Soja, Okayama 719-1112, Japan

Thomsen-Friedenreich antigen (T antigen) has been supposed to be a cancer-specific carbohydrate antigen. We have previously shown that one third of the Japanese population normally expressed T antigen in gastric surface epithelia and the other two thirds expressed fucosyl-T antigen. Their sialylation and blocked-synthesis were associated with diseased conditions. In the present study, we studied gastric surface epithelial expression of monosaccharide antigen Tn, *i.e.*, a precursor of T antigen, and sialyl-Tn. Normal fundic and pyloric epithelia, respectively, expressed Tn supranucleally and cytoplasmically, but did not express sialyl-Tn. In the intestinal metaplasias and intestinal-type adenomas, goblet cells expressed sialyl-Tn in their vacuoles, and absorptive cells expressed Tn apically. In gastric-type adenomas, Tn, but not sialyl-Tn, was detected. Intestinal-type cancers expressed Tn and sialyl-Tn more often than the diffuse-type cancers. Five cancers did not express Tn, sialyl-Tn, or the T-related antigens. In these, four were diffuse-type cancers. We concluded that: a) normal gastric epithelial cells express Tn; b) metaplastic dedifferentiation is associated with sialylation of Tn and c) expression of Tn and sialyl-Tn is depressed in the gastric cancers.

Key words: Tn, immunohistochemistry

Histological expression of complex carbohydrate antigens such as ABH blood group substances is characteristic for a given tissue (1, 2). Their expression is developmentally regulated. Cancer cells are often associated with changes in the carbohydrate antigens characteristic to their original tissues (3, 4). Phenotypic changes of

cellular carbohydrate antigens, however, are not restricted to malignant transformation. They can also be seen in benign pathological conditions as we have previously described (5, 6).

The first step of the O-glycosidic or mucin type carbohydrate antigen biosynthesis is represented by the linkage of N-acetyl-D-galactosamine (GalNAc) to serine or threonine residues of apoprotein, forming the structure named Tn antigen, *i.e.*, GalNAc α 1-O-Ser/Thr. Galactosylation of Tn forms T antigen, *i.e.*, Gal β 1-3GalNAc α 1-O-Ser/Thr. These simple core antigens are generally supposed to be masked by further glycosylation in normal tissues, and their expression is a cancer-associated phenomenon (7-10). However, recent studies using monoclonal antibodies specific for these sugar antigens showed that not only cancers but also the benign tissues expressed them. Normal colonic epithelial cells and pancreatic acinar cells, for example, express Tn supranucleally (11, 12). Both hyperplastic and adenomatous colorectal polyps express sialyl-Tn (13).

Human gastric epithelia expresses ABH and Lewis blood group antigens (1, 2, 14, 15). Gastric cancer is associated with changes in their expression (15-18). Gastric mucin carries these blood group antigens with the core structure of T (19). We have shown recently that Thomsen-Friedenreich antigen (T antigen) was allogeneically expressed in human gastric surface epithelia (20). About one third of the Japanese population normally express T antigen, and it is completely fucosylated in the other two thirds. We have also shown that T antigen was expressed gastric cancer-associatedly in the half of normally expressing fucosyl-T antigen (5). Thus T antigen is expressed cancer-specifically in the fucosyl-T-expressers as proposed (7-10) but constitutionally in the T-

* To whom correspondence should be addressed.

expressers. Tn is a precursor for T and fucosyl-T antigens. Although its precise distribution in normal gastric epithelia has not been described, sialyl-Tn was reported to be newly expressed even in intestinal metaplasias in spite of its absence in the normal gastric epithelial cells (21). Its higher expression was correlated with the progression of gastric cancers (22), and its high plasma levels were correlated with the prognosis of gastric cancer patients (23). On the other hand, Nakasaki *et al.* detected sialyl-Tn in the well, but not in the moderate or poorly, differentiated areas in gastric cancers (24). In the present study, we addressed whether Tn is a masked antigen in normal human gastric surface epithelia, and what are the changes in the benign and malignant gastric dedifferentiation disorders.

Materials and Methods

Stomach tissues. Each 15 of normal fundic and pyloric mucosae were obtained under endoscopy from patients subjected to diagnostic endoscopy for nonspecific gastrointestinal symptoms. Thirteen intestinal metaplastic and 12 gastric adenomatous tissues were also obtained. Ten of the adenomas were intestinal-type, and 2 were gastric-type (25, 26). Among 54 gastric cancer specimens, 35 were biopsied under endoscopy and 19 were surgically-resected tissues. Thirty one gastric cancers were intestinal-type, and 23 were diffuse-type (27).

All tissues were fixed in 10 % neutrally-buffered formalin, embedded in paraffin and cut into 4 μ m sections for immunohistochemical staining.

Immunohistochemistry. 1E3 (IgG), an anti-Tn mouse monoclonal antibody (MoAb), and TKH2 (IgG), an anti-sialyl-Tn mouse MoAb, were kindly provided by Professor S. Hakomori, Biomembrane Institute, Seattle, WA (Table 1). The antigens were detected immunohistochemically in an avidin-biotin-peroxidase complex method (Vectastain ABC kit, Vector Labs, Burlingame, CA) as previously described (6). Briefly, the deparaffinized and rehydrated tissue sections were incubated in 0.3 % hydrogen peroxide in methanol for 30 min to destroy endogenous peroxidase activities. Nonspecific sites were blocked with 2 % normal horse serum in 0.5 % bovine serum albumin (BSA) in phosphate-buffered saline (PBS). They were then reacted successively with the hybridoma supernatant diluted twice with 0.5 % BSA in PBS for 2 h at room temperature, with biotinylated horse anti-mouse IgG for 30 min, and then with the avidin-

Table 1 Carbohydrate antigen structures studied in the present study and monoclonal antibodies used for their immunohistochemical detection

Antigen	Carbohydrate structure	MoAb for detection
Tn	GalNAc α -O-Ser/Thr	1E3
Sialyl-Tn	SA α 2-6GalNAc α -O-Ser/Thr	TKH2

biotin-peroxidase conjugate. After thorough washing, the slides were incubated in a substrate solution containing 0.1 % diaminobenzidine, 0.002 % hydrogen peroxide and 0.065 % sodium azide in 0.1M Tris-HCl, pH 7.2.

When the first antibody was omitted or substituted with the myeloma cell supernatant or normal mouse serum, no nonspecific staining was observed. The absence of endogenous avidin- and biotin-like activities were confirmed with the use of the blocking kits (Vector Lab.).

The extent of carbohydrate antigen expression was evaluated according to the percentage of cells stained: negative expression, less than 5 % cells stained; moderate expression, 5 to 50 % cells stained; and extensive expression, more than 50 % cells stained. Positive but only faint staining was referred to as weak expression. Apical, cytoplasmic, and supranuclear expressions were distinguished according to the intracellular distribution of the antigens.

Statistical analysis. Statistical differences among the groups were calculated using the chi-square test. A *P* value of less than 0.05 was taken to be significant.

Results

The effects of glycosidase digestion on the staining were examined to confirm specificity of the immunohistochemical method. After treatment of tissues that were cytoplasmically positive for T antigen but unreactive with 1E3, with β -galactosidase, they became positively stained with 1E3. Similarly, when tissues positively stained with TKH2 but not with 1E3 were desialylated with neuraminidase, they lost TKH2-reactivity and gained 1E3-reactivity. These observations assured specificity of 1E3 and TKH2 immunostaining.

We haven't stained fresh-frozen tissues, but Oettgen *et al.* have previously shown that no difference in staining of Tn and sialyl-Tn between fresh-frozen and paraffin-embedded tissues (28).

Normal gastric surface epithelia. Tn was

detected in all normal gastric surface epithelia examined (Table 2). Expression was extensive in three fourths of the cases. Intracellular distribution differed between the fundus and pylorus. Fundic epithelia typically expressed Tn supranuclearly (Table 3, Fig. 1A), and pyloric epithelia expressed cytoplasmically (Table 3, Fig. 1B). Positively stained mucin layers were also found in the luminal

surfaces of the pylorus (Fig. 1B). Pyloric epithelial cytoplasm was rather weakly stained compared with the luminal mucins. Sialyl-Tn was not detected in the normal gastric epithelia (Fig. 1, inserts) except for occasional expression in parietal cells (data not shown). No apparent difference in the expression ratio of Tn was found between the T- and fucosyl-T-expressers (20).

Table 2 Expression of Tn and sialyl-Tn by the normal and diseased gastric epithelia

Diagnosis	Number	Positive cases (%) for			
		(-) ^a	Tn	Sialyl-Tn	T-related antigens ^b
Normal	30	0	30 (100) ^c	0	30 (100)
Metaplasia	13				
Goblet cells		0	0	13 (100)	13 (100)
Absorptive cells		0	13 (100)	0	0
Adenoma					
Intestinal-type	10				
Goblet cells		0	0	10 (100)	10 (100)
Absorptive cells		0	7 (70)	0	0
Gastric-type	2	0	2 (100)	0	2 (100)
Cancer					
Intestinal-type	31	1 (3)	17 (55) ^d	25 (81) ^e	25 (81)
Diffuse-type	23	4 (17)	6 (26) ^d	8 (35) ^e	19 (83)

a: None of Tn, sialyl-Tn and the T-related antigens were detected.

b: At least one of T, fucosyl-T, sialyl-T, or sialyl-fucosyl-T was detected.

c: See Table 3 for the intracellular distribution.

d: $P = 0.0346$ between the intestinal-type and diffuse-type cancers.

e: $P = 0.0006$ between the intestinal-type and diffuse-type cancers.

Table 3 Intracellular distribution of Tn and sialyl-Tn in human gastric epithelia

	Number	Tn				Sialyl-Tn			
		Supranuclear	Cytoplasmic	Apical	Goblet cell vacuoles	Supranuclear	Cytoplasmic	Apical	Goblet cell vacuoles
Normal									
Fundic epithelia	15	13 (87) ^a	3 (20)	0	—	0	0	0	—
Pyloric epithelia	15	3 (20)	14 (93)	0	—	0	0	0	—
Metaplasia	13	13 (100) ^b	0	3 (23) ^b	0	0	0	0	13 (100) ^c
Adenoma									
Intestinal-type	10	2 (20) ^b	3 (30) ^b	4 (40) ^b	0	0	0	0	10 (100) ^c
Gastric-type	2	2 (100)	2 (100)	0	—	0	0	0	—
Cancer									
Intestinal-type	31	0	10 (32)	7 (23)	—	0	21 (68)	4 (13)	—
Diffuse-type	23	0	6 (26)	0	—	0	8 (35)	1 (4)	—

a: Numbers in parentheses show percentage.

b: Only absorptive cells were positive (See Table 2).

c: Only goblet cells were positive (See Table 2).

Fig. 1 Expression of Tn and sialyl-Tn by normal gastric surface epithelia.

A: Tn-immunostaining of normal fundic mucosa with IE3. Note positive supranuclear staining. Insert shows negative staining with TKH2. Original magnification; $\times 200$. **B:** Tn-immunostaining of normal pyloric mucosa with IE3. Note positive cytoplasmic and apical staining. Insert shows negative staining with TKH2. Original magnification; $\times 200$.

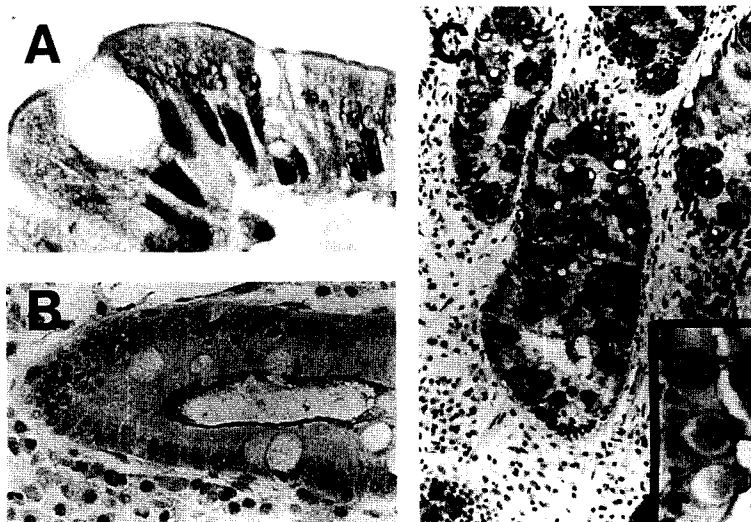
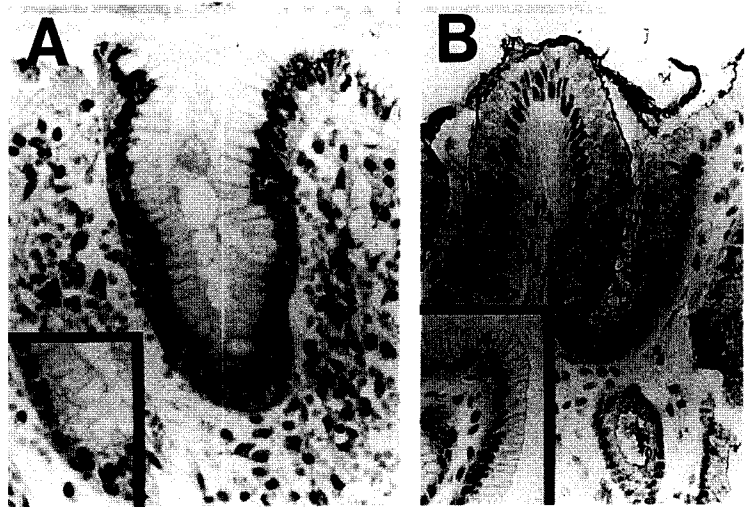


Fig. 2 Expression of Tn and sialyl-Tn by gastric intestinal metaplasia.

A: Tn-immunostaining with IE3. Note positive supranuclear staining of absorptive cells. Goblet cell vacuoles are negative. Original magnification; $\times 1000$. **B:** Tn-immunostaining with IE3. Note positive apical staining. Goblet cell vacuoles are negative. Original magnification; $\times 400$. **C:** Sialyl-Tn-immunostaining with TKH2. Goblet cell vacuoles are positively stained. Original magnification; $\times 100$. Insert at higher magnification; $\times 1000$.

Intestinal metaplasias. Goblet cells extensively expressed sialyl-Tn in their vacuoles (Table 3, Fig. 2C). They were negative for Tn (Fig. 2A). The absorptive cells were totally negative for sialyl-Tn but expressed Tn supranuclearly (Table 3, Fig. 2A). They also expressed Tn apically in some cases (Table 3, Fig. 2B).

Gastric adenomas. Expression of Tn and sialyl-Tn by the intestinal-type adenomas was similar to that of the intestinal metaplasias (Tables 2 to 3, Fig. 3). The goblet cells expressed sialyl-Tn in their vacuoles but did not Tn (Fig. 3B). Absorptive cells expressed Tn supranuclearly, cytoplasmically, and apically in some cases (Fig. 3A). They did not express sialyl-Tn.

Only two gastric-type adenomas could be examined. They expressed Tn apically and cytoplasmically (Table 3, Fig. 3C) but did not express sialyl-Tn (Fig. 3D).

Gastric cancers. Tn and sialyl-Tn, respectively, were detected in 43% and 61% of gastric cancers (Table 2). They were more often expressed by intestinal-type gastric cancers than by diffuse-type gastric cancers, *i.e.*, 55% *vs* 26% for Tn (0.0346), and 81% *vs* 35% for sialyl-Tn (0.0006) (Table 2). These antigens were usually detected cytoplasmically (Table 3, Fig. 4). Some of the intestinal-type gastric cancers also expressed them apically.

There was no statistically significant difference be-

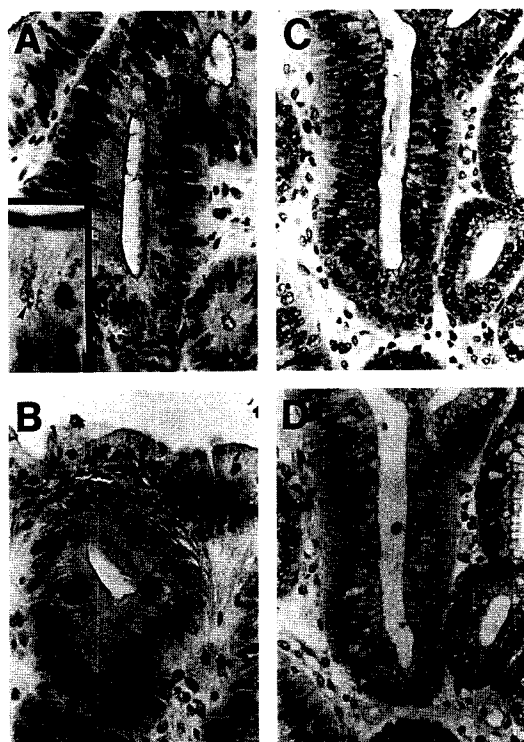


Fig. 3 Expression of Tn and sialyl-Tn by gastric adenoma. **A:** Tn-immunostaining of intestinal-type adenoma with IE3. Note positive apical staining of absorptive cells. Original magnification; $\times 400$. Insert shows positive supranuclear staining (arrow head). Original magnification; $\times 1000$. **B:** Sialyl-Tn-immunostaining of intestinal-type adenoma with TKH2. Note positive staining of goblet cell vacuoles. Original magnification; $\times 400$. **C:** Tn-immunostaining of gastric-type adenoma with IE3. Note positive apical and cytoplasmic staining. Original magnification; $\times 400$. **D:** Sialyl-Tn-immunostaining of gastric-type adenoma with TKH2. Positive staining is not observed. Original magnification; $\times 400$.

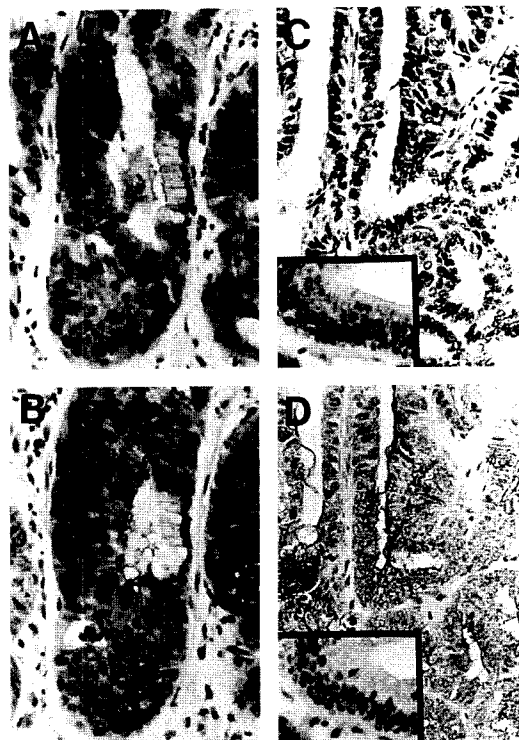


Fig. 4 Expression of Tn and sialyl-Tn by gastric cancer. **A:** Cancer cells are negative for Tn, which is expressed apically by normal epithelial cells (between arrows). Original magnification; $\times 400$. **B:** Cancer cells apically express sialyl-Tn, which is not detected in normal epithelial cells (between arrows). Same area as A. Original magnification; $\times 400$. **C:** Cancer cells in a cancer-in-adenoma case are negative for Tn. Adjacent adenoma cells are positive (Insert). Original magnification; $\times 200$. **D:** Cancer cells in the same area as C are positive for sialyl-Tn. Adjacent adenoma cells are negative (Insert). Original magnification; $\times 200$.

Table 4 Expression of Tn and sialyl-Tn in the T-related antigens positive and negative gastric cancers

	T-related antigens							
	(+)				(-)			
	Tn ^a		Sialyl-Tn ^b		Tn ^c		Sialyl-Tn ^d	
(+)	(-)	(+)	(-)	(+)	(-)	(+)	(-)	
Intestinal-type	12 ^e	13	20	5	5	1	5	1
Diffuse-type	6	13	8	11	0	4	0	4

a : No significant difference between the intestinal- and diffuse-type cancers ($P = 0.2697$).
b : Significant difference between the intestinal- and diffuse-type cancers ($P = 0.0096$).
c : Significant difference between the intestinal- and diffuse-type cancers ($P = 0.0098$).
d : Significant difference between the intestinal- and diffuse-type cancers ($P = 0.0098$).
e : Numbers of cases positive or negative for the antigens are shown.

tween the T-related antigen positive and negative cancers in their expression of Tn and sialyl-Tn ($P = 0.5997$ and 0.4246 , respectively).

Six intestinal-type and 4 diffuse-type gastric cancers were negative for any of the T-related antigens. Among them, 5 intestinal-type cancers expressed Tn and sialyl-Tn (Table 4). All 4 diffuse-type cancers, however, expressed neither Tn nor sialyl-Tn. Thus, all antigen-negative cases were seen more frequently in the diffuse-type cancers (4 in 23) than in the intestinal-type cancers (one in 32) ($P = 0.0724$).

The intestinal-type and diffuse-type cancers were compared in their Tn and sialyl-Tn expression (Table 4). In the T-related antigen positive cases, sialyl-Tn, but not Tn, was more often expressed in the intestinal-type cancers than the diffuse-type cancers ($P = 0.0096$). In the T-related antigen negative cases, the intestinal-type cancers expressed both antigens more frequently than the diffuse-type cancers ($P = 0.0098$).

Discussion

Addition of N-acetylgalactosamine to serine or threonine residues is the first step of mucin glycosylation forming Tn antigen. Tn antigen is converted to T antigen when β 1-3galactosylation takes place. Tn and T antigens are claimed to be masked by further glycosylation in the normal and benign-diseased tissues (7, 29, 30), but exposed in cancer tissues (30, 31). However, we have previously reported that T was an allogeneic antigen in normal gastric surface epithelia and expressed normally by one third of Japanese (20). We showed here that the normal human gastric surface epithelia also expressed the most simple mucin carbohydrate antigen, *i.e.*, Tn. Thus Tn and T are not cancer-specific antigens in the gastric surface epithelia.

We have previously reported that both fundic and pyloric epithelia expressed T and fucosyl-T cytoplasmically (20). In the present study, Tn was detected supranuclearly in the fundus and cytoplasmically in the pylorus. These observations altogether suggested that further glycosylation of Tn took place in the Golgi apparatus before its movement into cytoplasm in fundic epithelia. Pyloric epithelia, on the other hand, seemed to transport Tn into cytoplasm without galactosylation. Carbohydrate antigen phenotype in the gastric surface differs between the fundus and pylorus. Others have described differences between the surface epithelia and deep glands in their

ABH and Lewis blood group antigen expression (14, 15). Gastric mucosa thus has a unique three dimensional distribution of carbohydrate antigens.

The most striking change observed in the diseased gastric epithelia was sialylation of Tn. Expression of sialyl-Tn was observed in the metaplasias, adenomas, and cancers. Expression of sialyl-Tn by gastric intestinal metaplasias was previously reported (21). Similarly, we have previously shown that the T-related antigen was not sialylated in the normal epithelia, but highly sialylated in the diseased mucosae (5). Goblet cell vacuoles were strongly positive for sialyl-Tn. Sialyl-Tn was detected in the goblet cell vacuoles of the normal small intestines (32) but was not in those of the large intestines (31). Although we do not know the pathobiological implication of the observed sialylation, gastric surface epithelia seemed dedifferentiating mainly into the small intestinal-type epithelia in these pathological conditions. Dedifferentiation of normal gastric epithelia into the goblet cells must be associated with the induction of α 2-6 sialyltransferase. Increased activity of sialyltransferase in metaplasias was previously suggested (33).

Absorptive cells of intestinal metaplasias expressed Tn but neither sialyl-Tn nor any T-related antigens. It can be suggested that N-acetylglucosaminylation of Tn takes place in the goblet cells instead of N-acetylgalactosaminylation (22). Or T may be further glycosylated into the longer sugar chains with ABH and Lewis blood group antigen activities (19).

We could not find a cancer-specific pattern of Tn and sialyl-Tn expression. Although they were claimed to be the gastric cancer-associated antigens (7-10, 22), their expression is not restricted to cancers (21, 32). We also have shown in this and previous reports that they were expressed in the normal and benign-diseased gastric epithelia (5). However, one intestinal-type cancer was found in adenoma expressed sialyl-Tn in spite of its absence in adenoma (Figs. 4C and D). Its surrounding metaplastic epithelia expressed sialyl-Tn. This particular case indicated a possible cancer-specific sialylation. Another cancer-specific abnormality confirmed in the present study was the total loss of the O-glycosidic core antigens. Blocking of complex carbohydrate synthesis is proposed to be a unique cancer-specific phenomenon (3-5, 8, 34). Although biosynthesis of the O-glycosidic sugar chain is probably blocked at many steps, the neoexpressed antigens can not be detected as cancer-specific because in stomachs their expression is associated with normal and/

or benign-disease.

Epidemiological data indicated the close association of intestinal metaplasia with intestinal-type gastric cancer (35, 36). The present observations suggested a cellular lineage among the metaplasias, intestinal-type adenomas, and intestinal-type cancers. All of them expressed sialyl-Tn frequently. Most intestinal-type cancers may inherit the ability to synthesize sialyl-Tn in spite of the lack of ability to compartmentalize it into vacuoles. Abnormal compartmentalization of carbohydrate antigens was previously reported in cancer cells (37). There were significant differences between the intestinal-type and diffuse-type gastric cancers in their expression of Tn and sialyl-Tn. The T-related antigens were sialylated more often in the former (5). These two cancer types may have different cellular origins.

In conclusion, Tn is a normal gastric epithelial antigen, metaplastic dedifferentiation was associated with its sialylation, and malignant transformation was associated with its blocked synthesis. Further studies are needed to determine the clinical implications of the observed changes. Increased sialylation of cancer cells may affect their malignant potential (21-23, 38-42). Phenotypic change in carbohydrate antigens may modulate infectivity of *Helicobacter pylori* (43-45). Sialylation of mucins may have an implication in mucosal cytoprotection against acid as we have previously suggested (32, 46, 47).

References

1. Szulman AE: The histological distribution of blood group substances A and B in man. *J Exp Med* (1960) **111**, 785-800.
2. Szulman AE: The histological distribution of the blood group substances in man as disclosed by immunofluorescence. II. The H antigen and its relation to A and B antigens. *J Exp Med* (1962) **115**, 977-996.
3. Feizi T: Demonstration by monoclonal antibodies that carbohydrate structures of glycoproteins and glycolipids are onco-developmental antigens. *Nature* (1985) **314**, 53-57.
4. Hakomori S and Kannagi R: Glycosphingolipids as tumor-associated and differentiation markers. *J Natl Cancer Inst* (1983) **71**, 231-251.
5. Sotozono MA, Okada Y and Tsuji T: The Thomsen-Friedenreich antigen-related carbohydrate antigens in human gastric intestinal metaplasia and cancer. *J Histochem Cytochem* (1994) **42**, 1575-1584.
6. Okada Y, Shimoe T, Muguruma M, Usumoto R, Tsuji T, Jinno K, Moriwaki S, Shin S and Hakomori S: Hepatocellular expression of a novel glycoprotein with sialylated difucosyl Le^x activity in the active inflammatory lesions of chronic liver disease. *Am J Pathol* (1988) **130**, 384-392.
7. Springer GF: T and Tn, general carcinoma autoantigens. *Science* (Wash DC) (1984) **224**, 1198-1206.
8. Singhal A and Hakomori S: Molecular changes in carbohydrate antigens associated with cancer. *Bioessays* (1990) **12**, 223-230.
9. Barr N, Taylor CR, Young T and Springer GF: Are pancreatic carcinoma T and Tn differentiation antigens? *Cancer* (1989) **64**, 834-841.
10. Springer GF, Desai PR, Ghazizadeh M and Tegtmeyer H: T/Tn pancreatic carcinoma autoantigens: Fundamental, diagnostic and prognostic aspects. *Cancer Detect Prev* (1995) **19**, 173-182.
11. Itzkowitz S, Kjeldsen T, Frieria A, Hakomori S, Yang US and Kim YS: Expression of Tn, sialyl-Tn, and T antigens in human pancreas. *Gastroenterology* (1991) **100**, 1691-1700.
12. Giuffre G, Vitarelli E, Tuccari G, Ponz de Leon M and Barresi G: Detection of Tn, sialosyl-Tn and T antigens in hereditary nonpolyposis colorectal cancer. *Virchows Arch* (1996) **429**, 345-352.
13. Itzkowitz SH, Bloom EJ, Lau TS and Kim YS: Mucin associated Tn and sialosyl-Tn antigen expression in colorectal polyps. *Gut* (1992) **33**, 518-523.
14. Mollicone R, Bara J, Le Pendu J and Oriol R: Immunohistologic pattern of type 1 (Le^a, Le^b) and type 2 (X, Y, H) blood group-related antigens in the human pyloric and duodenal mucosae. *Lab Invest* (1985) **53**, 219-227.
15. Torrado J, Blasco E, Cosme A, Gutierrez-Hoyos A and Arenas JI: Expression of type 1 and type 2 blood group-related antigens in normal and neoplastic gastric mucosa. *Am J Clin Pathol* (1989) **91**, 249-254.
16. Kapadia A, Feizi T, Jewell D, Keeling J and Slavina G: Immunocytochemical studies of blood group A, H, I, and i antigens in gastric mucosae of infants with normal gastric histology and of patients with gastric carcinoma and chronic benign peptic ulceration. *J Clin Pathol* (1981) **34**, 320-337.
17. Sakamoto J, Watanabe T, Tokumura T, Takagi H, Nakazato H and Lloyd KO: Expression of Lewis^a, Lewis^b, Lewis^x, Lewis^y, sialyl-Lewis^a, and sialyl-Lewis^x blood group antigens in human gastric carcinoma and in normal gastric tissue. *Cancer Res* (1989) **49**, 745-752.
18. Torrado J, Blasco E, Gutierrez-Hoyos A, Cosme A, Lojendio M and Arenas JI: Lewis system alteration in gastric carcinogenesis. *Cancer* (1990) **66**, 1769-1774.
19. Slomiany BL, Zdebska E and Slomiany A: Structural characterization of neutral oligosaccharides of human H⁺Le^b gastric mucin. *J Biol Chem* (1984) **259**, 2863-2869.
20. Okada Y, Sotozono M-a, Sakai N, Yonei T, Nakanishi S and Tsuji T: Fucosylated Thomsen-Friedenreich antigen in α -anomeric configuration in human gastric surface epithelia: An allogeneic carbohydrate antigen possibly controlled by the Se gene. *J Histochem Cytochem* (1994) **42**, 371-376.
21. Kushima R, Jancic S and Hattori T: Association between expression of sialosyl-Tn antigen and intestinalization of gastric carcinomas. *Int J Cancer* (1993) **55**, 904-908.
22. Yamashita Y, Chung YS, Horie R, Kannagi R and Sowa M: Alterations in gastric mucin with malignant transformation: Novel pathway for mucin synthesis. *J Natl Cancer Inst* (1995) **87**, 441-446.
23. Takahashi I, Maehara Y, Kusumoto T, Yoshida M, Kakeji Y, Kusumoto H, Furusawa M and Sugimachi K: Predictive value of preoperative serum sialyl Tn antigen levels in prognosis of patients with gastric cancer. *Cancer* (1993) **72**, 1836-1840.
24. Nakasaki H, Mitomi T, Noto T, Ogoshi K, Hanaue H, Tanaka Y, Makuuchi H, Clausen H and Hakomori S: Mosaicism in the expression of tumor-associated carbohydrate antigens in human colonic and gastric cancers. *Cancer Res* (1989) **49**, 3662-3669.
25. Nelson RS and Lanza FL: *Gastroenterology*. W.B. Saunders, Philadelphia (1985) Vol 1, pp841-858.
26. Rubin E and Farber JL: *Pathology*. Lippincott, Philadelphia (1988) pp 644-661.
27. Lauren P: The two histological main types of gastric carcinoma: Diffuse and so-called intestinal-type carcinoma. An attempt at a histoclinical classification. *Acta Path Microbiol Scand* (1965) **64**, 31-

- 49.
28. Schuessler MH, Pintado S, Welt S, Real MX, Xu M, Melamed MR, Lloyd KO and Oettgen HF: Blood group and blood-group-related antigens in normal pancreas and pancreas cancer: Enhanced expressions of precursor type I, Tn and sialyl-Tn in pancreas cancer. *Int J Cancer* (1991) **47**, 180-187.
 29. Hirohashi S, Clausen H, Yamada T, Shimosato Y and Hakomori S: Blood group A cross-reacting epitope defined by monoclonal antibodies NCC-LU-35 and -81 expressed in cancer of blood group O or B individuals: Its identification as Tn antigen. *Proc Natl Acad Sci USA* (1985) **82**, 7039-7043.
 30. Takahashi HK, Metoki R and Hakomori S: Immunoglobulin G3 monoclonal antibody directed to Tn antigen that does not cross-react with blood group A antigen. *Cancer Res* (1988) **48**, 4361-4367.
 31. Itzkowitz SH, Yuan M, Montgomery CK, Kjeldsen T, Takahashi HK, Bigbee WL and Kim YS: Expression of Tn, sialosyl-Tn, and T antigens in human colon cancer. *Cancer Res* (1989) **49**, 197-204.
 32. Yonezawa S, Tachikawa T, Shin S and Sato E: Sialosyl-Tn antigen: Its distribution in normal human tissues and expression in adenocarcinomas. *Am J Clin Pathol* (1992) **98**, 167-174.
 33. Filipe MI: Mucins in the human gastrointestinal epithelium: A review. *Invest Cell Pathol* (1979) **2**, 195-216.
 34. Lloyd KO: Blood group antigens as markers for normal differentiation and malignant change in human tissues. *American Journal of Clinical Pathology* (1987) **87**, 129-139.
 35. Correa P, Cuello C and Duque E: Carcinoma and intestinal metaplasia of the stomach in Colombia migrants. *J Nat Cancer Inst* (1971) **44**, 297-306.
 36. Sipponen P, Kekki M and Siurala M: Atrophic chronic gastritis and intestinal metaplasia in gastric carcinoma. *Cancer* (1983) **52**, 1062-1068.
 37. Howard DR and Batsakis JG: Cytostructural localization of a tumor-associated antigen. *Science* (1980) **210**, 201-203.
 38. Bresalier RS, Rockwell RW, Dahiya R, Duh QY and Kim YS: Cell surface sialoprotein alterations in metastatic murine colon cancer cell lines selected in an animal model for colon cancer metastasis. *Cancer Res* (1990) **50**, 1299-1307.
 39. Irimura T, Carlson DA, Price J, Yamori T, Giavazzi R, Ota DM and Cleary KR: Differential expression of a sialoglycoprotein with an approximate molecular weight of 900,000 on metastatic human colon carcinoma cells growing in culture and in tumor tissues. *Cancer Res* (1988) **48**, 2353-2360.
 40. Yogeewaran G and Salk PL: Metastatic potential is positively correlated with cell surface sialylation of cultured murine tumor cell lines. *Science* (1981) **212**, 1514-1516.
 41. Itzkowitz SH, Bloom EJ, Kokal WA, Modin G, Hakomori S and Kim YS: Sialosyl-Tn. A novel mucin antigen associated with prognosis in colorectal cancer patients. *Cancer* (1990) **66**, 1960-1966.
 42. Wang BL, Springer GF and Carlstedt SC: Quantitative computerized image analysis of Tn and T (Thomsen-Friedenreich) epitopes in prognostication of human breast carcinoma. *J Histochem Cytochem* (1997) **45**, 1393-1400.
 43. Go MF: What are the host factors that place an individual at risk for *Helicobacter pylori*-associated disease? *Gastroenterology* (1997) **113**, S15-S20.
 44. Evans DG, Doyle J, Evans J, Moulds JJ and Graham DY: N-acetylneuraminylactose-binding fibrillar hemagglutinin of *Campylobacter pylori*: A putative colonization factor antigen. *Infect Immun* (1988) **56**, 2896-2906.
 45. Evans DG, Karjalainen TK, Doyle J, Evans DJ Jr, Graham DY and Lee CH: Cloning, nucleotide sequence, and expression of a gene encoding an adhesion subunit protein of *Helicobacter pylori*. *J Bacteriol* (1993) **175**, 674-683.
 46. Kjeldsen T, Clausen H, Hirohashi S, Ogawa T, Iijima H and Hakomori S: Preparation and characterization of monoclonal antibodies directed to the tumor-associated O-linked sialosyl-2-6 N-acetylgalactosaminyl epitope. *Cancer Res* (1988) **48**, 2214-2220.
 47. Usumoto R, Okada Y and Tsuji T: Effect of proton pump inhibitor, omeprazole, on expression of rat parietal cell specific carbohydrate antigen, type 2 chain N-acetylglucosamine. *Dig Dis Sci* (1994) **39**, 169-176.

Received January 30, 1998; accepted March 23, 1998.