

# *Acta Medica Okayama*

---

*Volume 56, Issue 3*

2002

*Article 6*

JUNE 2002

---

## A radiographic study of hip-joint alignment after prosthetic hip arthroplasty.

Isagi Mizuta\*

Hiroo Fujiwara<sup>†</sup>

Hajime Inoue<sup>‡</sup>

\*Okayama University,

<sup>†</sup>Mizushima Central Hospital,

<sup>‡</sup>Okayama University,

# A radiographic study of hip-joint alignment after prosthetic hip arthroplasty.\*

Isagi Mizuta, Hiroo Fujiwara, and Hajime Inoue

## Abstract

Postoperative hip alignment was studied on radiographs in cases of total hip arthroplasty (THA) and of Bipolar Head Prosthesis(BHP), both with MX-1. Postoperative anteroposterior-view radiographs of hip joints of patients with a normal hip joint on the unoperated side and without pelvic tilt were used. Thirty-nine THA patients (femoral neck fracture), 26 THA patients (osteonecrosis of the femoral head and osteoarthritis of the hip joint), and 34 BHP patients were selected for this study. Lines and points for measurement of 9 parameters were established on radiographs. The position of the greater trochanter upper edge is 6.5 mm (mean) superior to the femoral head center in the normal hip joint of Japanese, unlike in Caucasians. A femoral head prosthesis should be inserted so that its center and the greater trochanter upper edge are level in order to equalize leg lengths. In BHP cases, the insertion is made so that the greater trochanter upper edge is approximately 4-mm superior to the center of the prosthesis. For further securing of the stem and to equalize leg lengths, stems should be available in 11 diameters from 5-15 mm in 1-mm increments. Postoperative hip alignment in MX-1 THA cases was found to be satisfactory.

**KEYWORDS:** total hip arthroplasty, hip alignment, radiographic study, MX-1

---

\*PMID: 12108587 [PubMed - indexed for MEDLINE]

Copyright (C) OKAYAMA UNIVERSITY MEDICAL SCHOOL

*Original Article*

## A Radiographic Study of Hip-Joint Alignment after Prosthetic Hip Arthroplasty

Isagi Mizuta<sup>a\*</sup>, Hiroo Fujiwara<sup>b</sup>, and Hajime Inoue<sup>a</sup>

<sup>a</sup>Department of Orthopaedic Surgery, Okayama University Medical School, Okayama 700-8558, Japan, and

<sup>b</sup>Department of Orthopaedic Surgery, Mizushima Central Hospital, Kurashiki 711-8064, Japan

Postoperative hip alignment was studied on radiographs in cases of total hip arthroplasty (THA) and of Bipolar Head Prosthesis (BHP), both with MX-1. Postoperative anteroposterior-view radiographs of hip joints of patients with a normal hip joint on the unoperated side and without pelvic tilt were used. Thirty-nine THA patients (femoral neck fracture), 26 THA patients (osteonecrosis of the femoral head and osteoarthritis of the hip joint), and 34 BHP patients were selected for this study. Lines and points for measurement of 9 parameters were established on radiographs. The position of the greater trochanter upper edge is 6.5 mm (mean) superior to the femoral head center in the normal hip joint of Japanese, unlike in Caucasians. A femoral head prosthesis should be inserted so that its center and the greater trochanter upper edge are level in order to equalize leg lengths. In BHP cases, the insertion is made so that the greater trochanter upper edge is approximately 4-mm superior to the center of the prosthesis. For further securing of the stem and to equalize leg lengths, stems should be available in 11 diameters from 5-15 mm in 1-mm increments. Postoperative hip alignment in MX-1 THA cases was found to be satisfactory.

**Key words:** total hip arthroplasty, hip alignment, radiographic study, MX-1

In recent years, total hip arthroplasty (THA) in cases of hip disease and Bipolar Head Prosthesis (BHP) in cases of femoral neck fractures have become common surgical procedures. However, insertion of a femoral prosthesis may result in altered hip alignment and affect hip-joint function, eventually causing postoperative pain, limping, or decreased durability of total hip prostheses or hip components. It is ideal for these prostheses to be implanted in a manner resulting in normal alignment or alignment similar to that of the contralateral unaffected hip. Preoperative planning is performed to estimate the size of the implant to be used with reference to the

alignment of the unaffected side. In many cases, however, the predetermined size turns out to be inadequate intraoperatively, resulting in abandonment of the preoperative plan. It is however, difficult to replan and reselect a prosthetic design and/or material, possibly explaining the relatively few reports regarding postoperative hip alignment. In the present study, radiographs of hip joint of patients who had undergone a THA or BHP, both with MX-1, were taken for evaluation of the alignment in comparison with that of the unaffected side of the hip joint. The MX-1 is a prosthesis developed based on a skeletal study of Japanese [1].

### Subjects and Methods

THA with MX-1 was performed on 103 patients

Received February 2, 2001; accepted January 16, 2002.

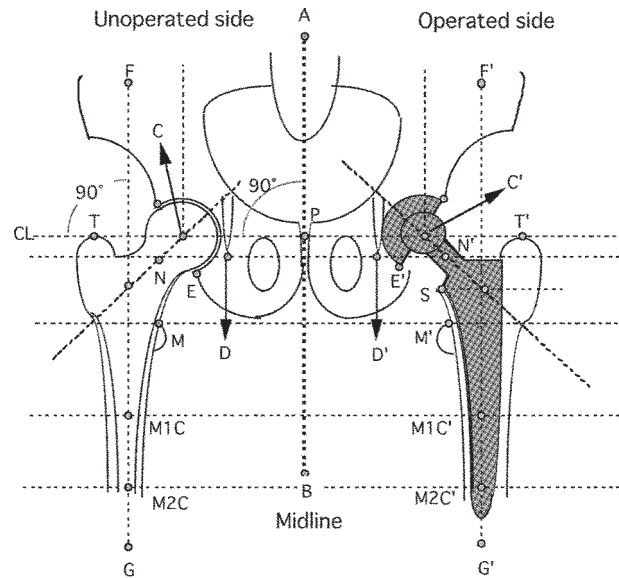
\*Corresponding author. Phone: +81-87-833-1551; Fax: +81-87-833-0933  
E-mail: rc45@mac.com (I. Mizuta)

between January 1989 and March 1997. BHP surgery with MX-1 was performed on 45 patients between January 1993 and July 1995. Among the anteroposterior view radiographs of bilateral hip joints of these patients, those with normal alignment on the unaffected side and without pelvic tilting were chosen for evaluation. These criteria were met by 39 of the THA patients who underwent the surgery for femoral neck fracture (fracture subgroup), 26 of these who underwent that for osteonecrosis of the femoral head and osteoarthritis of the hip joint (OA subgroup), and 34 of the BHP patients, (BHP group). The fracture subgroup consisted of 5 men and 34 women (mean age: 75.1 years), the OA subgroup 2 men and 24 women (mean age: 66.9 years), and the BHP group 10 men and 24 women (mean age: 79.1 years). All the BHP patients underwent this procedure for femoral neck fracture. The following points and lines were established, and measurements were made on anteroposterior-view radiographs of hip joints.

#### Lines and points for measurement (Fig. 1)

##### Measurements

1. Vertical change in the center of the femoral head. Operated-side center of femoral head:  $C'$ , relative to unoperated-side center of the femoral head:  $C$ , along a vertical axis.
2. Horizontal distance between the center of the femoral head and the midline of the body. The distance between the midline:  $AB$ , and the operated-side center of the femoral head:  $C'$  (unoperated side:  $C$ ).
3. Position of the cup lower edge relative to the teardrop lower edge in THA. Operated- side of the teardrop lower edge:  $D'$  (unoperated side:  $D$ ), relative to the cup lower edge:  $E'$  (unoperated side of the acetabulum edge:  $E$ ), along a vertical axis.
4. Angle of inclination of the cup in THA. BHP is excepted for the movability head.
5. Center-edge angle in THA. On the operated side, measurements were made with 2 edges, the upper edge of the lateral acetabulum and the upper edge of the latter cup. BHP is excepted for the movability head.
6. Leg-length difference at the height of the lesser trochanter. Unoperated-side lesser trochanter:  $M$ , relative to the operated-side lesser trochanter:  $M'$ , along a vertical axis.
7. Changes in the offset. Operated and unoperated sides were measured.
8. Height of the greater trochanter relative to the center



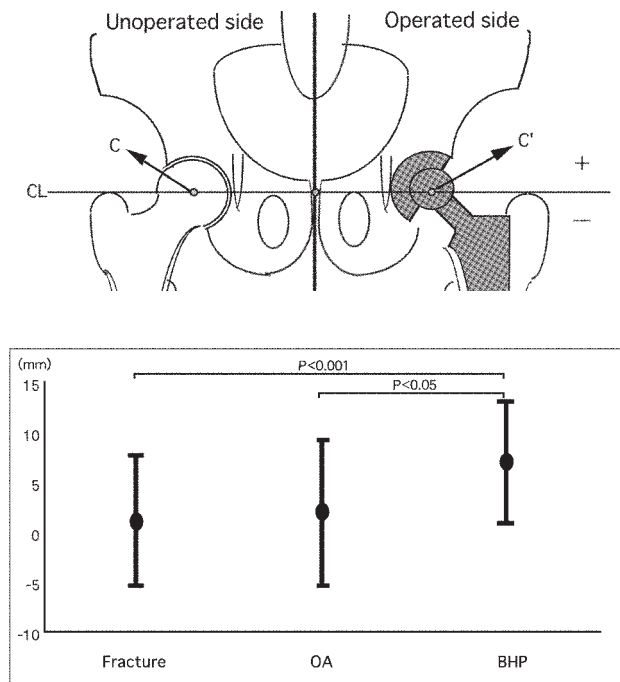
**Fig. 1** Lines and points for measurement. The following points and lines were established, and measurements were made on anteroposterior-view radiographs of hip joints.  $AB$ , Midline;  $C$ ,  $C'$ : Center of the femoral neck ( $C$ , on the unoperated side;  $C'$ , on the operated side);  $CL$ , Baseline (perpendicular to  $AB$ );  $D$ ,  $D'$ : Lower edge of teardrop ( $D$ , on the unoperated side;  $D'$ , on the operated side);  $E$ ,  $E'$ : Lower edge of lateral acetabulum ( $E$ , on the unoperated side;  $E'$ , on the operated side);  $FG$ , Femoral axis ( $F'G'$ , on the operated side);  $M$ ,  $M'$ : Upper edge of lesser trochanter ( $M$ , on the unoperated side;  $M'$ , on the operated side);  $MIC$ ,  $MIC'$ : Intramedullary cavity center 120 mm distal to  $T$  ( $MIC$ , on the unoperated side;  $MIC'$ , on the operated side);  $M2C$ ,  $M2C'$ : Intramedullary cavity center 180 mm distal to  $T$  ( $M2C$ , on the unoperated side;  $M2C'$ , on the operated side);  $N$ ,  $N'$ : Center of narrowest part of neck ( $N$ , on the unoperated side;  $N'$ , on the operated side);  $S$ , Medial upper edge of stem;  $T$ ,  $T'$ : Upper end of greater trochanter ( $T$ , on the unoperated side;  $T'$ , on the operated side).

of the femoral head. Operated- side center of femoral head:  $C'$  (unoperated side:  $C$ ), relative to the greater trochanter of the top:  $T'$  (unoperated side:  $T$ ), along the vertical axis.

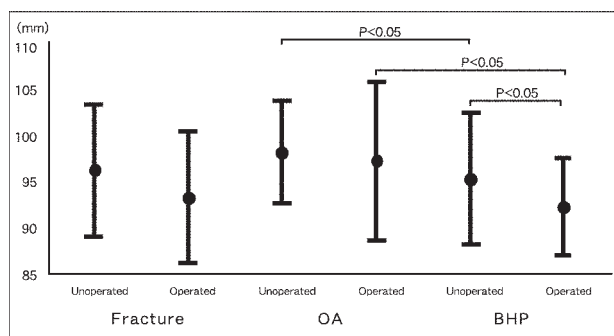
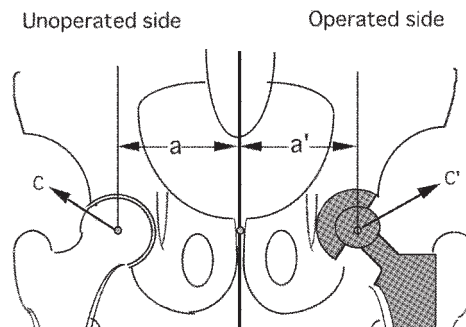
9. Neck-shaft angle. Operated and unoperated sides were measured.

##### Statistical Analysis

An unpaired  $t$ -test (Stat View 4.5 for Macintosh) was used for comparative analysis of every 2 unpaired groups.



**Fig. 2** Vertical change in the center of femoral head. In the THA group, the height of the femoral head center was nearly the same as that of the unoperated side. In the BHP group, however, the femoral head center was 6.9 mm higher. The difference between the BHP group and THA group was significant (fracture subgroup,  $P < 0.001$ ; OA subgroup,  $P < 0.05$ ). Values are mean  $\pm$  SD.



**Fig. 3** Horizontal distance between the center of femoral head and the midline of the body. The distance closed to the midline of the body on the operated sides in all groups. The difference between the operated and unoperated sides was significant ( $P < 0.05$ ) in BHP subgroup only. Values are mean  $\pm$  SD.

## Results

### Cup side

#### 1. Vertical change in the center of the femoral head (Fig. 2)

The mean change from the unoperated head center was +0.9 mm in the fracture subgroup, +1.8 mm in the OA subgroup, and +6.9 mm in the BHP group. The center of the operated femoral head was nearly the same as that of the unoperated one in THA patients. BHP resulted in positioning of the femoral head center 6.9 mm superior to the unoperated side. The difference between the BHP group and THA group was significant (fracture subgroup:  $P < 0.001$ , OA subgroup:  $P < 0.05$ ).

#### 2. Horizontal distance between the center of the femoral head and the midline of the body (Fig. 3)

The distance was nearly the same on the operated and unoperated sides in both THA groups. BHP subgroup

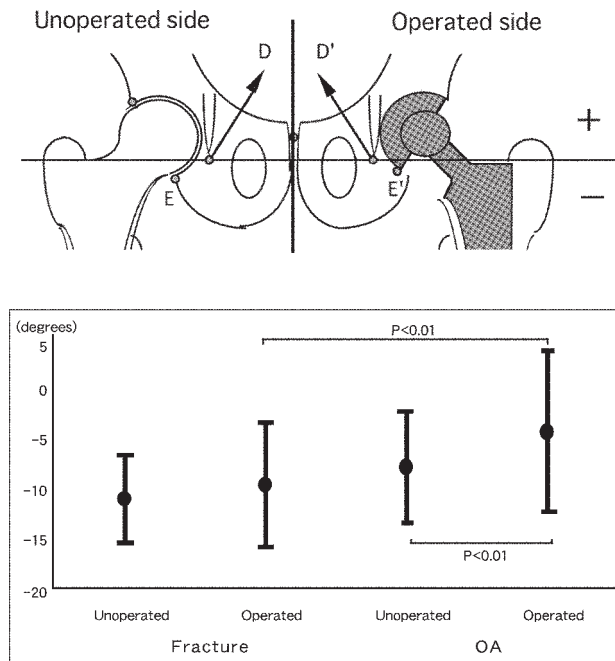
results were significant ( $P < 0.05$ ) between unoperated and operated sides.

#### 3. Position of the cup lower edge relative to the teardrop lower edge in THA (Fig. 4)

On the unoperated side, the cup position relative to the teardrop was similar between fracture and OA subgroups, being -11.3 mm (fracture) and -8.1 mm (OA), and similarly, -9.8 mm and -4.6 mm, respectively, on the operated side. The cup of the OA subgroup was slightly higher relative to the teardrop on the operated side. The differences in were significant ( $P < 0.01$ ) in the OA subgroup only.

#### 4. Angle of inclination of the cup in THA (Fig. 5)

The intended angle of 40 degrees was nearly obtained, being 38 degrees in the fracture subgroup and 36 degrees in the OA subgroup. The difference between the fracture subgroup and the OA subgroup was not significant.



**Fig. 4** Position of the cup lower edge relative to the teardrop lower edge in THA. In fracture subgroup, the cup height of the lower edge was nearly as that of the unoperated side. There was not significant. The difference between the operated and unoperated sides was significant ( $P < 0.01$ ) in OA subgroup. BHP is excepted for movability head. Values are mean  $\pm$  SD.

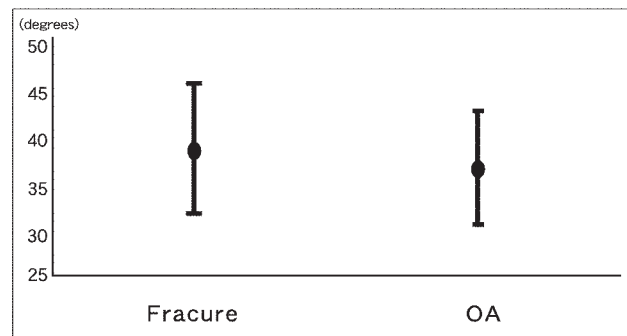
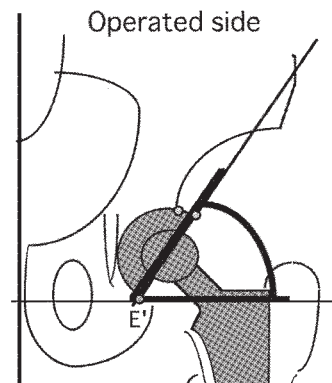
##### 5. Center-edge angle in THA (Fig. 6)

On the unoperated side, the mean was slightly smaller in the OA subgroup (fracture: 39 degrees, OA: 33 degrees). On the operated side, measurements were made with 2 edges, the upper edge of the latter acetabulum and the upper edge of the lateral cup. The center-acetabular edge angle was similar between unoperated and operated sides in both subgroups, with a significant ( $P < 0.01$ ) difference in the OA subgroup only. The center-cup edge angle was greater on the operated side by 16 degrees in the fracture subgroup and by 24 degrees in the OA subgroup.

##### Stem side

###### 1. Leg-length difference at the height of the lesser trochanter (Fig. 7)

The leg on the unoperated side was slightly longer in the THA group, with the mean difference being +3.1 mm in the fracture subgroup, +5.3 mm in the OA subgroup, and -0.6 mm in the BHP group. There was



**Fig. 5** Angle of inclination of the cup in THA. The difference between the fracture and OA subgroups was not significant. BHP is excepted for movability head. Values are mean  $\pm$  SD.

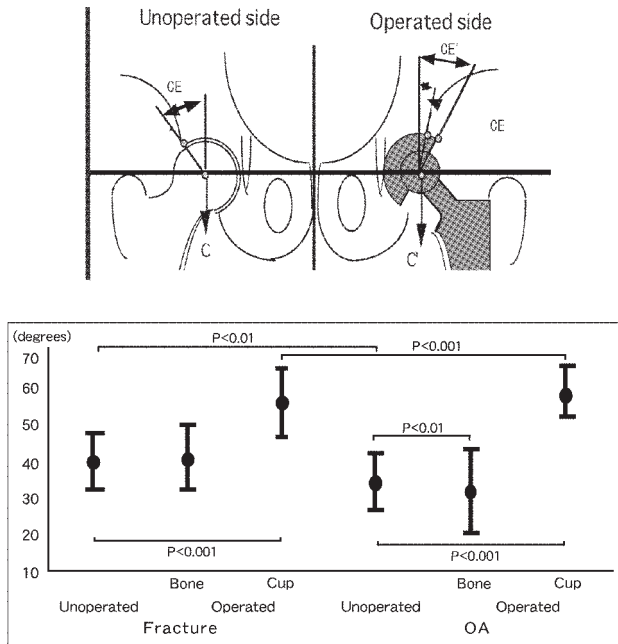
a significant ( $P < 0.05$ ) difference between the OA subgroup and BHP group.

###### 2. Change in the offset (Fig. 8)

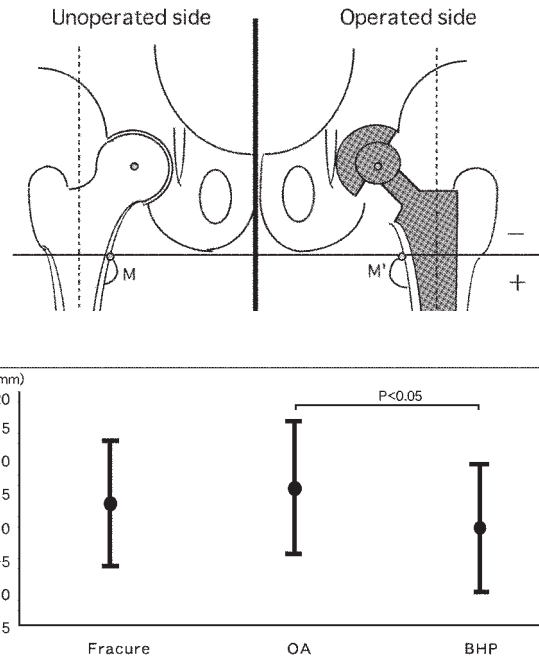
Rotation in the neck-shaft angle, the angle of anteversion, etc. of the hip joint can lead to errors in offset measurements. In the present study, the mean offset measurement of the fracture subgroup was similar between operated and unoperated sides. A significant ( $P < 0.01$ ) difference was noted in the OA subgroup and the BHP group (9 mm and 6 mm less, respectively, on the operated side).

###### 3. Height of the greater trochanter relative to the center of the femoral head (Fig. 9)

The greater trochanter was positioned superior to the center of the femoral head on the unoperated side in all groups. On the operated side, the greater trochanter was -3.4 mm (mean) inferior to the center of the head in the OA subgroup.



**Fig. 6** Center-edge angle in THA. Measurements were made with 2 edges, the upper edge of the latter acetabulum and the upper edge of the lateral cup on the operated side. The difference between the operated and unoperated sides was significant ( $P < 0.001$ ) in each group. BHP is excepted for movability head. Values are mean  $\pm$  SD.



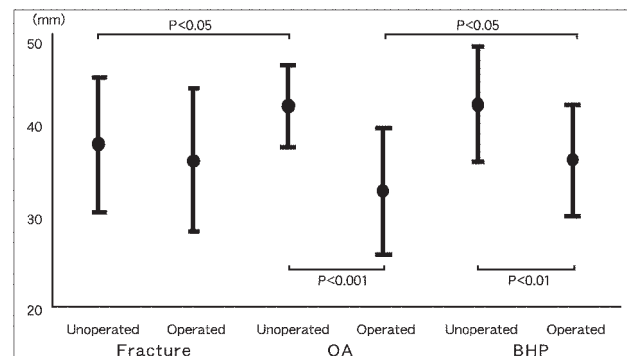
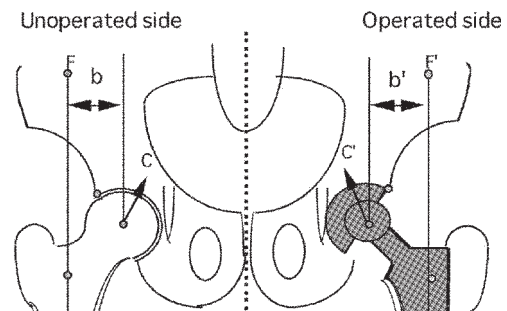
**Fig. 7** Leg length difference at the height of lesser trochanter. In the BHP group only, the leg length was  $-0.6$  mm shorter than on the unoperated side. There was a significant ( $P < 0.05$ ) difference between OA subgroup and BHP group. Values are mean  $\pm$  SD.

4. Neck-shaft angle (Fig. 10)

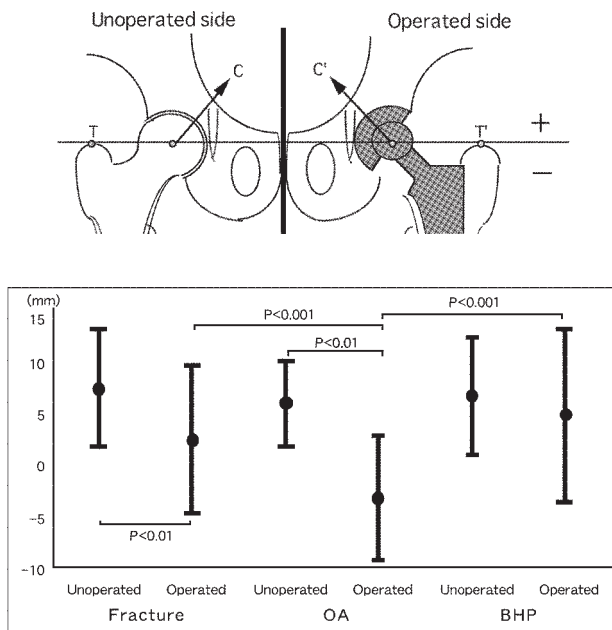
The mean neck-shaft angle was greater on the operated side by 8 degrees in the fracture subgroup, 12 degrees in the OA subgroup, and 10 degrees in the BHP group. The difference between operated and unoperated sides was significant ( $P < 0.01$ ) in each group.

**Discussion**

Achieving alignment of a normal hip joint is a factor having a large effect on postoperative outcomes in THA and BHP. In the present study, the postoperative alignment was evaluated in patients who underwent these surgical procedures in comparison with normal hip alignment. Many reports on clinical use of the Moore-type

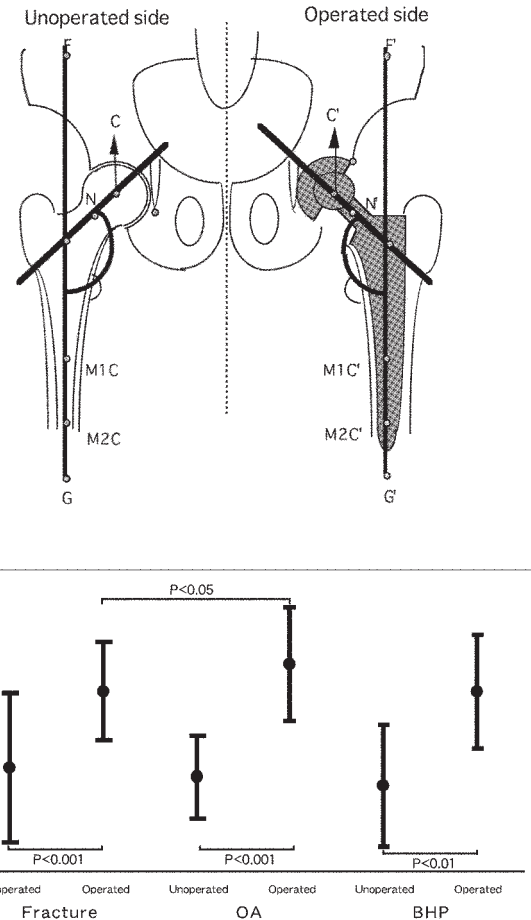


**Fig. 8** Change in the offset. The fracture subgroup was similar between operated and unoperated sides. There was, however, a significant difference between operated and unoperated sides in the OA subgroup ( $P < 0.001$ ) and BHP group ( $P < 0.01$ ). Values are mean  $\pm$  SD.



**Fig. 9** Height of the greater trochanter relative to the center of the femoral head. In the OA subgroup only, the greater trochanter was  $-3.4$  mm inferior to the center of the head on the operated side. There was significant difference between operated and unoperated sides in the fracture subgroup ( $P < 0.01$ ) and the OA subgroup ( $P < 0.01$ ). Values are mean  $\pm$  SD.

femoral-head prosthesis [2] and of the Charnley hip arthroplasty prosthesis [3] have been published in Japan. Also, with foreign-made implants dominant among other types of prostheses [4, 5], the use of Japanese devices has been limited to patients treated at universities that have developed these devices or their affiliates [6, 7]. The MX-1 is one of a few domestic prostheses relatively often applied in Japan. This led our study to evaluate the alignment on postoperative x-ray in cases of MX-1 THA and BHP. One of the most significant factors in x-ray measurements is the position of the femur on the X-ray. The exposure is generally centered over the pubic symphysis, allowing a distance of 1 m between the x-ray tube and the film, positioning the hip joint at a neutral position flexing the bilateral knee at a  $90^\circ$ , and lowering the limbs perpendicular to the floor [8]. This allows the posterior aspect of the condyles of the bilateral femurs to be level, *i.e.*, the standard position of the femur. The next important factor is the tilt of the pelvis. Seelen *et al.*, with the aid of a table top with wiremarkers and a fixed 30-degree wedge to allow for reproducible positioning under fluoroscopic control, have made and examined



**Fig. 10** Neck-shaft angle. The difference between operated and unoperated sides was significant ( $P < 0.001$ : fracture subgroup, OA subgroup.  $P < 0.01$ : BHP group) in each group. Values are mean  $\pm$  SD.

pelvic and spot films [9]. Using their method, standard position of the pelvis is achieved with a bilateral anterior superior iliac spine, with the anterior aspect of the pubic symphysis kept level. However, visualization of the pelvis and femurs in this position is not possible; as such, errors are caused in radiographic described measurements regarding hip alignment due to the femoral and pelvic positioning. The technique described above, however, is at present the best possible way of carrying out x-ray imaging of living body. Although reports regarding post-THA evaluation of either cups ("migration", "cleavage") or stems ("loosening", "sinking") using plain radiographs appear occasionally [10-12], few reports are available regarding measurement and evaluation of post-THA alignment to the best of our knowledge.



Changes in the position of the cup are discussed first. It is ideal for the acetabular component to be implanted in an appropriate manner that obtains primary acetabulum position. One index for primary acetabulum position is the femoral head center, on the operated side as well as the center of the cup. Massin *et al.* have estimated that the best landmark for measuring location along a vertical axis is the distance between the center of the cup and the teardrop line. The measurement for cup location along a horizontal axis is the distance between the center of the cup and vertical line through the teardrop [13]. However, the teardrop is sometimes not visible, and the result is not standardized. The horizontal distance from the midline of the trunk to the femoral head center was found to be nearly the same between operated and unoperated sides in both the THA and BHP subgroups. Regarding the vertical aspect in the fracture and OA subgroups, the center of the femoral head prosthesis was slightly higher than the unoperated side. Among the BHP subgroup, the center of the femoral head prosthesis was 6.9 mm (mean) higher; this degree of difference, resulting from the BHP structure, is deemed unavoidable and should be taken into consideration in preoperative planning. For MX-1, a 40-degree inclination of the cup from the horizontal plane is considered ideal. In this study, the mean angle of inclination was 38 degrees in the fracture subgroup and 36 degrees in the OA subgroup, which seems to be satisfactory in general. The present results fall within the "safe zone" (30–50 degrees) reported by Lewinnek *et al.* [14], and thus are considered to be satisfactory in terms of dislocation risk. We also have additional data to demonstrate the proper positioning of the cup in line with the ideal 40 degrees of inclination on the operated side. With regard to the center-edge angle, it was shown that the mean angle (39 degrees) on the unoperated side in the fracture subgroup was close to the mean angle (36 degrees). In contrast, the mean center-edge angle on the unoperated side in the OA subgroup was 33 degrees, 6 degrees smaller than that of patients without OA. This difference in angle suggests an indication of shelf plasty for installation of the cup. More specifically, shelf plasty for acetabular dysplasia seems to be possible if the center-edge angle on the affected side is similar to that of the unaffected side, *i.e.*, no less than 40 degrees. Given the above, bone grafting achieving at least a 40-degree center-edge angle seems to be needed in acetabuloplasty for installation of a cup in the OA subgroup.

Data regarding the relative position of the cup lower edge and teardrop lower edge are thought to be useful in optimizing cup position in patients with bilateral OA. It was found in the present study that the acetabular lower edge was positioned 8–11 mm (mean) inferior to the teardrop lower edge on the unoperated side in both subgroups. On the operated side, the corresponding value was 9.8 mm in the fracture subgroup, similar to the unoperated side, and 4.6 mm in the OA subgroup, making it higher than or the unoperated side. It is ideal for cup prostheses to be implanted in a manner that obtains a primary acetabulum. However, if the high dislocation (acetabulum) is brought down to the primary acetabulum, the femur may have to be shortened to reduce the risk of injury to the sciatic nerve. Generally, it is inappropriate to try to lengthen the femur more than 4 centimeters, as doing so increases the risk of sciatic nerve palsy [15]. The angle and size of the cup to be implanted should be considered in optimizing cup position in cases of bilateral OA.

With regard to measurements made on the stem side, differences in leg-length can be determined on x-ray by comparing the height of the lesser trochanter between sides. By this method, the mean leg-length difference on the operated side was estimated to be +3.1 mm in the fracture subgroup, +5.3 mm in the OA subgroup, and –0.6 mm in the BHP group. The leg on the operated side was longer in the THA group. The above results seem to be attributable to the use of the largest possible stem for THA and the availability of stems in –2 mm increments. For BHP, one of the causes of the leg-length difference observed is thought to be the center of the femoral head being at a higher position relative to THA cases due to the prosthetic structure, as noted above. The mean offset was 38 mm on the unoperated side in the fracture subgroup. On the operated side the measurement result was similar to fracture subgroup in contrast to the differences of 9 mm and 6 mm in the OA subgroup and the BHP group, respectively. This offset is related to the neck-shaft angle. A greater degree of stem anteversion appears to have been responsible for the smaller offset value on the operated side in the OA subgroup. In cases of patients with prostheses, it is not always true that a longer offset results in better clinical outcomes. This variability can be attributed to Pauwels principle of the lever arm [16], stating that there is less weight bearing on the femoral head in the coxa vara than in the coxa valga, not applying to prostheses. More

specifically, with a longer offset, the stem is exposed to greater inward stress toward the midline of the body in the medullary cavity.

Measurements regarding the relative position of the upper edge of the greater trochanter and the center of the femoral head were as follows. Among the many approaches to the hip, we applied the transgluteal approach [17]. The advantage of this approach is a better view of the acetabular rim, prevention of gluteal muscle damage, and protection of the superior gluteal nerve, without osteotomy of the trochanter. In cases of osteotomy and subsegment reattachment of the trochanter, the primary position of the upper edge of the greater trochanter can be changed. It is also important to obtain measurements regarding the relative position of the upper edge of the greater trochanter and the center of the femoral head. On the unoperated side, the greater trochanter was at a higher position by 7.2 mm in the fracture subgroup, by 5.8 mm in the OA subgroup, and by 6.5 mm in the BHP group. As compared with the alignment in Caucasians [8], with the edge of the greater trochanter being of the same height as the center of the femoral head, it appears that the greater trochanter is at a higher position in Japanese. On the operated side, it was found that the greater trochanter was positioned 2.3 mm higher in the fracture subgroup and 4.7 mm in the BHP group, but 3.4 mm lower in the OA subgroup. These results were compared with the leg-length inequalities noted above and relative positions to achieve an equalization of leg-length ( $T \pm M'$ ). According to this computation, the upper edge of the greater trochanter should have been superior to the center of the femoral head by 0.8 mm in the fracture subgroup, 1.9 mm in the OA subgroup, and 4.1 mm in the BHP group. Although these values, all less than 5 mm, are not clinically significant, it is thought to be a correct approach to insert the stem so that the center of the femoral head is at the same height as the upper edge of the greater trochanter [18]. The value for the BHP subgroup was greater because of the larger vertical change in the height of the femoral head center.

The mean shaft-neck angle on the unoperated side of all groups was approximately 130 degrees. On the operated side, the mean angle was 139 degrees in the fracture subgroup and 142 degrees in the OA subgroup. With the neck-shaft angle of the MX-1 template being 135 degrees, a greater degree of anteversion results in many cases. These data, together with the mean neck-shaft angle of approximately 130 degrees on the unoperated

side, offset-reduced by 10 mm, and the size of the stem influencing leg-length differences, suggest that, to further improve prosthetic design, it would be ideal to make stems available in 11 sizes from 5 to 15 mm in diameter in 1-mm increments for more suitable intramedullary placement. As such, the neck-shaft angle, leg-length differences, stem size and offset data indicate the need for further design improvements. In general, however, satisfactory hip alignment appears to be obtained with MX-1.

## References

1. Kajiki Y, Fujiwara H, Inoue M, Inoue T, Takahashi Y and Sunami Y: MX-1 Total Hip Prosthesis for Coxarthrosis. *Chugoku Shikoku Seikeigeka (The Journal of the Chugoku-Shikoku Orthopedic Association)* (1993) **5**, 287-291 (in Japanese).
2. Moore AT: Metal hip joint. A case report. *Clin Orthop* (1970) **72**, 3-6.
3. Charnley J: Total hip replacement by low-friction arthroplasty. *Clin Orthop* (1970) **72**, 7-21.
4. Müller ME: Total hip prostheses. *Clin Orthop* (1970) **72**, 46-68.
5. Ring RA: Complete replacement arthroplasty of the hip by Ring prosthesis. *J Bone Joint Surg* (1968) **50**, 720.
6. Nishio A, Eguchi M and Kaibara N: Socket and cup surface replacement of the hip. *Clin Orthop* (1978) **134**, 53-58.
7. Miyanaga Y, Tagawa H, Ninomiya S, Katoh F, Tateishi T and Shirasaki Y: A new socket design for the dysplastic acetabulum in total hip replacement. *Clin Orthop* (1980) **149**, 194-200.
8. Müller ME: Die Hüftnahen Femurosteotomien. Georg Thieme, Stuttgart (1957) pp 1-50.
9. Seelen JL, Bruijn JD, Hansen BE, Kingma LM and Bloem JL: Reproducible radiographs of acetabular prostheses. A method assessed in 35 patients. *Acta Orthop Scand* (1994) **65**, 258-62.
10. DeLee JG and Charnley J: Radiological demarcation of cemented sockets in total hip replacement. *Clin Orthop* (1976) **121**, 20-32.
11. Salvati EA, Im VC, Aglietti P and Wilson PD Jr: Radiology of total hip replacements. *Clin Orthop* (1976) **121**, 74-82.
12. Messieh M, Mattingly DA, Turner RH, Scott R, Fox J and Slater J: Wear debris from bipolar femoral neck-cup impingement. A cause of femoral stem loosening. *J Arthroplasty* (1994) **1**, 89-93.
13. Massin P, Schmidt L and Engh CA: Evaluation of cementless acetabular component migration. An experimental study. *J Arthroplasty* (1989) **4**, 245-251.
14. Lewinnek GE, Lewis JL, Tarr R, Compere CL and Zimmerman JR: Dislocations after total hip-replacement arthroplasties. *J Bone Joint Surg Am* (1978) **60**, 217-220.
15. Cameron HU, Eren OT and Solomon M: Nerve injury in the prosthetic management of the dysplastic hip. *Orthopedics* (1998) **21**, 980-981.
16. Pauwels F: Biomechanics of the locomotor Apparatus. Springer-Verlag, New York (1980) pp 76-105.
17. Bauer R, Kerschbaumer F, Poisel S and Oberthaler W: The transgluteal approach to the hip joint. *Arch Orthop Trauma Surg* (1979) **95**, 47-49.
18. Fujiwara H, Sunami Y and Nagano K: Preoperative planning for Müller total hip replacements. *Rinsho Seikeigeka (Orthopedic Surgery)* (1977) **12**, 1069-1076 (in Japanese).