

Acta Medica Okayama

Volume 35, Issue 3

1981

Article 2

JUNE 1981

A new adrenal computer imaging technique using dual-radioisotopes.

Teruhisa Ohashi* Massaki Morioka[†] Naoki Mitsuata[‡]
Teruaki Akaeda** Hiroyuki Ohmori^{††}

*Okayama University,

[†]Okayama University,

[‡]Okayama University,

**Okayama University,

^{††}Okayama University,

A new adrenal computer imaging technique using dual-radioisotopes.*

Teruhisa Ohashi, Massaki Morioka, Naoki Mitsuata, Teruaki Akaeda, and Hiroyuki Ohmori

Abstract

Computer processed adrenal imaging using dual-radioisotopes, 6 beta-iodomethyl-19-nor-cholest-5(10)-en-3 beta-ol-131I and 99mTc-phytate was performed in 12 patients with primary aldosteronism and 4 with Cushing's syndrome due to adrenocortical tumor. Adreno-photoscanning and hepato-photoscanning were performed in the same position 2-4 days following intravenous administration of radiocholesterol. The scintigraphic information was stored on cassettes and scan subtraction and a digital-computer method for data smoothing were performed on an oscilloscope. The tumor site could be determined in all cases until day 4 by this computer processed image.

KEYWORDS: new adrenal imaging technique, dual radioisotopes, adrenocortical tumor.

*PMID: 6457507 [PubMed - indexed for MEDLINE]

Copyright (C) OKAYAMA UNIVERSITY MEDICAL SCHOOL

A NEW ADRENAL COMPUTER IMAGING TECHNIQUE USING DUAL-RADIOISOTOPES

Teruhisa OHASHI, Masaaki MORIOKA, Naoki MITSUHATA,
Teruaki AKAEDA and Hiroyuki OHMORI

Department of Urology, Okayama University Medical School, Okayama 700, Japan
(Director: Prof. H. Ohmori)

Received January 30, 1981

Abstract. Computer processed adrenal imaging using dual-radioisotopes, 6 β -iodomethyl-19-nor-cholest-5(10)-en-3 β -ol-¹³¹I and ^{99m}Tc-phytate was performed in 12 patients with primary aldosteronism and 4 with Cushing's syndrome due to adrenocortical tumor. Adreno-photoscanning and hepato-photoscanning were performed in the same position 2-4 days following intravenous administration of radiocholesterol. The scintigraphic information was stored on cassettes and scan subtraction and a digital-computer method for data smoothing were performed on an oscilloscope. The tumor site could be determined in all cases until day 4 by this computer processed image.

Key words : new adrenal imaging technique, dual radioisotopes, adrenocortical tumor.

The use of scintigraphy and venography has greatly improved the diagnosis of adrenal tumors. Usual scintigraphy is more sensitive than retroperitoneal pneumography and has fewer complications than venography, but diagnosis takes longer and small adrenocortical tumors are difficult to visualize. We developed a new technique for early diagnosis of small adrenocortical tumors employing the dual-radioisotope techniques and digital image-subtraction methods used in pancreas visualization (1,2).

MATERIALS AND METHODS

Patients with primary aldosteronism. Ten female and two male patients between 29 and 56 years of age were examined (Table 1-a). Hypertension (160-230 mmHg systolic), muscle weakness, headaches and paresthesia were observed in most patients. Serum potassium levels were low, between 2.1-3.2 mEq/l. Plasma renin activity levels were low at 0.05-0.94 ng/ml/h at rest, while plasma aldosterone concentrations were high at 28.0-205 ng/dl.

Patients with Cushing's syndrome due to adrenocortical tumor. The patients were four females between 25 and 44 years of age with symptoms such as moon face, obesity, amenorrhea and hypertension (160-198 mmHg systolic) (Table 1-b). The plasma cortisol levels at 9 a.m. were increased to 29.5-34.5 μ g/dl, while the plasma ACTH levels were suppressed to undetectable levels (under 25 pg/ml) in all cases. Urinary 17-OHCS excretion was neither suppressed with 16mg of dexamethasone nor increased with 3g of

metryrapone.

Methods of adrenal imaging and adrenal angiography. Five drops of Lugol's iodine solution was given b.i.d. prior to injection of the radioactive tracer and continued for six days to block thyroid accumulation of ^{131}I . Then, a tracer dose of 0.3-0.4 mCi. ($0.6 \mu\text{Ci}/\text{kg}/\text{b.w.}$) of 6 β -iodomethyl-19-nor-cholest-5(10)-en-3 β -ol- ^{131}I (NCL-6- ^{131}I , Daiichi Radioisotope Laboratories, Tokyo) was injected intravenously (Fig. 1). On day 2 to 4 after tracer administration, adreno-photoscanning was conducted from the anterior side using a gamma camera (Nuclear-Chicago Corp.) (Fig. 2-A). Hepato-photoscanning was also conducted in the same position after an intravenous injection of 3.0 mCi of $^{99\text{m}}\text{Tc}$ -phytate (Daiichi Radioisotope Laboratories, Tokyo) (Fig. 2-B). These ^{131}I and $^{99\text{m}}\text{Tc}$ images were

TABLE 1-A. CLINICAL SYMPTOMS AND LABORATORY DATA IN 12 PATIENTS WITH PRIMARY ALDOSTERONISM

| Case no | Patients | Age | Sex | Clinical symptom | Blood pressure | Serum K | PRA | PA |
|---------|----------|-----|-----|---|----------------|---------|------|------|
| 1. | M.K. | 29 | F | Headache, paralysis | 210/130 | 2.9 | 0.10 | 74.0 |
| 2. | C.T. | 29 | F | Paralysis, muscle weakness | 200/102 | 2.8 | 0.36 | 45.8 |
| 3. | M.S. | 39 | F | Headache, paralysis, visual disturbance | 170/100 | 3.2 | 0.05 | 28.0 |
| 4. | M.M. | 40 | F | Paralysis, muscle weakness | 200/108 | 2.4 | 0.94 | 76.5 |
| 5. | E.I. | 32 | F | Headache, paralysis, edema | 172/120 | 2.5 | 0.1 | 36.0 |
| 6. | K.U. | 53 | F | Headache, polyuria | 220/110 | 2.8 | 0.24 | 134 |
| 7. | T.N. | 49 | F | Paralysis, edema | 200/100 | 2.1 | 0.80 | 42.0 |
| 8. | T.O. | 48 | M | Palpitation | 220/130 | 3.0 | 0.30 | 40.0 |
| 9. | Y.A. | 37 | F | Headache, paralysis, muscle weakness | 160/110 | 2.4 | 0.30 | 42.0 |
| 10. | K.T. | 37 | F | Paralysis, muscle weakness | 170/94 | 2.6 | 0.25 | 205 |
| 11. | T.I. | 54 | M | Headache, paralysis, muscle weakness | 230/130 | 2.6 | 0.40 | 40.1 |
| 12. | Y.Y. | 56 | F | Muscle weakness, edema | 175/90 | 2.5 | 0.50 | 32.0 |

PRA : Plasma renin activity, PA : Plasma aldosterone

TABLE 1-B. CLINICAL SYMPTOMS AND LABORATORY DATA IN 4 PATIENTS WITH CUSHING'S SYNDROME DUE TO ADRENOCORTICAL TUMOR

| Case no | Patients | Age | Sex | Clinical symptom | Blood pressure | P-F | U-17 OHCS | P-ACTH |
|---------|----------|-----|-----|---|----------------|------|-----------|--------|
| 13. | H.M. | 30 | F | Moon face, obesity, buffalo hump | 186/100 | 29.5 | 17.84 | n.d. |
| 14. | T.M. | 39 | F | Moon face, obesity, buffalo hump, amenorrhea, muscle weakness | 198/110 | 31.9 | 15.11 | n.d. |
| 15. | E.H. | 25 | F | Moon face, obesity, amenorrhea | 180/130 | 34.5 | 20.0 | n.d. |
| 16. | T.O. | 44 | F | Moon face, obesity, buffalo hump, amenorrhea | 160/102 | 32.2 | 17.3 | n.d. |

P-F: Plasma cortisol, U-17 OHCS: Urinary 17-hydroxy corticosteroid, P-ACTH: Plasma adrenocorticotrophic hormone

displayed as a 64×64 matrix on an oscilloscope, photographed and stored digitally on cassette. The region of interest specific to the liver was defined by profile display of the liver image with ^{99m}Tc (Fig. 2-C) and average $^{131}\text{I}/^{99m}\text{Tc}$ ratios for the matrix subtraction were determined after ^{131}I and ^{99m}Tc data were transferred from cassette to TOSBAC 40 computer (Toshiba, Tokyo). Thereafter a computer-processed adrenal image was obtained on an oscilloscope by display with a three-level gray scale (Fig. 2-D).

Adrenal venography was performed on eleven patients using the method of Reuter *et al.* (3) and adrenal arteriography was conducted on one patient with primary aldosteronism (case 9) using the method of Kahn and Nichrosz (4).

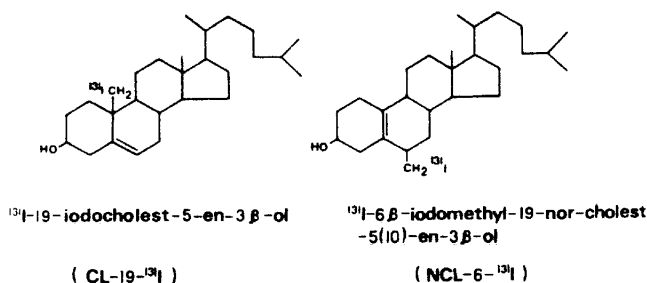


Fig. 1. Structural formulae for CL-19- ^{131}I and NCL-6- ^{131}I

RESULTS

Table 2 presents the results of retroperitoneal pneumography, adrenal angiography, adrenal imaging, tumor site and tumor size.

In primary aldosteronism patients, retroperitoneal pneumography did not show a clear tumor shadow. A suspicious shadow was evident in only 3 patients (Cases 4, 5 and 7). The tumor site was detected definitely by adrenal venography in four of nine cases. A clear tumor angiogram was not obtained in Case 2 because the tumor was in the upper posterior region of the adrenal vein and in Case 3 because the tumor was too small. Venous catheterization for measurement of aldosterone levels located the tumor site in six of nine cases. In Case 9 the tumor site was detected by selective adrenal arteriography. However, our adrenal computer imaging located the tumor site at day 2 after radioactive tracer injection in Cases 3, 5, 8, 9, 10 and 12, and at day 4 in Cases 1, 2, 4, 5, 7 and 11 (Figs. 2-4). In all primary aldosteronism cases, unilateral adrenalectomy or extirpation of the tumor was successful. Tumor size ranged from $0.9 \times 0.9 \times 0.6$ to $3.0 \times 3.0 \times 1.5$ cm (Table 2) and adenoma was confirmed histologically.

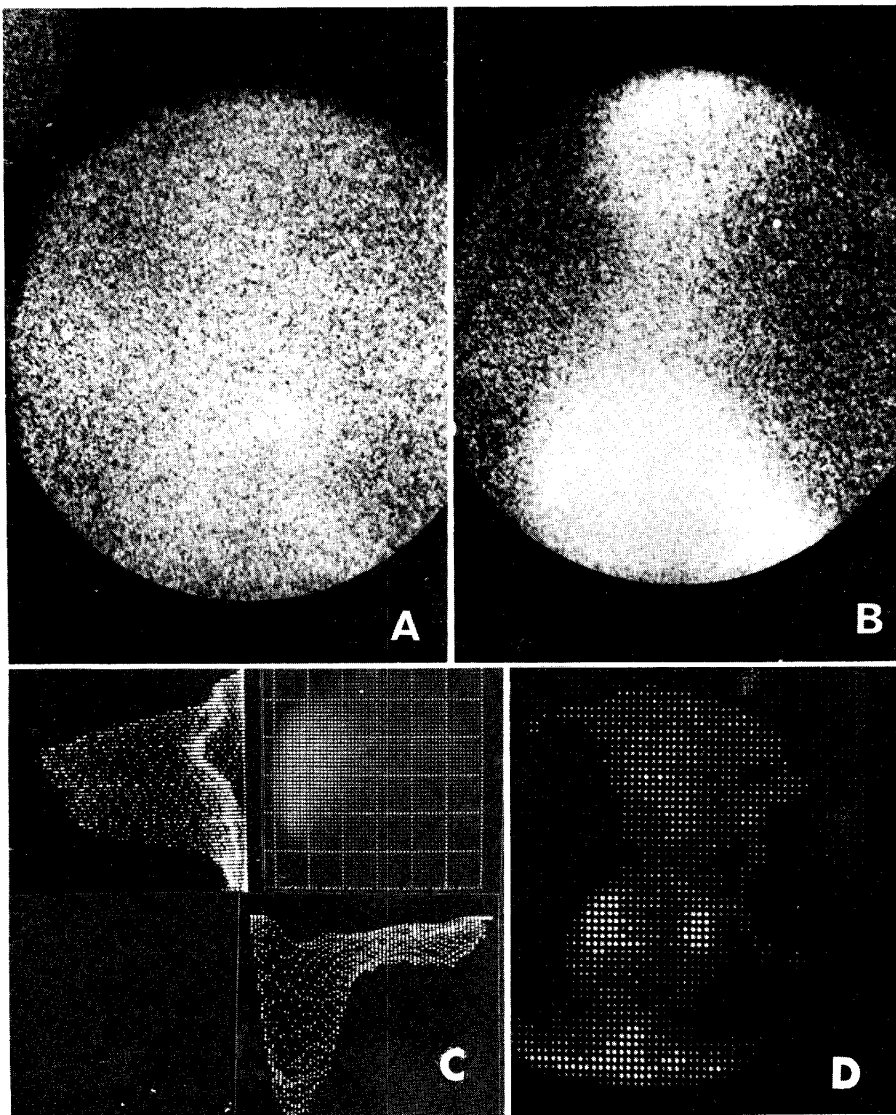


Fig. 2. Computer processed adrenal image of a primary aldosteronism patient (Case 3) A: Routine adreno-photoscan (anterior view) 2 days after intravenous injection of 0.3 mCi of NCL-6-¹³³I. B: Routine hepato-photoscan in the same position. C: Profile display of the liver image with ^{99m}Tc. D: Computer processed adrenal image after matrix subtraction and display with three-level gray scale.

TABLE 2. SUMMARY OF RESULTS

| Case no | Patients | PRP | Adrenal venography | Venous aldosterone levels | Adrenal imaging | Tumor site | Tumor size |
|---------|----------|-----------------|---------------------------|---------------------------|-----------------|------------|----------------|
| 1. | M.K. | Negative | Right | Right | Right | Right | 1.8×1.7×1.3 cm |
| 2. | C.T. | Negative | Susp. of right | Susp. of right | Right | Right | 1.8×1.7×1.3 cm |
| 3. | M.S. | Negative | Susp. of right | Right | Right | Right | 0.9×0.9×0.6 cm |
| 4. | M.M. | Susp. of left | Left | Left | Left | Left | 1.1×1.1×1.1 cm |
| 5. | E.I. | Susp. of left | Left | Susp. of left | Left | Left | 1.4×1.4×1.2 cm |
| 6. | K.U. | Negative | R: unsucc. L: negative | Left | Left | Left | 1.2×0.8×0.6 cm |
| 7. | T.N. | Susp. of righth | Right | Right | Right | Right | 1.5×1.5×0.5 cm |
| 8. | T.O. | Negative | R: unsucc. L: negative | Left | Right | Right | 2.0×1.5×1.5 cm |
| 9. | Y.A. | Negative | Left* | Not performed | Left | Left | 1.8×1.8×1.4 cm |
| 10. | K.T. | Negative | Not performed | Not performed | Right | Right | 3.0×3.0×1.5 cm |
| 11. | T.I. | Negative | R: unsucc. L: negative | Right | Right | Right | 1.0×0.9×0.8 cm |
| 12. | Y.Y. | Negative | Not performed | Not performed | Right | Right | 1.4×1.4×1.1 cm |
| 13. | H.M. | Left | Susp. of left | | Left | Left | 2.5×2.5×2.0 cm |
| 14. | T.M. | Right | Right | | Right | Right | 6.0×5.0×4.0 cm |
| 15. | E.H. | Negative | Not performed | | Left | Left | 2.5×2.2×1.6 cm |
| 16. | T.O. | Left | Not performed | | Left | Left | 2.2×2.0×0.6 cm |

* Selective adrenal arteriography was performed PRP. Pneumo retroperitoneum

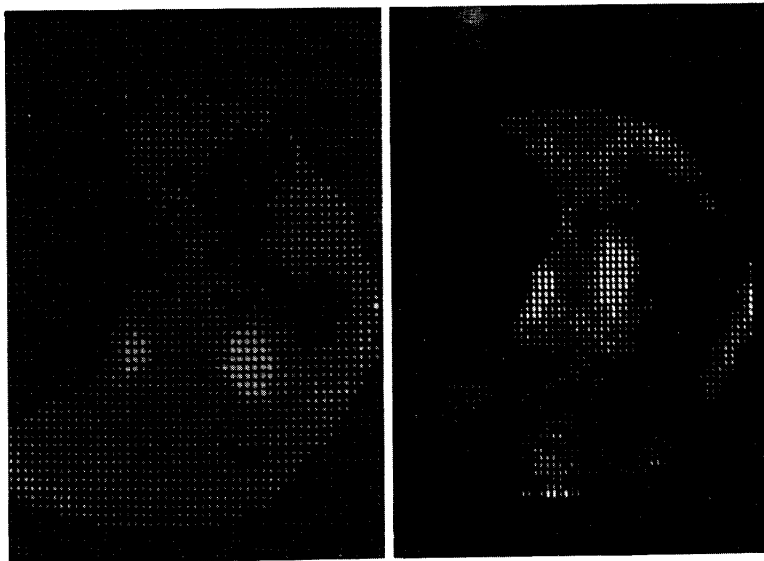


Fig. 3. (left) Computer processed adrenal image (anterior view) of a primary aldosteronism patient (Case 4) on day 4.

Fig. 4. (right) Computer processed adrenal image (anterior view) of a primary aldosteronism patient (Case 5) on day 2.

In Cushing's syndrome due to adrenocortical tumor (Cases 13-16), the tumors were large and easily located by retroperitoneal pneumography in three of four cases. Adrenal computer imaging showed marked radiocholesterol uptake at the tumor site in all cases (Fig. 5) including case 13 in whom the adrenal venography was not typical. A later unilateral adrenalectomy showed the presence of adrenal tumors, ranged from $2.2 \times 2.0 \times 0.6$ to $6.0 \times 5.0 \times 4.0$ cm (Table 2), and confirmed adenoma histologically.




Fig. 5. Computer processed adrenal image (anterior view) on day 4 of a patient with Cushing's syndrome due to lt. adrenal tumor (Case 16).

DISCUSSION

Significant progress has been made in locating adrenocortical tumors by adrenal venography and adrenal scintigraphy. Adrenal venography and venous catheterization for measurement of aldosterone levels are good for diagnosing adreno-cortical disease especially for primary aldosteronism (5). However, they are technically difficult and can be complicated by extravasation (6-8).

In adrenal imaging, Nagai and associates (9) in 1968 reported visualization of human adrenal glands by radioiodinated stigmastrol, but only a large adrenocortical tumor could be detected. In 1971 Blair and associates (10) synthesized 19-iodocholesterol (CL-19-¹³¹I) (Fig. 1) as a possible human adrenal scanning agent by iodinating the C-19 position of cholesterol. They reported that the isotope had a biological half-life of 3.15 days and an effective half-life of 2.26 days in man. Lieberman *et al.* (11) and Conn *et al.* (12) reported the clinical usefulness of this agent. However, some authors (13,14) reported difficulty in detecting small adrenocortical tumors. In regard to this, Moses *et al.* (15) reported computer display with background subtraction and Conn *et al.* (12,16) described a

dexamethasone-modified adrenal scintiscan. But these methods require further study of the time needed for diagnosis. Recently, NCL-6-¹³¹I was successfully synthesized by Kojima *et al.* (17), Maeda *et al.* (18) and Sarker *et al.* (19). Tissue distribution studies with NCL-6-¹³¹I in male rats revealed that the ratio of adrenal gland-to-liver concentration was 113 on day 1, 330 on day 3 and 851 on day 7 after radiocholesterol administration (17). These ratios were very high compared with the 157 (20) on day 7 with CL-19-¹³¹I. NCL-6-¹³¹I is a superior adrenal scanning agent to CL-19-¹³¹I. Some authors (21-23) reported the clinical usefulness of NCL-6-¹³¹I, but it was difficult to obtain satisfactory images because of liver images overlapping with the right adrenal gland 2-4 days. We performed adreno-photoscanning for two to four days following administration of NCL-6-¹³¹I when a substantial amount of ¹³¹I had accumulated in the adrenal glands, then performed hepato-photoscanning using ^{99m}Tc-phytate in the same position. The overlapping liver images of the right adrenal gland were eliminated by matrix subtraction and clear images of both adrenal glands were obtained on an oscilloscope. The tumor site could be predicted preoperatively in all cases by this method. Thus, our methods of adrenal computer imaging should be more suitable for detecting adrenocortical tumors in outpatient department because of its sensitivity and simplicity.

Acknowledgment. We thank Mr. Akiyama of the Radioisotope Center, Okayama University, for his expert technical assistance; the Third Department of Internal Medicine for measuring hormone concentrations; and Daiichi Radioisotope Laboratories, Tokyo, for providing NCL-6-¹³¹I and ^{99m}Tc-phytate.

REFERENCES

1. Blanquet, P.C., Beck, C.R. and Palais, C.J.: Pancreas scanning with ⁷⁵Se-selenomethionine and ¹⁹⁸Au using digital-data processing techniques. *J. Nucl. Med.* **9**, 486-488, 1968.
2. Overton, T.R., Heslip, P. G., Barrow, P.A. and Jelinek, J. : Dual-radioisotope techniques and digital image-subtraction methods in pancreas visualization. *J. Nucl. Med.* **12**, 493-498, 1969.
3. Reuter, S.R., Blair, A.J., Scheingart, D.E. and Bookstein, J.J. : Adrenal venography, *Radiology* **89**, 805-814, 1967.
4. Kahn, P.C. and Nickrosz, L.V. : Selective angiography of the adrenal glands, *Am. J. Roent.* **101**, 739-749, 1967.
5. Melby, J.C., Spark, R.F., Dale, S.L., Egdahl, R.H. and Kahn, P.C. : Diagnosis and localization of aldosterone-producing adenomas by adrenal venography. *N. Engl. J. Med.* **277**, 1050-1056, 1967.
6. Bookstein, J.J., Conn, J. and Reuter, S.R. : Intra-adrenal hemorrhage as a complication of adrenal venography in primary aldosteronism. *Radiology* **90**, 778-779, 1968.
7. Bayliss, R.I.S., Edwards, O.M. and Starer, F. : Complications of adrenal venography. *Br. J. Radiol.* **43**, 531-533, 1970.
8. Eagan, R.T. and Page, M.I. : Adrenal insufficiency following bilateral adrenal venography. *J. Am. Med. Assoc.* **215**, 115-116, 1971.
9. Nagai, T., Solis, B.A. and Koh, C.S. : An approach to developing adrenal-gland scanning. *J. Nucl. Med.* **9**, 576-581, 1968.

10. Blair, R.J., Beierwaltes, W. H., Lieberman, L.M., Boyd, C.M., Cunsell, R.E., Weinhold, P.A. and Varma, V.M. : Radiolabeled cholesterol. as an adrenal scanning agent. *J. Nucl. Med.* **12**, 176-182, 1971.
11. Lieberman, L.M., Beierwaltes, W.H., Conn, J.W., Ansari, A.N. and Nishiyama, H. : Diagnosis of adrenal disease by visualization of human adrenal glands with ¹³¹I-19-iodocholesterol. *N. Engl. J. Med.* **285**, 1387-1393, 1971.
12. Conn, J.W., Morita, R., Cohen, E.L., Beierwaltes, W.H., McDonald, W.J. and Herwig, K.R. : Primary aldosteronism: Photoscanning of tumors after ¹³¹I-19-iodocholesterol. *Arch. Intern. Med.* **129**, 417-425, 1971.
13. Dige-Peterson, H. Munkner, T., Fogh, J., Blichert-Toft, M. and Lund, J.O. : ¹³¹I-19-iodocholesterol scintigraphy of the adrenal cortex. *Acta Endocrinol.* **80**, 81-94, 1975.
14. Seabold, J.E., Cohen, E.L., Beierwaltes, W.H., Hinerman, D.L., Nishiyama, R.H., Bookstein, J.J., Ice, R.D. and Balachandran, S. : Adrenal imaging with ¹³¹I-19-iodocholesterol in the diagnostic evaluation of patients with aldosteronism. *J. Clin. Endocrinol. Metab.* **42**, 41-51, 1976.
15. Moses, D.C., Scheintgart, D.E., Sturman, M.F., Beierwaltes, W.H. and Ice, R.D. : Efficacy of radiocholesterol imaging of the adrenal glands in Cushing's syndrome. *Surg. Gynecol. Obstet.* **139**, 201-204, 1974.
16. Conn, J.W., Cohen, E.L. and Herwig, K.R. : The dexamethasone-modified adrenal scintiscan in hyporeninemic aldosteronism (tumor versus hyperplasia). A comparison with adrenal venography and adrenal venous aldosterone. *J. Lab. Clin. Med.* **88**, 841-856, 1976.
17. Kojima, M., Maeda, M., Ogawa, H. Nitta, K. and Ito, T. : New adrenal-scanning agent. *J. Nucl. Med.* **16**, 666-668, 1975.
18. Maeda, M., Kojima, M., Ogawa, H., Nitta, K. and Ito, T. : Homoallylic rearrangement of 19-iodocholest-5-en-3 β -ol: new adrenal scanning agent. *Steroids* **26**, 241-250 1975.
19. Sarkar, S.D., Beierwaltes, W.H., Ice, R. D., Basmadjian, G.P., Hetzel, K.R., Kennedy, W.P. and Mason, M.M. : A new and superior scanning agent, NP-59. *J. Nucl. Med.* **16**, 1038-1042, 1975.
20. Counsell, R.E., Ranade, V.V., Blair, R.J., Beierwaltes, W.H. and Weinhold, P.A. : Tumor localizing agents. IX. Radioiodinated cholesterol. *Steroids* **16**, 317-328, 1970.
21. Sarkar, S.D., Cohen, E.L., Beierwaltes, W.H., Ice, R.D., Cooper, R. and Gold, E.N. : A new and superior adrenal imaging agent, ¹³¹I-6 β -iodomethyl-19-nor-cholesterol (NP-59): evaluation in humans. *J. Clin. Endocrinol. Metab.* **45**, 353-362, 1977.
22. Ryo, U.Y., Johnston, A.S., Kim, B.S.I. and Pinsky, S.M. : Adrenal scanning and uptake with ¹³¹I-6 β -iodomethyl-nor-cholesterol. *Radiology* **128**, 157-161, 1978.
23. Freitas, J.E., Grekin, R.J., Thrall, J.H., Gross, M.D., Swanson, D.P. and Beierwaltes, W.H. : Adrenal imaging with iodomethyl-nor-cholesterol (I-131) in primary aldosteronism. *J. Nucl. Med.* **20**, 7-10, 1979.