

Acta Medica Okayama

Volume 63, Issue 2

2009

Article 5

APRIL 2009

Beneficial effects of *Vitis coignetiae* Pulliat leaves on nonalcoholic steatohepatitis in a rat model

Fusako Takayama*	Kazuo Nakamoto [†]	Hiromu Kawasaki [‡]
Mitsumasa Mankura**	Toru Egashira ^{††}	Keiji Ueki ^{‡‡}
Azusa Hasegawa [§]	Shigeru Okada [¶]	Akitane Mori

*Department of Clinical Pharmaceutical Science, Okayama University, Graduate School of Medicine, Dentistry and Pharmaceutical Sciences,

[†]Department of Clinical Pharmaceutical Science, Okayama University, Graduate School of Medicine, Dentistry and Pharmaceutical Sciences,

[‡]Department of Clinical Pharmaceutical Science, Okayama University, Graduate School of Medicine, Dentistry and Pharmaceutical Sciences,

**Anti-Aging Food Sciences, Okayama University Graduate School of Medicine, Dentistry and Pharmaceutical Sciences,

^{††}Anti-Aging Food Sciences, Okayama University Graduate School of Medicine, Dentistry and Pharmaceutical Sciences,

^{‡‡}Hiruzen Winery Co., Ltd.,

[§]Department of Clinical Pharmaceutical Science, Okayama University, Graduate School of Medicine, Dentistry and Pharmaceutical Sciences,

[¶]Anti-Aging Food Sciences, Okayama University Graduate School of Medicine, Dentistry and Pharmaceutical Sciences,

^{||}Anti-Aging Food Sciences, Okayama University Graduate School of Medicine, Dentistry and Pharmaceutical Sciences,

Beneficial effects of *Vitis coignetiae* Pulliat leaves on nonalcoholic steatohepatitis in a rat model

Fusako Takayama, Kazuo Nakamoto, Hiromu Kawasaki, Mitsumasa Mankura, Toru Egashira, Keiji Ueki, Azusa Hasegawa, Shigeru Okada, and Akitane Mori

Abstract

Vitis coignetiae Pulliat (Yamabudo) is used as a health juice and wine based on the abundant polyphenols and anthocyanins in its fruit. However, it is not known whether the leaves of this plant confer similar benefits. This study investigated the hepatoprotective effects of aqueous extracts from *Vitis coignetiae* Pulliat leaves (VCPL) in an animal model of nonalcoholic steatohepatitis (NASH). Rats were fed a choline-deficient high-fat diet for four weeks to generate fatty livers. NASH was induced by oxidative stress loading. Ten weeks later, blood and liver samples were collected from anesthetized animals and assessed biochemically, histologically, and histochemically to determine the extent of oxidative stress injury and the overall effects of VCPL. Six-week VCPL extract supplementation reduced serum levels of liver enzymes, decreased CYP2E1 induction, increased plasma antioxidant activities and delayed the progression of liver fibrosis. The findings suggested that VCPL has strong radical-scavenging activity and may be beneficial in preventing NASH progression.

KEYWORDS: Yamabudo, nonalcoholic steatohepatitis, antioxidant, hepatoprotection

Original Article

Beneficial Effects of *Vitis coignetiae* Pulliat Leaves on Nonalcoholic Steatohepatitis in a Rat ModelFusako Takayama^{a*}, Kazuo Nakamoto^{a,b}, Hiromu Kawasaki^a, Mitsumasa Mankura^b, Toru Egashira^b, Keiji Ueki^c, Azusa Hasegawa^a, Shigeru Okada^b, and Akitane Mori^b

^aDepartment of Clinical Pharmaceutical Science, Okayama University, Graduate School of Medicine, Dentistry and Pharmaceutical Sciences, Okayama 700-8530, ^bAnti-Aging Food Sciences, Okayama University Graduate School of Medicine, Dentistry and Pharmaceutical Sciences, Okayama 700-8558, Japan, and ^cHiruzen Winery Co., Ltd., Maniwa, Okayama 717-0604, Japan

Vitis coignetiae Pulliat (Yamabudo) is used as a health juice and wine based on the abundant polyphenols and anthocyanins in its fruit. However, it is not known whether the leaves of this plant confer similar benefits. This study investigated the hepatoprotective effects of aqueous extracts from *Vitis coignetiae* Pulliat leaves (VCPL) in an animal model of nonalcoholic steatohepatitis (NASH). Rats were fed a choline-deficient high-fat diet for four weeks to generate fatty livers. NASH was induced by oxidative stress loading. Ten weeks later, blood and liver samples were collected from anesthetized animals and assessed biochemically, histologically, and histochemically to determine the extent of oxidative stress injury and the overall effects of VCPL. Six-week VCPL extract supplementation reduced serum levels of liver enzymes, decreased CYP2E1 induction, increased plasma antioxidant activities and delayed the progression of liver fibrosis. The findings suggested that VCPL has strong radical-scavenging activity and may be beneficial in preventing NASH progression.

Key words: Yamabudo, nonalcoholic steatohepatitis, antioxidant, hepatoprotection

Nonalcoholic steatohepatitis (NASH) is a chronic liver disease characterized by necroinflammatory activity, with nonspecific inflammatory infiltrates, hepatocyte ballooning with Mallory's hyaline, and occasional fibrosis [1]. The "two-hit theory" describes the most widely accepted mechanism for the progression of NASH [2]. We previously developed an animal model of NASH in the rat (Patent application No. PCT/JP2007/52477). Our model rats with fatty livers developed methemoglobinemia following intermittent administration of a nitrate compound [3]. We

also demonstrated the excellent antioxidant activity of fermented green tea extracts, which prevented the progression of NASH, however, due to the paucity of information on the potential efficacy of antioxidant supplements in the treatment of NASH, we focused on identifying candidate antioxidant(s) potentially suitable for clinical use against NASH.

Vitis coignetiae Pulliat (Yamabudo) is a grape variety native to the Japanese Islands. Grape juice and wine made from this plant are taken by some for their health benefits. The flesh and skin of the fruit contain abundant amounts of polyphenols and anthocyanins compared with other grape varieties [4]. Several biological properties have been attributed to *Vitis coignetiae* Pulliat including high free-radical-scavenging

Received November 14, 2008; accepted December 24, 2008.

*Corresponding author. Phone: +81-86-251-7973; Fax: +81-86-251-7973
E-mail: takayamaf@cc.okayama-u.ac.jp (F. Takayama)

activity and inhibition of photodecomposition of anthocyanin pigments [5]. We suspect that the same functional compounds found in the fruit are also present in the *Vitis coignetiae Pulliat* leaves (VCPL), despite the fact that there are no reports of similar biological effects to date. The aim of the present study was to determine whether VCPL prevents NASH progression in animals and to test whether oxidative stress provides "a second hit" and thus contributes to the development of the condition.

Materials and Methods

Chemicals. 5,5-Dimethyl-1-pyrroline N-oxide (DMPO) was purchased from Labotech (Tokyo, Japan). Benzamidine hydrochloride and sodium nitrate were purchased from Nacalai Tesque (Kyoto, Japan). All other reagents were obtained from Wako Pure Chemical Industries (Osaka, Japan). All chemicals used in our study were of the highest grade available.

Preparation of water extracts. Hiruzen Winery (Okayama, Japan) provided the VCPL used in the present study. Fresh red leaves (1,000g) were lyophilized to a final 327g of dry leaves, which were extracted with distilled water (bath ratio; 1:20) by stirring at room temperature for 30min. The extract was filtered and then solvent-evaporated to dry under reduced pressure in a rotary evaporator. The resultant water-extracted red powder (73.6g, yield 7.4%) was stored at -20°C for use in this study.

Animals and experimental design. Male Wistar rats, 6 weeks of age and weighing 160–170g were purchased from Shimizu Experimental Animals (Shizuoka, Japan). The animals were housed at the Animal Research Center of Okayama University in a temperature-controlled room ($22 \pm 1^{\circ}\text{C}$) with a relative humidity of $50 \pm 10\%$ and a 12-h light/dark cycle (lights on at 8:00 a.m.). The study protocol was approved by the Ethics Review Committee of Animal Experimentation of the Faculty of Pharmaceutical Science, Okayama University.

We induced fatty liver in rats by feeding them a choline-deficient high fat (CDHF) diet (Oriental Yeast) for 4 weeks. The rats were divided at random into 5 groups: the control group (n=6) was fed standard chow for 4 weeks; the CDHF group (n=6) was fed CDHF diet only for 4 weeks; the NASH group (n=6) was fed CDHF diet for 4 weeks followed by intraperi-

toneal (i.p.) injections of nitrite (30mg/kg/day) for 6 weeks, the VCPL 100 group (n=6) was fed CDHF diet for 4 weeks followed by i.p. injections of nitrite at 30mg/kg/day for 6 weeks, and was also orally administered VCPL at 100mg/kg/day (low dose) for 6 weeks; and the VCPL 300 group (n=6) was fed CDHF diet for 4 weeks followed by i.p. injections of nitrite at 30mg/kg/day for 6 weeks, and was orally administered VCPL at 300mg/kg/day (high dose). At the end of the 10-week treatment period, the rats fasted overnight and were sacrificed under deep anesthesia. Liver and blood samples were taken to determine oxidative stress-related injury and the efficacy of VCPL administration biochemically and histologically. The liver samples were fixed in 20% formalin or snap-frozen in liquid nitrogen for histological examination and to determine lipid peroxidation and antioxidant activity.

Biochemical analyses. Alanine aminotransferase (ALT) and aspartate aminotransferase (AST) activities in plasma were measured using commercial enzyme assay kits (Wako). Plasma alkaline phosphatase (ALP) levels were determined using standard assays.

Plasma SOD-like activity. Plasma superoxide dismutase (SOD)-like activity was measured using electron paramagnetic resonance (ESR) spectroscopy. Superoxide radicals were generated using a hypoxanthine-xanthine oxidase system. CYPMPO (Radical Research, Tokyo, Japan) was used as an ESR spectroscopic spin-trapping reagent. The signal intensity was confirmed by the ratio of the heights of the internal manganese standard signal and the fourth of 8 peaks from the CYPMPO-OOH spin adducts. The conditions used were as follows: magnetic field, 331.5mT; power, 8mW; modulation frequency, 9.41GHz; modulation amplitude, $1 \times 0.1\text{mT}$; response time, 0.1s; amplitude, 790; sweep width, 10mT; sweep time, 4min; room temperature [6–8].

Preparation of the liver microsomal fraction. The liver mitochondria were isolated by differential centrifugation of tissue homogenates as previously described [9]. In brief, rats were transcardially perfused with ice-cooled 1.15% KCl buffer containing 5mM benzamidine (pH7.4) via the inferior vena cava. Liver tissue was then removed (6g) and homogenized in 18 volumes of ice-cooled 5mM Tris-HCl buffer (pH7.4) containing 0.25mM

sucrose and 100 mM KCl. The mixture was centrifuged at 2,500 rpm for 10 min at 4°C. The supernatant was collected after centrifugation at 9,000 × g for 20 min at 4°C, followed by another centrifugation at 100,000 × g for 60 min at 4°C. The resultant pellet containing the microsomal fraction was resuspended in the same buffer and stored at -80°C until analysis. Protein concentration was determined using a BCA kit (Pierce, Rockford, IL, USA) with bovine serum albumin as a standard.

Western blotting. Aliquots of liver microsomes (5 μg) were placed in sample buffer (0.5 M Tris-HCl pH 6.8, 10% glycerol, 2% SDS, 5% 2-mercaptoethanol, and 0.05% bromophenol blue) and denatured at 95°C for 5 min. The samples were separated on Ready Gels (BioRad, Hercules, CA, USA) then transferred to polyvinylidene fluoride sheets (BioRad) using a transblot apparatus (BioRad). The membranes were blocked overnight in 5% nonfat milk dissolved in TBS-T buffer (Tris 50 mM; 1.5% NaCl; and 0.05% Tween 20, pH 7.5), before incubating with primary rabbit anti-human/rat cytochrome P450 enzyme (CYP2E1) polyclonal antibodies for 1 h (1: 1,500; Chemicon International, Temecula, CA, USA). The blots were then washed thoroughly in TBS-T buffer before incubating with a peroxidase-conjugated secondary anti-rabbit IgG antibody (1: 5,000, Santa Cruz Biotechnology, Santa Cruz, CA, USA) for 1 h. Visualization was performed with Chemiluminescence Luminol Reagent (Santa Cruz Biotechnology).

Histological examination. Paraffin-embedded tissues were sectioned at a thickness of 4 μm and stained with hematoxylin and eosin (H&E). The sec-

tions were also stained by Masson trichrome staining to identify fibrosis. Histological assessment of tissue morphology was performed using an Olympus light microscope (Olympus, Tokyo, Japan).

Statistical analyses. Statistical analysis was performed using GraphPad Prism (Version 4.03; Graph Pad Software, La Jolla, CA, USA) on untransformed data. Data are expressed as mean ± standard error of the mean (SEM). The groups were compared by an analysis of variance using the Turkey-Kramer test, and differences were considered significant when the probability was less than 0.05.

Results

Histological evaluation of experimental liver samples. Representative histological sections of the liver from each experimental group are shown in Fig. 1. H&E staining of the liver sections showed hepatic macrovesicular steatosis in all CDHF-fed rats (Fig. 1). We next evaluated the effects of VCPL on liver fibrogenesis in the different treatment groups. No fibrosis was noted in the livers of control rats fed standard chow compared with those fed CDHF alone. However, the NASH rats showed advanced liver steatosis, fibrosis, and necrosis. The addition of VCPL clearly attenuated the fibrosis in all groups (Fig. 2).

Effects of VCPL on plasma biochemical parameters. The AST and ALP levels in the NASH group were significantly higher than those in the control group and the CDHF group. The ALT levels were significantly high in comparison with the controls. VCPL supplementation at 300 mg/kg significantly improved AST levels compared with the

Table 1 Effects of VCPL on biochemical markers

	Control (n = 6)	CDHF (n = 6)	NASH		
			0 (n = 6)	VCPL (mg/kg/day, p.o) 100 (n = 6)	300 (n = 6)
Biochemical markers (plasma)					
ALT (IU/L)	4.3 ± 1.7	13.0 ± 1.3 ^a	13.7 ± 2.6 ^a	16.0 ± 4.4 ^a	7.8 ± 1.1 ^a
AST (IU/L)	14.6 ± 5.5	87.6 ± 7.4 ^a	127.8 ± 6.6 ^{ab}	142.1 ± 17.2 ^{ab}	102.3 ± 4.9 ^{abc}
ALP (p-nitrophenol, mM)	0.7 ± 0.0	3.1 ± 0.7 ^a	6.9 ± 2.2 ^{ab}	3.1 ± 1.1 ^{bc}	3.0 ± 0.8 ^{cd}

Values represent the mean ± S.E.M. of 6 rats. ^aP < 0.01 versus control, ^bP < 0.01 versus CDHF, ^cP < 0.05 versus NASH, ^dP < 0.01 versus NASH. VCPL, *Vitis coignetiae* Pulliat leaves; control, standard diets; CDHF, choline-deficient high-fat; NASH, CDHF + oxidative stress; VCPL 100, NASH + VCPL 100 mg/kg; VCPL 300, NASH + VCPL 300 mg/kg.

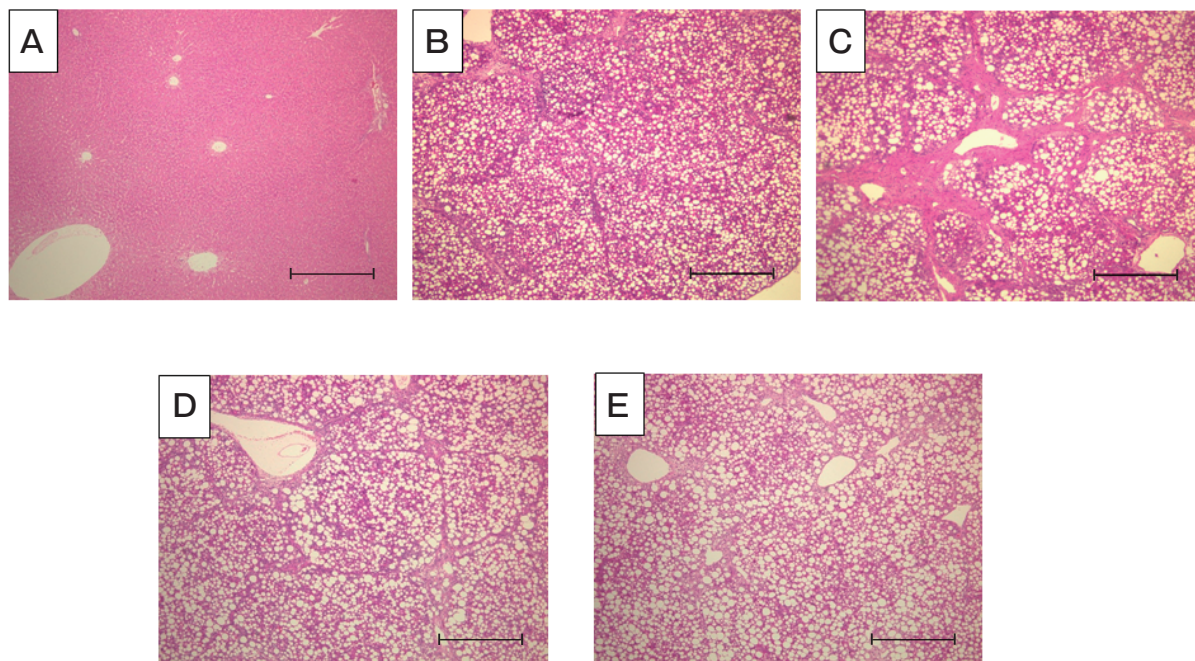


Fig. 1 Histological evaluation of rat liver. Effects of VCPL on liver structure were assessed by hematoxylin and eosin staining in control (A), CDHF (B), NASH (C), NASH + VCPL 100 mg/kg (D) and NASH + VCPL 300 mg/kg (E) rats. VCPL: *Vitis coignetiae Pulliat* leaves. Data show typical results. Scale bar = 500 μ m.

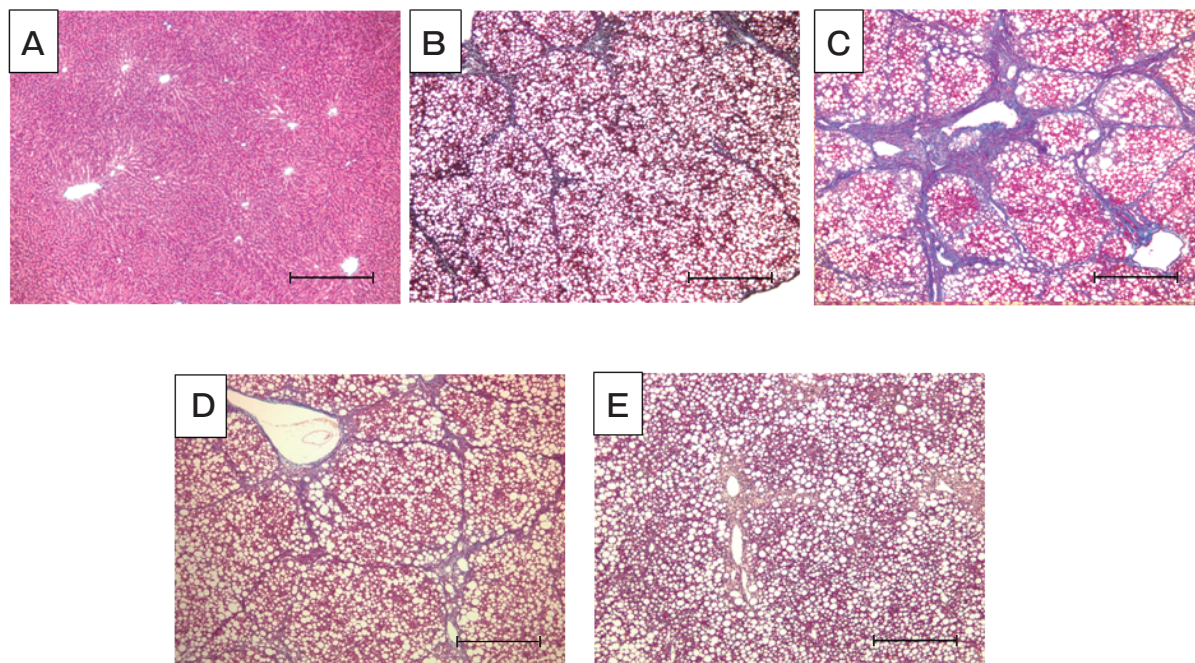


Fig. 2 Effects of VCPL on liver fibrosis were examined by Masson Trichrome staining in control (A), CDHF (B), NASH (C), NASH + VCPL 100 mg/kg (D) and NASH + VCPL 300 mg/kg (E) rats. VCPL: *Vitis coignetiae Pulliat* leaves. Data show typical results. Scale bar = 500 μ m.

NASH group, although these parameters were still higher than in the control and CDHF groups. However, there were no significant differences between the NASH group and the VCPL 100 group. Moreover, the ALP levels in VCPL 100 and VCPL 300 were significantly reduced in comparison with the NASH group (Table 1).

Effects of VCPL on plasma antioxidant activity. The levels of plasma SOD-like activity in the NASH group were significantly lower than those in the control group. There were no significant differences between the CDHF group and the NASH group. NASH rats treated with VCPL showed a significant increase and had high plasma SOD-like activity comparable to that found in NASH rats (Fig. 3).

Effects of VCPL on CYP2E1 induction in the liver microsomes. Western blot analysis was used to examine the induction of CYP2E1 expression with the development of NASH. The 50-kDa CYP2E1 protein was detected in all experimental groups. The CYP2E1 expression in the NASH group was significantly higher than those in the control group and the CDHF group. Moreover, the CYP2E1 expression in the CDHF group was significantly lower than those in

the VCPL 100 group and the VCPL 300 group. NASH rats treated with VCPL at 300mg/kg showed significantly lower CYP2E1 expression than the NASH group, but it was not lower than the control and CDHF group levels. There were no significant differences between the NASH group and the VCPL 100 group. VCPL seemed to prevent CYP2E1 induction in a dose-dependent manner (Fig. 4).

Discussion

Free radical damage inducing oxidative stress has been proposed as a likely process underlying the progression to hepatocellular damage, inflammation, and fibrosis [10]. It is therefore possible that nutritional support with antioxidants may be useful in preventing oxidative damage and thus the progression of NASH. There are many reports of food ingredients with antioxidant activities that can prevent clinical progression of NASH, including green tea extracts [11], fermented green tea extracts [12] and N-acetylcysteine [13]. The present study showed that supplying VCPL prevented NASH progression through both the increase of plasma antioxidant activity and the attenuation of microsomal CYP2E1 induction. Moreover,

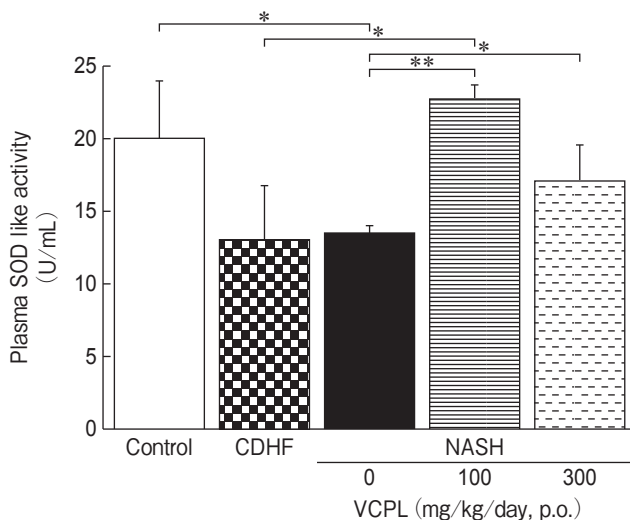


Fig. 3 Effects of VCPL on plasma SOD-like activity in the control, CDHF, NASH, VCPL 100 and VCPL 300 groups by ESR. ESR spectra of the CYPMPPO-OOH spin adducts obtained from hypoxanthine-xanthine oxidase systems in the control, CDHF, NASH, NASH + VCPL 100mg/kg, and NASH + VCPL 300mg/kg groups. VCPL: *Vitis coignetiae* Pulliat leaves. Values represent the mean \pm S.E.M. of 6 rats. * indicates $p < 0.05$, ** indicates $p < 0.01$

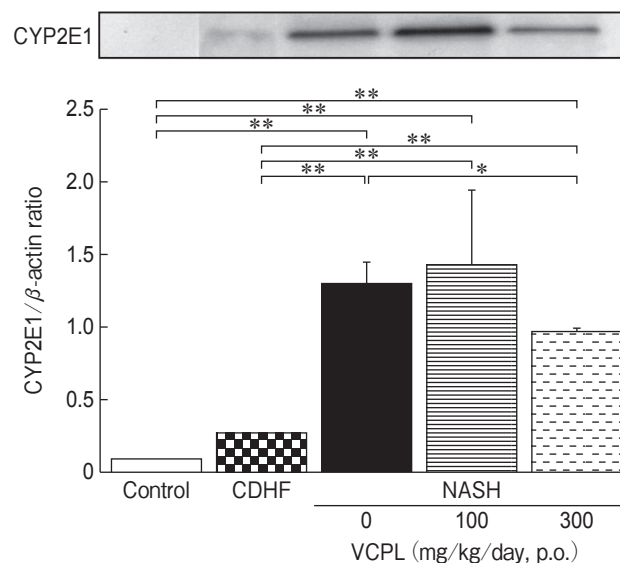


Fig. 4 Effects of VCPL on CYP2E1 induction in the liver microsomes of the control, CDHF, NASH, NASH + VCPL 100mg/kg, and NASH + VCPL 300mg/kg groups. Values represent the mean \pm S.E.M. of 6 rats. * indicates $p < 0.05$, ** indicates $p < 0.01$.

VCPL administration reduced the severe liver fibrosis of NASH rats. The degree of liver fibrosis seemed to correlate to the liver index ((liver weight/body weight) × 100) (data not shown). We recognize VCPL as a novel functional food for the prevention of NASH.

Previous studies identified the pigments in the fruit and skin of *Vitis coignetiae Pulliat* as mostly malvidin-3, 5-diglucoside and malvidin-3, 5-diglucoside coumarate [14]. These anthocyanins are generally included in the pericarp of American grape varieties. Some studies have attributed anthocyanins with remarkable antioxidant and oxygen radical-scavenging properties [15, 16]. The present study therefore used only red leaves collected during autumn, because these are presumably rich in anthocyanins, and would therefore be superior to the green leaves collected in summer in terms of the desired activities. Previous studies on leaves from European grapes (*Vitis vinifera L.*) showed antihyperglycemic effects in diabetic rats [17, 18] and hepatoprotective activities [19]. These findings would thus support the finding in this study that the anthocyanins in VCPL also conferred hepatoprotective effects in NASH rats. However, this assumption is speculative, and further studies are necessary to isolate and identify the VCPL components responsible for the observed effects.

To clarify the role of VCPL on NASH progression, we observed CYP2E1 protein expression in liver microsomes and antioxidant activity in plasma. CYP2E1 is a well-known source of oxidative stress and its levels are elevated in the liver of NASH patients [20]. CYP2E1 substrates include fatty acids and ketone bodies, both of which could upregulate CYP2E1 activity to induce excess production of reactive oxygen species [21, 22]. In fact, the depletion of antioxidants in NASH patients leads to increased lipid peroxidation [23, 24]. The current results demonstrate that the decrease in plasma antioxidant activity was also more pronounced in NASH rats than in those with fatty liver only. The administration of VCPL increased plasma SOD-like activity (Fig. 3). These results suggest that VCPL supplementation could regulate the balance of pro- and antioxidants. We expect that a lot of anthocyanins in VCPL may prevent NASH progression. It could therefore be suggested that regulation of oxidative stress is an important 'second hit' in the progression of NASH.

Furthermore, the induction of CYP2E1 was increased in NASH rats compared to those fed a CDHF diet, suggesting some functional link to the further progression from steatosis to steatohepatitis. The excessive reactive oxygen species induced by CYP2E1 induction also may be a key factor in the process of NASH progression.

The exact mechanism behind the increased CYP2E1 protein expression in NASH rats compared to CDHF-fed rats remains unknown. The administration of VCPL suppressed the microsomal CYP2E1 induction and increased plasma antioxidant activity. Anthocyanins lower the total lipid and triglyceride levels in the livers of high-fat-fed mice relative to control mice fed the same high-fat diet without anthocyanins [25]. It is therefore possible that anthocyanins in the VCPL tested here might regulate CYP2E1 via the lower liver content of total lipids, which are CYP2E1 substrates, thus delaying the progression of fatty liver to fibrosis.

In summary, VCPL ameliorated the progression of NASH by reducing CYP2E1 induction and increasing plasma antioxidant activity in rat models, suggesting that oxidative stress-induced damage is associated with the progression of NASH. Further studies are warranted to determine the mechanisms underlying the beneficial effect of the antifibrotic activity of VCPL on NASH, as well as to assess the serial changes in mitochondrial function and liver architecture in NASH livers.

In conclusion, this study demonstrated that the antioxidant activity of VCPL seems to prevent the progression of NASH by suppressing the induction of CYP2E1, suggesting that VCPL is a novel functional food for the prevention of NASH.

Acknowledgments. This work was supported by a Grant-in-Aid from the Ministry of Education, Culture, Sports, Science and Technology, Japan. We thank Hiruzen Winery Co. Ltd. for providing the *Vitis coignetiae Pulliat* leaves. We also thank Ms. Kei Morita for her excellent technical assistance.

References

1. Ludwig J, Viggiano TR, McGill DB and Oh BJ: Nonalcoholic steatohepatitis: Mayo Clinic experiences with a hitherto unnamed disease. *Mayo Clin Proc* (1980) 55: 434-438.
2. Day CP and James OF: Steatohepatitis: a tale of "two hits"? *Gastroenterology* (1998) 114: 842-845.
3. Takayama F, Hobara N, Nakamoto K, Ohro M, Yoshida N,

- Takeda A, Kawasaki H and Egashira T: Construction of a non-alcoholic steatohepatitis model induced by fatty liver and nitrite administration. *J Pharmacol Sci* (2006) 100: 164P.
4. Ueki K, Aoki H, Okamoto G and Hirano K: Yamabudou (*Vitis coignetiae* Pulliat) kazitsu no seizyuku niyobosu hasuu no eikyou to kazyuno seibunntekitokutyu. *J ASEV Jpn* (2003) 14: 77-82 (in Japanese).
 5. Okamoto G, Goto S and Ueki K: Studies on *Vitis Coignetiae* Grapes -Vine physiology and fruit constituents; in Scientific reports of the faculty of agriculture Okayama University, 97 Faculty of Agriculture Okayama University, Okayama (2008) 97: 69-81 (in Japanese).
 6. Takayama F, Egashira T, Kudo Y and Yamanaka Y: Effects of anti-free radical interventions on phosphatidylcholine hydroperoxide in plasma after ischemia-reperfusion in the liver of rats. *Biochem Pharmacol* (1993) 46: 1749-1757.
 7. Takayama F, Egashira T and Yamanaka Y: Effect of diclofenac, a non-steroidal anti-inflammatory drug, on lipid peroxidation caused by ischemia-reperfusion in rat liver. *Jpn J Pharmacol* (1994) 64: 71-78.
 8. Egashira T and Takayama F: Free radicals and oxidative stress: targeted ESR measurement of free radicals. *Nippon Yakurigaku Zasshi* (2002) 120: 229-236 (in Japanese).
 9. Hogeboom GH: Fractionation of cell components of animal tissues. *Methods in Enzymology* (1955) 1: 16-19.
 10. Chitturi S and Farrell GC: Etiopathogenesis of nonalcoholic steatohepatitis. *Semin Liver Dis* (2001) 21: 27-41.
 11. Kuzu N, Bahcecioglu IH, Dagli AF, Ozercan IH, Ustündag B and Sahin K: Epigallocatechin gallate attenuates experimental non-alcoholic steatohepatitis induced by high fat diet. *J Gastroenterol Hepatol* (2008) 23: e465-470.
 12. Kazuo N, Takayama F, Mankura M, Hidaka Y, Egashira T, Ogino T, Kawasaki H and Mori A: Beneficial Effects of Fermented Green Tea Extract in a Rat Model of Non-alcoholic Steatohepatitis. *J Clinical Biochemistry and Nutrition* (in press).
 13. Baumgardner JN, Shankar K, Hennings L, Albano E, Badger TM and Ronis MJ: N-acetylcysteine attenuates progression of liver pathology in a rat model of nonalcoholic steatohepatitis. *J Nutr* (2008) 138: 1872-1879.
 14. Okamoto G, Ueki K, Ichi T, Aoki H, Fujiwara M and Hirano K: Juice constituents and skin pigments in *Vitis coignetiae* Pulliat grapevines. *Vitis Germany* (2002) 41: 161-162.
 15. Tsuda T, Horio F and Osawa T: The role of anthocyanins as an antioxidant under oxidative stress in rats. *Biofactors* (2000) 13: 133-139.
 16. Wang H, Cao G and Prior R: Oxygen radical absorbing capacity of anthocyanins. *J Agric Food Chem* (1997) 45: 304-309.
 17. Orhan N, Aslan M, Orhan DD, Erguh F and Yesilada E: In-vivo assessment of antidiabetic and antioxidant activities of grapevine leaves (*Vitis vinifera*) in diabetic rats. *J Ethnopharmacol* (2006) 108: 280-286.
 18. Kosar M, Kùpeli E, Malyer H, Uylaser V, Türkben C and Baser KH: Effect of Brining on Biological Activity of Leaves of *Vitis vinifera* L. (Cv. Sultani Cu ekirdeksiz) from Turkey. *J Agric Food Chem* (2007) 55: 4596-4603.
 19. Orhan DD, Orhan N, Ergun E and Ergun F: Hepatoprotective effect of *Vitis vinifera* L. leaves on carbon tetrachloride-induced acute liver damage in rats. *J Ethnopharmacol* (2007) 112: 145-151.
 20. Weltman MD, Farrell GC, Hall P, Ingelman-Sundberg M and Liddle C: Hepatic cytochrome P4502E1 is increased in patients with nonalcoholic steatohepatitis. *Hepatology* (1998) 27: 128-133.
 21. Lieber CS: CYP2E1: from ASH to NASH. *Hepatology Res* (2004) 28: 1-11.
 22. Pessayre D, Mansouri A and Fromenty B: Nonalcoholic steatosis and steatohepatitis V. Mitochondrial dysfunction in steatohepatitis. *Am J Physiol Gastrointest Liver Physiol* (2002) 282: G193-199.
 23. Sanyal AJ, Campbell-Sargent C, Mirshahi F, Rizzo WB, Contos MJ, Sterling RK, Luketic VA, Shiffman ML and Clore JN: Nonalcoholic steatohepatitis: Association of insulin resistance and mitochondrial abnormalities. *Gastroenterology* (2001) 120: 1183-1192.
 24. Leclercq IA: Antioxidant defence mechanisms: new players in the pathogenesis of non-alcoholic steatohepatitis ? *Clin Sci* (2004) 106: 235-237.
 25. Tsuda T, Ueno Y, Aoki H, Koda T, Horio F, Takahashi N, Kawada T and Osawa T: Anthocyanin enhances adipocytokine secretion and adipocyte-specific gene expression in isolated rat adipocytes. *Biochem Biophys Res Commun* (2004) 316: 149-157.

