

Acta Medica Okayama

Volume 59, Issue 4

2005

Article 8

AUGUST 2005

A thoracoscopically resected case of mediastinal parathyroid cyst.

Seiki Takashima* Hideharu Nakano[†] Kanji Minamoto[‡]
Takahiko Misao** Kunihiko Shiota^{††}

*Kagawa Prefectural Central Hospital,

[†]Kagawa Prefectural Central Hospital,

[‡]Kagawa Prefectural Central Hospital,

**Kagawa Prefectural Cancer Detection Center,

^{††}Kagawa Prefectural Central Hospital,

A thoracoscopically resected case of mediastinal parathyroid cyst.*

Seiki Takashima, Hideharu Nakano, Kanji Minamoto, Takahiko Misao, and Kunihiro Shiota

Abstract

A 67-year-old male visited his physician because of a 2-month history of cough and sputum. An abnormal shadow at the left upper mediastinum on chest x-ray film was detected, and the patient was referred to our department for further examination. Chest x-ray film revealed a round shadow at the left upper posterior mediastinum. Computed tomography(CT)revealed a uniform iso density mass about 4 cm in diameter, with a well-defined border. After the intravenous contrast administration, a slight peripheral enhancement was seen around the mass. On magnetic resonance imaging, the mass was hypointense in T1-weighting and hyperintense in T2-weighting. The contrast pattern was the same as that observed in the CT scan. On sagittal and coronal sections, the mass was adjacent to the aortic arch. Although a benign tumor was mostly suspected based on imaging findings, a malignant tumor was also possible. Accordingly, we resected this mass with video-assisted thoracoscopy. Findings at operation were a cystic mass. The pathological findings were compatible with benign parathyroid cyst, which was suspected to be the cystic degeneration of a parathyroid adenoma.

KEYWORDS: parathyroid cyst, mediastinal tumor, thoracoscopic surgery

*PMID: 16155643 [PubMed - indexed for MEDLINE]

Copyright (C) OKAYAMA UNIVERSITY MEDICAL SCHOOL

Case Report

A Thoracoscopically Resected Case of Mediastinal Parathyroid Cyst

Seiki Takashima^a, Hideharu Nakano^a, Kanji Minamoto^a,
Takahiko Misao^b, and Kunihiro Shiota^a

^aDepartment of Surgery, Kagawa Prefectural Central Hospital, Takamatsu 760-8557, Japan, and

^bDepartment of Respiratory Organ, Kagawa Prefectural Cancer Detection Center,
Takamatsu 761-8031, Japan

A 67-year-old male visited his physician because of a 2-month history of cough and sputum. An abnormal shadow at the left upper mediastinum on chest x-ray film was detected, and the patient was referred to our department for further examination. Chest x-ray film revealed a round shadow at the left upper posterior mediastinum. Computed tomography (CT) revealed a uniform iso density mass about 4 cm in diameter, with a well-defined border. After the intravenous contrast administration, a slight peripheral enhancement was seen around the mass. On magnetic resonance imaging, the mass was hypointense in T1-weighting and hyperintense in T2-weighting. The contrast pattern was the same as that observed in the CT scan. On sagittal and coronal sections, the mass was adjacent to the aortic arch. Although a benign tumor was mostly suspected based on imaging findings, a malignant tumor was also possible. Accordingly, we resected this mass with video-assisted thoracoscopy. Findings at operation were a cystic mass. The pathological findings were compatible with benign parathyroid cyst, which was suspected to be the cystic degeneration of a parathyroid adenoma.

Key words: parathyroid cyst, mediastinal tumor, thoracoscopic surgery

Macroscopic cysts of the parathyroid glands that are greater than 1 cm in diameter are referred to as parathyroid cysts. Parathyroid cysts are unusual. In particular, such a cyst in the mediastinum is quite rare [1-19]. About 10% of parathyroid cysts are located in the mediastinum [14]. Usually, the lesion is accessible from the cervical region, although in some cases a median sternotomy or thoracotomy is required. Mediastinal parathyroid cysts frequently present as a clinical diagnostic problem, because most of them present as an

asymptomatic mass on chest x-ray film or computed tomography (CT). We present a rare case of a nonfunctioning mediastinal parathyroid cyst, which was resected with video-assisted thoracoscopy instead of standard thoracotomy. We also review the related literature.

Case Report

A 67-year-old male visited his physician because of a 2-month history of cough and sputum. An abnormal shadow at the left upper mediastinum on chest x-ray film was detected, and the patient was referred to our department for further examination. On admission, his subjective symptoms had subsided. Two years before presenta-

Received March 28, 2005; accepted May 18, 2005.

*Corresponding author. Phone: +81-87-835-2222; Fax: +81-87-837-6210
E-mail: hirokiseikimitsuko@ybb.ne.jp (S. Takashima)

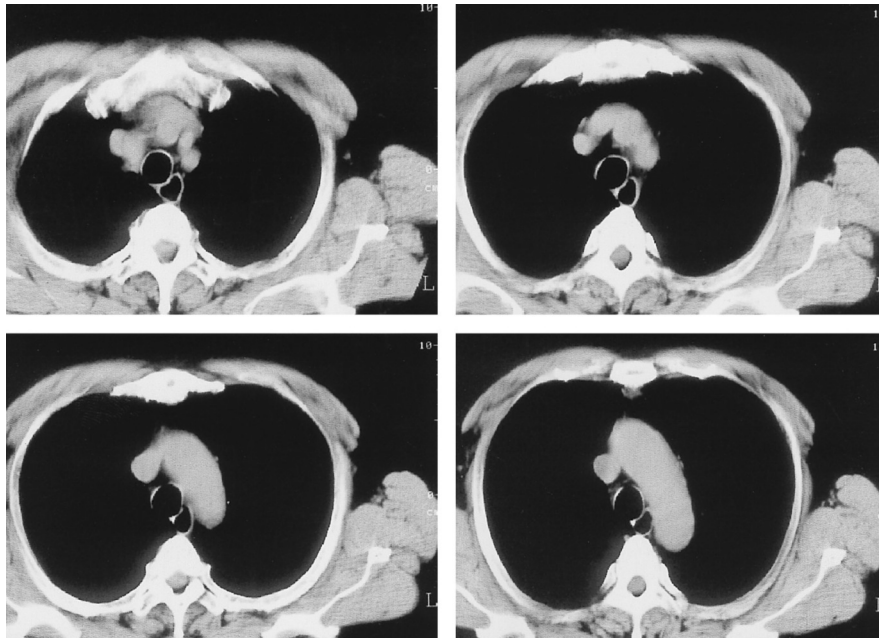


Fig. 1 This is a CT scan taken 2 years before the patient's recent presentation. This scan was taken when the patient was brought to our hospital because of a traffic accident. There was no abnormal finding.

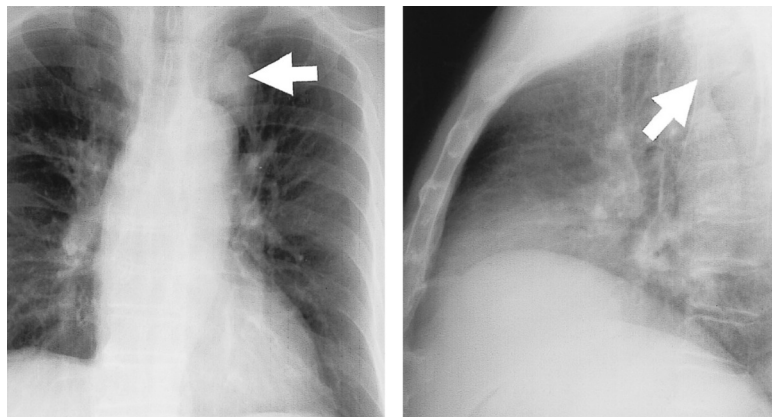


Fig. 2 Chest x-ray film revealed a round shadow at the left upper posterior mediastinum.

tion, this patient was seen at our hospital because of a traffic accident. He hit his chest, so we performed a chest x-ray examination and CT scan, but these examinations did not reveal abnormal findings (Fig. 1). Except for the injury sustained in the accident, there was no relevant past medical or family history. Physical examination was normal. No abnormalities were detected in blood chemical analysis or a lung function test, including serum levels of calcium and phosphate. A chest x-ray film revealed a

round shadow at the left upper posterior mediastinum (Fig. 2). CT scan revealed a uniform iso density mass about 4 cm in diameter, with a well-defined border. After the intravenous contrast administration, a slight peripheral enhancement was seen around the mass (Fig. 3). On magnetic resonance imaging (MRI), the mass was hypointense in T1-weighting and hyperintense in T2-weighting. The contrast pattern was the same as that observed in the CT scan (Fig. 4). On sagittal and coronal

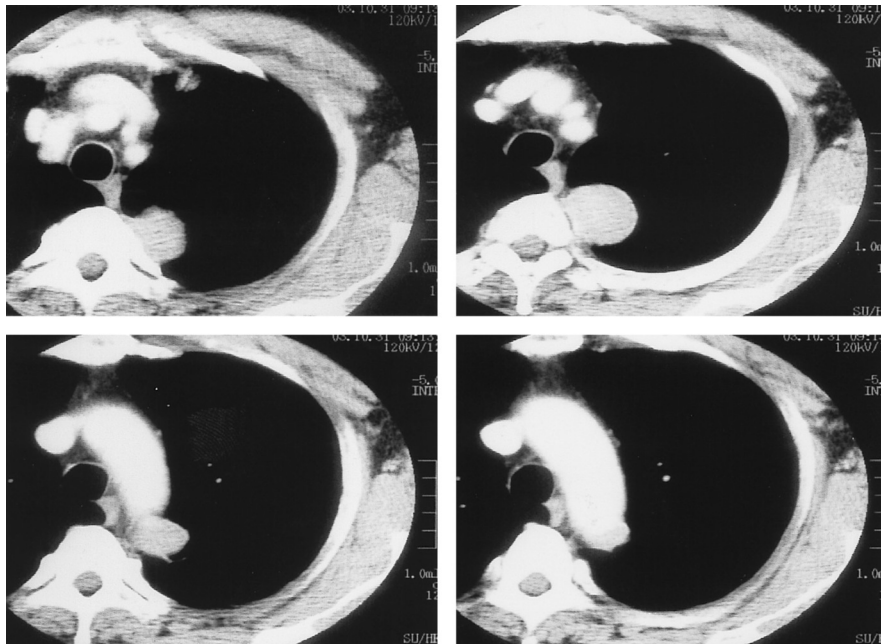


Fig. 3 CT scan revealed a uniform iso density mass about 4 cm in diameter, with a well-defined border. After the intravenous contrast administration, a slight peripheral enhancement was seen around the mass.

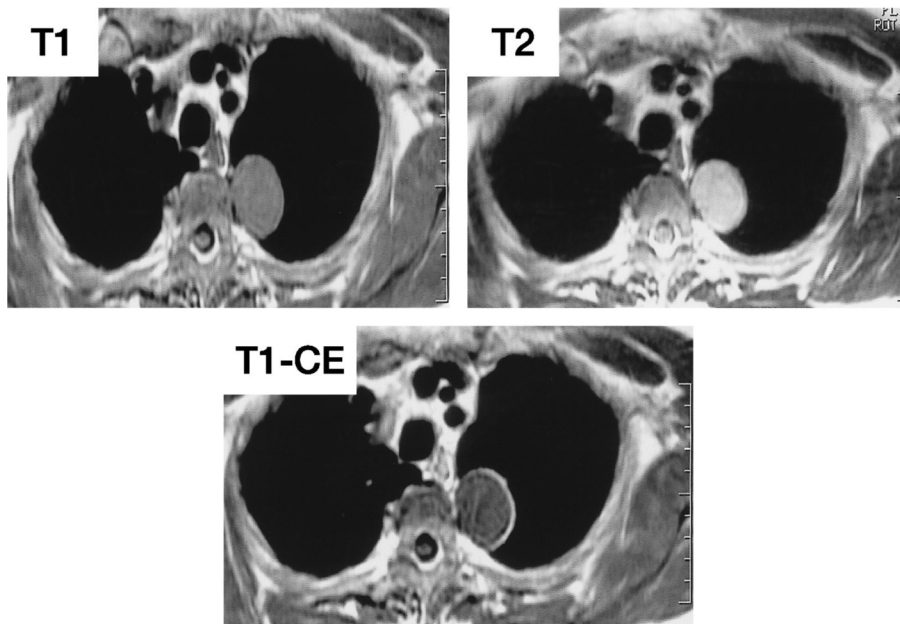


Fig. 4 On MRI, the mass was hypointense in T1-weighting and hyperintense in T2-weighting. The contrast pattern was the same as that seen on the CT scan.

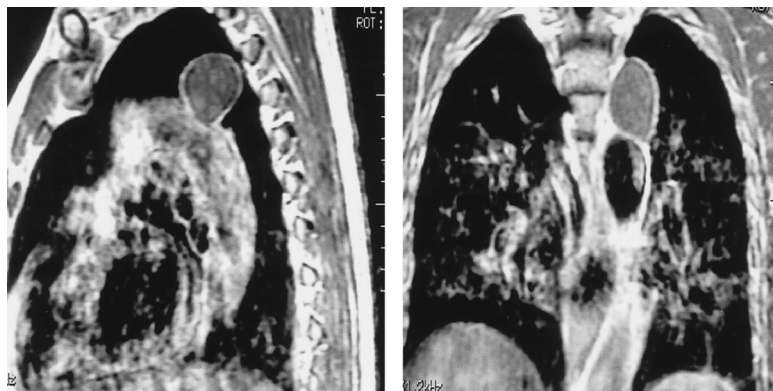


Fig. 5 On sagittal and coronal sections, the mass was adjacent to the aortic arch.

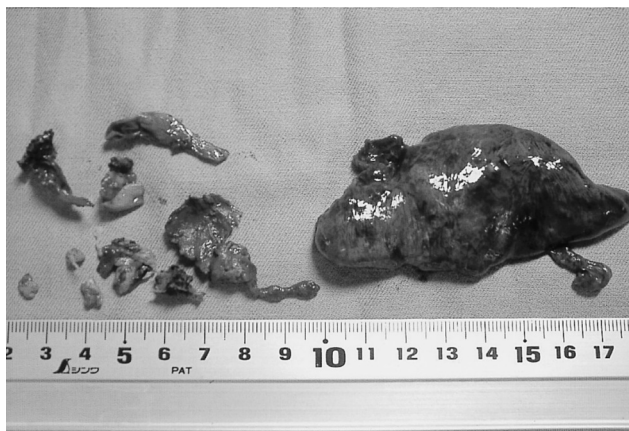

Fig. 6 We were able to divide the mass from the chest wall and lung, although we resected a portion of the left upper lobe of the lung at the same time. During the procedure, the mass broke down and clear, watery fluid was discharged. We resected most of the remnant wall with video-assisted thoracoscopy.

sections, the mass was adjacent to the aortic arch (Fig. 5).

Although a benign tumor was mostly suspected based on imaging findings, a malignant tumor was also possible because of rapid enlargement over the past 2 years. Accordingly, we elected to perform video-assisted thoracoscopy. Three small incisions were made for thoracoscopic ports. We discovered a soft and smooth surface mass with a well-defined border at the left upper posterior mediastinum. The mass was adhered to the chest wall, the left upper lobe of the lung, and the aortic arch severely. We were able to divide the mass from the chest wall and lung, although we had to resect a portion of the left upper lobe of the lung as well. During resecting, the

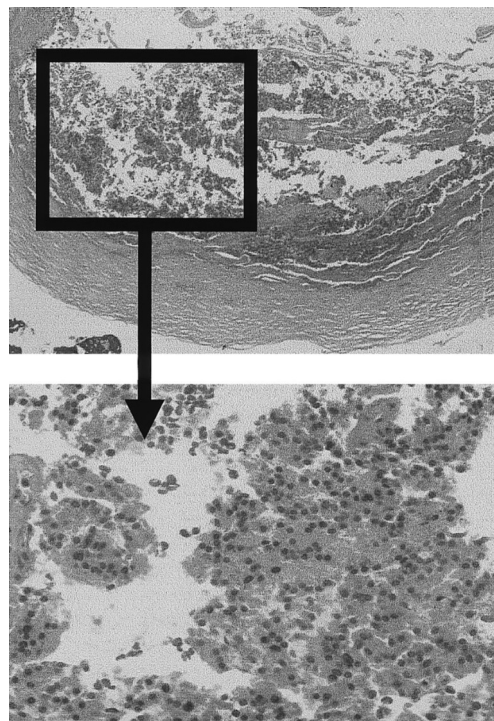


Fig. 7 Histopathologic examination revealed scattered nests of parathyroid cells within a fibrous cyst wall. The pathological findings were compatible with benign parathyroid cyst, which was suspected to be the cystic degeneration of a parathyroid adenoma.

mass broke down and clear, watery fluid was discharged. We aspirated the fluid and resected most of the remnant wall (Fig. 6). We suspected strongly that this cystic mass was not malignant, so we did not resect the portion of the wall that adhered severely to the aortic arch. We finished the operation thoracoscopically. Histopathologic

examination revealed scattered nests of parathyroid cells within a fibrous cyst wall. The pathological findings were compatible with a benign parathyroid cyst, which was suspected to be the cystic degeneration of a parathyroid adenoma. The mass had not invaded the left upper lobe of the lung, which was resected along with the mass (Fig. 7). The postoperative course was uneventful. The patient was discharged on postoperative day 6.

Discussion

Mediastinal parathyroid cysts are quite rare [1-19]. The pathogenesis of mediastinal parathyroid cysts is uncertain, although there are several theories about these cysts in the literature [5-7, 12-14, 20]. During embryogenesis, both the thymus and parathyroid gland arise from vestigial remnants of the third or fourth branchial cleft in the cervical region. Normally the parathyroid gland separates from the thymus and remains in the cervical region, when the thymus descends into the mediastinum. If it fails to separate, it may migrate into the mediastinum and become a heterotopic parathyroid gland, so most mediastinal parathyroid glands are between the cervical region and the thymus [4, 9, 14]. Usually, the lesion is accessible from the cervical region. However, some cases continue to descend into the deep mediastinum apart from the thymus and require a median sternotomy or thoracotomy. Also, it is not uncommon to find microcysts in the normal parathyroid glands and in parathyroid adenomas. Autopsy material have revealed up to 40% or 50% of asymptomatic glands containing microcysts [7, 11, 12]. Kursteiner canals have been described in fetuses, and these canals may coalesce and develop into large cysts. Furthermore, these may be enlarged by the coalescence of preexisting microcysts. Another theory is cystic degeneration of a parathyroid adenoma because of infarction or hemorrhage [13]. The majority of these cysts are nonfunctional, like the cyst in our case, but a few (less than 10%) may be functional depending on their association with hypercalcemia [4, 8, 10-13, 18].

Mediastinal parathyroid cysts frequently present as a clinical diagnostic problem. Sometime they cause hyperparathyroidism or subjective symptoms for compression of surrounding structures, including dyspnea caused by constriction of the trachea, dysphagia caused by esophageal compression, and hoarseness caused by transient paralysis of the recurrent nerve. But most of these cysts

present as an asymptomatic mass on chest x-ray film or CT scan. If the lesion is accessible from the cervical region, ultrasonography should be performed. When it reveals a cystic mass, fine-needle aspiration during ultrasonography is very helpful for diagnosis and therapy, especially for nonfunctional cysts. The diagnosis may be confirmed by assaying the parathyroid hormone from the fluid aspirate [8, 14]. In most case, cysts disappear and don't reaccumulate following aspiration. There have been several reports in the literature to support fine-needle aspiration as a therapeutic modality [12, 14, 15].

In our case, the mass was far from the cervical region. Recently, there were several reports of mediastinal parathyroid cysts resected with video-assisted thoracoscopy in Japan [16-19]. In these cases, parathyroid cysts were in the anterior or middle mediastinum and close to the thymus, unlike our case. Furthermore, our case didn't have findings of hyperparathyroidism, so we were not able to imagine a parathyroid cyst. Initially, we considered a mediastinal tumor, such as a neurogenic tumor or an aneurysm of the aorta. A neurogenic tumor seemed especially likely because of the cyst's typical location. Based on the enhanced CT scan and MRI findings, we excluded an aneurysm of the aorta. We mostly suspected a benign mediastinal neurogenic tumor, but because the mass had enlarged rapidly over the past 2 years, a malignant tumor was also possible. Accordingly, we elected to perform video-assisted thoracoscopy for diagnosis and therapy, because this method is a minimally invasive technique. The findings at operation were a cystic mass with a soft and smooth surface and a well-defined border, although adhesion to the surround structures was severe. We suspected strongly that this cystic mass was not malignant. Unfortunately, the mass broke down during surgery, and we were not able to resect the mass completely. However, we finished the operation under the thoroscope. If there had been findings of malignancy in our histopathologic examination, we intended to perform re-operation with standard thoracotomy and resect the remnant wall completely. The presence of parathyroid tissue within the cyst wall was diagnostic, and there were no clear findings of malignancy.

In conclusion, we presented a rare case of nonfunctioning mediastinal parathyroid cyst, which was resected with video-assisted thoracoscopy instead of standard thoracotomy. We have also reviewed the related literature. The operation with video-assisted thoracoscopy can

be safe and successful for diagnosis therapy, especially when a benign tumor is suspected.

References

1. Wood JW, Johnson KG and Hinds MJ: Parathyroid cysts. *Arch Surg* (1966) 92: 785-790.
2. Rogers LA, Fetter BF and Peete WP: Parathyroid cyst and cystic degeneration of parathyroid adenoma. *Arch Pathol* (1969) 88:476-479.
3. Thacker WC, Wells VH and Hall ER Jr: Parathyroid cyst of the mediastinum. *Ann Surg* (1971) 174: 969-975.
4. Seltzer SE, Balikian JP, Birnholz JC, Hargreaves H, Cartier P and Herman PG: Giant hyperplastic parathyroid gland in the mediastinum-partially cystic and calcified. *Radiology* (1978) 127:43-44.
5. Clark OH: Parathyroid cysts. *Am J Surg* (1978) 135: 395-402.
6. Calandra DB, Shah KH, Prinz RA, Sullivan H, Hofmann C, Oslapas R, Ernst K, Lawrence AM and Paloyan E: Parathyroid cysts: a report of eleven cases including two associated with hyperparathyroid crisis. *Surgery* (1983) 94: 887-892.
7. Katz AD and Dunkleman D: Needle aspiration of nonfunctioning parathyroid cysts. *Arch Surg* (1984) 119: 307-308.
8. Krudy AG, Doppman JL, Shawker TH, Spiegel AM, Marx SJ, Norton J, Schaaf M, Moss ML, Weiss MA and Schachner SH: Hyperfunctioning cystic parathyroid glands: CT and sonographic findings. *AJR Am J Roentgenol* (1984) 142: 175-178.
9. Togashi K, Sato Y and Yazawa M: Mediastinal parathyroid cyst. *Nippon Kyobu Geka Gakkai Zasshi* (1991) 39: 1117-1120 (in Japanese).
10. Sanchez A and Carretto H: Treatment of a nonfunctioning parathyroid cyst with tetracycline injection. *Head Neck* (1993) 15: 263-265.
11. Lydiatt DD, Byers RM, Khouri KG, Whitworth PW and Sellin RV: Functional parathyroid cyst and hypocalciuric hypercalcemia. *Ear Nose Throat J* (1993) 72: 142-144.
12. Gurbuz AT and Peetz ME: Giant mediastinal parathyroid cyst: an unusual cause of hypercalcemic crisis -case report and review of the literature. *Surgery* (1996) 120: 795-800.
13. Shimizu M, Akamatsu H, Yoshizaki T, Tanaka H, Sakamoto T and Sunamori M: Thoracoscopic resection of mediastinal parathyroid adenoma with cyst and hyperparathyroidism -a case report-. *Nippon Kyobu Geka Gakkai Zasshi* (1997) 45: 1972-1975 (in Japanese).
14. Umemori Y, Makihara S, Kotani K and Washio K: Mediastinal parathyroid cyst with tracheal constriction. *Jpn J Thorac Cardiovasc Surg* (2002) 50: 85-87.
15. Fortson JK, Patel VG and Henderson VJ: Parathyroid cysts: a case report and review of the literature. *Laryngoscope* (2001) 111: 1726-1728.
16. Shibata Y, Niwa H, Yamada T, Kani H, Maemoto K and Mizuno T: Mediastinal parathyroid cyst: a case resected under video assisted thoracoscopic surgery. *Nihon Kokyuki Geka Gakkai Zasshi (Jpn J Chest Surg)* (1998) 12: 676-680 (in Japanese).
17. Oyama T, Imoto H, Yasumoto K, Toyoshima S and Nagashima A: Mediastinal parathyroid cyst: treatment with thoracoscopic surgery — a case report —. *J UOEH* (1999) 21: 317-321.
18. Mishima O, Fukai M and Yokota R: A case of functioning parathyroid adenoma with cyst in the upper mediastinum resected by thoracoscopic surgery. *Nihon Kokyuki Geka Gakkai Zasshi (Jpn J Chest Surg)* (2003) 17: 505-510 (in Japanese).
19. Kitami A, Suzuki T, Usuda R, Masuda M and Suzuki S: Diagnostic and therapeutic thoracoscopy for mediastinal disease. *Ann Thorac Cardiovasc Surg* (2004) 10: 14-18.
20. Prinz RA, Lonchyna V, Carnaille B, Wurtz A and Proye C: Thoracoscopic excision of enlarged mediastinal parathyroid glands. *Surgery* (1994) 116: 999-1005.