

Acta Medica Okayama

Volume 63, Issue 6

2009

Article 7

DECEMBER 2009

Estimation of Carrying Angle Based on CT Images in Preoperative Surgical Planning for Cubitus Deformities

Shinsuk Park*

Eugene Kim[†]

*Department of Mechanical Engineering, Korea University,

[†]Department of Orthopedic Surgery, Kangbuk Samsung Hospital, Sungkyunkwan University
School of Medicine,

Copyright ©1999 OKAYAMA UNIVERSITY MEDICAL SCHOOL. All rights reserved.

Estimation of Carrying Angle Based on CT Images in Preoperative Surgical Planning for Cubitus Deformities

Shinsuk Park and Eugene Kim

Abstract

Conventionally, the carrying angle of the elbow is measured using simple two-dimensional radiography or goniometry, which has questionable reliability. This study proposes a novel method for estimating carrying angles using computed tomography that can enhance the reliability of the angle measurement. Data of CT scans from 25 elbow joints were processed to build segmented three-dimensional models. The cross-sectional centerlines of the ulna and the humerus were traced from the 3D models, and the angle between 2 vectors formed from the centerlines of the humerus and the ulna was defined as the “three-dimensional carrying angle.” These angles were compared with those measured by simple radiograph. Two cases of angular deformity were underwent surgery based on this preoperative surgical planning, and the postoperative 3D carrying angles were evaluated using the proposed method. The mean value of the calculated three-dimensional carrying angle was 20.7 degrees \pm 3.61, while it was 16.3 degrees \pm 3.21 based on simple radiography without statistical difference. Based on the 3D carrying angle estimations, 2 surgical cases of cubitus deformities were planned by comparison with the normal contra-lateral elbow. Postoperative angle estimations confirmed that the corrected angles were nearly identical to the planned angles for both cases. The results of this study showed that the carrying angle can be accurately estimated using three-dimensional CT and that the proposed method is useful in evaluating deformities of the elbow with high reliability.

KEYWORDS: elbow, carrying angle, computed tomography

Original Article

Estimation of Carrying Angle Based on CT Images in Preoperative Surgical Planning for Cubitus DeformitiesShinsuk Park^a and Eugene Kim^{b*}^aDepartment of Mechanical Engineering, Korea University, Seoul 136-713, Republic of Korea, and^bDepartment of Orthopedic Surgery, Kangbuk Samsung Hospital, Sungkyunkwan University School of Medicine, Seoul 110-746, Republic of Korea

Conventionally, the carrying angle of the elbow is measured using simple two-dimensional radiography or goniometry, which has questionable reliability. This study proposes a novel method for estimating carrying angles using computed tomography that can enhance the reliability of the angle measurement. Data of CT scans from 25 elbow joints were processed to build segmented three-dimensional models. The cross-sectional centerlines of the ulna and the humerus were traced from the 3D models, and the angle between 2 vectors formed from the centerlines of the humerus and the ulna was defined as the "three-dimensional carrying angle." These angles were compared with those measured by simple radiograph. Two cases of angular deformity were underwent surgery based on this preoperative surgical planning, and the postoperative 3D carrying angles were evaluated using the proposed method. The mean value of the calculated three-dimensional carrying angle was $20.7^\circ \pm 3.61$, while it was $16.3^\circ \pm 3.21$ based on simple radiography without statistical difference. Based on the 3D carrying angle estimations, 2 surgical cases of cubitus deformities were planned by comparison with the normal contra-lateral elbow. Postoperative angle estimations confirmed that the corrected angles were nearly identical to the planned angles for both cases. The results of this study showed that the carrying angle can be accurately estimated using three-dimensional CT and that the proposed method is useful in evaluating deformities of the elbow with high reliability.

Key words: elbow, carrying angle, computed tomography

The elbow joint is generally modeled as a hinged joint for flexion and extension although several reported have indicated that it has complex rotation movement in three-dimensional space [1-5]. The carrying angle of the elbow is clinically determined from the longitudinal axes of the upper arm and the forearm. It is usually estimated anatomically and radiologically from the angle formed by the long axes of the

humerus and the ulna. Generally, the carrying angle of the elbow is assessed with the elbow fully extended and the forearm fully supinated and is measured with a goniometer or a simple radiographic image.

Carrying angle measurements have been reported in the literature based on various methodologies. The first published study of the carrying angle may have been the estimation of obliquity of the arm in a female by Potter in 1895 [6]. Conventionally, goniometers were applied to the arms to estimate the carrying angle [6-11]. Since Steel and Tomlinson used a simple radiograph in 1958 [12], many studies have

Received March 23, 2009; accepted August 10, 2009.

*Corresponding author. Phone:+82-2-2001-2168; Fax:+82-2-2001-2176
E-mail:eugene0809@skku.edu (E. Kim)

employed radiographic measurements in estimating the carrying angle [3, 13–15]. Other researchers have reported data from cadaveric studies *in vitro* [4, 16].

The mean values of the carrying angles, as reported by different authors, show considerable differences: 12.7° in females and 6.8° in males by Potter [6], 13° and 11° by Keats *et al.* [15], 15° and 11° by Baughman *et al.* [17], 14° and 11° by Amis and Miller [7], 16.9° and 13.6° by Khare *et al.* [9], and 16.7° and 11.6° by Van Roy [18]. Beals [13] and Zampagni *et al.* [19], however, reported no sexual differences. Meanwhile, there have been very few studies of the equipment used to measure the carrying angle except other than goniometers and simple radiographs.

In this precursor study we propose a novel method for estimating carrying angles using computed tomography (CT) scans. The two-dimensional CT images are processed to build a segmented three-dimensional model. The center lines of the humerus and the ulna are estimated from the three-dimensional model, and the carrying angle is estimated based on those center lines. The validity of the proposed method was assessed by comparing the angle estimations with those from the simple radiographs. Closed-wedge corrective osteotomy for cubitus valgus and varus deformities was performed in 2 cases based on the proposed method using preoperative medical images.

Materials and Methods

Material. Data from CT scans of the elbow from 25 subjects were analyzed for this study. Fifteen males and 10 females with a mean age of 37.3 ± 15.2 years (range, 23–89 years) were scanned on CT, and the three-dimensional estimations of the carrying angle were compared with the direct measurements on the simple radiologic study. Cases with fractures or limited ranges of extension motion at the elbow joints were excluded.

One male (27-year old) with cubitus valgus deformity and 1 female (23-year old) with cubitus varus deformity underwent surgery for correction under surgical planning based on the preoperative images of the arms, and the surgical outcomes were evaluated by estimating the postoperative 3D carrying angles. For the operations, we obtained approval from the local ethics committee as well as written informed

consent from both participants.

Image processing. CT scans (Brilliance 40, Philips, Best, Netherlands) were taken for the arms of the subjects. The CT images were processed to segment a three-dimensional volumetric model of the arm using an image software package, 3D-Slicer (Surgical Planning Laboratory, Brigham and Women's Hospital, Boston, MA, USA). The voxel size for the CT scan was $0.586 \times 0.586 \times 1.25$ mm, which was a high enough resolution to visualize the humerus and the ulna. Fig. 1 and 2 show the two-dimensional CT image and the segmented three-dimensional image of the arm, respectively. The humerus and the ulna were segmented out from the three-dimensional model obtained from the CT images of the arm (Fig. 1).

Estimation of the 3D carrying angle. From the segmented 3D models of the humerus and the ulna, two-dimensional images of the transverse sections were obtained. From the transverse section images, the cross-sectional centerlines of the humerus and the ulna were traced using FreeForm software (SensAble, Inc., Cambridge, MA, USA). Fig. 2 shows the centerlines of the humerus and the ulna.

As can be seen in the figure, the centerlines are not straight for either the humerus or the ulna. To determine the 3D carrying angle, 2 points on the centerline were chosen for the humerus and the ulna, respectively making the distances from the center of the

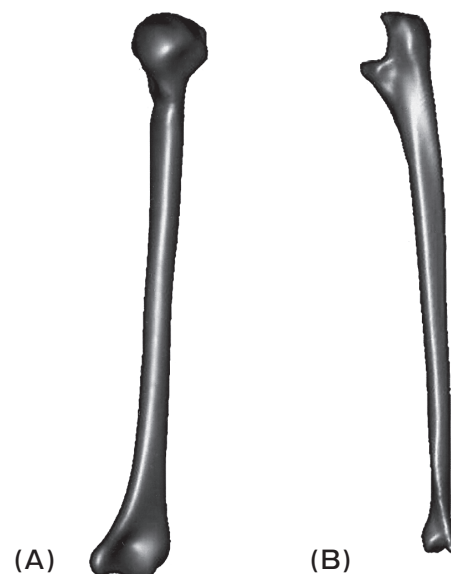

Fig. 1 Segmented models of the arm. A, Humerus; B, Ulna.

trochlea 1/3 and 2/3 of the length of the humerus and the ulna, respectively. To determine the center of the trochlea, the transverse cross-section of the trochlea, which has the narrowest concave region, was chosen, and then the midpoint of the concave portion was chosen as the center of the trochlea, as illustrated in Fig. 3.

The lines connecting the 2 points on the centerline of the humerus and the ulna form 2 vectors \mathbf{x}_h and \mathbf{x}_u , respectively (Fig. 4). In this study, the angle between the 2 vectors (\mathbf{x}_h in the humerus and \mathbf{x}_u in the ulna) is defined as the 3D carrying angle. The 3D carrying angle can be determined by the following equation:

$$\mathbf{x}_h \cdot \mathbf{x}_u = |\mathbf{x}_h| |\mathbf{x}_u| \cos \theta$$

$$\theta = \cos^{-1} \frac{\mathbf{x}_h \cdot \mathbf{x}_u}{|\mathbf{x}_h| |\mathbf{x}_u|}$$

Estimation of carrying angle using simple radiology.

For comparison with the 3D carrying angle estimation, simple radiographs were taken from an anterior-posterior view with the elbow fully extended and supinated. Using the same standard reported by Beals [13], 2 midpoints in the distal humerus and 2 midpoints in the proximal ulna were

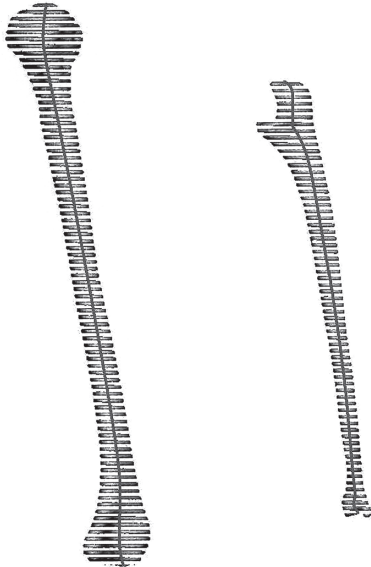


Fig. 2 Centerlines of humerus and ulna.

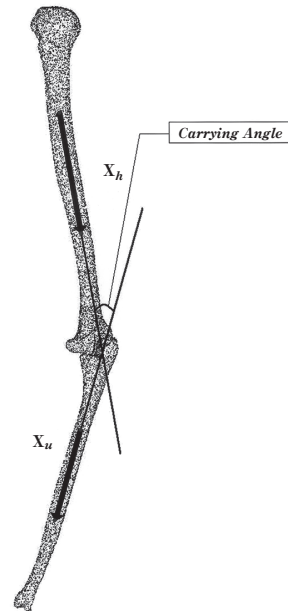


Fig. 4 The 3D carrying angle between two vectors \mathbf{x}_h in the humerus and \mathbf{x}_u in the ulna.

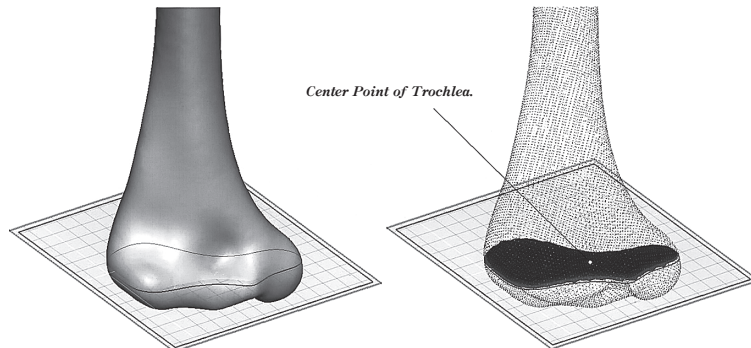


Fig. 3 Center point of trochlea.

chosen and the acute angle of the 2 lines that connect these midpoints was measured. To reduce inter- and intra-observer error, the 2 authors (SS Park and E Kim) evaluated the angles and the mean values were accepted as the carrying angle from the simple radiograph. The inter-observer reliability was evaluated by calculating the Interclass Correlation Coefficient (ICC) using SPSS 9.0 statistical software (SPSS Inc, Chicago, IL, USA) for Windows (Microsoft, Redmond, WA, USA). The ICC value was calculated to be 0.794, which indicates acceptably high inter-observer reliability (> 0.70).

Surgical planning for correction of cubitus deformity. The above-mentioned procedure for 3D carrying angle estimation can also be applied for the planning of surgical correction of elbow deformity. For 2 patients with cubitus varus and valgus deformities, CT scans were taken for both arms. The three-dimensional volumetric models of the arms were segmented out from the two-dimensional CT images. Among the models of the 2 arms with normal and deformed elbows, the image of the normal arm was converted to make mirror images and 2 segmented 3D models of both sides were overlapped so that the ulna and radius of the converted image matched with those of the other side (Fig. 5). From the overlapped image, the centerlines and vectors in the 2 humeri were then determined using the same method mentioned above. The angle difference between the 2 vectors of the

humeri is the same as the difference in the 3D carrying angles of the 2 arms. This angle difference was determined as the wedge angle for corrective osteotomy.

Conventional closed wedge osteotomy was applied to correct the carrying angle. Operations were performed through a posterior approach with the patient in a lateral position. Ulnar nerve transposition was performed in the cubitus varus case to prevent ulnar neuropathy. A sterilized triangular film with the preplanned correction angle was placed on the bone surface of the distal humerus just above the olecranon fossa. Osteotomy was performed along the margin of the triangle by electrical saw and the 2 fragments were fixed with K-wire and tension band wiring (Fig. 6). After the corrective surgeries, postoperative CT scans were taken for the 2 patients. Using the same procedure to estimate the 3D carrying angle, the carrying angles of the corrected arms were measured. The corrected carrying angles were compared with the target carrying angles determined by surgical planning.

Results

Comparison of 3D carrying angle with conventional estimation using simple radiography.

Table 1 compares the three-dimensional estimations of carrying angles with the estimations using a simple radiograph for 25 arms. The difference between the 2 estimations was restricted to a mean of 4.4° . The maximum difference between the estimations was 9.4° , the minimum difference 1.3° . The mean values of the 3D carrying angles were 19.8° in males and 22.1° in females. The 3D carrying angles ranged from 13.5° to 26.4° in the male subjects and from 15.9° to 27.0° in the female subjects. The mean values of carrying angle measured by simple radiography were 14.9° in male and 18.3° in females. The measured carrying angles ranged from 11.0° to 19.0° in the male and from 14.0° to 23.0° in the female, respectively.

As can be seen from the table, the 3D carrying angle estimations appear slightly larger than those from simple radiography. There appears, however, no statistically significant difference between the 2 estimations based on a paired *t*-test ($p < 0.05$). Additionally, the Interclass Correlation Coefficient (ICC) was calculated to evaluate the inter-method reliability

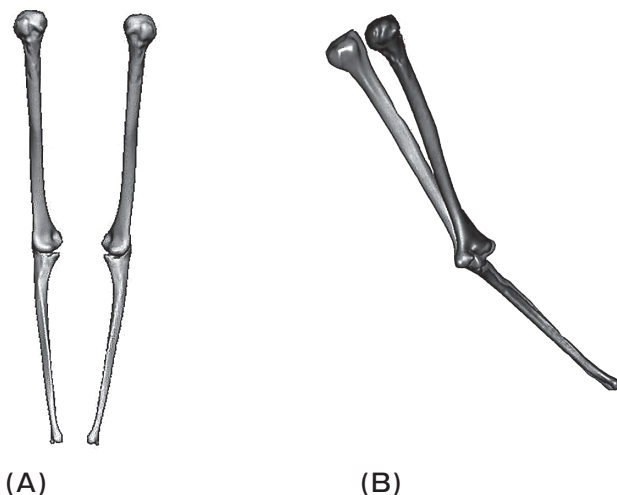


Fig. 5 Formed mirror images of humerus and ulna. A, Mirror images of both arms; B, Overlapped mirror images.

of the 2 methods. A high correlation between the 2 estimation methods was found ($ICC = 0.859 > 0.70$).

Comparison of the corrected carrying angle with that of the contralateral side using surgical planning. Table 2 compares the corrected carrying angle and the carrying angle of the normal side

determined by surgical planning, both estimated using 3D CT scan and simple radiography. Using the 3D carrying angle estimation, the wedge angles for closed wedge osteotomy, which are the differences between the carrying angles of the deformed and normal sides, were set to 30.9° (from -27.4° to 3.5°) for patient 1

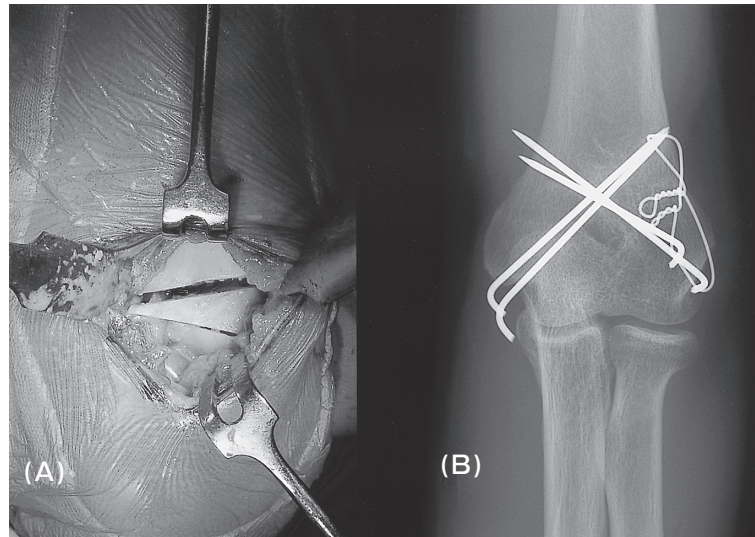


Fig. 6 Close wedge osteotomy through posterior approach. A, Operative finding; B, Post-operative X ray.

Table 1 Comparison of 3D Carrying angle with conventional estimation using simple radiography

| Method | 3D Carrying Angle | | | Simple Radiographic Carrying Angle | | |
|--------------------|-------------------|-----------|-----------|------------------------------------|-----------|-----------|
| | Male | Female | Total | Male | Female | Total |
| Mean | 19.8 | 22.1 | 20.7 | 14.9 | 18.3 | 16.3 |
| Standard Deviation | 3.42 | 4.61 | 3.61 | 2.60 | 4.38 | 3.21 |
| Range | 13.5–26.4 | 15.9–27.0 | 13.5–27.0 | 11.0–19.0 | 14.0–23.0 | 11.0–23.0 |

Table 2 Comparison of the corrected carrying angle with the target carrying angle by surgical planning

| | | Patient 1 | Patient 2 |
|--|--------------------|-----------|-----------|
| 3D CT | Pre-operative | -27.4 | 27.2 |
| | Contralateral side | 3.5 | 18.5 |
| | Post-operative | 3.0 | 16.7 |
| Simple Radiography | Pre-operative | -24.2 | 25.1 |
| | Contralateral side | 5.0 | 15.1 |
| | Post-operative | 2.5 | 13.1 |
| Difference between Target and Corrected Angles | 3D CT | 0.5 | 1.8 |
| | Simple Radiography | 2.5 | 2.0 |

and 8.7° (from 27.2° to 18.5°) for patient 2, respectively. From the estimation based on simple radiography, the wedge angles for corrective osteotomy were set to be 29.2° and 10.0° . The differences between the target and corrected angles were less than or equal to 2.5° in both estimation methods, which suggests that the corrective osteotomy was carried out successfully for the 2 patients (Table 2).

Discussion

While various estimation methods of the carrying angle have been reported, the data reported by different authors show considerable differences, as these studies have been based on different definitions of the carrying angle as well as different methodologies. The most commonly used method uses radiography of the arm that is fully extended and fully supinated. This method may incorporate measurement errors even when the same examiner measures the same angle (low test-retest reliability). These measurement errors can only be reduced by repeated measurements taken by the same examiner with the same instrument. There have been few literature reports regarding the reliability of any specific methodology, except for a brief mention as a result of recent biomechanical studies [18, 19].

In this preliminary study, we propose a novel method to estimate the carrying angle using computed tomography (CT) scan. Three-dimensional models segmented from two-dimensional CT images were used to yield the centerlines of the long bones in the arm. The three-dimensional carrying angle was estimated based on the centerlines of the humerus and the ulna.

The three-dimensional carrying angles were estimated for 25 elbows and were compared with the angles measured from two-dimensional radiographs. While no statistical differences were found between the three-dimensional and two-dimensional carrying angles in this study, the 3D carrying angles were estimated to be slightly larger than the angles from simple radiography. These results seem reasonable, since the 3D carrying angle is the largest angle that can be measured, while simple radiography can only provide the projection of the 3D angle on a plane. In addition, better accuracy and repeatability can be expected with the procedure using 3D CT scan, although the level of radiation exposure from CT scan

is higher than that from simple radiology. With radiography, there are inevitably inter-observer and intra-observer variations when measuring the angle from radiograph, as well as posture variations when the radiography is performed.

In the present study, 2 cases of cubitus deformities were corrected by closed-wedge osteotomy based on surgical planning with preoperative correction angle estimation using 3D CT scans. The corrected angles were compared with the planned correction angles, and those angles were nearly identical for both cases.

To our knowledge, this is the first study to use three-dimensional CT models in estimating the carrying angle. The proposed method for carrying angle estimation can be used to assess anatomical and functional features of the elbow joint. The method can also be combined with computer technologies to guide surgical navigation for better surgical outcomes [20].

We are currently working on a reliability assessment with more demographic data by comparing the proposed method with conventional methods. In our future work we will develop a preoperative simulation system by using rapid prototype technology. Using the simulation system, the surgeon can actually perform osteotomy on the prototype models of the bones, as well as osteotomy simulation in a 3D virtual reality environment. To further ensure surgical precision, we will investigate intraoperative surgical navigation using 3D digital measurement systems that which can guide the surgeon to perform preplanned procedures determined by surgical planning.

The application of the proposed method is limited to the CT scans of fully supinated and extended elbow joints. Further study is needed to address the three-dimensional relationship between the axes of the long bones and the rotational axis at the elbow joint, which allows us to estimate the carrying angle independent of the posture of the arm.

Acknowledgments. The authors would like to thank Mr. Yongwon Dong (Dept. of Mechanical Engineering, Korea University), Professor Min-Hee Lee (Dept. of Radiology, Kangbuk Samsung Hospital), and Dr. Jimmyung Lee (Dept. of Orthopedic Surgery, Kangbuk Samsung Hospital) for their scientific supports and advices.

This work was supported by Korea Science and Engineering Foundation Grant R01-2007-000-20977-0 funded by the Korean Ministry of Education, Science and Technology.

References

1. Chao EY and Morrey BF: Three-dimensional rotation of the elbow joint. *J Biomech* (1978) 11: 57–73.
2. Ishizuki M: Functional anatomy of the elbow joint and three-dimensional quantitative motion analysis of the elbow joint. *J Jap Orthop Ass* (1979) 53: 989–996.
3. London JT: Kinematics of the elbow. *J Bone Joint Surg Am* (1981) 63: 529–535.
4. Morrey BF and Chao EY: Passive motion of the elbow joint. *J Bone Joint Surg Am* (1976) 58: 501–508.
5. Youm Y, Dryer RF, Thambyrajah K, Flatt AE and Sprague BL: Biomechanical analyses of forearm pronation-supination and elbow flexion-extension. *J Biomech* (1979) 12: 245–255.
6. Potter HP: The obliquity of the arm of the female in extension. The relationship of the forearm with the upper arm in flexion. *J Anat Physiol* (1895) 29: 488–491.
7. Amis AA and Miller JH: The elbow. *Clin Rheum Dis* (1982) 8: 571–593.
8. Balasubramanian P, Madhuri V and Muliylil J: Carrying angle in children. A normative study. *J Pediatr Orthop B* (2006) 15: 37–40.
9. Khare GN, Goel SC, Saraf SK, Singh G and Mohanty C: New observations on carrying angle. *Indian J Med Sci* (1999) 53: 61–67.
10. Paraskevas G, Papadopoulos A, Papaziogas B, Spanidou S, Argiriadou H and Gigis J: Study of the carrying angle of the human elbow joint in full extension. A morphometric analysis. *Surg Radiol Anat* (2004) 26: 19–23.
11. Yilmaz E, Karakurt L, Belhan O, Bulut M, Serin E and Avci M: Variation of carrying angle with age, sex, and special reference to side. *Orthopedics* (2005) 28: 1360–1363.
12. Steel FL and Tomlinson JD: The carrying angle in man. *J Anat* (1958) 92: 315–317.
13. Beals RK: The normal carrying angle of the elbow. A radiographic study of 422 patients. *Clin Orthop Relat Res* (1976) 119: 194–196.
14. Keats TE, Teeslink R, Diamond AE and Williams JH: Normal axial relationships of the major joints. *Radiology* (1966) 87: 904–907.
15. Shiba R, Sorbie C, Siu DW, Bryant JT, Cooke D and Wevers HW: Geometry of the humeroulnar joint. *J Orthop Res* (1988) 6: 897–906.
16. An KN, Morrey BF and Chao EY: Carrying angle of the human elbow joint. *J Orthop Res* (1984) 1: 369–378.
17. Baughman FA Jr, Higgins JV, Wadsworth TG and Demaray MJ: The carrying angle in sex chromosome anomalies. *JAMA* (1974) 230: 718–720.
18. Van Roy P, Baeyens JP, Fauvart D, Lanssiers R and Clarijs JP: Arthro-kinematics of the elbow. Study of the carrying angle. *Ergonomics* (2005) 48: 1645–1656.
19. Zampagni ML, Casino D, Martelli S, Visani A and Marcacci MJ: A protocol for clinical evaluation of the carrying angle of the elbow by anatomic landmarks. *J Shoulder Elbow Surg* (2008) 17: 106–112.
20. Park S, Howe R and Torchiana D: Virtual fixtures for robotic cardiac surgery. *Lecture Notes in Computer Science* (2001) 2208: 1419–1420.